

ORIGINAL ARTICLE

DETECTION OF BREAST CANCERS REPRESENTED AS ARCHITECTURAL DISTORTION: A COMPARISON OF FULL-FIELD DIGITAL MAMMOGRAPHY AND DIGITAL BREAST TOMOSYNTHESIS

DOI: 10.36740/WLek202107121

Tetiana M. Babkina¹, Andrii V. Gurando^{2,4}, Tetiana M. Kozarenko¹, Viacheslav R. Gurando³, Vadim V. Telniy⁴, Denys V. Pominchuk⁴

¹P.L. SHUPYK NATIONAL MEDICAL ACADEMY OF POSTGRADUATE EDUCATION, KYIV, UKRAINE

²SI, "INSTITUTE OF NUCLEAR MEDICINE AND DIAGNOSTIC RADIOLOGY OF NATIONAL ACADEMY OF MEDICAL SCIENCE OF UKRAINE", KYIV, UKRAINE

³UZHGOROD NATIONAL UNIVERSITY, UZHGOROD, UKRAINE

⁴MEDICAL CENTER «VERUM EXPERT», KYIV, UKRAINE

ABSTRACT

The aim: The aim of our study was to determine if digital breast tomosynthesis improves breast cancer detection associated with architectural distortion in comparison with full-field digital mammography in the absence of appropriate history of trauma or surgery.

Materials and methods: The overall rate of breast cancer involvement for the 34 patients with architectural distortion was 15 cases (44,1%) (invasive breast cancers, n=12 (36,4%); ductal cancer in situ, n= 3 (8,8%)) other findings associated with architectural distortion were high-risk lesions and benign findings (radial scar, n=5 (14,7%); sclerosing adenosis, n=9 (26,5%); typical lobular hyperplasia, n=3 (8,8%); typical ductal hyperplasia, n=2 cases (5,9%)).

Results: Overall of 17/34 (50.0%) architectural distortions were identified at digital breast tomosynthesis that were missed at full-field digital mammography what was statistically significant difference ([95% CI, 2.56–7.45]; p=0.00001). Analysis of the results showed that sensitivity of full-field digital mammography for digital breast tomosynthesis detected breast cancers associated with architectural distortion was 53.3% [95% CI, 26.59% to 78.73%] and specificity was 52.63% [95% CI, 28.86% to 75.55%].

Conclusions: Our study suggests that digital breast tomosynthesis detects more breast cancers represented as architectural distortion which are occult on full-field digital mammography. Presence of microcalcifications within architectural distortion, in the absence of appropriate history of trauma or surgery, has a high likelihood of malignancy and obligatorily requires biopsy.

KEY WORDS: Breast cancer, architectural distortion, digital breast tomosynthesis, full-field digital mammography

Wiad Lek. 2021;74(7):1674-1679

INTRODUCTION

Breast cancer (BC), takes the first place among oncologic diseases in Ukrainian woman. According to the latest data of national cancer-register in 2018 year there were detected 14 872 female BC and 145 male BC [1].

Mammography is the cornerstone of population-based BC screening [2]. Early detection during mammography screening and optimal treatment can reduce BC mortality rate by 38–48% [3].

However, there are still difficulties in the differential diagnosis of masses, architectural distortions (ADs), asymmetries and normal breast tissue due to the summation artifact of tissue structures, which are located in different planes [4]. As follows we need to perform additional imaging, which worsens the psycho-emotional conditions of the woman, increases their anxiety and radiation dose on their breasts.

AD is thin straight lines or spiculations radiating from a point, and focal retraction, distortion, or straightening at the anterior or posterior edge of the parenchyma with no definite mass visible [5]. AD is not always a sign of cancer and may represent different benign processes and high-risk lesions, such as sclerosing adenosis, radial scars, complex sclerosing lesions and changes associated with surgery or trauma (fat necrosis) which should stabilize and/or regress eventually [6].

AD accounts for 12% to 45% of BC cases missed during screening mammography and are the third most prevalent mammographic appearance of BC [7, 8].

Relatively new technology – 3D mammography, which calls digital breast tomosynthesis (DBT), acquisition of tomosynthesis images, an x-ray source takes a series of low-dose exposures, providing multiple images of the breast in different planes that are 3D reconstructed, while moving in a limited arc above the compressed breast [9].

Table I. Study population characteristics

Patients with architectural distortion	34
Mean age, years	49
Microcalcifications within architectural distortions	15 (44%)
Non-dense breast, (ACR:a,b)	12 (35%)
Dense breast, (ACR:c,d)	22 (65%)
Breast cancers associated with architectural distortions	15 (44%)
Breast cancers associated with architectural distortions and microcalcifications	9 (27%)

Table II. ACR breast density distribution for BC associated with AD

ACR: a	0 (0%)
ACR: b	5 (33%)
ACR: c	6 (40%)
ACR: d	4 (27%)

THE AIM

The aim of our study was to determine if DBT improves BC detection associated with AD in comparison with FFDM in the absence of appropriate history of trauma or surgery.

MATERIALS AND METHODS

The institutional review board approved this study and waived the need for informed consent due to its retrospective character.

Exclusion criteria for our study were: absence of AD, lack of morphological verification, mass or microcalcifications (MCs) as a main finding, history of previous trauma or surgery concordant with AD.

This study included 34 patients with AD who underwent full-field digital mammography (FFDM), DBT, hand-held full breast *ultrasound* (HHUS) and morphological verification from March 2018 to January 2020 (Table I). Only patients with AD as a main finding, with or without MCs, were included in this study. BI-RADS categories, mammographic breast density, mode of biopsy, and pathology results were utilized for all lesions.

All patients underwent bilateral FFDM in "COMBO" mode in two standard projections (CC and MLO) as a first step of imaging examination on Selenia Dimensions Mammography system (Hologic, USA). This step incorporated digital mammography and tomosynthesis, including synthesized images. Stereotactic biopsies were performed on Hologic MultiCare Platinum Prone Breast Biopsy Table, when there wasn't possibility to establish correlation with HHUS and perform ultrasound-guided core needle biopsy (CNB). For AD which were detected only on tomosynthesis and weren't associated with MCs there were performed excisional biopsies with preoperative mammography-guided hookwire localization, due to lack of possibility to perform tomosynthesis-guided breast biopsy for such lesions.

HHUS and ultrasound-guided biopsies were performed on a Toshiba Viamo and Toshiba Aplio XG US systems with a linear probe centered at 9,0MHz.

Age of the patients ranged from 33 years to 66 years with mean age of 49 years. All 34 patients with AD were examined by pathology, revealing 12 invasive breast cancers (IBC), 3 ductal cancer in situ (DCIS) and 19 non-cancerous findings.

Retrospectively, all studies with previously DBT detected AD, in consensus, were read by two dedicated breast radiologist. Only FFDM images in two standard projections (CC, MLO) were read without knowing results of DBT examination and pathology.

Sixty five percent (11/17) of these lesions underwent ultrasound-guided CNB while the remainder underwent stereotactic CNB (4/17) and excisional biopsy (2/17) with preoperative mammography-guided hookwire localization.

A Chi-square test (χ^2) was used to calculate the p-value. A confidence interval of 95% confidence level was calculated, the differences were considered significant at p -value <0.05 .

RESULTS

The overall rate of BC involvement for the 34 patients with ADs were 15 cases (44,1%) (IBC, $n=12$ (36,4%); DCIS, $n=3$ (8,8%)) other findings associated with ADs were high-risk lesions and benign findings (radial scar, $n=5$ (14,7%); sclerosing adenosis, $n=9$ (26,5%); typical lobular hyperplasia, $n=3$ (8,8%); typical ductal hyperplasia, $n=2$ cases (5,9%)). Sixty seven percent (10/15) of BC were in dense breasts (Table II).

All cases with MCs which were present in ADs were seen on both methods DBT and FFDM, $n=13/34$ (38,2%) and associated with malignancy, $n=9/34$ (26,5%) what was considered statistically significant ([95% CI, 0.91–1.86]; $p=0.2$). In five cases of FFDM visible suspicious MCs ADs were not detected, two of these cases were associated with BC.

Total of 17/34 (50.0%) ADs were identified at DBT that were missed at FFDM what was statistically significant difference ([95% CI, 2.56–7.45]; $p=0.00001$).

There were 41,2% (7/17) FFDM occult BCs associated with AD (IDC, $n=5$; ILC, $n=1$; DCIS, $n=1$); 10/17 (58,8%) FFDM occult ADs were non-cancerous findings (radial scar, $n=4$; sclerosing adenosis, $n=4$; typical lobular hyperplasia, $n=1$; typical ductal hyperplasia, $n=1$) what was considered statistically significant difference between DBT and FFDM in BC detection ([95% CI, 0.82–2.53]; $p=0.01$).

Analysis of the results showed that sensitivity of FFDM for DBT detected BCs associated with AD was 53.3% [95% CI, 26.59% to 78.73%] and specificity was 52.63% [95% CI, 28.86% to 75.55%].

Sixty five percent (11/17) of the lesions underwent ultrasound-guided CNB while the remainder underwent stereotactic CNB (4/17) and excisional biopsy (2/17) with preoperative guidewire localization. In our setting there was no ability to perform tomosynthesis guided breast biopsy.

The most frequently localization of AD was in upper-outer quadrant of the breast and BCs associated with AD also were most frequently localized in upper-outer quadrant (Table III). Overall more AD we detected in the left breast 21 (61,8%) to 13 (38,2%) in

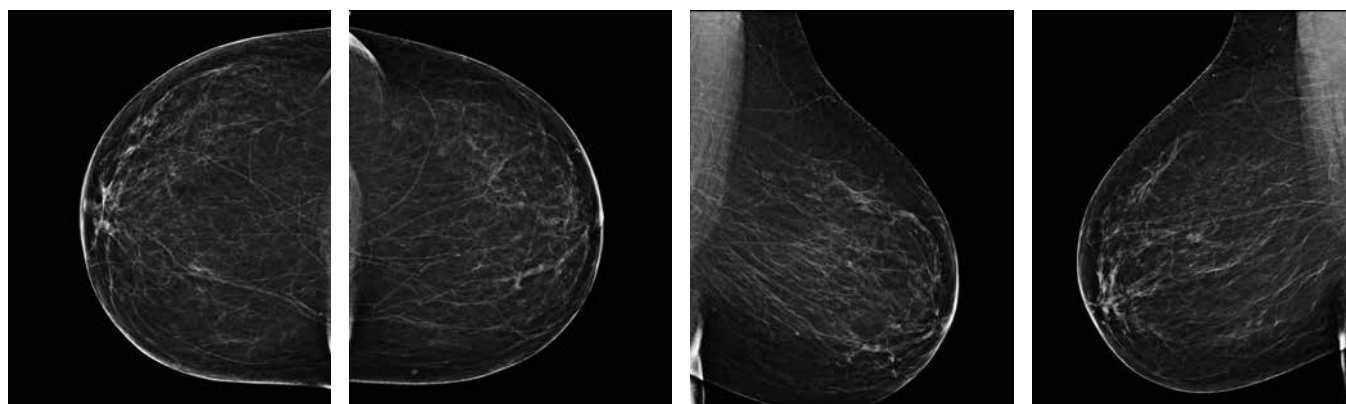


Fig. 1. Full-field digital mammography RCC, LCC, RMLO, LMLO views.

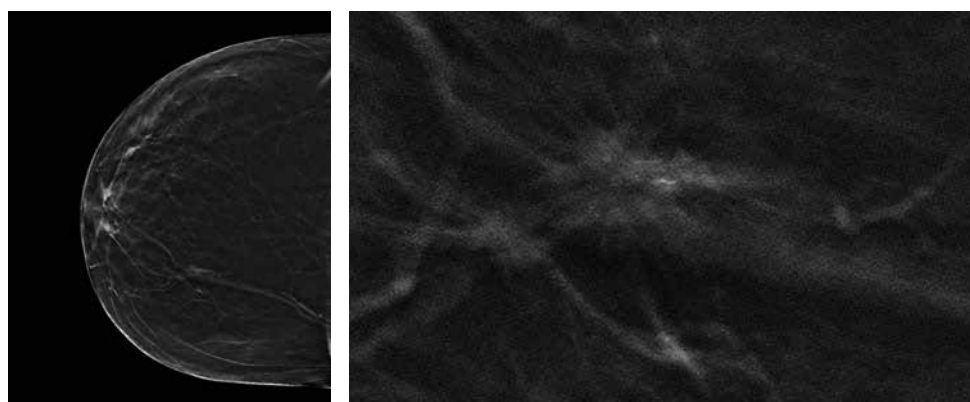


Fig. 2. Full-field digital mammography RCC view, Breast Tomosynthesis RCC view, magnification of architectural distortion in inner quadrant of the right breast on Tomo scans

the right breast. Also more BCs associated with AD were detected in the left breast 10 (66,7%) to 5 (33,3%) in the right breast.

As we see in Example 1 (Fig. 1-4) there is architectural distortion in upper inner quadrant of large fatty breast. Due to large size, fatty composition of the breast and lack of confident correlation between mammography and ultrasound stereotactic core-needle biopsy was performed. Pathology of suspicious lesion demonstrated G1 invasive carcinoma of no special type.

In another case Example 2 (Fig. 5-7) dense fibroglandular breast tissue obscured suspicious architectural distortion in upper outer quadrant of the left breast. There was performed excisional biopsy with preoperative hookwire localization of the lesion which showed at pathology radial scar associated with sclerosing adenosis and atypical ductal hyperplasia.

DISCUSSION

DBT is a relatively new modality for Ukrainian breast imaging. First experience of 3D mammography in Ukraine showed superior sensitivity for BC detection by using DBT than FFDM [10]. Considering that AD is the most common missed abnormality what caused false-negative mammography results, it's very important to compare DBT and FFDM in woman with ADs in Ukrainian population [11].

Our results showed that 17/34 (50,0%) ADs detected by DBT were missed on FFDM and 7/17 (41,2%) of these FFDM-occult

AD were malignant. Which are in line with previous study where AD were visualized better by using DBT than FFDM, moreover 73% of them were seen only on the DBT images and 21% of these 2D-occult AD were malignant [12].

Also our results correlate with one more study showing that AD is frequently associated with BC. That study showed that 17 of 36 (47%) sonographically occult AD, but detected on DBT, were malignant [13]. In our study 35,3% (6/17) sonographically occult but detected on DBT ADs were malignant.

According to another study ILCs was presented less frequently as masses and more often as AD on DBT [14]. Among 15 malignant lesions associated with AD, in our study, there was only one ILC.

Aim of earlier study was to determine the management of the lesions that were detected by DBT but were invisible on FFDM or HHUS [15]. Authors point that among 107 patients with DBT positive but FFDM or HHUS-negative breast lesions there were 48 (45%) MRI-negative lesions and none had a suspicious alteration during the follow-up period [15]. They concluded that breast MRI prior to biopsy may reduce the number of unnecessary biopsies for suspicious breast lesions that are DBT positive only [15].

Our results are also supported by the results of the recent study that DBT can detect suspected lesions that are occult in FFDM, especially in women with dense breast [16].

After AD is found it's very important to correlate the finding with HHUS. Ultrasound-guided CNB has become the first choice

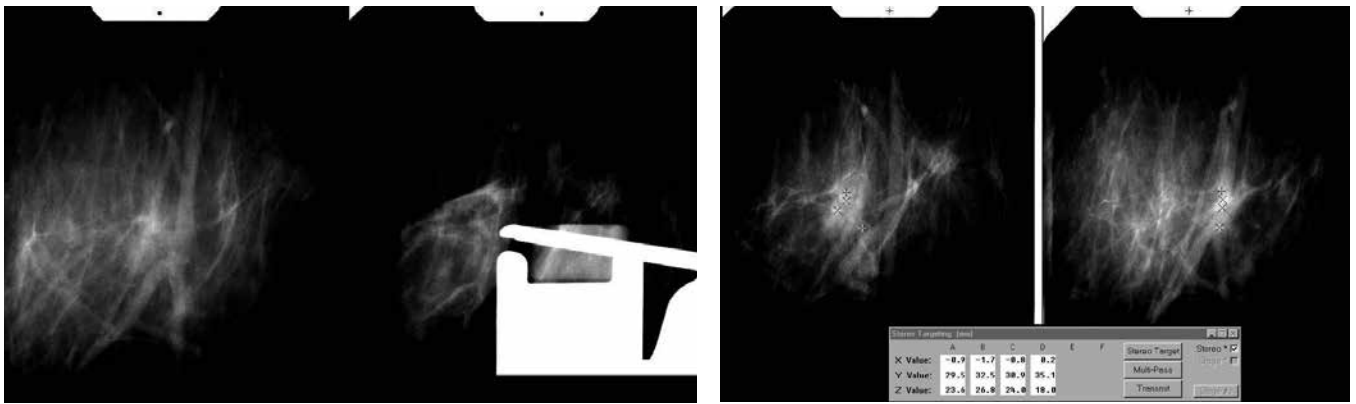


Fig. 3. Imaging of navigation during stereotactic core-needle biopsy of suspicious architectural distortion in the right breast.

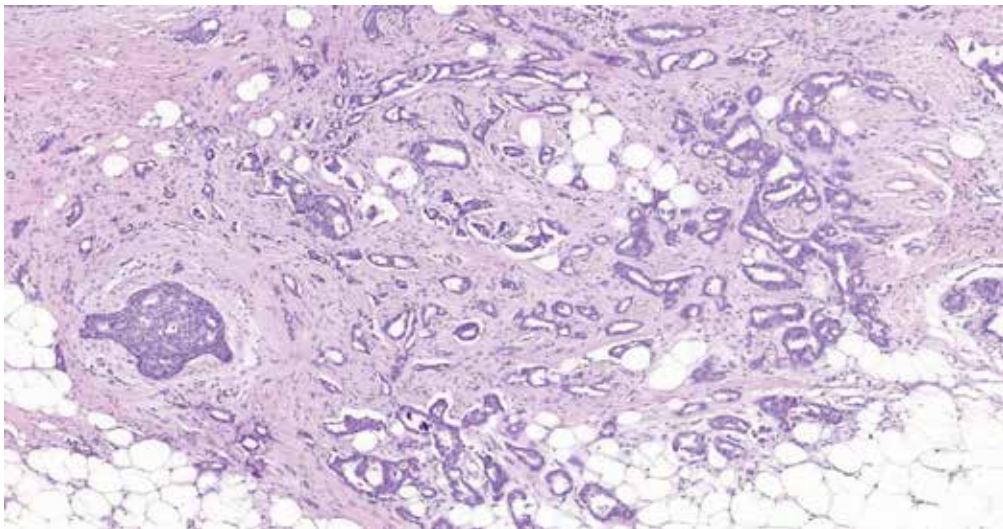


Fig. 4. Pathology revealed breast invasive carcinoma G1 of no special type (NST). Stained with hematoxylin-eosin, magnification 10.0 x.

Table III. Breast cancer localization within the breast.

Upper outer quadrant	9 (61%)
Upper inner quadrant	1 (7%)
Lower outer quadrant	1 (7%)
Lower inner quadrant	3 (18%)
Retroareolar region	1 (7%)

for performing most breast biopsies due to its non-ionising radiation, low cost, full control of the needle in real time, accessibility in difficult locations, multidirectional punctures and excellent comfort for patients [17]. In our study each AD was correlated with ultrasound images. In most cases 22/34 (64,7%) we found correlation and performed ultrasound-guided CNB. When AD was occult for HHUS there was performed stereotactic biopsy or excisional biopsy with preoperative mammography-guided hookwire localization.

Two big studies have shown that BC localized more frequently in the left breast with a left to right ratio of 1,10 and 1,07 [18,19]. In another study authors have shown that the upper outer quadrant was the most frequent site of carcinoma and supported hypothesis that the high proportion of upper outer quadrant carcinomas of the breasts is a reflection of the greater amount of breast tissue in this quadrant [20, 21]. Our study showed similar

results – 66,7% of BC were detected in the left breast and overall 60,0% of all BC were localized in upper outer quadrant.

Fifty three percent (8/15) of BC associated with AD were with MCs what correlates with previous research which showed that around 40% of BCs present with MCs and frequently, serve as the only mammographic features indicating the presence of a malignant lesion [22]. In other article researches noted that in screening programs, between 12.7 and 41.2% of women are recalled with MCs as the only sign of cancer [23].

Our study had some major limitations. We made comparison between two methods only for DBT-visible suspicious AD where we had results of pathology and then tried to identify them on FFDM. Due to its retrospective nature interpreting radiologists knew that in each case on FFDM there was previously detected suspicion lesion on DBT and this could potentially introduce a bias in their assessment.

The number of cancer cases in our sample was limited and we did not include other findings such as masses, asymmetries and MCs as a main finding in this analysis. Also, when radiologists saw just MCs on FFDM without association with AD we interpreted it as FFDM-occult AD.

CONCLUSIONS

The results of this study suggest that DBT detects more breast cancers represented as AD which are occult on

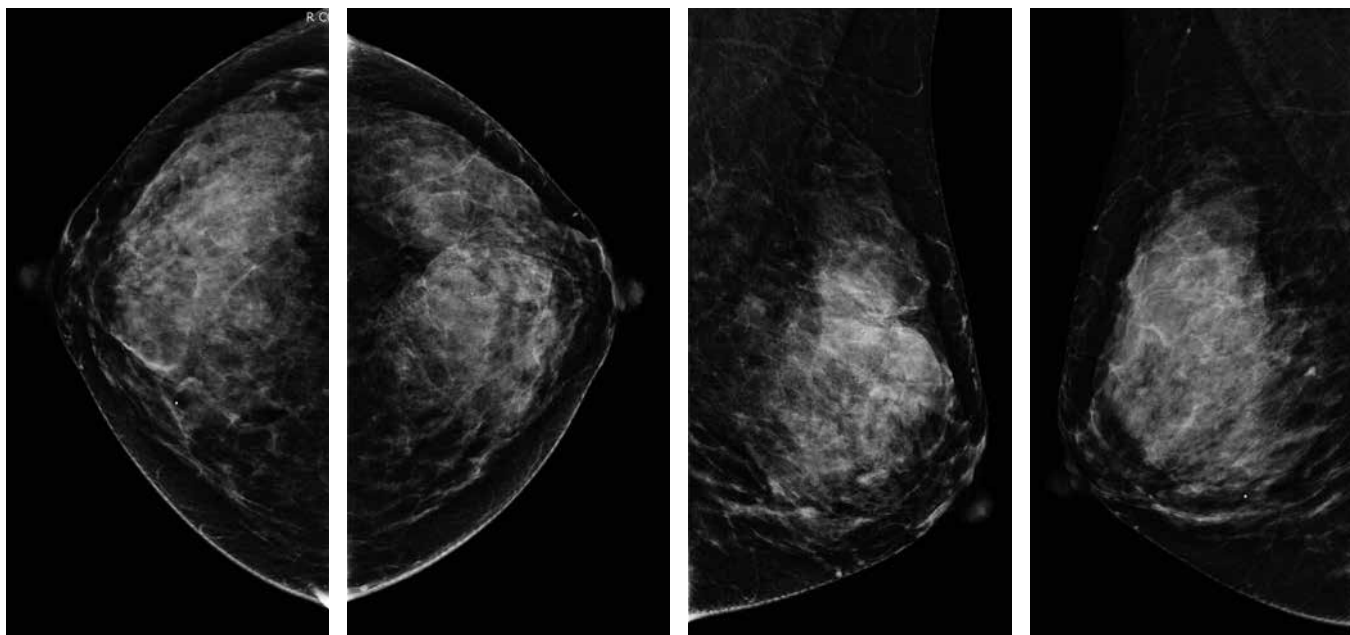


Fig. 5. Full-field digital mammography RCC, LCC, RMLO, LMLO views.

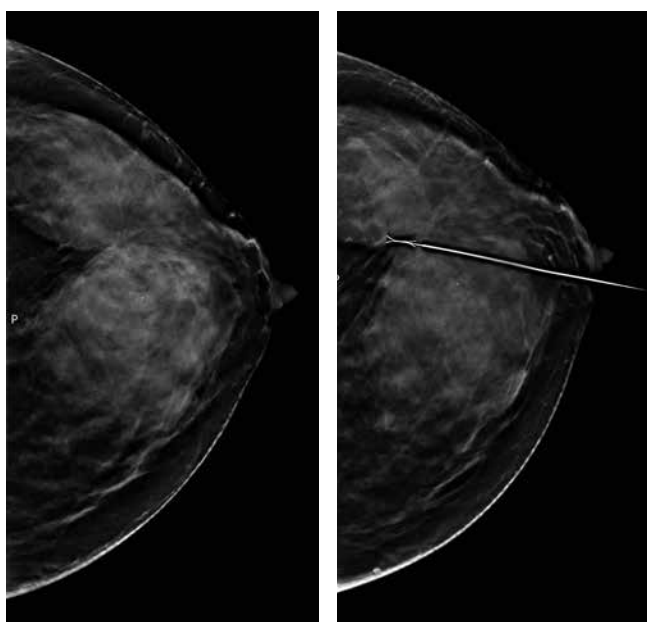


Fig. 6. Full-field digital mammography LCC view, Breast Tomosynthesis LCC view, preoperative hookwire localization of suspicious architectural distortion in upper outer quadrant of the left breast.

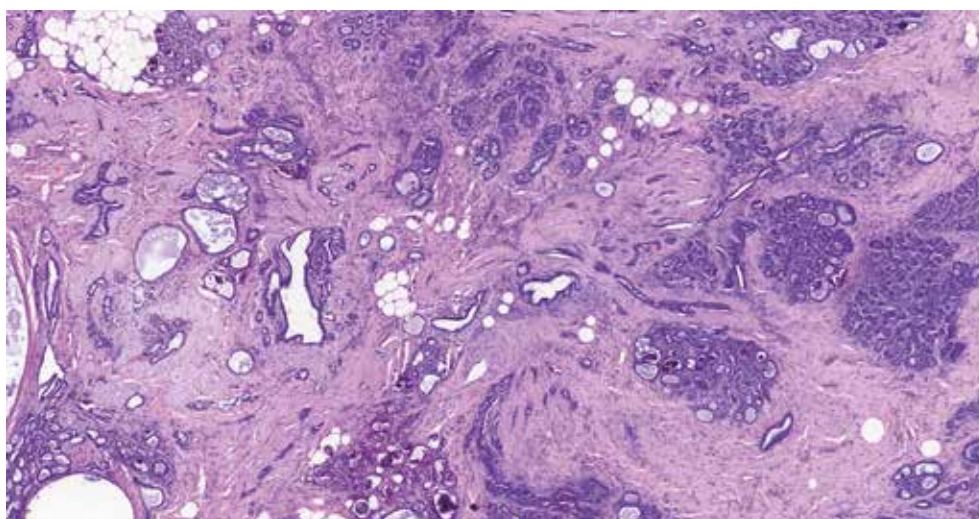


Fig. 7. Pathology showed radial scar associated with sclerosing adenosis and atypical ductal hyperplasia. Stained with hematoxylin-eosin, magnification 5.0x.

FFDM. Presences of MCs within AD, in the absence of appropriate history of trauma or surgery, have a high likelihood of malignancy and obligatorily require biopsy.

Our study proposes that combination of DBT and FFDM may increase detection of BCs represented as AD. We suggest using HHUS for all ADs detected on FFDM or DBT to correlate these findings and to perform US-guided biopsy; when MCs are present within US-occult AD to perform stereotactic biopsy; if AD is only seen on DBT to perform excisional biopsy with preoperative mammographic-guided hookwire localization in absence of possibility to perform tomosynthesis-guided breast biopsy.

However, using of DBT in Ukraine is just in the beginning and requires additional investigation in middle-income country settings.

REFERENCES

- Fedorenko Z.P. Cancer in Ukraine 2018 to 2019, incidence, mortality, activities of oncological service. In: Fedorenko ZP, Michailovich YY, Goulak LO et al. Kyiv: National Cancer Institute of Ukraine; 2020, 42-43 p.
- Perry N., Broeders M., Wolf C. et al. European guidelines for quality assurance in breast cancer screening and diagnosis. Fourth edition. International Agency for Research on Cancer. Lyon. France, 2006, 8 p.
- Broeders M., Moss S., Nyström L. et al. The Impact of Mammographic Screening on Breast Cancer Mortality in Europe: A Review of Observational Studies. *Journal of Medical Screening, J Med Screen*. 2012;19(1):14-25. doi: 10.1258/jms.2012.012078.
- Rangayyan R.M., Banik S., Desautels J.E. Computer-aided detection of architectural distortion in prior mammograms of interval cancer. *J Digit Imaging*. 2010;23(5):611-631. doi:10.1007/s10278-009-9257-x.
- D'Orsi C.J., Sickles E.A., Mendelson E.B. et al. ACR BI-RADS® Atlas, Breast Imaging Reporting and Data System. Reston, VA, American College of Radiology; 2013. 127-128 p.
- Durand M.A., Wang S., Hooley R.J. et al. Tomosynthesis-detected Architectural Distortion: Management Algorithm with Radiologic-Pathologic Correlation. *Radiographics*. 2016;36(2):311-21. doi: 10.1148/rg.2016150093.
- Rangayyan R.M., Banik S., Desautels J.E. Computer-aided detection of architectural distortion in prior mammograms of interval cancer. *J Digit Imaging*. 2010;23(5):611-631. doi:10.1007/s10278-009-9257-x.
- Knutzen A.M., Gissvold J.J. Likelihood of malignant disease for various categories of mammographically detected, nonpalpable breast lesions. *Mayo Clin Proc*. 1993;68:454-460. doi: 10.1016/s0025-6196(12)60194-3.
- Kopans D.B. Digital Breast Tomosynthesis From Concept to Clinical Care. *American Journal of Roentgenology*. 2014;202(2):299-308. doi: 10.2214/AJR.13.11520.
- Dykan I.M., Bozhok Ye.M., Gurando A.V. Pershyi dosvid vykorystannia 3D mamohrafi v Ukraini. Luhevaja diagnostika. Luhevaja Terapija [The first experience of using 3D mammography in Ukraine]. 2018;2:40-8. (in Ukrainian).
- Burrell H.C., Sibbering D.M., Wilson A.R. et al. Screening interval breast cancers: mammographic features and prognostic factors. *Radiology*. 1996;199(3):811-7. doi:10.1148/radiology.199.3.8638010.
- Partyka L., Lourenco A.P., Mainiero M.B. Detection of mammographically occult architectural distortion on digital breast tomosynthesis screening: initial clinical experience. *AJR Am J Roentgenol*. 2014;203(1):216-22. doi: 10.2214/AJR.13.11047.
- Freer P.E., Niell B., Rafferty E.A. Preoperative tomosynthesis-guided needle localization of mammographically and sonographically occult breast lesions. *Radiology*. 2015;275(2):377-83. doi: 10.1148/radiol.14140515.
- Chamming's F., Kao E., Aldis A. et al. Imaging features and conspicuity of invasive lobular carcinomas on digital breast tomosynthesis. *Br J Radiol*. 2017;90(1073):20170128. doi: 10.1259/bjr.20170128.
- Taskin F., Durum Y., Soyder A., Unsal A. Review and management of breast lesions detected with breast tomosynthesis but not visible on mammography and ultrasonography. *Acta Radiol*. 2017. doi: 10.1177/0284185117710681.
- Ray K.M., Turner E., Sickles E.A., Joe B.N. Suspicious Findings at Digital Breast Tomosynthesis Occult to Conventional Digital Mammography: Imaging Features and Pathology Findings. *Breast J*. 2015;21(5): 538-42.
- Apestequía L., Pina L.J. Ultrasound-guided core-needle biopsy of breast lesions. *Insights Imaging*. 2011;2(4):493-500. doi:10.1007/s13244-011-0090-7.
- Amer M.H. Genetic factors and breast cancer laterality. *Cancer Manag Res*. 2014;6:191-203. doi:10.2147/CMAR.S60006.
- Roychoudhuri R., Putcha V., Moller H. Cancer and laterality: a study of the five major paired organs (UK) *Cancer Causes Control*. 2006;17(5):655-662.
- Bright C.J., Rea D.W., Francis A. et al. Comparison of quadrant-specific breast cancer incidence trends in the United States and England between 1975 and 2013. *Cancer Epidemiol*. 2016;44:186-194.
- Lee A.H. Why is carcinoma of the breast more frequent in the upper outer quadrant? A case series based on needle core biopsy diagnoses. *Breast* 2005; 14(2):151-2.
- Castronovo V., Bellahcene A. Evidence that breast cancer associated microcalcifications are mineralized malignant cells. *Int J Oncol*. 1998;12(2):305-308. doi.org/10.3892/ijo.12.2.305.
- Mordang J.J., Gubern-Mérida A., Bria A. et al. The importance of early detection of calcifications associated with breast cancer in screening. *Breast Cancer Res Treat*. 2018;167(2):451-458. doi:10.1007/s10549-017-4527-7.

ORCID and contributionship:

Tetiana M. Babkina: 0000-0001-5046-870X^A
 Andrii V. Gurando: 0000-0002-2708-3040^{B,D}
 Tetiana M. Kozarenko: 0000-0002-0838-9773^E
 Viacheslav R. Gurando: 0000-0001-6303-3799^F
 Vadim V. Telniy: 0000-0001-9860-9663^C
 Denys V. Pominchuk: 0000-0002-7630-4241^C

Conflict of interest:

The Authors declare no conflict of interest.

CORRESPONDING AUTHOR

Viacheslav R. Gurando

Uzhhorod National University
 3 Narodna Square 88000 Uzhhorod, Ukraine
 tel: +380966104524
 e-mail: vhurando@gmail.com

Received: 2020-06-02

Accepted: 2021-06-01

A – Work concept and design, B – Data collection and analysis, C – Responsibility for statistical analysis, D – Writing the article, E – Critical review, F – Final approval of the article