



INTERNATIONAL COUNCIL  
*of* OPHTHALMOLOGY

**WOC**

*World Ophthalmology Congress*  
9-12 September, 2022

**Abstract Book**



# WORLD OPHTHALMOLOGY CONGRESS®

## 9-12 September 2022

WOC2022® Congress Secretariat, c/o Schipluidenlaan 4, 1062 HE Amsterdam, The Netherlands  
Tel: +31 20 575 4220 E-mail: [woc@icowoc.org](mailto:woc@icowoc.org)

No part of this publication may be reproduced, stored in a retrieval system, or transmitted in any form by any means, electronic, mechanical, photocopying or otherwise, without the prior consent of the copyright owners.

### **Disclaimer**

The International Council of Ophthalmology (ICO) organizes the World Ophthalmology Congress (WOC®) with the aim of providing education and scientific discourse in the field of ophthalmology and all related subspecialties. The ICO accepts no responsibility for any products, presentations, opinions, statements or positions expressed by speakers at the congress. The inclusion of material in the scientific program does not constitute an endorsement by ICO.

# TABLE OF CONTENTS

---

<b>Free papers</b>	1 - 240
<b>E-Poster Presentations</b>	242 - 882
<b>E-Posters</b>	884 - 1221
<b>Case presentations</b>	1223 - 1242
<b>Videos</b>	1244 - 1284

***FREE  
PAPERS***

FP-001

**Effect of CTR implantation on refractive stability and IOL calculation Formula selection for long axial myopia with cataract**H Yan, J Liang<sup>1</sup>, X Xie<sup>1</sup>.<sup>1</sup>Shaanxi Eye Hospital, Xi'an People's Hospital, Xi'an, People's Republic of China

**Objective:** To investigate the effect of intraoperative capsular tension ring (CTR) implantation on postoperative refractive stability and accuracy of seven IOL calculation formulas (SRK/T, Holladay II, Haigis, Barrett Universal II, Hill-RBF 2.0, EVO and Kane) in cataract patients with long axial myopia, and to provide reference for the application of CTR and selection of IOL calculation formulas.

**Methods:** A prospective case-control study. The eyes of patients with axial length (AL)  $\geq 27.00$ mm, treated in Shaanxi Eye Hospital (Xi'an People's Hospital) from 2020 to 2021, underwent phacoemulsification extraction combined with IOL implantation were enrolled with CTR implantation (group A) and without CTR (group B). Selected IOL power and predicted diopter was calculated with Barrett Universal II (BU II) formula according to the ocular biological parameters measured by IOL-Master 700. The prediction error (PE), absolute refractive error(AE), and mean absolute error(MAE) of each formula were calculated, respectively, by comparing the actual SE of patients with the predicted diopter of each formula 1 and 3 month after surgery. According to axial length,  $27\text{mm} \leq \text{AL} \leq 30\text{mm}$  and  $\text{AL} > 30\text{mm}$ , the diopter stability time and AE of the same formula were further compared respectively, and to analyze the influence of CTR on the diopter stability and formula in different AL ranges.

**Results:** A total of 63 cataract patients (89 eyes) with long axial myopia were included in this study, aged 35 to 82 years, with an average of  $55.93 \pm 10.17$  years. Preoperative AL ranged from 27.05 to 35.75 mm, with an average of  $30.30 \pm 2.18$  mm. Comparison of postoperative diopter, ACD and formula accuracy, group B showed statistical differences 1 week post-operation compared with 1 month and 3 months. The proportion of AE in  $\pm 0.5\text{D}$  from high to low distribution: Group A: Kane > EVO > Hill-RBF 2.0 > BU II > SRK/T > Haigis > Holladay II; Group B : EVO > Hill-RBF 2.0 > Kane > BU II > Haigis > SRK/T > Holladay II. Group B showed statistically significant differences between lower 30 mm and over 30 mm of AL.

**Conclusion:** Patients with CTR implantation tended to have stable diopter 1 week after surgery, while those without CTR implantation tended to have a stable diopter 1 month after surgery. CTR implantation had no effect on the prediction accuracy and selection of seven formulas for patients with high myopia combined with cataract. Kane and EVO formula have more accuracy in patients with high myopia.

FP-002

## Comparison of Binocular Visual Quality and Cost-effectiveness of Bilateral Cataract Surgery: a Single-Blind Two-Center Trial

L Qianqian<sup>1,2</sup>, Q Hong<sup>1</sup>, Z Si-Ming<sup>2</sup>, L Min<sup>2</sup>.

<sup>1</sup>Department of Ophthalmology, Peking University Third Hospital & Beijing key laboratory of restoration of damaged ocular nerve, Peking University Third hospital, Beijing, <sup>2</sup>Guangxi Academy of Medical Sciences & Department of Ophthalmology, the People's Hospital of Guangxi Zhuang Autonomous Region, Nanning, People's Republic of China

**Objective:** To compare postoperative binocular visual quality and cost-effectiveness of seven common strategies for the bilateral cataract surgery to provide a reference for healthcare policymakers in rationalizing resource utilization and surgeons in customizing patients.

**Methods:** The study based on a prospective single-blind two-center clinical trial included seven strategies of bilateral cataract surgery: monofocal, monovision, diffractive bifocal, blended, refractive bifocal, trifocal and extended depth of focus (EDOF) strategies. Binocular visual quality was measured at 3 mo postoperatively, including binocular uncorrected full-range visual acuity, binocular defocus curves (the depth of focus [DOF] and area under the curve [AUC]), binocular function (fusion function and stereopsis), binocular objective and subjective spectacle independence rates, visual analogue scale (VAS) of overall satisfaction, the 25- item visual function questionnaire (VFQ-25) and binocular dysphotopsia symptoms. The effectiveness based on the objective spectacle independence rate, costs, average cost-effectiveness ratios (ACERs) were estimated.

**Results:** Among 210 enrolled patients, 194 (92.4%, 388 eyes) were finally analyzed. The trifocal showed the best binocular uncorrected distance, intermediate and near visual acuity (0.00, 0.00 and 0.05 LogMAR) and best performance at all indicators of DOF and AUC. The monovision strategy showed the worst convergence, distance and near stereopsis of all ( $P < 0.001$ ). The trifocal strategy showed the highest objective spectacle independence rate (93.1% [95% CI, 77.2% to 99.2%]), while the EDOF strategy showed the highest subjective spectacle independence rate (92.9% [95% CI, 76.5%, 99.1%]). The EDOF strategy achieved the highest VAS (9.36, [95% CI, 9.05, 9.66]) and VFQ-25 scores (94.80, [95% CI, 93.69, 95.92]). The incidences of binocular dysphotopsia symptoms were comparable in all strategies. The refractive bifocal strategy had the minimum ACER (\$45.54/1% objective spectacle independence rate [95% CI, 34.57 to 56.50]).

**Conclusion:** Ranking the binocular visual quality and cost-effectiveness in different strategies could provide a reference for clinical and policy decisions. The trifocal strategy showed the best performance in most perspectives of binocular visual quality. The refractive bifocal, blended or EDOF strategies could provide approximate performance as trifocal strategy. The refractive bifocal strategy had the minimum ACER in China.

FP-003

### Trifocal IOL To Correct Refractive Defects And Presbyopia After Cataract Surgery:New Guidelines To Use In The Majority Of Patients

M Piovella, B Kusa.

**Objective:** To evaluate results in cataract eyes implanted with trifocal IOLs to get distance intermediate and near vision. New centre organization is key point to spread the use of trifocal lenses.

**Methods:** 686 eyes were implanted with trifocal IOLs.308 eyes with ATLISA tri 839MP-Carl Zeiss Meditec AG Jena and 378 eyes were implanted with AT LISA tri 939MP.Mean Age  $66.49 \pm 11.66$ . Biometry was performed with IOL Master 700 RK and astigmatism axis alignment performed with Callisto system. Blephex and Lipiflow were applied

**Results:** At 6 years monocular Trifocal IOLs results are UCDVA  $20/22 \pm 2.40$  UCIVA  $20/24 \pm 3.13$  UCNVA  $20/27 \pm 5.37$ ,monocularToric Trifocal IOLs are UCDVA  $20/20 \pm 3.25$  UCIVA  $20/35 \pm 4.75$  UCNVA  $20/29 \pm 2.56$  Binocular results(178 patients)are UCDVA was 20/20, intermediate 20/20 and near vision 20/24.97 %

**Conclusion:** AT LISA tri and tri toric trifocal IOLs provide glass free vision after cataract surgery. Data show that it is possible to adopt them in the majority of patients

FP-004

**Improving corneal astigmatism measures for keratoconic eyes**

N Alpins<sup>1</sup>, J KY Ong<sup>2</sup>, G Stamatelatos<sup>3</sup>.

<sup>1</sup>Ophthalmology, University of Melbourne, <sup>2</sup>ASSORT, <sup>3</sup>NewVision Clinics, Melbourne, Australia

**Objective:** To evaluate whether it is possible to customize corneal astigmatism measurement for keratoconic eyes to better match the perceived visual image, which would enhance outcomes of toric implants or laser vision correction of associated astigmatism.

**Methods:** Potential measures of corneal astigmatism are derived from raw total corneal power data (179 eyes from 124 patients) derived from a corneal tomographer. The measures are derived from varying regions on the cornea, both in extent and center position. The measures of corneal astigmatism are evaluated according to their vectorial difference from the manifest refractive cylinder, which is the ocular residual astigmatism (ORA). The lower the variability of the ORA, the better the corneal astigmatism measure corresponds to the manifest refractive cylinder. The variability of the ORA is quantified in this paper by the root-mean-squared distance of the ORA from the summated vector mean in double angle space (ORArms).

**Results:** ORArms are calculated for all possible corneal astigmatism measures, which are derived from varying inner and outer annular extents, and centered on corneal vertex, thinnest point, front apex, and back apex, and pupil center, as well as various points between the corneal vertex and the corneal thinnest point. For each different annulus center, the annular extent that minimizes the ORArms is reported. Results are stratified by keratoconus severity.

**Conclusion:** For eyes with mild keratoconus, corneal astigmatism measures centered on corneal vertex tend to correspond more closely with manifest refractive cylinder than other measures centered on corneal vertex, corneal apex (front or back), or pupil center. For eyes with moderate keratoconus midpoint between the corneal vertex and thinnest point corresponds more closely with manifest refractive cylinder. All these custom measures outperform simulated keratometry. None of the corneal astigmatism measures correspond closely with manifest refractive cylinder for severe keratoconus.



FP-005

**Combined phacoemulsification surgery and intravitreal triamcinolone injection in diabetic patients: A prospective randomized trial**S Zaher-Addeen<sup>1</sup>, I Shaddoud<sup>1</sup>.<sup>1</sup>Ophthalmology Department, Damascus University, Faculty of Medicine, Damascus, Syrian Arab Republic

**Objective:** To compare the efficacy of intravitreal injection of triamcinolone acetonide combined with standard phacoemulsification on the central subfield macular thickness (CSMT), the progression of diabetic retinopathy (DR), and the corrected distant visual acuity (CDVA) in type 2 diabetic patients.

**Methods:** In this prospective single-blinded randomized clinical trial we recruited all patients with type 2 diabetes who were eligible for cataract surgery in our hospital. The patients were randomly assigned in two groups. The case group received an intravitreal injection of triamcinolone acetonide IVTA at the end of phacoemulsification, and the control group had routine phacoemulsification surgery. CSMT, progression of DR, CDVA, intraocular pressure (IOP), and adverse events including endophthalmitis were compared between the groups preoperatively and at 1, 3, and 6 months postoperatively.

**Results:** Among a total of 66 patients that were treated within the study period, 50 patients were included in the final analysis. The case group (IVTA group) comprised 21 eyes, and the control group (no injection group) included 29 eyes. Regression models and corrected ANOVA test for repeated measures showed a significant reduction in CSMT at 3 and 6 months postoperatively, which was most significant when the preoperative CSMT was  $\geq 300 \mu\text{m}$ , with a cut-off value of  $347.3 \mu\text{m}$  in the IVTA group ( $p < 0.000$ ). Diabetic retinopathy progression was halted in the IVTA group at 6 months with 52.38% of patients having their DR classified as moderate ( $P=0.012$ ). CDVA was significantly improved from baseline 6/60 (logMAR 1.0) pre-op to 6/6 (logMAR 0.00) at 6 months post-op in the IVTA group, and from baseline 6/120 (logMAR 1.3) pre-op to 6/12 (logMAR 0.3) at 6 months post-op in the control group. The gain in visual acuity was significantly higher in the IVTA group at all study points ( $p < 0.001$ ). No significant rise in intraocular pressure was observed at any study point in both groups ( $p = 0.23 > 0.05$ ). No endophthalmitis was recorded.

**Conclusion:** Diabetic patients could significantly benefit from cataract surgery. This study provides evidence that supports the usage of intravitreal triamcinolone acetonide at the end of cataract surgery in diabetic patients as an affordable (which is of particular importance in low-income countries as per our setting), and relatively safe “phaco enhancer”.

FP-006

## Lens Capsule-related Complications in Femtosecond Laser-assisted Cataract Surgery: A Study Based on Video Analysis

W Wang, K Yao.

**Objective:** To analyse the occurrence and potential causes of lens capsule-related complications during femtosecond laser-assisted cataract surgery (FLACS).

**Methods:** This prospective consecutive cohort study included the first 1,600 eyes (from 1,140 consecutive patients) who received FLACS performed by the same surgeon from May 2015 to December 2018. The potential causes and characteristic signs of capsulotomy-related complications, including incomplete capsulotomies and radial anterior capsule (AC) tears, were summarised based on the agreement of two ophthalmologists after they analysed the surgical videos. Subgroup analysis was conducted to characterise the capsulotomy learning curve.

**Results:** Of the 1,600 eyes, 52 (3.25%) had incomplete capsulotomies, and 22 (1.38%) had radial AC tears. The most common causes of incomplete capsulotomies were eye tilt (16 eyes, 30.77%), air bubbles or ocular secretions at the interface (14 eyes, 26.92%) and white cataracts (7 eyes, 13.46%). Additionally, 54.55% (12/22) of AC tears were due to incomplete capsulotomy and secondary capsulorhexis. A significant difference was noted between the first 200 eyes and subsequent groups in terms of the incidence of incomplete capsulotomies. No difference was observed in the incidence of AC tears after the initial 100 procedures.

**Conclusion:** The most common causes of incomplete capsulotomies were eye tilt and air bubbles or ocular secretions at the interface. Secondary capsulorhexis after incomplete capsulotomy is the main risk factor for AC tears. There was a steep learning curve for laser capsulotomy in the first 100 operated eyes, as evidenced by the higher complication rate, but this stabilised after 200 procedures.

FP-007

## A Comparative Study on the Accuracy of IOL Calculation Formulas in Nanophthalmos and Relative Anterior Microphthalmos

T Zheng, P Lin, J Xu, Y Lu.

**Objective:** To compare the prediction accuracy of 6 intraocular lens (IOL) formulas, Haigis, Hoffer Q, Holladay, SRK/T, Barrett Universal II and Hoffer QST formulas, in microphthalmic eyes including nanophthalmos and relative anterior microphthalmos (RAM).

**Methods:** 26 eyes with nanophthalmos (axial length/AL:  $16.84 \pm 1.36$  mm) and 12 eyes with RAM (corneal diameter/WTW:  $8.41 \pm 0.92$  mm) who underwent cataract surgery were included. The mean and median of arithmetic and absolute refractive errors of the 6 original calculation formulas, the absolute refractive error of the 6 formulas after optimization, and the proportion of refractive error within  $\pm 0.25D$ ,  $\pm 0.5D$ ,  $\pm 1D$  and  $\pm 2D$  of each formula were compared. The influencing factors of the predictive errors were analyzed by multivariate regression.

**Results:** In the nanophthalmos group, the overall prediction results of each formula were shifted to myopia; the median absolute prediction errors of Haigis, Hoffer Q, Holladay, SRK/T, Barrett Universal II and Hoffer QST formulas were 1.61D, 4.61D, 2.05D, 2.02D, 3.69D and 2.18D respectively, and the Haigis formula had the smallest absolute error ( $p < 0.001$ ). The absolute error medians after optimization of the above formulas were 1.04D, 2.22D, 1.45D, 1.72D, 1.83D and 1.72D, respectively, without significant difference ( $p = 0.057$ ), but the optimized Haigis formula had the highest proportion of errors within  $\pm 0.25D$ ,  $\pm 0.5D$  and  $\pm 1D$ . The keratometric values (K) and AL had a significant impact on the prediction error of the original Haigis formula ( $p < 0.05$ ). The WTW had a significant impact on the prediction error of Haigis, Hoffer Q, Holladay, SRK/T and Hoffer QST formulas after optimization ( $p < 0.05$ ). In the RAM group, the overall prediction results of each formula shifted to hyperopia, and the medians of the absolute errors of Haigis, Hoffer Q, Holladay, SRK/T, Barrett Universal II and Hoffer QST formulas were 1.01D, 1.50D, 1.42D, 1.34D, 0.61D and 0.45D respectively, without significant difference ( $p = 0.146$ ). And no significant difference was found among the formulas after optimization ( $p = 0.161$ ), but the optimized Barrett Universal II formula has the highest proportion of errors within  $\pm 1D$  and  $\pm 2D$ . The K value has a significant effect on the predictive error of the optimized Haigis formula ( $p = 0.021$ ).

**Conclusion:** Among the 6 IOL calculation formulas, the Haigis formula was the most accurate in cataract patients with nanophthalmos (AL < 20mm), and Barrett Universal II formula was of the highest accuracy in cataract patients with RAM.

FP-008

## Biallelic ADAMTSL4 Mutations in a Chinese Cohort of Congenital Ectopia Lentis: Implications for Genotype-Phenotype Relationships

Z Chen, W Jia<sup>1</sup>, Y Jiang<sup>1</sup>.

<sup>1</sup>Eye Institute and Department of Ophthalmology, Eye & ENT Hospital, Fudan University, Shanghai, People's Republic of China

**Objective:** This study aimed to assess the contribution of biallelic *ADAMTSL4* mutations in a Chinese cohort of congenital ectopia lentis (EL) and explore the underlying genotype-phenotype correlations.

**Methods:** Potentially pathogenic *ADAMTSL4* mutations were screened from a Chinese cohort of congenital EL using panel-based next-generation sequencing followed by multiple bioinformatics analyses. The genotype-phenotype correlation was assessed via a systematic review of *ADAMTSL4* mutations within our data and those from the literature.

**Results:** A total of 12 mutations of *ADAMTSL4*, including seven frameshift mutations, one nonsense mutation, two splicing mutations, and two missense mutations, were found in nine probands. Combining genetic and clinical information from 72 probands in the literature revealed 37 *ADAMTSL4* mutations known to cause EL, and the ethnic difference was prominent. The lens was inclined to dislocate inferior temporally (22, 27.16%), while the pupil was always located oppositely (9, 81.82%). Several anterior segments anomalies were identified, including ectopia pupillae (15, 18.52%), persistent pupillary membrane (9, 11.10%), poor pupil dilation (4, 30.8%), cataract (13, 24.10%), and glaucoma (8, 13.33%). Genotype-phenotype analysis revealed that truncation mutations had higher risks of combined iris anomalies, including either ectopia pupillae or a persistent pupillary membrane ( $P = 0.007$ ).

**Conclusion:** The data from this study not only extend our knowledge of the *ADAMTSL4* mutation spectrum but also suggest that deleterious mutations of *ADAMTSL4* might be associated with severe ocular phenotypes.

FP-009

**Refractive outcome of toric intraocular lens calculation in cases of high posterior corneal astigmatism**T Jin.

**Objective:** To establish whether toric intraocular lens (IOL) calculation on the basis of total keratometry (TK) measurements of the corneal topography (Pentacam HR, Oculus Inc., Wetzlar, Germany), in corneas with high posterior corneal astigmatism (PCA), will result in a systematic overcorrection or undercorrection of postoperative refractive outcomes

**Methods:** Monocentric retrospective study. Data were collected from 126 consecutive eyes during uncomplicated cataract surgery by a single surgeon with measured PCA of 0.60 diopters (D) or greater. Toric IOL calculations were made using total keratometry (TK) measurements. Eyes were grouped as either “with-the-rule” (WTR) or “against-the-rule” (ATR) on the basis of the steep anterior corneal meridian. Uncorrected distance visual acuity (UDVA) and the postoperative refractive astigmatic prediction error were analyzed 1 month postoperatively using the vector analysis by the Alpins method.

**Results:** The mean UDVA was  $0.15 \pm 0.72$  LogMAR in ATR group and  $0.14 \pm 0.64$  LogMAR in WTR group ( $p = 0.88$ ). The Alpins correction index was  $0.40 \pm 0.46$  indicating a tendency to undercorrection in ATR eyes. For the WTR eyes, the correction index was  $0.26 \pm 0.16$ , also indicating a tendency to undercorrect. A significant difference in mean absolute error in predicted residual astigmatism ( $-1.15 \pm 0.81$  D versus  $-1.94 \pm 0.71$  D;  $p = 0.00$ ) and in mean centroid error in predicted residual astigmatism ( $0.14 \pm 0.72$  at  $20^\circ$  and  $0.30 \pm 0.73$  at  $180^\circ$ ;  $p = 0.043$  and  $0.041$  respectively for the x- and y- components) were found between the two groups. These were significantly different from the ideal value of zero (ATR:  $p = 0.00$ , WTR:  $p = 0.00$ ).

**Conclusion:** The results suggest that in cases of high PCA, the toric IOL calculation using total corneal measurements may have a potential undercorrection in ATR eyes and WTR eyes. The magnitude of undercorrection in ATR group is less than that in WTR group. Our recommendation is that changing in recommended IOL cylinder power for a given eye should be taken into account for the eye with high PCA.

**FP-010****Impact of COVID-19 Ripples on Cataract Surgical Care**J C Reddy, S Dwivedi, K Dhara, K Avasarala.

**Objective:** To estimate the size of the cataract surgical backlog owing to COVID-19 and forecast the time required to clear the backlog.

**Methods:** This study included patients presenting between March 23, 2019, and March 31, 2021, of a multi-tier ophthalmology network. A total of 106,279 eyes of patients who underwent cataract surgery during the study period were included. Our modelling consists of analysis in three dimensions based on pre-covid baseline trends, during covid lockdown, and recovery post lockdown. The first dimension is prediction of backlog based on historical distribution and on a prediction of when normalcy is restored. The second-dimension models the behavior of patients towards normalcy and the third dimension brings the effect of increased efficiency of surgical care to clear the backlogs.

**Results:** During the study period there is a cumulative backlog of 74000 procedures. The lifting of COVID-19 lockdown and patients coming back for elective cataract surgery in 3 months, our model predicted that with current efficiency it would take 20 years to clear the backlog. A 20% increase in efficiency from the mean pre-COVID forecasted volumes, which is 2% from their maximum would take 6 years. Our segmentation results suggest an increase of up to 6 and 7 years for increased mean efficiency of 25% and 20%. Time taken to clear the backlog was longer for patients from rural areas. Our analysis suggests that if the increase is not managed properly then clearing of back backlog for certain demographic segments will be adversely affected.

**Conclusion:** Suspension of elective cataract surgical care during the COVID-19 surge has created a gigantic cataract surgical patient backlog. The current prediction analysis can aid eye care professionals, and policymakers in planning for post-pandemic recovery

FP-011

**S.P.E.C.I.A.L. (SITTING PHACOEMULSIFICATION OF CATARACT AND INTRAOCULAR LENS IMPLANTATION)**J Brayan, P Chandrakanth.

**Objective:** 1.To assess the outcome of phacoemulsification with Intra Ocular Lens Implantation in Sitting position  
2.To determine the efficacy of phacoemulsification in sitting position  
3.To assess the challenges faced by the surgeon in face to face sitting phacoemulsification and how to overcome them

**Methods:** Patient was made to sit in a plastic chair erect at 90 degree face to face with the surgeon - who carried out phacoemulsification & foldable intraocular lens implantation in 27 such cases. the microscope was adjusted to make it compatible for sitting phacoemulsification. data on visual acuity, biometry, complication, vitals was then entered and analysed using SPSS software.

**Results:** demographic data : male (15) > female(12); male age group with highest cataract was in the range of 60-69(8 cases) and females 50-59(10cases); pre operative, intraoperative and postoperative statistics of blood pressure,pulse,spo2 were recorded which shows no statistically significant changes which means the patients had stable vitals during the surgery. BCVA-significant improvement in PostOperativeDay -1,30,60,90 days,88% patient with 6/6. On average LE surgery took 9.8mins,C.D.E energy of 9.6 & RE took 11.4mins & 17.4 C.D.E respectively. Surgery time in Mature Cataract(MC) > Immature Cataract(IMC) by 3 mins & twice the phaco energy for MC than IMC

**Conclusion:** S.P.E.C.I.A.L has given an insight on the statistical data on phacoemulsification carried out in sitting position. It might be the only option for some patients & this is the only study with 90degree surgery being conducted on patients who cannot lie down supine for cataract surgery.

FP-012

**Drug-eluting intraocular lens with sustained NSAIDs release for conquering posterior capsular opacification**H Han.

**Objective:** Posterior capsule opacification (PCO) is the most common long-term postoperative complication of cataract surgery, leading to secondary vision loss. Optimized intraocular lens (IOL) structure and appropriate pharmacological intervention can inhibit the development of PCO to a certain extent. However, there is still few effective approaches to prevent PCO, and the mechanism of pharmacological intervention in PCO is also unknown. This study was designed to construct a novel drug-eluting IOL based on ultrasonic spray technology for the prevention of EMT of LECs and PCO.

**Methods:** The HLEC-B3 cells were involved in this study to investigate the effect and mechanism of indomethacin on EMT and cell migration. The expression levels of EMT markers were detected by western blot. The autophagy activation was observed by western blot, immunofluorescence assay, and transmission electron microscopy. Furthermore, a novel drug-eluting IOL with an optimized sharper edge and a sustained drug release system was developed as a drug delivery platform for the prevention of PCO implanted into the capsule during cataract surgery. The effect of drug-eluting IOL on PCO was evaluated in a rabbit PCO model.

**Results:** NSAIDs were able to not only suppress cell migration and down-regulate the expression of cyclooxygenase-2 (COX-2) and EMT markers, but also promote the autophagy activation in LECs. The drug-eluting IOL, serving as a drug delivery platform, could carry an adjustable dose of NSAIDs with sustained drug release ability for more than 28 days, and showed excellent anti-inflammatory and anti-PCO effects in the rabbit PCO model.

**Conclusion:** NSAIDs is an effective pharmacological intervention in PCO prophylaxis, and the drug-eluting IOL prevented PCO in vivo under its sustained NSAIDs release property, which provided a promising approach for PCO prophylaxis in clinical application.



## FP-013

## Refractive outcome of toric intraocular lens calculation in cases of high posterior corneal astigmatism

T Jin.

**Objective:** To establish whether toric intraocular lens (IOL) calculation on the basis of total keratometry (TK) measurements of the corneal topography (Pentacam HR, Oculus Inc., Wetzlar, Germany), in corneas with high posterior corneal astigmatism (PCA), will result in a systematic overcorrection or undercorrection of postoperative refractive outcomes.

**Methods:** Monocentric retrospective study. Data were collected from 126 consecutive eyes during uncomplicated cataract surgery by a single surgeon with measured PCA of 0.60 diopters (D) or greater. Toric IOL calculations were made using total keratometry (TK) measurements. Eyes were grouped as either “with-the-rule” (WTR) or “against-the-rule” (ATR) on the basis of the steep anterior corneal meridian. Uncorrected distance visual acuity (UDVA) and the postoperative refractive astigmatic prediction error were analyzed 1 month postoperatively using the vector analysis by the Alpins method.

**Results:** The mean UDVA was  $0.15 \pm 0.72$  LogMAR in ATR group and  $0.14 \pm 0.64$  LogMAR in WTR group ( $p = 0.88$ ). The Alpins correction index was  $0.40 \pm 0.46$  indicating a tendency to undercorrection in ATR eyes. For the WTR eyes, the correction index was  $0.26 \pm 0.16$ , also indicating a tendency to undercorrect. A significant difference in mean absolute error in predicted residual astigmatism ( $-1.15 \pm 0.81$  D versus  $-1.94 \pm 0.71$  D;  $p = 0.00$ ) and in mean centroid error in predicted residual astigmatism ( $0.14 \pm 0.72$  at  $20^\circ$  and  $0.30 \pm 0.73$  at  $180^\circ$ ;  $p = 0.043$  and  $0.041$  respectively for the x- and y- components) were found between the two groups. These were significantly different from the ideal value of zero (ATR:  $p = 0.00$ , WTR:  $p = 0.00$ ).

**Conclusion:** The results suggest that in cases of high PCA, the toric IOL calculation using total corneal measurements may have a potential undercorrection in ATR eyes and WTR eyes. The magnitude of undercorrection in ATR group is less than that in WTR group. Our recommendation is that changing in recommended IOL cylinder power for a given eye should be taken into account for the eye with high PCA.

FP-014

**Autophagy facilitates oxidative stress-triggered apoptosis via NF- $\kappa$ B signaling in human lens epithelial cells**W Han<sup>1,2</sup>, J Huang<sup>1</sup>, W Chen<sup>3</sup>.<sup>1</sup>Eye center, The Second Affiliated Hospital, <sup>2</sup>Eye Hospital, <sup>3</sup>Institute of Immunology, Zhejiang University, Hangzhou, People's Republic of China**Objective:** To investigate the interaction between autophagy and apoptosis in human lens epithelial cells (LECs), and their potential regulatory role in cataract occurrence.**Methods:** Changes of LC3 and TUNEL in LECs from cataract patients and controls were evaluated by immunofluorescence staining. The autophagic ultrastructure was tested using transmission electron microscope. Apoptosis levels of LECs were assessed by CCK8 assay and Annexin V-FITC/PI staining in HLE-B3 under oxidative stress, including H<sub>2</sub>O<sub>2</sub> stimulation or ultraviolet (UV) irradiation. Changes in autophagy and related signals in WT and KO HLE-B3 cells were tested by Western Blot, RT-qPCR and flow cytometry. RNA-seq was performed in WT and KO HLE-B3 suffered oxidative stress, mRNA and protein levels of apoptosis-related genes (XIAP, Bcl-2, Bcl-xL and Bax) were verified by RT-qPCR and Western Blot.**Results:** We found that elevated levels of autophagy and apoptosis coexisted in the same LEC of age-related cataract patients. Oxidative stress triggered autophagy prior to apoptosis, and blocking autophagy by knocking down ATG3 or ATG7 genes significantly inhibited apoptosis in HLE-B3 cell lines. NF- $\kappa$ B signaling pathway processes pro-apoptotic signaling in LECs. Furthermore, the pharmacological inhibitor of autophagy, 3-MA, significantly rescued the apoptosis of primary cultured human LECs under oxidative stress. Collectively, our data suggest that autophagy promotes oxidative stress-triggered apoptosis by inhibiting the pro-survival axis of NF- $\kappa$ B.**Conclusion:** Excessive activation of autophagy exacerbates oxidative stress-induced apoptosis by inhibiting the pro-survival NF- $\kappa$ B axis in human lens epithelial cells. This work expands the understanding of the mechanisms of age-related cataractogenesis and provides the in-depth mechanisms regarding the age-related cell death in diseases associated with aging.

## FP-015

## Comparison of the two Barrett toric calculation with and without measured posterior corneal astigmatism

W Liu<sup>1</sup>, L Yang<sup>1</sup>, B Wang<sup>2</sup>, J Zhou<sup>3</sup>, H Dong<sup>1</sup>, J Liu<sup>1</sup>.

<sup>1</sup>Cataract, <sup>2</sup>Optometry, <sup>3</sup>Comprehensive Test, Shanxi Eye Hospital, Taiyuan, People's Republic of China

**Objective:** To compare the prediction errors in residual astigmatism of Barrett predicted posterior corneal astigmatism (PCA) toric calculator and Barrett measured PCA toric calculator.

**Methods:** In 109 eyes of 78 patients undergoing cataract surgery with toric IOL implantation (Acrysof IQ Toric), predicted residual astigmatism by each calculation was compared with the manifest refractive astigmatism. The prediction error in residual astigmatism was calculated by vector analysis.

**Results:** The two calculation methods resulted in undercorrection of with-the-rule astigmatism and overcorrection of against-the-rule astigmatism. For the with-the-rule astigmatism group, the centroid prediction error of Barrett predicted PCA toric calculator was  $0.24 \pm 0.52D@94^\circ$  ( $x=0.24 \pm 0.40, y=0.03 \pm 0.35$ ) and Barrett measured PCA toric calculator was  $0.30 \pm 0.57D@92^\circ$  ( $x=0.30 \pm 0.44, y=0.03 \pm 0.37$ ). The former yielded significantly reduced error compared with the latter ( $P<0.001$  and  $P=0.309$  for x and y, respectively). But for the against-the-rule astigmatism group, the centroid prediction error of Barrett measured PCA toric calculator yielded significantly ( $0.22 \pm 0.62D@109^\circ$ ;  $x=0.18 \pm 0.36, y=0.14 \pm 0.51$ ) reduced error compared with Barrett predicted PCA toric calculator ( $0.34 \pm 0.63D@102^\circ$ ;  $x=0.32 \pm 0.36, y=0.14 \pm 0.53$ ), the differences between the two toric calculator were statistically significant ( $P<0.001$  and  $P=0.033$  for x and y, respectively).

**Conclusion:** The Barrett predicted PCA toric calculator yielded the lowest centroid astigmatism prediction errors in subgroup of eyes with WTR astigmatism, But in the ATR astigmatism group, Barrett measured PCA toric calculator yielded the lowest centroid astigmatism prediction errors.

## FP-016

## Effect of Decentration on the Objective Optical Quality of Refractive–Diffractive Intraocular Lenses

Q Chen<sup>1</sup>, L Min<sup>1</sup>, Z Si-Ming<sup>2</sup>, L Qian-Qian<sup>3</sup>, X Fan<sup>2</sup>, Y Gang<sup>1</sup>, Z Zhou<sup>1</sup>, D Chun-Li<sup>1</sup>.

<sup>1</sup>Guangxi Academy Of Medical Sciences,the People's Hospital of Guangxi Zhuang Autonomous Region, <sup>2</sup> Guangxi Academy Of Medical Sciences,the People's Hospital of Guangxi Zhuang Autonomous Region, Nanning, <sup>3</sup>Guangxi Academy Of Medical Sciences,the People's Hospital of Guangxi Zhuang Autonomous Region, Nanning, People's Republic of China

**Objective:** To investigate the decentration of the refractive–diffractive multifocal intraocular lens SN6AD1 after intracapsular implantation for cataract surgery and to find the effect of decentration on the objective visual quality of the multifocal IOL SN6AD1.

**Methods:** 65 cataract patients were implanted with SN6AD1 (AcrySof IQ ReSTOR +3.0D IOL, multifocal IOL) or SN60WF (AcrySof IQ Monofocal IOL, monofocal IOL).iTrace system was used to measure the IOL decentration and the intraocular aberrations in 3mm artificial pupil size 3 months after the surgery. Modulation transfer function cut off(MTF cut off) and Strehl ratio (SR) were measured by Objective Quality Analysis System II (OQAS II). The patients who received each IOL type were then divided into three subgroups : low decentration subgroups (decentration $\leq$  0.3 mm) , medium decentration subgroups (0.3<decentration  $\leq$ 0.5mm) and high decentration subgroups ( $\geq$ 0.5 mm), and the effect of IOL decentration on these objective optical quality was analyzed.

**Results:** There was no significant difference in the IOL decentration among the two IOLs ( $P > 0.05$ ) , while significantly lower values of MTF cut off and SR were found in the SN6AD1 group ( $P < 0.001$ ). The MTF cut off and SR of SN6AD1 group were better in low decentration subgroups than high subgroups( $P = 0.037, 0.035$ ). However, no statistical difference was found in three subgroups of the objective optical quality of SN60WF group. When compared the effect according to different decentration subgroups, we found that the MTF cut off and SR performed in SN60WF were better than those in medium and high subgroups of SN6AD1( $P < 0.05$ ). No difference were found in intraocular aberrations between each groups or subgroups( $P > 0.05$ ). Furthermore, IOL decentration in SN6AD1 group were negatively correlated with MTF cut off and SR ( $r = -0.592, P < 0.001$ ;  $r = -0.555, P = 0.001$ ) .But no significantly correlation was found between IOL decentration and the parameter of objective optical quality in SN60WF.

**Conclusion:** Both SN6AD1 and SN60WF IOL show good stability in the capsular bag. SN60WF are more tolerant of decentration, and the SN6AD1 has a good objective optical quality similar to the SN60WF at low decentration ( $\leq 0.3$ mm). SN60WF decentration less than 1.0mm has no influence on Objective visual quality.And SN6AD1 decentration in about 0.3~0.8mm will reduce the MTF cut off and SR.

FP-017

**Trifocal IOLs Implantation in Cataract Patients That Have Experienced Previous Laser Vision Correction**G Scaltrini, M Piovella<sup>1</sup>.<sup>1</sup>*Piovella Global Center For Ophthalmology, Piovella Global Center For Ophthalmology, MONZA, Italy*

**Objective:** Purpose: To evaluate visual performances of trifocal IOLs AT LISA tri 839 MP and AT LISA tri toric 939MP trifocal IOLs (Carl Zeiss Meditec AG - Jena - Germany) in patient that experienced previous laser vision correction

**Methods:** Only eyes with regular cornea were included in this study: 36 eyes of 21 patients mean age:  $56.57 \pm 8.76$  years. Preop SE was  $-0.91 \pm 3.31$  BCDVA  $20/21.40 \pm 3.18$ . Postop were measured: distance (5m) near (40cm) and intermediate (80 cm) VA, corneal topography and aberrometry, contrast sensitivity and defocus curve and quality of vision. Follow-up examinations were performed at day 1 2 7 30 90 180 360 and yearly

**Results:** At six months BCDVA was  $20/20.65 \pm 2.51$ . SE was  $-0.20 \pm 0.45$ . Residual astigmatism was  $0.02 \pm 0.42$ . 83% of eyes after trifocal IOLs implantation achieved postop refractive results within  $\pm 0.75$  diopters

**Conclusion:** Trifocal IOLs provided good visual performances also with patients that experienced laser vision correction decades ago. To be selected for surgery eyes biometry needed to be applied with no difficulties and have to demonstrate no significant differences related the perfect IOLs power also after multiple attempts

**FP-018****Visual Outcomes of Enhanced Monofocal Intraocular Lens Targeted for Minimonovision**H Sabur, U Unsal.

**Objective:** To evaluate visual outcomes, spectacle independence, and patient satisfaction after bilateral implantation of Tecnis Eyhance, an enhanced monofocal intraocular lens (IOL), targeted for minimonovision.

**Methods:** Patients with senil cataract who had bilateral implantation of the Tecnis Eyhance with an emmetropia target in the dominant eye and a myopic refraction of -0.75D in the non-dominant eye were enrolled in this study. Objective refraction, monocular and binocular uncorrected and corrected distance visual acuity (UDVA, CDVA), uncorrected and distance-corrected intermediate visual acuity (UIVA, DCIVA), uncorrected and distance-corrected near visual acuity (UNVA, DCNVA), binocular defocus curves, contrast sensitivity, halo and glare perception, spectacle independence, and patient satisfaction were assessed.

**Results:** 72 eyes of 36 patients were included. The mean binocular UDVA, UIVA, and UNVA were  $0.04 \pm 0.05$ ,  $0.11 \pm 0.03$ ,  $0.34 \pm 0.08$  logMAR, respectively. For values of defocus curves ranging from -0.50 to -2.00 D, minimonovision significantly improved visual acuity compared to when minimonovision was neutralized ( $p < 0.05$ ). Thirty patients (83%) reported complete spectacle independence. Glare, halos, and starbursts were reported to be "not at all" or "a little" bothersome to more than 97% of subjects. The VFQ-25 questionnaire revealed high levels of satisfaction.

**Conclusion:** Implantation of the Tecnis Eyhance IOL with minimonovision resulted in high far and intermediate visual acuity with functional near vision as well as a reduction in spectacle dependence, and an increase in patient quality of life.

FP-019

**mTORC1 signaling underlies axial elongation in lens-induced myopia**R Zhang<sup>1</sup>, L Dong<sup>1</sup>, W Wei<sup>1</sup>.<sup>1</sup>Ophthalmology, Beijing Tongren Hospital, Beijing, People's Republic of China

**Objective:** Myopia, especially high myopia, increases the risk of pathologic ocular changes that would cause irreversible vision loss, such as myopic maculopathy, retinal detachment, and glaucoma. Exploring the mechanism of myopia development and progression becomes a research priority for the prevention of severe vision loss. The molecular dissection of the mechanisms underlying emmetropization signaling passage in the retina will provide effective targets for myopia control. Blockage of epidermal growth factor receptor (EGFR) by intravitreal EGFR antibody injection significantly inhibited axis elongation during negative lens induction. Intravitreal antibody for amphiregulin, a major EGFR ligand, also inhibited axis elongation, which indicated EGFR signaling has a crucial role in myopia development and progression. mTORC1 acts as the direct second messenger of EGFR, it is reasonable to the hypothesis that mTORC1 activation mediates the downstream signaling of EGFR.

**Methods:** Lens-induced myopia was established after 3 weeks duration of binocular negative lens induction on guinea pigs. mTORC1 inhibition is performed by monocular intravitreal everolimus (2μg, 10μg, 20μg) injection. We measured axial length by ocular sonographic biometry. At the end of the study, all guinea pigs were sacrificed and the retina-choroid tissue was collected.

**Results:** We performed 3 weeks of binocular negative lens (-10 Diopter) induction on guinea pigs, which resulted in  $0.23 \pm 0.01$ mm axial elongation. After 3 weeks of myopia induction, we observed the downstream signaling pathway, ERK1/2 and PI3K, were significantly activated in the retina-choroid of guinea pigs. The activated ERK1/2 and PI3K pathways were associated with increased p70S6 Kinase (p70S6K) phosphorylation. Compared to the control group without LIM, guinea pigs underwent binocular LIM and weekly monocular everolimus significantly inhibited mTORC1 activation. Compared to the contralateral eye, monocular everolimus injection also suppressed LIM-induced axial elongation in a dose-response manner. Intravitreal everolimus injection (10 μg) without LIM did not affect the normal axial length growth of 3 weeks age guinea pigs. TUNEL-staining further did not find a significant difference in TUNEL-positive cells in the inner nuclear layer and outer nuclear layer between the guinea pigs that received intravitreal everolimus injection without LIM and normal controls.

**Conclusion:** mTORC1 signaling pathway involved in the development and progression of myopia.

FP-020

### 3% Diquafosol Ophthalmic Solution Alter Ocular Surface parameter in Children Wearing Orthokeratology Lens

Y Yang<sup>1,2</sup>, Q Wu<sup>3</sup>, Y Tang<sup>2,3</sup>, Z Luo<sup>2</sup>, Z Yang<sup>1,2,3</sup>, X Li<sup>2,3</sup>.

<sup>1</sup>Aier School of Ophthalmology, Central South University, <sup>2</sup>Aier Institute of Optometry and Vision Science, <sup>3</sup>Changsha Aier Eye Hospital, Changsha, People's Republic of China

**Objective:** This study investigate the efficacy of 3% diquafosol ophthalmic solution (DQS) on ocular surface in children wearing overnight orthokeratology (OrthoK).

**Methods:** Nineteen participants ( 38 eyes) who wore OrthoK lenses every night and 27 ( 54 eyes) OrthoK lenses candidate (controls) were enrolled in this prospective observational study. All participants received 3% DQS four times per day for 1 month. Noninvasive keratograph tear film break-up time (NIK BUT, first and average), noninvasive tear meniscus height (NIKT MH), conjunctival hyperemia [redness score (RS)], blink pattern analysis, dry eye questionnaire (DEQ-5) were evaluated at baseline and 1 month after intervention.

**Results:** Forty-six children completed the study. NIKTMH increased from  $0.20 \pm 0.06$  mm to  $0.22 \pm 0.05$  mm ( $t=3.88, p=0.00$ ), NIKBUT-F and NIKBUT-A prolonged from  $7.79 \pm 5.84$  s to  $10.50 \pm 6.27$  s, from  $10.00 \pm 6.22$  s to  $13.28 \pm 6.20$  s (all  $p < 0.05$ ) respectively, RS decreased from  $0.65 \pm 0.29$  to  $0.53 \pm 0.28$  ( $t=4.27, p=0.00$ ) and DEQ-5 scores reduced from  $9.18 \pm 3.86$  to  $8.04 \pm 3.06$  ( $t=-2.83, p=0.00$ ), while PBR didn't change significantly. The OrthoK group and controls had similar significant improvement in NIKBUT after intervention ( $p < 0.05$ ). However, OrthoK group demonstrated higher improvement in NIKTMH and dry eye symptoms ( $p < 0.05$ ). Within controls group, RS was improved significantly ( $p < 0.05$ ) but not in NIKTMH and DEQ-5.

**Conclusion:** Short-term use of 3% diquafosol ophthalmic solution clinically reduced dry eye symptoms and also improve ocular surface parameter in children wearing overnight orthokeratology.



**FP-021****Safety and effectiveness of corneal bandage lens for the prevention and treatment of dry eye after cataract surgery in patients with**

Y Li, *Y pan*.

**Objective:** To evaluate the efficacy and safety of corneal bandage in the treatment of dry eye after cataract surgery in patients with mild meibomian gland dysfunction (MGD).

**Methods:** A non-randomized controlled clinical study was conducted. Sixty eyes of 60 patients with mild MGD after cataract surgery were enrolled in Yantai Yuhuangding Hospital from June 2020 to February 2021. The patients were divided into bandage lens group and control group, with 30 eyes in each group. All the patients received phacoemulsification and intraocular lens implantation. Patients in bandage lens group wore lenses for 14 days continuously after the operation and removed them on the 14th day. The structure and inflammation of the anterior segment were observed with a slit-lamp microscope before operation and on days 1, 7, and 14 after the operation. Best corrected visual acuity (BCVA) was obtained using a standard logarithmic visual acuity chart. Ocular surface symptoms were evaluated via an ocular surface disease index (OSDI) questionnaire. The intraoperative changes of meibomian glands were assessed with an ocular surface analyzer and the non-invasive first tear film break-up time (NIFBUT) was recorded. Corneal epithelium defects were observed by corneal fluorescein sodium staining (CFS) and corneal staining was evaluated.

**Results:** On the 1st, 7th, and 14th day after the operation, no inflammatory reaction or complication was observed in both groups. the BCVA values on the 14th postoperative day were significantly higher than those on the 1st and 7th postoperative days in both groups, with statistically significant differences (all at  $P < 0.05$ ). There were statistically significant differences in OSDI scores between the two groups at different postoperative time points ( $F_{\text{group}} = 31.219$ ,  $P < 0.001$ ;  $F_{\text{time}} = 15.672$ ,  $P < 0.001$ ). the NIFBUT values of bandage lens group on the 7th and 14th day after surgery were higher than those of control group, with statistically significant differences (both at  $P < 0.05$ ). The CFS scores of bandage lens group were higher than those of control group on postoperative days 7 and 14, and the differences were statistically significant ( $H = 5.805$ ,  $P = 0.016$ ;  $H = 13.245$ ,  $P = 0.001$ ).

**Conclusion:** For patients with mild MGD after cataract surgery, wearing bandage contact lens has no obvious ocular adverse reactions and can promote the growth of corneal epithelium, enhance the stability of tear film, improve dry eye symptoms, and relieve dry eye manifestations after surgery.

**FP-022****Is decentered orthokeratology treatment effective and safe in controlling myopic progression?**

M Chu, H Ni.

**Objective:** To compare the myopia control efficacy and safety of decentered versus centered positioning of orthokeratology.

**Methods:** This retrospective study included 33 patients with myopia (19 males, 14 females; age  $11.30 \pm 1.76$  years) treated for one year with decentered orthokeratology in one eye (group A) and centered in the other (Group B) from 2018 to 2019. The axial growth, corneal endothelium cell count, and the incidence of corneal epithelial adverse events and glare or ghosting during follow-up were compared between the groups.

**Results:** No differences were found between the groups in the spherical equivalent refraction, astigmatism, Q value, flat K, steep K, axial ocular length, and corneal endothelium cell count before treatment ( $P \geq 0.05$  for all). The axial growth in group A ( $0.08 \pm 0.13$  mm) and group B ( $0.13 \pm 0.11$  mm) was similar ( $P = 0.086$ ) after six months, but differed after 12 months ( $0.14 \pm 0.16$  mm vs.  $0.24 \pm 0.17$  mm, respectively;  $P = 0.016$ ). The corneal endothelium cell count changes after wearing orthokeratology for 12 months were similar in groups A and B ( $34 \pm 253$  cells/mm<sup>2</sup> and  $38 \pm 144$  cells/mm<sup>2</sup>, respectively;  $P = 0.140$ ). Similar corneal spotting rates ( $P = 0.092$ ) were noted during follow-up in groups A ( $n = 16$ ; corneal epithelium staining rate, 8.08%) and B ( $n = 8$ ; 4.04%), all of grade I. The groups were similar in the uncorrected visual acuity (UCVA) except for 1-month follow-up ( $P = 0.023, 0.313, 0.101, 0.109$ ). Group A ( $n = 20$ ; 15.15%) was more likely to have glare or ghosting (chi-squared test,  $P = 0.017$ ) than group B ( $n = 8$ ; 6.06%) during follow-up visits. No apparent strabismus, Kappa angle, or diplopia was detected during the follow-up.

**Conclusion:** This self-control study had few interference factors and showed that when the uncorrected visual acuity was acceptable and there were no apparent corneal complications, decentered orthokeratology positioning may have a better effect on controlling axial growth than the centered positioning.

**FP-023****Comparison of four different orthokeratology lenses in controlling myopia progression**

A Cheema, C *McAlinden*.

**Objective:** To compare axial length (AL) elongation in myopic children with four Orthokeratology (OrthoK) lenses and spectacles.

**Methods:** The medical records of 266 patients (532 eyes) who were fitted with OrthoK lenses or spectacles (control group) were reviewed. Data collection included baseline age, gender, baseline objective sphere and cylinder, baseline flat and steep corneal meridian power, corneal asphericity coefficient (Q value), AL at baseline and after 1-year, and 2-years of OrthoK or spectacle wear analyzed using analysis of repeated measures data ANOVA. Stepwise linear regressions between the changes in AL after 2 years relative to baseline parameters were calculated for the OrthoK and control groups separately.

**Results:** The baseline subject parameters for each of the four OrthoK lenses were not statistically different. Statistically significant differences between time points were found between 12- and 24- months (all  $P < 0.05$ ). AL growth was slower in all OrthoK groups than in the control group (all  $P < 0.05$ ). AL grew  $0.081 \pm 0.034$  mm per year slightly less than average with Essence compared to the Mouldway OrthoK group ( $P = 0.019$ ). The coefficient of regression weakly expressed between the increases in AL over 2-years study period and baseline spherical equivalent refraction was 0.065 in Essence, 0.079 in Euclid and 0.087 in Mouldway. The coefficient of regression was also weakly between age and the increases AL over 2-years study period and baseline age in all groups.

**Conclusion:** Different OrthoK lenses differ minimally in slowing axial elongation effectively in myopic children during 2-years lens wear.

FP-024

**Scleral contact lenses for optimal visual recovery in a case of severe acid burns with total lagophthalmos**S Chaudhary, S Basu<sup>11</sup>, N Jain.<sup>1</sup>Cornea, LV Prasad Eye Institute, Hyderabad, India

**Objective:** To describe the role of scleral contact lenses in managing complications of exposure keratopathy in eyes with total lid loss following severe ocular chemical injury

**Methods:** We present the case of a man in his 40s with severe periocular chemical injury with total lid loss and severe exposure keratopathy. He had 45% burns on his body and needed a tracheostomy and multiple full-thickness skin grafts. His right and left eye underwent Boston type 1 keratoprosthesis and penetrating keratoplasty, respectively. There was melting in the right eye and a persistent epithelial defect in the left eye. Eventually, we suggested 18 mm diameter scleral contact lenses for both eyes to aid ocular surface stabilization.

**Results:** His best corrected visual acuity improved significantly with the scleral lenses from counting fingers close to face in both eyes to 20/100 and 20/320 in the right and left eye, respectively. At 1month follow-up, his vision was stable in the right eye and the pericylindrical melt has resolved alongwith significant improvement in symptoms.

**Conclusion:** Scleral contact lenses provide a reservoir of artificial tears and aid wound healing, reduce symptoms, and improve vision in complicated eyes without eyelids. Therefore, they can be considered for rehabilitation of the ocular surface in eyes with severe chemical periocular injuries.

FP-025

## Quercetin-Loaded Dendritic Nanoparticles Targeting the Biofilm Microenvironment for Bacterial Keratitis Management

Z Lu<sup>1</sup>, H Han<sup>1</sup>, K Yao<sup>1</sup>.

<sup>1</sup>Eye Center, the Second Affiliated Hospital, School of Medicine, Zhejiang University, Hangzhou, People's Republic of China

**Objective:** The study aimed to investigate quercetin-loaded dendritic nanoparticles (QCT@SAPP) to manage severe biofilm-based bacterial keratitis effectively.

**Methods:** The cryo-TEM, LIVE/DEAD staining and sterilization were performed at *P. aeruginosa* biofilms to test the antibiofilm effect of QCT@SAPP in vitro. Meanwhile, the anti-quorum sensing activity was figured out by BODIPY-loaded SAPP, visualizing the nanoparticles' function in HIS-SIM, and a series of virulence factor experiments. Keratitis models of biofilm were performed in mice, and the therapy was evaluated by slit-lamp photos, clinical scoring, colony counting and histological and immunohistochemical analyses of the infected corneas. Distinctively, the SEM of cornea ex vivo and CLSM (GFP-labeled bacteria) images of keratitis biofilm in vivo revealed the therapy process. The restoration of the visual sensitivity and sight of the mice were examined using a visual water test.

**Results:** QCT@SAPP possessed outstanding anti-biofilm capacity, the anti-biofilm ability of SAPP (200ug/mL) was inferior to QCT@SAPP obviously (2 orders of magnitude difference). The LIVE/DEAD staining images and the SEM images of biofilm also verified the perfect sterilization of QCT@SAPP. BODIPY-loaded SAPP was employed to visualize that QCT@SAPP were penetrated into the biofilm and insoluble quercetin was absorbed by bacteria with a considerable proportion. The obvious decrease of biomass, violacein, pyocyanin and EPS in QCT@SAPP group demonstrated the anti-quorum sensing effects of the nanoparticles. The in vivo efficacy of QCT@SAPP in mice bacterial keratitis was manifested excellent. All the therapy evaluation (including slit-lamp photos, clinical scores, colony counting, SEM, CLSM images, water visual task data and histological and immunohistochemical analyses of the infected corneas) revealed the excellent therapy of QCT@SAPP against other groups.

**Conclusion:** In this study, we provide a viable antibacterial alternative, quercetin-loaded dendritic nanoparticles (QCT@SAPP), that can target the biofilm microenvironment with antibacterial performance, showing potential for the treatment of bacterial keratitis. The QCT@SAPP are effective as specific antibiofilm agents which barely lead to drug resistance and exert an improved therapeutic potential against ocular inflammation via a significant downregulation of inflammatory cytokines.

FP-026

## Comparison of Single Administration of 5% Povidone-Iodine and Ganciclovir Ophthalmic Gel 0.15% in Adenoviral Keratoconjunctivitis

S Kocamış<sup>1</sup>, A Boz<sup>2</sup>.

<sup>1</sup>Ophthalmology Department, University of Health Sciences Ankara Dışkapı Yıldırım Beyazıt Training and Research Hospital, Ankara, <sup>2</sup>Ophthalmology Department, Sakarya University Sakarya Training and Research Hospital, Sakarya, Türkiye

**Objective:** To evaluate the efficacy of single administration of 5% povidone-iodine (SAPI) in the treatment of adenoviral keratoconjunctivitis (AKC) by comparing its clinical outcomes with ganciclovir ophthalmic gel 0.15% (GC) treatment.

**Methods:** Medical records of patients who had AKC, confirmed with an immunoassay, and treated with SAPI or GC five times a day for 21 days between January 2019 and January 2022 in Sakarya Training and Research Hospital and Sakarya Yenikent State Hospital were assessed. A clinical score (CS) was generated via grading of conjunctival injection, conjunctival chemosis, corneal subepithelial infiltrates, mucoid and serous discharge, lid edema and lid matting, follicular and papillary response, and Schirmer's test 1. The time to resolve the clinical symptoms, CS, and visual acuity (VA) before the treatment, in the first and third weeks were recorded. Independent t-test, Mann-Whitney U test, Pearson's chi-squared test, and Fischer's exact test were used to compare the variables between the two groups.

**Results:** There were 42 patients (20 male/22 female) and 46 patients (22 male/24 female) in SAPI and GC groups respectively. There was not any difference between two groups regarding age (SAPI:31.8 ± 6.81, GC:30.6 ± 6.81), VA (SAPI:0.97 ± 0.05, GC:0.98 ± 0.04) and CS (SAPI:8.52 ± 1.56, GC:7.93 ± 1.62) before the treatment (p:0.43, p:0.29, p:0.09, respectively). While the mean CS of the SAPI group (2.36 ± 2.40) in week one was lower than that of the GC group (3.39 ± 2.32) (p:0.04), VA (SAPI:0.99 ± 0.04, GC:0.98 ± 0.05) and the number of the patients having corneal subepithelial infiltrates (CSI) (SAPI:4/42, GC:9/46) between two groups were similar (p: 0.29 and p:0.18, respectively). In the third week, CS was not statistically different between the groups (SAPI:0.29 ± 0.60, GC:0.63 ± 1.08, p:0.26). The mean VA of the SAPI group (0.98 ± 0.06) was higher than that of the GC group (0.92 ± 0.12) (p:0.01). While there was not any statistical difference in the number of the patients having CSI between the groups (SAPI: 6/42, GC: 10/46, p:0.36), the number of patients having more than 10 CSI was higher in the GC group than that of the SAPI group (SAPI:1/42, GC:8/46, p:0.03). The mean time to resolution of the clinical symptoms was shorter in the SAPI group (16.5 ± 10.58 days) compared to the GC group (21.46 ± 12.29 days) (p:0.047).

**Conclusion:** SAPI treatment in AKC was found to be superior to GC treatment in terms of improving clinical symptoms in a shorter time, intense CSI in fewer patients, and higher final VA.

FP-027

**An up-to-date meta-analysis of risk factors for dry eye disease**W Yang<sup>1</sup>, K Yang<sup>2</sup>, Y Yang<sup>2</sup>, Y Xing<sup>1</sup>.<sup>1</sup>Aier Eye Hospital of Wuhan University, <sup>2</sup>Department of Ophthalmology, Renmin Hospital of Wuhan University, Wuhan, People's Republic of China

**Objective:** To provide evidence for interventional measures targeting patients with significant risk factors of dry eye disease (DED).

**Methods:** Pubmed, Medline (ovid), ScienceDirect, Embase, China Knowledge Resource Integrated, and Wan Fang Data databases were searched from inception to April 15, 2021. Data were extracted by two independent researchers. Random- and fixed-effects models were applied based on heterogeneity tests. Odds ratios (ORs) are reported with 95% confidence intervals (CIs).

**Results:** Of the 2,578 articles retrieved with targeting searching, 41 (403,170 subjects in total) were included in the final analyses. The following factors were significant risk factors of DED: thyroid disease (OR=1.49 [1.34, 1.66], P<0.001), arthritis (OR=1.56 [1.28, 1.91], P<0.001), diabetes (OR=1.15 [95% CI 1.04, 1.27]; P=0.0055), stroke (OR=1.30 [1.21, 1.39], P<0.001), and depression (OR=1.60 [1.34, 1.92]; P<0.001). Hypertension (OR=1.08; 95% CI 0.99, 1.18; P=0.0727), smoking (OR=1.14 [0.98, 1.33]; P=0.0956), and alcohol use (OR=1.01 [0.84, 1.20]; P=0.9552) were not significant risk factors.

**Conclusion:** In conclusion, additional interventional measures targeting patients with DED risk factors, including thyroid disease, arthritis, diabetes, stroke, and depression should be considered.



FP-028

## The Risk and protective factors of Dry Eye Disease in Type II Diabetic Mellitus patients: A Retrospective Cohort Study

L Pan<sup>1</sup>, Y Kuo<sup>2</sup>, C Sun<sup>2</sup>.

<sup>1</sup>Ophthalmology, Chang Gung Memorial hospital, Linkou branch, Taoyuan City, <sup>2</sup>Ophthalmology, Chang Gung Memorial hospital, Keelung branch, keelung City, Taiwan, China

**Objective:** We conducted a retrospective cohort study using Chang Gang Research database collecting electric medical records from 2005 to 2020 in Taiwan. Patient with type II DM were included, and those without complete demographic data, glycated hemoglobin, with previous ocular diseases including cornea transplantation, pre-existing DED, legal blindness, glaucoma, uveitis and congenital ocular abnormality were excluded. A total of 10,029 of them had developed DED, which, are defined as the DED group; and the other 142,491 with no DED are defined as the non- DED group.

**Methods:** We compare the possible risk and protective factors among two groups and perform a logistic regression model to further analyse the characteristic of these factors.

**Results:** Female patients accounted for the majority of dry eye patients with statistical significance. After age and gender matching, the DED group had significantly higher initial and average HbA1c level ( $p < 0.001$ ); moreover, higher incidence of diabetic neuropathy ( $p < 0.001$ ) and retinopathy ( $p < 0.001$ ) was noted in the DED group. In conditional logistic regression model, advanced age was shown as a risk factor, but a longer DM duration appeared to be protective; after adjusting gender, age and DM duration; average HbA1c, diabetic neuropathy, retinopathy and nephropathy with eGFR between 30~59 were shown as contributing factors for DED, as well as patients receiving intravitreal injection (IVI), trans pars plana vitrectomy (TPPV), pan-retinal photocoagulation (PRP) and cataract surgery. When taking anti-hyperglycemic agents into consideration, DPP4 inhibitor, SGLT2 inhibitor, GLP-1 agonist and insulin monotherapy as well as dual medications combing any two of aforementioned agents were all demonstrated as protective factors against DED compared to Metformin alone. In monotherapy group, the lowest odds ratio medication is SLGT2 inhibitor, followed by GLP1 agonist, DPP4 inhibitor and insulin.

**Conclusion:** The occurrence of DED in diabetic patient are associated with female gender, advanced age, poor diabetic control, and microvascular or macrovascular diabetic complications; receiving various ocular procedures are also shown as risk for developing DED. As for anti-hyperglycemic agents, GLP-1 agonist, SGLT-2 inhibitor, DPP4 inhibitor and insulin monotherapy are superior to Metformin alone in preventing DM-related DED. A prospective randomized control trial will be needed to further clarify our results.

FP-029

**Umbilical cord patch grafting in corneal perforations and descemetocelles – A novel approach**A Majumdar<sup>1</sup>, J Dutta<sup>2</sup>.

<sup>1</sup>Ophthalmology, Regional Institute of Ophthalmology, Kolkata, Kolkata, India, <sup>2</sup>Ophthalmology, Government Medical College and Hospital, Kolkata, Kolkata, Indonesia

**Objective:** To evaluate the clinical outcome of umbilical cord patch (UCP) transplantation for deep corneal ulcers with perforations and descemetocelles.

**Methods:** In this prospective, noncomparative, interventional study, 34 eyes of 34 patients with corneal perforation or descemetocelle of less than 5.5 mm diameter were included. All eyes were treated with UCP for corneal reconstruction. Corneal ulcer healing, corneal thickness, anterior chamber formation, Intra Ocular pressure (IOP) and best-corrected visual acuity (BCVA) were recorded and analysed.

**Results:** The average age was  $53.4 \pm 16.8$  years. The mean time for re epithelialization over the graft was  $83.4 \pm 28.1$  days. The anterior chambers in all patients were formed and no statistically significant difference noted in Anterior chamber depth (ACD) and IOP with other eye in postoperative 6 months period . All patients regained a normal corneal thickness and smooth corneal surface within the 3rd postoperative month. The vision improved in patients with peripheral or para-central perforations or descemetocelle and remained unchanged in eyes those who have central involvement. No recurrence nor side effects occurred during the follow-up.

**Conclusion:** UCP can serve as an alternative material in the treatment of corneal perforations and descemetocelles.

FP-030

### **Incidence and outcome of transplantation of fungal-culturepositive donor corneoscleral tissue in optical keratoplasty**

R Alshabeeb, A Aldayel<sup>1</sup>, H -Osorio<sup>2</sup>, M Ahad<sup>1</sup>.

<sup>1</sup>Cornea ,Cataract and Refractive Surgery, King Khaled Eye Specialist Hosptial, Riyadh, Saudi Arabia, <sup>2</sup>Cornea ,Cataract and Refractive Surgery, Barraqure Eye Hospital Dubai, Dubai, United Arab Emirates

**Objective:** This study aims to determine the incidence of fungal-culture-positive corneoscleral donor rim in patients undergoing keratoplasty and evaluate clinical outcomes of eyes that received these contaminated donor tissues.

**Methods:** Patients who had optical keratoplasty between 2006 and 2016 and were found to have fungal-culture-positive donor rim were included. Microbiological and eye bank records were reviewed to determine the incidence of positive fungal rim cultures. Data were collected on visual and clinical outcomes. The main outcome measures were fungalculture-positive donor rim and development of fungal keratitis or endophthalmitis post keratoplasty. Longterm clinical outcome and associated complications were the secondary outcome measures.

**Results:** Out of 9620 cases of corneal transplants, 145 (1.5%) had fungal-culture-positive donor rim. Candida was the most common organism, cultured in 127 (87.6%) cases. There were no cases of postoperative fungal keratitis or endophthalmitis. Median follow-up was 4.8 years (interquartile range 3.8–7.2 years). Only eight cases (5.5%) received prophylactic antifungal treatment. There were 34 (23.4%) cases of rejection, 13 (8.9%) developed glaucoma, and 7 (4.8%) developed late bacterial keratitis. At last follow-up, best corrected visual acuity was 20/60 or better in 88 cases (60.7%) and 115 eyes (79.3%) had a clear graft.

**Conclusion:** The incidence of fungal-culture-positive donor rim is extremely low. The risk of developing fungal keratitis or endophthalmitis in patients who received contaminated donor tissue was almost negligible. Further studies are warranted to prove whether prophylaxis or adding amphotericin B in Optisol-GS confers any added benefit.

FP-031

### Alterations in Corneal Epithelial Thickness in Patients with Dermatochalasis

N Arslan, M Acar, H Sabur.

**Objective:** To evaluate the corneal epithelial thickness (CET) maps obtained by optical coherence tomography (OCT) of different grades of dermatochalasis.

**Methods:** CET maps of 100 patients with different grades of dermatochalasis and randomly selected one eye of 43 controls were investigated. Dermatochalasis was further grouped into 3 groups: as group 1 mild, group 2 moderate and group 3 severe dermatochalasis according to the amount of the excess skin and its relation to the eyelashes. Three pachymetry scans of each eye were performed by OCT (RTVue-XR, Optovue Inc., USA), and the scan with the highest signal strength index was selected for the analysis. Scans were 6 mm in total diameter, centralizing the pupil with 8 radials and 17 sectors. Complete ophthalmologic examination and anterior segment OCT were done for all of the participants. The patients with the history of previous eyelid surgery, ocular surface disease, amblyopia, use of contact lens, and ophthalmic drops were excluded.

**Results:** The mean age was  $53.8 \pm 10.3$  years in cases with dermatochalasis and  $37.0 \pm 9.0$  years in the control group. The CET in the superior and temporal sectors (S, ST, T) was found to be thinner than the inferior counterparts and nasal sector (I, IN, N) ( $p=0,001$ ) in cases with dermatochalasis. Whereas the difference in the control group was statistically not significant. As the CET was compared according to the severity of dermatochalasis, the ST sector was found to be significantly thinner in severe dermatochalasis compared to those with mild dermatochalasis ( $p=0,02$ ).

**Conclusion:** Dermatochalasis can cause structural changes on cornea specially in the superior and superotemporal sectors, which may have future clinical consequences as refractive problems. The mechanic effect of the excess skin in dermatochalasis to the ocular surface may reshape the corneal epithelium, which can be objectively detected by OCT.

FP-032

**Collagen Cross Linking as an Adjuvant Therapy for Microbial Keratitis Actually Works!!**K Shah<sup>1</sup>, S Potti<sup>2</sup>, S U<sup>3</sup>, S Koya<sup>2</sup>.<sup>1</sup>Cornea & Refractive Surgery, Sankara Eye Hospital, <sup>2</sup>Cornea & Refractive Surgery, <sup>3</sup>Resident (Ophthalmology), Sankara Eye Hospital, Guntur, India**Objective:** To compare the healing status, healing time of ulcer and visual acuity at 3 months in both the groups.**Methods:** A prospective randomized interventional study was conducted in 50 patients with microbial keratitis presenting to Sankara Eye Hospital, Guntur, India. All patients satisfying the inclusion and exclusion criteria, consenting to participate in the study with culture proven bacterial or fungal keratitis of ulcer size <6mm and involving <50% of the depth of cornea were randomly divided into two groups. After detailed ocular examination including slit-lamp examination, patients satisfying the inclusion and exclusion criteria underwent corneal scraping as per standard protocol. The scraping was sent for 10% KOH mount, Gram staining, Sabouraud's Dextrose agar, Blood agar, Chocolate agar and appropriate treatment was given. After obtaining culture results, one group of randomly selected patients were subjected to Collagen Cross Linking (CXL) by standard Dresden protocol and patients of both groups were continued on antimicrobials. Patients were followed up on weekly basis and findings were recorded. 2 cases with signs of worsening of ulcer, 1 from each group underwent Therapeutic keratoplasty. All the data was entered in a proforma and the results were tabulated using IBM SPSS version 22 and statistically analyzed.**Results:** In our analysis, we included 44 patients with culture proven microbial keratitis, categorized into two groups; one group with 22 patients received CXL along with standard antimicrobials and the other group with 22 patients received antimicrobials alone. The median time to heal in cases was 3 weeks (IQR2,5) and 5 weeks (IQR3.5,6) in controls and the difference was statistically significant (P value=0.014). The median Best Corrected Visual Acuity after 3 months in cases was 0.48 (IQR-0.27,0.78) logMAR units, while in controls was 0.39 (IQR-0.18,1) logMAR units and the difference was statistically not significant (P value=0.767). It is due the additional haze created by the CXL procedure extending onto the visual axis. CXL has not resulted in any adverse event.**Conclusion:** CXL is a promising option as an adjuvant therapy in cases of microbial keratitis (i.e., bacterial and fungal) with an ulcer diameter <6mm and infiltration <50% of the depth of cornea by quickening the healing process/ eradicating the causative pathogens. A larger study is required to confirm this observation.

FP-033

### Comparative study of efficacy of topical Bepotastine besilate versus Alcaftadine in patients with vernal keratoconjunctivitis

N Yadav, S Sachdeva<sup>1</sup>, M Rath<sup>2</sup>.

<sup>1</sup>Ophthalmology, RIO, PGIMS, <sup>2</sup>Ophthalmology, Regional Institute of Ophthalmology, PGIMS, Rohtak, India

**Objective:** To study the efficacy of bepotastine besilate versus alcaftadine in patients with VKC.

**Methods:** A comparative, randomized, single-blind and prospective study was conducted in a tertiary care centre in North India. Study included 100 patients with VKC and were allocated to either of the two treatment groups. Patients in Group A received Alcaftadine(0.25%) eye drops once daily, while Group B received bepotastine besilate (1.5%) twice daily for 8 weeks. The efficacy assessment was done at baseline and then at 4 and 8 weeks post-treatment. The patients were evaluated by the following parameters - the Primary endpoints included clinical symptoms score and clinical signs score at 4 and 8 weeks and secondary endpoints included upper tarsal conjunctival brush cytology for eosinophil count.

**Results:** On intra-group analysis of clinical symptoms score in VKC patients, it was noted that there was **statistically significant reduction in clinical symptoms & signs score** when compared to baseline values at the end of 4 and 8 weeks with both the drugs. In Group A, baseline mean symptom score was  $7.04 \pm 0.56$  which reduced to  $1.72 \pm 0.50$  at 8 weeks. Similarly in Group B, the baseline clinical symptom score was  $7.78 \pm 0.39$ . The clinical symptoms score reduced to  $2.26 \pm 0.19$  at 8 weeks.

On evaluating upper tarsal conjunctival brush cytology, it was found that eosinophil count reduced significantly both in Group-A and Group-B at 8 weeks post-treatment. Both the treatments were found to be equally effective with regard to improvement in eosinophil count. Difference in reduction in eosinophil count amongst the two groups was statistically insignificant.

**Conclusion:** This study concluded that both drugs were equally efficacious in relieving signs and symptoms of VKC. Response of both drugs was statistically significant ( $p < 0.0001$ ). Difference in improvement of signs, symptoms, eosinophil count and quality of life between both the groups drugs was not statistically significant. Both the drugs proved equally efficacious in alleviating signs and symptoms of VKC at 4 weeks and 8 weeks post treatment.

Hence, we conclude that both Alcaftadine and Bepotastine are equally efficacious and both can be used in management of VKC. The benefit of Alcaftadine over Bepotastine is in its once daily schedule, but it is slightly more expensive than Bepotastine. Hence both may be used according to the scenario and considering patient's affordability.

FP-034

**Age-related analysis of corneal biomechanical parameters in healthy Chinese individuals**G Yihan<sup>1</sup>, G LiLi<sup>2</sup>, Y Weiqiang<sup>3</sup>, T Lei<sup>1,4</sup>, J Ying<sup>1</sup>.

<sup>1</sup>Beijing Tongren Eye Center, Beijing Tongren Hospital, Beijing, <sup>2</sup>The First People's Hospital of Xuzhou, Xuzhou, <sup>3</sup>Beijing Chaoyang Hospital, Capital Medical University, Beijing, <sup>4</sup>Beijing Advanced Innovation Center for Big Data-Based Precision Medicine, Beihang University, Beijing, China

**Objective:** To report the correlation between corneal biomechanical parameters and age in healthy Chinese individuals.

**Methods:** The study was a cross-sectional survey conducted on 864 eyes of 543 healthy participants. A comprehensive ophthalmic examination and corneal biomechanics examination using Corneal Visualization Scheimpflug Technology (Corvis ST) were conducted. Based on age, all participants were further divided into five age groups (*n*) as follows: group A, 11–20 years (105); group B, 21–30 years (112); group C, 31–40 years (113); group D, 41–50 years (100); and group E, >50 years (113). Using Corvis ST, we examined 35 corneal biomechanical parameters and compared them across the different age groups. Spearman's correlation coefficients and stepwise multivariate linear regression models were used to investigate whether the corneal biomechanical parameters were related to demographic and ocular characteristics.

**Results:** The study included 864 (431 right and 433 left) eyes of 543 healthy participants. A correlation analysis between the left and right eyes of 35 biomechanical parameters revealed that six parameters were significantly associated with eye differences. Among the 28 dynamic corneal response parameters, 22 exhibited significant differences across the age groups. Moreover, out of the seven Vinciguerra screening parameters, only bIOP was similar among all age groups. Spearman's correlation analysis showed that most of the parameters were significantly associated with age, IOP, and CCT. Furthermore, a stepwise multivariate linear regression analysis revealed that Corvis biomechanical index had a significant negative correlation with age, IOP, and CCT, whereas SPA1 and SSI were positively correlated with IOP.

**Conclusion:** Corneal biomechanical parameters can be significantly affected by age, albeit without any obvious differences between the left and right eyes. Corneal hardness was significantly correlated with age, IOP, and CCT.

FP-035

## Efficacy and Safety of Corneal Crosslinking with the Sub400 Protocol in Progressive Keratoconus Patients with Thin Corneas

B Uysal.

**Objective:** To investigate the efficacy and safety of corneal cross-linking (CXL) with the Sub400 protocol in arresting disease progression at 12-month follow-up in keratoconus patients with thin corneas.

**Methods:** Keratoconus patients whose corneal thickness was less than 400  $\mu\text{m}$  after epithelial debridement during CXL and whose UVA dose was adjusted according to the stromal thickness (sub400 protocol) were included in the present study. Patients' medical file records, corneal topography (Pentacam) and demarcation line data obtained by anterior segment OCT (MS-39) were analyzed retrospectively. Best corrected visual acuity (BCVA), manifest spherical equivalent (MSE), mean keratometry (K-mean), maximum keratometry (K-max), minimum corneal thickness (MCT), and demarcation line depth (DHD) values at preoperative and postoperative 6 and 12 months were recorded. An increase in K-max of more than 1 diopter at the end of 12-month follow-up was noted as progression.

**Results:** Thirty-one eyes of 27 patients underwent Sub400 CXL. The DHD at postoperative 1 month was  $311.06 \pm 61.78 \mu\text{m}$  (min: 97  $\mu\text{m}$  - max: 408  $\mu\text{m}$ ) and the distance of the demarcation line to the corneal endothelium was  $87.68 \pm 38.14 \mu\text{m}$  (min: 30  $\mu\text{m}$  - max: 200  $\mu\text{m}$ ). No haze of more than grade 1 or corneal endothelial decompensation was observed in any eye in the postoperative follow-up. 17 eyes had a 6-month follow-up and 11 eyes had a 12-month follow-up. BCVA (logMAR) of 17 eyes at preoperative and postoperative 6 months was  $0.71 \pm 0.52$ ,  $0.59 \pm 0.50$  ( $p=0.041$ ); MSE (D)  $-6.93 \pm 3.42$ ,  $-7.74 \pm 3.30$  ( $p=0.507$ ); K-mean (D)  $56.83 \pm 9.31$ ,  $56.26 \pm 9.69$  ( $p=0.059$ ); K-max (D)  $67.09 \pm 12.44$ ,  $66.73 \pm 13.20$  ( $p=0.185$ ); MCT ( $\mu\text{m}$ ) was  $392.59 \pm 47.38$ ,  $377.82 \pm 43.94$  ( $p=0.000$ ), respectively. BCVA (logMAR) of 11 eyes at preoperative and postoperative 12 months was  $0.87 \pm 0.57$ ,  $0.68 \pm 0.50$  ( $p=0.186$ ); MSE (D)  $-6.97 \pm 4.17$ ,  $-5.03 \pm 9.61$  ( $p=0.404$ ); K-mean (D)  $59.57 \pm 9.45$ ,  $58.53 \pm 9.66$  ( $p=0.012$ ); K-max (D)  $69.06 \pm 13.89$ ,  $68.18 \pm 14.29$  ( $p=0.142$ ); MCT ( $\mu\text{m}$ ) was  $387.27 \pm 46.87$ ,  $377.00 \pm 45.15$  ( $p=0.002$ ), respectively. Progression was observed in none of the eyes at the end of 6 months and in 1 eye (9.09%) at the end of 12 months.

**Conclusion:** As thin corneas have a higher risk of progression after CXL than corneas thicker than 400  $\mu\text{m}$ , both safe and effective CXL treatment is required in thin keratoconic corneas. In our study, it was demonstrated that 91% stabilization was achieved with the Sub-400 protocol in ultra-thin corneas at the end of 1-year follow-up without any adverse effects.



FP-036

## A Next Generation Crosslinking Calculator For Titrating Ultraviolet Energy (Nxt-Uva) In Thin Keratoconic Corneas

R R Ranade, R Shetty<sup>1</sup>, A Sinha Roy<sup>1</sup>, P Khamar<sup>1</sup>, S Dsouza<sup>1</sup>.

<sup>1</sup>NARAYANA NETHRALAYA, BENGALURU, India

**Objective:** To evaluate the performance of the NXT (New generation CXL for Thin Cornea) UV-A calculator, which aids in customizing fluence to the corneal thickness for crosslinking (CXL) in thinner corneas.

**Methods:** The study included 84 eyes of 84 patients with progressive keratoconus and mean thinnest corneal thickness (TCT)  $<420 \mu\text{m}$ . Corneal tomography, epithelial mapping (CSO MS39 ASOCT) and specular microscopy were done preoperatively and postoperatively. Mean TCT after de-epithelialization was entered into the custom-built web-based calculator, which gave us customized fluence time based on the chosen UV power (<https://jscalc.io/calc/VmanUJD6yQ13VQQ6>). The NXT UVA calculator provided fluence times for UV powers of 9 and 3 mW/cm<sup>2</sup>, which are commonly used for the accelerated protocol and for 0.1 and 0.2% riboflavin concentrations. Post-operative assessments were performed at 1 week, 1, 3, 6 and 12 months for safety and efficacy.

**Results:** Estimation of safety determined that there was no post operative loss of lines/visual acuity (VA) and no significant haze on densitometry. Pre-op values of were K1  $52.6 \pm 4.95$ , K2  $57.68 \pm 5.28$ , Kmax  $64.71 \pm 8.42$ . Efficacy determinants demonstrated decrease in K1 ( $51.37 \pm 5.55$ ,  $p < 0.0001$ ), K2 ( $56.76 \pm 6.15$ ,  $p = 0.0002$ ) and stable Kmax ( $63.99 \pm 8.6$ ,  $p = 0.2$ ) at 6 months and no change in cell density on specular microscopy ( $2707.7 \pm 270.9$  pre-operatively to  $2641.33 \pm 374.9$  post-operatively,  $p = 0.2$ ). 64% had a demarcation line at 3 months at a depth of  $295 \pm 71 \mu\text{m}$ .

**Conclusion:** The UV "on" time needs to be titrated based on the corneal thickness, riboflavin concentration and incident intensity to minimize the risk of damage to the corneal endothelium. The NXT Calculator thus provides a easy, quick, user-friendly approach of CXL in thin corneas, with no additional tools and no risk of corneal scarring.

FP-037

**Lysozyme protects against SARS-CoV-2 infection and inflammation in human corneal epithelial cells**Y Song<sup>1</sup>, H Zhang<sup>1</sup>, H Yan<sup>1</sup>.<sup>1</sup>Department of Ophthalmology, Tianjin Medical University General Hospital, Tianjin, People's Republic of China

**Objective:** To investigate the effects of lysozyme, an antimicrobial enzyme found in tears that protects the eye against pathogens, on pseudotyped severe acute respiratory syndrome coronavirus 2 (SARS-CoV-2) infection through corneal epithelial cells.

**Methods:** The expression of the angiotensin-converting enzyme 2 (ACE2) and transmembrane serine protease (TMPRSS2) in human corneal epithelial cells (HCECs) was measured by RT-PCR and Western blotting. The altered expression of the proinflammatory molecules induced by spike protein and lysozyme was analyzed by RT-PCR. Cell toxicity was tested by CCK8 assay. The cell entry of SARS-CoV-2 was detected by luciferase assay.

**Results:** ACE2 and TMPRSS2 were highly expressed in HCECs. The spike proteins of SARS-CoV-2 stimulated a robust inflammatory response in HCECs, characterized by increased secretion of proinflammatory molecules, including IL-6, TNF- $\alpha$ , iNOS, and MCP-1. And pretreatment with lysozyme in HCECs markedly decreased the production of proinflammatory molecules induced by spike proteins. In addition, the inflammatory cytokine TNF- $\alpha$  enhanced the entry of SARS-CoV-2 into HCECs, which can be mitigated by pretreatment with lysozyme.

**Conclusion:** In this study, we analyzed the susceptibility of human corneal epithelial cells to SARS-CoV-2 infection and suggested the protective effects of lysozyme on SARS-CoV-2 infection.

FP-038

## Clinical and Confocal Microscopy Correlation in a Pioneer Experience of Advanced Cell Therapy in Keratoconus

M El Zarif, K Abdul Jawad<sup>1</sup>, J Alió Del Barrio<sup>2</sup>, J Alió<sup>2</sup>.

<sup>1</sup>Optometry, Optica General, Saida, Lebanon, <sup>2</sup>Ophthalmology, Miguel Hernandez University, Alicante-Spain, Alicante, Spain

**Objective:** Managing keratoconus, recently we described a new surgical approach based on advanced regenerative therapy, using autologous adipose-derived adult stem cells (ADASCs) and decellularized/recellularized human corneal stromal laminae with ADASCs into corneas with advanced keratoconus. We report herein the safety and efficacy of the surgery, the clinical results of 3-year, and corneal confocal microscopy evolution in vivo of the cell density in the corneal stroma, as well in the implanted laminae, along with one year of follow-up. Also, to evaluate the presence of fibrotic structures and the association between the degree of fibrosis and recellularization.

**Methods:** Fourteen consecutive patients were involved in three experimental groups. Group-1 patients underwent implantation of autologous ADASCs ( $3 \times 10^6$  cells/1 ml) (n = 5). Group-2 patients received decellularized donor corneal stromal lamina 120  $\mu$ m thick (n = 5). Group-3, patients received implantation of recellularized lamina with ADASCs ( $1 \times 10^6$  cells/1ml) (n = 4). Implantation was performed into a femtosecond-assisted 9.5 mm diameter lamellar pocket. 36 months of follow-up clinical data are presented. Besides, one-year follow-up of the cell density evolution, morphological changes of implanted cells, as well the formation of fibrotic structures using confocal microscopy.

**Results:** three-year clinical outcomes were obtained in (G-1, G-2&G-3) regarding the preoperative mean values: An increase of 1-2 logMar lines with the UDVA, CDVA, and CLDVA. We obtained a statistically significant increase in CCT with G-2 [P=0.012] and G-3 [P<0.001], Thinnest-point in G-2 [P=0.007], and G-3 [P=0.001] when compared to G-1. A significant increase [P<0.001] was observed in the cell density in the anterior and posterior corneal stroma with all the groups and the implanted laminae. There was not a significant association between recellularization and the presence of fibrotic tissue.

**Conclusion:** Intrastromal implantation of ADASCs, and decellularized/ADASCs-recellularized human corneal stroma laminae did not have complications at 3 years in advanced keratoconus. The technique showed a moderate improvement in UDVA and CDVA, and a significant increase in corneal thickness in the groups that received laminae. Using confocal microscopy, we observed a significant increase in cell density at one year in the corneal stroma, as well in the implanted tissue. The increase in the cell density was not significantly correlated with the presence of fibrotic tissue.

FP-039

## Metagenomic Profiling of the Ocular Surface Microbiome in Patients after Allogeneic Hematopoietic Stem Cell Transplantation

J Li, L Liang<sup>1</sup>.

<sup>1</sup>Zhongshan ophthalmic center, Guangzhou, People's Republic of China

**Objective:** To investigate the characteristics of the ocular surface microbiome in patients after allogeneic hematopoietic stem cell transplantation (allo-HSCT) and the associations between the microbial dysbiosis and chronic ocular graft-versus-host disease (oGVHD).

**Methods:** Ocular surface samples from 48 healthy subjects and 76 patients after allo-HSCT, including 50 patients with chronic oGVHD and 26 patients without oGVHD were collected. Species-level composition of the ocular surface microbiome was surveyed via metagenomic shotgun sequencing. OGVHD was diagnosed and graded according to the International Chronic Ocular GVHD (ICO) Consensus Group criteria.

**Results:** The  $\alpha$ -diversity of the microbiota was significantly decreased in patients after allo-HSCT. Nevertheless, we detected more types of viral species in the allo-HSCT group than the healthy group, especially anelloviruses. The mismatch of donor-recipient sex was only negatively associated with the  $\alpha$ -diversity in male but not female recipients. Moreover, the microbiome of oGVHD patients was distinct from non-oGVHD patients. *Gordonia bronchialis* and *Pseudomonas parafulva* were enriched in oGVHD patients and positively associated with ICO score.

**Conclusion:** This study suggests that the ocular surface microbiome after allo-HSCT is characterized by a loss of diversity. Furthermore, the microbial dysbiosis at the ocular surface is associated with the status and severity of chronic oGVHD. These results lay the groundwork for future investigations of the potential microbial mechanism for oGVHD.

FP-040

**Plasma Arc As Treatment For Severe Corneal Infectious Melting Challenging Cases**L Garduño Vieyra<sup>1</sup>, R Rúa Martínez<sup>2</sup>.<sup>1</sup>Anterior Segment, <sup>2</sup>Retina, Oftalmología Garduño, Irapuato, Guanajuato., Mexico**Objective:** To describe the use of plasma arc for severe corneal infectious melting challenging cases.**Methods:** Three cases with infectious corneal melting were described. The first one is after refractive surgery (patient 1), the second one is secondary to vegetable ocular trauma (patient 2), and the third is due to improper use of contact lenses (patient 3). Given the non-response to topical treatment and the severity of the corneal melting, it was decided to use a plasma arc to reduce the microorganism colony and avoid mechanical debridement. The procedure consists in evaporating the affected corneal surface, exciting the electrons of the atoms with an arc of plasma.**Results:** Patient 1, on postoperative refractive surgery day 4 had visual acuity (VA) of hand motion perception and laboratory found Fusarium. Patient 2, three weeks after a vegetal ocular trauma came with VA of light perception and laboratory report Fusarium too. Patient 3 was multi-treated and arrived after 3 weeks of symptoms with VA of questionable light perception, with corneal perforation, culture informs Acanthamoeba. The three patients had a severe corneal melting and after informed consent, it was done plasma arc. The Plasma surgery evaporates the infectious tissue using the plasma arc. After surgery treatment and 4 months of postoperative consultations, patient 1 achieved VA 20/25 with total corneal recovery, patient 2 final VA was 20/200 with total corneal recovery too. On patient 3 anterior chamber with corneal recovery was obtained, and there was a final VA of hand motion perception.**Conclusion:** The plasma arc is an effective treatment tool in patients with severe corneal melting.

FP-041

**Which one is more sensitive: Corneal Biomechanics or Corneal Topography for the Diagnosis of Early Keratoconus?**X Chen, H Cao, Y Huo, Y Wang.

**Objective:** To explore the capacity of corneal topography and corneal biomechanics in diagnosing early keratoconus (KC).

**Methods:** A prospective cohort study included a total of 306 patients. KC group (n = 80): patients with bilateral KC, one eye was randomly selected; early KC group (n = 72): the fellow eye of patients with unilateral KC and relatively normal topography; normal control (NL) group (n = 154): candidates for corneal refractive surgery, one eye was randomly selected. Receiver operating characteristic curves were used to assess the capacity of corneal topography and corneal biomechanics to diagnose early KC and to calculate cut-off values, sensitivity, and specificity.

**Results:** A total of 34 parameters, including 20 corneal morphology related parameters and 14 corneal deformation related parameters, were analyzed in this study. Analysis of the area under the receiver operating characteristic curve (ROAUC) found that most corneal parameters were shown to have excellent (ROAUC  $\geq$  0.9) capacity for the diagnosis of KC. A1 dArcLength (ROAUC = 0.865) showed the best diagnostic capacity, although a single parameter did not have excellent capacity in diagnosing early KC, and of the top ten parameters, 80% were corneal biomechanical parameters, which included A1 dArcLength, Tomographic and Biomechanical Index, Belin/Ambrósio Deviation, Max InverseRadius, Corvis Biomechanical Index composed based on Chinese, A2 dArcLength, A2 Time, Deviation of ARTmax, Radius, Corvis Biomechanical Index, Ambrósio's Relational Thickness to the horizontal profile.

**Conclusion:** The assessment of corneal biomechanics is more advantageous than corneal topography in detecting keratoconus-like changes as early as possible.

FP-042

### Comparison between dry eye questionnaire 5 (DEQ- 5) with the ocular surface disease index (OSDI) in children taking online class

. Jethani<sup>1</sup>, D Dalal<sup>2</sup>, S Mishra<sup>3</sup>, A Kamath<sup>4</sup>.

<sup>1</sup>Director, Baroda eye care and Squint clinic, <sup>2</sup>Department of Paramedical and Health Sciences, <sup>3</sup>Optometry Intern, Department of Paramedical and Health Sciences,, Faculty of Medicine, Parul University, <sup>4</sup>Pediatric Optometrist, Baroda eyecare and Squint clinic, Vadodara, India

**Objective:** To compare between dry eye questionnaire 5 (DEQ-5) with the ocular surface disease index (OSDI) in children taking online classes and correlating it with the total number of hours per day usage of screen

**Methods:** A comparative study was been conducted at Baroda Children Eyecare and Squint clinic, Gujarat, India among school going children of age group 4- 16 taking online classes. Total screen time was documented apart from the demographic data.

Either the child or parents were asked to fill out the OSDI and DEQ-5 questionnaire. Children spending less than or equal to 4 hours on screen in a day or more than 4 hours in a day were separated in two groups. Both the groups had 35 children each. DEQ-5 and OSDI Questionnaire were given to both group of children. Scores were calculated as per the response and compared.

**Results:** Mean age of 70 children was 6.3 +/- 2.8 years with less than or equal to 4 hours group having mean age of 5.8 +/- 3.2 years and more than 4 hours screen time group having mean of 6.8 +/- 1.2 years

OSDI score was calculated on the basis of the formula Sum of cores X25/ total questions answered. Mean score for OSDI in less than 4 hours screen exposure is 29.1 +/- 11.6 and with more than 4 hours screen time exposure is 37.5 +/- 12.4. On doing a student t test, the p value was significant.

In DEQ-5 questionnaire, the mean score is 3.4 +/- 0.8 in children with less than or equal to 4 hours of screen time whereas in the more than 4 hours screen time it was 6.2 +/- 0.9. The p value was less than 0.05 on doing a student t test. The increased number of screen time are directly related with the increased OSDI and DEQ-5 questionnaire.

**Conclusion:** We found that children having screen time < than =4 hours are less affected as per OSDI and DEQ-5 scores compared with children who use screen more than 4 hours per day. Screen time is directly related with increase in dry eye symptoms and OSDI and DEQ-5 scores. The changes seen due to increased screen time are much higher in DEQ-5 than in OSDI score.

FP-043

### Evaluation of artificial intelligence models for the detection of asymmetric keratoconus eyes using Scheimpflug tomography

Z Xu, R Feng, J Wu, K Yao.

**Objective:** To evaluate artificial intelligence (AI) models based on objective indices and raw corneal data from the Pentacam HR system (OCULUS Optikgeräte GmbH, Wetzlar, Germany) for the detection of clinically unaffected eyes in patients with asymmetric keratoconus (AKC) eyes.

**Methods:** A total of 1108 eyes of 1108 patients were enrolled, including 430 eyes from normal control subjects, 231 clinically unaffected eyes from patients with AKC, and 447 eyes from keratoconus (KC) patients. Eyes were divided into a training set (664 eyes), a test set (222 eyes) and a validation set (222 eyes). AI models were built based on objective indices (XGBoost, LGBM, LR, and RF) and entire corneal raw data (KerNet). The discriminating performances of the AI models were evaluated by accuracy and the area under the ROC curve (AUC).

**Results:** The KerNet model showed great overall discriminating power in the test (accuracy=94.67%, AUC=0.985) and validation (accuracy=94.12%, AUC=0.990) sets, which were higher than the index-derived AI models (accuracy=84.02%–86.98%, AUC=0.944–0.968). In the test set, the KerNet model demonstrated good diagnostic power for the AKC group (accuracy=95.24%, AUC=0.984). The validation set also proved that the KerNet model was useful for AKC group diagnosis (accuracy=94.12%, AUC=0.983).

**Conclusion:** KerNet outperformed all the index-derived AI models. Based on the raw data of the entire cornea, KerNet was helpful for distinguishing clinically unaffected eyes in patients with AKC from normal eyes.



FP-044

## Conjunctival impression cytology & its relationship with ocular GvHD in those undergoing hematopoietic stem cell transplantation

D Rh, T GP<sup>1</sup>.

<sup>1</sup>Department of Ophthalmology, MS Ramaiah Medical College, Bangalore, India

**Objective:** To study the conjunctival impression cytology (CIC) changes in all patients undergoing HSCT and to study the proportion of Dry eye syndrome in patients undergoing HSCT by using CIC as a tool to detect ocular GvHD.

**Methods:** This was a prospective study design. All patients that underwent HSCT underwent a complete ophthalmic examination that included -visual acuity, dry eye evaluation- Schirmer's test, Tear film Break-up Time and subjected to the OSDI questionnaire. Conjunctival Impression cytology was performed after informed consent. All patients who undergo HSCT were thus included and assuming that the sensitivity of detecting GvHD based on conjunctival impression cytology as 80%; in the present study expecting similar results with 95% confidence interval and 14% absolute precision, 14 eyes were included in the study.

**Results:** Out of the total 14 eyes who underwent allogenic HSCT (hematopoietic stem cell transplantation) whose mean age was between  $21.4 \pm 11.06$  years, 6 eyes showed clinical signs of ocular Graft versus host Reaction i.e., symptoms of dry eye disease were noted in 26%. Subjective tests like the Ocular Surface Disease Index score were mild, moderate & severe in 11.57%, 24.83%, and 14.83% respectively. Objective tests like the Tear film breakup time was found to be less than 5 seconds in 35.83%, more than 5 seconds in 46.27% of eyes. While the Schirmer's I test score was less than 5 mm in 43.25%. It was found that the Conjunctival Impression Cytology was abnormal in 35.71% with altered morphology seen in 5 eyes in patients who underwent HSCT ( $p=0.007$ ).

**Conclusion:** We can expect significant changes ocular surface morphology and it can be picked up by performing CIC and can be used as an invaluable tool to detect early changes of ocular GvHD. Hence it can be utilized as a screening tool in conjunction with other time-tested objective and subjective tests to evaluate Ocular GvHD and Dry Eye Syndrome in those undergoing HSCT.

FP-045

**Thermosensitive chitosan-based hydrogels sustained releasing iPSC-MSCs exosomes for corneal epithelium and stroma regeneration**Q Tang, B Lu<sup>1</sup>, K Yao<sup>1</sup>.<sup>1</sup>Zhejiang university, Hangzhou, People's Republic of China

**Objective:** Corneal damage forms scar tissue and manifests as permanent corneal opacity, which is the main cause of visual impairment caused by corneal diseases. The aims were to elucidate the relevant signaling pathways and molecular mechanisms of miR-432-5p in corneal damage, and to confirm the effect of tissue engineered cornea of sustained-releasing iPSC-MSCs or iPSC-MSC-exosomes on rat corneal anterior lamellar injury.

**Methods:** The present study was divided into three stages: firstly, the role of iPSC-MSC-exosomes on HCEs and CSSCs was determined *in vitro* and the study of the highly expressed exosomal miR-432-5p on the expression of collagen in CSSCs was studied. Secondly, the thermosensitive chitosan-based hydrogel was designed and prepared to the sustained releasing iPSC-MSC-exosomes for corneal epithelium and stroma regeneration. Finally, the constructed tissue engineered cornea was used in rat corneal anterior lamellar injury.

**Results:** Present study showed that iPSC-MSCs derived exosomes (iPSC-MSC-exos) can enhance the proliferation and migration of human corneal epithelium cells (HCEs) and corneal stromal stem cells (CSSCs). Moreover, iPSC-MSC-exosomes downregulate the collagen genes expression of CSSCs *in vitro*. On the basis of thermosensitive chitosan-based hydrogels (CHI) developed in our previous study, the tissue engineered cornea of sustained-releasing iPSC-MSCs or iPSC-MSC-exosomes can effectively promote the repair of damaged corneal epithelium and stromal layer, downregulating the expression of mRNA encoding the three most abundant collagens (collagen type I alpha 1, collagen type V alpha 1 and collagen type V alpha 2) in corneal stroma and reducing scar formation *in vivo*. Further, iPSC-MSCs secrete exosomes containing miR-432-5p, which represses TRAM2, a vital regulator of collagen biosynthesis in the CSSCs to prevent the extracellular matrix (ECM) deposition.

**Conclusion:** These findings indicate that iPSC-MSCs secrete miRNA-containing exosomes to promote corneal epithelium and stroma regeneration and that miR-432-5p can prevent ECM deposition through a mechanism most likely related to direct suppression of its target gene TRAM2.

FP-046

**Melatonin attenuates LPS-induced proinflammatory cytokine response and lipogenesis in human meibomian gland epithelial cells**R Liu<sup>1</sup>, L Liang<sup>1</sup>.<sup>1</sup>State Key Laboratory of Ophthalmology, Zhongshan Ophthalmic Center, Sun Yat-sen University, Guangzhou, People's Republic of China

**Objective:** Inflammation contributes to the development of meibomian gland dysfunction (MGD) under specific disease conditions, but the underlying mechanisms remain elusive. We examined whether lipopolysaccharide (LPS) induced a proinflammatory cytokine response and lipogenesis in human meibomian gland epithelial cells (HMGEs) and whether melatonin (MLT), a powerful anti-inflammatory reagent in the eyes, could protect against LPS-induced disorders.

**Methods:** Human meibomian gland (MG) tissues and immortalized HMGEs were stained to identify Toll-like receptor (TLR) 4 and MLT receptors (MT<sub>1</sub> and MT<sub>2</sub>). HMGEs were pretreated with or without MLT and then stimulated with LPS. Then, TLR4 activation, cytokine levels, lipid synthesis, apoptosis, autophagy, and MAPK/NF- $\kappa$  B factor phosphorylation in HMGEs were analyzed.

**Results:** TLR4, MT<sub>1</sub>, and MT<sub>2</sub> were expressed in human MG acini and HMGEs. Pretreatment with MLT inhibited the TLR4/MyD88 signaling and attenuated proinflammatory cytokine response and lipogenesis in LPS-stimulated HMGEs, which manifested as decreased production of cytokines (IL-1 $\beta$ , IL-6, IL-8, and TNF- $\alpha$ ), reduced lipid droplet formation, and downregulated expression of meibum lipogenic proteins (ADFP, ELOVL4, and SREBP-1). Phospho-histone H2A.X foci, lysosome accumulation, and cytoplasmic cleaved caspase 3/LC3B-II staining were increased in LPS-stimulated HMGEs, indicating enhanced cell death mediated by apoptosis and autophagy during LPS-induced lipogenesis. MLT downregulated cleaved caspase 3 levels and the Bax/Bcl-2 ratio to alleviate apoptosis and ameliorated the expression of Beclin 1 and LC3B-II to inhibit autophagy. The protective mechanisms of MLT include the inhibition of MAPK and NF- $\kappa$  B phosphorylation.

**Conclusion:** MLT attenuated lipogenesis, apoptosis, and autophagy in HMGEs induced by proinflammatory stimuli, indicating the protective potential of MLT in MGD.

FP-047

## Hyperosmolarity Promotes the Macrophage Pyroptosis by Driving the Glycolytic Reprogramming of Corneal Epithelial Cells in Dry Eye

X Huang, Y han, Y zhang.

**Objective:** To reveal the mechanism how pyroptosis was mediated by glycolytic reprogramming and promotes aseptic inflammation in dry eye disease (DED) using in vivo and vitro models.

**Methods:** The mechanism how hyperosmolar microenvironment drives the metabolic reprogramming of HCECs and regulates the pyroptosis was explored in clinical, in vitro, and in vivo. Human conjunctival epithelial cells obtained by conjunctival impression cytology and tears of DED patients, were collected for the test of the expression of gene related to glycolysis and pyroptosis, as well the production of related inflammatory cytokines. Co-culture of HCECs and activated immune cells, macrophages derived from THP-1 cells, were carried out to explain the interaction between cells. HCECs were treated with NaCl solution as the DED hyperosmolar model and glycolysis inhibitor, 2-DG, was used to indicate the role of glycolytic reprogramming. Then macrophages derived from THP-1 cells by PMA stimulation was co-cultured with the supernatant of HCECs to study the changes of aseptic inflammation activated by pyroptosis. Also, pyroptosis inhibitor DSF or 2-DG were used to clarify the specific regulation of glycolysis upon pyroptosis in a hyperosmolar environment. In vivo, 2-DG and DSF were used for the treatment on DED mice to study the treatment efficacy, tear secretion were observed, and related changes of proteins were confirmed by western blot.

**Results:** It was observed that the expression of glycolysis and pyroptosis-related genes, PKM2, NLRP3, Caspase-1, Gasdermin D and IL-1 $\beta$  and the secretion of inflammatory cytokines in the tear were significantly increased compared with healthy control. In vitro, hyperosmolar environment could greatly induce HCECs' glycolytic reprogramming which could lead to subsequent pyroptotic inflammation in macrophages compared with the control group by increasing the gene and protein expression of PKM2, NLRP3, Caspase-1, Gasdermin D, and IL-1 $\beta$ , while 2-DG obviously inhibits glycolysis of HCECs and pyroptosis of macrophages. In vivo, 2-DG significantly improved tear secretion and reduced the cell death level in the corneal. After 2-DG treatment, Glycolysis and pyroptosis in the cornea were inhibited by reduced protein expression of PKM2, NLRP3, Caspase-1, Gasdermin D, and IL-1 $\beta$ .

**Conclusion:** Under hyperosmolar stress, glycolytic reprogramming played positive role in promoting DED aseptic inflammation by mediating pyroptosis.

FP-048

**Modified Deep Anterior Lamellar Keratoplasty (DALK) - a versatile technique for extreme corneal ectasias**A Heda, S Joshi<sup>1</sup>.<sup>1</sup>Cornea, H V Desai Eye Hospital, Pune, India

**Objective:** To report our experience of modification in the technique of Deep Anterior Lamellar Keratoplasty (DALK) , in terms of anatomical & visual outcome in advanced keratoconus, keratoglobus , Pellucid marginal degeneration (PMD) and variants of ectactic dystrophies

**Methods:** We present a retrospective case series of 8 patients , out of which , 4 were advanced Keratoconus with steep curvatures,1 PMD, 1 keratoglobus with irregular corneal surface, 1 keratoglobus with PMD. A Modified DALK , with central 7.0 mm big bubble DALK and peripheral lamellar keratoplasty was done in all these cases, with peripheral graft size ranging from 2 to 3.5 mm.

**Results:** Mean follow up duration ranged from 6.5 months to two years 7 months, with average 10.5 months , postoperatively. Preoperative Mean Central Keratometry (K) was 60.8 +/- 4.8D & K max 73.7 D+/-12.6 D which improved postoperatively to Central K 46.21+/-2.3 D & K max 52.6 D +/- 5.8 D. Preoperative average astigmatism of 9.4 +/- 6.4D improved to postop. 3.7D +/- 1.5 D. Preoperative Average best corrected visual acuity was 6/60 (range CF 3 meters to 6/24) which improved to BCVA of 6/12 (range from 6/18 to 6/9), except one patient of PMD who had dense amblyopia( due to myopia with chorioretinal atrophic patch at macula) . Intraoperatively, no patient had DM perforation . All corneal grafts had grade 4 clarity postoperatively & none of the patients had complications like double anterior chamber, rejection or postoperative glaucoma.

**Conclusion:** In our series, a conventional Penetrating Keratoplasty would have required large graft sizes, 9mm or more , with higher possibility of graft rejection. A standard DALK, either manual or big bubble may not have been possible due to very steep corneal curvatures, with possibilities of intraoperative DM perforation & conversion to Penetrating Keratoplasty (PK). This modified technique of central DALK & peripheral LK has shown good & consistent outcomes in our patients with very advanced cones with steep curvatures and those with variants like Keratoconus & PMD

FP-049

## Construction of A New Drug-loaded Glaucoma Drainage Valve Based on 4D Printing and Its Anti-scarring Effect after Operation

M Jiang<sup>1</sup>, Z Fu<sup>2</sup>, A Dong<sup>1</sup>, J Ma<sup>1</sup>, Y Han<sup>1</sup>, F Zhang<sup>2</sup>, H Yuan<sup>1</sup>.

<sup>1</sup>Department of Ophthalmology, The Second Affiliated Hospital of Harbin Medical University, <sup>2</sup>Centre for Composite Materials and Structures, Harbin Institute of Technology, Harbin, People's Republic of China

**Objective:** To solve the problem of scarring in the filtration area after AGV implantation, we constructed a novel glaucoma drainage valve based on 4D printing using F127DA micellar cross-linked double network loaded hydrogels as the substrate.

**Methods:** We synthesized double network hydrogels and performed material characterization. The drug release characteristics of hydrogel in vitro were detected by uv spectrophotometer. The safety of hydrogels was verified in vitro and in vivo. For in vivo studies, thirty New Zealand white rabbits were randomly divided into five groups (6 rabbits per group): Group A was implanted with AGV glaucoma drainage valve, Group B was implanted with AGV glaucoma drainage valve and infiltrated with 0.2 mg/ml concentration of MMC cotton for 1 minute intraoperatively, Group C was implanted with new glaucoma drainage valve (unloaded), Group D was implanted with new drug-loaded glaucoma drainage valve (drug-loaded without deformation), and Group E was implanted with new drug-loaded glaucoma drainage valve (drug-loaded + heat-driven deformation). Intraocular pressure was measured with a Tonopen tonometer after surgery, and AS-OCT was used to measure the thickness of the filtration wall in vivo at the fixed site. Masson staining was used to evaluate the collagen layer thickness of the follicles.

**Results:** Using double network hydrogels as substrate, a new glaucoma drainage plate was successfully constructed by 4D printing. Drug release could be achieved slowly with the gel loading, and the release peak was reached on the 5th day and continued for about 30 days. Accelerated drug release could be achieved under heat drive. The survival rate of fibroblasts formed by hydrogels was not significantly different from that of blank control group; The survival rate of cells in the drug-loading group was significantly lower than that in the blank control group; The hydrogels were degraded gradually within 3 months after implantation, and the histocompatibility was good. One month after operation, Masson staining showed the collagen thickness of upper and lower walls of follicles in groups C、 D and E was significantly lower than in groups A and B.

**Conclusion:** F127DA micellar cross-linked double network hydrogels can construct a novel drug-loaded glaucoma drainage valve. Controlled release of drugs can be achieved in vitro. It has no obvious toxicity to cells and can inhibit the proliferation of HTFs in vitro. After implantation, the scar reaction of filter bubbles can be alleviated.

FP-050

## Improving SD-OCT Artifact Rates with 3D Ganglion Cell Complex Volume Scans versus 2D Retinal Nerve Fiber Layer Thickness Scans

M Guzman Aparicio<sup>1,2</sup>, F Jassim<sup>1,2</sup>, A Verticchio Vercellin<sup>2,3</sup>, D Pavlenko<sup>1,2</sup>, H Lee<sup>4</sup>, E Tsikata<sup>1,2</sup>, E Park<sup>5</sup>, B Braaf<sup>6,7</sup>, B Vakoc<sup>6</sup>, B Bouma<sup>1,6,8,9</sup>, J de Boer<sup>1,0</sup>, T Chen<sup>1,2</sup>.

<sup>1</sup>Harvard Medical School, <sup>2</sup>Department of Ophthalmology, Glaucoma Service, Massachusetts Eye and Ear Infirmary, Boston, <sup>3</sup>Department of Ophthalmology, Icahn School of Medicine at Mount Sinai, New York, <sup>4</sup>Massachusetts General Hospital Biostatistics Center and Harvard Medical, <sup>5</sup>Boston University School of Medicine, <sup>6</sup>Massachusetts General Hospital, Wellman Center for Photomedicine, Boston, United States, <sup>7</sup>Heidelberg Engineering, Heidelberg, Germany, <sup>8</sup>Institute for Medical Engineering and Science, <sup>9</sup>Massachusetts Institute of Technology, Boston, United States, <sup>10</sup>LaserLaB Amsterdam, Department of Physics and Astronomy, Vrije Universiteit, and Department of Ophthalmology, Vrije Universiteit Medical Center, Amsterdam, Netherlands

**Objective:** To compare the rates of clinically significant artifacts for a novel three-dimensional (3D) ganglion cell complex (GCC) volume parameter versus the most commonly used spectral-domain optical coherence tomography (SD-OCT) glaucoma parameter (i.e. the gold standard two-dimensional (2D) retinal nerve fiber layer (RNFL) thickness parameter).

**Methods:** SD-OCT clinical RNFL thickness scans and research high-density macular volume scans were obtained (Spectralis, Heidelberg Engineering, Heidelberg, Germany). One eye per patient was used for analysis in 94 open angle glaucoma (OAG) and 56 normal patients. Artifact rates were calculated per B-scan and per eye. A clinically significant artifact is defined as one that requires a repeat scan or one that requires manual correction of segmentation errors to obtain an accurate measurement. For both 2D and 3D scans, segmentation errors were identified manually for all B-scans. For 3D scans, GCC thickness and volume were calculated, without manual correction of segmentation errors (i.e. pre-interpolation) and with manual correction (i.e. post-interpolation). Pre- and post- interpolation values were considered equivalent if they differed no more than normal test-retest variability ( $1.7 \times 10^{-2} \text{ mm}^3$ ). GCC volumes were calculated within a 3 to 4 mm diameter annulus.

**Results:** For all eyes (i.e. normal and OAG eyes), artifact rates per B-scan were 52.7% (79 of 150) for 2D RNFL thickness versus 16.9% (4054 of 23998) for 3D GCC volume scans ( $p$ -value  $< 0.001$ ). For 2D RNFL thickness scans, clinically significant artifacts were more common in OAG eyes compared to normal eyes (i.e. 74.5% versus 16.1%,  $p$ -value  $< 0.001$ ). In contrast, for 3D GCC volume scans, clinically significant artifact rates were similar for OAG and normal eyes (i.e. 6.4% and 10.7%,  $p$ -value 0.34). For OAG eyes, 2D RNFL thickness scans had significantly higher rates of clinically significant artifacts compared to 3D GCC volume scans (i.e. 74.5% versus 6.4%,  $p$ -value  $< 0.001$ ). For normal eyes, clinically significant artifact rates were similar (i.e. 16.1% RNFL versus 10.7% GCC,  $p$ -value 0.40).

**Conclusion:** Compared to the most commonly used 2D RNFL thickness scans, 3D GCC volume scans have fewer artifacts and less frequently require repeat scanning to obtain accurate measurements. For OAG patients, 3D volumetric scanning (6.4% artifact rate) was particularly advantageous compared to 2D RNFL thickness scans (74.5% artifact rate).



FP-051

### Lifetime Exposure of Ambient PM<sub>2.5</sub> Elevates Intraocular Pressure In Young Mice

L Li, J Zhou<sup>1</sup>, W Fan<sup>2</sup>, L Niu<sup>3</sup>, M Song<sup>3</sup>, B Qin<sup>3</sup>, X Sun<sup>3</sup>, Y Lei<sup>3</sup>.

<sup>1</sup>Shanghai Meteorological Bureau, Shanghai, <sup>2</sup>State Key Laboratory of Natural Medicines and Jiangsu Key Laboratory of Drug Discovery for Metabolic Diseases, Center of Advanced Pharmaceuticals and Biomaterials, Nanjing,

<sup>3</sup>Department of Ophthalmology & Visual Science, Eye & ENT Hospital, Shanghai Medical College, Fudan University, Shanghai, China, Shanghai, People's Republic of China

**Objective:** Epidemiological studies suggest that ambient particulate matter exposure may be a new risk factor of glaucoma, but it lacks experimental evidence to establish a causal relationship. This study aims to investigate if long-term PM<sub>2.5</sub> whole body exposure adversely affects intraocular pressure (IOP) and to elucidate the underlying mechanism.

**Methods:** Young mice (4 weeks old) were exposed concentrated ambient PM<sub>2.5</sub> (CAP) for 9 months, which is throughout most of the life span of a mouse under heavy pollution. CAP was introduced using a versatile aerosol concentration enrichment system which mimics natural PM<sub>2.5</sub> exposure. IOP and the aqueous humor outflow facility were measured. iNOS, 3-nitrotyrosine (3-NT) protein expressions of the conventional outflow tissue which regulates IOP were evaluated by western blot. Porcine aqueous angle plexus (AAP) cells were exposed to PM<sub>2.5</sub>. Cell viability, iNOS and 3-NT expression, and transepithelial electrical resistance (TEER) were measured. Peroxynitrite scavenger MnTMPyP were used to intervene PM<sub>2.5</sub> induced damages in vivo and in vitro.

**Results:** CAP exposure caused a gradual elevation of IOP and an increase in aqueous humor outflow resistance. In the conventional outflow tissues that regulates IOP, iNOS was up-regulated after PM<sub>2.5</sub> exposure. 3-NT formation was increased at 3 and 6 months, but downregulated at 9 months. In vitro experiments showed PM<sub>2.5</sub> exposure decreased cell viability and increased TEER by 34% in AAP cells, accompanied by an up-regulation of iNOS and 3-NT. MnTMPyP gradually lowered the IOP of mice exposed to PM<sub>2.5</sub> and reduced 3-NT formation in CAP mice at 16 weeks. Furthermore, MnTMPyP also prevented PM<sub>2.5</sub> induced 3-NT formation in AAP cells.

**Conclusion:** This study provides the novel evidence that in young mice, lifetime whole-body PM<sub>2.5</sub> exposure in young mice has a direct toxic effect on intraocular tissues, which imposes a significant risk of IOP elevation and may initiate the development of glaucoma and ocular hypertension. This occurs as a result of protein nitration of conventional aqueous humor outflow tissues.

FP-052

### 30-Month Outcomes of Kahook Dual Blade Goniotomy Combined with Cataract Surgery in Eyes with Medically Treated Glaucoma

M Cunha<sup>1</sup>, M Lemos<sup>1</sup>, L Ibrahim<sup>1</sup>, L Terenzi<sup>1</sup>, A Scoralick<sup>1</sup>, M Vianello<sup>1</sup>, F Kanadani<sup>1</sup>, T Prata<sup>1,2</sup>.

<sup>1</sup>Glaucoma Instituto, Belo Horizonte, São Paulo, <sup>2</sup>Glaucoma, The Federal University of São Paulo - UNIFESP, São Paulo, Brazil

**Objective:** To describe the 30-month efficacy and safety of goniotomy performed using the Kahook Dual Blade (KDB) in combination with cataract surgery in eyes with medically treated open-angle glaucoma (OAG).

**Methods:** This was a retrospective, non-comparative, interventional case series in which all patients with OAG who underwent phacoemulsification with KDB between June 2018 and April 2019 were enrolled. All the participants had a minimum follow-up of 30 months. Preoperative and postoperative intraocular pressure (IOP), number of glaucoma medications, surgical complications, and any subsequent related events or procedures were recorded. Success was defined as an IOP reduction of at least 20%, or a reduction of at least 1 glaucoma medication, compared to baseline.

**Results:** A total of 30 patients (30 eyes) were included (mean age, 65.8±9 years). After a mean follow-up of 35.5±4.2 months, mean IOP was reduced from 15.9±3.5 mmHg to 13.4±2.7 mmHg ( $p<0.01$ ). The mean number of glaucoma medications also decreased significantly from 2.2±0.8 to 1±0.9 at the last follow-up visit ( $p<0.01$ ). On the basis of the predefined criterion (IOP reduction  $\geq 20\%$  and/or reduction  $\geq 1$  medication), the 30-month success rate was 86%. Most common postoperative complication was transient hyphema (30%) and IOP spike  $>5$ mmHg (17%). No sight-threatening adverse event was documented.

**Conclusion:** Our mid to long-term findings suggest that phacoemulsification with Kahook Dual Blade goniotomy significantly reduces both IOP and dependence on IOP-lowering medications in eyes with OAG. Adverse events were not sight-threatening and typically resolved spontaneously.

FP-053

**Anti-PANoptosis is Involved in Neuroprotective Effects of Melatonin in Acute Ocular Hypertension Model**D Ye<sup>1</sup>, Y Xu<sup>1</sup>, J Huang<sup>1</sup>.

<sup>1</sup>State Key Laboratory of Ophthalmology, Zhongshan Ophthalmic Center, Sun Yat-sen University, Guangdong Provincial Key Laboratory of Ophthalmology and Visual Science, Guangzhou, People's Republic of China

**Objective:** Approved effective therapy is still lacking in acute glaucoma. PANoptosis, which is consist of three key modes of programmed cell death—apoptosis, necroptosis, and pyroptosis, may contribute to acute ocular hypertension (AOH)-induced retinal ganglion cell (RGC) death. Melatonin, a pineal hormone related to the circadian rhythm, exerts neuroprotective effects in many retinal degenerative diseases. This study aimed to explore the role of melatonin in PANoptosis after AOH injury, and its underlying mechanisms.

**Methods:** A murine AOH model was used in this study. Melatonin or the equal volume of saline containing 0.5% ethanol was administered by daily intraperitoneal injection to AOH mice. Hematoxylin & eosin staining, and optical coherence tomography were used to observe the changes of retinal structure. Electroretinogram was used to detect changes in visual function. TUNEL assay and PI assay were used to detect the apoptotic and necroptotic cells. Immunofluorescence and western blot were performed to evaluate the localization and quantitative changes of protein.

**Results:** Melatonin treatment attenuated the loss of retinal nerve fiber layer thickness, ganglion cell complex thickness (both  $p < 0.05$ ) and RGC ( $p < 0.001$ ). Meanwhile, melatonin improved the amplitudes of a-wave, b-wave, and oscillatory potentials in the electroretinogram ( $p < 0.0001, 0.01, 0.05$ , respectively). Additionally, the number of TUNEL-positive cells was decreased, and the upregulation of cleaved caspase-8, cleaved caspase-3, Bax, Bad and downregulation of Bcl-2, p-Bad were inhibited after melatonin administration ( $p < 0.05$ ). Moreover, melatonin attenuated high IOP-induced necroptosis in RGC and microglia, as demonstrated by both the expression and activation of MLKL, RIP1, and RIP3, along with the number of PI-positive cells were reduced in melatonin-treated mice ( $p < 0.05$ ), and p-RIP3 was in both RGC and microglia after AOH injury. Furthermore, melatonin reduced expression of NLRP3, ASC, cleaved caspase-1, GSDMD, and cleaved GSDMD, and decreased the number of Iba1/IL-1 $\beta$ -positive cells ( $p < 0.05$ ), which means melatonin attenuated high IOP-induced microglial pyroptosis and retinal inflammation.

**Conclusion:** Collectively, melatonin ameliorated retinal morphology and prevented retinal dysfunction after AOH and exerts neuroprotective effect via inhibition of PANoptosis in AOH retinas.

FP-054

## Interaction of background genetic risk, psychotropic medications, and primary angle closure glaucoma in the UK Biobank

S Sekimitsu<sup>1</sup>, J Wang<sup>2,3</sup>, T Elze<sup>4</sup>, A Segre<sup>2,3</sup>, J Wiggs<sup>2,3</sup>, N Zebardast<sup>5</sup>.

<sup>1</sup>Tufts University School of Medicine, <sup>2</sup>Massachusetts Eye and Ear, <sup>3</sup>Ocular Genomics Institute, <sup>4</sup>Schepens Eye Research Institute, <sup>5</sup>Harvard Medical School, Boston, United States

**Objective:** To understand the utility of a genome wide polygenic risk score (PRS) in identifying and risk stratifying subjects with primary angle closure glaucoma (PACG) and to investigate the association between PACG genetic burden and exposure to psychotropic medications on prevalent angle closure.

**Methods:** Data from the UK Biobank, a prospective cohort study of 502,506 UK residents aged 40-69, was used to construct a genome wide PACG PRS for participants. We used summary statistics from the largest multiethnic genome-wide association study meta-analysis to date (10,503 PACG cases and 29,567 controls). The Lassosum method, a regression-based model that shrinks variants via variable selection, was used to compute the PRS.

**Results:** Among the 441,054 participants included in this analysis, 959 (0.22%) were identified as PACG cases. Compared to controls, PACG subjects were older (61.2 vs. 56.5,  $p < 0.001$ ), more likely to be female (65.1% vs. 54.0%,  $p < 0.001$ ), and more likely to use psychotropic medications (18.0% vs. 11.7%,  $p < 0.001$ ). Individuals with PACG had significantly higher PRS compared to those without PACG ( $0.24 \pm 1.03$  vs.  $0.00 \pm 1.00$ ,  $p < 0.001$ ) and PACG prevalence increased with each decile of higher PRS. In a logistic regression model adjusting for age, gender, ancestry inferred from top principal components, and psychotropic medication use, a one-point increase in PRS was associated with 1.25 times higher odds of PACG ( $p < 0.001$ ). Among individuals using psychotropic medication, those with PACG had higher average PRS ( $0.31 \pm 1.00$  vs.  $0.00 \pm 1.00$ ,  $p < 0.001$ ) and were more likely to have a PRS in the upper deciles of polygenic risk ( $p = 0.04$ ). At each decile of PRS, the use of psychotropic medications was associated with increased risk of PACG. These effects were more pronounced and significant in higher PRS deciles.

**Conclusion:** Here we demonstrate the utility of a genome wide PRS for identifying individuals at higher risk of PACG. Additionally, we demonstrate an important gene-environmental interaction where higher PRS for PACG modulates the effect of psychotropic medications on PACG. Our results suggest that individuals who are on psychotropic medications and have high polygenic risk may need more careful monitoring and treatment for PACG than those with low polygenic risk, reinforcing the importance of genetic risk profiling in clinical medicine.

FP-055

## A short online course successfully trains non-ophthalmic graders to recognize glaucomatous optic nerves in low resource settings

O Olawoye<sup>1,2</sup>, P Ngoc<sup>3</sup>, H Thu Huong<sup>3</sup>, L Nguyen<sup>4</sup>, H Cherwek<sup>5</sup>, K Fowobaje<sup>6</sup>, R Craig<sup>7</sup>, M Coote<sup>8</sup>, V Chan<sup>1</sup>, T Peto<sup>1</sup>, A Azuara-Blanco<sup>1</sup>, N Congdon<sup>1</sup>.

<sup>1</sup>Centre for Public Health, Queens University Belfast, Belfast, United Kingdom, <sup>2</sup>Ophthalmology, University of Ibadan, Ibadan, Nigeria, <sup>3</sup>Orbis International, <sup>4</sup>Ophthalmology, Hanoi Medical University, Hanoi, Viet Nam, <sup>5</sup>Orbis International, New York, United States, <sup>6</sup>Department of Epidemiology and Medical Statistics, University of Ibadan, Ibadan, Nigeria, <sup>7</sup>Ophthalmology, <sup>8</sup>Centre for Eye Research, East Melbourne, Australia

### Objective:

Recent evidence (Tang J et al Lancet Glob Health 2019) suggests that glaucoma screening may be cost-effective in developing countries although it is generally not in high income countries. Screening of two major blinding eye diseases (glaucoma and diabetic retinopathy (DR) using the same resources is likely to further improve cost-effectiveness. The aim of this study was to test the efficacy of a one-week online course in training non-ophthalmic DR graders to recognize glaucomatous optic nerves in Vietnam.

**Main Research Question:** Can non-ophthalmic DR graders be trained inexpensively to accurately screen for glaucoma?

**Methods:** In this uncontrolled, interventional before-and-after study, 43 non-ophthalmic DR graders participating in an NGO program (primarily nurses and internists) took part in a self-taught, one-week online course on recognizing glaucomatous optic nerves. Their performance (% of images graded correctly as to 'refer/no refer and 'reason for referral' compared to a panel of glaucoma specialists) on a test set of optic nerve photos from the GONE website, population studies and patients taking part in the DR screening program was assessed before and after training, and was compared with 29 local, non-glaucoma-specialist ophthalmologists not taking the course.

**Intervention:** Self-paced participation in an online course describing various aspects of a glaucomatous optic nerve over one week.

**Results:** The mean  $\pm$  SD age of the non-ophthalmic graders was  $32.3 \pm 7.3$  years, with a mean  $\pm$  SD working experience of  $8.2 \pm 7.1$  years, compared to  $32.6 \pm 5.5$  and  $7.2 \pm 5.2$  years for ophthalmologists. Non-ophthalmic graders' test performance improved from a mean of  $33.3 \pm 14.3\%$  pre-training to  $55.8 \pm 12.6\%$  post-training ( $P < 0.0001$ ). Their post-test performance did not differ from that of ophthalmologists ( $58.7 \pm 15.4\%$ ,  $p = 0.384$ ). Results (significant improvement with training, no difference between post training graders and ophthalmologists) were consistent regardless of the origin of the optic nerve images (GONE website, population study, local images from the Vietnam program).

**Conclusion:** Non-ophthalmic graders could significantly improve their accuracy in detecting glaucoma after a brief online course, and had performance comparable to ophthalmologists. This model could contribute to low-cost glaucoma screening in underserved settings.

FP-056

## Comparison of Longitudinal Peripapillary Vessel Density Loss between Normal-Tension Glaucoma and Primary Angle-Closure Glaucoma

R Shen<sup>1</sup>, C Cheung<sup>1</sup>, C Tham<sup>1</sup>, P Chan<sup>1</sup>.

<sup>1</sup>Ophthalmology and Visual Sciences, The Chinese University of Hong Kong, Hong Kong, Hong Kong, China

**Objective:** To evaluate the pattern of longitudinal peripapillary vessel density (VD) loss and retinal nerve fiber layer (RNFL) thinning between normal-tension glaucoma (NTG) and primary angle-closure glaucoma (PACG).

**Methods:** This is a prospective, longitudinal observational study. All participants were followed up semi-annually. OCT-A image was obtained using swept-source optical coherence tomography angiography (OCT-A; DRI-OCT, Topcon, Japan). Quantitative peripapillary VD from OCT-A images was measured using a customized MATLAB program. Linear mixed-effects models were performed to estimate the rate of VD loss and RNFL thinning over time and to evaluate the baseline ocular factors associated with the rate of global VD loss.

**Results:** 75 eyes from 60 NTG patients and 75 eyes from 60 PACG patients with a follow-up duration of at least 12 months were included in the final analysis. NTG eyes and PACG eyes were followed up  $24.5 \pm 8.4$  months and  $23.5 \pm 9.2$  months respectively. Significant rates of VD loss in the global region and each sector were detectable in the NTG group ( $P \leq 0.05$ ), significant global VD and RNFL thinning were shown in PACG ( $P \leq 0.047$ ). NTG had faster rates of VD loss in the global region (mean difference,  $-1.08$  %/year; 95% CI,  $-1.90, -0.27$ ;  $P = 0.009$ ), temporal sector (mean difference,  $-1.57$  %/year; 95% CI,  $-2.91, -0.23$ ;  $P = 0.022$ ), and superotemporal sector (mean difference,  $-1.46$  %/year; 95% CI,  $-2.65, -0.26$ ;  $P = 0.017$ ). The rate of global VD loss was significantly associated with baseline visual field mean deviation (MD) and global VD measurement ( $P \leq 0.041$ ) in multivariable mixed-effect models.

**Conclusion:** NTG had a more evenly VD loss than PACG. NTG had faster rates of VD loss in the global region, temporal and superotemporal sectors. Baseline global VD measurement and severity of disease were independently associated with the rate of global VD loss.

FP-057

## Endogenous Dual Stimuli-activated NO Generation In the Conventional Outflow Pathway for Precision Glaucoma Therapy

Y Lei<sup>1</sup>, W Fan<sup>2</sup>, M Song<sup>1</sup>, L Li<sup>1</sup>, L Niu<sup>1</sup>, B Han<sup>1</sup>, X Sun<sup>1</sup>, Z Yang<sup>3</sup>, X Chen<sup>4</sup>.

<sup>1</sup>Department of Ophthalmology & Visual Science, Eye Institute, Eye & ENT Hospital, Shanghai Medical College, Fudan University, Shanghai 200031, China, Shanghai, <sup>2</sup>State Key Laboratory of Natural Medicines and Jiangsu Key Laboratory of Drug Discovery for Metabolic Diseases, Center of Advanced Pharmaceuticals and Biomaterials, Nanjing, <sup>3</sup>Fujian Cross Strait Institute of Flexible Electronics (Future Technologies), Fujian Normal University, Fuzhou, People's Republic of China, <sup>4</sup>Departments of Diagnostic Radiology, Surgery, Chemical and Biomolecular Engineering, Biomedical Engineering, Yong Loo Lin School of Medicine and Faculty of Engineering, National University of Singapore, Singapore, Singapore

**Objective:** Due to the inconvenient handling of gaseous nitric oxide (NO), a sustained-NO release nano carrier drug system is proposed to achieve the effect of long-term intraocular pressure reduction.

**Methods:** Hollow mesoporous organic silica (HOS) nanomaterials loaded with JS-K (JR) and L-arginine (LO) were designed and synthesized. The concentration of NO in vivo and in vitro was analyzed by Griess assay. Cytotoxicity, corneal penetration and phagocytosis was detected by CCK-8 and fluorescence microscope. Pharmacological experiment, cell contraction kit and transmembrane resistance instrument were used to evaluate the effect of reducing intraocular pressure in high intraocular pressure model mice, the contractility of HTM and transmembrane resistance of AAP cells.

**Results:** JR- LO@HOS can effectively release NO without affecting the activity of HCE, HTM and AAP cells. And mouse eyes administrated JR- LO@HOS were free from ocular surface irritation symptoms. JR- LO@HOS relaxed HTM cells and reduced the resistance of AAP cells. FITC-HOS can be engulfed and released by HTM and can penetrate the mouse cornea. JR- LO@HOS effectively reduced the intraocular pressure of CAV1 ko, NOS3 ko and WT mice, and the protein and gene expression of sGC increased significantly.

**Conclusion:** We have developed an endogenous double stimulation responsive NO nano therapeutic drug, which is also expected to establish a versatile, non-invasive, and efficacious treatment paradigm for precision glaucoma therapy.



FP-058

## Vitamin A alleviates retinal ganglion cell degeneration via the activation of RARb-ADAM10 axis in a chronic glaucoma mice model

T Ren<sup>1</sup>, D Lin<sup>1</sup>, R Pang<sup>1</sup>, N Wang<sup>1</sup>.

<sup>1</sup>Beijing Institute of Ophthalmology, Beijing Tongren Hospital, Beijing, People's Republic of China

**Objective:** We previously reported that patients with normal-tension glaucoma have lower serum Vitamin A (VitA) levels than healthy subjects. Additionally, emerging evidence has highlighted that VitA and its downstream regulator, retinoic acid receptor  $\beta$  (RARb), could ameliorate neurodegenerative conditions like Alzheimer's disease by activating disintegrin and metalloproteinase domain-containing protein 10 (ADAM10). This study investigated the potential neuroprotective role of VitA and RARb-ADAM10 axis in a hydrogel-induced chronic glaucoma model.

**Methods:** Adult C57BL/6J mice were pre-treated with either water or VitA derivatives for 4 weeks before the induction of IOP elevation by unilateral intracameral injection of an *in-situ* crosslinking hydrogel. Mice were then fed with VitA or water for another 28 days. Selective downregulation of RARb was achieved by injecting AAV2-shRNA-RARb intravitreally at baseline. IOP was measured with a rebound tonometer at baseline and three times a week after injection. Scotopic electroretinogram response (a- and b-waves) and the photopic negative response (PhNR) were assessed prior and post the IOP elevation after 28 days. Retinol levels (serum, retina, and optic nerve) were measured with LC-MS at baseline and day 28.

**Results:** Whereas the IOP elevations were comparable between the VitA and the control groups ( $19.7 \pm 0.5$  vs  $19.3 \pm 0.4$  mmHg,  $p > 0.05$ ), the RGC density was greater in the former than the latter ( $2586.3$  vs  $2281.4/\text{mm}^2$  at 4 weeks following IOP elevation,  $p < 0.01$ ,  $n = 8-10/\text{group}$ ). Improvement of RGCs function was also detected by ERG in the VitA group, with a greater restoration of the PhNR amplitudes (48.3%,  $p < 0.01$ ) than the control group after gel injection. The retinol levels in the optic nerve were significantly elevated in the hypertensive eyes of the VitA group than the control group ( $n = 6/\text{group}$ ,  $p < 0.001$ ). Mice underwent intravitreal injection of AAV2-shRNA-RARb showed a remarkable reduction of RARb and ADAM10 at the RGC level ( $n = 12$ ,  $p < 0.01$ ). The RGC survival was significantly lower in the hypertensive eyes with adjacent treatment (VitA with AAV2-shRNA-RARb) ( $2276.9/\text{mm}^2$ ) than the VitA group ( $2586.3/\text{mm}^2$ ) ( $p < 0.01$ ).

**Conclusion:** VitA supplementation restored retinol levels in RGCs *in vivo*, rescued RGC from degeneration, and improved the inner retinal function in eyes with chronic IOP elevation. The subsequent activation of the RARb-ADAM10 axis is pertinent for investigating novel neuroprotective and neuroregenerative therapeutics for glaucoma.

FP-059

## Evaluation of Genetic Markers of LOXL1 and CACNA1A and Their Association with Pseudoexfoliation Disease in Malays

M Mohamad Kamil<sup>1</sup>, A Ahmad Shukri<sup>2</sup>, L Ahmad Tajudin<sup>3</sup>.

<sup>1</sup>Ophthalmology Department, Faculty of Medicine and Health Sciences, Universiti Malaysia Sabah, Kota Kinabalu,

<sup>2</sup>Ophthalmology Department, Hospital Raja Perempuan Zainab II, Kota Bharu, <sup>3</sup>Department of Ophthalmology and Visual Sciences, School of Medical Sciences, Universiti Sains Malaysia, Kubang Kerian, Malaysia

**Objective:** To evaluate single nucleotide polymorphisms (SNPs) of LOXL1 and CACNA1A—rs3825942 and rs4926244, respectively—and their association with pseudoexfoliation syndrome (PEX) and pseudoexfoliation glaucoma (PEXG) in Malays.

**Methods:** A case control study was conducted involving Malays with PEX (50), PEXG (52), and controls (50). Venesection was performed and genomic DNA was extracted using a commercial DNA extraction kit. Primer optimization was conducted for rs3825942 and rs4926244. Polymerase chain reaction was performed, and the products were purified. A DNA sequencer was used to identify the polymorphisms. Pearson's chi-square and multiple logistic regression analysis were used to analyze the data.

**Results:** SNP of rs3825942G and rs4926244G were significantly associated with PEX, which increased risks 4.3-fold (95%CI: 1.33, 17.52,  $p=0.017$ ) and 2.6-fold (95%CI: 1.25, 5.37,  $p = 0.015$ ), respectively. There was a significant difference of rs3825942G between Malay patients with PEXG and controls ( $p < 0.001$ ), but no significant difference for rs4926244G ( $p = 0.243$ ).

**Conclusion:** This study suggests that rs3825942G of LOXL1 and rs4926244G of CACNA1A are potential genetic markers for PEX and PEXG susceptibility in Malays. Identification of these genetic markers could assist in the early detection of pseudoexfoliation disease amongst Malays in the future.

FP-060

**Targeting the AhR with ITE limit NF- $\kappa$ B dependent microglia inflammation and neurodegeneration in acute ocular hypertension injury**Y Yang, N Wang, L Huang, Y Liu, H Sun, W Guo.

**Objective:** Glaucoma is the major cause of irreversible blindness in the world. Current consensus has proposed immune and inflammatory factors as one of major contributors to the development of glaucoma, but still remains unclear. 2-(1'H-indole-3'-carbonyl)-thiazole-4-carboxylic acid methyl ester (ITE) is a potent endogenous ligand of aryl hydrocarbon receptor (AhR), which has been demonstrated to be associated with immune and inflammatory diseases. Here, we hypothesized that ITE may inhibit microglia inflammation and confer neuroprotective effects in mice with acute ocular hypertension (AOH).

**Methods:** ITE or vehicle was systemically applied to C57/BL6 mice with induction of AOH. Immunofluorescence staining of retinal flat mounts and sections were performed to detect RGC survival and retinal structure. Quantitative real-time PCR (qRT-PCR) and Western blots were used to analyze pro-inflammatory responses in mice retina. BV-2 microglia were treated with ITE followed by lipopolysaccharide (LPS) stimulation to detect inflammation and related pathways. AhR antagonist CH223191 was used to determine the AhR dependent role of ITE.

**Results:** The in vivo experiments revealed that ITE treatment alleviated RGC loss and reduced iNOS, IL-1 $\beta$ , IL6 and CCL2 levels in mice under AOH. Moreover, ITE limit the reduction of retinal thickness under AOH via activating AhR. The in vitro results showed that ITE potently diminished LPS-induced expression of iNOS, IL-1 $\beta$  and IL-6 in both mRNA and protein level in BV2 microglia. In addition, ITE reduced LPS-induced NF  $\kappa$  B signaling, which was also AhR dependent.

**Conclusion:** In summary, these findings suggest the critical role of AhR signaling in glaucomatous RGC injury and provide a potential avenue to glaucoma treatment by AhR agonists supplementation.

## FP-061

**Structure-function agreement in glaucoma progression: visual field testing, disc photography, RNFL and neuroretinal rim thickness**

D Manik<sup>1</sup>, K Ratanawongphaibul<sup>2,3,4</sup>, J Kim<sup>2,3</sup>, E Tsikata<sup>2,3</sup>, H Lee<sup>3,5</sup>, M Margeta<sup>2,3</sup>, C Ondeck<sup>2,3,6</sup>, J de Boer<sup>7,8</sup>, T Chen<sup>2,5</sup>.

<sup>1</sup>Boston University, <sup>2</sup>Department of Ophthalmology, Glaucoma Service, Massachusetts Eye and Ear, <sup>3</sup>Harvard Medical School, Boston, United States, <sup>4</sup>Department of Ophthalmology, King Chulangkorn Memorial Hospital, Bangkok, Thailand, <sup>5</sup>Massachusetts General Hospital Biostatistics Center, Department of Medicine, Massachusetts Eye and Ear, <sup>6</sup>Department of Ophthalmology, VA Boston Hospital, Boston, United States, <sup>7</sup>LaserLaB Amsterdam, Department of Physics and Astronomy, Vrije Universiteit, <sup>8</sup>Department of Ophthalmology, Vrije Universiteit Medical Center, Amsterdam, Netherlands

**Objective:** To evaluate the degree of agreement among different tests of glaucoma progression: disc photography (DP), visual field (VF) testing, 2D retinal nerve fiber layer (RNFL) thickness, and 3D OCT neuroretinal rim measurements (i.e., minimum distance band or MDB).

**Methods:** 125 open-angle glaucoma patients underwent yearly DP, VF testing, and spectral domain OCT imaging to measure RNFL thickness and MDB thickness. For each test, eyes were classified as non-progressors or progressors at each study visit. Agreement occurred if tests progressed at the same study visit. Agreement between all compared tests were calculated as percentages with kappa coefficient, and multiple logistic regression was used to define factors associated with disagreement among testing methods.

**Results:** The average follow up period was  $67 \pm 16.3$  months. Most cases (63.2% [79/125]) had glaucoma progression defined by only 1 or 2 tests at the same time, while only 7.2% (9/125) of cases had progression by all 4 tests at the same time. Progression by structural tests (i.e., DP, RNFL thickness, and MDB thickness) matched the functional test (i.e., VF testing) only 50.4% to 62.4% of the time ( $k = -0.010-0.189$ ). More advanced glaucoma and a smaller cup-to-disc ratio were associated with poorer agreement between tests ( $P < 0.033$ ).

**Conclusion:** In a clinical setting, glaucoma tests generally show only slight agreement. About half the time, tests of structure and function do not progress at the same time.

FP-062

### Bleb-less glaucoma surgery to activate uveolymphatic route of aqueous humor outflow in management of glaucoma in cataract patients

V Kumar.

**Objective:** To assess the safety and effectiveness of a two-stage modified deep sclerectomy (MDS) technique with suprachoroidal drainage of aqueous humor (AH) in management of open angle glaucoma (OAG) in cataract patients.

**Methods:** Thirty-six patients (average age  $-74.9 \pm 7.9$  yrs., 12 male and 24 females) having undergone a combined procedure for OAG and cataract were included in this study. First, cataract surgery by phacoemulsification with implantation of a foldable intraocular lens (IOL) was performed followed by creation of an intrascleral pool (ISP) ab externo for future AH accumulation. After dissecting superficial scleral flap, deep scleral layers were divided into three parts by two parallel to limbus incisions. In distal part, deep scleral layers were excised along with the external wall of Schlemm's canal. Next, the uvea under the remaining two parts was detached from the sclera to insert a collagen implant in the suprachoroidal space. The third proximal part was completely excised to expose uvea. A Nd:YAG laser trabeculotomy was made on postoperative days 7–10. Outcome measures were IOP change, use of hypotensive medication(s) and complications. An IOP decrease by  $\geq 20\%$  and IOP between 6 and 21 mmHg without medication was considered as a complete success.

**Results:** At 3(n=31), 6(n=29) and 12 months (n=20) baseline IOP decreased from  $27.3 \pm 7.7$ mmHg to  $14.3 \pm 5.4$ mmHg (95% confidence interval (CI) 12.4-16.3) ( $p=7.6E-09$ ),  $14.8 \pm 3.2$ mmHg (95% CI 13.6-16.0) ( $p=2.4E-10$ ) and  $15.4 \pm 5.3$ mmHg (12.9-17.8)( $p=6.0E-06$ ); hypotensive medication use reduced from  $2.7 \pm 1.0$  to  $0.6 \pm 1.1$ ,  $0.7 \pm 1.1$  and  $0.7 \pm 1$ ; complete success was achieved in 71%, 52% and 55% cases, partial - in 16%, 34% and 30% cases respectively. At 12 months 3 cases (15%) were levelled as failure. The failure was due to blockage of trabeculotomy opening by iris tissue. Intraoperative and postoperative complications were few and manageable. Postoperatively no bleb was formed in any of the cases. Instead, different patterns of transparent fluid filled lymphatic vessels were observed in the conjunctiva of more than 30% of cases. OCT of surgery and nearby sites revealed presence of lymphatic vessels with characteristic bicuspid valves in 55% cases indicating enhanced AH outflow after surgery through lymphatics.

**Conclusion:** The MDS with suprachoroidal drainage was safe and effective in decreasing IOP in glaucoma patients with cataract. The IOP decrease was by enhanced AH outflow through the uveolymphatic route.

FP-063

## Accurate External Localization of Schlemm's Canal and Relative Parameters Measurement in Patients with Primary Open-angle Glaucoma

J Peng, J Wang.

**Objective:** To locate Schlemm's canal precisely during external Schlemm's canal-related surgeries for POAG patients and measure relevant parameters so as to provide data reference for precise performing external Schlemm's canal-related surgeries.

**Methods:** A total of 40 eyes underwent external Schlemm's canal-related surgeries in our hospital from July 2020 to October 2021. According to different intraoperative measurement methods, the patients were divided into two groups, 20 eyes in each group. Base mark line (BML) was positioned between semitransparency and non-transparency area by outside transillumination, reflux blood band of Schlemm's canal (SC) was clearly observed and marked on deep scleral bed under surgical microscope by intraocular transillumination with optic fiber of endoscope. Exposing superior conjunctiva adhesion line (CAL) on the cornea and unroofing the out wall of SC completely. SC width (SW), anterior edge of SC (AE), posterior edge of SC (PE) and white to white (WTW) were also as the measurement indices. Surgical area was photographed and measured with measuring microscope in group A, for group B, parameters were measured with spring compact and marked on sterile drawings, and then measured with microscope. To measure the distances between marks and analyze correlations with axial length.

**Results:** SW was  $0.33 \pm 0.07$  mm in the group A,  $0.34 \pm 0.08$  mm in the group B, there was no statistical significant difference between two groups ( $P > 0.05$ ). The distance between BML and PE in the group A was  $0.36 \pm 0.11$  mm,  $0.41 \pm 0.14$  mm in the group B. There was no statistical significant difference between the two groups ( $P > 0.05$ ). The distance between the CAL and the AE in the group A was  $1.85 \pm 0.28$  mm,  $1.61 \pm 0.37$  mm in the group B. The distance between the BML and CAL was  $2.63 \pm 0.30$  mm in the group A,  $2.41 \pm 0.38$  mm in the group B. The data of group A were higher than that of group B, and the difference was statistically significant ( $P < 0.05$ ). WTW and the distance from BML to PE were positively correlated with axial length in both groups. There was a significant positive correlation between the distance from BML to PE and the distance from BML to CAL. ( $P < 0.05$ ).

**Conclusion:** Intraoperative intraocular illumination can display Schlemm's canal reflux blood band and can be precisely positioned external on deep scleral bed. The distance between BML and PE is positively correlated with axial length, the data obtained by both methods provide reference for external SC surgeries in POAG patients.

FP-064

**Omidenepag Isopropyl 0.002% Significantly Lowers IOP in Latanoprost Low/Non-Responders with POAG or OHT: Phase 3 SPECTRUM 5 study**E McLaurin<sup>1</sup>, M Tepedino<sup>2</sup>.<sup>1</sup>Total Eye Care, P.A., Memphis, TN, <sup>2</sup>Atrium Health Wake Forest Baptist, Winston-Salem, NC, United States

**Objective:** To evaluate the intraocular pressure (IOP) lowering effect of omidenepag isopropyl 0.002% (OMDI) in latanoprost low/non-responders with primary open-angle glaucoma (POAG) or ocular hypertension (OHT).

**Methods:** Phase 3, open-label, multicenter study (NCT03697811) in latanoprost low/non-responders with POAG or OHT. Following a washout period of up to 35 days, and an 8-week run-in period with latanoprost ophthalmic solution 0.005% once-daily, latanoprost non-/low responders (patients who did not achieve a  $\geq 15\%$  reduction in IOP from the end of the washout period to the end of the latanoprost run-in period) were treated open-label with OMDI once daily in the evening for 3 months. IOP was measured at three timepoints (08:00, 12:00, and 16:00) on scheduled visits at Week 2, Week 6, and Month 3. The primary efficacy endpoint was the change from baseline in mean diurnal IOP at Month 3.

**Results:** 107 subjects were enrolled, with a mean age of 63.1 years, and with POAG (70.1%; n=75) or OHT (29.9%; n=32) as a primary diagnosis of the study eye at baseline. Lens status was phakic in 87 (81.3%) and pseudophakic in 20 (18.7%) of the study eyes at baseline. Prior IOP-lowering medication use in study eyes was prostaglandins/prostaglandin analogs (63.6%; n=68), oral/topical carbonic anhydrase inhibitors (31.8%; n=34), beta-blockers (14.0%; n=15) and alpha agonists (4.7%; n=5); and with 15.0% (n=16) reported as having no prior IOP medication use. At baseline (the end of the latanoprost run-in period), mean (SD) IOP was 23.3 mmHg (2.1), and at Month 3 it was 20.5 mmHg (3.3). Respective mean (SD) change from baseline in IOP at Week 2, Week 6 and Month 3 was -2.9 mmHg (2.5), -2.9 mmHg (2.6), and -3.0 mmHg (2.9) and was statistically significant ( $p < 0.0001$ ) and clinically relevant at Month 3. No significant safety issues or serious adverse events (AEs) were reported during the OMDI treatment period. The most frequently reported AE in subjects who received OMDI during the study was conjunctival hyperemia (8.4%; n=9), which was mild in severity in all cases except for one moderately severe case. The other most frequent AEs were punctate keratitis (2.8%, n=3) and eye pain (1.9%, n=2).

**Conclusion:** The primary efficacy endpoint of the study, change from baseline in mean diurnal IOP at Month 3, was met. Treatment with OMDI once daily resulted in early onset IOP reduction at the first post-baseline visit (Week 2) and a continued, stable IOP-lowering effect throughout the study. There were no significant safety concerns.

FP-065

**Tafluprost promotes axon regeneration after optic nerve crush via the Zn<sup>2+</sup>/mTOR pathway**

W Siting, Z qi, W caiqing, T Jiahui, L zhe, L canying, L yiqing<sup>1</sup>.

<sup>1</sup>The State Key Laboratory of Ophthalmology, Zhongshan Ophthalmic Center, Sun Yat-sen University, Guangzhou, People's Republic of China

**Objective:** To investigate whether tafluprost, which is a prostaglandin F<sub>2</sub> (PGF<sub>2</sub>) analogue and a first-line medical treatment for patients with primary open angle glaucoma (POAG), could promote optic nerve regeneration in mice after optic nerve crush (ONC), and to find out the underlying molecular mechanism.

**Methods:** Multiple concentrations of tafluprost (1uM, 10uM and 100uM of which dissolved in 0.1% dimethylsulfoxide (DMSO)) or 0.1% DMSO was injected immediately into the vitreous of 8-10-week-old male C57BL/6J mice after ONC. At 7 and 14 days after ONC, the numbers of survival retinal ganglion cells (RGCs) were counted with co-stained by neuronal class  $\beta$  III tubulin (TUJ1) and RBPMS. Individual axons that regenerated to 0.05mm, 0.1mm and 0.2 mm were manually counted in the whole-mount optic nerve labeled by growth-associated protein-43 (GAP-43). The level of Zn<sup>2+</sup> in inner plexiform layer (IPL) of retina with or without tafluprost was stained by autometallography (AMG). Retinal sections were subjected to p-mTOR, p-Akt, p-S6 and 4EBP1 staining to detect protein activation.

**Results:** Tafluprost eliminated the AMG signal in the IPL when examined at 6h after ONC (P<0.05). Tafluprost significantly protects RGCs from apoptosis at both 7 and 14 days after ONC (P<0.01 and P<0.001 respectively). At 2 weeks post-injury, tafluprost promotes greater optic nerve axon regeneration with GAP-43 positive fiber at multiple sites distal to the lesion than the DMSO-treated group. The high-affinity, membrane-permeable Zn<sup>2+</sup> chelator TPEN (N,N,N',N'-tetrakis (2-pyridylmethyl) ethylenediamine) can reactive the mTOR signal pathway after ONC with the observation of elevated intensity of p-mTOR and p-S6 in the retina.

**Conclusion:** Our results suggest that tafluprost promoted axon regeneration via the regulation of Zn<sup>2+</sup>-mTOR pathway, and provide novel research directions for the mechanisms of glaucomatous optic nerve injury.



FP-066

## Melatonin Prevents Acute Ocular Hypertension-Induced Oxidative Stress, Senescence, and Inflammation in Anterior Segment of Mice

D Ye<sup>1</sup>, Y Xu<sup>1</sup>, J Huang<sup>1</sup>.

<sup>1</sup>State Key Laboratory of Ophthalmology, Zhongshan Ophthalmic Center, Sun Yat-sen University, Guangdong Provincial Key Laboratory of Ophthalmology and Visual Science, Guangzhou, People's Republic of China

**Objective:** The mechanisms underlying the causal link between acute ocular hypertension (AOH) and subsequent pathological changes of anterior segment in acute glaucoma remain unclear, preventing improvements in treatments. Our previous study has demonstrated that oxidative stress, senescence, and inflammation were involved in the anterior segment of acute glaucoma patients. Melatonin, a hormone mainly secreted by pineal gland, exerts antioxidative, anti-apoptotic, and anti-inflammatory effects in the eye. This study aimed to explore the role of melatonin in oxidative stress, senescence, and inflammation induced by AOH in anterior segment and its underlying mechanisms.

**Methods:** A murine AOH model was used in this study. Melatonin, or sirtuin 1 (SIRT1) inhibitor with melatonin was administered by daily intraperitoneal injection to AOH mice. Pathological changes of the anterior segment were recorded by a slit-lamp microscope. Hematoxylin & eosin staining, and optical coherence tomography (OCT) were used to observe the changes of anterior segment structure. Immunofluorescence and western blot were performed to evaluate the protein changes in anterior segment tissues.

**Results:** Corneal edema was observed immediately after AOH injury, melatonin treatment significantly ameliorated corneal edema at Day 3, as reflected by reducing the central corneal thickness measured by OCT ( $p < 0.01$ ). Iris became thin and stiff in shape at Day 7, and melatonin treatment greatly relieved the morphological changes of iris. SIRT1 expression was decreased in cornea, iris, ciliary body, and anterior lens capsule after AOH injury, and increased after melatonin treatment ( $p < 0.001$ ). Meanwhile, SIRT1 inhibitor could counteract the effects of melatonin. In addition, the number of positive cells of oxidative stress markers (8-OHdG,  $\gamma$ -H2AX), senescence markers (p16, p21, p53), and inflammation markers (Iba1, CD68) and related protein expression levels were dramatically increased in the anterior segment of AOH model, and the number of these positive cells and related protein expression levels were decreased after melatonin treatment ( $p < 0.05$ ). While inhibiting SIRT1 pathway could predominantly eliminate the effects of melatonin.

**Conclusion:** Collectively, melatonin ameliorated morphology of anterior segment and exerted anti-oxidative stress, anti-senescence, anti-inflammation effects via activation of SIRT1 pathway in anterior segment tissues of AOH.

FP-067

**Intravitreal dexamethasone versus bevacizumab in Aboriginal and Torres Strait Islander patients with Diabetic Macular Oedema***J Meyer, C Fry, A Turner, H Razavi.*

**Objective:** Frequent intravitreal anti-VEGF injections are impractical for many Aboriginal patients in Australia with diabetic macular oedema (DMO). The longer acting intravitreal dexamethasone implant (DEX-implant) is approved for DMO but has not been assessed in an Aboriginal population. We sought to assess the safety and efficacy of the DEX-implant in Aboriginal people with DMO. In doing so we sought to conduct the first ever ophthalmic clinical trial to recruit Aboriginal-only participants.

**Methods:** This was a prospective, multicentre, randomized, single-masked, non-inferiority clinical trial. Aboriginal adults from Western Australia with DMO were randomized to receive 3-monthly DEX-implant, or monthly intravitreal bevacizumab. The primary outcome was the change in best corrected visual acuity (BCVA) at 12 months.

**Results:** The final endpoint was analysed for 24 DEX-implant and 28 bevacizumab injection eyes. Mean BCVA improved by 4.0 letters (-0.08 LogMAR) in the DEX-implant group and worsened by 5.5 letters (0.11 LogMAR) in the bevacizumab group. Before adjusting for cataract surgery, the upper bound of the two-sided 90% CI for the DEX-implant was 3.5 letters (0.07 LogMAR), which met non-inferiority criteria. The BCVA of remote participants who received the DEX-implant improved by 5.5 letters (0.11 LogMAR), compared to an 18.5 letter (0.37 LogMAR) decline for bevacizumab ( $P=0.04$ ). The incidence of steroid-induced ocular hypertension for the DEX-implant was 33.3%.

**Conclusion:** Before adjusting for the effect of cataract surgery, the DEX-implant was non-inferior to bevacizumab for treating DMO in Aboriginal participants. In remote participants, the DEX-implant surpassed non-inferiority to achieve superior outcomes to bevacizumab. The incidence of steroid-induced hypertension was comparable to that reported in non-Aboriginal populations. We provide guidelines for the judicious use of DEX-implant among Aboriginal people, and a framework for performing ophthalmic clinical trials in Aboriginal communities.

FP-068

**Real World Outcomes: Reporting Clinical Results Online**

A Maheshwari<sup>1</sup>, A Malpani, A Tomar<sup>1</sup>, G Garg<sup>1</sup>, P Finger<sup>1</sup>.

<sup>1</sup>New York Eye Cancer Centre, New York, United States

**Objective:** Online reporting helps both patients and physicians by comparing results, thereby, improving health care standards. To provide real-world data on the world-wide-web for patient and doctor awareness.

**Methods:** From December'2017 to March'2022, patients with *choroidal melanoma (CM)*, *iridociliary melanoma (ICM)* and *ocular surface squamous carcinoma (OSSC)* had specific outcomes recorded at each return visit. Each result was anonymized, entered in an online portal and sent to a unique software program developed to create real-world-data i.e., numbers(count), most common(median) and averages(mean) for our eye cancer specialty center. Outcome measures were number of patients, mean vision, local tumor control, eye salvage, metastases and follow-up time.

**Results:** A HIPAA compliant, internet-based software program was developed and linked to public access web page, in order to collect and analyze near-real-time data pertaining to vision, life and follow-up time of eye cancer patients. During this period, CM tumor control was 99.7%, median vision 20/25(mean 20/63) and eye salvage was 96.5%. ICM tumor control was 99.1%, median vision 20/20(mean 20/25). OSSC tumor control was 98.4%, median vision 20/20(mean 20/32). Rates of primary enucleation were 3.5% for CM, 1.7% for ICM and 0% for OSSC. All patient results were updated by the ophthalmic oncology fellow at each patient visit so as to reflect near-real-time outcomes.

**Conclusion:** This software is available, and thus paves way for other specialists to post their clinical results online for patient and physician reference. Posting treatment results offers transparency, a measure used to improve clinical practice by monitoring the clinical care results.

FP-069

**Macular OCT angiography parameters predict kidney disease progression in type 2 diabetes: a prospective study**W Wang, W Huang.

**Objective:** To determine whether the distribution or geometry of retinal or choroidal microcirculation was related to renal function deterioration of type 2 diabetic patients at two-year follow-up.

**Methods:** This is a community-based prospective cohort of adult type 2 diabetic patients in Guangzhou, China. Baseline and 2-year follow-up of swept-source OCT angiography imaging measured the total or parafoveal parameters of retinal vessel density, retinal diameters, fractal dimension, and blood vessel tortuosity of the superficial or deep capillary plexus in the retina and the choroid. Participants were divided into two groups by the level of eGFR decline: progressors and non-progressors. Logistic regression was applied to analyze the association after adjusting for traditional risk factors.

**Results:** A total of 655 patients with a mean age of  $64.1 \pm 7.8$  years were included in the final analysis. 65.58% (n=383) of the non-progressors were female while 47.89% (n=34) of the progressors were female (P = 0.003). No differences were found over other parameters between the groups (P > 0.05) at baseline. For the OCT angiography parameters, the progressors group had lower vessel density and vessel diameter in all measured layers at baseline (all, p<0.05). To look into the subregion of macular vessel distribution, the progressors group have lower vessel density in all quadrants of deep capillary and choriocapillaris plexus (all, p<0.001), as well as smaller vessel diameter in all quadrants of deep capillary plexus (all, p<0.01). After adjustment for known diabetic kidney disease related risk factors, both decreased vessel density and vessel diameter in all layers were associated with renal function deterioration. The predictive discrimination for the model of traditional risk factors plus OCTA metrics was significantly improved compared to the published risk factors only model (AUCs from 0.605 to 0.761, p<0.001).

**Conclusion:** In our 2-year prospective study, OCT-A parameters of macular vessel density and vessel diameters were predictive metrics of diabetic kidney disease progression. And the independent association of classical risk factors had been proved.

FP-070

**Persistence of severe global inequalities in the burden of blindness and vision loss from 1990 to 2019: GBD 2019**

H Wang, Y Li<sup>1</sup>, N Congdon<sup>2</sup>, K Qiu<sup>1</sup>, M Zhang<sup>1</sup>.

<sup>1</sup>Joint Shantou International Eye Center of Shantou University and The Chinese University of Hong Kong, Shantou, People's Republic of China, <sup>2</sup>School of Medicine, Dentistry and Biomedical Sciences Centre for Public Health, Queen's University Belfast, Belfast, United Kingdom

**Objective:** To assess the global burden and economic inequalities in the distribution of blindness and vision loss between 1990 and 2019.

**Methods:** A secondary analysis of the Global Burden of Diseases, Injuries, and Risk Factors Study (GBD) 2019. Data for disability-adjusted life years (DALYs) due to blindness and vision loss were extracted from the GBD 2019. Data for gross domestic product per capita were extracted from the World Bank database. Slope index of inequality (SII) and concentration index were computed to assess absolute and relative cross-national health inequality, respectively.

**Results:** Countries with high, high-middle, middle, low-middle, and low socio-demographic index (SDI) had decline of age-standardized DALY rate of 4.3%, 5.2%, 16.0%, 21.4%, and 11.30% from 1990 to 2019, respectively. The poorest 50% of world citizens bore 59.0% and 66.2% of the burden of blindness and vision loss in 1990 and 2019, respectively. The absolute cross-national inequality (SII) fell from -303.5 (95% CI -370.8 to -236.2) in 1990 to -256.0 (95% CI -288.1 to -223.8) in 2019. The relative inequality (concentration index) for global blindness and vision loss remained essentially constant between 1991 (-0.197, 95% CI -0.234 to -0.160) and 2019 (-0.193, 95% CI -0.216 to -0.169).

**Conclusion:** Though countries with middle and low-middle SDI were the most successful in decreasing burden of blindness and vision loss, a high level of cross-national health inequality persisted over the past three decades. More attention must be paid to the elimination of avoidable blindness and vision loss in low- and middle-income countries.

**FP-071****Comprehensive and Gender Sensitive Eye Care Services Reduce the Avoidable Blindness among Women and Girls in Bangladesh**F Afrose.

**Objective:** To evaluate the impact of comprehensive and gender sensitive eye care services to reduce avoidable blindness due to cataract and other eye complications among women and girls in the mid-northern areas of Bangladesh

**Methods:** The evaluation was designed to gather information from various stakeholders and incorporate their perspectives with a purpose of getting a complete and accurate picture of the effectiveness, efficiency, and impact of the comprehensive and gender sensitive eye care project. Data was collected through Observational Field visits, Document review, Informal and Semi-structured Interviews with relevant stakeholders and Focus Group Discussion with the beneficiaries

**Results:** Evaluation finds that Cataract, refractive error and other eye disorders decreased in the target population, especially amongst women and girls through project interventions. In three years, 15k adults (52% women) were identified at risk of blindness through outreach camps. Among them 10k adults (52% women) underwent cataract surgery. In order to prevent blindness among children, around 36.5K children were screened and 2644 were prescribed with refractive glasses. Screening campaigns at schools were routinely carried out and 300 teachers were trained on vision screening. To ensure women's participation in eye health services, courtyard meetings were conducted at household level involving male members to aware them on the importance of eye care for women. Among other services, four vision centres and free eye camps in remote areas, free transport service for poor patients, accessibility at Base Hospital, dedicated admission counter for female, breast feeding corner and fast-track for pregnant, lactating, or elderly women and recruitment of female staff are mentionable. As a result, within three years, the female patient flow increased to 5.27% at the Base Hospital compared to baseline.

Number of workshops and training programmes were organized on 'Gender in Eye Health Care in Bangladesh' at local and national level with Govt. and Non-Govt. Institutions and Hospitals to sensitize them. Also, project implementing hospital was institutionally strengthened for providing quality eye care services to women and girls

**Conclusion:** The evaluation recommended that low vision services should be developed and scaled up for the mid-northern region as there is none available in the surrounding districts. Besides providing gender responsive services, project should give focus on delivering inclusive eye health services.

FP-072

**A Forgotten People: Glaucoma Awareness and Prevalence Amongst a North-eastern Nigerian Population****A Kalambe**<sup>1,2</sup>, **A abdullahi**<sup>3</sup>.<sup>1</sup>Dept of Ophthalmology, Asokoro District Hospital, <sup>2</sup>College of Health Sciences, Nile University of Nigeria, Abuja,<sup>3</sup>Dept. of ophthalmology, Federal Medical Center Nguru, Yobe state, Nigeria

**Objective:** The aim of this study was to determine the awareness and proportion of people with glaucoma in a four-day rural eye outreach programme

**Methods:** This was a cross-sectional study carried out at a cataract outreach programme. Data was collected by means of structured 2-part questionnaires from consenting participants, the first part collected data on the demographics of the participants while the second part comprised ophthalmological examination findings carried out by the ophthalmologists. Participants were grouped into those diagnosed with glaucoma and those considered to be glaucoma suspects based on the International Society of Geographical and Epidemiological Ophthalmology (ISGEO) definitions for glaucoma. The data was analysed using IBM SPSS STATISTICS software version 21, p-values of <0.05 was considered statistically significant.

**Results:** 364 participants were included in the study, 278 (76.4%) were evaluated for glaucoma. The participants ranged from age 18-90 years with a mean age of 55 ( $\pm$  15.9 SD), female participants were only marginally higher at 51.1% (186). The highest percentage of the participants were unskilled workers 187 (51.4%), and those with informal/Islamic education 112 (30.8%) and no education 140 (38.6%) at all were of a larger proportion. This study found that 90 (24.7%) of the participants had heard about glaucoma. Awareness was credited to friends and family by 41.4% of participants, to the hospitals by 32.2% and to health workers at health talks by 20.7%. Glaucoma was diagnosed in 28 (10.1%) of the study population while 111 (39.9%) were found to be glaucoma suspects, a combined prevalence being very high at 50% of the study population.

**Conclusion:** The state has only one resident ophthalmologist for a population of about 4 million. Glaucoma awareness and screening programmes could piggy-back on cataract screening and surgical outreach programmes that have proven to be very successful in these areas. Trained manpower, basic diagnostic equipment and management options suitable for low-resource setting need to be developed and adapted to suit the environment.

FP-073

**Post Hoc Analysis of Nascent Geographic Atrophy Progression in the GATHER1 Trial**

A Loewenstein<sup>1</sup>, S Patel<sup>2</sup>, J Nielsen<sup>3</sup>, J Hsu<sup>4</sup>.

<sup>1</sup>Division of Ophthalmology, Tel Aviv Medical Center, Tel Aviv, Israel, <sup>2</sup>West Texas Retina Consultants, Abilene, Texas, <sup>3</sup>Wolfe Eye Clinic, Des Moines, Iowa, <sup>4</sup>The Retina Service of Wills Eye Hospital, Mid Atlantic Retina at Wills Eye Hospital, Thomas Jefferson University, Philadelphia, Pennsylvania, United States

**Objective:** Avacincaptad pegol is a C5 inhibitor being investigated for the treatment of geographic atrophy (GA). Based on optical coherence tomography (OCT) changes that signify the evolution of the atrophic process, the atrophy can be subdivided as (1) complete retinal pigment epithelium (RPE) and outer retinal atrophy (cRORA), and (2) incomplete RPE and outer retinal atrophy (iRORA). This post hoc analysis was conducted to better understand the impact of avacincaptad pegol treatment on the progression of GA.

**Methods:** The GATHER1 study was a prospective, randomized, double-masked, Phase 2/3 trial that evaluated avacincaptad pegol compared with sham in 286 GA patients with disease inside and/or outside of the 1.5-mm diameter foveal area. A post hoc imaging analysis of GATHER1 OCT data was performed by a masked analysis evaluating regions of OCT volume scans >500  $\mu$ m from the border of GA lesion(s) at baseline and months 6, 12, and 18 for progression of iRORA to cRORA and drusen to iRORA and/or cRORA.

**Results:** In the original prespecified analysis, the least squares mean change from baseline to Month 18 in square-root GA lesion area was 0.599 mm in sham-treated (n=110) patients vs 0.430 mm in avacincaptad pegol 2 mg-treated (n=67) patients (28% reduction;  $P<.0014$ ). In the post hoc analysis, a smaller proportion of patients in the avacincaptad pegol 2-mg group (n=20) compared with the sham group (n=43) progressed from iRORA to cRORA (20% vs 42%, respectively) and from drusen to iRORA or cRORA (8% vs 27%, respectively) over 18 months. Additional analyses on predictors of early atrophy progression in patients with GA are being evaluated to determine features potentially associated with disease progression. Over 18 months, 63.6% of patients in the combined avacincaptad pegol groups and 40.9% of patients in the combined sham groups were reported to have at least one ocular TEAE in the study eye. The most frequently reported ocular adverse events with avacincaptad pegol were related to the injection procedure.

**Conclusion:** In this post hoc analysis of the GATHER1 trial, avacincaptad pegol 2 mg was associated with a greater numerical reduction compared with sham in the progression of iRORA to cRORA, and in the progression of drusen to iRORA or cRORA over 18 months.



FP-074

## Brolucizumab for Treatment of Diabetic Macular Edema (DME): 100-Week Results from the KESTREL and KITE Studies

A Chang<sup>1</sup>, C Wykoff<sup>2</sup>, J Garweg<sup>3,4</sup>, C Regillo<sup>5</sup>, E Souied<sup>6</sup>, S Wolf<sup>4</sup>, D Dhoot<sup>7</sup>, H Agostini<sup>8</sup>, A Laude<sup>9</sup>, L Kovacic<sup>10</sup>, L Wang<sup>10</sup>, Y Wang<sup>10</sup>, E Bouillaud<sup>10</sup>, D Brown<sup>2</sup>.

<sup>1</sup>Sydney Retina Clinic, Sydney Eye Hospital, Sydney University, NSW, Australia, <sup>2</sup>Retina Consultants of Texas, Houston, TX, United States, <sup>3</sup>Berner Augenklinik am Lindenhofspital and Swiss Eye Institute, Bern, Switzerland, University of Bern, <sup>4</sup>Department of Ophthalmology, Inselspital, Bern University Hospital, University of Bern, Bern, Switzerland, <sup>5</sup>Retina Service, Wills Eye Hospital, Thomas Jefferson University, Philadelphia, United States, <sup>6</sup>Department of Ophthalmology, Hopital Intercommunal de Creteil, Créteil, France, <sup>7</sup>California Retina Consultants, Santa Barbara, California, United States, <sup>8</sup>Department of Ophthalmology, Medical Faculty, University of Freiburg, Freiburg, Germany, <sup>9</sup>National Healthcare Group Eye Institute, Tan Tock Seng Hospital, Singapore, Singapore, <sup>10</sup>Novartis Pharma A.G., Basel, Switzerland

**Objective:** To present the 100-week results from the KESTREL and KITE studies that evaluated efficacy and safety of brolucizumab (BRO) versus aflibercept (AFL) in patients with DME.

**Methods:** KESTREL (NCT03481634) and KITE (NCT03481660) were two 100-week (W), double-masked, active-controlled, Phase 3 studies. In KESTREL, patient randomization was 1:1:1 to BRO 3mg, BRO 6mg or AFL 2mg; in KITE, randomization was 1:1 to BRO 6mg or AFL 2mg. The BRO arms received 5 loading doses every 6 weeks (q6w) followed by q12w dosing, with an option to adjust to q8w at predefined disease activity assessment visits. At W72 in KITE, based on the disease stability assessment by the masked investigator, there was an option to extend the treatment interval for BRO patients by 4 weeks i.e. from q12w to q16w or q8w to q12w. The AFL arms received 5 monthly loading doses followed by fixed q8w dosing until end of study.

**Results:** In both studies, BRO 6mg was non-inferior to AFL for the change in BCVA at W52 (primary endpoint) and the VA gains were maintained to W100 (change in BCVA (letters) from baseline: BRO 6mg +8.8 vs AFL+10.6, difference -1.7 [95% CI, -3.8, 0.4] in KESTREL; BRO 6mg +10.9 vs AFL +8.4, difference +2.6 [95% CI, 0.2, 4.9] in KITE). The change in central subfield thickness (CSFT) from baseline over the period W88 through W100 in BRO 6mg and AFL arms were -171.9µm vs -168.5µm in KESTREL; -196.6µm vs -173.4µm in KITE. Fewer BRO 6mg patients had IRF and/or SRF vs AFL at W100 (KESTREL, 41.8% vs 54.0%; KITE, 40.8% vs 56.9%). Of the BRO 6mg

patients who successfully completed the first q12w cycle immediately after the loading phase, 70.2% remained on q12w interval in KESTREL and 69.6% on q12w/q16w interval in KITE up to W100. In KESTREL, intraocular inflammation (IOI) rates were 5.3%, 4.2% and 1.1% in BRO 3mg, BRO 6mg and AFL, respectively; incidence of retinal vascular occlusion (RO) and retinal vasculitis (RV) were 1.6% and 1.6% in BRO 3mg, 1.6% and 0.5% in BRO 6mg and, 0.5% and 0% in AFL arms, respectively. No new RV reported in Year 2 in KESTREL. In KITE, IOI rates were 2.2% in BRO 6mg vs 1.7% AFL; incidence of RO was 0.6% in both BRO 6mg and AFL arms; there were no cases of RV through W100.

**Conclusion:** The 100-week results from KESTREL and KITE reaffirm the efficacy of brolocizumab for the treatment of DME seen in the Year 1 data. The overall safety profile of BRO 6mg remained unchanged through Year 2.

FP-075

## Personalised Treatment Interval (PTI) Dosing Dynamics in the Phase 3 YOSEMITE/RHINE Trials of Faricimab in Diabetic Macular Edema

C Tan<sup>1</sup>, G Jaffe<sup>2</sup>, B Gerendas<sup>3</sup>, U Chakravarthy<sup>4</sup>, R Goldberg<sup>5</sup>, J Korobelnik<sup>6</sup>, F Abreu<sup>7</sup>, N Jain<sup>8</sup>, Y Tang<sup>7</sup>, A Camino<sup>7</sup>, Z Haskova<sup>7</sup>.

<sup>1</sup>Tan Tock Seng Hospital, Novena, Singapore, <sup>2</sup>Duke Reading Center, Duke University, Durham, NC, United States, <sup>3</sup>Vienna Reading Center, Medical University of Vienna, Vienna, Austria, <sup>4</sup>Queen's University of Belfast, Royal Victoria Hospital, Belfast, United Kingdom, <sup>5</sup>Bay Area Retina Associates, Walnut Creek, CA, United States, <sup>6</sup>Centre Hospitalier Universitaire de Bordeaux, Bordeaux, France, <sup>7</sup>Genentech, Inc., South San Francisco, CA, United States, <sup>8</sup>Roche Products Ltd., Welwyn Garden City, United Kingdom

**Objective:** Dual inhibition of the angiotensin-2 and vascular endothelial growth factor (VEGF)-A pathways with faricimab may extend treatment durability beyond current anti-VEGF therapies for diabetic macular edema (DME). In the phase 3 YOSEMITE/RHINE trials, treat-and-extend-based personalised treatment interval (PTI) dosing up to every 16 weeks (Q16W) aimed to demonstrate the durability of faricimab, and its potential to reduce treatment burden for patients with DME while maintaining optimal efficacy.

**Methods:** YOSEMITE (NCT03622580) and RHINE (NCT03622593) were randomised, double-masked, active comparator-controlled, phase 3 trials of faricimab in DME. Patients were randomised 1:1:1 to faricimab 6.0 mg per PTI up to Q16W after a minimum of 4 initial Q4W doses, faricimab 6.0 mg Q8W after 6 initial Q4W doses or aflibercept 2.0 mg Q8W after 5 initial Q4W doses. In the PTI arms, patients received faricimab Q4W until central subfield thickness (CST) < 325 µm was achieved at or after week 12. Once achieved, treatment intervals could be extended by 4 weeks (up to Q16W), maintained or reduced by 4 or 8 weeks (as low as Q4W) based on pre-specified CST and best-corrected visual acuity criteria at active dosing visits. Treatment intervals in the faricimab PTI arms were assessed through week 96.

**Results:** Of the 1891 patients enrolled in YOSEMITE (N = 940) and RHINE (N = 951), 313 and 319 patients, respectively, were randomised to the faricimab PTI arms. At week 52, 52% of patients in the faricimab PTI arms achieved Q16W dosing and 72% achieved ≥ Q12W dosing. The durability of faricimab was further extended in year 2, with 62% of patients on Q16W dosing and 78% on ≥ Q12W dosing at week 96. The majority of patients who achieved ≥ Q12W dosing at week 52 (79%) subsequently maintained ≥ Q12W dosing without an interval reduction below Q12W through week 96, and most patients who achieved Q16W dosing at week 52 (76%) maintained this treatment interval through week 96. Less than 5% of patients in the faricimab PTI arms extended to Q8W dosing and then remained on ≤ Q8W dosing through week 96, and < 4% of patients could not be extended beyond Q4W dosing throughout the 2-year studies. Faricimab PTI dosing dynamics through week 96 and illustrative case studies will be presented at the meeting.

**Conclusion:** Treat-and-extend-based PTI dosing in the phase 3 YOSEMITE/RHINE trials supports the extended durability of dual angiopoietin-2/VEGF-A inhibition with faricimab in patients with DME.

FP-076

## Faricimab in Neovascular Age-Related Macular Degeneration: Year 2 Results From the Phase 3 TENAYA and LUCERNE Trials

D Hwang<sup>1,2</sup>, F Holz<sup>3</sup>, A Khanani<sup>4</sup>, R Singh<sup>5</sup>, A Demetriades<sup>6</sup>, D Silverman<sup>7</sup>, B Swaminathan<sup>8</sup>, V Patel<sup>7</sup>, H Lin<sup>6</sup>, J Willis<sup>6</sup>, A Kotecha<sup>7</sup>.

<sup>1</sup>Taipei Veterans General Hospital, <sup>2</sup>National Yang Ming Chiao Tung University, Taipei City, Taiwan, China,

<sup>3</sup>Department of Ophthalmology and GRADE Reading Center, University of Bonn, Bonn, Germany, <sup>4</sup>Sierra Eye

Associates, Reno, NV, <sup>5</sup>Cleveland Clinic Florida, Stuart, FL, <sup>6</sup>Genentech, Inc., South San Francisco, CA, United States,

<sup>7</sup>Roche Products Ltd., Welwyn Garden City, United Kingdom, <sup>8</sup>F. Hoffmann-La Roche Ltd., Mississauga, Canada

**Objective:** Year 1 data from the phase 3 TENAYA/LUCERNE trials support the hypothesis that dual inhibition of the angiotensin-2 and vascular endothelial growth factor (VEGF)-A pathways with faricimab, the first bispecific antibody designed for intraocular use, may promote vascular stability and durable efficacy beyond current anti-VEGF therapies for neovascular age-related macular degeneration (nAMD). Year 2 of TENAYA/LUCERNE will inform the longer-term efficacy, durability and safety of faricimab up to every 16 weeks (Q16W) compared with aflibercept Q8W in patients with nAMD.

**Methods:** TENAYA (NCT03823287) and LUCERNE (NCT03823300) were identical, global, randomised, double-masked, active comparator-controlled, 112-week, phase 3 trials of faricimab in patients with nAMD. Treatment-naïve patients (N = 1329) were randomised 1:1 to receive faricimab 6.0 mg up to Q16W (n = 665) based on protocol-defined disease activity assessments at weeks 20 and 24 after 4 initial Q4W doses, or aflibercept 2.0 mg Q8W (n = 664) after 3 initial Q4W doses. From week 60, faricimab-treated patients followed a treat-and-extend-based personalised treatment interval (PTI) regimen, with dosing intervals extended by 4 weeks (to a maximum of Q16W), maintained or reduced by 4 or 8 weeks (to a minimum of Q8W), based on central subfield thickness (CST), best-corrected visual acuity (BCVA) and presence or absence of new macular haemorrhage at active dosing visits. Aflibercept-treated patients continued fixed Q8W dosing through week 108. The primary efficacy endpoint was mean change in BCVA from baseline at 1 year, averaged over weeks 40, 44 and 48. Other efficacy and safety endpoints were assessed through week 112.

**Results:** In both trials, faricimab up to Q16W offered durable vision gains that were non-inferior to aflibercept Q8W at weeks 40–48, with 78.7% of patients on ≥ Q12W dosing intervals and ~45.3% on Q16W dosing intervals at week 48. Even with reduced injection frequency, mean reductions in CST were comparable between treatment arms. Faricimab up to Q16W was well tolerated, with low rates of intraocular inflammation. Selected key year 2 outcomes will be presented at the meeting, including mean changes in BCVA and CST from baseline, treatment interval distribution and safety.

**Conclusion:** Year 2 results from the TENAYA/LUCERNE trials will explore whether early vision gains, reductions in CST and extended (up to Q16W) dosing with faricimab are maintained over 2 years in patients with nAMD.

FP-077

## VOYAGER: An Innovative Real-world Study of the Port Delivery System With Ranibizumab and Faricimab in Patients With nAMD and DME

A Koh<sup>1</sup>, C Bailey<sup>234</sup>, M Bengus<sup>5</sup>, V Chaikitmongkol<sup>6</sup>, U Chakravarthy<sup>78</sup>, V Chaudhary<sup>910</sup>, G Chi<sup>11</sup>, R Finger<sup>12</sup>, R Gallego-Pinazo<sup>13</sup>, C Glittenberg<sup>5</sup>, M Lövestam-Adrian<sup>1415</sup>, M Parravano<sup>16</sup>, J Luna Pinto<sup>17</sup>, S Scheidl<sup>5</sup>, M Schmitz-Valckenberg<sup>121819</sup>, V Sheth<sup>20</sup>, E Souied<sup>21</sup>, R Guymer<sup>2223</sup>.

<sup>1</sup>Eye & Retina Surgeons, Camden Medical Centre, Singapore, Singapore, <sup>2</sup>Bristol Eye Hospital, <sup>3</sup>University Hospitals Bristol, <sup>4</sup>NHS Foundation Trust, Bristol, United Kingdom, <sup>5</sup>F. Hoffmann-La Roche Ltd., Basel, Switzerland, <sup>6</sup>Retina Division, Department of Ophthalmology, Faculty of Medicine, Chiang Mai University, Chiang Mai, Thailand, <sup>7</sup>Queen's University of Belfast, <sup>8</sup>Royal Victoria Hospital, Belfast, United Kingdom, <sup>9</sup>Department of Surgery, Hamilton Regional Eye Institute, <sup>10</sup>McMaster University, Hamilton, Canada, <sup>11</sup>Genentech, Inc., South San Francisco, United States, <sup>12</sup>Department of Ophthalmology, University of Bonn, Bonn, Germany, <sup>13</sup>Unit of Macula and Clinical Trials, Oftalvist Clinic, Valencia, Spain, <sup>14</sup>Department of Ophthalmology, Lund University, <sup>15</sup>Department of Clinical Sciences, Skane University Hospital, Lund, Sweden, <sup>16</sup>IRCCS-Fondazione Bietti, Rome, Italy, <sup>17</sup>Centro Privado de Ojos Romagosa-Fundacion VER, Córdoba, Argentina, <sup>18</sup>Department of Ophthalmology & Visual Sciences, John A. Moran Eye Center, Salt Lake City, <sup>19</sup>University of Utah, Salt Lake City, <sup>20</sup>University of Illinois, Chicago, United States, <sup>21</sup>Department of Ophthalmology, Centre Hospitalier Intercommunal de Créteil, Créteil, France, <sup>22</sup>Center for Eye Research Australia, Royal Victorian Eye and Ear Hospital, <sup>23</sup>University of Melbourne, Melbourne, Australia

**Objective:** To gather real-world insights into long-term functional and anatomic outcomes, safety, treatment patterns and drivers of treatment decisions among patients receiving Susvimo (Port Delivery System with ranibizumab) or Vabysmo (faricimab) for neovascular age-related macular degeneration (nAMD) and diabetic macular edema (DME) in routine clinical practice globally.

**Methods:** At least 5000 adult patients receiving Susvimo or Vabysmo for their approved indication(s) in routine local clinical practice (~500 sites and 31 countries) will be observed for ≤ 5 years. Variables to be collected include visual acuity (VA), clinician treatment patterns and management, imaging assessments and management decisions (interpretation of disease activity and treatment intentions), and safety events. Optical coherence tomography (OCT; spectral-domain OCT or swept-source OCT) and other images will be captured during routine care to evaluate retinal fluid and anatomic biomarkers impacting VA.

**Results:** The primary outcome is change in VA from baseline at month 12 per eye, by indication and per product. Key secondary objectives (by indication and per product) include real-world treatment regimens, treatment patterns and tolerance to fluid; and to evaluate correlations between these clinical practice patterns and change in VA over time. Safety outcomes will include the incidence, severity, duration and outcome of ocular and non-ocular adverse events. Other objectives will be to evaluate the effectiveness of Susvimo or Vabysmo on central subfield thickness reduction

and to evaluate nAMD- and DME-specific disease features (eg, disease activity, presence and location of atrophy and fibrosis in nAMD, diabetic retinopathy severity level in DME).

**Conclusion:** By collecting real-world long-term clinical data and images, clinician treatment patterns and key anatomic features impacting VA in patients treated with Susvimo or Vabysmo for their approved indication(s), VOYAGER will generate insights into treatment patterns and factors driving patient treatment decisions worldwide, real-world effectiveness and safety outcomes. A digital investigator interface will provide graphical visualisation of key parameters to display the patient's treatment journey in real time. In addition, retinal images will be collected and further evaluated using advanced analytic tools. These data will evaluate the impact of clinical practice patterns and key anatomic features on VA outcomes with Susvimo or Vabysmo.



FP-078

**ADVM-022 Intravitreal Gene Therapy For Neovascular AMD: Phase 1 OPTIC Trial Update**A M Khanani<sup>1</sup>, J Han<sup>2</sup>, A Turpcu<sup>3</sup>.<sup>1</sup>Sierra Eye Associates, Reno, Nevada, <sup>2</sup>Adverum Biotechnologies, Redwood City, California, <sup>3</sup>Adverum Biotechnologies, Redwood City, California, United States**Objective:**

OPTIC is an ongoing phase 1 study assessing safety, tolerability and efficacy of ADVM-022 (AAV.7m8-aflibercept) in treatment-experienced nAMD patients.

A single-injection intravitreal (IVT) gene therapy that durably expresses intraocular anti-vascular endothelial growth factor (VEGF) could reduce the burden of repeated anti-VEGF injections and optimize long term anatomical and visual outcomes in nAMD. OPTIC is an ongoing phase 1 study assessing safety, tolerability and efficacy of ADVM-022 (AAV.7m8-aflibercept) in treatment-experienced nAMD patients.

**Methods:** Multicenter, open-label, multiple cohort, dose-ranging, 104 week study in patients with nAMD with a demonstrated response to anti-VEGF therapy. Patients were administered a single IVT injection of ADVM-022 at 6E11 vg/eye for Cohort (C) 1 (n=6) and C4 (n=9) and at 2E11 vg/eye for C2 (n=6) and C3 (n=9). Incidence and severity of adverse events, change in best corrected visual acuity (BCVA), change in central subfield thickness (CST) and number of and need for aflibercept rescue injections were evaluated.

**Results:** As of July 16, 2021, median follow-up was 104 weeks (C1&C2), 88 weeks (C3) and 56 weeks (C4). Patients received a mean of 6.6–9.2 anti-VEGF injections 12 months prior to ADVM-022; mean baseline BCVA was 64.7–65.9 ETDRS letters. ADVM-022-related ocular adverse events were mild (83%) to moderate (17%). Ocular inflammation was minimal at 2E11 vg/eye and responsive to steroid eye drops. There were no cases of retinitis, vasculitis or clinically relevant intraocular pressure decreases. BCVA was maintained (mean change -2.8 to +2.6 ETDRS letters) and CST improved (mean change of -8.7 to -142.3  $\mu$ m). Both doses showed robust, sustained aflibercept expression. Mean annualized anti-VEGF injection frequency was reduced by 97% and 83% after 6E11 and 2E11 vg/eye ADVM-022 respectively. In patients with baseline neutralizing antibodies (NAbs) titre to AAV.7m8 <1:125, annualized injection frequency was reduced by 97% (6E11) and 93% (2E11) and CST fluctuations were reduced by 85% (6E11) and 76% (2E11).

**Conclusion:** In treatment experienced nAMD patients, ADVM-022 reduces treatment burden, maintains visual and anatomical outcomes and minimizes CST fluctuations relative to standard of care bolus anti-VEGF therapy. Further investigation of the 2E11 vg/eye and lower doses are warranted in larger studies.

FP-079

## Efficacy, Durability and Safety of Faricimab in Diabetic Macular Edema: 2-Year Results From the Phase 3 YOSEMITE and RHINE Trials

T Murata<sup>1</sup>, J Wells<sup>2,3</sup>, C Bauma<sup>4</sup>, C Danzig<sup>5,6</sup>, P Schlottmann<sup>7</sup>, H Lin<sup>8</sup>, S Mohan<sup>8</sup>, D Silverman<sup>9</sup>, Y Tang<sup>8</sup>, Z Haskova<sup>8</sup>.

<sup>1</sup>Department of Ophthalmology, Shinshu University School of Medicine, Matsumoto, Japan, <sup>2</sup>Palmetto Retina Center,

<sup>3</sup>Retina Consultants of America, Columbia, <sup>4</sup>Tufts Medical Center, Boston, <sup>5</sup>Rand Eye Institute, Deerfield Beach,

<sup>6</sup>Charles E. Schmidt College of Medicine, Florida Atlantic University, Boca Raton, United States, <sup>7</sup>Organización

Médica de Investigación, Buenos Aires, Argentina, <sup>8</sup>Genentech, Inc., South San Francisco, United States, <sup>9</sup>Roche

Products Ltd., Welwyn Garden City, United Kingdom

**Objective:** Year 1 data from the phase 3 YOSEMITE/RHINE trials suggest that dual angiopoietin-2/VEGF-A blockade with faricimab may promote vascular stability in diabetic macular edema (DME) and lead to extended durability with up to every-16-week (Q16W) dosing. Year 2 of YOSEMITE/RHINE evaluated the longer-term efficacy, durability and safety of faricimab.

**Methods:** YOSEMITE/RHINE (NCT03622580/NCT03622593) were randomised, active comparator-controlled trials of faricimab in patients with centre-involving DME. Patients were randomised 1:1:1 to faricimab 6.0 mg Q8W after 6 initial Q4W doses, faricimab 6.0 mg per treat-and-extend-based personalised treatment interval (PTI) after 4 initial Q4W doses or aflibercept 2.0 mg Q8W after 5 initial Q4W doses. The faricimab PTI arms followed a treat-and-extend-based regimen, with dosing intervals adjusted (from Q4W up to Q16W), based on central subfield thickness (CST) and best-corrected visual acuity (BCVA) change from reference values at active dosing visits. The primary efficacy endpoint was mean BCVA change from baseline at 1 year, averaged over weeks 48, 52 and 56. Other efficacy and safety endpoints were assessed through week 100.

**Results:** In total, 1891 patients were enrolled in YOSEMITE (N = 940) and RHINE (N = 951). Non-inferior vision gains achieved at 1 year were maintained through year 2; mean BCVA change from baseline at 2 years (averaged over weeks 92, 96 and 100) with faricimab Q8W (YOSEMITE/RHINE, +10.7/+10.9 letters) or PTI (+10.7/+10.1 letters) were comparable with aflibercept Q8W (+11.4/+9.4 letters). In the faricimab treat-and-extend PTI arms, durable vision gains were maintained with extended dosing, with > 60% of patients on Q16W interval and almost 80% on ≥ Q12W at week 96. Mean CST reductions favoured faricimab over aflibercept at 1 year and were maintained through year 2. More patients achieved absence of DME (CST < 325 µm) and absence of intraretinal fluid with faricimab Q8W or PTI versus aflibercept Q8W through week 100. Faricimab was well tolerated through study end; intraocular inflammation event rates were low. No cases of retinal vasculitis or occlusive retinal vasculitis were reported.

**Conclusion:** Robust vision gains, anatomic improvements and extended durability with faricimab up to Q16W were maintained through year 2 in YOSEMITE/RHINE. Treat-and-extend-based PTI dosing suggests that dual angiopoietin-2/VEGF-A inhibition with faricimab may promote vascular stability and durable efficacy beyond current anti-VEGF therapies for DME.

FP-080

## Faricimab in Neovascular Age-Related Macular Degeneration: Efficacy, Safety, and Durability Through Week 48 in TENAYA and LUCERNE

R Guymer<sup>1,2,3</sup>, G Cheung<sup>4,5,6,7</sup>, P Margaron<sup>8</sup>, C Quezada Ruiz<sup>9</sup>, D Silverman<sup>8</sup>, J Ives<sup>8</sup>, K Basu<sup>10</sup>, A Souverain<sup>11</sup>, M Yang<sup>9</sup>, H Lin<sup>9</sup>, J Willis<sup>9</sup>, A Kotecha<sup>8</sup>.

<sup>1</sup>Centre for Eye Research Australia, <sup>2</sup>Royal Victorian Eye and Ear Hospital, <sup>3</sup>University of Melbourne, Melbourne, Australia, <sup>4</sup>Singapore Eye Research Institute, <sup>5</sup>National Eye Centre, <sup>6</sup>Duke-NUS Medical School, <sup>7</sup>National University of Singapore, Singapore, Singapore, <sup>8</sup>Roche Products Ltd., Welwyn Garden City, United Kingdom, <sup>9</sup>Genentech, Inc., South San Francisco, United States, <sup>10</sup>Roche Products (Ireland) Ltd., Dublin, Ireland, <sup>11</sup>F. Hoffmann-La Roche Ltd., Basel, Switzerland

**Objective:** Dual inhibition of angiopoietin-2 and vascular endothelial growth factor (VEGF)-A with faricimab, a bispecific antibody designed for intraocular use, may promote vascular stability and durable efficacy in patients with neovascular age-related macular degeneration (nAMD). Here we report pooled efficacy, safety, and durability results through week 48 from the phase 3 TENAYA/LUCERNE trials and compare anatomical outcomes of faricimab with aflibercept through week 12, after 3 initial doses, in patients with nAMD.

**Methods:** TENAYA/LUCERNE (NCT03823287/NCT03823300) were identical, randomised, double-masked, active comparator-controlled, 112-week, phase 3 trials of faricimab in nAMD. Treatment-naïve patients (N = 1329) were randomised 1:1 to faricimab 6.0 mg up to every 16 weeks (Q16W; n = 665) or aflibercept Q8W (n = 664). After 4 initial doses Q4W, faricimab-treated patients received Q8W, Q12W, or Q16W doing based on protocol-defined disease activity assessments at weeks 20 and 24. Aflibercept-treated patients received 3 initial Q4W doses and then Q8W dosing. Primary endpoint was mean change from baseline in best-corrected visual acuity (BCVA) averaged over weeks 40, 44, and 48. Secondary efficacy endpoints, including visual/anatomical outcomes and safety, were assessed Q4W through week 48.

**Results:** Faricimab resulted in comparable visual acuity and anatomical outcomes compared with aflibercept averaged over weeks 40, 44, and 48, with 45.3% of faricimab-treated patients on Q16W dosing and 78.7% on  $\geq$  Q12W dosing. When both study treatments were administered Q4W through week 12, mean change in BCVA from baseline was comparable with faricimab versus aflibercept. Faricimab resulted in a greater reduction in mean (95% CI) change in central subfield thickness from baseline through week 12 versus aflibercept ( $-145.4 \mu\text{m}$  [ $-149.1, -141.8$ ] vs  $-132.9 \mu\text{m}$  [ $-136.6, -129.2$ ] at week 12, respectively). Proportions of patients with no subretinal fluid (SRF) and no retinal fluid (SRF or intraretinal fluid) were greater with faricimab through week 12. Faricimab was well tolerated through week 48, with low rates of intraocular inflammation and no vasculitis or occlusive retinitis events.

**Conclusion:** Through week 48 of TENAYA/LUCERNE, faricimab up to Q16W offered durable vision gains/meaningful anatomical improvements that were comparable with aflibercept Q8W and was well tolerated. When treated Q4W through week 12, faricimab resulted in more rapid improvement in anatomical outcomes versus aflibercept.

FP-081

## Incidence of New-onset Exudative AMD in Patients Treated with Pegcetacoplan for Geographic Atrophy in OAKS and DERBY

J Wong<sup>1</sup>, J Mones<sup>2</sup>, C Bauma<sup>3</sup>, P Joshi<sup>4</sup>, D Morris<sup>4</sup>, C Bliss<sup>4</sup>, C Wykoff<sup>5</sup>.

<sup>1</sup>Strathfield Retina Clinic, Sydney, Australia, <sup>2</sup>Institut de la Màcula Centro Médico Teknon, Barcelona, Spain, <sup>3</sup>Tufts Medical Center, Boston, <sup>4</sup>Apellis Pharmaceuticals, Waltham, <sup>5</sup>Houston Methodist Hospital, Houston, United States

**Objective:** New-onset exudative age-related macular degeneration (eAMD) has been observed in clinical trials of complement inhibitors for geographic atrophy (GA) secondary to AMD. Intravitreal pegcetacoplan, a C3 complement inhibitor, administered monthly (PM) or every-other-month (PEOM) is being evaluated in the Phase 3 OAKS and DERBY trials as a treatment for GA. Here we report on new-onset eAMD at 12 months of OAKS and DERBY.

**Methods:** OAKS and DERBY study designs have been previously reported. Any history of or active CNV in the study eye was excluded; history of CNV in the fellow eye was allowed. If eAMD was suspected by investigators based on clinical examination or SD-OCT, fluorescein angiography (FA) images went to an imaging reading center for confirmation. Patients remained on pegcetacoplan and anti-VEGF treatment was initiated at the investigator's discretion.

**Results:** At 12 months, 6322 pegcetacoplan injections had been administered in the trials (safety set: OAKS, N=636; DERBY, N=620). Pooled investigator-reported events of study eye new-onset eAMD, were reported in 25 (6.0%), 17 (4.1%) and 10 (2.4%) patients in the PM, PEOM, and sham groups, respectively. Six suspected CNV cases not confirmed by the reading center were reported by investigators as an eAMD event. The reading center detected 12 cases of macular neovascularization (MNV) at the Month 12 FA, not reported by investigators. One of 52 patients with study eye eAMD discontinued study treatment (PEOM). Fellow eye CNV at baseline was associated with increased incidence of new-onset study eye eAMD; no clear pattern was observed with respect to the presence of study eye double-layer sign at baseline. All but three events of eAMD were treated with anti-VEGF therapy. eAMD treated with anti-VEGF was well-managed, with favorable visual and anatomical outcomes. Of the investigator-determined eAMD events in pegcetacoplan-treated patients with reading center determination of CNV type on FA taken at the time of eAMD diagnosis, 28 of 32 (88%) showed occult MNV. At the time of eAMD, the majority of pegcetacoplan-treated patients had no subretinal fluid present on SD-OCT.

**Conclusion:** Patients receiving pegcetacoplan had low incidence of new-onset eAMD, with most remaining on pegcetacoplan and receiving anti-VEGF treatment. Outcomes for eAMD events treated with anti-VEGF were favorable. Future research should examine the relationship between Type 1 MNV and progression of atrophic lesions.

FP-082

## Faricimab for Macular Edema Due to Retinal Vein Occlusion: Rationale and Design of the Phase 3 BALATON and COMINO Trials

H Mehta<sup>1,2,3</sup>, C Danzig<sup>4</sup>, L Paris<sup>5</sup>, H Lin<sup>5</sup>, N Jain<sup>6</sup>, F Abreu<sup>5</sup>, Z Haskova<sup>5</sup>, L Hattenbach<sup>7</sup>.

<sup>1</sup>Save Sight Registries, University of Sydney, Sydney, <sup>2</sup>Strathfield Retina Clinic, Strathfield, Sydney, Australia,

<sup>3</sup>Ophthalmology Department, Royal Free London NHS Foundation Trust, London, United Kingdom, <sup>4</sup>Rand Eye Institute, Miami, FL, <sup>5</sup>Genentech, Inc., South San Francisco, CA, United States, <sup>6</sup>Roche Products Ltd., Welwyn Garden City, United Kingdom, <sup>7</sup>Augenlinik, Klinikum der Stadt Ludwigshafen gGmbH, Ludwigshafen, Germany

**Objective:** Dual inhibition of angiopoietin-2 and vascular endothelial growth factor-A (VEGF-A) with faricimab offers excellent visual acuity gains with strong durability in patients with diabetic macular edema. We will investigate the effects of faricimab on visual acuity and durability in patients with macular edema due to retinal vein occlusion (RVO).

**Methods:** BALATON (NCT04740905; n = 553; branch RVO) and COMINO (NCT04740931; n = 730; central/hemiretinal RVO) are phase 3, multicentre, randomised, double-masked, active comparator – controlled studies comparing faricimab with aflibercept in anti-VEGF treatment-naïve patients with branch or central/hemiretinal RVO. Both studies will compare 6 × monthly injections of faricimab 6.0 mg with aflibercept 2.0 mg. Patients will continue to faricimab 6.0 mg administered in up to 16 weekly intervals using a personalised treatment interval (PTI) dosing regimen (weeks 24–72). PTI adjustments, based on a protocol-driven treat-and-extend concept, are determined by changes in best-corrected visual acuity (BCVA) and central subfield thickness (CST).

**Results:** The primary endpoint is non-inferiority of faricimab versus aflibercept in mean change from baseline in BCVA at week 24. Secondary endpoints at week 24: mean change from baseline in BCVA, CST and 25-item National Eye Institute Visual Function Questionnaire composite score; proportion of patients gaining/avoiding loss of  $\geq 15$ ,  $\geq 10$ ,  $\geq 5$  or  $> 0$  letters. Secondary endpoints at week 72: same endpoints as week 24 and durability of treatment. Ocular/non-ocular adverse events, faricimab plasma concentration over time and anti-drug antibody development will be assessed.

**Conclusion:** BALATON and COMINO will evaluate whether dual inhibition of angiopoietin-2 and VEGF-A with faricimab improves outcomes beyond anti-VEGF monotherapy in patients with RVO and whether treatment can be personalised.

## FP-083

**Faricimab in Neovascular Age-Related Macular Degeneration: Year 2 Patient Case Profiles From the Phase 3 TENAYA and LUCERNE Trials**

I Pearce<sup>1</sup>, M Figueroa<sup>2</sup>, D Silverman<sup>3</sup>, B Swaminathan<sup>4</sup>, V Patel<sup>3</sup>, H Lin<sup>5</sup>, J Willis<sup>5</sup>, A Kotecha<sup>3</sup>.

<sup>1</sup>Royal Liverpool University Hospital, Liverpool, United Kingdom, <sup>2</sup>Clinica Baviera, Ramon y Cajal University Hospital, Madrid, Spain, <sup>3</sup>Roche Products Ltd., Welwyn Garden City, United Kingdom, <sup>4</sup>F. Hoffmann-La Roche Ltd., Mississauga, Canada, <sup>5</sup>Genentech, Inc., South San Francisco, United States

**Objective:** Year 1 data from the TENAYA/LUCERNE trials support the hypothesis that dual inhibition of angiopoietin-2 and vascular endothelial growth factor (VEGF)-A with faricimab, the first bispecific antibody designed for intraocular use, may promote vascular stability and durable efficacy beyond current anti-VEGF therapies for neovascular age-related macular degeneration (nAMD). Here we present a selection of illustrative case profiles for patients treated through year 2 of TENAYA/LUCERNE.

**Methods:** TENAYA/LUCERNE (NCT03823287/NCT03823300) were identical, randomised, double-masked, active comparator-controlled, 112-week, phase 3 trials of faricimab in nAMD. Treatment-naïve patients were randomised 1:1 to receive faricimab 6.0 mg up to every 16 weeks (Q16W) after 4 initial Q4W doses or aflibercept 2.0 mg Q8W after 3 initial Q4W doses. Patients in the faricimab arm were assessed for protocol-defined disease activity at weeks 20 and 24. Patients with no evidence of active disease received Q16W dosing through week 60, those with active disease at week 20 received Q8W dosing and patients with active disease only at week 24 received Q12W dosing. From week 60, faricimab-treated patients followed a treat-and-extend-based personalised treatment interval regimen, with dosing intervals extended by 4 weeks (maximum Q16W), maintained or reduced by 4 or 8 weeks (minimum Q8W), based on central subfield thickness (CST), best-corrected visual acuity and the presence or absence of new macular haemorrhage at active dosing visits. Aflibercept-treated patients continued fixed Q8W dosing through week 108.

**Results:** Overall, 1329 patients were enrolled in TENAYA (N = 671) and LUCERNE (N = 658). At 1 year, faricimab up to Q16W offered durable vision gains that were noninferior to aflibercept Q8W, with ~80% and ~45% of patients on ≥ Q12W and Q16W dosing intervals, respectively, at week 48. Decreases in CST were similar between arms. Faricimab up to Q16W was well tolerated, with low rates of intraocular inflammation. Year 2 data from TENAYA/LUCERNE are soon to be reported and will inform the longer-term efficacy, durability and safety of faricimab in patients with nAMD. Here we will describe representative cases and present associated retinal images for patients treated through year 2 of TENAYA/LUCERNE.

**Conclusion:** These year 2 TENAYA/LUCERNE case profiles will explore whether early vision gains, reductions in CST and extended (up to Q16W) dosing with faricimab are maintained over 2 years in patients with nAMD.



FP-084

## Predicting lesion shrinkage in eyes with myopic choroidal neovascularization from features on OCT angiography

J Liu<sup>1</sup>, X Yu<sup>1</sup>.

<sup>1</sup>Ophthalmology, Beijing Hospital, Beijing, People's Republic of China

**Objective:** To identify baseline morphological predictors of lesion shrinkage in patients with myopic choroidal neovascularization (mCNV) receiving anti-vascular endothelial growth factor (VEGF) therapy.

**Methods:** This retrospective study included 46 eyes (41 consecutive patients) with active mCNV receiving anti-VEGF treatment. Optical coherence tomography angiography (OCTA) was performed at baseline and after 1 year of treatment. Quantitative features of neovascularization, including mCNV area, total vessel length, vessel area, vessel length, junction, and endpoint density, and mean lacunarity were obtained from OCTA images using AngioTool software. Eyes were classified as “high-shrinkage” or “low-shrinkage” according to the median relative change in lesion area. Baseline quantitative morphological features associated with mCNV shrinkage were identified in univariate and multivariate logistic regression analyses.

**Results:** The mCNV area was significantly smaller by the 1-year follow-up visit ( $P=0.013$ ), with a median relative change of -16.5% (range, -100.0, 48.0). The relative change in mCNV area was -48.3% in the high-shrinkage group (23 eyes) and -5.2% in the low-shrinkage group (23 eyes). Eyes in the high-shrinkage group had a smaller mCNV area ( $P=0.013$ ), shorter total vessel length ( $P=0.023$ ), and a higher endpoint density ( $P<0.001$ ). Multivariate logistic regression analysis showed significant associations of high shrinkage with endpoint density (odds ratio 2.137,  $P=0.022$ ) and previous anti-VEGF treatment (odds ratio 0.437,  $P=0.028$ ).

**Conclusion:** Morphological features of neovascularization detected by OCTA can predict lesion shrinkage in eyes with mCNV receiving anti-VEGF therapy. Higher endpoint density of neovascularization contributed to mCNV shrinkage, particularly in treatment-naïve lesions.

## FP-085

**Does retinal vascularization progress after 60 weeks postmenstrual age in infants treated with bevacizumab?**

S Bayramoglu, N Sayin.

**Objective:** To investigate whether temporal retinal vascularization progresses after the 60 weeks postmenstrual age (PMA) in infants treated with intravitreal bevacizumab (IVB).

**Methods:** Patients charts of 489 eyes that were treated with IVB for Type 1 retinopathy of prematurity (ROP) and aggressive-ROP between March 2017 and December 2019, were retrospectively evaluated. Eyes that underwent two consecutive fundus fluorescein angiography (FFA) after 60 weeks PMA and that were not treated with laser during the follow-up were included in the study. 27 eyes of 14 infants fulfilled the all criteria. Horizontal disc diameter (DD), disc-to-fovea (DF) distance, length of temporal retinal vascularization (LTRV) were measured in pixels on the consecutive fluorescein angiograms.

**Results:** Mean gestational age, treatment age, age at first and final FFA sessions were  $28.9 \pm 2.7$ ,  $35.3 \pm 2.3$ ,  $77.7 \pm 15.7$ , and  $168.0 \pm 49.0$  weeks PMA, respectively. Between consecutive FFAs, DD, DF, and LTRV were significantly decreased in pixels by 1.9%, 6%, and 3.7%, respectively ( $p < 0.05$ ). The DF/DD ratio was  $3.30 \pm 0.46$ , and  $3.16 \pm 0.46$  in the first and final FFAs ( $p = 0.001$ ). The LTRV/DD ratio was  $13.38 \pm 2.12$  and  $13.15 \pm 2.13$ , in the first and final FFAs ( $p = 0.027$ ). The LTRV/DF ratio was  $4.06 \pm 0.39$  and  $4.17 \pm 0.42$ , respectively ( $p = 0.032$ ). Between consecutive FFAs, LTRV decreased by 0.23 in units of DD and increased by 0.09 in units of DF.

**Conclusion:** Temporal retinal vascularization decreased in units of pixels and DD during 90 weeks follow-up. We consider that the slight increase of LTRV in terms of DF is related to the decrease of the DF/DD ratio with age. In early childhood, with increasing age the asymmetrical growth of the globe and the increase in axial length affect the actual distance corresponding to each pixel. When we evaluate the findings of our study and previous reports that investigates the growth pattern of the globe, our study indicates that retinal vascularization did not progress after the 60 weeks PMA.

FP-086

**Artificial Intelligence for Screening of Multiple Retinal Diseases: A Real-world, Multicenter Study**L Dong<sup>1</sup>, R Zhang<sup>1</sup>, W He<sup>2</sup>, Y Chen<sup>2</sup>, W Wei<sup>1</sup>.<sup>1</sup>Beijing Tongren Hospital, Capital Medical University, Beijing, China, <sup>2</sup>Beijing Airdoc Technology Co., Ltd, Beijing, People's Republic of China

**Objective:** Deep learning algorithms applied to color fundus images have shown competitive or close-to-expert performance for automatically detecting single retinal diseases. Algorithms recognizing simultaneously occurring retinal diseases have only rarely been explored, in particular not in a real-world scenario. We used retinal images taken in several healthcare centers throughout China to evaluate the performance and efficiency of a deep learning system to detect various concurrently occurring retinal disorders and to compare the results with those obtained by ophthalmologists.

**Methods:** Retinal photographs centered on the optic nerve head or macula and taken by non-mydratiac 45-degree fundus cameras were divided into a development dataset, retrospective validation dataset, and prospective validation dataset. We applied a novel deep learning system (Retinal Artificial Intelligence Diagnosis System, RAIDS) to identify ten retinal diseases (referral diabetic retinopathy, referral age-related macular degeneration, referral possible glaucoma, pathological myopia, retinal vein occlusion, macular hole, epiretinal macular membrane, hypertensive retinopathy, myelinated fibers, and retinitis pigmentosa).

**Results:** As compared to retinal specialists, RAIDS reached a superior or similar diagnostic sensitivity in 7 out of 10 retinal diseases (referral diabetic retinopathy, referral possible glaucoma, macular hole, epiretinal macular membrane, hypertensive retinopathy, myelinated fibers, and retinitis pigmentosa), and achieved a comparable performance in two other diseases (age-related macular degeneration, retinal vein occlusion). As compared to ophthalmologists, RAIDS achieved a higher detection rate of any retinal abnormality (RAIDS: 91.6%, certified ophthalmologists: 83.7%; junior retina specialists: 86.4%; senior retina specialists: 88.5%). RAIDS saved 96%-97% of time costs and >99% of the financial costs. In the validation dataset of 208,758 images, RAIDS distinguished the ten retinal diseases with an accuracy ranging between 95.3% to 99.9% without marked differences between the various Chinese geographical regions.

**Conclusion:** The DL system may be helpful for an automated immediate referral of patients in screening and primary care scenarios, and it may help to overcome the lack of ophthalmologists in underdeveloped areas.

FP-087

**Risk of ischemic stroke and hemorrhagic stroke in retinal vein occlusion: A nationwide Population-Based Cohort study**Y Chen<sup>1,2</sup>, M Hung<sup>3</sup>.

<sup>1</sup> Department of Ophthalmology, Taichung Veterans General Hospital, Taichung, Taiwan, China, <sup>2</sup> Wilmers Eye Institute, Johns Hopkins Hospital, Baltimore, Maryland, United States, <sup>3</sup> Department of Medical Education, Taichung Veterans General Hospital, Taichung, Taiwan, China

**Objective:** To investigate whether the risk of subsequent stroke, ischemic stroke, and hemorrhagic stroke is increased among retinal vein occlusion (RVO) patients compared to non-RVO patients.

**Methods:** From the entire population of the Taiwan National Health Insurance Research Database (NHIRD) from 2001 to 2013, a total of 22919 subjects with RVO were enrolled in the RVO group, and 114595 propensity score (PS)-matched non-RVOs were enrolled in the comparison group. PS matching was based on age, gender, obesity, diabetes, hypertension, hyperlipidemia, coronary artery disease, atrial fibrillation, hyperviscosity syndrome, Charlson comorbidity index, glaucoma, and the use of antithrombotic drugs. A multivariate Cox regression analysis was used to estimate the adjusted hazard ratios (HRs) with a 95% confidence interval (CI) for each of the clinical outcomes, including stroke, ischemic stroke, and hemorrhagic stroke. Furthermore, we divided the RVO group into the branch retinal vein occlusion (BRVO) group and the central retinal vein occlusion (CRVO) group and separately compared their subsequent risks of the clinical outcomes with those of the comparison group.

**Results:** After adjusting for PS, the RVO group had a significantly higher risk of stroke (adjusted HR=1.36; 95% CI: 1.32–1.40), ischemic stroke (adjusted HR=1.36; 95% CI: 1.32–1.40), and hemorrhagic stroke (adjusted HR=1.34; 95% CI: 1.24–1.44). Furthermore, both the BRVOs and CRVOs had a significantly higher risk of subsequent stroke, ischemic stroke, and hemorrhagic stroke than did the comparisons.

**Conclusion:** People with RVO are at a significantly greater risk of developing stroke, ischemic stroke, and hemorrhagic stroke.

FP-088

## Unsupervised Domain Adaptation with Self-selected Active Learning for Cross-domain OCT Image Segmentation

T Liu<sup>1</sup>.

<sup>1</sup>Eye , Eye Hospital of Shandong First Medical University (Shandong Eye Hospital), Jinan, China, China, Hong Kong, China

**Objective:** we propose an UDA adversarial learning framework with self-selected active learning.by aligning the data distribution between labeled data(source domain) and unlabeled data (target domain).

**Methods:** The framework consists of two parts: domain adaptation module (DAM) and self-selected active learning module (SALM). The DAM learns domain-invariant features (i.e., common features) gradually to narrow the distribution discrepancy between two domains.

**Results:** The SALM introduces the target data into source domain through discrepancy method and similarity method, which promotes the DAM to learn unique features of target domain.

**Conclusion:** Extensive experiments show the effectiveness of our method. Compared with the state-of-the-art UDA methods, our method has achieved better performance on two medical cross-domain datasets

FP-089

## The Efficacy And Safety of Conbercept Ophthalmic Injection For Macular Edema Secondary to Central Retinal Vein Occlusion (CRAVE)

W Wei, X Shi, X Li, X Li, H Han, X Sun, L Tang, M Zhang, L Lv, Y Chen, G Su, X Liu, M Huang, J Ye, L Wang, L Li, F Yuan, H Dou, T Liu, L Yang, Y Wang, Y Song, P Wang, L Qin, X Chen, S Wang.

**Objective:** To evaluate the efficacy and safety of intravitreal conbercept injections for the treatment of macular edema (ME) secondary to central retinal vein occlusion (CRVO-ME).

**Methods:** A randomized, multicenter, double-blind placebo-controlled phase III study. From day 0 to month 5, patients received either 0.5mg intravitreal conbercept ophthalmic injection (the treatment group) or sham injection (the control group) every month. From months 6 to 11, the treatment group received conbercept as needed (pro re nata, PRN). While the control group received a single 0.5mg intravitreal conbercept ophthalmic injection in month 6 and received conbercept as needed till month 12. The primary efficacy outcome was mean changes in Best-Corrected Visual Acuity (BCVA) from baseline at month 6. Secondary efficacy outcomes included mean changes in central retinal thickness (CRT) and total macular volume from baseline to month 6. Efficacy endpoints at 12 months were exploratory.

**Results:** For 240 patients in the full analysis set (FAS), the mean age of patients was 57.3 years in the treatment group and 55.0 years in the control group. The proportions of males were 50.3% and 60.2% in the treatment group and control group, respectively. The mean change from baseline BCVA letter score at month 6 was  $13.6 \pm 12.1$  ( $P < 0.001$ ) and  $-2.2 \pm 16.5$  ( $P < 0.001$ ) in the treatment group and the control group, respectively ( $P < 0.001$  for treatment group vs control group). The mean change of BCVA letter score from month 6 to month 12 was  $0.8 \pm 8.1$  in the treatment group ( $P = 0.2136$ ), and  $5.2 \pm 8.1$  letters in the control group ( $P < 0.0001$ ). The mean reduction CRT from baseline was  $138.38 \pm 99.37$   $\mu\text{m}$  in the treatment group and  $35.1 \pm 98.83$   $\mu\text{m}$  in the control group at month 6 ( $P < 0.0001$ ). No patients received rescue therapy during the entire study. The most frequent ocular serious adverse event from baseline to month 12 was increased intraocular pressure (13.24%), conjunctival hemorrhage (12.79%), and visual impairment (10.96%) in patients treated with conbercept. The SAEs related to the study intervention were endophthalmitis (1 case) and hypertension (1 case). No patients died in the study.

**Conclusion:** The CRAVE study showed that intravitreal injection of conbercept ophthalmic injection has definite efficacy and expected controllable safety in patients with ME secondary to CRVO. The extended period study provided a more flexible strategy for conbercept in the clinical treatment of CRVO.

FP-090

**Various Phenotypes of Autosomal Dominant Cone-Rod Dystrophy with CRX Mutation in Two Chinese Families**H Cui.

**Objective:** To present the clinical manifestations of 5 autosomal dominant cone-rod dystrophy (adCORD) patients from two Chinese families with CRX mutation (p. R41W), and to explore the clinical heterogeneity of adCORD with CRX mutation (p. R41W).

**Methods:** Interrogation and ophthalmological examinations were undertaken in all patients and the unaffected members. Analysis of clinical features was performed by visual acuity, slit lamp examination, visual field examination, funduscopy, autofluorescence and spectral domain optical coherence tomography. The targeted next-generation sequencing was applied as a useful tool to identify the causative mutation of CORD genes.

**Results:** A CRX missense mutation c.121C>T was identified in all the patients, resulting in an amino acid change from arginine acid to tryptophan (p. R41W). And the patients presented early onset, progressive and different severity cone-rod dystrophy.

**Conclusion:** This is the first report of clinical phenotype of CRX mutation (p. R41W) in Chinese families, and the mutation can lead to a wide range of various retinal phenotypes.

## FP-091

**Key Pearls of the Refill-Exchange Procedure for the Port Delivery System With Ranibizumab (PDS)**

A Fung<sup>1</sup>, A Khanani<sup>2</sup>, N Singh<sup>3</sup>, G Barteselli<sup>3</sup>, N Callaway<sup>3,4</sup>, S Patel<sup>3</sup>, P Jaycock<sup>5</sup>, A Menezes<sup>3</sup>, V Malhotra<sup>3</sup>.

<sup>1</sup>Westmead Hospital, Sydney, Australia, <sup>2</sup>Sierra Eye Institute, Reno, <sup>3</sup>Genentech, Inc., South San Francisco, <sup>4</sup>Stanford University Byers Eye Institute, Palo Alto, United States, <sup>5</sup>Roche Products Limited, Welwyn Garden City, United Kingdom

**Objective:** The Port Delivery System with ranibizumab (PDS) is an innovative drug delivery system designed for continuous intravitreal release of a customised formulation of ranibizumab through a surgically implanted, refillable ocular implant. PDS with ranibizumab 100 mg/mL (PDS 100 mg/mL) is approved in the United States for neovascular age-related macular degeneration (nAMD). Here we report key pearls from the optimisation of the PDS refill-exchange procedure.

**Methods:** The phase 2 Ladder trial (NCT02510794) and phase 3 Archway trial (NCT03677934) compared the PDS with monthly intravitreal ranibizumab 0.5 mg injections for the treatment of nAMD. The ongoing open-label extension trial, Portal (NCT03683251) is evaluating the long-term safety and tolerability of PDS 100 mg/mL. Experiences during refill-exchange procedures in clinical trials have informed the evolution of PDS procedural methodologies, with the goal of optimising procedure and patient outcomes.

**Results:** The PDS implant is refilled during a minimally invasive in-clinic refill-exchange procedure under strict aseptic conditions using the specially designed PDS refill needle. The refill needle is a 34G double cannula with a vented needle and fluid collection reservoir that enables exchange of the implant contents with fresh ranibizumab 100 mg/mL. The refill-exchange procedure is successfully performed with the retina specialist standing on the contralateral side of the study eye using a cotton-tipped applicator to stabilize the globe and minimise eye movement. Optimisation of visualisation with proper patient positioning (supine at ~20- to 30-degree angle with patient looking down and towards their nose), magnification, transillumination and task lighting set the stage for success. A strictly perpendicular approach, precise targeting into the septum center and avoidance of twisting and manoeuvring while the needle is engaged during the procedure is critical. The implant should be refilled slowly over ~5–10 seconds and the refill needle soft stop must remain in contact with the conjunctiva throughout the refill-exchange procedure.

**Conclusion:** The PDS refill-exchange procedure represents a new advancement in vitreoretinal practice. Appropriate adherence to the refill-exchange procedure maximises safe and optimal outcomes. Clinical trial experiences have informed the evolution and refinement of the refill-exchange procedure, which will continue to evolve as needed to support successful patient outcomes.



FP-092

### Faricimab in Neovascular Age-Related Macular Degeneration: 48-Week Results by Dosing Cohort in the Phase 3 TENAYA/LUCERNE Trials

S Michels<sup>1,2</sup>, G Cheung<sup>3,4,5,6</sup>, T Lai<sup>7</sup>, C Quezada Ruiz<sup>8</sup>, D Silverman<sup>9</sup>, J Ives<sup>9</sup>, B Swaminathan<sup>10</sup>, H Lin<sup>8</sup>, J Willis<sup>8</sup>, A Kotecha<sup>9</sup>.

<sup>1</sup>Eye Clinic Zurich West, <sup>2</sup>University of Zurich, Zurich, Switzerland, <sup>3</sup>Singapore Eye Research Institute, <sup>4</sup>Singapore National Eye Centre, <sup>5</sup>Duke-NUS Medical School, <sup>6</sup>National University of Singapore, Singapore, Singapore, <sup>7</sup>Department of Ophthalmology and Visual Science, The Chinese University of Hong Kong, New Territories, Hong Kong, China, <sup>8</sup>Genentech, Inc., South San Francisco, United States, <sup>9</sup>Roche Products Ltd., Welwyn Garden City, United Kingdom, <sup>10</sup>F. Hoffmann-La Roche Ltd., Mississauga, Canada

**Objective:** Week 48 data from the phase 3 TENAYA/LUCERNE trials support the hypothesis that dual inhibition of angiopoietin-2 and vascular endothelial growth factor (VEGF)-A with faricimab, the first bispecific antibody designed for intraocular use, may promote vascular stability and durable efficacy beyond current anti-VEGF therapies for neovascular age-related macular degeneration (nAMD). Here we report pooled 48-week efficacy results by faricimab dosing interval cohort.

**Methods:** TENAYA (NCT03823287) and LUCERNE (NCT03823300) were identical, randomised, double-masked, active comparator-controlled, 112-week, phase 3 trials of faricimab in nAMD. Treatment-naïve patients (N = 1329) were randomised 1:1 to faricimab 6.0 mg up to every 16 weeks (Q16W; n = 665) or aflibercept 2.0 mg Q8W (n = 664). After 4 initial Q4W doses, faricimab-treated patients received Q8W, Q12W or Q16W dosing during the maintenance phase, based on prespecified central subfield thickness (CST) and best-corrected visual acuity (BCVA) disease activity criteria and presence of new macular hemorrhage per investigator examination at weeks 20 and 24. The primary endpoint was change in BCVA from baseline averaged over weeks 40, 44 and 48. Secondary efficacy endpoints, including visual/anatomical outcomes, were assessed Q4W through week 48. This post hoc analysis evaluated efficacy outcomes by faricimab dosing interval cohort as determined during clinical examination visits.

**Results:** Faricimab resulted in similar visual acuity and anatomical outcomes vs aflibercept at week 48. The proportions of faricimab-treated patients on the dosing interval cohorts at week 48 were: Q16W, 45%; Q12W, 34%; and Q8W, 21%. Baseline demographics were generally well balanced across dosing interval cohorts. All faricimab-treated cohorts showed sustained vision gains throughout the maintenance phase. There was a consistently high proportion of patients avoiding a  $\geq 15$ -letter vision loss throughout the study in all faricimab dosing interval cohorts (at week 48: Q16W, 96%; Q12W, 95%; and Q8W, 92%). In all faricimab cohorts, the rapid decreases in CST during the 4-month initiation phase were sustained throughout the maintenance phase, with similar reductions between cohorts through week 48. Patients on the extended Q16W dosing interval maintained CST reductions after the initiation phase, with minimal variations in CST.

**Conclusion:** Vision gains and disease control in TENAYA/LUCERNE were sustained in the maintenance phase in all faricimab dosing interval cohorts.

FP-093

**Brolucizumab for the Treatment of Diabetic Macular Edema: 52-week Results from the KINGFISHER Study**

A Emanuelli<sup>1</sup>, M Barakat<sup>2</sup>, R Singh<sup>3</sup>, M Ip<sup>4,5</sup>, P Higgins<sup>6</sup>, V Sheth<sup>7</sup>, D Eichenbaum<sup>8</sup>, C Wykoff<sup>9</sup>, Y Kim<sup>10</sup>, F He<sup>11</sup>, G Cho<sup>12</sup>, Y Wang<sup>10</sup>.

<sup>1</sup>Department of Ophthalmology, University of Puerto Rico School of Medicine, San Juan, Puerto Rico, <sup>2</sup>Retinal Consultants of Arizona, Phoenix, AZ, USA, Arizona, <sup>3</sup>Center for Ophthalmic Bioinformatics, Cole Eye Institute, Cleveland Clinic, Cleveland, <sup>4</sup>Department of Ophthalmology, David Geffen School of Medicine, University of California, <sup>5</sup>Doheny Eye Institute, Los Angeles, CA, <sup>6</sup>Retina Center of New Jersey, Bloomfield, NJ, <sup>7</sup>University Retina and Macula Associates, Oak Forest, IL, <sup>8</sup>Retina Vitreous Associates of Florida, St. Petersburg, FL, <sup>9</sup>Retina Consultants of Texas; Retina Consultants of America; Blanton Eye Institute, Houston Methodist Hospital, Houston TX, United States, <sup>10</sup>Novartis Pharma AG, Basel, Switzerland, <sup>11</sup>Beijing Novartis Pharma Co., Ltd., Beijing, People's Republic of China, <sup>12</sup>Novartis Pharmaceuticals Corporation, East Hanover, NJ, United States

**Objective:** To present 52-week results from the KINGFISHER study that evaluated efficacy and safety of brolucizumab (BRO) versus aflibercept (AFL) in patients with visual impairment due to diabetic macular edema (DME).

**Methods:** KINGFISHER (NCT03917472) was a 12-month, randomized, double-masked, multicenter phase 3 study. Patients were randomized 2:1 to either BRO 6 mg or AFL 2 mg. The primary efficacy endpoint was change from baseline (least squares mean [standard error] [LS mean (SE)]) in best corrected visual acuity (BCVA; Early Treatment Diabetic Retinopathy Study letters) at Week 52 in the study eye. Secondary efficacy endpoints included the proportion of patients with  $\geq 2$ -step improvement from baseline in Diabetic Retinopathy Severity Scale (DRSS) score at Week 52; the proportion of study eyes with absence of both sub-retinal fluid (SRF) and intra-retinal fluid (IRF) at Week 52; and change from baseline in central subfield thickness (CSFT) at Week 52 in study eye.

**Results:** A total of 517 subjects (mean [standard deviation] age: 60.7 [10.18] years; HbA1c: 7.89 [1.51] %; BCVA: 61.1 [10.5] letters) were randomized to either BRO (n=346) or AFL (n=171). BRO was non-inferior to AFL with respect to the primary endpoint of change from baseline in BCVA (BRO: +12.2 [0.51] letters; AFL: +11.0 [0.73] letters; difference [95% confidence interval (CI)]: 1.1 [-0.6, 2.9] letters; non-inferiority margin [NIM]: 4 letters;  $p < 0.001$ ). Additionally, BRO non-inferiority vs AFL was demonstrated for proportion of subjects with  $\geq 2$ -step improvement from baseline in DRSS at Week 52 (BRO: 43.4%; AFL: 37.4%; difference [95% CI]: 6.0% [-3.9%, 16.1%]; NIM: 10%;  $p = 0.002$ ). BRO superiority vs AFL was confirmed for the proportion of study eyes with absence of both SRF and IRF at Week 52 (BRO: 41.8%; AFL: 21.8%; difference [95% CI]: 20.0% [12.5%, 28.6%];  $p < 0.001$ ) and for

change from baseline in CSFT at Week 52 in the study eye (LS mean [SE] BRO: -237.8 [5.13]  $\mu$ m; AFL: -196.5 [7.30]  $\mu$ m; difference [95% CI]: -41.4 [-58.9, -23.8]  $\mu$ m;  $p < 0.001$ ).

Incidence of intraocular inflammation was BRO: 4.0%; AFL: 2.9%, retinal vasculitis: BRO: 0.9%; AFL: 0.6%, and retinal vascular occlusion: BRO: 0.3%; AFL: 0.6%. No cases of endophthalmitis were reported.

**Conclusion:** In KINGFISHER, BRO 6 mg demonstrated non-inferior visual gains and superior anatomical improvements compared with AFL 2 mg in patients with DME, with no new safety signals.

FP-094

## Efficacy and safety of biosimilar QL1207 vs aflibercept for neovascular age-related macular degeneration (nAMD): a phase 3 trial

B Li<sup>1</sup>, Y Chen<sup>1</sup>, K Fan<sup>2</sup>, F Wang<sup>3</sup>, T Zhang<sup>4</sup>, D Zheng<sup>5</sup>, S Zeng<sup>6</sup>, M Zhao<sup>7</sup>, Z Wu<sup>8</sup>, X Liu<sup>9</sup>, Y Song<sup>10</sup>, Q Ren<sup>11</sup>, J Wang<sup>12</sup>, Z Wang<sup>12</sup>.

<sup>1</sup>Peking Union Medical College Hospital, Beijing, <sup>2</sup>Henan Provincial Eye Hospital, Henan, <sup>3</sup>The Second Affiliated Hospital of Xi'an Jiaotong University, Zhengzhou, <sup>4</sup>Jinan Second People's Hospital, Jinan, <sup>5</sup>Shanxi Ophthalmic Hospital, Taiyuan, <sup>6</sup>Guangxi Zhuang Autonomous Region People's Hospital, Nanning, <sup>7</sup>Peking University People's Hospital, Beijing, <sup>8</sup>Wuxi Second People's Hospital, Wuxi, <sup>9</sup>Eye Hospital, WMU Zhejiang Eye Hospital, Wenzhou, <sup>10</sup>General Hospital of Central Theater Command, Wuhan, <sup>11</sup>The First Hospital of Hebei Medical University, Shijiazhuang, <sup>12</sup>Qilu Pharmaceutical Co., Ltd., Jinan, People's Republic of China

**Objective:** This trial aimed to evaluate the equivalence of efficacy and safety between QL1207 and the reference aflibercept for nAMD (NCT05345236).

**Methods:** This randomized, double-blind, parallel-group phase 3 trial was conducted in 35 centers in China. Eligible patients were  $\geq 50$  years old, with untreated subfoveal choroidal neovascularization (CNV) secondary to nAMD and best-corrected visual acuity (BCVA) letter score of 73 to 34 using Early Treatment Diabetic Retinopathy Study (ETDRS) charts in the study eye. Patients were randomized 1:1 to receive intravitreal injection of either QL1207 or aflibercept 2 mg (0.05 mL) in the study eye every four weeks for the first three months, followed by 2 mg (0.05 mL) every eight weeks until Week 48 (eight doses in total). The primary endpoint was BCVA change from baseline at Week 12, analyzed using mixed model for repeated measures. The equivalence margin was  $\pm 5$  letters. Secondary endpoints included BCVA change from baseline at other timepoints, central retinal thickness and CNV size changes from baseline at each timepoints, etc. The safety, immunogenicity, pharmacokinetics (PK), and plasma vascular endothelial growth factor (VEGF) level were also assessed.

**Results:** From Aug 2019 to Jan 2022, 366 patients were enrolled. Baseline characteristics were comparable between the two groups. The least-squares means (LSM) of BCVA change from baseline at Week 12 were 10.4 (standard error 0.7) letters in the QL1207 group (n=185) and 11.5 (0.7) letters in the aflibercept group (n=181). The LSM difference was -1.1 (95% CI -3.0 to 0.7; P=0.2275), within the equivalence margin. Most secondary endpoints showed similar results between the two groups. The incidences of treatment-emergent adverse events (TEAE; QL1207: 71.4% [132/185] vs aflibercept: 71.8% [130/181]) and serious TEAE (QL1207: 14.1% [26] vs aflibercept: 12.7% [23]) appeared comparable between treatment groups, and no new safety concerns were observed. Anti-drug antibody was detected in 13/184 (7.1%) patients for QL1207 and 14/181 (7.7%) for aflibercept. The PK and plasma VEGF level profiles were similar between the two groups.

**Conclusion:** QL1207 is equivalent to aflibercept in respect of efficacy and safety profiles for patients with nAMD.

FP-095

**Real World Efficacy, Durability and Safety of Faricimab in Diabetic Macular Edema: The TAHOE Study**

H Khan<sup>1,2</sup>, T Ewing<sup>1</sup>, A Aziz<sup>2</sup>, R Fong<sup>2</sup>, M Thomas<sup>2</sup>, A Saulebayeva<sup>1</sup>, A Khanani<sup>1,2</sup>.

<sup>1</sup>Sierra Eye Associates, <sup>2</sup>University of Nevada Reno School of Medicine, Reno, United States

**Objective:** Faricimab was approved by the FDA in late January 2022 for the sustained treatment of diabetic macular edema (DME). Current anti-VEGF agents drastically improved patient outcomes but real-world patients show decline in visual acuity due to frequent injections and high treatment burden. This real-world retrospective study collects and analyzes efficacy, safety, and durability of faricimab in patients diagnosed with DME.

**Methods:** Patients are evaluated following treatment switch from other anti-vascular endothelial growth factor (anti-VEGF) to faricimab along with treatment-naïve patients. Demographics, early treatment diabetic retinopathy study (ETDRS) scores, changes in central subfield thickness (CST) and previous treatment frequency were collected at specified endpoints. Faricimab treatment interval is compared to previous anti-VEGF treatment intervals to investigate durability. Visual acuity (VA), sub/intraretinal fluid (SRF/IRF), and CST improvements are evaluated as averages. Adverse events are collected and reported.

**Results:** Due to the recent approval of faricimab, data collection is ongoing. Thus far, three DME eyes were evaluated at baseline to faricimab treatment. Mean [SEM] age is 81.7 [2.5] years. Adjusted mean baseline ETDRS and CST values are 59.11 [6.82] letters and 349.5 [29.35]  $\mu\text{m}$ , respectively, with increased VA six weeks following injection at 67.95 letters. No adverse events have been reported.

**Conclusion:** Phase III clinical trials have demonstrated durability of faricimab in patients afflicted by DME with improvements in VA and CST values over time. This study is designed to evaluate the efficacy and safety of faricimab in controlling real-world DME disease progression.

FP-096

## Eight-year visual acuity outcomes of the Treat-and-Extend Regimen in Management of Neovascular Age-related Macular Degeneration

R Fong, M Thomas<sup>1</sup>, C Romero<sup>2</sup>, J Vannavong<sup>2</sup>, J Dang<sup>1</sup>, A Aziz<sup>1</sup>, P Shappell<sup>3</sup>, A Wadsworth<sup>2</sup>, F Siddiqui<sup>1</sup>, M Koci<sup>4</sup>, G Gahn<sup>5</sup>, N Mojumder<sup>1</sup>, M Hagen<sup>1</sup>, W Yang<sup>1</sup>, J Chhablani<sup>6</sup>, A Khanani.

<sup>1</sup>University of Nevada, Reno School of Medicine, <sup>2</sup>Sierra Eye Associates, Reno, <sup>3</sup>University of Southern California, Los Angeles, <sup>4</sup>Ophthalmology, University of Missouri School of Medicine, Columbia, <sup>5</sup>University of Arizona Department of Ophthalmology and Vision Science, Tucson, <sup>6</sup>University of Pittsburgh Medical Center, Pittsburgh, United States

**Objective:** The Treat-and Extend (T&E) regimen with anti-VEGF agents is often used by retina specialists in clinical settings in the treatment of neovascular age-related macular degeneration (nAMD). This study evaluated the real-world long-term eight-year visual acuity outcomes of regular intravitreal anti-VEGF agents in patients with nAMD in the United States.

**Methods:** This is a retrospective, interventional, consecutive case series. 165 eyes from 137 treatment-naïve patients diagnosed with nAMD after August 2010 were treated at a single site by one physician with ranibizumab, aflibercept, bevacizumab, or brolucizumab for  $\geq 1$  year using a T&E regimen. Patients needed to receive  $\geq 6$  injections in the first year and  $\geq 3$  injections in the following years to be included in this study. Snellen best-corrected visual acuity (BCVA) was converted to ETDRS letters using a standardized formula. The main outcome measures were: BCVA change from baseline to end of patient follow-up, mean number of injections per year, and percentage of eyes losing  $\geq 15$  letters, gaining  $\geq 15$  letters or maintained vision within 15 letters.

**Results:** The average (standard deviation [SD]) baseline patient age was 78 years (8.5); 60% of patients were female. The mean follow-up period was 5.4 years, with 165, 158, 143, 126, 102, 78, 48, and 26 eyes completing 1, 2, 3, 4, 5, 6, 7, and 8 years of follow up, respectively. The average BCVA at baseline was 53 letters. Mean (SD) changes from baseline in BCVA were 8.3 (21.8) letters, 7.1 (25.0) letters, 4.7 (26.5) letters, 4.5 (27.1) letters, 4.5 (28.3) letters, 5.1 (26.5) letters, and -0.5 (34.8) letters and -4.3 (38.9) letters for years 1-8 respectively. Mean number of injections during years 1-8 were 7.9, 6.1, 5.8, 6.0, 6.2, 5.9, 6.2, and 6.0, respectively. At the final follow-up, 24.2% of eyes had lost  $\geq 15$  letters, 26.1% eyes had gained  $\geq 15$  letters and 49.7% of eyes had maintained vision within 15 letters.

**Conclusion:** 75.8% of patients on the T&E regimen either maintained or improved their vision at the final follow up. The T&E regimen has been effective in maintaining visual acuity in nAMD patients treated with ranibizumab, aflibercept, bevacizumab, or brolucizumab for up to six years of treatment. Years seven and eight had an overall average loss in EDTRS letters, however further collection of data is needed to confirm these findings.



FP-097

**Safety and Efficacy of Intravitreal Conbercept in China: A Long-term, Prospective, Multi-center and Real-World Study (STONE STUDY)**X Zhang, N Wang<sup>1</sup>.<sup>1</sup>Being Tongren Eye Center, Beijing, People's Republic of China

**Objective:** Conbercept is a novel recombinant fusion protein designed as a decoy receptor for vascular endothelial growth factor and placental growth factor. The aim of this real-world study is to further validate the safety and efficacy of intravitreal injection of 0.5mg Conbercept in China.

**Methods:** STONE was a prospective, multicenter, non-interventional, phase IV real world cohort study. All enrolled participants with 0.5 mg Conbercept intravitreal indications were followed up for 1 year. The main outcome measures were the mean best corrected visual acuity (BCVA), mean changes in BCVA, the incidence of adverse events (AEs) and serious AEs (SAEs).

**Results:** A total of 4113 patients with retinal and choroidal vascular diseases were randomized included in the study, 3833 subjects were included in the per-protocol data set (PPS, 2125 people [51.70%] females; mean [SD] age, 59.2[14.10] years). The population covered 23 provinces or regions, distributed in 68 centers. The average number of injections was 1.85, and 50.4%, 26.3% and 23.4% of participants received one, two and three injections or more during 1 year, respectively. The overall incidence, ocular and non-ocular, intravitreal injection related adverse events was 12.4%, 9.2%, 3.3% and 4.9% respectively. At month 12, adjusted mean gained BCVA was 6.26 (18.53) letters from baseline (95%CI, 5.66-6.8,  $p < 0.0001$ ). The mean BCVA gains in eyes with branch retinal vein occlusion (BRVO), CRVO, diabetic macular edema, neovascular age-related macular degeneration, polypoidal choroidal vasculopathy, and other indications was 8.03 ( $P < 0.0001$ ), 6.27 (20.08,  $p < 0.0001$ ), 3.59 ( $P < 0.0001$ ), 4.52 (15.85,  $p < 0.0001$ ), 2.24 (17.52,  $P = 0.002$ ) and 8.82 (21.10,  $p < 0.0001$ ) letters respectively from baseline. The mean BCVA gains in Eyes with only 1 injection was 6.48 (18.03) letters, with 3 to 6 injections ( $n = 122$ ) was 17.90 (20.59) letters from baseline.

**Conclusion:** The safety profile established in this study was similar to the current instructions of Conbercept. Conbercept is significantly effective for visual and anatomic improvement in variable retinal and choroidal vascular diseases. Increased injection frequency was associated with higher 12-month BCVA gains. Eyes with lower baseline BCVA improved significantly after one year of Conbercept injection.

**FP-098****Causes of Papilledema in the Pediatric Age Group: A 10-Year Hospital Based Study in Northeastern India**H Das<sup>1</sup>.<sup>1</sup>*Ophthalmology, Nazareth Hospital, Shillong, Shillong, India***Objective:** To study the various causes of papilledema in the pediatric age group.**Methods:** 160 cases of papilledema from January 2011 to December 2020 were studied prospectively. Detailed history, C/F, neuroimaging mostly CT scan were done and followed up to 3 months.**Results:** Cases were divided into 3 age groups: (0-3) yrs, (4-12) yrs and (13-18) yrs. 42.86% of cases were infection, 33.57% space occupying lesion (SOL), 10.71% otogenic intracranial complication, 8.57% pseudotumor cerebri and 4.29% hypertension. Among the infective group, there were 25.72% tuberculosis, 10.71% viral, 5.00% bacterial and 1.43% of fungal etiology. Among SOL there were 10.715% tumors, 10.715% tuberculoma, 5.71% intracranial hematoma, 3.57% brain abscess and 2.86% neurocysticercosis. Earliest regression was at the end of 1 month and maximum in infective group.**Conclusion:** Important findings were 1.tuberculosis (meningitis and tuberculoma) due to urban overcrowding and rural poverty; 2. middle ear infection due to the higher altitude location of the region; 3. neurocysticercosis due to the habit of eating smoked pork. This geographic area is located 5000 feet above the sea level. Knowledge of common causes of papilledema will guide us in early diagnosis and management of cases with headache in this tribal dominated, underdeveloped area.

FP-099

**Reduced mobile zinc protects RGCs from optic nerve injury through inhibiting oxidative stress and autophagy**C Wu, J Han, J Tang, Z Liu, S Wu, Y Li<sup>1</sup>.

<sup>1</sup>*Glaucoma, The State Key Laboratory of Ophthalmology, Zhongshan Ophthalmic Center, Sun Yat-sen University, Guangdong Provincial Key Laboratory of Ophthalmology and Visual Science, Guangzhou, China, Guangzhou, People's Republic of China*

**Objective:** Mobile zinc ( $Zn^{2+}$ ), mostly originated from amacrine cells, increased rapidly in retina after optic nerve crush (ONC). Lowering the level of  $Zn^{2+}$  by its chelation (TPEN) was shown to promote RGCs survival and axon regeneration<sup>[1]</sup>. However, the mechanism of how reduced  $Zn^{2+}$  protects RGCs from ONC was still unclear. The aim of this study was to investigate whether lower  $Zn^{2+}$  protects RGCs from ONC by inhibiting oxidative stress and autophagy.

**Methods:** ONC model of mice was performed as previously described<sup>[1]</sup>. The mice conditionally knocked out with  $Zn^{2+}$  transporter (ZnT3) in amacrine cells (VGAT-Cre:ZnT3<sup>fl/fl</sup>, CKO) of retina was used.  $Zn^{2+}$  chelation, TPEN (100 $\mu$ mol/L, 3 $\mu$ l) was injected into the vitreous body after ONC immediately. Dihydroethidium (DHE) staining was used to detect reactive oxygen species (ROS) in retina. Immunofluorescence and western blot were employed to evaluate protein expression levels.

**Results:** Treatment of CKO or TPEN remarkably reduced oxidative stress after ONC by lowering ROS level in retina ganglion cell layer. Moreover, CKO or TPEN inhibited the formation of autophagosome in RGCs after ONC, as demonstrated by the downregulation of LC3B and Beclin1.

**Conclusion:** Reduced mobile zinc probably protects RGCs by anti-oxidative stress and anti-autophagy effects.

FP-100

## Construction and functional enrichment analysis of CeRNA regulatory network for non arteritis anterior ischemic optic neuropathy

Z Meng.

**Objective:** Based on the transcriptome high-throughput sequencing of non arteritis anterior ischemic optic neuropathy, this study constructed a competitive endogenous RNA (CeRNA) network of interaction network, enriched and analyzed it, screened lncRNA and circRNA that may participate in the competitive endogenous mechanism in NAION, and inferred its function.

**Methods:** 4ml peripheral blood of NAION patients and control group were extracted from clinical samples, and the transcriptome high-throughput sequencing was performed, and the sequencing data were visualized; Based on the principle of CeRNA network, lncRNA-miRNA-mRNA interaction axis and circRNA-miRNA-mRNA interaction axis were constructed respectively; The differentially expressed genes in the interaction axis were enriched and analyzed by GO and KEGG, and the functions and signal pathways of lncRNA and circRNA in the interaction network were speculated.

**Results:** 51 circRNAs were differentially expressed in the sequencing data: 25 were up-regulated and 26 were down-regulated; There were 996 differentially expressed lncRNAs: 317 were up-regulated and 679 were down-regulated; 1161 differentially expressed mRNAs: 698 were up-regulated and 463 were down-regulated. 33 differentially expressed miRNAs, up-regulated mirna18 and down-regulated 15. After screening, the co-expressed 13 mRNAs, 15 lncRNAs and 3 miRNAs were finally constructed in lncRNA-miRNA-mRNA network and the circRNA-miRNA-NETmRNA network were constructed by 159 mRNAs, 26 miRNAs and 34 circRNAs. In the lncRNA network, GO enrichment analysis obtained 182 biological processes, 12 cell components and 38 molecular functions, which are mainly related to the activity regulation of proteins and enzymes such as cyclic nucleotide dependent protein kinase activity and magnesium ion dependent protein serine / threonine phosphatase activity. KEGG analysis mainly involves FOXO signal pathway, Apelin signal pathway, etc. In the result of circRNA enrichment, 353 biological processes, 52 cell components and 45 molecular functions were obtained, mainly involving calcium channel regulation, neutrophil activation, mRNA transport and metabolism. KEGG mainly involves Wnt signaling pathway, Apelin signaling pathway, Hippo signaling pathway, oxytocin signaling pathway, etc.

**Conclusion:** This paper provides a new idea for lncRNA and circRNA to mediate the occurrence and development of NAION through CeRNA mechanism. It lays a foundation for the in-depth study of pathogenesis of NAION.

## FP-101

## Assessment of retinal sensitivity and structural integrity in optic neuritis

S Phuljhele<sup>1</sup>, R Khan<sup>1</sup>, R Saxena<sup>1</sup>, A Pujari<sup>1</sup>, R Dhiman<sup>1</sup>.

<sup>1</sup>Ophthalmology, AIIMS New Delhi, New Delhi, India

**Objective:** To evaluate Microperimetry as a tool for retinal sensitivity in optic neuritis and to correlate retinal sensitivity with anatomical changes of GCL-IPL complex, RNFL and visual fields.

**Methods:** A case control study with 19 cases of optic neuritis and 15 controls was conducted. Detailed ophthalmic evaluation and visual field assessment was done. Microperimetry for retinal sensitivity and RNFL and GCL-IPL thickness was evaluated at time of presentation and at 3 months. Retinal sensitivity testing was done with MAIA microperimeter

**Results:** The visual acuity of the affected eye at presentation, fellow eye and control eyes was  $0.79 \pm 0.08$ ,  $0.08 \pm 0.02$  and  $0.00 \pm 0.00$  respectively. The visual acuity of affected eye improved significantly to  $0.24 \pm 0.06$  ( $p < 0.001$ ) at 3 months. The mean sensitivity thresholds on MAIA at presentation were  $9.42 \pm 7.08$ ,  $20.12 \pm 7.34$  and  $28.94 \pm 1.89$  respectively of which affected and fellow eye showed a significant improvement to  $20.43 \pm 3.82$  ( $< 0.001$ ) and  $23.52 \pm 5.03$  ( $p: 0.034$ ) at 3 months. The mean sensitivity thresholds of 30-2 visual field test at presentation were  $-13.53 \pm 3.43$ ,  $-4.97 \pm 3.71$  and  $-2.65 \pm 0.20$  of which affected and fellow eye showed a significant improvement to  $-6.72 \pm 2.86$  ( $p < 0.001$ ) and  $-3.11 \pm 2.61$  ( $p = 0.002$ ) respectively at 3 months. The RNFL thickness at presentation was  $110.12 \pm 15.27$ ,  $95.68 \pm 6.12$  and  $98.66 \pm 2.28$  of which affected eye improved significantly to  $86.26 \pm 7.1$  ( $p < 0.001$ ) at 3 months. There was a significant correlation between BCVA and mean sensitivity ( $r = 0.798$ ), BCVA and RNFL thickness ( $r = -0.705$ ), mean sensitivity and RNFL thickness ( $r = -0.603$ ), mean sensitivity and 30-2 fields ( $r = 0.764$ ), RNFL thickness and 30-2 fields ( $r = -0.522$ ) at time of presentation. At 3 months follow up, significant correlation was present between BCVA and mean sensitivity ( $r = 0.697$ ), BCVA and RNFL thickness ( $r = 0.606$ ), mean sensitivity and RNFL thickness ( $r = 0.479$ ), mean sensitivity and 30-2 fields ( $r = 0.702$ ), RNFL thickness and 30-2 fields ( $r = 0.737$ ).

**Conclusion:** Microperimetry may be able to pick up subtle change in retinal sensitivity, specially in fellow eye of patients with optic neuritis. There is significant correlation between structural and functional parameters of retina in these patients as measured using microperimetry, OCT and visual fields.

## FP-102

**Optic coherence tomography angiography in patients with non-arteritic anterior ischemic optic neuropathy of different stages**

Q Xiao, H Bai, C Sun.

**Objective:** To observe the vessel density and structure of optic nerve in patients with non-arteritic anterior ischemic optic neuropathy of different stage by optic coherence Tomography angiography(OCTA).

**Methods:** A cohort study. Twenty-nine inpatients (29 eyes) identified as non-arteritic anterior ischemic optic neuropathy(NAION) in eye center of Second Affiliated Hospital, Zhejiang University School of Medicine from January 2020 to December2020were enrolled, including 29patients(29 eyes). General eye examination, visual field examination, and optical coherence tomography angiography were performed to obtain data of blood flow in the peripapillary area and structure such as mean defect(MD) ,radial peripapillary capillary(RPC)vessels density, peripapillary retinal nerve flayer(pRNFL),macular ganglion cell complex (GCC). All affected eyes were observed and compared at the acute stage ( $\leq 3$  weeks), sub-acute stage(4 to 12 weeks), and chronic stage (12 weeks to 6months,  $>6$  months) in line with the course of the disease.

**Results:** The average age was  $42.79 \pm 15.12$  years. There were 18males (62.1%) with a ratio of male/female 1.6/1 . Over the course of NAION follow-up,we didn't find any difference in mean defect( $F=0.277, P=0.842$ ), but we observed that there was significant difference between every two stages in whole image RPC vessels density( $F=8.939, P<0.001$ ) , intra disc( $F=1.079, P=0.363$ ),Prnfl( $F=47.122, P<0.001$ ),mean GCC( $F=14.954, P<0.001$ ).They reduced over the course of NAION. We also found the correlation between every two index including MD,RPC WI,pRNFL,mGCC,FLV,GLV( $P<0.001$ ).

**Conclusion:** Compared with each datas at different stage , the RPC superficial vessel density,pRNF,macular GCC in NAION patients decreased along with the course of the disease, and its correlation with structural and visual function is revealed. There is a great clinical significance to explore the pathogenesis, course and outcome of NAION by OCTA.

**FP-103****Clinical and Multi-Mode Imaging Features of Peripapillary Hyperreflective Ovoid Mass-Like Structures and optic disc drusen**T Liu.

**Objective:** To observe and analyze the clinical and multi-mode imaging features of eyes with PHOMS and optic disc drusen (odd)

**Methods:** Methods:

A retrospective analysis was conducted on 41 patients (57 eyes) were analyzed retrospectively. B-ultrasound, fundus autofluorescence (FAF), OCTA, and FFA enhanced depth imaging optical coherence tomography (edi-oct) images were analyzed and evaluated.

**Results:** We found the hyperreflective structures surrounded by hyporeflexive

edges around the optic discs in 37 eyes. EDI-OCT results revealed hyperreflective structures surrounded by hyporeflexive edges around the optic discs in all eyes. Typical hyperreflexia lesions occurred around the optic disc, located subretinally and above Bruch's membrane. OCTA revealed that the highly reflective perioptic material also had vascular structures. The results of FAF showed irregular spontaneous fluorescence areas. Local hyperechoic bulge was found in B-ultrasound examination. In OCT imaging examination, the retinal nerve fiber layer of odd patients was highly bulged. Different sizes of masses were seen on edi-oct. ODD With the development of multi-modal imaging, however, it appears that there are several features of PHOMS that are distinct from ODD, even though some symptoms

**Conclusion:** EDI-OCT of PHOMS showed hyperreflective structures surrounded by hyporeflexive edges around all of the optic discs. Infra-red photography showed temporal hyperreflexia. These characteristics can be seen in a variety of diseases and may be a relatively common feature revealed by EDI-OCT scanning. These characteristics may also be seen in elderly patients as well as children.

FP-104

**Transverse sinus stenting reverses medically refractory idiopathic intracranial hypertension**

K Reid<sup>1,2</sup>, H Winters<sup>3</sup>, T Ang<sup>3</sup>, G Parker<sup>3</sup>, G Halmagyi<sup>4,5</sup>.

<sup>1</sup>Ophthalmology, Canberra Hospital, <sup>2</sup>Medical School, Australian National University, Canberra, <sup>3</sup>Medical Imaging, <sup>4</sup>Neurology, Royal Prince Alfred Hospital, <sup>5</sup>Central Clinical School of Medicine, University of Sydney, Sydney, Australia

**Objective:** To characterise the ophthalmic indications for, and ophthalmic efficacy of, transverse sinus stenting in adults with medically refractory idiopathic intracranial hypertension (IIH).

**Methods:** A retrospective cohort study was undertaken on a single-author database of 226 successive patients with confirmed IIH. 32 patients were identified who received a transverse sinus stent for medically refractory disease, which was defined as visual threat and/or intolerance of maximal medical therapy. Patients with medically refractory disease were considered for stenting if found to have a significant transverse sinus stenosis gradient at catheter venography.

Visual threat was quantified via the degree of papilledema on optical coherence tomography of the retinal nerve fibre layer, and via the visual field mean deviation. CSF opening pressure at lumbar puncture and cerebral venous sinus pressure measurements from catheter venography were correlated with the ophthalmic data, noting also intolerance of maximal medical therapy. Complications of stenting were fully assessed.

**Results:** Medically refractory IIH was found in 18% of the total cohort of IIH patients. 90% of those with medically refractory disease had a significant transverse sinus stenosis pressure gradient, and 80% proceeded to stenting. The intervention eliminated papilledema in 96% of stented patients, and allowed 81% to cease acetazolamide. The need for a further procedure was low at 6%, and the safety profile was favourable.

**Conclusion:** Medically refractory disease in IIH is common (18%), and nearly always associated with a significant transverse sinus stenosis pressure gradient (90%). Endovascular stenting of the stenosis deserves wider uptake as a highly effective, safe and usually definitive treatment. It safeguards vision by eliminating papilledema (96%), and allows most patients to cease acetazolamide (81%). By analogy with glaucoma, if acetazolamide is the prostaglandin of IIH and CSF diversion the emergency glaucoma filter, stenting is the minimally invasive glaucoma surgery (MIGS).



FP-105

### Three-dimensional ophthalmic artery model reconstruction and assessment captured by computed tomographic angiography in non-arteri

J Wang, Y Wang.

**Objective:** The ophthalmic artery was first reconstructed using computer software. The structural differences of ophthalmic arteries in non-arteritic anterior ischemic optic neuropathy and normal eyes, in addition to hemodynamic alterations, were assessed.

**Methods:** Thirty-one non-arteritic anterior ischemic optic neuropathy eyes, 19 uninvolved eyes with non-arteritic anterior ischemic optic neuropathy, and a control group of 26 healthy eyes were retrospectively included. Computed tomographic angiography data were recorded, and corresponding three-dimensional ophthalmic artery models were constructed. Initial ophthalmic artery and internal carotid artery diameters and the angle between them were analyzed. Three different ophthalmic artery models were used to evaluate hemodynamic performance. The statistical relationships between the initial diameters of the ophthalmic artery and internal carotid artery and the angle between the ophthalmic artery and internal carotid artery were described.

**Results:** Ophthalmic artery diameters in non-arteritic anterior ischemic optic neuropathy eyes were significantly smaller than those in both uninvolved and healthy eyes ( $P < 0.05$ ). There was no significant difference between uninvolved and healthy eyes ( $P = 0.31$ ). The initial internal carotid artery diameter and the angle between the ophthalmic artery and internal carotid artery did not significantly differ among the three groups. In the three models, the blood flow velocity in the initial ophthalmic arteries of uninvolved eyes was higher than that in the non-arteritic anterior ischemic optic neuropathy eyes. The mass flows of the right and left ophthalmic arteries, accounting for the ipsilateral internal carotid artery in the control model, were 0.57%. However, these values in uninvolved and non-arteritic anterior ischemic optic neuropathy eyes were 1.36% and 0.25%, respectively.

**Conclusion:** Non-arteritic anterior ischemic optic neuropathy is associated with a smaller initial ophthalmic artery diameter, which may be related to hypoperfusion. To our knowledge, this is the first pilot study to analyze hemodynamic alterations using ophthalmic artery models.

FP-106

**Temporal Artery Biopsies at Sydney Eye Hospital – an 11-year review**R Malik<sup>123</sup>, A Sammel<sup>456</sup>, C Fraser<sup>67</sup>.

<sup>1</sup>Port Macquarie Base Hospital, Port Macquarie, <sup>2</sup>The University of Newcastle, Newcastle, <sup>3</sup>The University of New South Wales, Port Macquarie, <sup>4</sup>The University of New South Wales, Sydney, <sup>5</sup>Prince of Wales Hospital, Randwick, <sup>6</sup>Sydney Eye Hospital, <sup>7</sup>The University of Sydney, Sydney, Australia

**Objective:** To evaluate Sydney Eye Hospital temporal artery biopsy length and timing to biopsy from commencement of steroids through a clinical audit over an 11-year period.

**Methods:** A retrospective review of 263 temporal artery biopsies at Sydney Eye Hospital between 1<sup>st</sup> January 2010 to 31<sup>st</sup> December 2020.

**Results:** Biopsy positive rate at Sydney Eye hospital was 27% (total of 71 cases), with a mean age of 73 years and 65% female gender distribution. Mean length of biopsy was 17.35mm, with 35% being greater than 20mm, while 64% were greater than 15mm and 89% were greater than 10mms in length. The mean length of stay in hospital was 4.14 days.

Out of 71 biopsy positive cases, the majority 83.10% were arranged within 7 days after commencing steroid treatment. The mean time to biopsy was 3.76 days and 69% of biopsy positive cases required admission to hospital. General Ophthalmology on call consultants were the most common admitting medical officer (41%) followed by Oculoplastics (19%) and then General Medicine (13%). Intravenous methylprednisolone (IVMP) treatment was given to 78% of biopsy positive cases that presented with visual symptoms. Majority 72.10% received a daily dose of 1000mg IVMP and 23.26% received 500mg IVMP daily. From presentation to first follow up clinic of biopsy positive cases, 33% showed visual improvement, 25% showed deterioration and 42% had stable visual acuity. Within biopsy positive cases, the mean ESR was 55.06 and mean CRP was 63.78. In our clinical practice, there was a limited use of FFA in only 5.63% of biopsy positive cases and a limited role of PET scan at Sydney Eye Hospital given the feasibility of timely temporal artery biopsy operations.

**Conclusion:** Sydney Eye Hospital temporal artery biopsies are of good length and are completed in a time effective manner with highly satisfactory mean timing to biopsy from commencement of steroid treatment. Majority of cases are getting the minimum 10mm biopsy length required. There is the potential to expand the role of FFA in the giant cell arteritis diagnostic algorithm at Sydney Eye Hospital.

FP-107

**Photoreceptor abnormalities In Glaucomatous And Non-Glaucomatous Optic Neuropathy**R Dhiman, V Gupta<sup>1</sup>, S Phuljhele<sup>1</sup>, R Saxena<sup>1</sup>.<sup>1</sup>*Ophthalmology, Dr. RP Centre for Ophthalmic Sciences, New Delhi, India*

**Objective:** Involvement of retinal ganglionic cell is well established in optic neuropathies, but that of photoreceptor layer is debatable. The aim of this cross sectional study is to examine the cone mosaic characteristics in optic neuropathies using adaptive optics (AO) and compare with age-matched controls.

**Methods:** In this cross sectional study, patients aged 20-40 years with glaucomatous and non-glaucomatous optic neuropathies with 6/9 or better vision and with no central visual field defects were recruited. Controls were age and refractive error matched healthy controls. Apart from anterior and posterior segment evaluation, colour vision, contrast sensitivity, visual field, OCT for RNFL and GC-IPL and AO retinal imaging for cone mosaic characteristics using rtx1 retinal camera (Imagine Eyes; Paris, France) was done.

**Results:** This is an ongoing study. Sixteen eyes of 16 patients (8 glaucomatous and 8 non-glaucomatous optic neuropathy) are enrolled till date. Preliminary results show significantly lesser cone mosaic density ( $P=0.001$ ) and cone regularity ( $P=0.004$ ), significantly increased cone spacing ( $P=0.016$ ) and dispersion ( $P=0.011$ ) and significantly reduced NN6 % ( $P=0.006$ ) in optic neuropathies compared to the age-matched controls at 2° , 4° and 6° . 4° and 6° degrees nasal (i.e area adjacent to the disc) were the most affected especially in non-glaucomatous optic neuropathy.

**Conclusion:** This confirms the presence of cone photoreceptor damage along with inner retinal changes in optic neuropathies.

**FP-108****Glial antibodies prevalence in late-onset optic neuritis and clinical predictive factors for diagnosis: a Chinese cohort study**

H Song, S Wei.

**Objective:** Different glial-antibody-mediated optic neuritis (ON) are associated with different clinical features and prognosis that require different treatments. Because glial antibody detection is not available in some parts of the world and there are often delays in obtaining results, there is a need for clinical factors that can be used to predict late-onset ON subtypes.

**Methods:** This was a single-center retrospective cohort study. Late-onset ON patients who presented with their first ON attack and for whom clinical data were available were included in the analysis. Single and multiple parameters for predicting late-onset myelin oligodendrocyte glycoprotein immunoglobulin-associated ON (MOG-ON) and aquaporin-4 immunoglobulin-related ON (AQP4-ON) were calculated.

**Results:** From January 2016 to January 2020, 83 patients with late-onset ON had their first ON attack, of whom 81 were included in the final analysis, including 32 AQP4-ON cases, 19 MOG-ON cases and 30 Seronegative-ON cases. For predicting late-onset MOG-ON, the most sensitive predictors were 'follow-up VA  $\leq 0.1$  log MAR' (sensitivity 0.89 (95% CI 0.65 to 0.98)), 'bilateral or follow-up VA  $\leq 0.1$  log MAR' (sensitivity 0.95 (95% CI 0.72 to 1.00)), 'bilateral or without neurological history' (sensitivity 1.00 (95% CI 0.79 to 1.00)) and 'follow-up VA  $\leq 0.1$  log MAR or without neurological history' (sensitivity 1.00 (95% CI 0.79 to 1.00)), and the most specific factor was 'bilateral involvement' (specificity 0.81 (95% CI 0.68 to 0.89)). For predicting late-onset AQP4-ON, the most sensitive predictor was 'unilateral involvement' (sensitivity 0.88 (95% CI 0.70 to 0.96)), 'unilateral or neurological history' (sensitivity 0.91 (95% CI 0.74 to 0.98)), and 'unilateral or other autoimmune antibodies' (sensitivity 1.00 (95% CI 0.87 to 1.00)), and the most specific factors were neurological history (specificity 0.98 (95% CI 0.88 to 1.00)).

**Conclusion:** According to our late-onset ON cohort study, the use of multiple parameters improves the sensitivity and specificity of diagnosing late-onset MOG-ON and AQP4-ON. These can help clinicians diagnose and treat late-onset ON when glial autoantibody status is not available.

FP-109

## Artificial Intelligence Detects Macular Microvascular Changes in Cerebral Small Vessel Disease

H Miao<sup>1,2</sup>, H Ye<sup>1,2</sup>, W Robert Kwapong<sup>3</sup>, N Zeng<sup>1,2</sup>, Z Zhang<sup>3</sup>, X Wang<sup>1,2</sup>, R Jin<sup>1,2</sup>, H Jiang<sup>1,2</sup>, J Fang<sup>1,2</sup>, S Zhang<sup>3</sup>, J Liu<sup>1,2</sup>.

<sup>1</sup>Research Institute of Trustworthy Autonomous Systems, <sup>2</sup>Department of Computer Science and Engineering, Southern University of Science and Technology, Shenzhen, <sup>3</sup>Department of Neurology, West China Hospital, Sichuan University, Chengdu, People's Republic of China

**Objective:** The retinal microvasculature allows direct visualization of cerebral microcirculation. Because the retina shares similar anatomical, embryological, and physiological features with the cerebral microvasculature, the retinal vessels offer a unique and easily accessible window to study and understand the cerebral microvasculature. Advanced retinal vascular imaging technologies have been developed to allow a more comprehensive, objective, and precise assessment of the retinal microvascular changes. Using machine learning (ML) and deep learning (DL) we aimed to assess the macula microvascular changes in cerebral small vessel disease (CSVD) compared to healthy controls (HC).

**Methods:** In this research, 51 (93 eyes) HC and 53 (88 eyes) CSVD patients were included. Swept-source optical coherence tomography angiography (SS-OCTA) was used to image and segment the retinal microvasculature into the superficial vascular complex (SVC) and deep vascular complex (DVC). Unet model was used to extract and quantitatively measure the microvasculature using different parameters. The extracted parameters included the vascular area density (VAD), vascular fractal dimension (VFD), vascular length density (VLD), vascular bifurcation number (VBN), vascular mean diameter (VMD), and vascular tortuosity (VT) in superficial vascular capillary (SVC) and deep vascular capillary (DVC). Generalized estimating equations (GEE) were used to analyze the changes in retina microvascular between CSVD patients and HC. And depending on the multiple microvascular parameters, the patients had to be classified by ML and DL models.

**Results:** In addition to the increase of VT, other DVC parameters of CSVD patients were significantly lower than those of HC (all  $P < 0.05$ ). In general ML classification models (Leave-One-Out Cross Validation), the decision tree model present good classification performance on the all DVC parameters (F1 = 0.684, precision = 0.699, recall = 0.741, accuracy = 0.697). And in multi-Layer perceptron (MLP) models, the two-layer MLP (5-fold cross validation) showed better performance on all DVC parameters (F1 = 0.765, precision = 0.654, recall = 0.929, accuracy = 0.730).

**Conclusion:** ML and DL have the potential to quantitatively characterize macular microvascular changes in CSVD. Changes in the DVC could be an early pointer for microvascular impairment in CSVD.

**FP-110****Early detection of retinal microvascular and structural impairments in multiple sclerosis before optic neuritis**

Y Gao, M Zhang.

**Objective:**

To investigate the retinal structural and microvascular changes in Multiple Sclerosis (MS) participants without Optic Neuritis (ON) and other visual impairment with Swept-Source optical coherence tomography (SS-OCT) and angiography (SS-OCTA).

**Methods:** A total of 34 MS participants (64 eyes) and 48 healthy controls (96 eyes) were included in this cross-sectional study. All the MS and healthy control participants were obtained the baseline information and underwent standard ophthalmic examination, SS-OCT, and SS-OCTA examination. SS-OCT and SS-OCTA were performed centered on both the macula and the optic disc, within the 6mm × 6mm area. The Early treatment diabetic retinopathy study (ETDRS) rings were used to quantify the thickness of peripapillary retinal nerve fiber layer (pRNFL), ganglion cell-inner plexiform Layer (GCIPL), inner nuclear layer (INL) and outer retina. The ETDRS rings were also used for measuring the vessel density (VD), including superficial vascular complex (SVC), superficial vascular plexus (SVP), intermediate capillary plexus (ICP), deep capillary plexus (DCP) centered on the macula and the VD of radial peripapillary capillaries (RPCP) centered on the optic disc. The potential associations between the abnormal SS-OCT, SS-OCTA parameters and the Expanded Disability Status Scale (EDSS) score were detected in the MS group. The SPSS was used for statistical analysis and p-value less than 0.05 was considered statistically significant throughout the study.

**Results:** Compared with healthy controls, the MS participants had significantly thinner pRNFL ( $p=0.001$ ), GCIPL ( $p<0.001$ ) and nasal INL ( $p=0.022$ ). The VD decreased significantly in SVP ( $p=0.047$ ) and RPCP ( $p=0.006$ ), and increased in ICP ( $p=0.045$ ) and DCP ( $p<0.001$ ). Meanwhile, in MS groups, positive correlations were found between the average thickness of pRNFL and the average VD of RPCP ( $r=0.747$ ,  $p<0.001$ ) and between the average thickness of GCIPL and the average VD of macular SVC ( $r=0.644$ ,  $p<0.001$ ). A negative correlation was found between the thickness of the superior part of GCIPL and EDSS score ( $r=-0.355$ ,  $p=0.007$ ), also between the superior part of SVP in the macula and EDSS score ( $r=-0.282$ ,  $p=0.032$ ).

**Conclusion:** This study indicated that in MS patients without ON and other visual impairment, there have already been some changes in both retinal structure and microcirculation. SS-OCT and SS-OCTA could help in the early evaluation.

## FP-111

**Ocular Factors of Fractal Dimension and Blood Vessel Tortuosity Derived From OCTA in a Healthy Chinese Population**

Y Song<sup>1</sup>, W Cheng<sup>1</sup>, F Lin<sup>1</sup>, P Wang<sup>1</sup>, W Wang<sup>1</sup>, X Zhang<sup>1</sup>.

<sup>1</sup>Zhongshan Ophthalmic Center, Guangzhou, People's Republic of China

**Objective:** To identify the ocular factors of microvascular fractal dimension (FD) and blood vessel tortuosity (BVT) of macula measured with optical coherence tomography angiography (OCTA) in a healthy Chinese population.

**Methods:** Healthy subjects without ocular disorders were recruited at Zhongshan Ophthalmic Center. The FD and BVT in the superficial capillary plexus (SCP) and deep capillary plexus (DCP) at the macula were obtained from OCTA images. The FD was calculated using the box-counting method, and the BVT was defined as the ratio of the actual distance between two points to the straight distance on the skeletonized image. Univariate and stepwise multivariate linear regression analyses were performed to identify the ocular factors of FD and BVT, and the results are presented as coefficients and 95% confidence intervals (CIs). Only the right eye of each subject was included.

**Results:** A total of 2189 healthy individuals (2189 eyes) were included with a mean age of  $49.9 \pm 13.2$  years; 54.4% were female. In the multivariate model, the FD in the SCP was significantly associated with higher intraocular pressure (IOP) ( $\beta = 0.204$ ; 95% CI, 0.073–0.335;  $P < 0.001$ ), axial length (AL) ( $\beta = -0.875$ ; 95% CI,  $-1.197$  to  $-0.552$ ;  $P < 0.001$ ;  $R^2 = 0.26$ ; root mean square error [RMSE] = 7.78). The FD in the DCP was significantly associated with best-corrected visual acuity ( $\beta = -6.170$ ; 95% CI,  $-10.175$  to  $-2.166$ ;  $P = 0.003$ ) and anterior chamber depth ( $\beta = -0.348$ ; 95% CI,  $-0.673$  to  $-0.023$ ;  $P = 0.036$ ;  $R^2 = 0.10$ ; RMSE = 2.58). Superficial BVT was independently associated with IOP ( $\beta = -0.044$ ; 95% CI,  $-0.079$  to  $-0.009$ ;  $P = 0.012$ ) and AL ( $\beta = 0.097$ ; 95% CI, 0.014–0.181;  $P = 0.022$ ;  $R^2 = 0.15$ ; RMSE = 2.02). Deep BVT was independently associated with IOP ( $\beta = -0.004$ ; 95% CI,  $-0.009$  to  $-0.0005$ ;  $P = 0.028$ ) and lens thickness ( $\beta = 0.036$ , 95% CI, 0.003–0.060;  $P = 0.028$ ;  $R^2 = 0.07$ , RMSE = 0.25).

**Conclusion:** The IOP and AL were dependent ocular parameters variables of FD and BVT in the SCP in this healthy population. The FD in the DCP was also influenced by visual acuity and anterior chamber depth. These factors should be considered when microvascular geometrics are used in the future studies.

FP-112

### Axial Length, Optic Disc Tilt and Rotation Effects on Peripapillary Retinal Nerve Fiber Layer Thickness Measurements in Myopic Eye

A Tellioglu, I Çakır<sup>1</sup>, G Yalçinkaya<sup>1</sup>, A Altan<sup>1</sup>.

<sup>1</sup>Beyoglu Eye Training and Research Hospital, Istanbul, Türkiye

**Objective:** To determine the presence of tilted optic disc, optic disc rotation degree, and their effects on the angular location of peak thickness of the superotemporal and inferotemporal retinal nerve fiber layer (RNFL) bumps in healthy myopic individuals.

**Methods:** Non-glaucomatous healthy myopic eyes with an axial length (AL)>24mm were enrolled. The ImageJ quantified the optic disc tilt and torsion on red-free fundus photography. The RNFL was scanned using a spectral domain-optical coherence tomography. The angle of the superotemporal and inferotemporal peaks with the vertical-horizontal meridian was measured with the ImageJ

**Results:** Fifty-four eyes of 54 patients were evaluated. The AL was correlated with the angular location of peak thickness for both the superotemporal ( $r=-0.549$ ,  $p<0.001$ ) and inferotemporal ( $r=-0.415$ ,  $p=0.002$ ) RNFL bumps; they were placed more temporally in eyes with higher ALs. For each 1 mm increase in AL, the angle between the superotemporal peak and the temporal horizontal meridian decreased by  $3.976^\circ$ , and the angle between the inferotemporal apex and the temporal horizontal meridian by  $3.028^\circ$ . The angle between the superotemporal peak and the temporal horizontal meridian decreased by  $0.231^\circ$  for each  $1^\circ$  increase in optical disc torsional degree ( $R^2=0.09$  Regression coefficient= $-0.231$ ,  $p=0.027$ ).

**Conclusion:** Temporal shift of superior and inferior peaks, thickening of temporal and nasal RNFL, presence of tilted optic disc, and optic disc rotation may cause misinterpretation of RNFL in myopic patients. When assessing peripapillary RNFL thickness in myopic individuals, it would be better to consider the degree of optic disc tilt and rotation.



FP-113

**Choroidal arterial watershed zone topography and its relationship with maculopathy in highly myopic eyes**J Sun, J Wang<sup>1</sup>, Y Wang<sup>1</sup>.<sup>1</sup>Beijing Friendship Hospital, Beijing, People's Republic of China

**Objective:** To evaluate choroidal arterial watershed zones (CWZ) in highly myopic patients. The relationships between CWZ location and myopic maculopathy location and classification were also examined.

**Methods:** This retrospective study included 102 consecutive patients who had been diagnosed with myopic maculopathy. Indocyanine green videoangiography was used to evaluate CWZ presence, location, and configuration. Maculopathy signs were used to examine the relationship between CWZ and myopic maculopathy.

**Results:** Various CWZ types were identified in 102 of 158 eyes. The CWZ patterns were classified as vertical optic nerve head (vertical-ONH) in 30 eyes, stellate in 29 eyes, vertical-ONH extending to the macula in 28 eyes, horizontal fovea in eight eyes, and vertical parafovea in seven eyes. Choroidal neovascularization occurred within CWZs in 35 of 42 eyes, and macular atrophy was located within foveal CWZs in 20 of 23 eyes. The CWZ type was significantly correlated with mCNV presence (OR = 5.652, P = 0.014).

**Conclusion:** Variations in CWZ topography are associated with myopic maculopathy, particularly in eyes with myopic choroidal neovascularization (mCNV) and macular atrophy, and CWZ is a risk factor for mCNV. This suggests that eyes with macular CWZs are vulnerable to developing myopic maculopathy and are predisposed to mCNV because of ischaemic hypoxia.

FP-114

## Semiautomated and Automated Quantitative Analysis of Corneal Sub-Basal Nerves in Patients With DED With Ocular Pain Using IVCM

Y Zhang.

**Objective:** Investigate the correlation and agreement between the results of semiautomated and fully automated quantitative analysis of the corneal sub-basal nerve plexus (SNP) in patients with dry eye disease (DED) with ocular pain using in vivo confocal microscopy (IVCM).

**Methods:** A total of 50 voluntary participants were enrolled in this study, i.e., 25 DED patients with ocular pain and 25 healthy controls. Each patient underwent an evaluation of ocular symptoms that utilized: the Ocular Surface Disease Index (OSDI), the Ocular Pain Assessment Survey (OPAS), the tear film breakup time (TBUT) test, the Schirmer test, corneal staining, and IVCM. Five SNP images of the cornea of each eye were selected and analyzed using a semiautomated analysis software (NeuronJ) and a fully automated method (ACCMetrics) to quantify corneal nerve fiber density (CNFD), corneal nerve branch density (CNBD), and corneal nerve fiber length (CNFL).

**Results:** The intraclass correlation coefficient (ICC) of the CNFD (0.460 [0.382–0.532],  $p < 0.001$ ), CNBD (0.608 [0.545–0.665],  $p < 0.001$ ), and CNFL (0.851 [0.822–0.875],  $p < 0.001$ ) represents the repeatability and consistency of measurements by the NeuronJ and ACCMetrics software. The CNFL values ( $r = 0.881$ ,  $p < 0.001$ ) obtained using the two methods have extremely high correlation, and similarly, the CNFD values ( $r = 0.669$ ,  $p < 0.001$ ) and CNBD values ( $r = 0.703$ ,  $p < 0.001$ ) are highly correlated. The CNFL had the biggest area under the curve (AUC; 0.747 [0.700–0.793],  $p < 0.001$ ) when using ACCMetrics. In DED patients with ocular pain, the mean CNFD values for semiautomated and fully automated quantization were  $23.5 \pm 8.1$  and  $23.8 \pm 8.6$  n/mm<sup>2</sup>; the mean CNBD values were  $46.0 \pm 21.3$ ,  $35.7 \pm 23.3$  n/mm<sup>2</sup>; and the mean CNFL values were  $19.3 \pm 4.3$  and  $15.2 \pm 3.8$  mm/mm<sup>2</sup>, which were significantly lower than healthy subjects ( $p < 0.001$ ).

**Conclusion:** There is a significant correlation between the measurements obtained via ACCMetrics and NeuronJ, especially for CNFL, which can be considered as the primary indicator in the diagnosis of DED with ocular pain. The SNP of the disease was significantly lower than that of healthy subjects.

FP-115

## Association of the Choriocapillaris Microcirculation with Cognitive Function in Diabetes: A Swept-source OCTA Study

W Wang, W Huang.

**Objective:** To investigate the association of choriocapillaris blood perfusion with cognitive function in type 2 diabetes without retinopathy using non-invasive optical coherence tomographic angiography (OCTA).

**Methods:** This cross-sectional study recruited diabetic participants from the diabetes registry in the community of Guangzhou, China. The ETDRS-7 retinal photography was performed to confirm the non signs of retinopathy. The choriocapillaris perfusion index (CPI) was quantified by using angiograms from swept-source (SS) OCTA imaging. The validated structured questionnaires and tests with a word recall test, Telephone Interview of Cognitive Status (TICS-10), and a pentagon drawing test were used to evaluate the cognitive function. Only the data of the right eyes were used for analysis.

**Results:** A total of 2095 participants were included in the final analysis, involving 1418 examined by  $3 \times 3 \text{ mm}^2$  scanning and 565 examined by  $6 \times 6 \text{ mm}^2$  scanning. The mean age of the eligible participants was  $64.2 \pm 7.7$  years old, and 57.33% were female. The measurements of CPI was significantly greater in the participants with the 2nd and 3rd tertile of cognition function score in comparisons with those in the 1st tertile in both  $3 \times 3$  and  $6 \times 6 \text{ mm}^2$  images ( $p < 0.05$ ). After a full adjustment for age, gender, and other confounders, CPI presented a significant positive association with cognitive scores, with coefficient of 0.680 [95%CI, 0.486-0.874,  $P < 0.001$ ] for 1-standard deviation (SD) increase in  $3 \times 3 \text{ mm}^2$  whole image, and Coef.: 1.284 [95%CI, 0.781-1.786,  $P < 0.001$ ] for 1-SD increase in  $6 \times 6 \text{ mm}^2$ .

**Conclusion:** Decreased choriocapillaris blood perfusion is associated with an increased risk of declined cognitive function, suggesting that choroidal vascular alteration detected by SS-OCTA may serve as a novel biomarker for preclinical cognitive impairment.

FP-116

**Spectrum of germline mutations in RB1 in Chinese patients with retinoblastoma: Application of targeted next-generation sequencing**Y Zou<sup>1</sup>, X Ji<sup>1</sup>, P Zhao<sup>1</sup>.<sup>1</sup>Xinhua Hospital Affiliated to Shanghai Jiao Tong University School of Medicine, Shanghai, People's Republic of China

**Objective:** Retinoblastoma (RB) is a pediatric ocular malignancy due to biallelic inactivation of the *RB1* gene. Genetic testing is critically important for treatment decisions for this disease. Targeted next-generation sequencing (NGS) has been demonstrated to be an effective strategy for discovering all types of mutations in the *RB1* gene. The aim of this study is the application of targeted NGS in a cohort of Chinese patients with retinoblastoma to identify germline mutations in the *RB1* gene.

**Methods:** Blood samples were collected from 149 unrelated probands with retinoblastoma (62 bilaterally and 87 unilaterally) and their parent(s). Genomic DNA was analyzed with custom panel-based targeted NGS, and the panel was designed to include exons 1-27 of the *RB1* gene with flanking intronic sequences. Single nucleotide variations (SNVs) and small insertions/deletions (InDels) identified were confirmed with Sanger sequencing. If the Sanger sequencing of a low-frequency variant (LFV) detected with targeted NGS was negative, PCR-based deep NGS was conducted for added confirmation. Copy number variations (CNVs) detected with targeted NGS were confirmed with multiplex ligation-dependent probe amplification (MLPA).

**Results:** Overall, 74 germline mutations were detected in 48.3% of the probands (72/149, 56 bilateral and 16 unilateral cases). The total detection rate in the bilateral cases was 90.3% (56/62). These mutations included 64 SNVs and InDels (25 nonsense, 20 splicing, ten frameshift, eight missense, and one synonymous variants) and ten CNVs. All CNVs were confirmed with MLPA. Twenty-four (32.4%, 24/74) variants detected were novel, including nine splicing, six frameshift, five missense, and four nonsense variants. Eight LFVs (10.8%, 8/74) were found with targeted NGS; six of which were identified with Sanger sequencing, and two were identified with PCR-based deep NGS (13.16% and 3.000% mutant rates, respectively).

**Conclusion:** This study expanded the spectrum of germline mutations in *RB1* using targeted NGS technology, which is a cost-saving and efficient method for genetic sequencing of retinoblastoma and may improve the molecular diagnosis of retinoblastoma.

FP-117

## Clinical Characteristics, Prognosis and Risk Factors of Distant Metastasis for Uveal Melanoma in a Chinese Population

L Zhang<sup>1</sup>, A Zhuang<sup>1</sup>, H Pan<sup>1</sup>, S Jia<sup>1</sup>, X Jin<sup>1</sup>, X Xu<sup>1</sup>, L Lu<sup>1</sup>, Z Wang<sup>1</sup>, R Jia<sup>1</sup>, X Fan<sup>1</sup>.

<sup>1</sup>Department of Ophthalmology, Shanghai Ninth People's Hospital, Shanghai, People's Republic of China

**Objective:** To determine the clinical and pathological characteristics of uveal melanoma (UM) in a Chinese population, analyze the metastasis rate and disease-related mortality, and identify the risk factors of poor prognosis.

**Methods:** This is a retrospective cohort study. 82 consecutive patients with UM from 2012 to 2021 in Shanghai Ninth People's Hospital were retrospectively reviewed. All eligible clinical and pathological records were collected and analyzed. Moreover, immunohistochemical staining of BAP1 and EZH2 were conducted to correlate with prognosis. Disease-related and metastasis free survival were evaluated by Kaplan–Meier analysis. Univariate and multivariate Cox proportional hazard regressions were employed to predict the risk factors of distant metastasis in UM.

**Results:** The study consisted of 50 (61.0%) males and 32 (39%) females, with a mean age of  $54.0 \pm 12.8$  years. The mean largest basal diameter and thickness of tumor were  $12.5 \pm 4.0$  mm and  $7.5 \pm 3.1$  mm respectively. Tumors of AJCC stage II (52.4%) claimed the major proportion of the cohort, followed by stage III (29.3%). Ciliary body involvement, monosomy 3 and 8q gain were observed in 24.4%, 40.4% and 24.1% of the patients respectively. The spindle cell-type was observed in 39 (53.4%) tumors while the epithelioid and the mixed each presented in 17 (23.3%). The median follow-up time was 26.3 months (range 5.4–84.9 months, mean  $30.8 \pm 17.9$  months). Disease-related mortality at 2 and 5 years were 8.1% and 26.2%, and metastasis-free survivals at 2 and 5 years were 89.8% and 71.5%, respectively. Multivariate Cox regression revealed that larger basal tumor diameters, 8q gain, the epithelioid cell-type, immunohistochemical BAP1 loss and EZH2 overexpression were significantly associated with distant metastasis in UM. Intriguingly, patients with both BAP1 loss and EZH2 overexpression ( $p=0.002$ , HR: 21.807, 95% CI: 3.163–150.343) seem to be at higher risk of distant metastasis than those only with BAP1 ( $p=0.045$ , HR: 4.342, 95% CI: 1.035–18.212) or EZH2 ( $p=0.014$ , HR: 5.918, 95% CI: 1.442–24.284) aberration.

**Conclusion:** Larger basal tumor diameters, 8q gain, epithelioid cell-type, immunohistochemical BAP1 loss and EZH2 overexpression presented as risk factors of distant metastasis in UM. Patients with concurrence of both BAP1 loss and EZH2 overexpression should be paid more attention for higher risk of distant metastasis in UM.

**FP-118****vitreoretinal lymphoma in young adults**

Q Chang<sup>1†</sup>.

<sup>1</sup>Eye & ENT Hospital of Fudan University, Shanghai , People's Republic of China

**Objective:** To investigate the clinical features, diagnostic approaches, and outcomes of young patients with vitreoretinal lymphoma (VRL)

**Methods:** The clinical data of 51 patients (97 eyes) with VRL from 2011 to 2020 was analyzed. These patients were divided into two groups based on their age at VRL onset (group age $\leq$ 50 and group age $>$ 50).

**Results:** Young patients represented 31.4% (n=16) of all VRL patients in this cohort. Young patients less complained about the painless loss of vision than the elderly group (p=0.015). As to ocular findings, more eyes had retinal/sub-RPE infiltration(p=0.018) and fewer eye presented with the isolated vitritis (p=0.011) was observed in the young group. The *MYD88* mutation rate was 50% of young patients which was significantly lower than that of elderly patients (91.3%, p=0.016). Moreover, the median time to central nervous system (CNS) lymphoma was significantly shorter in young patients (11.7 months, p=0.012).

**Conclusion:** Early diagnosis and CNS evaluation are crucial for young VRL patients as rapid CNS involvement from ocular symptoms presenting. While early-onset VRL(age $\leq$ 50) patients have some unique features like more retinal/sub-RPE infiltration and lower *MYD88*mutation rates.

FP-119

### A Novel and Easy-to-Promote Prognostic Model for Patients with Uveal Melanoma

H Yue, B Xu<sup>1</sup>, J Gao<sup>2</sup>, Y Bi<sup>3</sup>, K Xue<sup>1</sup>, J Qian<sup>1</sup>.

<sup>1</sup>Ophthalmology, Eye & ENT Hospital of Fudan University, <sup>2</sup>Shanghai Eye & ENT Hospital of Fudan University Key Laboratory of Visual Impairment and Restoration, <sup>3</sup>Pathology, Eye & ENT Hospital of Fudan University, Shanghai, People's Republic of China

**Objective:** To establish an easy and widely applicable prognostic prediction model for uveal melanoma (UM) based on a Chinese population.

**Methods:** A total of 295 consecutive cases treated at the Eye & ENT Hospital of Fudan University were included as the primary cohort, and 256 cases were included in the validation cohorts from the TCGA and SEER databases. Clinicopathological data were collected retrospectively, and nomogram models were formulated based on multivariable analysis. The C-index, AUC (area under the ROC curve), and Brier score were calculated and compared.

**Results:** Based on the training cohort, a nomogram model was established with five relevant variables: age, tumor size, ciliary body involvement, non-spindle cell type and extra-scleral extension. The C-index was 0.737, the 3- and 5-year AUCs were 0.767 and 0.742, and the Brier scores for 3- and 5-year survival were 0.082 and 0.129, respectively, which showed superior prediction compared to that of the TNM staging system. The model also displayed good discrimination and calibration in the external validation cohorts. By risk stratification, patients could be divided into low- and high-risk groups, and the overall survival curves displayed significant differences in the training and validation cohorts.

**Conclusion:** Our nomogram model was simple and accurate at predicting the overall survival of patients with UM. It was established based on Asian patients and proved suitable for Caucasian patients; thus, it has a wide range of potential applications, especially for patients living in less medically developed countries and regions.

**FP-120****Salvage intra-arterial chemotherapy for recurrent or persistent intraocular retinoblastoma**R Verma, S Kaliki, B adewara.

**Objective:** To analyse the outcomes of salvage intra-arterial chemotherapy (IAC) for recurrent or persistent retinoblastoma (RB).

**Methods:** Retrospective analysis of 24 eyes of 23 patients who underwent salvage IAC

**Results:** The mean age at the time of salvage IAC was 41 months (median, 36 months; range, 14 to 86 months). All patients (n=23) received intravenous chemotherapy (IVC) as primary treatment. The mean number of IVC cycles prior to salvage IAC were 10 (median, 12; range, 6 to 18). The indications for salvage IAC were tumor recurrence (n=17; 71%) and persistent tumor (n=7; 29%) post-IVC. The mean number of salvage IAC cycles were 3 (median, 3; range, 1 to 6). Of 24 eyes, 17 eyes (71%) achieved tumor regression with salvage IAC, while 7 (29%) eyes displayed poor response. Of these 17 eyes with initial tumor regression, 9 (38%) eyes sustained good response while 8 (33%) eyes displayed tumor recurrence over a mean follow-up period of 21 months (median, 21 months; range, 6 to 44 months). Mean interval between IAC and tumor recurrence (n=8) was 4 months (median, 3 months; range, 1 to 14 months). Of these 8 eyes, globe salvage was achieved in 5 (21%) eyes with additional alternate treatment. Of the 7 eyes with poor response to IAC, globe salvage was achieved in one (4%) eye with additional alternate treatment. Overall, globe salvage was achieved in 15 eyes (63%).

**Conclusion:** Salvage IAC is an effective treatment modality for recurrent and persistent RB enabling globe salvage in 63% cases.



FP-121

**Analysis of clinical features of MALT lymphoma of ocular adnexal And the early postoperative effect evaluation of PET/CT**X Zhang<sup>1</sup>, J Ma<sup>2</sup>.

<sup>1</sup>The Affiliated Taian City Central Hospital of Qingdao University, Tai'an, <sup>2</sup>Beijing Tongren Hospital, Capital Medical University, Beijing, People's Republic of China

**Objective:** The clinical characteristics of 21 cases of ocular adnexal MALT lymphoma and the evaluation of the early postoperative effects of PET/CT examination were retrospectively analyzed.

**Methods:** Methods: Gender, age, eye type, ocular symptoms, involved site, immunohistochemical KI-67 results, initial recurrence, postoperative PET/CT results and SUVmax values, postoperative treatment and prognosis of 21 patients with ocular adnexal MALT lymphoma confirmed by pathological examination from October 2017 to September 2021 were collected.

**Results:** Among the 21 patients, 5 were treated with surgery, 13 with surgery plus radiotherapy, 3 with surgery plus chemotherapy. 2 patients with positive PET/CT results were combined with chemotherapy after surgery. Twenty-one patients were followed up for 4-50 months, and no recurrence was found. The survival rate was 100%.

**Conclusion:** Early postoperative PET/CT examination can guide the treatment, surgical resection of the tumor, combined with radiotherapy and chemotherapy can achieve better results. MALT lymphoma can be localized for a long time, with a generally good prognosis and a low incidence of systemic metastasis.

FP-122

**Smartphone ophthalmoscope as a tool in teaching direct ophthalmoscopy: a crossover randomized controlled trial**

H Wang, X Liao<sup>1</sup>, M Zhang<sup>1</sup>, C Pang<sup>2</sup>, H Chen<sup>1</sup>.

<sup>1</sup>Joint Shantou International Eye Center of Shantou University and the Chinese University of Hong Kong, Shantou, People's Republic of China, <sup>2</sup>Department of Ophthalmology & Visual Sciences, Chinese University of Hong Kong, Hong Kong, Hong Kong, China

**Objective:** To evaluate the effectiveness of smartphone ophthalmoscope (SO) in teaching ophthalmoscopy, compared with direct ophthalmoscope (DO).

**Methods:** In this cross-over study, forty-five final-year medical students attending sessions at a single institution were randomly allocated to two groups (A and B). Both groups attended two training sessions. In the first session, Group A students were taught ophthalmoscopy using DO and Group B students using SO. In the second session, the training sessions were crossed over. A series of eye models with 10 letters placed on the inner surface were designed to assess the students' skill on ophthalmoscopy. Students performed ophthalmoscopy on the eye models, recorded their findings and completed a questionnaire of feedback on DO and SO. The main outcome measure was the score of ophthalmoscopy, assessed by the student correctly recording each letter (score 1 for each letter).

**Results:** For Group A, the mean score of ophthalmoscopy on the eye model using DO and SO was  $3.9 \pm 2.4$  and  $8.2 \pm 2.2$ , respectively. For Group B, the respective mean scores were  $5.7 \pm 3.5$  and  $8.7 \pm 1.8$ . Students scored significantly higher in ophthalmoscopy when using SO than DO ( $P < 0.001$ ). They expressed better visualization of the fundus using SO than DO ( $4.49 \pm 0.65$  vs  $4.13 \pm 0.81$ ,  $P = 0.004$ ).

**Conclusion:** Students' performance of ophthalmoscopy was better when SO was used compared with DO. The use of SO as an adjunctive tool is recommended and should improve the effectiveness of teaching ophthalmoscopy.

FP-123

**Impact of simulation based manual small incision cataract surgery (MSICS) training on ophthalmology trainees in developing country**V Singh, S Pandey .

**Objective:** To assess and compare the visual outcomes and complication rates of MSICS performed by Ophthalmology trainees receiving simulator training in addition to the traditional wet lab training

**Methods:** This retrospective study performed in a tertiary care center included two set of trainees. Group 1 (n=340) included eyes operated on for MSICS by trainees who underwent traditional wet lab training whereas Group 2 (n= 676) included those who received MSICS simulator training apart from the wet lab training

**Results:** The mean number of surgeries performed by the trainees before joining the institute were 316 (+/- 632.2) and 186 (+/-234.4) in group 1 and group 2 respectively (p=0.25). Posterior capsular rupture with vitreous loss was reported in 7.3% in group 1 and 6.5 % in group 2 (p=0.6). Zonular dialysis was reported more commonly in group 1(3.5%) than in group 2 (1.4%) (p=0.002). Nuclear fragment drop was again found to be more common in group 1 (1.1%) than group 2 (0.2%) (p=0.02). Wound related complications (premature entry, button-hole, irregular wound) were also reported to be significantly more common group 1(12.06%) than group 2 (1.33%) (p=0.00001). However, there was no difference in the final visual outcomes with both the groups reporting 20/40 or better vision in approximately 90% of eyes (p=0.569).

**Conclusion:** MSICS simulator trained surgeons reported lesser complications as compared to the ones trained only on the wet lab. Simulator training can be an important tool and can be used to strengthen the existing MSICS training.

FP-124

**Ophthalmology Teaching: How An Effective Teaching Programme Effects Junior Doctor confidence**S Maripi.

**Objective:** Ophthalmology rotation for junior doctors in the UK is rare, however every year a handful of posts are taken up by junior doctors as part of their core curriculum. Ophthalmology has a very narrow space in the curriculum in medical schools in the UK, therefore this can be often an arduous and anxiety inducing experience. A quality improvement project was implemented to identify the effects of an Ophthalmology themed teaching programme on the confidence of junior doctors after attendance of a weekly teaching programme for 4 months.

**Methods:** A ophthalmology curriculum was developed using local medical tutors and based on the template given by the Royal College of Surgeons "National Curriculum in Surgery". Next a baseline survey was performed at the start of the junior doctor's Ophthalmology rotation. Following this, a 12-week teaching programme was implemented, covering the most common acute ophthalmology presentations and key practical procedures. At the end of the 12 weeks, a repeat survey was taken.

**Results:** Survey results showed a positive impact in all categories. Of significance, junior doctor response in their confidence level on-call went from an average 2/10 to 8/10; confidence on the wards went from an average 4/10 to 7/10; confidence in practical procedures from 1/10 to 7/10. In addition, 90% of the respondents attributed an increase in their confidence level due to the implementation of a regular and consistent surgical teaching programme.

**Conclusion:** The inclusion of a teaching programme based on core principles junior doctors will be using on a day-to-day bases yields a positive result in terms of confidence and ability. Based on the feedback received, organised ophthalmology teaching should continue to evolve and develop in order to improve junior doctor's experience of their surgical rotations.

FP-125

### Faculty development opportunities through international collaboration agreement

H Filipe<sup>1</sup>, A Geary<sup>2</sup>, J Kilangalanga<sup>3</sup>, A Buque<sup>4</sup>, C Timbo<sup>5</sup>, H Mack<sup>6</sup>, K Golnik<sup>7</sup>.

<sup>1</sup>Ophthalmology, West Lisbon Hospitals Center. Hospital Egas Moniz, Lisbon, Portugal, <sup>2</sup>Ophthalmology, ORBIS, New York, United States, <sup>3</sup>Ophthalmology, Congolese Society of Ophthalmology, Kinshaza, Congo, The Democratic Republic of the, <sup>4</sup>Ophthalmology, Mozambican College of Ophthalmology, Maputo, Mozambique, <sup>5</sup>Ophthalmology, ORBIS, Seattle, United States, <sup>6</sup>Ophthalmology, University of Melbourne, Melbourne, Australia, <sup>7</sup>Ophthalmology, University of Cincinnati, Cincinnati, United States

**Objective:** Reaching out to geographically remote and or underserved regions to widen professional development opportunities.

**Methods:** An international group of five ophthalmologists' educators with experience in clinical education serving a global professional organization in its educational project, created an online program on curriculum design. The ten modular program was developed around the six steps curriculum approach. Each module requiring 2.5h to complete, consisted of curated readings, a recorded lecture, a pre and post-test and, a feedback survey.

Upon a partnership, the program became free to undertake in a nongovernmental organization online platform, either as self-paced or group-mentoring assisted.

The latter included peer mentoring and group facilitation and followed a flipped learning approach with an additional pre-activity, a concluding webinar, an applied assignment (AA), and the formation of a virtual community of practice.

**Results:** In 2019-2020, two cohorts of ten ophthalmologists' educators from SubSaharan Africa, the CSO and the MOC, identified by their respective professional society President as most likely to make a change, undertook the program in accordance with the group-mentoring assisted mode.

Both enjoyed the program, asserted willingness to continue developing scholar teaching skills, and showed learning improvement (CSO and MOC, pre-test and post-test average correct responses, respectively: 78% and 67% against 85% and 87%).

Additionally, both showed team competence improvement as per at least two differences identified in the final submitted versions of their simulation-based training session curriculum design (AA) upon program completion. Both formed a virtual community of ophthalmologists-educators engaged in developing a scholar approach in their teaching practice.

Participants of the self-paced mode showed appreciation and learning improvement (58% against 72% of average corrected answers).

**Conclusion:** Online education grounded in learning theory can widen professional development opportunities, overcoming geographically remote, human and financial under-resourced settings and even extreme circumstances such as the pandemic.

Technology can support the formation of a virtual community of ophthalmologists' educators.

Group-mentoring can play a key part in the learning process including the establishment of longitudinal educational projects and international collaboration agreements to maximize expertise and resources

FP-126

**SIEP'S TEST- A NOVEL TEST TO CHECK WOUND INTEGRITY**

A Pai<sup>1</sup>, A Kamath<sup>2</sup>, D Bhosale<sup>3</sup>.

<sup>1</sup>Netradhama Superspeciality Eye Hospital, Bangalore, <sup>2</sup>Ophthalmology, Yenepoya Medical College & Hospital, Mangalore, <sup>3</sup>Ophthalmology, Government medical College & District Hospital, Satara, India

**Objective:** To ensure integrity of surgery wounds

**Methods:** A randomized prospective trial of 150 patients who underwent intraocular surgery at our hospital over 1 year period. We used 2-3 drops of Betadine 5% (povidone-iodine) at the end of each case, not only to sterilize the surface of the eye but also as a disclosing dye to demonstrate any wound leaks.

**Results:** 110 patients underwent SICS, 35 underwent corneal tear repair & 5 underwent trabeculectomy surgery. 60 patients had post op wound leak in SICS due to surgical complications. Pre-mature entry comprising 75%, followed by floppy iris syndrome comprising 20% & 5% comprising PXF syndrome. 4 post corneal repair surgery & 2 post trab had wound leak.

**Conclusion:** The simple procedure is very handy & economical in identifying THE LEAK & can reduce further complications such as endophthalmitis & resurgeries. SIEP's TEST plays an important role in identifying any postoperative wound leaks & also sterilizing the eye surface post surgery.

FP-127

**Comparison of allied ophthalmic personnel accreditation programs: a cross-sectional international study**L Anderson.

**Objective:** 1. Investigate the value of accreditation between training programs in middle-income countries with those in higher income countries.

2. Identify the outcomes of accreditation experiences and results.

**Methods:** The study's purpose was to investigate and describe the differences of the organizational attributes of allied ophthalmic personnel (AOP) accredited training programs and identify sustaining contextual factors or barriers in middle-income countries from those in higher-income countries.

The study investigated organizational attributes, sustaining factors or barriers of eight allied ophthalmic personnel (AOP) accredited training programs globally, in middle- and higher-income countries using an online questionnaire of three cases.

**Results:** Worldwide accreditation models provide standards promoting continuous improvement, self-assessments, feedback, and outcomes. Accreditation outcomes reported were organizational attributes and cross-international differences. Similarities included accreditation value, student outcomes, certification, and obstacles. Divergences identified were support for institutional recognition, sustainability, government policy, recruitment, funding, and improvement.

Accredited AOP programs in middle-income countries exhibit parallel characteristics to those in higher income countries, with some significant differences. The worldwide accreditation model provides consistent standards and measures that center on promoting improvements, applying standards, conducting self-assessment, providing feedback, and measuring outcomes.

Understanding similarities and differences of accreditation programs in middle- and higher-income countries can be applied to benefit and sustain programs.

**Conclusion:** Accreditation processes may benefit, sustain, and achieve a thriving training program to support quality eye care delivery.



FP-128

**FIRST NATION-WIDE STUDY OF DIABETIC RETINOPATHY IN POLAND IN THE YEARS 2013-2017**M S Nowak, M *Kozioł*<sup>1</sup>.<sup>1</sup>*Department of Analyses and Strategies, Polish Ministry of Health, Warsaw, Poland*

**Objective:** To assess the prevalence and time trends of diabetic retinopathy (DR) in the overall population of Poland from 2013 to 2017 and diagnose the risk factors of occurring DR among patients with diabetes mellitus (DM).

**Methods:** Data from all levels of healthcare services at public and private institutions recorded in the National Health Fund (NHF) database were evaluated. International Classification of Diseases codes (ICD-9 and ICD-10) and unique NHF codes were used to identify DM type 1 and type 2 patients, DR and treatment procedures including laser photocoagulation, pars plana vitrectomy (PPV), anti-VEGF and steroid intravitreal injections.

**Results:** The overall registered prevalence of DR in the entire population of Poland was 0.81%. The mean prevalence of DR was 20.01% in the population with type 1 DM and 9.70% in the population with type 2 DM. In the study period, women represented 56.36% of all individuals registered with DR and 55.09% of all DM patients. In Poland, only 6.34% of all DM patients with DR received specific treatment with laser photocoagulation of the retina (82.32%), PPV (11.56%), anti-VEGF or steroid injections (5.15% and 0.97%, respectively). Cox regression hazard analysis showed that the risk of DR was associated with DM treatment only by GPs, female sex, coexisting systemic diseases and urban residence in both type 1 and type 2 DM.

**Conclusion:** A 5-year retrospective analysis reveals the mean prevalence of DR in the population with type 1 and type 2 DM in Poland was rather low.

FP-129

## A nationwide surveillance study of long-term effects of environmental factors on acute hemorrhagic conjunctivitis in China

L Zhang.

**Objective:** Acute hemorrhagic conjunctivitis (AHC) is a common ocular surface disease which can occur worldwide and associated with a high disease burden. The association between environmental factors and AHC circulation remain inconclusive. This study aimed to quantify the relationship between the environment and AHC. The impact of enhanced public health intervention and the incidence of AHC during the COVID-19 pandemic in China was also investigated.

**Methods:** The monthly counts and incidence of AHC, meteorological variables and air quality in mainland China between 2013 and 2020 was retrieved. Exposure risks were evaluated by multivariate distributed lag nonlinear models.

**Results:** A total of 289,933 AHC cases were reported in mainland China during 2013–2020, predominantly in southern and central China, seasonally increased in summer. A moderate positive correlation was seen between AHC and monthly mean temperature, relative humidity (RH) and precipitation. Each unit increment was associated with a relative risk for AHC of 1.058 at  $17^{\circ}$ – $32^{\circ}$  C at lag 0 months, 1.017 at 65–71% RH at lag 1.4 months, and 1.039 at 400–569 mm at lag 2.4 months. Significant reductions in AHC incidence were found both during the emergency period and after the relaxation of emergency measures in 2020 compared to the previous 5 years.

**Conclusion:** Long-term exposure to higher mean temperature, RH and precipitation were associated with an increased risk of AHC. The general public, especially susceptible populations, should pay close attention to weather changes and take protective measures in advance to any AHC outbreak as the above situations occur. Enhanced public health initiatives during the COVID-19 pandemic in China were therefore associated with lower transmission of pathogens causing AHC.

FP-130

**Mutation Spectrum of Patients with Familial Exudative Vitreoretinopathy in the eyeGENE®**

F Yaylacioglu Tuncay<sup>1,2</sup>, M Reeves<sup>1</sup>, E Ullah<sup>1</sup>, B Guan<sup>1</sup>, S Tumminia<sup>1</sup>, R Hufnagel<sup>1</sup>.

<sup>1</sup>National Institutes of Health, National Eye Institute, BETHESDA, United States, <sup>2</sup>Medical Biology Department, University of Health Sciences, Ankara, Türkiye

**Objective:** To report the mutations and phenotype-genotype correlations in patients with Familial Exudative Vitreoretinopathy included in the eyeGENE® database

**Methods:** Genotype and phenotype information were reviewed from 122 eyeGENE® participants from 114 families. Clinical details were provided by referring clinicians participating in the eyeGENE® Network and the genetic test results were provided by the eyeGENE® Network clinical laboratories using Sanger or Next generation sequencing.

**Results:** Nearly half of the patients (45.1%, 55 patients in 52 families) had a genetic test result reporting a mutation in the genes linked to Norrin/Beta-catenin signaling pathway. Fifty-four mutations were reported including 25 mutations in *LRP5*, 12 in *FDZ4*, 10 in *TSPAN12* and 7 in *NDP*. Among those mutations 18 were not reported previously (6/25 in *LRP5*, 6/12 in *FDZ4*, 4/10 in *TSPAN12* and 2/7 in *NDP*). Two thirds of the mutations were missense (19/25 in *LRP5*, 5/12 in *FZD4*, 5/7 in *NDP* and 7/10 in *TSPAN12*). More than half of the patients with a *FZD4* mutation (57%) had asymmetric findings. However, asymmetry less pronounced in patients with mutations in *LRP5* (24%), *NDP* (29%) and *TSPAN12* (15%). Adult-onset disease were mostly reported in *LRP5* group (20%) and least reported in *NDP* group (0%). Retinal detachment (stage 3 or higher) was reported with the highest ratio in *NDP* group (86%) and with the lowest ratio in *TSPAN12* group (23%).

**Conclusion:** This was one of the largest cohorts from USA expanding the mutation spectrum in FEVR associated with the Norrin/Beta-catenin signaling pathway. The genotype-phenotype correlations supported the phenotypic variability in FEVR. Among the eyeGENE® FEVR patients; *LRP5* mutations were the most common, *FZD4* mutations caused the most asymmetric presentation and *NDP* mutations resulted in the most severe eye findings.

FP-131

**Diabetic retinopathy risk in patients with unhealthy lifestyle: a Mendelian randomization study**Z Su<sup>1</sup>, Z *wu*<sup>2</sup>, X *wang*<sup>1</sup>, F *Jiang*<sup>1</sup>.

<sup>1</sup>Department of Ophthalmology, Tongji Medical College, Union Hospital, Huazhong University of Science and Technology, <sup>2</sup>Department of Endocrinology, Union Hospital, Tongji Medical College, Huazhong University of Science and Technology, Wuhan, People's Republic of China

**Objective:** The association between unhealthy lifestyle factors and diabetic retinopathy (DR) remains inconclusive. Conventional observational studies are susceptible to inverse causality and potential confounders. Thus, we performed a Mendelian randomization (MR) analysis to explore the causal relationship between unhealthy lifestyle and DR incidence and guide the development of prevention strategies.

**Methods:** Our study included 721 single-nucleotide polymorphisms (SNPs) associated with unhealthy lifestyle as instrumental variables. Aggregated data of individual-level genetic information were obtained from corresponding studies and consortia. A total of 292,622,3 cases and 739,241,18 controls from four large consortia (MRC Integrative Epidemiology Unit [MRC-IEU], Genetic Investigation of ANthropometric Traits [GIANT], GWAS & Sequencing Consortium of Alcohol and Nicotine use [GSCAN] and Neale Lab) were included. The inverse variance-weighted method was applied to assess the causality between unhealthy lifestyle and risk of DR.

**Results:** Our study demonstrated that higher BMI (odds ratio (OR) = 1.42; 95% confidence interval (CI) 1.29-1.56;  $P < 0.001$ ) and higher cigarettes per day (OR=1.16; 95% CI 1.03-1.31;  $P=0.013$ ) were causally associated with an increased risk of DR, while patients with higher hip circumference had a lower risk of DR (OR=0.85; 95% CI 0.76-0.95;  $P=0.005$ ). Furthermore, no pleiotropy was found in our study.

**Conclusion:** Our findings suggested that higher BMI and smoking were likely to be causal factors in the development of DR, while genetically higher hip circumference was associated with a lower risk of DR, providing insights for a better understanding for the etiology and the prevention of DR.

FP-132

**Visual Impairment and Major Eye Diseases in Stroke: The National Health and Nutrition Examination Survey, 2005-2008**H Li.

**Objective:** Major ocular diseases share common risk factors and pathogeneses with stroke. This study aimed to evaluate the relation between stroke and the prevalence of ocular diseases including visual impairment (VI).

**Methods:** The cross-sectional study investigated the prevalence and associations of VI and major eye diseases with stroke among 4570 participants in the 2005-2008 National Health and Nutrition Examination Survey (NHANES). The association of VI and major ocular diseases with stroke were estimated using univariate and multivariate logistic regression crude models and models adjusted for demographics and clinical factors. We also conducted stratified analyses by diabetes and hypertension status.

**Results:** VI was risk factors for stroke, and the odds ratios (ORs) for mild and moderate and severe visual impairment (MSVI) were 7.04 (95% confidence interval (CI): 2.50-19.86) and 11.60 (95% CI: 2.97-45.31), respectively. Ocular disease was associated for stroke with OR 6.88 (95% CI: 2.67-17.76), and the OR for other major eye diseases were as followed: DR, 8.61 (95% CI: 2.55-29.07) and cataract, 3.75 (95% CI: 1.11-12.71) (all  $P < 0.05$ ). After multivariable adjustment, the associations were limited to mild VI (OR=10.00, 95% CI: 3.16-30.58), MSVI (OR=8.57, 95% CI: 1.58-43.36), and any ocular disease (OR=5.18, 95% CI: 1.46-18.42) (all  $P < 0.05$ ). Significant associations between stroke and any ocular disease and DR were observed among diabetic participants, and significant relation between stroke and MSVI was found among hypertension patients.

**Conclusion:** The sample of the US population demonstrates high prevalence and significant associations between VI and major ocular disease with stroke.

FP-133

### Evolving trends in Keratoconus

R Deshmukh, P Vaddavalli<sup>1</sup>, A Das<sup>1</sup>.

<sup>1</sup>LV Prasad Eye Institute, Hyderabad, India

**Objective:** To describe changing trends of keratoconus in patients presenting to a multi-tier ophthalmology hospital network in India, between 1987-2020 (33 years)

**Methods:** This retrospective hospital-based study included keratoconus patients presenting from 1987-2020. Patients with a clinical diagnosis of keratoconus in at least one eye were included. Descriptive statistics were used to elucidate demographic data. Chi square test was used for univariate analysis to detect significant differences in distribution of demographic features between patients with keratoconus and overall population.

**Results:** A total of 20,576 cases of keratoconus were identified from 1987-2020. Of these, 14,749 (69.4%) patients were diagnosed in between 2012-2020. The mean age at diagnosis has reduced from 29.3 years (1987-1991) to 22.2 years (2016-2020). Adults (76.64%) were commonly affected with majority being male (61.25%). The corneal signs included Fleischer ring (44.52%), prominent nerves (45.75%), ectasia (41.35%), Vogt's striae (18.97%), corneal scar (13.60%) and hydrops (0.71%). Use of contact lenses increased from 4.34% (2002-2006) to 11.23% (2016-2020). Advancements in anterior lamellar keratoplasties have led to an increase in the number of patients undergoing deep anterior lamellar keratoplasty (DALK) as compared to penetrating keratoplasty (PK). A trend towards earlier CXL was seen over past two decades. In the last 8 years, 17.2% patients underwent a surgical procedure and the most common was CXL (14.77%) followed by DALK (1.72%) and optical PK (1.04%).

**Conclusion:** The last 30 years have seen a change in the trend of clinical presentation and management of keratoconus. Advancements in diagnostic techniques have made it possible to diagnose keratoconus earlier. Use of contact lenses and advancements in CXL have reduced the number of keratoplasties in these patients. Lamellar keratoplasties are more commonly done than PK.

FP-134

## High Fluence and Benzalkonium(BAK) Increase the in-Vitro Efficacy of PACK-CXL to Eradicate Fungi and Bacteria but not Acanthamoeba

V Sánchez-Huerta<sup>1</sup>, R Barrera Rodríguez<sup>1</sup>, J Cruz Cervantes<sup>2</sup>, R Alvarado-Villacorta<sup>1</sup>, M Omaña Molina<sup>3</sup>, D Hernández Hernández<sup>4</sup>, V Vanzzini Zago<sup>2</sup>.

<sup>1</sup>Cornea and refractive surgery, <sup>2</sup>Microbiology laboratory, Asociación para evitar la ceguera en México I.A.P-APEC, Mexico city, <sup>3</sup>el Laboratory for anphizoic amoebas-Faculty of Superior Studies , UNAM Iztacala, Tlanepantla State of Mexico, <sup>4</sup>Laboratory for anphizoic amoebas in Faculty of Superior Studies, UNAM Iztacala, Tlanepantla.State of Mexico, Mexico

**Objective:** To quantify the efficacy of Photo-Activated Chromophore for Keratitis – Corneal Collagen Cross-linking (PACK-CXL) combined with benzalkonium chloride (BAK) and different UVA fluence levels and riboflavin concentrations to eradicate fungi, bacteria and acanthamoeba strains isolated from previous infectious keratitis cases.

**Methods:** An experimental in vitro study was designed to analyze clinically isolated strains of *Pseudomonas aeruginosa*, *Candida parapsilosis*, *Aspergillus flavus*, *Fusarium solani* and *Acanthamoeba polyphaga*. Riboflavin, BAK and 0.9% sodium chloride suspensions of 11 µL with fungal and bacterial concentrations between  $1.5 \times 10^2$  and  $2 \times 10^4$  cells/mL were used to simulate small corneal ulcers. Each suspension was individually exposed within a microtiter plate to UVA light with an irradiance of 30 mW/cm<sup>2</sup> and different fluences (5.4–27 J/cm<sup>2</sup>). The decrease percentage in colony forming unit (CFU) for bacterial and fungal strains and the morphological changes of acanthamoeba trophozoites or cysts were determined to evaluate the antimicrobial efficacy of PACK-CXL.

**Results:** PACK-CXL with 0.1% riboflavin was found to be effective on *Pseudomonas aeruginosa* after 9 minutes of UVA exposure (5.4 J/cm<sup>2</sup>). PACK-CXL with 0.25% riboflavin and BC at 27 J/cm<sup>2</sup> achieved CFU reduction in *Candida parapsilosis* (76.9%), *Aspergillus flavus* (35.3%) and *Fusarium solani* (52.7%). 0.1% riboflavin without BC also decreased CFU in *Candida parapsilosis* (100% with 5.4 J/cm<sup>2</sup>), *Aspergillus flavus* (94.8% with 16.2 J/cm<sup>2</sup>) and *Fusarium solani* (100% with 5.4 J/cm<sup>2</sup>). No morphological changes were found in acanthamoeba trophozoites or cysts after high fluence levels of PACK-CXL with riboflavin and BAK.

**Conclusion:** Higher UVA fluence and high riboflavin concentration combined with BAK significantly increase the fungal and bacterial killing rates; however, the required exposure dose may exceed the safety limits used in the clinical practice. None of the PACK-CXL modifications showed significant efficacy to eradicate acanthamoeba cysts or trophozoites.

FP-135

**The vicious cycle of IL-1 $\beta$  autoinduction contributes to VEGF-A expression in Müller glia cell**D Wu<sup>1,2</sup>, Y Liu<sup>1,2</sup>, Q Fu<sup>1,2</sup>, K Yao<sup>1,2</sup>.<sup>1</sup>Zhejiang Provincial Key Lab of Ophthalmology, <sup>2</sup>Eye Center of the Second Affiliated Hospital, School of Medicine, Zhejiang University, Hang Zhou, People's Republic of China

**Objective:** Müller glia cell is one of the sources of vascular endothelial growth factor (VEGF)-A, a major angiogenic factor that contributes to the pathogenesis of ocular diseases such as diabetic retinopathy. The purpose of this study was to investigate the molecular mechanisms of VEGF-A production in Müller glia cells.

**Methods:** Immunoblot, enzyme-linked immunosorbent and real-time PCR analyses were performed to measure protein and mRNA expression levels of VEGF-A in human Müller glia cells (MIO-M1 cell line).

**Results:** Of various pro-fibrotic cytokines, e.g. interleukin-1 $\beta$  (IL-1 $\beta$ ), platelet derived growth factor (PDGF-BB), connective tissue growth factor (CTGF), nerve growth factor (NGF), and fibroblast growth factor (FGF-2), only IL-1 $\beta$  stimulation to Müller glia cells exclusively increased mRNA (fold change=2.7, P<0.01) and protein (fold change=5.4, P<0.01) levels of VEGF-A, which were abolished by treatment with IL-1 $\beta$  inhibitor. IL-1 $\beta$  induced VEGF-A mRNA expression were significantly reversed by p38 MAPK (fold change=2.1, P<0.01), and PI3K (fold change=1.6, P<0.01). Moreover, IL-1 $\beta$  upregulated the expression of IL-1 $\beta$  via its own downstream pathway in an autocrine manner.

**Conclusion:** Our data implicate that the IL-1 $\beta$  activates p38 MAPK and PI3K signal transduction in Müller glia cells, which causes VEGF-A production forming the vicious cycle of IL-1 $\beta$  autoinduction concurrently.



FP-136

**The influence of slit lamp shield size and design in reducing aerosol transmission**M Butt<sup>1</sup>, M Dogramaci<sup>1</sup>.<sup>1</sup>*The Princess Alexandra Hospital, Harlow, United Kingdom*

**Objective:** Previous studies have highlighted the effectiveness of slit lamp shields in reducing aerosol spread. Our study investigated the optimal size and design for such shields.

**Methods:** Two sets of shields were made; each set included five cardboards of the following dimensions 1:(44x52cm), 2:(44x44cm), 3:(22x52cm), 4:(22x33.5cm) and 5:(44x22.5cm). Cardboards in set 1 were kept flat whilst set 2 were curved using plastic frames. Aerosol was generated at the patient's position using a water spray bottle and aerosol levels were measured at the face position of the examiner and on the slit lamp table using two GP2Y1014AU0F sensors. The measurements were recorded in particles/0.01f<sup>3</sup> and analysed using a Mann Whitney U Test.

**Results:** Mean background indoor aerosol was 559. Following aerosol generation, the level increased to a mean of 571 in the absence of any kind of shield but to a mean of 567 when shields were in place ( $p < 0.05$ ). Flat shield 1 provided the best protection against inhaled aerosol. Flat shield 2, despite its shorter height compared to shield 1, provided the best protection against precipitated aerosol on the table. Curving shield 5 significantly improved its protective properties against both inhaled and precipitated aerosol, whilst keeping the short height that allowed better access during slit lamp examinations.

**Conclusion:** Shields reduced aerosol spread with curved shields being more effective. GP2Y1014AU0F particle sensors are effective tools for quantifying aerosol spread. Slit lamp parts could change the aerodynamics of aerosol transmission therefore larger shields may not provide better protection against precipitated aerosols.

FP-137

## Composition and Diversity of the Gut Microbiota in Diabetic Retinopathy

J Bai<sup>1</sup>, Q Peng<sup>1</sup>.

<sup>1</sup>Shanghai Tenth People's Hospital of Tongji University, Shanghai, People's Republic of China

**Objective:** Diabetic retinopathy (DR) is one of the most common complications in type 2 diabetes mellitus. The current study examined the composition, structure, and function of the gut microbiota in DR to establish a correlation between gut microbiota and clinical characteristics.

**Methods:** A total of 50 stool samples were collected from 50 participants, including 25 DR patients and 25 healthy controls (HCs). 16S ribosomal RNA gene sequencing was used to analyze the gut microbial composition in the two groups. DNA was extracted from the fecal sample using the MiSeq platform.

**Results:** Microbial structure and composition of DR patients were different from that of HCs. The microbial richness of gut microbiota in DR was higher than that of normal individuals. The microbiome alterations of DR patients were associated with disrupted Firmicutes, Bacteroidetes, Synergistota, and Desulfobacterota phyla. In addition, increased levels of *Bacteroides*, *Megamonas*, *Ruminococcus\_torques\_group*, *Lachnoclostridium*, and *Alistipes* and decreased levels of *Blautia*, *Eubacterium\_hallii\_group*, *Collinsella*, *Dorea*, *Romboutsia*, *Anaerostipes*, and *Fusicatenibacter* genera were observed in the DR groups than in the healthy individuals. Additionally, a stochastic forest model was developed to identify a set of biomarkers of the seven bacterial genera that can differentiate patients with DR from those with HC. Due to these alterations, microbial communities exhibited varied functions in the two groups. A total of 6507 Kyoto Encyclopedia of Genes and Genomes (KEGG) ortholog (KO) genes and 335 KEGG pathways were predicted. The pathways involved in insulin resistance and glucosinolate biosynthesis were suppressed in DR patients. The predicted KEGG pathways were significantly differently related to other several metabolic pathways involved in carbohydrate metabolism, glycan biosynthesis and metabolism, metabolism of cofactors and vitamins, and amino acid metabolism.

**Conclusion:** The altered composition and function of gut microbiota in DR indicated a potential for the gut microbiome to serve as the noninvasive biomarker, improve the clinical diagnostic methods of DR, and identify the putative therapeutic targets.

FP-138

**Prognostic significance of survivin (BIRC5) in retinoblastoma**S Chahar, K Mulay<sup>1</sup>, S Honavar<sup>1</sup>, S Sengupta.<sup>1</sup>Centre For Sight, Hyderabad, India

**Objective:** The study aimed at evaluating the expression of survivin (BIRC5) in retinoblastoma and to determine whether this expression is associated with histopathological high-risk factors (hHRFs) and response to chemotherapy

**Methods:** This was a retrospective clinicopathologic case series which included patients who underwent enucleation for retinoblastoma. Immunostaining for survivin was performed in all. Multiple univariate analysis was performed using Fisher's exact test and paired-t test.

**Results:** The study included 65 patients who underwent enucleation for retinoblastoma (primary,39; secondary 26). Nuclear survivin score was associated with poor differentiation ( $p<0.1$ ), massive choroidal invasion ( $p<0.05$ ), retrolaminar invasion ( $p=0.05$ ), ciliary body and anterior segment involvement (both,  $p<0.05$ ). Survivin expression was higher in chemotherapy-resistant tumors.

**Conclusion:** Expression of survivin significantly impacts prognosis and is thus a promising prognostic marker in retinoblastoma.

FP-139

## Effect of Sample Collection and Storage on Biological Stability of Cytokines in Human Aqueous Humor and Vitreous Samples

T Felfeli<sup>1</sup>, J Park<sup>2</sup>, B Nestor<sup>3</sup>, F Altomare<sup>14</sup>, S El-Defrawy<sup>15</sup>, A Rai<sup>15</sup>, E Mandelcorn<sup>16</sup>, D Chow<sup>14</sup>, D Wong<sup>14</sup>.

<sup>1</sup>Department of Ophthalmology and Vision Sciences, <sup>2</sup>Faculty of Medicine, <sup>3</sup>Department of Computer Science, University of Toronto, <sup>4</sup>Department of Ophthalmology, St. Michael's Hospital, Unity Health Toronto, <sup>5</sup>Kensington Eye Institute, University of Toronto, <sup>6</sup>Department of Ophthalmology, Toronto Western Hospital, University Health Network, Toronto, Canada

**Objective:** To determine the effects of sample collection and storage duration on the levels of various cytokines in the human aqueous humor (AH) and vitreous (Vit) samples.

**Methods:** AH and Vit samples were obtained from 27 human eyes, aliquoted into 3 tubes and stored at -80C for analysis within 1-week, 3-month and 9-month duration since collection with the Bioplex Pro-Human cytokine 27-plex assay kit. An ANOVA was run to assess the impact of storage time and sample type. A p-value less than Bonferroni corrected threshold of 0.05 was considered statistically significant.

**Results:** Four of 27 biomarkers were significantly impacted by storage duration at both 3- and 9-month timepoints (IL-10, IL-12, IL-2 and PDGF-BB), whereas 11 were significantly influenced by sampling type of AH versus Vit within the same eyes (GM-CSF, IL-12, IL-2, IL-5, IL-6, IL-7, IL-8, IL-9, IL-15, PDGF-BB, and VEGF). Amongst biomarkers where sample duration was significant, the relative abundance tended to decrease with time. Cytokine concentrations tended to be higher in AH compared to Vit, except for IL-7. Neither AH or Vit offered a significant advantage of mitigating deterioration in storage. Separability of patient-specific cytokine biomarker profiles at all 3 timepoints in a principal component analysis (PCA) remained relatively the same over time.

**Conclusion:** Although there is degradation amongst specific cytokine analytes over 9 months of sample storage, sampling between AH and Vit specimens within the same eyes shows much more variation than individual sample deterioration. The overall patient-specific cytokine biomarker profiles remained relatively the same over time.

FP-140

## An Essential Role of the Tyrosine Metabolic Pathway and Inflammation in Myopia-induced Retinal Degeneration in Guinea Pigs

L Zeng<sup>12</sup>, X Li<sup>234</sup>, H Xu<sup>125</sup>, Z Yang<sup>12</sup>.

<sup>1</sup>Aier School of Ophthalmology, Central South University, <sup>2</sup>Aier Institute of Optometry and Vision Science, <sup>3</sup>Aier Eye Hospital, Changsha, <sup>4</sup>Aier School of Optometry and Vision Science, Hubei University of Science and Technology, Xianning, People's Republic of China, <sup>5</sup>The Wellcome-Wolfson Institute for Experimental Medicine, School of Medicine, Dentistry and Biomedical Sciences, Queen's University, Belfast, United Kingdom

**Objective:** To illustrate the mechanism of action underlying retinal degeneration caused by myopia with a model of myopia-induced early-stage retinal degeneration in guinea pigs.

**Methods:** Two- to three-week-old guinea pigs were randomly assigned to two groups (n = 30/group): form deprivation and naïve nontreatment controls. In the form-deprivation group, the right eyes were occluded with nontoxic balloons as translucent masks for 15 weeks. The left eye remained untreated and served as a self-control. Another group of untreated age-matched animals was used as naïve controls. The refractive error and ocular biometrics were measured at 3, 7, 9, 12 and 15 weeks post-FDM induction. Visual function was evaluated by electroretinography. Retinal neurons and synaptic structures were examined by confocal microscopy of immunolabelled retinal sections. The total RNAs were extracted from the retinas and processed for RNA sequencing analysis.

**Results:** The FDM eyes presented a progressive axial length elongation and refractive error development. After 15 weeks of intervention, the change of refractive power was  $-6.33 \pm 2.05$  D in the FDM eyes,  $-0.15 \pm 1.37$  D and  $1.11 \pm 1.05$  D in the self-control and naïve control eyes, respectively. The change of axial length was  $-1.27 \pm 0.28$  mm in the FDM,  $0.78 \pm 0.19$  mm and  $0.89 \pm 0.14$  mm in the self-control and naïve control eyes, respectively. The a-wave amplitude was significantly lower in FDM eyes and these eyes had a significantly lower number of rods, secretagogin+ bipolar cells, and GABAergic amacrine cells in selected retinal areas. RNA-seq analysis showed that 288 genes were upregulated and 119 genes were downregulated in FDM retinas compared to naïve control retinas. In addition, 152 genes were upregulated and 12 were downregulated in FDM retinas compared to self-control retinas. The Kyoto Encyclopedia of Genes and Genomes (KEGG) enrichment analysis showed that tyrosine metabolism, ATP-binding cassette transporter (ABC transporters) and inflammatory pathways were upregulated, whereas tight junction, lipid and glycosaminoglycan biosynthesis were downregulated in FDM eyes.

**Conclusion:** The long-term (15-week) FDM in the guinea pig models induced an early-stage retinal degeneration. The dysregulation of the tyrosine metabolism and inflammatory pathways may contribute to the pathogenesis of myopia-induced retinal degeneration.

**FP-141****Multicolour® imaging (MCI) findings in commotio retinae involving macula and topographical correlation with outer retinal layers**

H Nahata, R Venkatesh, S Sharief, R Mangla, N Yadav.

**Objective:** To report Multicolour® imaging (MCI) findings in commotio retinae (CR) involving macula and correlate topographically with outer retinal layers on OCT.

**Methods:** This retrospective study included participants with CR involving macula without any other type of traumatic maculopathy and imaged with OCT and MCI.

**Results:** The study included 16 eyes of 16 patients (14 males). Age of presentation ranged from 7–56 years and presenting vision ranged from 6/6–6/24. On OCT, increased reflectivity of inner segment-outer segment (IS-OS) layer, obliteration of hyporeflective ellipsoid zone (EZ) and impaired cone outer segment tip (COST) layer visualisation at CR region was seen. Fovea and other retinal layers were spared. On MCI, white areas due to hyperreflectance corresponding to CR were noted on individual colour reflectance channels. Multicolour image showed white areas of discolouration. In all cases, foveal reflectance pattern was unaffected. On OCT correlation, affection of IS-OS layer, EZ and COST layer at the CR correlated with increased reflectance on individual wavelength colour channels. Foveal sparing on MCI correlated with photoreceptor layer sparing at the fovea on OCT. In 6 (38%) cases with follow-up details, normal reflectivity of IS-OS layer was noted in the region of previous CR as early as 1-week post-presentation. White coloration on multicolour image showed resolution.

**Conclusion:** Foveal sparing was common and rod-dominated areas were affected in CR. Corresponding changes on MCI showed hyperreflectance areas on individual wavelength colour channels. Studies combined with photoreceptor-specific electrophysiological tests and histological evidences would be required in future.

FP-142

## Risk Factors for Band Keratopathy in Aphakic Eyes with Silicone Oil Tamponade for Open-Globe Injuries: A Multicenter Case-Control

M Liao<sup>1</sup>, H Yan<sup>2</sup>.

<sup>1</sup>Ophthalmology, Tianjin Medical University General Hospital, <sup>2</sup>Ophthalmology, Tianjin Medical University General Hospital, Tianjin, People's Republic of China

**Objective:** To identify the risk factors for band keratopathy (BK) in aphakic eyes following vitreoretinal surgical treatment with silicone oil tamponade for open-globe injuries.

**Methods:** This was a multicenter, case-control study. A total of 100 patients (100 eyes) who underwent vitrectomy combined with silicone oil tamponade following open-globe injuries with aphakia were included and divided into two groups: BK and non-BK groups. The factors related to BK were analyzed using multivariate binary logistic regression. Hierarchical interaction analysis was used to determine the outcome of BK with silicone oil retention time and zone of injury. Odds ratios (ORs) and 95% confidence intervals (CIs) were calculated. Restricted cubic splines with three knots at the 25th, 50th, and 75th centiles were used to model the association of silicone oil retention time with BK.

**Results:** The incidence of BK was 28% (28/100 eyes), of which 21 eyes had zone III open-globe injury ( $P=0.01$ ). Silicone oil retention time was significantly longer in the BK group ( $13.96 \pm 10.71$  months) than in the non-BK group ( $7.86 \pm 6.81$  months,  $P=0.001$ ). From the regression analysis, silicone oil retention time (OR=1.32; 95% CI: 1.06–1.21) and zone of injury (OR=6.88; 95% CI: 1.94–24.44) were significant risk factors for BK. From the hierarchical interaction analysis, silicone oil retention over 6 months had a significant risk for BK in eyes with rupture (OR=5.08; 95% CI: 1.42–18.16,  $P=0.01$ ), aniridia (OR=9.84; 95% CI: 1.26–76.74,  $P=0.01$ ), and zone III injury (OR=7.74; 95% CI: 1.76–34.10,  $P=0.03$ ), while zone III injury had a significant risk for BK in eyes with rupture (OR=6.84; 95% CI: 1.69–27.69,  $P=0.01$ ), incomplete/complete iris (OR=13.80; 95% CI: 2.76–69.08,  $P=0.001$ ), and silicone oil retention over 6 months (OR=7.71; 95% CI: 1.73–34.73,  $P=0.01$ ). From the restricted cubic splines of silicone oil retention time, there was a marked increase in the risk for BK at  $\geq 10$  months and a slow increase after 6 months, but almost stable within 4–6 months.

**Conclusion:** In eyes following vitreoretinal surgical treatment with silicone oil tamponade for open-globe injuries with aphakia, silicone oil retention time over 6 months and zone III injury were independent risk factors for BK. The risk of BK increases sharply after 10 months of silicone oil tamponade.

FP-143

## Development and clinical validation of intelligent prediction technology for reconstruction of ocular light perception

X Meng, S Zhang<sup>1</sup>, H Lin<sup>2</sup>, M Li<sup>1</sup>, H Yan<sup>3</sup>.

<sup>1</sup>Tianjin Medical University, Tianjin, <sup>2</sup>Zhongshan Ophthalmic Center, Sun Yee-sen University, Guangzhou, Guangdong, <sup>3</sup>Ophthalmology, Tianjin Medical University General Hospital, Tianjin, People's Republic of China

**Objective:** To develop and validate a new machine learning model to predict the results of light reconstruction in severe ocular trauma, and to investigate the feature contribution of the model.

**Methods:** 18 research centers in China were identified to define a set of criteria for NLP eyes after severe ocular trauma, and after discussion among the project team experts, 16 clinical features were decided to be used to describe the clinical data. After pre-process and normalize the collected clinical data, interpolate the missing values by the method of Multiple Imputation by Chained Equations (MICE), the largest database to date were established, and the machine learning model were built using the nested cross-validation (CV) strategy.

**Results:** Compared with the traditional Ocular Trauma Score (area under the receiver operating characteristic curve (AUC) = 0.49), our model showed a high accuracy with AUC of 0.75 and 0.90 in preoperative and postoperative application scenarios. Compared to ophthalmologists, our machine learning model showed better sensitivity (preoperative scenario 0.73 vs 0.57, postoperative scenario 0.87 vs 0.64). In order to verify the accuracy of the model in the real world, we conducted a 7-month real-world application validation at the Ophthalmology Department of the General Hospital of Tianjin Medical University, and the results showed that the AUC in the preoperative and postoperative application scenarios was 0.62 and 0.93 respectively. In order to determine the contribution of clinical features to vision prognosis, we decomposed the contribution of 16 clinical features to individual prediction by SHapley Additive exPlanations (SHAP) method, and found that wound length-related indicators, vitreous status and retina-related indicators contributed highly. In clinical applications, the ML model is able to calculate the contribution of clinical indicators to vision outcome at the individual level.

**Conclusion:** The machine learning model has achieved a breakthrough in predicting the results of eye light reconstruction, and the prediction is accurate and reliable, which has reference significance in clinical decision making.



FP-144

## Presentations, management and factors affecting outcomes in posterior segment open globe injuries – An analysis of 2360 eyes

V Dave, A Das<sup>1</sup>.

<sup>1</sup>Department of eyeSmart EMR & AEye, LV Prasad Eye Institute, Hyderabad, India

**Objective:** To report the clinical presentations, management and factors affecting outcomes in posterior segment open globe injuries in 2360 consecutive eyes

**Methods:** This was a retrospective, consecutive, non-comparative interventional case series. The study was conducted at 4 tertiary eye care centers in southern India. All cases of scleral and corneo-scleral tear repair presenting to our institute centers from January 2014 to January 2021 were included. The cases were defined as penetrating injury, globe rupture and perforating injury as per the BETTS classification. Detailed demographic and clinical data was retrieved by the institute electronic medical records. The ocular trauma score (OTS) was applied to the dataset.

**Results:** Mean age of presentation was  $36.63 \pm 19.92$  years (median 35 years). Penetrating trauma accounted for 70.92%, rupture for 18.6%, perforation for 4.6% and intraocular foreign body in 5.88% of all cases. Zone of injury was seen involving 1 & 2 in 76.6% and either only in 2 or extending from 2 till 3 in 23.4%. Vision recorded at presentation was logMAR  $3.03 \pm 0.99$  (median 3.5). Time interval between presentation to the clinic and globe repair was  $13.93 \pm 19.56$  hours (median 7.6 hours). Favorable functional outcome was seen in 29.2% eyes and a favorable anatomic outcome in 66.9%. In multivariate regression, decreasing age at presentation (OR 1.02), penetrating injury instead of rupture or perforating injury (OR 1.38), a higher OTS (OR 2.62), absence of corneal involvement (OR 2.5), absence of retinal detachment at presentation (OR 3.27) and absence of concurrent orbital fracture (OR 3.33) were associated with a favorable functional outcome. The final visual acuity in logMAR was correlated with the OTS value at presentation (Correlation coefficient -0.51,  $p < 0.0001$ ).

**Conclusion:** In the absence of concurrent corneal involvement, retinal detachment and orbital fracture, posterior open globe injuries can have a favorable functional outcome. The OTS correlates with the final visual acuity.

FP-145

**Intraocular foreign body removal: Magnet or forceps? Both!**M Parlak<sup>1</sup>, A Wolf<sup>1</sup>, J Werner<sup>1</sup>.<sup>1</sup>*Department of Ophthalmology, Ulm University Medical School, Ulm, Germany*

**Objective:** Intraocular foreign bodies (IOFB) can typically be removed with (foreign body) forceps or with a bar magnet. One advantage of magnet removal is that picking up the foreign body is less traumatic. In contrast, grasping with forceps prevents stripping of the foreign body from the magnet as it passes through the sclera.

To determine whether the advantages of both methods can be combined by magnetizing typical disposable forceps.

**Methods:** After preliminary testing, a protocol for effective and feasible magnetization was determined. An end gripping 23 G forceps according to Eckardt from Alcon was guided on a microcontroller-directed linear guide with closed branches at constant speed over an electromagnet (Fa. Oculus, Germany). The magnetic flux density at the tip of the forceps was measured before and after magnetization with a Hall effect sensor. Subsequently, steel balls with ascending weight, which were in balanced salt solution (BSS), were used to test the mass that can be lifted with such magnetized forceps.

**Results:** Before magnetization, the forceps were virtually non-magnetic at the tip with a magnetic flux density of 0.49 mT. Magnetization increased the magnetic flux density by 7.12 mT. While the non-magnetized forceps was unable to lift the smallest available steel ball weighing 13.74 mg in BSS, the magnetized forceps was able to lift steel balls weighing up to 87.43 mg.

**Conclusion:** Contrary to popular belief, stainless steel can be magnetized under certain conditions. The procedure applied here using an electromagnet from ophthalmic surgery can be performed quickly and easily, even under sterile conditions. The magnetic flux density that can be generated at the tip of the forceps used here is sufficient to lift steel intraocular foreign bodies of typical weight. Thus, the advantages of the different procedures for the removal of intraocular foreign bodies can be combined.

FP-146

**Comparison of Ocular Trauma Between Normalized and the COVID-19 Epidemic Periods in China**? 亚欣<sup>1</sup>, H Yan<sup>1</sup>.<sup>1</sup>Ophthalmology, Tianjin Medical University General Hospital, Tianjin, People's Republic of China

**Objective:** To compare the feature of ocular trauma between normalized period and the COVID-19 epidemic period in China, to provide a scientific basis for prevention and control eye injuries in special times in future.

**Methods:** This study is a multi-center cross-sectional study with 30 participated hospitals involving the China Ocular Trauma Society members. All hospitalized cases who visited the ophthalmology department in participated hospitals with eye injuries during the normalized period (2019) and the COVID-19 epidemic period (2020) were included in this study. Demographic characteristic of cases, date of injury, sites and types of injury were collected.

**Results:** This study involved 13525 (61cases with both eyes) injured cases. There were 7269 (53.74%) eye-injured cases and 6256 (46.26%) eye-injured cases in 2019 and 2020 separately. Compared with 2019, the incidence of ocular trauma in retirees, housewives and unemployed increased with year-on-year of 4.96%, 102.67% and 11.64% among all occupations. In 2020, the incidence of eye injuries decreased in all injury sites except for an increase in home (30.29% year-on-year). The incidence of mechanical eye injuries decreased, while that of non-mechanical eye injuries (Chemical/Thermal/Radiation) increased (47.45% year-on-year). There were 255 (3.50%, 255/7269) and 376 (6.01%, 376/6256) non-mechanical injured cases in 2019 and 2020 (Pearson  $\chi^2 = 47.33$ ,  $P < 0.001$ ) separately.

**Conclusion:** During the COVID-19 epidemic period, the incidence of eye injuries decreased. The prevention and control measures should be focused on the non-mechanical injuries, and the retirees, unemployed and housewives during public events period in future.

FP-147

**New predictive model to predict visual outcome in younger children following mechanical ocular injuries and comparison with other**M Shah<sup>1</sup>, S Shah<sup>1</sup>.<sup>1</sup>Ocular Trauma, Drashti Netralaya, Dahod, India

**Objective:** This study was designed to compare the prognostic value between OTS POTS and TOTS in a cohort of Indian children with mechanical eye injuries causing traumatic cataracts.

**Methods:** This was a prospective, interventional case series study and included consecutive children with mechanical globe injuries operated for traumatic cataracts at the Drashti Netralaya. The medical records collected in online pretested form which included the circumstance and time of injury, type of penetrating injury, initial and final visual acuity (VA), time of surgery, and associated eye disease. OTS, POTS and TOTS scores were calculated according to specific variables. The final VA achieved for each patient was compared with that predicted for all scores with the Fischer's exact test; accuracy, sensitivity, and specificity were calculated for each score using AUROC.

**Results:** Study cohort included 124 eyes. Mean age was  $4.6 \pm 1.29$  years; 44 (35.41%) were female and 74 (64.5%) were male, Management of traumatic cataracts caused significant improvement in visual outcome ( $p=0.000$ ) and no difference found amongst open and closed globe injuries. ( $p=0.162$ ) When we compared actual achieved results and predicted visual outcome from all three models did not find significant difference. While on comparing low risk injuries using ROC curves sensitivity and specificity was better in TOTS and POTS while OTS was found to be better higher risk cases.

**Conclusion:** In this cohort of Indian children with traumatic cataracts because of mechanical globe injuries the TOTS and POTS had better accuracy than OTS in predicting VA after treatment in toddlers. However, all scores are helpful to estimate of the potential VA after treatment.

FP-148

**Physical characteristics of intraocular foreign bodies: a clinical correlation**M Parlak<sup>1</sup>, A Wolf<sup>1</sup>, J Werner<sup>1</sup>.<sup>1</sup>*Ophthalmology, Ulm University Medical School, Ulm, Germany*

**Objective:** Penetrating injuries with intraocular foreign bodies (IOFB) remain a major cause of ocular morbidity worldwide. Depending on the course of the accident, they can result in a wide range of complications. This study aimed to determine the physical characteristics of IOFBs and investigate the correlation to the injury pattern.

**Methods: Venue:** Ulm University Clinic, Ophthalmology Department, Laboratory of Ocular Pathology

Intraocular foreign bodies retrieved between January 2018 and January 2022 were investigated in terms of dimension, weight, shape, and magneticity. For this purpose, a macroscope with a calibration ruler (Leica M420, Leica Microsystems, Wetzlar/Germany), a micrometer screw, and an analytical balance (AR1530, Ohaus, Nänikon/Switzerland) were used. To classify the IOFB shape, various length, width, and thickness indices were calculated. In addition, clinical records, imaging data, and surgery reports were analyzed retrospectively to determine the course of the accident, entry point, and final intraocular position. Only foreign bodies which break through the cornea or sclera were included.

**Results:** Thirty-seven IOFBs were removed in the study period. Of these, 25 met the inclusion criteria. Most IOFBs consisted of metal and were magnetic (n=22; 88%). Two IOFBs consisted of glass, and one was made of wood. The mean length, width, and thickness were 4,88mm, 1,72mm, and 0,86mm. The average weight was 21,25mg (0,2-112mg; SD: 31mg). Final intraocular position of foreign bodies showed strong variation (lens=1, sclera=1, suprachoroidal space=3, vitreous=4, anterior chamber=6 and retina/choroid=11). The most common shape of the IOFBs was a spearhead with a length/width index between 1,5 and 10 (16; %64). All wire-shaped foreign bodies, which had a length/width index over 10, entered the limbal cornea and penetrated the suprachoroidal space. The major cause of ocular injury was hammering (12; 46%).

**Conclusion:** To break through the corneal or scleral rigidity, foreign bodies must have specific physical properties and sufficient kinetic energy during impact. Special foreign body shapes can also lead to corresponding injury patterns. These precise measurement data can be necessary for future investigations in material research or the development of ophthalmic instruments.

FP-149

**Ocular trauma during COVID-19 pandemic: a systemic review and meta-analysis**L Huiyu.

**Objective:** This study aims to summarize the current literature on the incidence of ocular trauma during the COVID-19 pandemic.

**Methods:** A systematic literature search was conducted to identify the relevant literature. The search period was between January 1, 2020 and September 20, 2021. The incidence of overall and various types of ocular trauma during the COVID-19 pandemic and the control period was analyzed. The data from different studies were pooled. The odds ratio (OR) and 95% confidence interval (CI) were calculated.

**Results:** A total of 32 articles were included. After pooling the data from all included studies, the incidence of total and pediatric ocular trauma during the COVID-19 pandemic was 67.7% and 54.3% of those in the control period, respectively. However, the proportion of ocular trauma in eye emergency visits increased during the pandemic (OR, 95% CI: 1.46, 1.04–2.06). The proportion of domestic ocular trauma increased (OR, 95% CI: 3.42, 1.01–11.62), while ocular trauma related to sports and outdoor activities decreased (OR, 95% CI: 0.64, 0.09–4.29). It was also reported that chemical injury caused by alcohol-based sanitizers, photokeratitis caused by ultraviolet lamps, and mechanical eye injury caused by masks increased during the COVID-19 pandemic.

**Conclusion:** There was a reduction in overall eye injuries during the COVID-19 pandemic, and substantial differences in the spectrum of ocular trauma presentations to the emergency units during this period. Proper health education and supervision should be strengthened to prevent ocular injuries related to COVID-19 preventive interventions.

FP-150

## A Quantitative Analysis of War-related Ocular Trauma Literature

D Pavlenko<sup>1</sup>.

<sup>1</sup>*Department of Ophthalmology, Bogomolets National Medical University, Kyiv, Ukraine*

**Objective:** To explore the literature related to combat and wartime ocular trauma and characterize it using bibliometric analysis.

**Methods:** The Core Collection of Clarivate Web of Science was used to search the titles with relevant keywords. Only publications until 2021 were included. The "Citation Report" function was used to determine the h-index of the research topic and the number of citations. "Bibliometrix" and "Biblioshiny" (Aria, M. & Cuccurullo, C., 2017) R-packages (RStudio, PBC, Boston, MA) were utilized for scientific production, author, authors collaboration, and citation analyses.

**Results:** One hundred papers published in 48 sources by 336 authors between 1974 and 2021 were included. The English language was predominant (n=93; 93.0%), and the average years from publication was 14.9. There were 68 (68.0%) articles and 6 (6.0%) review articles. The collaboration index was 3.8, and 16 documents (16.0%) were single-authored. There were 0.3 documents per author and 3.4 authors per document. The annual growth rate was 0%, and 2021 was the most productive year (n=8; 8.0%). The most prolific journals were *Military Medicine* (n=12; 12.0%), *Investigative Ophthalmology & Visual Science* (n=9; 9.0%), *Ophthalmology* (n=8; 8.0%), and *Journal of Trauma Injury Infection and Critical Care* (n=5; 5%). Also, only these 4 journals were the core sources, according to Bradford's law of scattering. When the source local impact was analyzed by the h-index, *Ophthalmology* (h-index=8) and *Military Medicine* (h-index=5) were at the top. Colyer MH (n=17; 17.0%), Weichel ED (n=13; 13.0%), and Ryan DS (n=10; 10.0%) contributed mostly, while Colyer MH, Mader TH, and Weichel ED had the highest number of local citations (60, 57, and 55, respectively). The Walter Reed National Military Medical Center (USA; n=23; 23.0%), Uniformed Services University of the Health Sciences (USA; n=17; 17.0%), and Shahed University (Iran; n=14; 14.0%) were the most prolific institutions. The h-index of the research field was 18. The corresponding author most likely was from the USA (n=49; 49.0%). The USA, Iran, and Israel were leading by the number of citations. Iran, the USA, and Germany had the highest average article citations. The total number of citations was 1,517, with average citations per document of 15.2 and average citations per year per document of 1.0.

**Conclusion:** Despite there is not much literature on combat and wartime eye injuries and no annual growth rate, the citations per document suggest its high importance.

**FP-151****Ocular Trauma: Epidemiology, visual and surgical predictive variables, prognostic models, and economic cost analysis**

B Lee<sup>1234</sup>, D Hunter<sup>5</sup>, D Robaei<sup>34</sup>, C Samarawickrama<sup>134</sup>.

<sup>1</sup>Translational Ocular Research and Immunology Consortium (TORIC), The Westmead Institute for Medical Research,

<sup>2</sup>Faculty of Medicine, University of New South Wales, <sup>3</sup>Sydney Medical School, University of Sydney, <sup>4</sup>Ophthalmology, Westmead Hospital, <sup>5</sup>Centre for Vision Research, The Westmead Institute for Medical Research, Sydney, Australia

**Objective:**

Open globe injuries (OGI) represent a visually and economically devastating cause of vision loss. This study examines the epidemiology, predictive variables, prognostic models, and economic cost of surgically managed OGI.

**Methods:**

Retrospective tertiary centre study from 2008-2018 of 155 consecutive OGI in individuals aged over 16 was performed. Medical records review, application of Ocular Trauma Score (OTS) and Classification and Regression Tree Analysis (CART) and economic cost analysis were undertaken. Key outcomes measured were values predictive of visual acuity (VA) and number of operating theatre visits, prognostication using OTS and CART and costs.

**Results:**

Younger males at work with inadequate protective eyewear (89.1%) and falls in the elderly were overrepresented. Presenting mean VA was  $2.04 \pm 0.97$  logMAR (Count Fingers) and this improved to  $1.40 \pm 1.16$  logMAR (6/150) at final followup. Inferior visual outcomes were associated with a more severe OTS score, a larger injury zone, increasing age, the presence of retinal detachment, extraocular muscle involvement, intraocular foreign body, and globe rupture ( $R^2=0.723$ ,  $p<0.001$ ). In total, 494 surgeries were completed. Multiple operating theatre visits were required in the presence of retinal detachment, lens or orbit involvement, work-related injury, globe rupture, and a history of previous intraocular surgery ( $R^2=0.0423$ ,  $p<0.001$ ). Both the OTS and CART prognosticated outcomes ( $p<0.001$ ). The OTS predicted for no vision (no light perception/enucleation/evisceration) and profound visual loss (worse than 6/120; specificity: both 100%, sensitivity: 88.2% and 88%) whereas the CART predicted for visual survival (light perception or better) and minimal-to-severe visual loss (6/120 or better; specificity: 88.5% and 81.7% , sensitivity: 97.7% and 100%). The estimated annual cost of OGI for Australia was AUD48.1–60.5 million (USD37.3–47.0 million).



**Conclusion:**

The total cost of OGI is immense with young males and the elderly being disproportionately affected. OGI impose a disproportionate cost on the individual, workforce, healthcare system and society at large. It is imperative that ophthalmologists, their organisational bodies, and governments work collaboratively to reduce this enormous medical and societal burden. Implementation of targeted government legislation and public health preventative measures may be cost-effective in ameliorating the significant burden.

FP-152

**Profile and Management Outcomes of Fireworks Ocular Injury in Saudi children**H AlGhadeer<sup>1</sup>.<sup>1</sup>King Khaled Eye specialist hospital, Riyadh, Saudi Arabia

**Objective:** To explore the demographic profiling, causes, types, complications, management outcomes, and severity of fireworks-inflicted ocular injuries in children in KSA.

**Methods:** This is a retrospective study of 115 cases with eye injuries managed at the Emergency Department, of our institution between 2003 and 2019. Demography, clinical features at presentation, mode of management and the Best-corrected visual acuity (BCVA) were evaluated at the last follow-up.

**Results:** The study included 117 eyes of 115 children [median age: 9 years; 96 (83.5%) boys; 19 (16.5%) girls]. Fifty-six (48.7%) participants were bystanders. The injuries were caused mainly due to bangers (n=47; 40.9%), rockets in bottle (n=28; 24.3%), firecrackers (n=27; 23.5%), and nonspecific reasons (n=13; 11.3%). The children had presented with various severity levels: corneal abrasion (n=52; 44.4%); cataract (n=47; 40.2%); penetrating injury (n=40; 34.2%); secondary glaucoma (n=22; 18.8%); subluxated lens (n=19; 16.2%); limbal stem cell deficiency (n=14; 12.0%); Iridodialysis (n=12; 10.3%), and vitreous hemorrhage (n=11; 9.4%). Management interventions of the eyes under study included: penetrating injury repair (n=40; 34.2%), lens removal plus intraocular lens implantation (n=26; 22.2%), removal of foreign body (n=9; 7.7%). The BCVA after six months was 20/20 to 20/60 in 49 (41%) cases; 20/70 to 20/200 in 27 (23.1%) cases; <20/200 to 20/400 in 7 (6%) cases, and <20/400 in 34 (29.1%) of the cases. Out of 51.3% eyes with <20/200 before management, only 35% recorded severe visual impairment.

**Conclusion:** Fireworks-related eye injuries were mainly observed in boys primarily due to the use of bangers. Visual disability remained in one-third of the managed cases.

FP-153

## A Deep Learning Approach with Cascade-network Design for Eyelid Tumors Diagnosis Based on Gigapixel Histopathology Images

L Wang<sup>1</sup>, D Lv<sup>2</sup>, J Ye<sup>1</sup>.

<sup>1</sup>Department of Ophthalmology, The Second Affiliated Hospital, Zhejiang University School of Medicine, <sup>2</sup> The Key Lab of RF Circuits and Systems of Ministry of Education, Microelectronics CAD Center, Hangzhou Dianzi University, Hangzhou, People's Republic of China

**Objective:** To develop a robust diagnostic deep learning system (DLS) to detect eyelid tumors using digital histopathological sections.

**Methods: Setting:** Double institutional retrospective study.

**Study Population:** 794 haematoxylin-eosin [H&E] stained whole slide images (WSIs) were used to generate 473,037 pathological patches.

**Observation Procedures:** A DLS was developed to distinguish the most common five benign and four malignant eyelid tumors from WSIs using a training set, with and without cascade-network design. The model was evaluated in a test set from the same population for model development, as well as an independent test set. Visualization heatmaps for pathologic images were made utilizing the probability of malignancy estimated by the DLS.

**Main Outcome Measure(s):** Area under the receiver operating characteristic curve, accuracy, sensitivity, specificity, precision, and F1-score were used to evaluate the efficacy of the DLS for classification. An independent subsample was used to estimate generalizability.

**Results:** Our model utilizing cascade-network design achieved 1.0 and 0.946 accuracy in the test and independent test set, respectively, for benign and malignant binary classification; without cascade-network design, accuracy was 0.957 and 0.887, respectively. For multiple classification of individual disease, the DLS with cascade-network design achieved 0.989 and 0.931 overall accuracy for WSI diagnosis in the test set (9-class) and independent test set (8-class) respectively, while without cascade design achieved 0.774 and 0.662.

**Conclusion:** This DLS, using cascade-network design, can automatically detect malignancy in histopathologic slides of common eyelid tumors with a high degree of accuracy, which has potential to augment histopathological diagnosis for a wide range of tumors.

FP-154

**Assessment of Orbital Tissue Biomechanics with Quantitative T1 Mapping MRI in Graves' Orbitopathy**R Ma, X Li, Z Peng, J Guo, J Qian.

**Objective:** Direct measurement of orbital tissue biomechanics requires invasive maneuvers. T1 mapping MRI may noninvasively evaluate intraorbital pressure (IORP) and orbital compliance in Graves' orbitopathy.

**Methods:** Our study prospectively recruited 30 cases of moderate-to-severe active GO without dysthyroid optic neuropathy (GO group) and 15 cases of DON (DON group). Medical records were collected, including clinical activity score (CAS), intraocular pressure (IOP) and exophthalmos. The extracellular volume (ECV) was quantified on T1 mapping sequence. The optic nerve subarachnoid space (ONSS) was quantified on T2-weighted sequence. The muscle index was calculated on CT scan. After treatment with systemic steroids, both IORP and compliance were measured during orbital decompression surgery. Logistic/linear regression, receiver operating characteristic (ROC) curve and area under ROC (AUC) were adapted for data analysis.

**Results:** Upon recruitment, both clinical (CAS, IOP) and imaging (ECV, muscle index, but not ONSS) parameters significantly differed between the GO group and the DON group. ECV was able to distinguish DON (odds ratio = 1.13,  $P=0.031$ ) with a sensitivity of 76% and a specificity of 63% at cut-off value of 19.3% (AUC = 0.706). A combination of ECV ( $P=0.069$ ) and IOP ( $P=0.014$ ) showed better performance to predict DON (AUC = 0.816). After steroid treatment, 23 cases (76.7%) in the GO group achieved positive response, resulting into significant decrease of CAS from  $3.4 \pm 0.7$  to  $1.4 \pm 0.7$  ( $P<0.001$ ). A combination of ECV ( $P=0.066$ ) and muscle index ( $P=0.030$ ) was able to predict positive steroid response (AUC = 0.820). Regarding to biomechanics, the GO group exhibited lower IORP ( $8.70 \pm 3.50$  vs  $15.33 \pm 1.84$  mmHg,  $P<0.001$ ) and higher compliance ( $3.50 \pm 1.91$  vs  $1.38 \pm 0.27$ ,  $P<0.001$ ) than the DON group. Linear regression detected significant effects of ECV ( $P<0.001$ ) and exophthalmos ( $P=0.012$ ) on prediction of IORP and compliance in the GO group, reaching the formulas: IORP (mmHg) =  $0.27 * \text{ECV} (\%) + 0.71 * \text{exophthalmos} (\text{mm}) - 11.23$ ; compliance =  $13.46 - 0.14 * \text{ECV} (\%) - 0.35 * \text{exophthalmos} (\text{mm})$ .

**Conclusion:** ECV combined with exophthalmos were reliable to predict IORP and compliance in non-DON GO orbits, providing insights into noninvasive measurement of orbital tissue biomechanics.

FP-155

**Demographic study and risk factor analysis in patients of Mucormycosis: A current scenario**

A Maharana, N Mishra<sup>1</sup>, A Kaur<sup>1</sup>.

<sup>1</sup>*ophthalmology, King George's Medical University, Lucknow, India*

**Objective:** To study the demographics and various risk factors in patients with Mucormycosis in current COVID scenario.

**Methods:** Retrospective data analysis of 351 patients of Mucormycosis treated at our tertiary care institute over a period of 2 months (June and July, 2021) was done. Computer records were obtained regarding the demography along with relevant positive and negative history to analyze the disease distribution and risk factors association. Clinical and radiological examinations done as per the institutional protocol. These patients were managed in special mucor ward designed by the institution.

**Results:** Age distribution ranges from 17 to 79 years with maximum in age group 30-65 years (47.9%) and male predominance of 1.8:2. Mean age of distribution was 50.7 +/- 11.6 years. 53% of patients came from urban areas. Risk factor analysis showed an association of 80% with diabetes mellitus, 43% with COVID-19 infection, 34% with oxygen therapy, 26% with hypertension, 23.5% with steroid use, 2.3 % with cardiac disease, 1.7% with use of ventilator in past and 0.6% with asthma. 235 patients had ophthalmic complaints (67%) at time of presentation. Imaging revealed paranasal sinus involvement (87%), orbital involvement (59%) and CNS involvement (22%).

**Conclusion:** In the current scenario, the burden of Mucormycosis appears to be more on middle aged population, particularly those from urban areas. History of COVID infection, uncontrolled diabetes mellitus, oxygen supplementation and steroid use were the important risk factors implicated. Having a high index of suspicion, targeting the susceptible population having the implicated risk factors, we can detect this dreadful disease early in its course, and can spare the person from a lifelong comorbidity or even death.

FP-156

### Comparative Evaluation of DCR with Retrograde Bicanalicular Intubation and Conjunctivo-DCR in Proximal-mid Bicanalicular Blocks

P Golhait<sup>1</sup>, R Goel<sup>1</sup>, S Khanam<sup>1</sup>, S Raghav<sup>1</sup>.

<sup>1</sup>Ophthalmology, Maulana Azad Medical College, New Delhi, India

**Objective:** To compare the outcomes of dacryocystorhinostomy with retrograde bicanalicular intubation (DCR-RBI) & conjunctivo-DCR (CDCR) in proximal-mid bicanalicular blocks with  $\leq 6$ mm patent canaliculus.

**Methods:** We conducted this study for 12 months wherein 50 such eyes were randomly divided into 2 equal groups A & B. Group A underwent DCR-RBI & group B underwent CDCR. In group A, during DCR the common internal opening was identified within the sac. Pseudopuncta were created for both the canaliculi by passing a probe retrogradely till a soft stop was felt, followed by an incision at tip of the probe. The canaliculi were intubated through the pseudopuncta & the tube was removed at 6 weeks. In group B, standard CDCR was performed with a straight, glass lacrimal bypass tube.

**Results:** Success was defined as patency on syringing, negative fluorescein dye disappearance test & relief in epiphora at end of 12 months. The success rate of group A & group B was 100% & 88% respectively ( $p=0.74$ ). Group B had a higher complication rate compared to that of group A ( $p=0.001$ ).

**Conclusion:** Though the success was comparable, DCR-RBI had lesser reinterventions, utilised the remaining normal canaliculus, precluded long-term maintenance of bypass tube & thus is an effective alternative to CDCR in proximal-mid bicanalicular blocks.

FP-157

### The efficacy of orbital decompression combined with strabismus surgery in the treatment of thyroid-associated ophthalmopathy

W Xu, X Yang.

**Objective:** Thyroid-associated ophthalmopathy (TAO) clinical manifestations are diverse, including proptosis, eyelid retraction, strabismus and diplopia, exposure corneal lesions and visual impairment, etc. The surgical treatment of TAO was carried out by three steps nowadays, that is, orbital decompression, strabismus correction and eyelid surgery. In recent years, some studies have found that orbital decompression combined with strabismus correction or eyelid surgery could shorten the recovery period and has good results as well, indicating a prospect clinical application. Our study aimed to observe the therapeutic effect of orbital decompression surgery combined with strabismus correction surgery on TAO, and to analyze the relevant factors affecting the effect.

**Methods:** This is a retrospective case study. The clinical data were collected from patients with TAO with restrictive strabismus and accepted balanced orbital decompression together with strabismus correction surgery during January 2021 and January 2022 in our department. Main outcome measures included best corrected vision acuity, proptosis, ocular position and ocular movement, diplopia.

**Results:** Balanced orbital decompression surgery effectively reduced the proptosis in TAO patients ( $17.75 \pm 0.42$  mm vs  $22.4 \pm 0.42$  mm,  $P < 0.001$ ), alleviated optic nerve compression and improved visual acuity (LogMAR,  $0.22 \pm 0.06$  vs  $0.52 \pm 0.09$ ,  $P < 0.05$ ), strabismus correction surgery effectively alleviated the patients' diplopia (85% success rate). Young age, smaller interocular exophthalmos difference, unsatisfactory orbital decompression outcome (smaller differences in preoperative and postoperative proptosis), and restrictive strabismus of both eyes may be the adverse factors of outcome.

**Conclusion:** Balanced orbital decompression combined with strabismus correction surgery produced satisfactory outcomes as well as shortened postoperative recovery period for TAO patients, it could be an effective surgical solution for the treatment of TAO with restrictive strabismus.

FP-158

## Using the Random Forest Algorithm to Detect the Activity of Thyroid-associated Ophthalmopathy

M Wang<sup>1</sup>, D Li<sup>1</sup>.

<sup>1</sup>Beijing Tongren Eye Center, Beijing Tongren Hospital, Beijing Ophthalmology and Visual Science Key Lab, Capital Medical University, Beijing, China, Beijing, People's Republic of China

**Objective:** The aim of this study is to establish a random forest model to detect active and quiescent phases of patients with Thyroid-associated ophthalmopathy (TAO).

**Methods:** A total of 243 patients (486 eyes) diagnosed with TAO in Beijing TongRen hospital were included in the study. The clinical activity score of TAO was regarded as the golden standard, while gender, age, smoking status, I-131 treatment history, thyroid nodules, thyromegaly, thyroid hormone and TSH-receptor antibodies (TRAb) were chosen as predictive characteristic variables in the model. Finally, the model's accuracy, precision, sensitivity, specificity, positive predictive value (PPV), negative predictive value (NPV), F1 score and out-of-bag (OOB) error were analyzed, with the accuracy, the brier loss and the area under the receiver operator characteristic curve (AUC) compared to logistic regression model.

**Results:** Our model has a sensitivity of 0.81, a specificity of 0.90, a positive predictive value of 0.87, a negative predictive value of 0.86, an F1 score of 0.85 and an OOB error of 0.15. The random forest model performed more precisely and reliably than the logistic regression model with regard to accuracy (0.86 vs. 0.66), brier loss (0.14 vs 0.34) and AUC (0.92 vs 0.76).

**Conclusion:** By integrating these high-risk factors, the random forest algorithm may be used as a complementary diagnostic method to determine the activity of TAO, with precise and reliable performance.



FP-159

**Alteration in Retrobulbar Hemodynamics after Orbital Decompression Surgery for Thyroid Eye Disease**S Shah<sup>1</sup>, R Goel<sup>1</sup>, M Chhabra, S Kumar, S Khanam.<sup>1</sup>Ophthalmology, GURU NANAK EYE CENTRE, NEW DELHI, India

**Objective:** Perfusion biomarkers in thyroid eye disease (TED) are an important predictor for the pathogenesis of dysthyroid optic neuropathy (DON). Inactive TED shows reduced orbital blood flow with an increased resistance index in the orbital arteries. We plan to evaluate the exact effects of orbital decompression surgery on arterial, venous and capillary beds in orbit.

**Methods:** 20 euthyroid inactive moderate-to-severe TED patients with no other ocular diseases underwent detailed evaluation and surgical orbital decompression. Colour Doppler imaging was used to evaluate the flow patterns in the ophthalmic artery (OA), central retinal artery (CRA), and superior ophthalmic vein (SOV). Optical coherence tomography (OCT) was used to calculate subfoveal choroidal thickness (SFCT). OCT angiography (OCTA) was used to study retinal and peripapillary circulation parameters. OCT retinal nerve fibre layer (RNFL) thickness was used to monitor for DON. All perfusion biomarkers were evaluated before the surgery and 3 months post-surgery.

**Results:** A significant reduction in proptosis and intraocular pressure was noted after orbital decompression surgery in all cases. A significant improvement was noted in peak systolic and end-diastolic velocities of OA and CRA, with a reduction in SOV dilatation post-surgery. SFCT has significantly reduced post-surgery. No significant changes were noted on OCTA. A decline in OCT RNFL values was noted post-surgery.

**Conclusion:** Orbital decompression surgery improves the orbital hemodynamics, possibly by resolution of the orbital volume conflict. A reduction in orbital perfusion parameters could herald the onset of ischemic DON. A timely intervention in form of early orbital decompression can help reduce the visual morbidity in TED cases.

FP-160

**Reconstruction strategy for congenital cryptophthalmia**D Huang<sup>1</sup>.<sup>1</sup>*Oculoplastic Department, Zhongshan Ophthalmic Center, Guangzhou, People's Republic of China***Objective:** To investigate the reconstruction strategy for congenital cryptophthalmia.**Methods:** A retrospective, noncomparative, clinical study. 30 patients (39 eyes) with congenital cryptophthalmia were diagnosed at Zhongshan Ophthalmic Center Sun Yat-Sen University between 2014 to 2019. Including 5 cases (6 eyes) of complete cryptophthalmia, 2 cases (2 eyes) of incomplete cryptophthalmia, and 25 cases (31 eyes) of abortive cryptophthalmia. For the patients with complete or incomplete cryptophthalmia, the cyst was found in the orbit in 3 cases, 1 patient manifested as microphthalmos. These patients underwent the primary enucleation and porous polyethylene sphere implantation. 6 months later, the patients received free flap transplantation, blepharoplasty, and conjunctival sac reconstruction. For the abortive cases, these patients underwent symblepharon separation, amniotic membrane transplantation, and eyelid reconstruction. 7 cases received keratoplasty.**Results:** For the complete or incomplete cryptophthalmia cases, 3 patients could wear prostheses with symmetric osseous development and a satisfying appearance. 1 case underwent secondary blepharoplasty and conjunctival sac reconstruction due to conjunctival sac stenosis and could wear a prosthesis after the operation. For the 25 abortive cases, all the patients had favorable eyelid appearance without symblepharon or eye globe movement restriction.**Conclusion:** Congenital cryptophthalmia severely impairs physiological function and appearance. Before the operation, a thorough evaluation of visual function and orbital development was needed. If there is a potential vision, the keratoplasty, blepharoplasty, and conjunctival reconstruction were needed as early as possible. If not, selective surgery of primary enucleation combined with porous polyethylene sphere implantation was needed. Then the patients could undergo secondary eyelid and conjunctival sac reconstruction. The prosthesis should be worn consistently after the operation.

FP-161

**Modified Guo-Heindl Approach for Three-dimensionally Evaluating Area and Volume of Upper Eyelids**

Y Guo<sup>1,2</sup>, A Rokoh<sup>3</sup>, T Gao<sup>1,2</sup>, K Yao<sup>1,2</sup>, L Heindl<sup>4</sup>.

<sup>1</sup>Eye Center, Second Affiliated Hospital, Zhejiang University School of Medicine, <sup>2</sup>Zhejiang University Eye Hospital, Zhejiang University, Hangzhou, People's Republic of China, <sup>3</sup>Department of Ophthalmology, University of Cologne, Faculty of Medicine and University Hospital of Cologne, <sup>4</sup>Department of Ophthalmology, University of Cologne, Faculty of Medicine and University Hospital Cologne, Cologne, Germany

**Objective:** Three-dimensional (3D) surface imaging and morphometrics is fast becoming the preferred craniofacial surface imaging modality. However, as a unique advantage of 3D imaging, areal and volumetric measurements have been rarely conducted and validated for assessing soft tissue change in the periorbital region, especially the upper eyelids. Therefore, we aimed to propose a strategy to define a standardized upper eyelid region for areal and volumetric measurements and validate its reliability.

**Methods:** Forty-four healthy adult volunteers were enrolled in this cross-sectional study. Three-dimensional facial images were taken with a 3D imaging system. Subsequently, with a modified landmarks localization strategy, the upper eyelid region selection and areal and volumetric measurements were conducted to evaluate their intra-rater, inter-rater, and intra-method reliability.

**Results:** Our findings indicated highly reliable results for areal measurement of the upper eyelid, i.e., intraclass correlation coefficient (ICC) 0.982, mean absolute difference(MAD) 0.1620 cm<sup>2</sup>, relative error measurement (REM) 2.9%, technical error of measurement (TEM) 0.1510 cm<sup>2</sup>, relative technical error of measurement (%TEM) 2.7% for intra-rater reliability; respectively 0.969, 0.2076 cm<sup>2</sup>, 3.7%, 0.1930 cm<sup>2</sup>, 3.5% for inter-rater reliability; and respectively 0.917, 0.3636 cm<sup>2</sup>, 6.5%, 0.3354 cm<sup>2</sup> and 6.0% for intra-method reliability. Whereas, unsatisfactory results were achieved for volumetric measurement than areal: for intra-rater reliability, ICC, MAD, REM, TEM, %TEM estimates were 0.992, 0.2299 ml, 10.3%, 0.2414 ml, and 10.8%, respectively; for inter-rater reliability, 0.985, 0.2749 ml, 12.3%, 0.3253 ml, and 14.6%, respectively; and for intra-method reliability, 0.433, 1.6716 ml, 77.9%, 2.0615 ml, and 96.1%, respectively.

**Conclusion:** This is the first study to propose a standardized upper eyelid region selection strategy and simultaneously validate its reliability for 3D areal and volumetric measurements. This study confirms the high-level reliability of areal measurement and poor reliability of volumetric measurement based on the direct measurement of a single image. It may give better results when combining this method with overlapping and registering image procedure, which is subject to further validation. Nonetheless, it could provide quantitative data for the areal and volumetric measurements of upper eyelids and might have widespread application potential in the future.

## FP-162

**Clinical research about correction of severe ptosis using a modified frontalis muscle suspension surgery**

L Zhang, H Zhao<sup>1</sup>, Y Pan<sup>1</sup>.

<sup>1</sup>Tianjin Eye Hospital, Tianjin, People's Republic of China

**Objective:** To introduce a modified frontalis muscle flap suspension for severe ptosis and evaluate the clinical effect of it.

**Methods:** All patients underwent a modified frontalis muscle flap suspension approach. Frontalis muscle was exposed by a crease incision. The procedure involved dissection between the orbicularis muscle and septum until supraorbital margin, subcutaneously separating frontalis muscle at the lower edge of the eyebrow without temporal cutting vertically until 0.5cm above the eyebrow. All patients underwent pre- and postoperative photography, and final outcomes were assessed after a minimum of 6 months. Outcome measures included pre- and post-marginal reflex distance (MRD1), symmetry of height, contour and complications.

**Results:** 258 patients undergoing 343 procedures were included. The mean postoperative MRD1 was 3.05mm. 229 patients achieved their desired lid height and contour, and 29 patients had under-correction, with a final success rate of 88.8% (229/258 patients). Complications such as exposure keratitis, frontal paralysis, frontal hypoesthesia, severe hematoma were not seen in our series.

**Conclusion:** Our modified frontalis muscle suspension technique showed a high success rate. It only needs a crease incision to complete the operation. The whole operation under direct vision has the advantages of clear operation field, less bleeding, mild damage and fewer complications. It is a reasonable alternative in severe ptosis and is very suitable for beginners to master.

FP-163

## Meibomian Gland Dysfunction not Ocular Surface Exposure determines Tear Film Instability In Thyroid Associated Orbitopathy

X Liao<sup>1</sup>, K Lai<sup>1</sup>, C Pang<sup>1</sup>, C Tham<sup>1</sup>, K Chong<sup>1</sup>.

<sup>1</sup>Department of Ophthalmology and Vision Sciences, The Chinese University of Hong Kong, Hong Kong, Hong Kong, China

**Objective:** To compare the association of MGD, ocular surface exposure with tear film instability in thyroid associated orbitopathy (TAO).

**Methods:** A prospective cohort of TAO patients managed at the Chinese University of Hong Kong from January to March 2022. Ocular surface parameters included ocular surface disease index(OSDI), tear meniscus height(TMh), non-invasive tear break up time(NIKBUT) by keratography; partial blinking rate, lipid layer thickness(LLT) by interferometry, meibomian gland dropout(meiboscore) on infrared meibography, Schirmer's test, and slit-lamp evaluation of punctate epithelial erosions(PEE). 7-item clinical activity score(CAS), intraocular pressure(IOP) at primary and upgaze, ocular surface exposure by margin reflex distance of the upper and lower eyelid(MRD1 and MRD2), lateral flare, lagophthalmos, exophthalmometry were evaluated by a single orbital surgeon.

**Results:** 320 eyes from 80 TAO patients(59 females) and 80 healthy control(HC, 51 females) were examined. The mean(SD) age of TAO patients was 45.50(12.22) years while HC was 45.48(18.57) years. TAO eyes had higher OSDI, TMh, LLT, more severe partial blinking, PEE, shorter NIKBUT and worse meiboscore than HC eyes(all P<0.05). Multivariate analysis identified that meiboscore, but not MRD1, lagophthalmos or exophthalmos, was associated with short NIKBUT in TAO eyes ( $\beta = -1.31$ ; 95% CI: -2.51, -0.11), especially the lower eyelid meiboscore ( $\beta = -1.42$ ; 95% CI: -2.76, -0.08) and eyes with severe MGD ( $\beta = -4.83$ ; 95% CI: -7.33, -2.33)(all P<0.05).

**Conclusion:** Worse meiboscore due to meibomian gland dropout, especially in the lower eyelid was more crucial than mechanical exposure in determining tear film instability in this TAO cohort.

FP-164

**Novel approach of retrobulbar amphotericin-B to tackle orbital mucormycosis**A Pai<sup>1</sup>, A Kamath<sup>2</sup>, D Bhosale<sup>3</sup>.

<sup>1</sup>Netradhama Superspeciality Eye Hospital, Bangalore, <sup>2</sup>Ophthalmology, Yenepoya Medical College & Hospital, Mangalore, <sup>3</sup>Ophthalmology, Government medical College & District Hospital, Satara, India

**Objective:** Role of retrobulbar amphotericin to tackle orbital mucormycosis

**Methods:** Prospective randomised study of patients who were admitted with orbital mucormycosis. Amphotericin-B of dosage 3.5mg/ml was given via retrobulbar approach in the infero-medial and supero-medial aspect of the globe after giving 2ml of lignocaine. Consent and ethics committee approval was obtained. Amphotericin-B was injected every 5th day for 4 doses & observed

**Results:** 74 patients had orbital mucormycosis out of which 50 were given amphotericin. 28 had improvement while 12 underwent exenteration & remaining 10 succumbed to the disease. Out of the total 74 patients where retrobulbar amphotericin was given as an adjunct with intravenous amphotericin, 45 patients had arrest of orbital infection with halting the loss of visual acuity and subsequent discharge. The survival rate of using retrobulbar amphotericin-B as an adjunct along with intravenous amphotericin-B to patients presenting at early stages was around 60%

**Conclusion:** The second wave of covid-19 pandemic caused havoc in India with many people being debilitated with mucormycosis. Although various theories were given for the development and to tackle mucormycosis, retrobulbar amphotericin was tried and found to be effective in controlling orbital mucormycosis to some extent. Cosmesis was a major issue for the patients post exenteration

FP-165

**Conbercept versus laser therapy for the treatment of Type 1 retinopathy of prematurity**Y Cheng, J Liang.

**Objective:** To evaluate the efficacy and safety of intravitreal conbercept compared with laser therapy in treatment of ROP

**Methods:** This randomised, off-label, multicentre trial was done in four ophthalmic centres. We included infants with type 1 ROP, and randomised patients to receive a single bilateral intravitreal dose of conbercept 0.2 mg or laser therapy. The primary outcome was survival with effectiveness of the treatment based on structural outcomes, including decrease or disappearance of neovascularization, regression of plus disease and growth of the normal retinal vessels towards ora serrata, or need for a different treatment modality at or before 24 weeks. Analysis was by intention to treat.

**Results:** From Dec, 2018, and June, 2020, 204 eyes (102 infants) with conbercept 0.2 mg treatment and 200 eyes (100 infants) with laser therapy were enrolled. Treatment success occurred in 180 (88.2%) of 204 eyes receiving conbercept 0.2 mg compared with 166 (83.0%) of 200 eyes after laser therapy. No systemic or ocular complications or side effects were observed during the follow-up period.

**Conclusion:** In the treatment of ROP, conbercept 0.2 mg might be superior to laser therapy, with fewer unfavourable ocular outcomes than laser therapy and with an acceptable 24-week safety profile.

FP-166

**Expanding the phenotypic spectrum of mutations in *LRP2*: a novel candidate gene of non-syndromic familial comitant strabismus**Y Wang, X *Chen*, H *Liu*.

**Objective:** Comitant strabismus (CS) is a heterogeneous disorder that is a major contributing factor to unilateral childhood-onset visual impairment. Studies have confirmed that genetic factors play an important role in the development of CS. The aim of this study was to identify the genetic cause of non-syndromic familial CS.

**Methods:** Fourteen unrelated CS families were recruited for the study. Twelve affected and 2 unaffected individuals from a large four-generation family (CS08) were selected to perform whole genome-wide linkage analysis. Parallel whole-exome sequencing (WES) was conducted in the same family (9 patients and 1 unaffected member) and 31 additional CS cases from 13 other unrelated families. Sanger sequencing was used to determine whether any of the remaining variants co-segregated with the disease phenotype in the corresponding family.

**Results:** Based on linkage analysis, CS in family CS08 mapped to a novel region of 34.17 centimorgan (cM) on chromosome 2q22.3-2q32.1 between markers D2S151 and D2S364, with a maximum log odds (LOD) score of 3.54 ( $\theta = 0$ ) at D2S142. Parallel WES identified a heterozygous variant, *LRP2* c.335 A>G (p.Q112R), located in such a linkage interval that completely co-segregated with the disease in the family. Furthermore, another novel heterozygous variant (c.7274A>G, p.D2425G) in *LRP2* that co-segregated was detected in 2 additional affected individuals from another unrelated family by WES. Both variants are predicted to be damaging by PolyPhen-2, SIFT and MutationTaster, and were absent in 100 ethnically matched normal controls.

**Conclusion:** *LRP2* is a novel candidate genetic cause of non-syndromic familial CS.



FP-167

**Divergence insufficiency esotropia: characteristics and management**X Zuo.

**Objective:** To describe the clinical characteristics and management outcomes of a group of patients at 12 years of age with divergence insufficiency esotropia.

**Methods:** The medical records of the patients diagnosed with divergence insufficiency esotropia between 2009 and 2021 were retrospectively reviewed. Clinical features evaluated included age at diagnosis, refractive errors, primary position deviations at distance and near, treatment offered, postsurgical deviations were evaluated.

**Results:** A total of 38 patients (19 females [50%]) were identified. The mean age at diagnosis was 32 years (range 16-56 ys) . The mean refractive error was -4D (+2- -7.5Ds) .The mean initial esodeviation was 29PD(range 15-55PD) at distance and 11PD (range 0-40PD)at near. All the patients had been ruled out neurological disease and without limitation of abduction. Therapeutic prism was used by 12 patients (32%). Unilateral medial rectus muscle recession (mean 5.5 mm [range 5.0-6.0 mm]) was performed on 15 patients (39%), bilateral medial rectus muscle recession(mean total 10.0mm [range 8.0-12.0 mm]) was performed on 8 patients (21%) and unilateral lateral rectus muscle resection (8.0 mm [range 7-9mm]) was performed on 3 patients (8%). All reoccurred in the unilateral lateral rectus resection group and 2 reoccurred in Ipsilateral medial rectus muscle recession group.

**Conclusion:** Divergence insufficiency esotropia could happens mostly in young and middle aged adults, with various refractive errors. Therapeutic prisms, bilateral and unilateral medial rectus muscle recessions were generally successful, with 87% not requiring further surgery. Unilateral lateral rectus muscle resection is not a good choice for its treatment.

FP-168

### New treatment for anisometropic amblyopia based on rules of synaptic plasticity

X Huang<sup>1</sup>, H Xia<sup>2</sup>, Q Zhang<sup>3</sup>, C Blakemore<sup>4</sup>, Y Nan<sup>5</sup>, W Wang<sup>6</sup>, J Gao<sup>5</sup>, J Wen<sup>7</sup>, T Huang<sup>8</sup>, X Li<sup>7</sup>, M Pu<sup>5</sup>.

<sup>1</sup>Research and Development, Precision Sight (Beijing) Medical Technology Co., Ltd., Beijing, <sup>2</sup>Ophthalmology, Hei Bei General Hospital, Shijiazhuang, <sup>3</sup>Ophthalmology, The second affiliated hospital, Peking University, Beijing, People's Republic of China, <sup>4</sup>Biomedical Sciences, City University of Hong Kong, Hong Kong, Hong Kong, China, <sup>5</sup>Anatomy/Embryology, School of Basic Medical Sciences, Peking University, <sup>6</sup>Electronics Engineering & Computer Sciences, Peking University, <sup>7</sup>Ophthalmology, Peking University first hospital, <sup>8</sup>National Engineering Laboratory for Video Technology, Peking University, Beijing, People's Republic of China

**Objective:** To test the hypothesis that asynchronous stimulation of both eyes induces synaptic plasticity and re-balances binocular input, and to verify the efficacy of asynchronous visual treatment in 4 to 8 year-old children with anisometropic amblyopia.

#### Methods:

**Participants:** The visual psychophysical study part included 6 normal individuals aged 26 to 29 years, and the clinical study consisted of 46 children aged 4 to 8 years with anisometropic amblyopia and a mean baseline VA of 0.42 logMAR.

**Experimental protocols:** In the visual psychophysical study part, we performed a binocular repetitive brief exposure of grating stimuli, with the onset of each stimulus delayed by 8 ms in one eye. In the first part of the clinical study, the participants of the study group underwent an asynchronous three-dimensional movies treatment paradigm (AMTP) for 10.5 hours (45min/session, 14 sessions within 3 weeks), while the participants of the control group underwent a synchronous three-dimensional movie treatment paradigm (SMTP) for 10.5 hours. All participants had unilateral eye patching for six hours per day. In the second part, the study group received 30 hours of AMTP within 12 weeks, in addition to six hours of daily patching, while the control group had only the daily patching without the AMTP. After completion, twelve subjects additionally were participated in 2-year follow-up.

#### Results:

**Main outcome measures:** Visual psychophysical study: shift in perceptual eye dominance; Clinical studies: changes in amblyopic-eye VA from baseline to < 3 weeks and 12 weeks assessed by a masked examiner, respectively.

**Results:** In the visual psychophysical study, repetitive brief exposure of grating stimuli, resulted in a shift in the perceptual eye dominance. In the first study, VA improved significantly in the study group ( $0.41 \pm 0.11$  logMAR to  $0.09 \pm 0.04$  logMAR;  $P=0.03$ ), while in the control group VA did not change significantly ( $0.34 \pm 0.07$  logMAR to  $0.22 \pm 0.03$  logMAR;  $P=0.17$ ). In the second study, VA improved 3.8 lines in the study group ( $0.47 \pm 0.06$  logMAR to  $0.09 \pm 0.02$  logMAR;  $P<0.0001$ ), while in the control group VA improved 2.4 lines ( $0.53 \pm 0.05$  logMAR to  $0.29 \pm 0.03$  logMAR;  $P<0.0002$ ).

After a follow-up of two years, the difference remained to be significant (between the groups:  $P<0.0001$ ).

**Conclusion:** Asynchronous stimulation, in addition to eye patching, persistently improved visual acuity of amblyopic eyes in children aged 4-8 years.

FP-169

**Blood parameters as diagnosis index for the Retinopathy of Prematurity in Chinese population**Y Li<sup>1</sup>, X Tian<sup>1</sup>.

<sup>1</sup> the Second Xiangya Hospital, Central South University, the Second Xiangya Hospital, Central South University, Chang sha, People's Republic of China

**Objective:** To determine whether there is an association between blood parameters and retinopathy of prematurity (ROP).

**Methods:** A retrospective case-control study was conducted in a single large tertiary referral hospital in Central South China. The data of 19 neonates were excluded because of the lack of their information. Finally, three hundred and seven hospitalized neonates with gestational age (GA) <32 weeks and birth weight (BW) <2000 g from Oct 2012 to Dec 2021 were divided into three groups: Group 1 (133 premature infants without any evidence of ROP), group 2 (100 infants with Non-treatment-requiring ROPs, NTR-ROPs), Group 3 (74 treatment-requiring ROP infants, TR-ROPs). Demographic features, comorbidity data, laboratory parameters, and ocular examinations were collected. Blood parameters at the initial established diagnosis of ROP (in Group 2 and 3), and the most paired time point in Group 1 were compared, with fluctuation at birth, at 32 weeks, and the first ROP diagnosis were observed. Univariate analysis and multiple="multiple" logistic regression were used to analyze the associations with ROP in neonates, and than ROC curves were used to access the sensitivity and specificity of these obviously changed parameters and the combined value of the parameters by binary logistic regression analysis.

**Results:** three hundred and seven infants were included in the study. Hemoglobin, Platelet, WBC, Eosinophil granulocytes, procalcitonin (PCT), Bronchopulmonary Dysplasia (BPD), and Necrotizing enterocolitis (NEC), gastrointestinal bleeding and the use of immunoglobulin were statistically significant in TR-ROP compared with NO ROP + NTR ROP groups, the combining of the 9 parameters could prognosticate the occurrence of TR ROP with AUC of 0.845, with the best value of the sensitivity and specificity of 72% and 84%.the trends of the blood parameters are shown during three periods, there are upward trends of Platelet and PCT, and during the period from 32 weeks to the time firstly confirmed with ROP, the data of the severe ROP group shows a steep elevatory. While a significant decline was observed from their birth to 32 weeks in TR ROP group.

**Conclusion:** Our data reveal that the statistical fluctuation of blood parameters and significant variance between early stages of ROP and the condition of infants with no ROP implicates the pathogenesis of ROP. Monitoring the occurrence of ROP through blood tests may be a calculated, widely available, and less suffering way to predict ROP development.

FP-170

**Community centered ROP screening approach- Aarambh Tele ROP Model.**D Agrawal.

**Objective:** To establish the team approach & Tele ROP model for the successful community centered mass screening of premature babies.

**Methods:** We visited neonatologists, NICU'S & SNCU'S. We hired ophthalmic Assistant (Graduate in Optometry) with a good experience in ophthalmology work. He was trained for **ROP** Screening & taking images by wide angle fundus camera. **Forus – Neo Camera** is a Wide field, portable, infant's retinal (ROP) Camera. It is Novel, Low cost, indigenously manufactured as compared to imported **RETCAM**. It is Portable, Compact with good added features & can easily **accessible to Rural Area** and hence **Mass screening is possible with this portable device**. Approximately 3 Minutes is required for screening of each baby in the expert hand. Our's is a team approach comprising 2 **Vitreo-retina specialists** and 1 **pediatric Ophthalmologist**.

We visited neonatologists, NICU'S & SNCU'S. We hired ophthalmic Assistant (Graduate in Optometry) with a good experience in ophthalmology work. He was trained for **ROP** Screening & taking images by wide angle fundus camera. We maintained proper documentation, good communication & co-ordination between patient, Neonatologist and ROP expert through a systematic strategy. We utilize multimedia, social media & IT Technology for the same. In one day we travel on one route, cover one city. For Counseling we use posters, handbills which are already kept in each NICU for patients & relatives. Showing screened image had a good impact. For Awareness among neonatologists we took workshops & seminars in each district. Taking local interested ophthalmologist in the loop as **collection center or for diagnosis & treatment**. Currently with a single device we screen 25-30 babies in each visit in 4-5 NICU'S. At present we cover around 8 districts of **Marathwada, Khandesh** & part of **Vidarbha** including **3 Govt. Civil hospitals** and one Govt. medical College.

**Results:** Our Data is from Jan 2018 to Sept 2021, we screened **5559** babies **12.35%** had ROP, Treatment has been given to **3.52 % (194)** Babies. Intravit. Injection was given to **102** babies & Retina Laser was done in 92 babies.

**Conclusion:** Our team approach & Tele ROP Screening model has been found quite successful in terms of mass screening of preterm babies, documentation & counselling. **"Aarambh ROP Screening project"** is an ideal **Tele ROP Model** which can be adopted across India (especially in **private sector**) to curb the incidence of ROP and huge burden of Childhood blindness.

FP-172

### Evaluation of Distance Stereoacuity in Children with a Novel Digital Application

G Barnett-Itzhaki<sup>1,2</sup>, Z Barnett-Itzhaki<sup>3,4</sup>, N Ela-Dalman<sup>1,2</sup>.

<sup>1</sup>Ophthalmology, Meir Medical Center, Kfar Saba, <sup>2</sup>Sackler Faculty of Medicine, Tel Aviv University, Tel Aviv,

<sup>3</sup>Research group in environmental and social sustainability, <sup>4</sup>Computer and data science, Ruppin Academic Center, Emek Hefer, Israel

**Objective:** Stereopsis is a fundamental skill in human vision and visual actions. There are several ways to test and quantify distance stereoacuity: traditional and new digital applications are both valid ways to test the stereoacuity. The aim of this study is to compare the results obtained using standard tests for distance stereoacuity measurement with the new StereoTAB App.

**Methods:** A group of 120 children (69 females), aged between 4 and 17 years old (mean age 9.16), were tested using different tests for the quantification of stereopsis at distance. These tests were Distance Randot Stereotest, M&S random dots and the new developed StereoTAB App.

**Results:** Stereopsis at distance was better with M&S random dots (2.09) than with Distance Randot Stereo test (2.19) or StereoTAB (2.21), but not significantly (Kruskal Wallis,  $P=0.117$ ). A strong correlation was demonstrated between: M&S random dots and Distance Randot Stereotest (0.83,  $P<0.0001$ ), M&S random dots and StereoTAB App (0.84,  $P<0.0001$ ), Distance Randot Stereotest and StereoTAB App (0.88,  $P<0.0001$ ). The limits of agreement (Bland-Altman) between M&S random dots and Distance Randot Stereotest was 0.54, between M&S random dots and StereoTAB App was 0.55, and between Distance Randot Stereotest and StereoTAB App was 0.45.

**Conclusion:** The distance stereoacuity based on random dots stereopsis showed that the better values were obtained in order by M&S random dots, Distance Randot Stereo test, and StereoTAB. However, the clinical significance of their values is similar, and they can be used interchangeably. The introduction of versatile, fast, and portable stereopsis test which can be used at different distances with children is of primary importance.

FP-173

**Surgical results of medial transposition of lateral rectus muscle for oculomotor nerve palsy**J Li.

**Objective:** To report the effect on ocular alignment and ductions of nasal transposition of Y splitting lateral rectus muscle(LR) for oculomotor nerve palsy.

**Methods:** Five patients with congenital oculomotor nerve palsy were included. The patients with prior strabismus surgery and complete restricted abduction were excluded. The mean age at surgery was 17.4 (5-28) years. The mean preoperative exotropia was -101 (90-120) PD. The mean follow-up was 10.4 (7-16) months. LR was split in half longitudinally 20 to 22 mm posteriorly. The upper half was transposed behind the insertion of superior oblique (SO), then under SO and superior rectus to the superior border of medial rectus muscle (MR) insertion, while the lower half of LR was transposed under inferior oblique and inferior rectus to inferior border of MR insertion. Successful alignment was defined as postoperative alignment between -10PD to +5PD.

**Results:** Of the five patients, one achieved orthophoria, two were slightly overcorrected (+8PD, +15PD) and the other two were slightly undercorrected (-15PD, -20PD) at the last follow-up. The patients with orthotropia and overcorrection had satisfactory appearance in the primary position, but they were not satisfied with the almost fixed eyeball since they had obviously restriction in abduction. However, the patients with slightly undercorrection were pleased since there was no severe restriction of both abduction and adduction.

**Conclusion:** Acceptable comestic results can be achieved in the treatment of complete oculomotor nerve palsy by transposing the split LR to MR. In view of horizontal ductions, mild undercorrection maybe better than orthophoria or overcorrection.

FP-174

### Plasma Level of Apelin as a Promising Factor for Retinopathy of Prematurity

J Feng<sup>1</sup>, G Liang<sup>2</sup>, W Gao<sup>2</sup>, X Li<sup>2</sup>, L Wei<sup>2</sup>, H Chang<sup>3</sup>, X Zhang<sup>4</sup>, Y Tao<sup>1</sup>.

<sup>1</sup>Ophthalmology, Beijing Chaoyang Hospital, Capital Medical University, <sup>2</sup>Ophthalmology, <sup>3</sup>Pediatrics, PLA Rocket Force Characteristic Medical Center, <sup>4</sup>Pediatrics, Peking University People's Hospital, Beijing, People's Republic of China

**Objective:** To investigate the relevance of plasma levels of apelin and other risk factors in infants with retinopathy of prematurity (ROP).

**Methods:** This was a single-center cross-sectional study. Fifty preterm infants with ROP and 50 preterm infants without ROP were enrolled. The analysis included evaluation of gestational age, birth weight, and measurement of plasma concentrations of apelin, vascular endothelial growth factor (VEGF), erythropoietin (EPO), and insulin-like growth factor (IGF-1) using enzyme-linked immunosorbent assay.

**Results:** The mean BW and GA of babies with ROP were considerably lower than those without ROP ( $P < 0.001$ ,  $P = 0.003$ , respectively). Plasma levels of VEGF, EPO, and IGF-1 were all lower in babies with ROP (all  $P < 0.001$ ), while plasma apelin levels were greater ( $P < 0.001$ ). We compared the sensitivity and selected the best cut-offs while keeping the specificity constant (80.0%). Among all the criteria, plasma apelin levels had the best sensitivity (72%), with the cut-off of 21.08 pg/mL. Multivariable logistic regression analyses showed that the plasma level of apelin was the only parameter associated with ROP ( $P = 0.02$ , OR = 16, CI = 95%: 1.54-166.53). The AUC of the multivariable regression model that comprised GA, BW alone was 0.67, while the model that included apelin was 0.90.

**Conclusion:** Plasma apelin level demonstrated good sensitivity and specificity with regard to the association of ROP, the inclusion of apelin may be a promising factor to include in screening criteria.



## FP-175

## Clinical study of two different designs of multi-point myopia off-focus spectacles for myopia control in children

?王.

**Objective:** This paper examines two different designs of multi-point myopia defocus lenses (multifocus incorporated multiple segments, DIMS and high aspheric microlenses highly aspherical lenslets, HAL) for myopia control in children.

**Methods:** From September 5, 2020 to March 28, 2021, 52 children aged 7 to 12 years were selected from 7 to 12 years old with multi-point forward optical defocusing mirror (DIMS) with diopter  $-2.16 \pm 1.05D$ , 67 children wearing high aspheric microlens (HAL) with diopter of  $-2.69 \pm 1.53D$ ; the above two groups were observation groups; 55 children wearing single light lenses (SVL) with diopter of  $-1.86 \pm 0.89D$  control group. Changes in equivalent spherical goggles (SER) and eye axis (AL) were compared 6 months after wearing with 12 months without other intervention.

**Results:** The SER of each group before and after 12 months of wearing glasses increased to varying degrees. The diopter change in the DIMS group was  $0.42 \pm 0.40D$  in the 12-month period, the diopter change in the HAL group was  $0.30 \pm 0.81D$ , the diopter change in the 12-month diopter in the single light group was  $1.19 \pm 0.91D$ , the diopter growth in the DIMS group in 12 months was significant ( $P < 0.01$ ), and the diopter growth in the HAL group was significant ( $P < 0.01$ ); the 12-month diopter in the HAL group was not significantly different from that in the DIMS group ( $P = 0.24$ ). The eye axis of each group increased to varying degrees after wearing glasses for 12 months. The eye axis change in the DIMS group was  $0.26 \pm 0.18$  mm in the 12 months, the eye axis change in the HAL group in 12 months was  $0.16 \pm 0.17$  mm, and the eye axis change in the 12 months in the single light group was  $0.79 \pm 0.17$  mm. The 12-month eye axis growth in the DIMS group was significantly smaller than that in the single light group ( $P < 0.01$ ), the 12-month eye axis growth in the HAL group was significant ( $P < 0.01$ ), and the 12-month eye axis growth in the HAL group was less than that in the DIMS group ( $P = 0.01$ ).

**Conclusion:** Both high aspheric microlenses and multi-point forward optical defocus lenses can effectively delay the progression of children's myopia, and the effect of high aspheric microlens with more points of forward optical defocus lenses in this experiment is more significant.

FP-176

**Superselective triple-drug Intraarterial Chemotherapy in Retinoblastoma**A Aishwarya, S Honavar.

**Objective:** To assess the outcomes in retinoblastoma (RB) treated with triple-drug intraarterial chemotherapy (IAC)

**Methods:** Retrospective interventional study of 145 eyes of 112 RB patients from 2013 to 2019 treated with super-selective triple-drug (topotecan, carboplatin and melphalan) IAC.

**Results:** The mean age was 22.8m with a mean follow up of 42.1m. Of 126 treatment-naïve eyes, ICRB Groups were A (n=0), B (n= 10), C (n=16), D (n=59), and E (n=41). Primary IAC was provided in 92 eyes and secondary IAC in 53 eyes, with local consolidation in 128 (88%). Group B and C showed 100% regression, with maximum reduction in tumor volume after IAC cycle 1 and maximum calcification seen after IAC cycle 3. Complications following IAC included vitritis in 4 (2.7%), sterile inflammation in 2 (1.4%) and ptosis in 1 (0.7%). Eye salvage was achieved in all in Group B and C, 54 (92%) in Group D and 22 (54%) in Group E. Three of 19 (16%) enucleated eyes in Group E had histopathological high-risk factors, prompting adjuvant IVC. None developed systemic metastasis.

**Conclusion:** Triple drug superselective IAC is remarkably effective in Group B-D RB, while modest success is possible in Group E.

FP-177

### The efficacy of using crosslinked strips during posterior scleral reinforcement to slow down high myopic progression in children

J Ye.

**Objective:** To evaluate the efficacy of using crosslinked strips during posterior scleral reinforcement (PSR) for slowing down the progression of high myopia in children.

**Methods:** Forty-six high myopic children were done the PSR (24 with crosslinked strip during the PSR, 22 with non-crosslinked strip). All patients were examined with axial length (AL) at pre-operation, post-operation 1, 2, 3, 4, and 5 years, respectively. During the PSR, the crosslinked/non-crosslinked strip was sent across the inferior-temporal scleral surface to the posterior pole, then two ends were led out from nasal-inferior and temporal-superior areas. It was tightened to reinforce the posterior sclera. The AL alteration from the pre-operation was analyzed and was compared between the crosslinked group and the non-crosslinked group. The regression analysis was done to figure out the related variables associated with the AL alteration as the predictor factor at the post-operative follow-up point.

**Results:** There was no difference in pre-operative AL between the two groups (crosslinked group vs. non-crosslinked group,  $27.81 \pm 0.77\text{mm}$  vs.  $27.45 \pm 0.82\text{mm}$ ,  $P=0.132$ ). The age, gender ratio, and spherical equivalent didn't show any significant difference between the two groups (All  $P>0.2$ ). In the crosslinked group, the AL alteration from pre-operation was  $-0.08 \pm 0.32\text{mm}$ ,  $0.16 \pm 0.41\text{mm}$ ,  $0.32 \pm 0.47\text{mm}$ ,  $0.48 \pm 0.57\text{mm}$ , and  $0.50 \pm 0.61\text{mm}$  at each post-operative follow-up point. In the non-crosslinked group, the AL alteration from pre-operation was  $0.27 \pm 0.25\text{mm}$ ,  $0.52 \pm 0.32\text{mm}$ ,  $0.82 \pm 0.42\text{mm}$ ,  $1.03 \pm 0.44\text{mm}$ ,  $1.25 \pm 0.57\text{mm}$ -at each post-operative follow-up point. For the AL alteration at each post-operative follow-up point, there was a significant difference between the two groups (All  $P < 0.004$ ). In the linear regression analysis of related variables associated with AL alteration as the predictor factor at the post-operative follow-up point, less AL elongation was associated with earlier age for PSR (Standardized Coefficients= $-0.183$ ,  $P=0.001$ ) and using crosslinked strip (Standardized Coefficients= $-0.473$ ,  $P<0.001$ ).

**Conclusion:** The crosslinked strip used in the PSR surgery was efficient for slowing down the progression of high myopia in children when compared to the non-crosslinked strip.

FP-178

## Comparison of Clinical Outcomes After Immediately Sequential Bilateral ICL Surgery vs. Delayed Sequential Bilateral ICL Surgery

Y Jiang<sup>1</sup>, X Chen<sup>1</sup>, M Cheng<sup>1</sup>, Y Lei<sup>1</sup>, B Li<sup>1</sup>, X Wang<sup>1</sup>, X Zhou<sup>1</sup>.

<sup>1</sup>Department of Ophthalmology and Optometry, Eye and ENT Hospital, Fudan University, Shanghai, People's Republic of China

**Objective:** To compare the safety, efficacy and predictability of the same day bilateral surgery with a short interval between eyes for EVO implantable collamer lens (ICL) surgery.

**Methods:** This retrospective study included patients who underwent bilateral ICL implantation from November 2014 through December 2018. Patients were divided into 2 groups: (1) immediately sequential bilateral ICL surgery (ISBICLS): both eye surgeries on the same day (2) delayed sequential bilateral ICL surgery (DSBICLS): second-eye surgery less than 7 days after the first eye surgery. Propensity score matching (PSM) was conducted for each surgery eye respectively. The visual and refractive outcomes at 1 month after surgery were compared between groups.

**Results:** Overall, 3906 eyes of 1953 participants were included (2418 eyes of ISBICLS; 1488 eyes of DSBICLS). After PSM, 487 first surgery eyes of 244 patients and 427 second surgery eyes of 214 patients in the ISBICLS group were matched (1:1) to DSBICLS. At 1 month after surgery, the safety index was similar between groups for the first eye ( $1.10 \pm 0.23$  vs  $1.21 \pm 0.47$ ,  $P=0.153$ ) and differed for the second eye ( $1.19 \pm 0.25$  vs  $1.15 \pm 0.31$ ,  $P=0.002$ ). For the first eye, the postoperative mean corrected distance visual acuity was better in the ISBICLS than in the DSBICLS ( $-0.04 \pm 0.10 \log \text{MAR}$  vs  $0.01 \pm 0.13 \log \text{MAR}$ ,  $P=0.003$ ). The differences persisted for the second eye ( $-0.04 \pm 0.09 \log \text{MAR}$  vs  $0.01 \pm 0.16 \log \text{MAR}$ ,  $P=0.001$ ). The efficacy index was similar between groups for the first eye ( $1.10 \pm 0.23$  vs  $1.07 \pm 0.26$ ,  $P=0.153$ ) and the second eye ( $1.09 \pm 0.25$  vs  $1.05 \pm 0.26$ ,  $P=0.356$ ). A higher proportion of eyes in ISBICLS achieved an uncorrected visual acuity of 20/20 or better for the first eye (81.00% vs. 77.15%) and the second eye (80.00% vs. 76.39%). Postoperative spherical equivalent within  $\pm 0.5\text{D}$  was achieved in 63.41% of DSBICLS first eyes, 66.36% of ISBICLS first eyes, 76.74% of DSBICLS second eyes and 72.53% of second ISBICLS eyes. Ideal vault was observed in 81.04% of ISBICLS first eyes, 82.82% of DSBICLS first eyes, 85.00% of ISBICLS second eyes, and 83.12% of DSBICLS second eyes. IOP spikes occurred in 1 first eye (0.10%) of ISBICLS and 2 first eyes (0.22%) of DSBICLS. There were no other cases of complications.

**Conclusion:** ISBICLS provided better safety, efficacy, and predictability than DSBICLS in the early postoperative period, without increasing the risk of complications. Bilateral ICL surgery on the same day may be a good way to promote visual recovery after surgery and improve patient compliance.

FP-179

**Femtosecond Intrastromal Lenticule Implantation (FILI) for management of moderate to high hyperopia- 5 years outcomes and clinical**H D Bhavsar, S Ganesh<sup>1</sup>, S Brar<sup>1</sup>.<sup>1</sup>Department of phaco- refractive surgery, Nethradhama superspeciality eye hospital, Bangalore, India, Bangalore, India

**Objective:** To report the long term clinical experience following Femtosecond Intrastromal Lenticule Implantation (FILI) for management of moderate to high hyperopia.

**Methods:** Eligible patients who underwent FILI for moderate to high hyperopia from July 2013 to October 2020 were included. A donor SMILE lenticule, matched for refractive error was implanted into the recipient's corneal pocket created using a femtolasar at 160 microns depth. Visual and refractive outcomes and long term complications were evaluated at the end of a mean follow-up of  $68 \pm 17.28$  months (5.6 years).

**Results:** 42 eyes of 25 patients (mean age  $27.29 \pm 5.52$  years) were analysed. The mean SE reduced significantly from  $+5.5 \pm 1.96$  to  $+0.66 \pm 1.17$  D at 5 years post-op. Seventy-one % (n=30) eyes were within  $\pm 1.00$  D of SE correction. Cumulative UDVA of 20/40 or better was achieved in 81% (n=34) of eyes. Efficacy and safety indices were  $0.86 \pm 0.19$  and  $1.17 \pm 0.39$ , respectively. There was a significant increase in Kmean anterior, central corneal thickness, Q-value and corneal HOAs and decrease in Kmean posterior 2 weeks post-op, without any significant change in these parameters thereafter,  $p > 0.05$ . Four eyes of 3 patients underwent enhancement and another 4 eyes underwent explantation of the lenticule followed by exchange (2 eyes) and hyperopic LASIK (2 eyes). No eye lost more than 1 line of CDVA.

**Conclusion:** At 68 months, FILI for moderate to high hyperopia, showed good safety, efficacy and reversibility. Modification of nomograms and surgical planning may be employed for further refinement of the outcomes.

FP-180

**Study Of Surgically Induced Astigmatism After Laser In Situ Keratomileusis In Myopes**

A Sinha<sup>1</sup>, R Acharya<sup>2</sup>, J Bose<sup>3</sup>.

<sup>1</sup>Ophthalmology, Worcestershire Acute Hospitals NHS Trust, Worcester, <sup>2</sup>Medical Student, University of Birmingham Medical School, Birmingham, United Kingdom, <sup>3</sup>Ophthalmology, EyeQ Hospitals, Gurgaon, India

**Objective:** To evaluate the surgically induced astigmatism (SIA) after laser in situ keratomileusis (LASIK) in myopes

**Methods:** Refractive outcomes in 48 eyes that underwent myopic LASIK over a one year period from December 2017 to December 2018, were analysed in this prospective observational study. The enrolled patients had myopia upto 10 D with or without astigmatism upto 1 D. All flaps were nasally hinged. The patients were followed up till 3 months after surgery. The SIA was calculated and was correlated with the type and amount of preoperative refractive error, keratometric power, ablation depth and refractive and corneal astigmatism

**Results:** The mean SIA was found to be  $0.45 \pm 0.33$  D using vector analysis. SIA showed a positive correlation with increasing grades of myopia ( $p = 0.019$ ). SIA was higher in spherocylinders ( $0.5 \pm 0.34$  D) as compared to pure spherical errors ( $0.32 \pm 0.26$  D). On univariate regression, spherical equivalent ( $p = 0.03$ ), ablation depth ( $p = 0.001$ ), preoperative refractive astigmatism ( $p = 0.04$ ), preoperative corneal astigmatism ( $p = 0.0002$ ) and steep K ( $p = 0.04$ ) remained the significant predictors of SIA. On multivariate regression, preoperative corneal astigmatism ( $p = 0.01$ ) was found to be the single most important predictor of SIA. There was a significant change in the mean axis of astigmatism from preoperative 89 degrees (with-the-rule) to postoperative 171 degrees (against-the-rule)

**Conclusion:** There was a consistent trend towards greater SIA seen in eyes with higher preoperative astigmatism, spherical equivalent, ablation depth and steep K. Nasally hinged flaps cause ATR astigmatism due to relative steepening of the hinge meridian

FP-181

**Comparison of Actual and Predicted Implantable Collamer Lens (ICL) Vault Using Three Different Formulas.**

A Eldanasoury<sup>1</sup>, S Pieger, H Bains.

<sup>1</sup>Ophthalmology, Magrabi Hospitals & Centers, Jeddah, Saudi Arabia

**Objective:** Comparing postoperative ICL vault using conventional STAAR online calculation and ordering system (OCOS) with predicted vault using Nakamura 2 (NK2) and a modified NK2 formula.

**Methods:** Interventional case series of 275 eyes that had ICL implantation. ICL size was calculated with OCOS. Data were collected using anterior segment optical coherence tomography (ASOCT, MS39, CSO, Italy). Postoperative vaults were measured at 1 month with ASOCT. Optimal ICL sizes and predicted vault values were calculated for NK2 and a modified NK2 formula with different coefficients derived from regression analysis. Simulations were performed to compare actual vaults with predicted vaults.

**Results:** Using OCOS, mean achieved vault was  $0.51 \pm 0.27$  mm, between 0.25 and 1.0 mm in 80%, below 0.25 mm in 16% and above 1.0 mm in 4% eyes. Mean predicted vault was  $0.78 \pm 0.34$  mm with the NK2 formula and above 1.0 mm in 22% eyes; with modified NK2 it was  $0.48 \pm 0.33$  mm and below 0.25 mm in 17% eyes

**Conclusion:** Similar mean ICL vault was achieved with OCOS and modified NK2. NK2 resulted higher mean vault. Compared to NK2 and modified NK2, OCOS resulted in less percentage of eyes with low and high vault.

FP-182

**Artificial-Intelligence-Assisted Suction Loss Prediction During Small Incision Lenticule Extraction(SMILE)**B Li, Y Shen, X Wang.

**Objective:** To predict imminent suction loss during small incision lenticule extraction(SMILE) by artificial intelligence(AI).

**Methods:** We collected 4173 eyes underwent SMILE procedures for the treatment of myopia or myopia astigmatism from 2014 to 2020, of which 173 eyes developed suction loss during the procedure. Intraoperative surgical videos of all eyes were analyzed. Convolutional LSTM Network(ConvLSTM) was applied to identify the signs of imminent suction loss. We used GooleNet to transfer the videos into feature vectors series, extracting information of every frame in the videos. LSTM Network was then used to predict video labels. By combing two network layers, we built a ConvLSTM Network to predict imminent suction loss by classifying the videos directly.

**Results:** The ConvLSTM Network can identify the signs of imminent suction loss within 9 frames which is about 150ms with an accuracy of 83%. If the time extend to 500ms, the accuracy can reach 90%. The average time from identifying the signs by artificial intelligence to the happening of suction loss is about 2 seconds.

**Conclusion:** AI can identify the signs of imminent suction loss far more quickly than human beings, thus predicting suction loss in advance. By doing so, we could improve the safety and efficacy of SMILE especially in surgeons with less surgical experience.



FP-183

**Prediction of Insufficient Vault After Implantable Collamer Lens Implantation Using iris Morphology**L Zhao, M Khan, D Lin.

**Objective:** To investigate the factor related to the iris morphology that are predictive of outcomes of insufficient vault (< 100  $\mu\text{m}$ ) after Implantable Collamer Lens V4c Implantation.

**Methods:** In this retrospective case-control study, 27 eyes of 27 patients who presented with insufficient vault (< 100  $\mu\text{m}$ ) following implantation of an ICL V4c were matched in a 1:2 ratio with those who presented with a normal vault (250 to 750  $\mu\text{m}$ ) on anterior chamber depth, white-to-white distance, and ICL size. The preoperative biometric parameters and clinical outcomes were compared between the two groups. The relationship between the postoperative vault and various variables was assessed by multiple linear regression analysis. Conditional logistic regression models were used to estimate the risk factors for insufficient vault.

**Results:** The postoperative vault was associated with preoperative iris curvature and crystalline lens vault ( $P < 0.05$ ). In the conditional regression logistic analysis, the iris curvature was associated with an increased risk of insufficient vault after ICL implantation ( $P < 0.05$ ).

**Conclusion:** Eyes with an extremely concave iris were associated with a higher rate of insufficient vault after ICL implantation, so the size of the ICL may need to be adjusted in these patients. Evaluation of iris morphology characteristics adds significant information to the prediction of insufficient vault after surgery.

## FP-184

**Appropriate Laser Ablation Limit of SMILE and Risk Factors for Posterior Corneal Protrusion Over a Follow-up Period of 5 Years**

H Cao, Y Wang.

**Objective:** To determine risk factors for posterior corneal protrusion after small incision lenticule extraction (SMILE) and appropriate laser ablation limit for myopia correction.

**Methods:** This retrospective, longitudinal study enrolled 161 patients post-SMILE. The corneal stability was evaluated by posterior corneal elevation (PCE) over a follow-up period of 5 years and was predicted by predictive modelling using baseline characteristics (age, sex, refraction, corneal thickness, et al.). Based on a Scheimpflug camera (Pentacam), the PCE values were measured at the apex, thinnest, maximal, and 24 other prespecified preoperative points on 3 concentric circles (2-, 4-, and 6-mm center diameter) and at 6 months, 1 year, and 5 years postoperatively.

**Results:** Posterior corneas exhibited time-dependent (slightly protruded during the early postoperative period, reached the peak at 1 year, and reverted to original levels within 5 years), region-dependent (central corneas shifted backward while peripheral corneas shifted forward), and angle-dependent (the highest and lowest elevation occurred along the 90° and 270° semi-meridians, respectively) changes. For every dioptre increase in the absolute preoperative spherical equivalent (SE), 10- $\mu$ m decrease in the central corneal thickness (CCT), 10- $\mu$ m increase in the maximum lenticule thickness (MLT), 10- $\mu$ m decrease in the residual bed thickness (RBT), 10% increase in the percentage ablation depth (PAD, MLT divided by CCT), and 10% decrease in the percentage stromal bed thickness (PSBT, RBT divided by CCT), PCE exhibited average forward displacements of 0.2–0.4, 0.2–0.7, 0.1–0.2, 0.1–0.3, 0.6–1.0, and 0.5–1.1  $\mu$ m, respectively ( $P < 0.05$ ), after adjusting for age, sex, and other variables. The cutoff values of SE, CCT, MLT, RBT, PAD, and PSBT for increased PCE were  $-8.00$ – $-8.31$  D, 481.0–498.5  $\mu$ m, 139.5–144.5  $\mu$ m, 255.5–263.5  $\mu$ m, 26.9–28.3%, and 48.9–52.6%, respectively.

**Conclusion:** Eyes with thinner corneas ( $< 481$   $\mu$ m), higher myopia ( $> -8.31$  D) requiring greater MLT ( $> 145$   $\mu$ m), and lower RBT ( $< 256$   $\mu$ m) exhibited greater predispositions toward posterior protrusion. The thresholds for preventing forward posterior corneal displacement were 26.9–28.3% for PAD and 48.9–52.6% for PSBT. Long-term prediction of posterior corneal stability is useful for determining the laser ablation limit and assessing surgical risks post-SMILE.

FP-185

**Hemidivisional Vector Planning to Reduce and Regularize Irregular Astigmatism by Laser Treatment**N Alpins<sup>1</sup>, J KY Ong<sup>2</sup>, G Stamatelatos<sup>3</sup>.<sup>1</sup>Ophthalmology, University of Melbourne, Melbourne, <sup>2</sup>ASSORT, <sup>3</sup>NewVision Clinics, Cheltenham, Australia

**Objective:** To demonstrate how hemidivisional Vector Planning of refractive laser treatments of astigmatism can be used to directly address idiopathic corneal irregular astigmatism.

**Methods:** The cornea is conceptually divided into two hemidivisions along the flat meridian of the corneal topographic astigmatism (CorT). An astigmatism reduction treatment can then be planned separately for each hemidivision using the Vector Planning technique, based on both its two hemidivisional CorT measures and common manifest refractive cylinder. The remaining irregularity is then regularized, and the junctional zone smoothed across the flat meridian. The final intended treatment thus combines hemidivisional astigmatism reduction and regularization of the corneal astigmatism and spherical refractive error in one treatment application. This could be applied to LASIK, PRK, SMILE, and Transepithelial PRK procedures using Designer Cornea® software.

**Results:** A theoretical treatment profile is derived from an actual example of a cornea with idiopathic asymmetric non-orthogonal astigmatism. The three steps of the derivation are: (i) astigmatism reduction through the use of the Vector Planning technique, (ii) regularization, and (iii) smoothing across the hemidivisional midline.

**Conclusion:** Hemidivisional Vector Planning treatments both reduce and regularize asymmetric non-orthogonal astigmatism. These treatments can be systematically customized to account for qualitative and quantitative differences between the two corneal hemidivisions at the same time as correction of coexistent myopia or hyperopia.

FP-186

## Correlation between decentration after SMILE and index of corneal anterior surface morphology before surgery for high myopia

H Zeng, R Ji, R Zhang, L Sun.

**Objective:** To analyze the correlation between decentration after Small Incision lenticule extraction (SMILE) and index of corneal anterior surface morphology before surgery for high myopia.

**Methods:** This retrospective study included 86 right eyes of 86 high myopia patients who met the inclusion criteria and underwent SMILE surgery in Joint Shantou International Eye Center from August 2017 to December 2019. Visual acuity, refraction, intraocular pressure, anterior segment, fundus and topography was examined before and 3 months after SMILE. Index of corneal anterior surface morphology ( index of surface variance [ISV], index of vertical asymmetry [IVA], keratoconus index [KI], central keratoconus index [CKI], index of height asymmetry [IHA], index of height decentration [IHD]) , corneal tangential curvature and kappa angle was collected from Pentacam HR. Image J software was used to measure decentration.

**Results:** The mean of SEQ was  $(-6.47 \pm 0.82)$  D before SMILE. Kappa angle was not correlated with the decentrations ( $p > 0.05$ ). 1.The results of decentration: At 3 months after SMILE, the mean of horizontal decentration, vertical decentration, total decentration was  $(0.14 \pm 0.11)$  mm,  $(0.24 \pm 0.17)$  mm and  $(0.30 \pm 0.17)$  mm. The results of Index of corneal anterior surface morphology (preoperative) : ISV, IVA, KI, CKI , IHA and IHD was  $15.78 \pm 3.74$ ,  $0.10 \pm 0.40$ ,  $1.03 \pm 0.18$ ,  $1.01 \pm 0.01$ ,  $5.20 \pm 3.76$  and  $0.01 \pm 0.00$ . 2.The results of correlation between decentration and Index of corneal anterior surface morphology: The vertical decentration is correlated with IHD ( $r=0.340$ ,  $p=0.001$ ) and IVA ( $r=0.292$ ,  $p=0.006$ ). The horizontal decentration is correlated with CKI ( $r=0.257$ ,  $p=0.017$ ). The total decentration is correlated with IHD ( $r=0.270$ ,  $p=0.012$ ).

**Conclusion:** IHD, IVA and CKI of the high myopia patients before SMILE may affect the decentration after SMILE. Among the 3 factors, IHD before surgery had the highest positive correlative index with decentration. The horizontal decentration and total decentration after SMILE increase with IHD. When using coaxial corneal light reflex (CCLR) as cutting center, kappa angle has little influence on decentration.

FP-187

**1.Refractive and visual outcomes of SMILE with intraoperative angle kappa adjustment for myopia correction.**Th.

**Objective:** To investigate the refractive and visual outcomes of small incision lenticule extraction (SMILE) with intraoperative angle kappa adjustment guided by the Atlas 9000 corneal topography for myopia and myopic astigmatism correction.

**Methods:** Prospective randomized controlled clinical trial. A total of 193 patients (193 eyes) with myopia and myopic astigmatism who were about to undergo SMILE were included in this study. Patients were randomly allocated into two groups: the first group was the observation group (100 eyes) with the intraoperative angle kappa adjustment guided by the corneal topography (Atlas 9000); the second group was the control group (93 eyes) without the angle kappa adjustment. UDVA, CDVA, refractive outcomes, the cornea and whole-eye HOAs were measured and compared preoperatively, and at 1 day, 1 week, 1 and 3 months postoperatively.

**Results:** At 3 months postoperatively, UDVA (LogMAR) of the observation group and the control group were  $-0.12 \pm 0.07$  (range:  $-0.20$  to  $0.00$ ) and  $-0.11 \pm 0.07$  (range:  $-0.20$  to  $0.00$ ), respectively ( $P=0.270$ ); The CDVA (LogMAR) was  $-0.15 \pm 0.05$  (range:  $-0.20$  to  $0.00$ ) and  $-0.15 \pm 0.05$  (range:  $-0.20$  to  $0.10$ ), respectively ( $P=0.199$ ); The spherical equivalent (SE) was  $-0.12 \pm 0.39$  (range:  $-1.13$  to  $0.5$ ) D and  $-0.10 \pm 0.39$  (range:  $-1.00$  to  $0.75$ ) D, respectively ( $P=0.952$ ); respectively ( $P=0.690$ ). At 3 months postoperatively, the safety indices were  $1.36 \pm 0.16$  (range:  $1.00$  to  $1.50$ ) in the observation group and  $1.34 \pm 0.17$  (range:  $1.00$  to  $1.88$ ) in the control group ( $P=0.371$ ); The efficacy indices were  $1.28 \pm 0.19$  (range:  $1.00$  to  $1.50$ ) in the observation group and  $1.26 \pm 0.20$  (range:  $1.00$  to  $1.88$ ) in the control group ( $P=0.394$ ). As for the HOAs, the corneal and whole-eye vertical coma at 1 and 3 months postoperatively in the observation group were significantly lower than those in the control group ( $P=0.017$ ;  $P=0.018$ ).

**Conclusion:** The corneal topography Atlas 9000 could safely and effectively guide the angle kappa adjustment during SMILE for myopia correction with great feasibility, so as to reduce the postoperative corneal and whole-eye higher order aberrations (HOAs) and optimize postoperative visual quality.

FP-188

**Visual outcomes of SMILE for myopic astigmatism  $\geq -3.00$  D using a triple marking method and manual cyclotorsion compensation**S Salguti<sup>1</sup>, S Ganesh<sup>1</sup>, S Brar<sup>1</sup>.<sup>1</sup>PhacoRefractive Department, Ophthalmology., Nethradhama Superspeciality Eye Hospital, Bangalore, India, bangalore, India**Objective:** To evaluate the clinical outcomes and long-term safety, efficacy, predictability, and refractive stability following myopic astigmatism correction with SMILE in eyes with cylinders  $\geq -3.00$  D**Methods:** This retrospective study included eyes undergoing SMILE for myopic astigmatism with pre-op cylinders  $\geq -3.00$  D. A nomogram aiming for 15%, 10% and 0% over correction for WTR, oblique and ATR astigmatism was applied. Intra-operatively, cyclotorsion compensation was performed by gentle rotation of the contact glass after marking the cornea with a 3-reference marker (Ganesh bubble marker, Epsilon, USA). The mean post-operative follow-up for was 18.08 months.**Results:** Fifty eyes from 50 patients (mean age  $29.7 \pm 6.35$  years) were included. The pre-operative mean sphere, cylinder and SE was  $-2.11 \pm 1.68$ ,  $-3.53 \pm 0.46$ , and  $-3.87 \pm 1.65$  D, which reduced to  $-0.03 \pm 0.08$ ,  $-0.21 \pm 0.34$ , and  $-0.14 \pm 0.23$  respectively at 18 months. Ninety- two % and 82 % eyes, respectively, remained within  $\pm 0.50$  D of manifest SE and cylinder. Eighty % eyes maintained a UDVA of 20/20 or better. Twenty- four % eyes gained 1 or more lines, while no eye lost more than 1 line of CDVA. Safety and Efficacy indices were 1.13 and 1.01 respectively. Vector analysis suggested mean TIA, SIA, AOE and CI values of  $-3.39 \pm 0.43$ ,  $-3.44 \pm 0.51$ ,  $6.22 \pm 21.43$  degrees and  $1.01 \pm 0.10$  respectively. No eye developed post-operative ectasia or underwent enhancement for significant residual refractive error.**Conclusion:** At 18 months, our results demonstrate good safety, efficacy, predictability, and stability of SMILE for high astigmatism ( $> -3.00$  D cylinder), using a triple marking method, manual cyclotorsion compensation and appropriate nomogram.

FP-189

## Retinal displacement On Fundus Autofluorescence Imaging: The Tip Of the Iceberg

E Roditi<sup>1,2</sup>, M Potter<sup>1</sup>, H Totah<sup>1</sup>, H Cain, M Devir, A Bensal<sup>3</sup>, R Muni<sup>3</sup>, K Brosh<sup>1</sup>.

<sup>1</sup>Ophthalmology, Shaare Zedek Medical Center, Jerusalem, Israel, <sup>2</sup>Ophthalmology, Westmead Hospital, Sydney, Australia, <sup>3</sup>Ophthalmology, St. Michael Hospital, Toronto, Canada

**Objective:** Retinal displacement has been documented to occur commonly following pars plana vitrectomy for rhegmatogenous retinal detachment (RRD) repair and has been associated with worse functional outcomes. Although fundus autofluorescence (FAF) imaging can identify retinal displacement, there is a concern regarding the accuracy of detection.

This study assesses the sensitivity and specificity of detecting retinal displacement with FAF imaging following PPV for RRD.

**Methods:** A retrospective study of all patients with infrared (IR) images available before the occurrence of RRD and after RRD repair. At least 4 corresponding RPE and choroidal landmarks were marked on pre-RRD & post-RRD IR images extracted from the optical coherence tomography (OCT). Overlay of IR images based on the marked landmarks utilized a computer code in Python to compute the homography and then align the two images. The same procedure was carried out in the contralateral normal eyes to validate the technique. Two masked graders analyzed both the post-operative FAF and the IR overlay images to detect the presence and extent of retinal displacement.

**Results:** Fifteen eyes had both a pre-RRD & post-RRD repair OCT and a post-RRD FAF. In 8 patients, the contralateral eye had no other pathology or history of RRD. Homography was able to perfectly align the contralateral eye IR images in 100% (8/8) of cases. Retinal displacement was detected in 73.3% (11/15) of FAF images and in 93.3% (14/15) of IR overlay images respectively. FAF had specificity and sensitivity of 100% and 78.6%, respectively in detecting retinal displacement when using the IR overlay images as a gold standard. The extent of retinal displacement was far greater when observed on the IR overlay images with a mean number of displaced vessels of  $1.1 \pm 0.88$  in the FAF group and  $2.9 \pm 1.05$  in the IR overlay group ( $p=0.00004$ ). Qualitatively, the IR overlay method was superior at demonstrating both the presence and extent of retinal displacement compared to FAF.

**Conclusion:** FAF does not demonstrate the full extent of retinal displacement that is present and reveals only the “tip of the iceberg”. Furthermore, some cases with true retinal displacement could be missed on FAF. When available, overlay of pre-RRD & post-RRD repair IR images generated by OCT provides a better assessment of retinal displacement. Advancements in multimodal imaging and image processing are required to detect the full extent of retinal displacement with greater sensitivity.

FP-190

## Correlation between retinal displacement and outer retinal tomographic changes after retinal detachment surgery

R Maroto Cejudo<sup>1</sup>, S Copete Piqueras<sup>1</sup>, C Blanco Marchite<sup>1</sup>, T Prieto Morán<sup>1</sup>, A Donate Tercero<sup>1</sup>, C Cava Valenciano<sup>1</sup>, F López Martínez<sup>1</sup>, S Pérez Pascual<sup>1</sup>.

<sup>1</sup>Albacete University Hospital Complex, Albacete, Spain

**Objective:** To analyze tomographic changes in outer retinal layers after vitrectomy for rhegmatogenous retinal detachment (RD) and its association with the presence of retinal displacement.

**Methods:** Retrospective study that included outer retina tomographic analysis of 42 patients with RD who underwent RD surgery in 2018 and 2019 at Albacete University Hospital Complex (Spain). Tomographic images obtained with spectral-domain optical coherence tomography (SD-OCT) at 3, 6 and 12 months after RD surgery were analyzed according to the presence or absence of alterations in outer retinal layers (external limiting membrane, ellipsoid zone and interdigitation zone). Autofluorescence images at 6 months were also observed to detect retinal displacement. Exclusion criteria were: Presence of previous retinal pathology, age under 18 years and images of insufficient quality.

**Results:** The mean age was  $60,14 \pm 10,71$ . Any grade of retinal displacement was detected in 50% of autofluorescence images. Alterations in external limiting membrane (ELM) layer at 3, 6 and 12 months were detected in 45,2%, 19% and 14,3% of images respectively. Changes in ellipsoid zone (EZ) were observed in 69%, 38,1% and 28,6% and changes in the interdigitation zone (IZ) were detected in 73,8 %, 42,9% and 31% respectively. Improvement in ELM layer occurred in 31% of images after 12 months, in EZ was observed in 45,2% and 47,6% in IZ . Of the total of patients with retinal displacement detected at 3 months, 17 (85%) showed alterations in the EZ, with a statistically significant difference (Chi-squared-test,  $p = 0,038$ ). IZ layer showed alterations in similar proportion but no significant differences were detected ( $p=0.144$ ). Association between the presence of retinal displacement and improvement of EZ at 6 and 12 months was observed (Chi-squared-test,  $p = 0,014$  and  $0.004$  respectively). No other significant differences were observed at different times.

**Conclusion:** Retinal displacement after retinal detachment surgery is associated with higher rate of tomographic alterations in the EZ at 3 months, as with an increased probability of improvement of those changes at 6 and 12 months.



FP-191

**Vitreous interface characteristics of IRVAN syndrome and the effect of minimally invasive vitrectomy**S Li.

**Objective:** To analyze the changes of vitreous interface in IRVAN syndrome and the effect of minimally invasive vitrectomy.

**Methods:** The clinical data of 8 cases(16 eyes) with IRVAN syndrome were analyzed retrospectively. The status of vitreous interface at the posterior pole of all patients was analyzed by OCT. Among them, 9 eyes of 6 cases underwent minimally invasive vitreous surgery. The posterior vitreous cortex and proliferative membrane were completely removed with the help of triamcinolone acetonide, and the visual acuity before and after operation were compared. the regression rate retinal arterial aneurysms and the absorption rate of hard exudation were observed.

**Results:** All the 8 patients were female, aged from 9 to 41 years old, with an average of 30 years old. Red retinal arterial aneurysms were seen on the surface of optic disc and branches of peridisc artery in all patients, yellow circular exudation were seen around these optic discs. FFA of all patients showed that there were large capillary nonperfusion area in the peripheral retina. OCT examination showed proliferative membrane on the surface of optic disc in 15 eyes of 8 cases. According to the diagnostic criteria, IRVAN syndrome was diagnosed as stage 2 in 6 cases(12 eyes), stage 3 in 2 cases (3 eyes) and stage 5 in 1 eye (eyeball atrophy after vitreous surgery in other hospital). All 15 eyes of 8 cases were treated with fundus laser.

Nine eyes of six cases were followed up from 7 months to 122 months after minimally invasive vitrectomy combined with membrane peeling , with an average of 47 months. The visual acuity of 8 eyes was improved and 1 eye remained unchanged. The aneurysms and hard exudation on the surface of the optic disc and around the optic disc all disappeared. Although the condition of 4 cases (6 eyes) without operation was basically controlled after fundus laser and corticosteroid treatment, there was no significant change in arterial aneurysms and peridisc hard exudation on the surface of optic disc.

**Conclusion:** IRVAN syndrome is common in women and occurs in both eyes. In this study, it was found that the posterior vitreous cortex of the vitreoretinal interface at the posterior pole thickened. Vitrectomy removes the abnormal vitreoretinal interface and improves the oxygen supply on the retinal surface, which may be an effective method for the treatment of IRVAN.

FP-192

**Novel i-OCT assisted Sub-capsular Vitrectomy Technique: a Necessary Step to Prevent Intractable Sub-capsular Opacification**Y Bi<sup>1,2</sup>, M Lin<sup>1</sup>.<sup>1</sup>Ophthalmology, Tongji Hospital affiliated with Tongji University, <sup>2</sup>Ophthalmology, Eye institute of Tongji University, Shanghai, People's Republic of China**Objective:** To investigate the clinical effect of vitrectomy behind posterior capsular lens.**Methods:** Sixty-three eyes of 63 patients who underwent phacoemulsification intraocular lens implantation combined with vitrectomy in our hospital from January 2020 to April 2021 were collected. All eyes were filled with silicone oil and subsequently removed. According to different surgical methods, the groups were divided into Berger resection group and Berger retention group. In the Berger resection group, a complete vitreous anterior cortex resection was performed within a range of about 8mm behind the posterior capsular lens, this step was assisted by the intraoperative optical coherence tomography (i-OCT). The excision was performed alternately by suction and cutting under negative pressure. The residual degree of silicone oil droplets and vitreous cortex in posterior capsule of lens after silicone oil removal were graded. Grade 0 is free of silicone oil droplets or visible vitreous cortical residue.**Results:** After the silicone oil was removed in Berger resection group, the posterior capsular area of the crystal was clear, no obvious silicone oil droplets remained. After the removal of silicone oil in Berger retention group, different degrees of turbidity and silicone oil droplets remained in the subcapsular region of posterior crystal, with significant difference between the two ( $P < 0.05$ ).**Conclusion:** Complete and safe resection of the vitreous cortex behind the capsule of the lens can reduce the residual silicone oil droplets and the compressed turbidity of the cortex after removal of silicone oil.

FP-193

**Dry-lensectomy assisted lensectomy in the management for end-stage familial exudative vitreoretinopathy**J Peng, P Zhao<sup>1</sup>.

<sup>1</sup>Ophthalmology, Xinhua hospital affiliated to Shanghai Jiao Tong University School of Medicine, Shanghai, People's Republic of China

**Objective:** To report a modified technique of dry-lensectomy assisted lensectomy in the management of end-stage familial exudative vitreoretinopathy (FEVR) complicated with capsule-endothelial, iris-endothelial adhesion and secondary glaucoma.

**Methods:** 24 eyes of 16 patients with severe complications of advanced pediatric total retinal detachment caused by FEVR who received limbus-based dry-lensectomy were studied retrospectively. Preoperative and postoperative clinical information was collected and reviewed.

**Results:** Among the 24 eyes, three eyes (12.50%) underwent lensectomy combined with vitrectomy and membrane peeling simultaneously. 21 (87.50%) eyes underwent staged-lensectomy due to severe corneal opacity or retinal vascular activity, of which eight underwent another vitrectomy combined with membrane peeling. At the last visit (mean:  $13.86 \pm 5.24$  months of follow-up), all eyes had a reconstructed anterior chamber with normal depth. Among 21 eyes having preoperative corneal opacity, 15 (71.43%) had a clearer cornea with reduced opacity, 6 (28.57%) showed similar corneal opacification without deterioration. Among 11 eyes undergone retrolental fibroplasia peeling, six (54.55%) eyes showed partial retinal reattachment in open-funnel type.

**Conclusion:** Dry-lensectomy offered a simple way to lower the IOP and simplified the surgery, which helped to solve the severe anterior segment complications and offer a chance for following retrolental fibroplasia peeling and potential visual gain for selected end-stage FEVR patients.

FP-194

## Efficiency of Laser on the Prevention of Retinal Detachment in Acute Retinal Necrosis: A Systematic Review and Meta-Analysis

M Chen, M Zhang, H Chen.

**Objective:** To evaluate whether prophylactic laser is effective for RD following ARN.

**Methods:** PubMed, Embase and Cochrane databases were searched, and the retrieved records were screened. Each included study has well-defined laser treated group and control group without laser treatment, or with enough data for manual grouping. The quality of the included studies was assessed using ROBINS-I ("Risk Of Bias In Non-randomised Studies - of Interventions"). Meta-analysis was conducted to calculate the pooled odds ratios (ORs) and their 95% confidence interval (CI). Sensitivity analysis was used to test the solidarity, and subgroup analysis was performed to determine the source of heterogeneity.

**Results:** 14 studies with a total of 532 eyes were eventually included. The quality of the included studies was moderate. The combined results showed that the pooled OR was 0.61 (95% CI [0.41~0.90],  $P < 0.05$ ,  $I^2 = 27\%$ ). Sensitivity analysis showed that the ORs were similar when excluding any study. Subgroup analysis showed moderate heterogeneity among three subgroups ( $I^2 = 48.0\%$ ,  $P = 0.15$  for heterogeneity) and the OR in antiviral therapy and steroid combined with prophylactic laser was 0.43 (95% CI [0.25~0.74],  $P < 0.05$ ,  $I^2 = 0\%$ ).

**Conclusion:** In patients with ARN, laser photocoagulation is an effective treatment to prevent RD, especially in the subgroup combined with antiviral therapy and steroid.

FP-195

## Real-World Efficacy and Safety of the Ranibizumab Port-Delivery System in Neovascular AMD: The SUMMIT Study

H Khan<sup>12</sup>, T Ewing<sup>1</sup>, A Aziz<sup>2</sup>, M Masud<sup>2</sup>, H Sulahria<sup>1</sup>, M Khan<sup>2</sup>, D Pieramici<sup>3</sup>, J Kitchens<sup>4</sup>, N Holekamp<sup>5</sup>, V Sheth<sup>67</sup>, J Graff<sup>89</sup>, D Eichenbaum<sup>1011</sup>, A Saulebayeva<sup>1</sup>, A Khanani<sup>12</sup>.

<sup>1</sup>Sierra Eye Associates, <sup>2</sup>University of Nevada Reno School of Medicine, Reno, <sup>3</sup>California Retina Consultants, Bakersfield, <sup>4</sup>Retina Associates of Kentucky, Lexington, <sup>5</sup>Pepose Vision Institute, Chesterfield, <sup>6</sup>University Retina and Macula Associates, <sup>7</sup>University of Illinois at Chicago College of Medicine, Chicago, <sup>8</sup>BDP Eye Center at American Vision Partners, <sup>9</sup>The University of Arizona College of Medicine Phoenix, Phoenix, <sup>10</sup>Retina Vitreous Associates of Florida, Tampa Bay, <sup>11</sup>Ophthalmology, USF Health Morsani College of Medicine, Tampa, United States

**Objective:** FDA approved anti-VEGF therapeutic agents have transformed neovascular age-related macular degeneration (nAMD) treatment, but real-world evidence indicates a decrease in visual acuity over time due to injection frequency. The ranibizumab port-delivery system (PDS) was FDA approved for the treatment of nAMD in late 2021 to reduce injection frequency, alleviating patient burden. The SUMMIT study is a multi-center, retrospective study that will evaluate the efficacy and safety of PDS as a long-term nAMD treatment.

**Methods:** Patients will receive the PDS implant following diagnosis of nAMD with a favorable response to at least two anti-VEGF intravitreal injections. Following implantation, subsequent refill exchange procedure in clinic will be conducted every 24 weeks. Efficacy of PDS will be evaluated through changes in best corrected visual acuity (BCVA), the presence or absence of subretinal/intraretinal fluid (SRF/IRF), and central subfield thickness (CST) values via optical coherence tomography (OCT) scans. Safety will be monitored through documentation of adverse events. Need for supplementary ranibizumab 0.5 mg injections will be evaluated.

**Results:** Due to the recent approval of PDS in October 2021, this study is currently ongoing. Full patient data will be available by the time of presentation.

**Conclusion:** FDA approval of PDS is based on favorable visual and anatomic outcomes from the Phase III Archway trial (NCT03677934). Patients with nAMD endure high treatment burden and potential worsening of disease activity due to high frequency of injections. This study is designed to evaluate the efficacy and safety of PDS in controlling nAMD disease progression and reduction of patient burden.

FP-196

## Nanopore Targeted Sequencing to Identify Pathogenic Microorganisms in Patients with Postoperative Endophthalmitis

X Hao<sup>1</sup>, W Jin<sup>1</sup>, A Yang<sup>1</sup>.

<sup>1</sup>Ophthalmology, Renmin Hospital of Wuhan University, Wuhan, People's Republic of China

**Objective:** To investigate the clinical characteristics of postoperative endophthalmitis, to identify the associated etiological agents using nanopore targeted sequencing (NTS), and to evaluate the feasibility of clinical application of NTS.

**Methods:** In this retrospective study, we reviewed the medical records and etiological results of 41 patients (41 eyes) with postoperative endophthalmitis whose samples were examined using both NTS and microbial culture.

**Results:** Cataract surgery was the most common predisposing factor for postoperative endophthalmitis (31 of 41 patients, 75.61%). Twenty-nine of these 31 patients with post-cataract endophthalmitis had risk factors such as advanced age and systemic diseases. Their mean best corrected visual acuity (BCVA) improved from logMAR 2.13 ± 0.55 at baseline to logMAR 1.46 ± 0.77 after treatment ( $P < 0.001$ ), and 34 individuals (82.93%) showed improvements in terms of visual outcomes. NTS helped detect etiologic agents in 90.24% of the patients, which is higher than that detected using microbial culture ( $P < 0.001$ ). In nine of 13 patients who showed culture-positivity, these results corresponded with those of NTS. Moreover, species resolution was better with NTS than with the traditional culture-based technique in one case, and the former led to the identification of additional species in three patients. NTS could detect bacteria and fungi simultaneously within 48 h in all patients. The average time required to obtain NTS results was 1.15 ± 0.36 days, which is shorter than that for microbial culture ( $P < 0.001$ ).

**Conclusion:** NTS can provide rapid identification and highly sensitive detection of pathogens among patients with postoperative endophthalmitis. Thus, it serves as a highly efficient supplemental method.

FP-197

## Vascular Endothelial Growth Factor (VEGF) Levels in Serum and Vitreous in Different Stages of Diabetic Retinopathy

S Buragohain, M Barman<sup>1</sup>, S Roy<sup>1</sup>, P Bhola<sup>1</sup>, H Deka<sup>2</sup>.

<sup>1</sup>Vitreo-retina, <sup>2</sup>Medical Retina, Sri Sankaradeva Nethralaya, Guwahati, India

**Objective:** This study aimed to quantify and compare VEGF levels in vitreous humor and blood (serum) of patients having diabetic retinopathy (DR) of varying severity with an age-matched control population and to correlate it with systemic factors.

**Methods:** 150 patients were enrolled in this prospective, observational, case-control study. Vitreous and serum samples were collected from treatment naïve proliferative diabetic retinopathy (PDR) and non-proliferative diabetic retinopathy (NPDR) cases (50 from each) and age-matched non-diabetic cases as controls (50) to estimate VEGF levels. Systemic parameters like blood glucose, HbA1C, Hb, smoking habit, lipid profile, serum creatinine and blood pressure were checked and standardized to a comparable level. VEGF levels were estimated by ELISA test.

**Results:** VEGF levels in serum were  $154.26 \pm 10.78$ pg/mL,  $163.43 \pm 4.64$ pg/mL,  $170.93 \pm 9$ pg/mL,  $201.42 \pm 19.9$ pg/mL,  $321.6 \pm 70.24$ pg/mL and in vitreous humor were  $165.65 \pm 11.24$ pg/mL,  $177.06 \pm 8.6$ pg/mL,  $228 \pm 31.4$ pg/mL,  $453.36 \pm 86.6$ pg/mL,  $819.8 \pm 119.4$ pg/mL in controls, mild NPDR, moderate NPDR, severe NPDR and PDR respectively. VEGF levels had significant positive correlation with BMI ( $r= 0.446$ ,  $p = 0.000$ ), TGL ( $r= 0.30$ ,  $p = 0.000$ ), LDL ( $r= 0.30$ ,  $p = 0.000$ ), FBS ( $r= 0.73$ ,  $p = 0.000$ ), & HbA1c ( $r= 0.79$ ,  $p = 0.000$ ).

**Conclusion:** VEGF levels in the intraocular environment and systemic circulation showed a positive correlation with severity of diabetic retinopathy. There was a strong association of VEGF with lipid profile in such patients.

FP-198

**Clinical study on the treatment of RRD by external scleral jacking with foldable capsular vitreous body**F Fan, S Li.

**Objective:** To compare the efficacy and complications of scleral buckling of silica gel and external scleral jacking with foldable capsular vitreous body(FCVB) in the treatment of RRD.

**Methods:** Prospective randomized controlled studies. The clinical data of 28 cases (28 eyes) who were diagnosed as RRD and eligible for scleral buckling surgery from August 2020 to March 2022 were selected. According to the different pressurizing materials during surgery, the patients were divided into group silica gel and group balloon, with 15 patients (15 eyes) in group silica gel and 13 patients (13 eyes) in group balloon. The duration of intraoperative eye surgery and intraoperative complications were compared between the two groups. After 6 months of follow-up, BCVA, SE and DC, and ocular axis, surface and F-ERG related parameters, postoperative comfort score, and OSDI score, postoperative anatomical reset rate and surgical complications occurred before and after surgery were evaluated. Data were analyzed by T-test, Chi-square test and Fisher exact method.

**Results:** Six months postoperative follow-up, there was no significant difference in the final retinal anatomical reduction rate between the two groups ( $P > 0.05$ ). The difference of the surgery time was not statistically significant ( $P > 0.05$ ). The DC of the eyes in group silica gel increased after surgery significantly compared with before surgery, and the difference was statistically significant (all  $P < 0.05$ ). The ACD depth of the eye was decreased after surgery in both groups and the difference was statistically significant (all  $P < 0.05$ ). The comfort scores and TMH of patients in the group silica gel were significantly lower than those in the group balloon, and the differences were statistically significant ( $P < 0.05$ ). The OSDI scores and subjective pain scores of the patients in the group silica gel were higher than those in the group balloon and the differences were statistically significant ( $P < 0.05$ ). Postoperative diplopia occurred in 5 eyes of the group balloon and no diplopia occurred in the group silica gel. There were no other postoperative complications in the group silica gel and the group balloon during the 6-month follow-up.

**Conclusion:** The success rate of anatomical reduction in the treatment of RRD by external scleral jacking with FCVB is the same as that by scleral buckling of silica gel, with good safety, and can be promoted clinically.



FP-199

## Key Clinical Pearls for Evaluating Surgical Candidates, and Patient Preference, for the Port Delivery System With Ranibizumab

A Koh<sup>1</sup>, M Figueroa<sup>2</sup>, N Holekamp<sup>3</sup>, A Bobbala<sup>4</sup>, N Callaway<sup>4,5</sup>, S DeGraaf<sup>4</sup>, A Menezes<sup>4</sup>, D Heinrich<sup>6</sup>.

<sup>1</sup>Eye and Retina Surgeons, Camden Medical Centre, Singapore, Singapore, <sup>2</sup>Clinica Baviera, Hospital Universitario Ramón y Cajal, Madrid, Spain, <sup>3</sup>Pepose Vision Institute, Chesterfield, <sup>4</sup>Genentech, Inc., South San Francisco, <sup>5</sup>Stanford University Byers Eye Institute, Palo Alto, United States, <sup>6</sup>F. Hoffmann-La Roche Ltd., Basel, Switzerland

**Objective:** The Port Delivery System with ranibizumab (PDS) is a US Food and Drug Administration–approved drug delivery system that includes a refillable ocular implant for continuous delivery of a customised formulation of ranibizumab (RBZ). It is surgically implanted in the superotemporal quadrant at the pars plana. Here we report key clinical pearls for pre-operative evaluation of PDS surgical candidates and patient preference for the PDS vs intravitreal (ITV) injections.

**Methods:** Archway (NCT03677934) was a phase 3, randomised, active treatment–controlled trial for the treatment of neovascular age-related macular degeneration (nAMD). The safety and efficacy of PDS 100 mg/mL with fixed refill-exchanges every 24 weeks vs ITV RBZ 0.5 mg injections every 4 weeks were investigated in patients with nAMD. Treatment preference was assessed in the PDS arm at week 40 using the PDS Patient Preference Questionnaire.

**Results:** PDS candidates require careful pre-operative evaluation, including thorough review of medical and surgical history, to identify factors that may negatively affect conjunctival health and impact suitability for PDS implantation. A history of prior conjunctival-based surgery or trauma may lead to conjunctival scarring or poor tissue integrity. Long-term use of topical medications (eg, for glaucoma) may affect conjunctival quality, causing inflammation, scarring and reduced thickness. Relevant ocular medical history (eg, severe ocular surface disease, scleritis, uveitis, iritis, high myopia) or concomitant conditions (eg, scleroderma, pemphigoid or Sjogren’s syndrome) may also affect conjunctival or scleral integrity.

Examination of the conjunctiva and Tenon’s capsule should be performed pre-operatively at the slit lamp with a cotton swab to assess mobility, scarring and translucency/thickness. Eyelid health should also be evaluated, with attention to lid hygiene, position and mobility, because these may impact post-operative infection risk and wound healing.

In Archway, 93.2% of PDS-treated patients (n = 234) preferred RBZ delivery via the PDS compared with ITV injections. Patients’ top reasons for preferring the PDS were fewer treatments, less discomfort and less worry/nervousness.

**Conclusion:** Careful pre-operative evaluation is required to ensure optimal surgical outcomes for PDS candidates. PDS-treated patients demonstrate a marked preference for the PDS over ITV injections. Consistent attention to the clinical pearls described should help to maintain high levels of patient satisfaction.

FP-200

## Long-term Follow-up of Primary Silicone Oil Tamponade for Retinal Detachment Secondary to Macular Hole in Highly Myopic Eyes

M Li, J Qu<sup>1</sup>, M Zhao<sup>1</sup>.

<sup>1</sup>Ophthalmology, Peking University People's Hospital, Beijing, People's Republic of China

**Objective:** To investigate the risk factors associated with retinal detachment recurrence after first vitrectomy in high myopic eyes with macular hole retinal detachment (MHRD).

**Methods:** Patients with high myopic eyes with MHRD who underwent pars plana vitrectomy and silicone oil tamponade with a follow-up period more than 12 months and more than 3 months after silicone oil removal were included in this retrospective study. Logistic regression was performed to determine the risk factors associated with retinal re-detachment.

**Results:** A total of 45 eyes from 43 patients were included in this study (11 male and 34 female patients). The retinal re-detachment rate after the first removal of silicon oil was 35.5% (16/45) in a mean postoperative follow-up time of  $35.64 \pm 32.94$  months. Complete macular atrophy on fundus photography (odds ratio [OR]= 17.021, 95% confidence interval [95% CI] 2.218-130.609,  $p=0.006$ ) was a risk factor for MHRD after SO removal, while ILM peeling (OR=0.091, 95% CI 0.013-0.633),  $p=0.015$ ) and duration of SO tamponade (OR= 0.667, 95% CI 0.454-0.980,  $p=0.039$ ) were protective factors.

**Conclusion:** For high myopic eyes with MHRD, complete macular atrophy was a significant risk factor for retinal re-detachment after silicon oil removal. ILM peeling and the duration of silicon oil tamponade were protective factors.

FP-201

## A New Perspective on the Evaluation of Fuchs Uveitis Syndrome

P Kaya<sup>1</sup>, Y Özdamar Erol<sup>1</sup>.

<sup>1</sup>Ophthalmology, Health Sciences University Ulucanlar Eye Training and Research Hospital, Ankara, Türkiye

**Objective:** To investigate vitreo-lenticular, vitreo-macular interface and anterior vitreous structure in Fuchs uveitis syndrome (FUS) with using optical coherence tomography (OCT).

**Methods:** This prospective, controlled, randomised single-centre study included 20 Fuchs uveitis patients (13 females) and 20 healthy individuals (10 females) with the mean age of  $40.2 \pm 10.3$  and  $35.1 \pm 6.23$  respectively. OCT scanning was performed on the device SOLIX (OPTOVUE, USA), high resolution-spectral optical coherence tomography (OCT). The scans were performed in the Full Range AC mode with the parameters of 18 mm in horizontal length and 6.25 mm in the axial dimension for lens and anterior vitreous. Full Range Retina mode with 16 mm in horizontal length was used for posterior segment. Clinical features, the lens thickness, presence and distance of Berger space, posterior vitreous detachment and the presence of premacular bursa were evaluated. The parameters of eyes with FUS, healthy eyes of patients and healthy participants' were compared.

**Results:** The patients were divided into 3 groups as FUS (Group 1), the fellow eyes of FUS patients (Group 2) and the healthy control group (Group 3). There was no statistical difference between the groups in term of gender and age ( $p = 0.535$  and  $p = 0.136$ ). Best corrected visual acuity was  $0.54 \pm 0.29$ ,  $0.94 \pm 0.1$  and  $1.00$  with Snellen chart in the groups respectively ( $p < 0.001$  between group 1 and 3). Lens thickness in groups was  $2924.95 \pm 561.75 \mu$ ,  $3066.80 \pm 672.27 \mu$  and  $3040.40 \pm 565.72 \mu$  respectively and there was no statistically difference. Berger space was detected in all of eyes with FUS, 19 eyes (95%) in the fellow eyes of patients and 12 eyes (60%) in control group ( $p < 0.05$ ). Hyperreflective spots were identified in Berger spaces in 13 of 20 eyes (65%) with FUS. The measurements of Berger space the distance in central, nasal 2 mm and temporal 2 mm were  $715 \pm 101 \mu$ ,  $620 \pm 66 \mu$ ,  $676 \pm 76 \mu$  in group 1. They were  $370 \pm 40 \mu$ ,  $321 \pm 41 \mu$ ,  $297 \pm 39 \mu$  in group 2 and  $290 \pm 37 \mu$ ,  $267 \pm 32 \mu$ ,  $227 \pm 28 \mu$  in group 3. There was a statistical difference between the group 1 and 2<sup>nd</sup> and 3<sup>rd</sup> in all the values. But there was not a difference between group 2 and 3.

**Conclusion:** The present study is the first to investigate the structure of Berger space in FUS patients. Berger space was found to be significantly larger in FUS patients than the fellow eyes of patients and healthy controls and hyperreflective spots were detected in Berger space in FUS patients.

## FP-202

**Comparison of the safety and efficacy of IFN- $\alpha$  2a and CsA in the treatment of refractory Behçet's uveitis: A RCT study**

Y Qian, Y Qu, M Zhang, C Zhao.

**Objective:** To evaluate and compare the efficacy and safety of interferon alpha-2a (IFN- $\alpha$  2a) and cyclosporine-A (CsA) in patients with refractory Behçet's uveitis (BU).

**Methods:** In this 12-month randomized, controlled, prospective trial, 26 participants (44 eyes) completed the study. Patients were randomly allocated to the IFN- $\alpha$  2a or CsA groups. All patients in both groups received a standardized prednisone burst and tapering schedule as per protocol. The primary outcome measures were response rate, complete remission rate, and tolerance rate. The secondary outcome measures included time to achieve complete remission, the logarithm of the minimum angle of resolution (logMAR) of best-corrected visual acuity (BCVA), and Behçet's disease ocular attack score 24 (BOS24). T-tests and non-parametric tests were used to compare quantitative variables, and chi-square tests were performed to compare qualitative variables.

**Results:** The response and complete remission rates were 85.7% (12/14 patients) and 50.0% (7/14 patients) in the IFN- $\alpha$  2a group, compared with 66.7% (8/12 patients) and 25.0% (3/12 patients) in the CsA group, respectively ( $p>0.05$ ). Complete remission was achieved at 3.3 and 7.0 months after initiation of IFN- $\alpha$  2a and CsA ( $p=0.023$ ). LogMAR BCVA significantly improved 1 month after IFN- $\alpha$  2a initiation (23 eyes) ( $p=0.002$ ), and this beneficial effect remained statistically significant during the entire follow-up period ( $p<0.05$ ); however, this improvement was not observed in the CsA group (21 eyes). At the endpoint, LogMAR BCVA in the IFN- $\alpha$  2a group was significantly better (0.22 vs. 0.31,  $p=0.031$ ) with a higher improvement rate (60.9 vs. 47.6%,  $p>0.05$ ). Moreover, compared to the CsA group, more eyes in the IFN- $\alpha$  2a group had a lower BOS24 score (87.0 vs. 57.1%,  $p=0.042$ ). None of the patients had any side effects that influenced the medication adherence.

**Conclusion:** Compared to CsA plus corticosteroid, IFN- $\alpha$  2a plus corticosteroid appears to induce a better treatment response, a significantly greater improvement in visual acuity, and more stable remission of intraocular inflammation in a 12-month study period.

FP-203

**Enriched and Decreased Intestinal Microbes in Active VKH Patients**X Liu, M Li.

**Objective:** To determine the possible related to Vogt-Koyanagi-Harada (VKH) disease in comparison to noninfectious anterior scleritis patients and healthy people.

**Methods:** Faecal samples were extracted from 42 individuals, including 11 active VKH patients, 11 healthy people and 20 noninfectious anterior scleritis patients. We amplified the V3-V4 16S rDNA region to obtain the target sequence. Then, the target sequence was amplified by polymerase chain reaction. The obtained target sequences were sequenced by high-throughput 16S rDNA analysis.

**Results:** At the genus level, there were 3 enriched (*Stomatobaculum*, *Pseudomonas*, *Lachnoanaerobaculum*) and 2 depleted microbes (*Gordonibacter*, *Slackia*) that were detected only in VKH patients. There were 10 enriched and 12 depleted microbes that were observed in both VKH disease and noninfectious anterior scleritis patients ( $P < 0.05$ ). The interactions of these microbes were graphed. *Tyzzarella* and *Eggerthella* were the nodes of interaction between these microorganisms, which were regulated by both positive and negative aspects, but the expression level in VKH patients was upregulated.

**Conclusion:** Special or nonspecial enrichment and decreased intestinal microbes were observed in active VKH patients. The action mechanism of these microbes needs further study.

FP-204

**Intravitreal Dexamethasone Implant for Noninfectious Uveitis in Chinese patients**X Liu, S Zeng.

**Objective:** To evaluate the effectiveness and safety of the dexamethasone intravitreal implant (DEX-I) in Non-Infectious Uveitis (NIU) in Chinese patients.

**Methods:** Ninety-one eyes of 77 patients (56 men, 21 women) receiving 130 implant injections for NIU were included. Treatment indication, uveitis diagnosis, best-corrected visual acuity (BCVA), central retinal thickness (CRT), vitreous haze score, intraocular pressure (IOP), phakic status, number of injections, time to reinjection, and systemic treatments were collected at baseline, 1week, 1 month, 3 and 6 months after treatment.

**Results:** All patients were followed at least 12 weeks and had a mean follow-up period of 5.1 months (range, 3-14 months) after the first implant. The main treatment indications were macular edema (ME), retinal vasculitis, retinal vasculitis with ME. Sixty-one eyes (67.03%) received only one injection, while 31 eyes (32.97%) received two or more. In eyes that received 2 injections the mean time to second injection was 3.83 months and that received 3 injections the mean time to third injection was 7.5 months. BCVA and CRT significantly improved at 1week, 1 month, 3 and 6 months after treatment. When compared to baseline, the mean prednisone (or equivalent) dosage significantly decreased at 3- and 6-month follow-up evaluations after DEX implantation. 14.29% of eyes developed a transient increase in intraocular pressure and cataract was removed from 1 phakic eyes.

**Conclusion:** DEX implants, either alone or in combination with common adjunctive NIU treatments, is safe and effective in the treatment of NIU in Chinese patients.

FP-205

### Clinical analysis and predictive factors for Endogenous Bacterial Endophthalmitis: A Ten-Year Experience in Tianjin China

C Mao, H Yan.

**Objective:** To investigate the clinical features and prognostic factors in patients with Endogenous Bacterial Endophthalmitis (EBE).

**Methods:** Clinical features of 36 patients (42 eyes) diagnosed with EBE were reviewed between October 2010 and February 2021. Poor visual outcomes were defined as visual acuity (VA) worse than counting fingers (CF), and variables about prognosis were statistically analyzed on the SPSS 18.0 software. A significance level of  $P < 0.05$  was taken.

**Results:** Diabetes mellitus (DM) was the most commonly associated systemic disease (26/36 [72.2%]), and liver abscess was the major infection source (22/36 [61.1%]), and *Klebsiella pneumoniae* was the most common pathogen (23/36 [63.9%]). 32 of 42 eyes (76.2%) had final VA worse than CF, and 7 eyes required evisceration or enucleation. The inflammatory indicators, such as Neutrophil-to-lymphocyte ratio (NLR), C-reactive protein (CRP) and procalcitonin (PCT) were prognostic factors for poor visual outcomes, the mean level was higher in the poor final VA group than that in the favorable final VA group (NLR:  $9.66 \pm 6.31$  vs.  $5.89 \pm 3.22$ ,  $P = 0.038$ ; CRP:  $61.95 \pm 67.37$  vs.  $12.39 \pm 16.96$ ,  $P = 0.001$ ; PCT:  $8.14 \pm 14.15$  vs.  $1.60 \pm 2.48$ ,  $P = 0.025$ , respectively). Besides, poor initial VA, conjunctival injection, hypopyon, high intraocular pressure, retina involved, *Klebsiella pneumoniae*, and glycosylated hemoglobin (HbA1c) on DM patients were significant risk factors for poor visual outcomes.

**Conclusion:** *Klebsiella pneumoniae* was the most common pathogen of Endogenous Bacterial Endophthalmitis in Tianjin, and also a factor causing poor prognosis. Inflammatory markers can also be used to assess visual outcome earlier. Early and timely intraocular treatment may save some eyes.



FP-206

## CXCL13, CXCL10 and CXCL8 as indicators of ocular and neurological involvement in patients with ocular syphilis

L Van Der Merwe, C *Snyders*<sup>1</sup>, M *Kidd*<sup>2</sup>, N *Chegou*<sup>1</sup>, D *Smit*<sup>3</sup>.

<sup>1</sup>*Division of Molecular Biology and Genetics*, <sup>2</sup>*Centre for Statistical Consultation, Stellenbosch University*, <sup>3</sup>*Tygerberg Academic Hospital, Cape town, South Africa, Cape Town, South Africa*

**Objective:** To investigate the role of the chemokines CXCL13, CXCL10 and CXCL8 in the diagnosis of ocular- and neurosyphilis by examining the serum, aqueous humour (AH) and cerebrospinal fluid (CSF) of patients with ocular syphilis.

**Methods:** An observational descriptive study was performed prospectively at Tygerberg Academic Hospital in Cape Town, South Africa from 1 February 2018 till 31 January 2021 which enrolled 23 participants. 14 Patients were male and 9 female, 15 patients were HIV positive, and all patients were newly diagnosed with ocular syphilis. Upon diagnosis of ocular syphilis, the HIV status of each patient was determined, and 3 samples (AH, serum and CSF) were collected to measure the levels of CXCL13, CXCL10 and CXCL8 in each. All patients were treated with 14 days of intravenous Penicillin G and topical corticosteroid drops for uveitis.

**Results:** The mean concentrations of all 3 biomarkers were higher in the AH and CSF than in the serum. The mean concentrations of the 3 measured biomarkers were markedly different when comparing both AH and CSF levels to serum levels. The level of CXCL13 measured in the AH correlated well with the concentrations found in the CSF of patients with neurosyphilis.

In patients with neurosyphilis, mean AH levels of CXCL13 and CXCL10 were markedly higher than in serum while mean CSF levels of CXCL10 were also markedly higher than in serum. Also, the AH/serum ratio of CXCL13 and CXCL10, as well as the CSF/serum ratio of CXCL10, was much higher in patients with neurosyphilis than without.

In patients with HIV infection, mean AH CXCL13 levels were much higher than in patients without HIV infection.

**Conclusion:** The levels of CXCL13, CXCL10 and CXCL8 in the AH of patients with neurosyphilis are similar to previously reported levels in the CSF of patients with neurosyphilis and can potentially be an adjunct in the diagnosis of ocular syphilis. Patients with ocular syphilis who tested negative for neurosyphilis with conventional CSF testing showed features of neurosyphilis when analysing the CSF chemokines.

FP-207

## Posthoc Analysis of PEACHTREE and AZALEA: Correlations between Visual Functions and Anatomy in Uveitic Macular Edema (UME)

R Wong<sup>1,2</sup>, E Wong<sup>3</sup>, T Ciulla<sup>4</sup>, T Bai<sup>5</sup>, Q Liu<sup>6</sup>.

<sup>1</sup>Department of Ophthalmology and Visual Sciences, The Chinese University of Hong Kong, <sup>2</sup>CMER Dennis Lam & Partners Eye Center, <sup>3</sup>Arctic Vision Hong Kong Limited, Hong Kong, Hong Kong, China, <sup>4</sup>Clearside Biomedical, Inc., Alpharetta, United States, <sup>5</sup>Arctic Vision Biotechnology Limited, Beijing, <sup>6</sup>Arctic Vision Biotechnology Limited, Shanghai, People's Republic of China

**Objective:** PEACHTREE [NCT02595398] and AZALEA [NCT03097315] were phase 3 studies evaluating suprachoroidal injection of a proprietary suspension of triamcinolone acetonide (CLS-TA/ARVN001) for treatment of macular edema associated with noninfectious uveitis. This posthoc analysis explored the anatomic biomarkers in relation with visual functions in UME.

**Methods:** 198 patients with uveitis enrolled in the two phase 3, 24-week clinical trials with CLS-TA/ARVN001 and 134 received treatments. The relationships between best corrected visual acuity (BCVA) and central subfield thickness (CST), Ellipsoid Zone (EZ) integrity and the presence and location of cystoid spaces and subretinal fluid (SRF) were assessed. Longitudinal modeling assessed the rates of change in BCVA and CST.

**Results:** At baseline, mean BCVA progressively worsened with EZ grade but no significant correlation was shown with cystoid spaces and SRF. At week 24, eyes with normal baseline EZ showed greater BCVA improvement compared with those eyes with EZ considered abnormal (11.9 letters vs 9.4 letters;  $p=0.006$ ). Eyes without center involving (CI) cystoid spaces or SRF at baselines showed less improvement versus those eyes with CI cystoid spaces (5.5 letters vs 13.7 letters;  $p=0.012$ ) and with SRF (9.5 letters vs 17.2 letters;  $p<0.001$ ). Improvement in cystoid spaces and/or SRF was indicative of greater BCVA improvement as compared to eyes with no improvement or worsening ( $p<0.001$  for both). Regardless of baseline BCVA, CST improved to approximately 300um at Week 24 among those patients received CLS-TA/ARVN001 treatment and the reduction was larger with worse baseline BCVA. Longitudinal modeling showed rapid response in CST improvement followed by BCVA.

**Conclusion:** In this analysis, subjects with normal EZ, CI cystoid spaces, or SRF at baseline experienced an improved CLS-TA/ARVN001 therapeutic response. Improvement in CST preceded visual response regardless of baseline BCVA, CST improved to approximately normal thickness.

FP-208

**Posthoc Analysis of PEACHTREE: Systemic Therapy and Suprachoroidally Injected CLS-TA/ARVN001 in Uveitic Macular Edema (UME)**

S Sheu<sup>1</sup>, E Wong<sup>2</sup>, T Ciulla<sup>3</sup>, T Bai<sup>4</sup>, Q Liu<sup>5</sup>.

<sup>1</sup>Department of Ophthalmology, Kaohsiung Medical University Chung-Ho Memorial Hospital, Kaohsiung, Taiwan, China, <sup>2</sup>Arctic Vision Hong Kong Limited, Hong Kong, Hong Kong, China, <sup>3</sup>Clearside Biomedical, Inc., Alpharetta, United States, <sup>4</sup>Arctic Vision Biotechnology Limited, Beijing, <sup>5</sup>Arctic Vision Biotechnology Limited, Shanghai, People's Republic of China

**Objective:** A combination of systemic and local therapies is often used for treating uveitic macular edema (UME). PEACHTREE [NCT02595398] is a phase 3 clinical study investigating the efficacy of suprachoroidal triamcinolone acetonide injectable suspension (CLS-TA/ARVN001) in noninfectious uveitis (NIU) patients with ME, or UME patients. In this study, patients on low dose corticosteroid or a stable dose of immunomodulatory therapy were allowed to participate. This posthoc analysis characterizes UME patients with or without systemic therapy (including corticosteroid and steroid-sparing therapies) at baseline and evaluates the efficacy and safety of CLS-TA/ARVN001.

**Methods:** In PEACHTREE, 160 eligible patients were randomized to receive CLS-TA/ARVN001 (active) or a sham procedure (control) in a 3:2 ratio. Patients received CLS-TA/ARVN001 at day 0 and week 12 and were followed through week 24. Efficacy and safety data of CLS-TA/ARVN001 were stratified by the use of systemic therapy(ies) at baseline.

**Results:** Overall, 46.9% of patients in the active arm gained  $\geq 15$  letters at week 24 versus 15.6% in the control. The mean change from baseline best corrected visual acuity (BCVA) was 13.8 letters, versus 3.0 in the control. The mean CST reduction was 152.6  $\mu\text{m}$  in the active arm vs. 17.9  $\mu\text{m}$  in the control.

For this post hoc analysis, at baseline, 28 active patients and 15 control patients were receiving systemic therapy. Patients on systemic therapy at baseline were diagnosed more with panuveitis and had a longer NIU diagnosis time. In patients not receiving systemic therapy, BCVA at week 24 improved by 15.6 letters in the active group compared with 4.9 letters in control ( $p < 0.001$ ). Central subfield thickness (CST) at week 24 reduced by 169.8  $\mu\text{m}$  in active arm compared with 10.3  $\mu\text{m}$  in control arm ( $p < 0.001$ ). In patients receiving systemic therapy at baseline, similar trends were observed. BCVA at week 24 improved by 9.4 letters in active patients and reduced by 3.2 letters in control patients ( $p = 0.019$ ). CST reduced by 108.3  $\mu\text{m}$  in active patients and 43.5  $\mu\text{m}$  in the control ( $p = 0.190$ ). With respect to safety, no meaningful imbalances between those receiving and not receiving baseline systemic therapy in the active control patients were noted.

**Conclusion:** Suprachoroidally injected CLS-TA/ARVN001 has improved the visual function and anatomy in UME patients regardless of whether patients receiving systemic therapy at baseline.

FP-209

## HISTOPATHOLOGY, IMMUNOHISTOCHEMISTRY AND MOLECULAR BIOLOGY IN EVISCERATED AND ENUCLEATED SPECIMEN OF END STAGE OCULAR INFLAMMATORY

J Biswas, G Patnaik<sup>1</sup>.

<sup>1</sup>Uvea, Sankara Nethralaya, Kolkata, India

**Objective:** To describe the histopathology (HPE), immunohistochemistry (IHC) and molecular biology correlations in various end stage ocular inflammatory pathologies.

**Methods:** Retrospective chart analysis of 18 eviscerated or enucleated globes secondary to intractable ocular inflammation due to multiple etiologies over a period of 10 years was conducted in a tertiary eye care centre. IHC and molecular biologic study was carried out from the paraffin sections of the eviscerated or enucleated specimen with various stains and molecular markers.

**Results:** In Vogt-Koyanagi-Harada syndrome (1 case) and Sympathetic Ophthalmia (9 cases), predominant T-cell infiltration of choroid was noted. CD3 as well as CD20 positivity was observed in VKH specimen. One case of VKH showed nongranulomatous inflammation with predominant CD 20 positivity, whereas sympathetic ophthalmia globes showed predominant CD 3 positivity. In 3 cases of tubercular (TB) panuveitis, mycobacterial tuberculosis (MTB) genome was detected by nested and real time polymerase chain reaction (PCR). Acid fast bacilli (AFB) was seen within retinal pigment epithelial cells in only 1 case of TB panuveitis. Two eyes of Eales' disease showed chronic non granulomatous inflammation around blood vessels of the retina. IHC showed CD 8 positive T cells. PCR showed mycobacterium tuberculosis (MTB) DNA from the paraffin sections. Nested PCR was positive in 2 cases of Eales' disease. In addition to this, real time PCR was positive in 1 of the Eales' disease. One eye with pars planitis showed acellular tissue with chronic granulomatous inflammation on HPE. IHC showed both CD 3 and CD 20 positivity. HPE in one case of acute retinal necrosis showed chronic non granulomatous inflammation in the retina with occluded retinal blood vessels and herpes virus inclusion bodies, with nested PCR positive for Varicella zoster virus and CD3 positivity on IHC. MTB DNA was found in one case of sclerouveitis

**Conclusion:** Knowledge regarding ocular inflammatory disorders is still evolving. HPE, IHC and molecular analysis of enucleated globes and eviscerated specimens can give an insight to etiopathogenesis of several uveitis, retinal vasculitis and sclerouveitis cases, which in turn can help develop efficient therapies.

FP-210

## Single-Cell Transcriptome Analysis Reveals Immune Cells Heterogeneity of Vogt-Koyanagi-Harada (VKH) Disease

S Ouyang.

**Objective:** Vogt-Koyanagi-Harada (VKH) disease is one of the most common forms of panuveitis in China, yet the pathogenesis remains largely unexplored. We mainly performed single cell transcriptome analysis to reveal immune cell heterogeneity and cell-cell interaction signals in immune microenvironment in the pathogenesis of acute VKH.

**Methods:** The single cell RNA sequencing (scRNA-seq) public datasets GSE148020 of VKH was downloaded from the Gene Expression Omnibus (GEO) database. We utilized single cell transcriptome analysis using the R package Seurat v4. Moreover, functional enrichment analyses, cell communication analysis and transcription factor regulation analysis were performed to explore immune cell heterogeneity.

**Results:** We constructed a single cell atlas comprising 47853 PBMC of VKH, and identified 12 cell types according to marker genes. Differential expression gene (DEGs) analysis showed that in VKH, major antigen-presenting cells CD14+ Monocytes and mDC cells function enriched in antigen-presenting, T, NK and NKT cells mainly involved in acute immune responses and immune activation functions, upregulated function of plasma cells and mast cell related to increased protein translation, synthesis and processing. Moreover, we uncovered VKH involves multiple immune cell-cell interactions increased and cell communication signals were dysfunction in VKH. In addition, we revealed that pro-immunity and inflammation transcription factors like USF2, IRF8, POU2F2 and JUN were activated while anti-immunity and inflammation transcription factors such as ETS2 and MXD4 were suppressed in the majority of cell types of VKH.

**Conclusion:** We firstly revealed cell heterogeneity and cell-cell interaction signals which were dysregulation in peripheral blood immune cell based on scRNA-seq approach. These findings deepened our understanding of the pathogenesis of VKH and provided potential target cell population or target genes for immunotherapy and anti-inflammation treatments.

**FP-211****Adalimumab is effective in treating pediatric noninfectious chronic anterior uveitis with peripheral retinal vascular leakage.**

H Song, M Zhang.

**Objective:** This study aimed to assess the efficacy of adalimumab in alleviating peripheral vascular leakage in pediatric chronic anterior uveitis patients, along with its ability to improve best-corrected visual acuity (BCVA) and inflammation parameters, its efficacy in reducing topical glucocorticosteroids (GCs) and systemic immunomodulatory therapy (IMT), and its safety profile.

**Methods:** A self-controlled study of pediatric chronic anterior uveitis patients who presented with peripheral retinal vascular leakage on ultra-widefield fluorescein fundus angiography and underwent adalimumab treatment was conducted. The primary outcome was the extent of retinal vascular leakage at the 3- and 6-month follow-up visits. Secondary outcomes included BCVA, inflammation parameters (fresh keratic precipitates, anterior chamber cell, and vitreous cell grades), frequency of topical glucocorticosteroid eye drops, IMT load, and adverse effects at the 3- and 6-month follow-up visits.

**Results:** Twenty patients with a mean age of  $9.30 \pm 3.26$  years old were included. The mean follow-up period was  $9.0 \pm 3.0$  months, with all patients followed up for at least 6 months. At the 3- and 6-month follow-ups, the peripheral vascular leakage score decreased significantly (2.87, 95% CI (2.14, 3.60),  $p < 0.001$  for 3 months, 2.75, 95% CI (1.76, 3.73),  $p < 0.001$  for 6 months). Alongside BCVA ( $p = 0.013$  for 3 months,  $p = 0.005$  for 6 months) was improved significantly, inflammatory parameters represented by fresh keratic precipitates, anterior chamber cell, and vitreous cell grades were improved significantly ( $p < 0.001$ ,  $p < 0.001$ , for all parameters) and topical GC usage was significantly reduced ( $p < 0.001$ ,  $p < 0.001$ ) at 3 and 6 months. There was also a statistically significant reduction in systemic IMT load at 6 months ( $p < 0.001$ ). Adverse events in the observation period included local redness around the injection site and mild upper respiratory symptoms.

**Conclusion:** Adalimumab could effectively alleviate peripheral vascular leakage in pediatric patients with chronic anterior uveitis. It could also be helpful in improving BCVA and inflammation parameters and decreasing topical glucocorticosteroid eye drops and systemic IMT. Adalimumab is generally safe for pediatric uveitis.

FP-212

**PGRN suppressed autoimmune uveitis and autoimmune neuroinflammation by inhibiting Th1/Th17 Cells and promoting Treg cells**C Wang, W Zhou, P Yang.

**Objective:** Progranulin (PGRN) is an important immune regulatory molecule in several immune-mediated diseases. To investigate the role of PGRN in uveitis and its counterpart, experimental autoimmune uveitis (EAU), as well as experimental autoimmune encephalomyelitis (EAE).

**Methods:** Serum PGRN levels in BD or VKH patients and normal controls were measured by ELISA. EAE and EAU were induced in B10RIII, WT and PGRN<sup>-/-</sup> mice to evaluate the effect of PGRN on the development of these two immune-mediated disease models. The local and systemic immunological alterations were detected by ELISA, flow cytometry and Real-time PCR. RNA-sequencing (RNA-seq) was performed to identify the hub genes and key signaling pathway.

**Results:** A significantly decreased PGRN expression was observed in active BD and active VKH patients. Recombinant PGRN significantly reduced EAU severity in association with a decreased frequency of Th17 and Th1 cells. PGRN<sup>-/-</sup> mice developed an exacerbated EAU and EAE in association with strikingly increased frequency of Th1 and Th17 cells and reduced frequency of regulatory T (Treg) cells. In vitro studies revealed that rPGRN could inhibit IRBP<sub>161-180</sub> specific Th1 and Th17 cell response, and promote Treg cell expansion. It promoted non-antigen-specific Treg cell polarization from naïve CD4<sup>+</sup>T cells in association with increased STAT5 phosphorylation. Using RAN sequencing we identified 5 shared hub genes including Tnf, Il6, Il1b, Cxcl2 and Ccl2 and the most significantly enriched MAPK and TNF signaling pathway in PGRN<sup>-/-</sup> EAU mice. The aggravated EAE activity in PGRN<sup>-/-</sup> mice was associated with a skew from M2 to M1 macrophages.

**Conclusion:** Our results collectively reveal an important protective role of PGRN in EAU and EAE. These studies suggest that PGRN could serve as an immunoregulatory target in the study of prevention and treatment for the Th1/Th17 mediated diseases.



**FP-213****To determine the role of Transcutaneous Retrobulbar Amphotericin B in COVID -19 related Rhino-Orbital-Cerebral mucormycosis-A case**R Kaur.

**Objective:** To determine the effect of Transcutaneous Retrobulbar amphotericin B (TRAMB) injection on orbital manifestations in cases of COVID related ROCM in a tertiary care centre.

**Methods:** Patients admitted in AIMSRS for treatment of ROCM and confirmed as mucormycosis on KOH mount of nasal scraping or histopathological examination of debrided tissue with good visual acuity at presentation were considered for TRAMB. All the patients will undergo thorough and complete ocular examination including visual acuity assessment on Snellen's chart, color vision assessment on Ishihara colour plates, intraocular pressure measurement with non contact tonometry, assessment of pupillary reactions, measurement of ptosis or proptosis, assessment of ocular movements and dilated fundus examination. Associated cranial nerves (5<sup>th</sup> and 7<sup>th</sup>) will also be assessed. Radiological examination will include contrast enhanced MRI brain and face with paranasal sinuses & orbit using 1.5 Tesla Siemens Avanto. Sections taken will include axial, coronal and saggital T1- weighted and T2- weighted images, FLAIR images, DWI/ADC images and fat suppressed post contrast T1 weighted images.

To assess the extent & severity of ROCM, following radiological features will be assessed:

- a) Signal characteristics and imaging appearances of orbit and ocular muscles.
- b) Extrasinus extension.

**Results:** Symptomatically ,clinically and radiologically,patients improved .

**Conclusion:** ROCM apperaed as storm in COVID -19 ,but TRAMB proved to be less invasive sight preserving method.

FP-214

**Cerebral Visual Impairment- An experience from Liberia, West Africa**N Pehere.

**Objective:** To describe epidemiology, causes, clinical features and challenges in management of children with cerebral visual impairment (CVI) from Liberia in West Africa.

**Methods:** This is a retrospective study of all children aged less than 16 years with diagnosis of CVI seen from July 2018 to December 2021 seen by a single pediatric ophthalmologist. Following details were included for each patient- age, gender, presenting symptom, birth history, systemic co-morbidities, ocular examination, vision assessment, interventions and follow-up.

**Results:** Total 48 patients were included in the study. Age ranged between 2 months to 16 years (mean 52.14 months), 29 (60.42%) were girls and 19 (39.58%) boys. Most (43, 89.58%) children were full term born and only 4 (8.33%) were preterm (birth details not available in 1). Most common presenting symptom was poor vision (41, 85.41%). Seven children (14.58%) presented with vision processing related difficulties. Common causes of CVI were perinatal asphyxia (29, 60.42%), cerebral malaria (7, 14.58%), neonatal seizures (4, 8.33%), meningitis (2, 4.17%), malnutrition (2, 4.17%), hydrocephalus (2, 4.17%) and eclampsia (1, 2.08%). Eleven children (2.08%) were suffering from epilepsy and was poorly controlled in all of them. Visual acuity could be assessed by Snellen's chart/Lea symbols in 7 children (14.58%), ranging from 20/20 to 20/500. There was no evidence of visual awareness in 23 (47.92%) children. Seven children showed only perception of light. Central, steady and maintained fixation pattern was seen in 3 children. Significant refractive error was found in 14 (29.17%) children (high myopia 3, high hypermetropia 1, low myopia 7, low hypermetropia 3). Significant squint was seen in 14 (29.17%) children (exotropia 9, esotropia 5). One child had developmental cataract for which surgery was performed. Amblyopia was seen in 5 (10.42%) children (3 ametropic, 1 due to cataract and 1 due to constant exotropia). Optic disc pallor was seen in 24 (50%) children and optic nerve hypoplasia in 2 (4.17%). Five (10.42%) children had follow-up of more than 6 months, improvement in vision was seen in 3 of them.

**Conclusion:** This study shows some new causes of CVI like cerebral malaria, eclampsia and malnutrition. Most of the children had very severe visual impairment and developmental delays. Lack of vision rehabilitation personnel, supportive therapies like physiotherapy, poor access to pediatric neurological services are some of the challenges in managing these children.

## FP-215

## Quality of life in patients with tunnel vision and influencing factors

D Xu, J Dai.

**Objective:** To investigate the clinical characteristics and quality of life (QoL) of patients with tunnel vision, and summarize influencing factors of QoL of patients with tunnel vision.

**Methods:** A total of 52 tunnel vision patients were enrolled in this study, including 26 males and 26 females, with an average age of  $57.92 \pm 13.61$  years. 35 volunteers with normal visual field (VF) and BCVA of not below 16/20 were included as the control group. We summarized subjects' gender, age, educational level, occupation, symptom duration, course of disease, presenting visual acuity (PVA), VF diameter, Low Vision Quality-of-Life Questionnaire (LVQoL) score and other relevant clinical data, and explored the characteristics and influencing factors of quality of life in patients with tunnel vision.

**Results:** The total score of the LVQOL questionnaire were  $62.63 \pm 21.34$  in tunnel vision group and  $112.42 \pm 11.90$  in the control group ( $P < .001$ ). The LVQoL score of tunnel vision patients was negatively correlated with PVA (logMAR) and positively correlated with VF diameter, according to multiple linear regression analysis ( $R^2 = 0.52$ ). Both the score of "distant vision, mobility, and lighting" and "activities of daily living" were associated with PVA and VF diameter ( $R^2 = 0.50$  and  $0.39$ ), the "adjustment" score was correlated with age ( $R^2 = 0.08$ ), and the "reading and fine work" was related to PVA ( $R^2 = 0.40$ ). LVQoL score was mild impairment in  $\geq 30^\circ$  group ( $83.90 \pm 16.96$ ) and  $20^\circ \sim 29^\circ$  group ( $63.49 \pm 19.29$ ), and the score was moderate to severe impairment in  $< 20^\circ$  group ( $56.94 \pm 20.61$ ). The "Distant vision, mobility, and lighting" subscale score was mild impairment in  $\geq 30^\circ$  group ( $39.28 \pm 6.94$ ), and was moderate to severe and impairment in  $20^\circ \sim 29^\circ$  group ( $29.59 \pm 9.42$ ) and  $< 20^\circ$  group ( $29.59 \pm 9.42$ ). The "Activities of daily living" subscale score was mild impairment in  $\geq 30^\circ$  group ( $14.73 \pm 4.53$ ) and  $20^\circ \sim 29^\circ$  group ( $10.39 \pm 4.78$ ), and was moderate to severe and impairment in  $< 20^\circ$  group ( $8.44 \pm 5.23$ ).

**Conclusion:** The main influencing factors of QoL of patients with tunnel vision were PVA and VF diameter. When the VF diameter was above  $20^\circ$ , QoL is impaired mildly; when the VF diameter declined below  $20^\circ$ , QoL is impaired more severely. Outdoor activities of those with a VF diameter of  $< 30^\circ$  was restricted severely, while indoor activities of patients with VF diameter of  $< 20^\circ$  was limited more severely.

FP-216

**Etiology and Prevalence of low vision among the patients availing Low vision Rehabilitation at Low Vision Clinic in Ahmedabad.**S Asal<sup>1</sup>, D Dala<sup>2</sup>.

<sup>1</sup>Optometry, Nagar School of Optometry, Ahmedabad, <sup>2</sup>Department of Paramedical and Health Sciences, Faculty of Medicine, Parul University, Vadodara, India

**Objective:** To determine the prevalence and causes of low vision and blindness attending low vision department in a tertiary hospital in Ahmedabad, Gujarat.

**Methods:** All the subjects visiting Low Vision Rehabilitation Centre during January to December 2018 were included. Oral Consent of Subjects were Obtained. Comprehensive Ocular examination was done followed by Low vision trial and management. Data was analysed with Microsoft Excel 2016.

**Results:** 106 low vision patients reported at Low vision clinic during January to December 2018 were included in the study. 62.26% were male and 37.73% were female. Mean age of the subjects were 44.04 years and standard deviation was 23.47 years. Among the subjects screened, the prevalence of Optic Atrophy were 1.80%, Retinitis Pigmentosa were 12.30%, Diabetic Retinopathy were 1.80%, Macular Degeneration were 10.40%, Refractive error were 1.80%, Keratoconus were 1.80%, Albinism with Nystagmus were 13.20%, Amblyopia were 0.90%, Retinal Detachment were 5.70%, Glaucoma were 1.80%, Corneal Opacity were 1.80%, Macular Hole were 1.80%, High Myopia were 5.70%, CNVM with Macular Scar were 3.80%, Rod Cone Dystrophy were 1.90%, Nystagmus were 2.90%, Multiple Choroiditis were 4.70%, Coloboma were 0.90%, Aniridia were 1.80%, Vitreous Degeneration were 3.80, Macular Dystrophy were 9.43%, Cataract were 2.83%.

**Conclusion:** Among the patients visiting at Low Vision Clinic, Albinism followed by Retinitis Pigmentosa and uncorrected refractive errors were found to have higher prevalence. Earlier diagnosis would help in successful management with Low vision devices.

FP-217

### Detection Of Preferred Retinal Locus: An Image Processing (MATLAB) Program Versus Best Retinal Area (BRA) Test

A Saleh<sup>1</sup>, S Sharafeldeen<sup>1</sup>, R Mahdy<sup>1</sup>, A Atalah<sup>2</sup>, K Solaiman<sup>1</sup>.

<sup>1</sup>Ophthalmology, Zagazig University Hospital, <sup>2</sup>Computer science, Zagazig Faculty of Engineering, Zagazig, Egypt

**Objective:** To evaluate the accuracy and validity of detection of the preferred retinal locus (PRL) using an image processing (MATLAB) program versus the best retinal area test (BRA) in patients with bilateral irreversible maculopathy causing central scotoma.

**Methods:** A prospective comparative study that included a consecutive series of patients having bilateral irreversible maculopathy causing central scotoma whose visual acuity in the best seeing eye ranging from 0.01 to 0.1. Colored fundus photos of the best seeing eyes if equal visual acuity the photos of the dominant eye were analyzed by MATLAB program to detect the red and green maximum pixel and blue minimum intensity for detection of PRL. The detected PRL was compared to that detected by BRA test.

**Results:** Thirty patients were included. There was statistically significant almost perfect agreement between PRL detected by MATLAB and that by BRA (Best Retinal Area test) ( $\kappa=0.902$ ,  $p<0.001$ ). There was statistically non-significant difference between both regarding the site of PRL.

**Conclusion:** Detection of PRL by a MATLAB program is as accurate as the BRA test. In addition MATLAB program could provide a more precise and quantitative estimate of the PRL than the clinical subjective BRA test.

**FP-218****Photobiomodulation therapy on Congenital Colour Vision Deficiencies patients: study protocol for a randomized clinical trial**L Jia.

**Objective:** To assess the effectiveness of photobiomodulation (PBM) therapy for congenital color vision deficiency (CCVD)

**Methods:** Subjects were aged between 7 and 60 years (average age of  $28.08 \pm 13.28$  years), of which 81 were male and 8 were female. Patients were randomly assigned to one of the three study groups: PBM therapy group (group A), placebo group (group B), and blank group (Group C) with a ratio of 2:1:1. In group A, Patients with protan defects underwent red light irradiation; patients with deutan defects underwent green light irradiation. In group B, all Patients underwent red and green light irradiation. In Group C: Patients received no treatment. Follow-up observation of 4 weeks was carried on. Standardized case report forms (CRF) were used at the initial, follow-up, and final visits. The follow-up period included 3 study visits: 1 week, 2weeks, and 4weeks after treatment.

**Results:** There were significant differences among the three groups ( $P < 0.01$ ). Recognition rates of Yu and Ishihara Pseudoisochromatic Plates of group A were increased significantly than group B and C on visits of 2 and 4 weeks ( $P < 0.01$ ), The error scores of group A were decreased significantly than group B and C on visits of 2 and 4 weeks ( $P < 0.01$ ).

**Conclusion:** PBM therapy can be used to treat congenital color vision deficiency and raise recognition rates of pseudoisochromatic Plates. This is the first direct observation of noninvasive physical therapy could alleviate symptoms of an inherited genetic disorder.

FP-219

**Effects of Knocking Out Melanopsin and Neuropsin on Oxygen-Induced Retinopathy**G Danziger<sup>1</sup>, A Radu<sup>1</sup>, S Modgil<sup>2</sup>, M Chrenek<sup>2</sup>, P Iuvone<sup>2</sup>, J Dixon<sup>2</sup>, M Shah<sup>1</sup>.<sup>1</sup>College of Arts and Sciences, <sup>2</sup>Department of Ophthalmology, Emory University, Atlanta, GA, United States

**Objective:** Retinopathy of Prematurity (ROP) is an ischemic vascular eye disease that affects premature infants exposed to high oxygen for respiratory support. The disease manifests as abnormal blood vessel growth within the light sensitive retina and is one of the leading causes of childhood blindness in severe cases. Oxygen-induced retinopathy (OIR) is a mouse model that mimics many aspects of the pathology of ROP. Mice exposed to 75% oxygen (hyperoxia) from postnatal days 7 to 12 (P7-P12) and returned to room air develop vaso-obliteration (VO) of the central retina and neovascular (NV) tufts in the peripheral retina. Melanopsin (OPN4) and neuropsin (OPN5) are light sensitive proteins of retinal ganglion cells that have been linked to early vascular development of the eye. This study examined the effects of knocking out melanopsin and neuropsin within the retina and determining the effects on retinal vaso-obliteration and neovascularization.

**Methods:** *Opn4*<sup>-/-</sup> and *Rx*<sup>cre</sup>;*Opn5*<sup>fl/fl</sup> mice were bred and exposed to either room air or 75% oxygen from P7 to P12. Mice exposed to high oxygen were returned to room air on P12 and all mice were euthanized on P17. Retinas were fixed and retinal flat mounts prepared and stained with isolectin-B4 to visualize blood vessels. Areas of VO and NV were quantified by Image J and a deep learning algorithm.

**Results:** Mice with a homozygous knockout of the melanopsin gene (*Opn4*<sup>-/-</sup>) showed more retinopathy than either wildtype or heterozygous melanopsin mice (*Opn4*<sup>+/-</sup>). Retinas of *Opn4*<sup>-/-</sup> mice had significantly greater ratios of the areas of VO and NV to total retinal area in comparison to heterozygous mice (*Opn4*<sup>+/-</sup>). Mice with neuropsin knocked out in the retina (*Rx*<sup>cre</sup>; *Opn5*<sup>fl/fl</sup>) did not show any statistically significant difference compared to control mice (*Opn5*<sup>fl/fl</sup>) in the amount of VO or NV.

**Conclusion:** This study demonstrates melanopsin influences the pathogenesis of OIR, and suggests that activation of melanopsin with blue light may provide a non-invasive treatment to reduce the development of ROP in infants.

FP-220

## Construction of CRYGS Gene Mutation in Human Lens Epithelial Cells and Screening of Related miRNAs

W Shang<sup>1</sup>, X Chen<sup>2</sup>.

<sup>1</sup>Department of Ophthalmology, West China School of Medicine and West China Hospital, Sichuan University, #37 Guoxue Alley, Wuhou District, Chengdu, Sichuan Province, <sup>2</sup>Department of Ophthalmology, Lanzhou Aier Eye Hospital, Lanzhou City, Gansu Province, People's Republic of China

**Objective:** The  $\gamma$  S-crystallin G57W mutation (i.e., CRYGS\_G57W) was constructed in human lens epithelial cells, and miRNAs associated with this mutation were screened by high-throughput sequencing.

**Methods:** The experiment was divided into NC group (negative control group), CRYGS group (wild-type CRYGS gene overexpression group) and CRYGS\_G57W group (mutant CRYGS\_G57W gene overexpression group). The wild-type CRYGS gene and the synthesized mutant CRYGS\_G57W gene were cloned into GV492 vector to obtain the recombinant plasmid, transfected into 293T cells for lentiviral packaging, prepared and concentrated to obtain lentiviral particles and infected with human lens epithelial cells B3 line (HLEB3 cells), and then the differentially expressed miRNAs in each group were screened by high-throughput sequencing, and their downstream target genes were predicted and enriched.

**Results:** The overexpression lentiviral plasmid of CRYGS group CRYGS\_G57W was successfully constructed. After high-throughput sequencing, a total of 84 significantly differentially expressed miRNAs were selected from the CRYGS\_G57W group. Of these, a total of 71 miRNAs were identified compared with the NC group; a total of 13 miRNAs were identified compared with the CRYGS group, including 10 up-regulated miRNAs (miR-148a-3p, miR-151a-3p, miR-224-5p, miR-2682-5p, miR-30a-3p, miR-30e-3p, miR-379-5p, miR-493-5p, miR-671-3p, miR-941) and 3 down-regulated miRNAs (miR-125b-5p, miR-17-5p, miR-181a-5p). After bioinformatics analysis, a total of 9932 target genes were predicted for 84 miRNAs. Compared with the NC group, the target genes were mainly associated with cellular processes, single biological processes, and protein binding, mainly involved in the PI3K-Akt signaling pathway, cancer pathway, and MAPK signaling pathway; compared with the CRYGS group, the target genes were enriched only in the cellular fraction, mainly playing biological roles intracellularly, mainly involved in the Ras signaling pathway, Rap1 signaling pathway, and Insulin signaling pathway.

**Conclusion:** Thirteen miRNAs, miR-148a-3p, miR-151a-3p, miR-224-5p, miR-2682-5p, miR-30a-3p, miR-30e-3p, miR-379-5p, miR-493-5p, miR-671-3p, miR-941, miR-125b-5p, miR-17-5p and miR-181a-5p, and three pathways, Ras signaling pathway, Rap1 signaling pathway and Insulin signaling pathway, may mediate the G57W mutation of  $\gamma$  S-crystallin, but which pathway is specifically involved in the pathogenesis of congenital cataract needs to be further explored.



FP-221

## Visual Improvement, Comorbid Depression and Quality of life in LHON Patients after Yoga intervention

M bansal<sup>1</sup>, R Saxena<sup>2</sup>, S Gautam<sup>3</sup>, R Mishra<sup>3</sup>, S Phuljhele<sup>2</sup>, R Dada<sup>4</sup>.

<sup>1</sup>Laboratory for Molecular Reproduction and Genetics, Department of Anatomy, All India Institute of Medical Sciences, <sup>2</sup>Dr. Rajendra Prasad Centre for Ophthalmic Sciences, <sup>3</sup>Laboratory for Molecular Reproduction and Genetics, Department of Anatomy, <sup>4</sup>Laboratory for Molecular Reproduction and Genetics,, All India Institute of Medical Sciences, Delhi, India

**Objective:** Leber hereditary optic neuropathy (LHON) is a rare, maternally-inherited optic neuropathy caused by point mutation in mitochondrial DNA. It leads to blindness in the first to third decade of life. It affects males up to 4 to 5 times higher as compared to females. Currently, there is no available modality in modern medicine for LHON treatment. It relies on antioxidants and drugs to improve mitochondrial functioning and oxidative phosphorylation. This pilot study was planned with an aim to study the impact of Yoga on vision, quality of life, and comorbid depression in LHON cases.

**Methods:** In this longitudinal study, we enrolled 9 patients, however only 5 LHON patients agreed for Yoga intervention. Genetic analysis to confirm presence of mutation was done. Cases underwent 8 weeks of Yoga based lifestyle intervention (YBLI) (6 days a week for 1hour) under a trained yoga therapist ,which includes asanas (physical postures), pranayama (regulated practice), and dhayna (meditation) with focus on awareness of breath. Genes involved in mitochondrial integrity (*AMPK, IGF1R, PRC-1, TFAM, SIRT-1, TIMP-1*, and *KLOTHO*), biogenesis, and changes in mitochondrial membrane potential (MMP), nicotinamide adenine dinucleotide (NAD+) levels were analyzed pre-post intervention. Severity of depression and quality of life were assessed pre-post intervention by Beck depression inventory (BDI-II Score) and WHOQOL-BREF scales respectively.

**Results:** Post YBLI, the patients reported, stabilization in visual acuity with no further deterioration. There was subjective improvement in basic visual symptoms reported. The patients also showed significant decline in reactive oxygen species (ROS) levels ( $p<0.05$ ) and NAD+ levels ( $p<0.05$ ). The transcripts responsible for mitochondrial integrity, biogenesis were found to be upregulated along with improvement in MMP. Patients of LHON showed significant improvement in WHOQOL score ( $p<0.05$ ) and decline in BDI-II score ( $p<0.05$ ).

**Conclusion:** YBLI reduces oxidative stress, increases the MMP, upregulates mitochondrial transcript levels, improves NAD+ levels and improves mitochondrial integrity and biogenesis. All four domains (physical, physiological, social relationships and environment) of Quality of life improved and reduction in the severity of depression in LHON patients after Yoga intervention. Hence, Yoga can be used as a powerful adjunct in management of LHON patients.

FP-222

**Characterization of patient-specific congenital cataract model from induced pluripotent stem cells**D Lyu<sup>1</sup>, Q Fu<sup>1</sup>, K Yao<sup>1</sup>.<sup>1</sup>Eye Center of Second Affiliated Hospital of Zhejiang University School of Medicine, Hangzhou, People's Republic of China

**Objective:** Congenital cataract (CC) is the leading cause of childhood blindness. It is necessary to establish new strategies of cataract prevention and management since surgery is the only established treatment and yet is associated with multiple complication. To date, appropriate disease models in vitro are lacking for the mechanism research and drug screening of CC. In our previous study, we acquired a CC model in vitro through generation of patient-specific lentoid bodies from induced pluripotent stem cells (iPSCs). The present study aims to demonstrate the characterization of this model during the entire differentiation process.

**Methods:** Lentoid bodies (LBs) with highly similarity to human lens were developed from iPSCs derived from two families affected by CC identified with c. 70C>A (p. P24T) of the  $\gamma$  D-crystallin gene (CRYGD) and c. 463C>T (p. Q155X) of the  $\beta$  B2- crystallin gene (CRYBB2), respectively. The morphology of LBs was observed via light microscope and compared with the patient's phenotype and disease course during the differentiation process. The structure of the LBs was analyzed via DiOC6 staining and TEM. qRT-PCR and immunofluorescence staining were used to examine the expressions of lens-specific markers during each stage of differentiation.

**Results:** The CRYGD-mutated LBs exhibited an earlier onset and more severe opacification compared to the CRYBB2-mutated LBs, which was similar to the patients' phenotypes and disease courses. Both of the mutated LBs showed normal differentiation during the placodal stage (before day 8). Opacification began to occur in the CRYGD-mutated LBs from lens progenitor cell differentiation stage (day 11-14), and further aggravated during late-stage differentiation stage (day 17-21). The CRYBB2-mutated LBs showed milder opacification with a later onset compared to the CRYGD-mutated LBs. Expression of the specific placodal, early lens, and lens fiber cell markers, were detected in the mutated LBs during the differentiation process. The structure of mutated LBs were as intact as that in the normal LBs, with the presence of lens capsule, epithelial cells and fiber cells, though slightly disordered structure was also observed.

**Conclusion:** The patient-specific LBs shared similarities with the patients' cataracts in terms of morphologies and disease courses. The present study provided a promising platform for the research on pathological mechanisms and clinical drug candidate screening for CC in the future.

FP-223

**Semaphorin 3A inhibits endoplasmic reticulum stress induced by high glucose in Müller cells**

M Li<sup>1</sup>, E Jin<sup>1</sup>, L Zhu<sup>1</sup>, J Qu<sup>1</sup>, M Zhao<sup>1</sup>.

<sup>1</sup>Ophthalmology, Peking University People's Hospital, Beijing, People's Republic of China

**Objective:** The study was aimed to explore the effect of Semaphorin3A (Sema3A)/ Neuropilin-1 (Nrp-1) pathway on Müller cells phenotypic changes and endoplasmic reticulum (ER) stress induced by high glucose (HG) in vitro.

**Methods:** The primary Müller cells of C57/BL6J mice were isolated and cultured in normal or HG medium respectively. The expression of endogenous Sema3A and Nrp-1 receptor was measured by western blot. Müller cells were incubated with exogenous recombinant Sema3A protein or transfected by lentiviral vectors expressing small hairpin RNA (shRNAs) to knock down the expression of endogenous Sema3A. The proliferation of Müller cells was detected by CCK8 experiment and Edu staining. The migratory ability was measured by transwell migration assay. The level of ER stress was analyzed through detection of GRP78/BiP, IRE1  $\alpha$  and splicing rate of XBP1 (XBP1s/XBP1u) by using immunofluorescence, western blot or quantitative polymerase chain reaction (qPCR).

**Results:** HG induced the upregulation of endogenous Sema3A and Nrp-1 receptor of Müller cells. The expression of GRP78/BiP and IRE1  $\alpha$  was up-regulated by HG, with an increased splicing rate of XBP1. Exogenous Sema3A inhibited HG-induced Müller cells proliferation, migration and activation of GRP78/BiP-IRE1  $\alpha$ -XBP1 axis. Knockdown of Sema3A promoted proliferation, migration and ER stress induced by high glucose in Müller cells.

**Conclusion:** Sema3A could inhibit increased proliferative and migratory activities induced by high glucose via attenuating ER stress in Müller cells.

FP-224

## Inhibition of MAPK/c-Jun-EGR1 pathway decreases photoreceptor cell death in rd1 mice for retinal degeneration

K Jiao, Y Dong<sup>1</sup>, W Xu<sup>1</sup>, F Paquet-Durand<sup>2</sup>, Z Hu<sup>1</sup>.

<sup>1</sup>Yunnan univeristy, Kunming, People's Republic of China, <sup>2</sup>Institute for Ophthalmic Research, Tübingen university, Tübingen, Germany

**Objective:** Retinitis pigmentosa (RP) is a group of inherited retinal dystrophies that typically results in photoreceptor cell death and vision loss in animal models and affected patients. Here, we explored the effect of Early growth response 1 (EGR1) expression on photoreceptor cell death in *PDE6b<sup>rd1</sup>* mice and its mechanism of action.

**Methods:** Single-cell RNA-seq (scRNA-seq) was used to identify differentially expressed genes (DEGs) in Rd1 and C3H mice. Chromatin immunoprecipitation (ChIP), dual-luciferase reporter gene, and western blotting assays were used to verify the relationship between EGR1 and PARP1. Immunofluorescence staining was used to assess PARP1 expression after silencing or overexpression of EGR1. Apoptosis of photoreceptor cells was assessed using a TUNEL assay following silencing or overexpression of EGR1 or administration of MAPK/c-Jun pathway inhibitors (Tanzisertib and PD98059).

**Results:** scRNA-seq analysis showed that EGR1 expression was significantly increased in Rd1 mice compared with that in C3H mice. ChIP assay demonstrated that EGR1 binds to the PARP1 promoter region. The dual-luciferase reporter gene and western blot results revealed that EGR1 upregulated PARP1 expression. Additionally, TUNEL assay showed that silencing EGR1 effectively reduced the apoptosis of photoreceptor cells. Furthermore, the addition of Tanzisertib and PD98059 reduced the expression of c-Jun and EGR1 and decreased the apoptosis of photoreceptor cells.

**Conclusion:** Inhibition of MAPK/c-Jun pathway reduces the expression of EGR1, which in turn reduces PARP1 expression and ultimately inhibits photoreceptor cell death. This study lays a theoretical foundation for subsequent studies on RP.

***E-POSTER  
PRESENTATIONS***

**PP-001****Real-time assessment of intraoperative vaulting in implantable collamer lens and correlation with postoperative vaulting**

X Tan<sup>1</sup>, J Liu<sup>1</sup>.

<sup>1</sup>cataract, Shanxi Eye Hospital, Taiyuan, People's Republic of China

**Objective:** To assess the intraoperative vaulting in patients undergoing implantable collamer lens (ICL; STAAR Surgical) implantation with microscope-integrated intraoperative optical coherence tomography (iOCT) and correlate it with the postoperative vaulting.

**Methods:** A total of 161 eyes of 86 patients undergoing myopic ICL implantation were evaluated (mean age of  $28.0 \pm 6.9$  years, 23 men and 63 women). Central ICL vault was measured both intraoperatively using RESCAN 700 intraoperative OCT (Carl Zeiss, Germany) before and after ophthalmic viscosurgical device (OVD) removal, and postoperatively using the high-speed anterior segment optical coherence tomography (RTVue100 OCT) at 1 day.

**Results:** Intraoperative mean vaulting with OVD was  $223.83 \pm 130.23 \mu\text{m}$  (range:  $0 \sim 763.97 \mu\text{m}$ ), and without OVD was  $491.66 \pm 241.87 \mu\text{m}$  (range  $0 \sim 1398.97 \mu\text{m}$ ). Postoperative mean vaulting was  $615.75 \pm 217.26 \mu\text{m}$  (range  $102 \sim 1290 \mu\text{m}$ ) at 1 day. Correlation analysis shows significant agreement between the two intraoperative times (Spearman Rho = 0.303,  $P < 0.001$ ) and between vault values obtained postoperatively and at the two intraoperative times, with OVD (Spearman Rho = 0.455,  $P < .001$ ) and after OVD removal (Spearman Rho = 0.460,  $P < .001$ ). In 16.0% of cases, intraoperative vault after OVD removal could be predicted by intraoperative vault with OVD values. Postoperative vault values 1 day after the surgery could be predicted from intraoperative vault with OVD values in 22.4% of cases, and so were 27.6% of intraoperative vault after OVD removal values.

**Conclusion:** Real-time assessment of intraoperative determination of ICL vault using iOCT correlated highly with postoperative OCT vaulting and can be considered a reliable tool to predict the final ICL vault.

**PP-002****A novel nomogram based on the total corneal astigmatism for paired anterior penetrating femtosecond laser arcuate keratotomy**

Z Zhang.

**Objective:** To develop a nomogram for paired anterior penetrating femtosecond laser arcuate keratotomy (FLAK) based on the total corneal refractive power (TCRP) astigmatism ( $CA_{tot}$ ) during femtosecond laser-assisted cataract surgery (FLACS)

**Methods:** Paired anterior penetrating FLAKs were created at an 8.0 mm optical zone with a depth of 90% by LenSx laser.  $CA_{tot}$  measurements were obtained preoperatively and after 1 year with Scheimpflug tomography (Pentacam HR; Oculus, Wetzlar, Germany) for 3- and 5-mm diameter zones respectively. Vector analysis using the Alpins method to describe the surgically induced astigmatism (SIA) and correction index (CI). Holladay-Cravy-Koch formula was used to calculate the corneal net changes in 3-mm diameter zone caused by the FLAKs. Multiple regression analysis with generalized estimating equations was used to develop the nomogram.

**Results:** The study included 64 eyes of 64 patients. The mean preoperative  $CA_{tot}$  (3-mm:  $1.50 \pm 0.59$  D; 5-mm:  $1.45 \pm 0.52$  D) were significantly reduced to  $0.73 \pm 0.46$  D and  $0.76 \pm 0.49$  D respectively at 1-year follow-up period (both  $P < 0.05$ ). The 3-mm and 5-mm SIA was  $1.16 \pm 0.61$  D and  $1.03 \pm 0.56$  D respectively ( $P < 0.01$ ). The 3-mm and 5-mm CI was 0.72 and 0.64 ( $P > 0.05$ ). The mean corneal net changes were -0.97 D in 3-mm zone, -0.85 D in 5-mm zone respectively. A nomogram is established based on age, length, and location of the FLAKs.

**Conclusion:** Paired anterior penetrating FLAKs showed efficient and stable corneal astigmatism reduction 1 year postoperatively. The nomogram is proposed according to the  $CA_{tot}$ , which considers the effect of posterior astigmatism of the cornea, may further improve correction accuracy.

PP-004

### Phacoemulsification Combined with Supra-Capsular and Scleral-Fixated Intraocular Lens Implantation in Microspherophakia

Z Chen, W Jia<sup>1</sup>, Y Jiang<sup>1</sup>.

<sup>1</sup>Eye Institute and Department of Ophthalmology, Eye & ENT Hospital, Fudan University, Shanghai, People's Republic of China

**Objective:** To evaluate the surgical outcomes of a novel procedure, supra-capsular and scleral-fixated intraocular lens implantation (SCSF-IOL), in microspherophakia (MSP).

**Methods:** This study included MSP eyes managed with phacoemulsification combined with SCSF-IOL and made the comparison with those treated by transscleral-fixated modified capsular tension ring and in-the-bag intraocular lens implantation (MCTR-IOL).

**Results:** A total of 20 MSP patients underwent SCSF-IOL, and 17 patients received MCTR-IOL. The postoperative best corrected visual acuity was significantly improved in both groups ( $P < 0.001$ ), but no difference was found between the groups ( $P = 0.326$ ). The IOL tilt was also comparable ( $P = 0.216$ ). Prophylactic Nd:YAG laser posterior capsulotomy was performed 1 week to 1 month after the SCSF-IOL procedure. In the SCSF-IOL group, two eyes (10.00%) needed repeated laser treatment and one eye (5.00%) had a decentered capsule opening. Posterior capsule opacification was the most common complication (6, 35.29%) in the MCTR group. No IOL dislocation, secondary glaucoma, or retinal detachment was observed during follow-up.

**Conclusion:** SCSF-IOL is a viable option for managing MSP and is comparable with the MCTR-IOL. Nd:YAG laser posterior capsulotomy was necessary to prevent residual capsule complications after the SCSF-IOL procedure.



PP-005

**Treatment of subluxation of closed loop intraocular lens by U-shaped suture**L Wang.

**Objective:** To investigate the application value of U-shaped suture in the treatment of subluxation of closed loop intraocular lens.

**Methods:** From June 2020 to March 2021, 21 patients (21 eyes) with subluxation of intraocular lens after implantation of closed loop intraocular lens were selected. The posterior capsule was intact. The intraocular lens was displaced downward in 11 patients (52.38%), downward in 5 patients (23.81%) and downward in 6 patients (28.57%). After passing through the lower part of the closed loop through the scleral tunnel incision, the lens suture was immediately turned up, butted with the contralateral relay needle, and then penetrated out of the contralateral clear cornea (2 mm from the limbus corneae), about 5 mm of the suture was pulled out, and then the tail of the straight needle of the lens suture was repenetrated into the original corneal incision, and the relay needle was butted on the contralateral side again to pull out the suture, The best corrected visual acuity (BCVA), intraocular lens reduction rate and patient satisfaction were observed at 1d, 7d and 1mo after operation.

**Results:** There was significant difference in BCVA at 1d, 7d and 1mo after operation ( $P < 0.05$ ); The reduction rate of intraocular lens was 95.24% at 1d, 7d and 1mo after operation. At 1mo after operation, 1 case (4.76%) of intraocular lens fell into vitreous cavity due to suture loosening, which needed further treatment.

**Conclusion:** In the treatment of subluxation of closed loop intraocular lens, the U-shaped corneal suture can shorten the operation time, reduce the occurrence of complications and improve the vision of patients, which is worthy of clinical application.

PP-006

**Novel Compound Heterozygous Variants in LTBP2 Associated with Relative Anterior Microphthalmia**P Lin, J Xu<sup>1</sup>, T Zheng<sup>1</sup>.<sup>1</sup>department of ophthalmology, Eye and ENT Hospital of Fudan University, Shanghai, People's Republic of China

**Objective:** Relative anterior microphthalmia (RAM) is a rare congenital defect associated with severe vision impairment and is primarily caused by genetic alterations. The purpose of this study was to identify the causative genetic variants in two Chinese families with relative anterior microphthalmia with a recessive inheritance pattern.

**Methods:** DNA samples were obtained from two probands and their family members. Targeted next-generation sequencing (NGS) was used to screen 256 genes to identify the possible disease-causing variants in the two patients. Sanger sequencing was then used to validate the results in both families.

**Results:** The targeted NGS targeted panel identified potentially causative novel mutations in the latent transforming growth factor beta binding protein 2 (*LTBP2*) gene in the two RAM families: a missense mutation (c.2771C>T;p.Ala924Val) and an intronic mutation (c.4582+9A>G) in family A, and a different missense mutation (c.5239C>A;p.Arg1747Ser) and a synonymous mutation (c.951G>A;p.Pro317Pro) in family B. These four novel variants all cosegregated with the disease phenotype.

**Conclusion:** To the best of our knowledge, this is the first study to report novel *LTBP2* gene mutations related to RAM. The results will not only enhance our current understanding of the genetic basis of RAM but also may contribute to a better understanding of the diverse phenotypic consequences caused by mutations in the *LTBP2* gene.

**PP-008****Accuracy improvement of IOL power prediction for highly myopic eyes with an XGBoost machine learning-based calculator**

X Zhu<sup>1</sup>, L Wei<sup>1</sup>, W He<sup>1</sup>, Y Lu<sup>1</sup>.

<sup>1</sup>Eye & ENT Hospital of Fudan University, Shanghai, People's Republic of China

**Objective:** To develop a machine learning-based calculator to improve the accuracy of IOL power predictions for highly myopic eyes.

**Methods:** Data of 1450 highly myopic eyes from 1450 patients who had cataract surgeries at our hospital were used as internal dataset (train and validate). Another 114 highly myopic eyes from other hospitals were used as external test dataset. A new calculator was developed using XGBoost regression model based on features including demographics, biometrics, IOL powers, A constants, and the predicted refractions by Barrett Universal II (BUII) formula. The accuracies were compared between our calculator and BUII formula, and axial length (AL) subgroup analysis (26.0–28.0, 28.0–30.0, or  $\geq 30.0$ mm) was further conducted.

**Results:** The median absolute errors (MedAEs) and median squared errors (MedSEs) were lower with the XGBoost calculator (internal: 0.25 D and 0.06 D<sup>2</sup>; external: 0.29 D and 0.09 D<sup>2</sup>) versus the BUII formula (all  $P \leq 0.001$ ). The mean absolute errors and were  $0.33 \pm 0.28$  versus  $0.45 \pm 0.31$  (internal), and  $0.35 \pm 0.24$  versus  $0.43 \pm 0.29$  D (external). The mean squared errors were  $0.19 \pm 0.32$  versus  $0.30 \pm 0.36$  (internal), and  $0.18 \pm 0.21$  versus  $0.27 \pm 0.29$  D<sup>2</sup> (external). The percentages of eyes within  $\pm 0.25$  D of the prediction errors were significantly greater with the XGBoost calculator (internal: 49.66% versus 29.66%; external: 78.28% versus 60.34%; both  $P < 0.05$ ). The same trend was in MedAEs and MedSEs in all subgroups (internal) and in AL  $\geq 30.0$ mm subgroup (external) (all  $P < 0.001$ ).

**Conclusion:** The new XGBoost calculator showed promising accuracy for highly or extremely myopic eyes.

PP-009

**Racemization in Cataractous Lens from Diabetic and Aging Individuals: Analysis of Asp 58 Residue in  $\alpha$ A-crystallin**K Zhang<sup>1234</sup>, X Zhu<sup>12345</sup>, W He<sup>1234</sup>, J Qi<sup>1234</sup>, Y Lu<sup>1234</sup>.

<sup>1</sup>Department of Ophthalmology and Eye Institute, Eye & ENT Hospital of Fudan University, <sup>2</sup>Key Laboratory of Myopia (Fudan University), National Health Commission, <sup>3</sup>Key Laboratory of Myopia, Chinese Academy of Medical Science, <sup>4</sup>Shanghai Key Laboratory of Visual Impairment and Restoration, <sup>5</sup>State Key Laboratory of Medical Neurobiology, Fudan University, Shanghai, People's Republic of China

**Objective:** Cataract is the leading cause of visual impairment globally. Racemization of lens proteins may contribute to cataract formation in aging individuals. As a special type of age-related cataract (ARC), diabetic cataract (DC) is characterized by the early onset of cortical opacification and finally developed into a mixed type of cortical and nuclear opacification. By analysis of Asp 58 residue in  $\alpha$ A-crystallin, we aimed to investigate the racemization in cataractous lens from diabetic and aging individuals, and its possible influence on the differential phenotypes of lens opacification.

**Methods:** We compared racemization of Asp 58 residue, a hotspot position in  $\alpha$ A-crystallin, from the cortex and nucleus of diabetic and age-matched senile cataractous lenses, by identifying L-Asp/L-isoAsp/D-Asp/D-isoAsp by mass spectrometry. Changes of protein solubility in diabetic cataractous lenses were also analyzed.

**Results:** Compared to nondiabetic cataractous lenses, DC lenses showed a significantly increased cortex/nucleus ratio of D-Asp 58, which originated primarily from an increased percentage of D-Asp 58 in the lens cortex of DC. Moreover, patients diagnosed with diabetes for over 10 years showed a lower cortex/nucleus ratio of D-isoAsp 58 in the lens compared with those who had a shorter duration of diabetes, which originated mainly from an increased percentage of D-isoAsp 58 in the lens nucleus of DC with increasing time of hyperglycemia. Further analysis confirmed decreased protein solubility in diabetic cataractous lenses.

**Conclusion:** The different racemization pattern in DC may be distinguished from ARC and influence its phenotype over the protracted duration of diabetes.

**PP-010**

**To study visual outcome, endothelial cell loss and complications after retropupillary Iris claw lens implantation**

S Singh.

**Objective:** To study visual outcome, endothelial cell loss and complications after retropupillary Iris claw lens implantation in patients with deficient posterior capsule.

**Methods:** This prospective study included 33 patients who underwent retropupillary iris claw lens implantation in patients with posterior deficient capsule.

**Results:** The mean Preop LogMAR was 0.5338 while it improved to 0.3149, 3 month postoperatively which is equivalent to 6/12. The mean endothelial cell loss was 14.95 %. There was no significant increase in IOP. Macular oedema was observed in 18 (54.54%) cases which decreased in follow up, pigment dispersion was seen in 12 (36.36%) cases. No disenclavation was seen in any case.

**Conclusion:** Retropupillary Iris Claw lens implantation is less time consuming, cost effective, predictable and safe procedure capable of delivering good visual outcomes and associated with fewer complications.

## PP-014

**The Prediction Error of Five IOL Calculation Formulas in Chinese Eyes With Normal Axial Length And Implanted With PanOptix**

F Zhang<sup>1</sup>, L Wu<sup>1</sup>.

<sup>1</sup>Aier Eye Hospital, Chengdu, China, Chengdu, China

**Objective:** To evaluate the prediction error of five IOL calculation formulas (SRK/T, Holladay 2, Hoffer Q, Haigis and Barrett Universal II) in Chinese eyes with normal axial length and implanted with PanOptix.

**Methods:** Retrospective case study. Patients who underwent cataract phacoemulsification combined with Panoptix implantation in Chengdu Aier Eye Hospital from July 2020 to January 2022 were selected. Biometric values were obtained by IOL-Master 700 before surgery, and the eye axis was 22mm to 26mm. The postoperative diopter was predicted by five IOL calculation formulas built in the device. Through refraction 3 months after surgery, the differences in postoperative refractive error and mean absolute error MAE of each formula were compared, and the postoperative refractive errors were compared between  $\pm 0.25D$ ,  $\pm 0.50D$  and  $\pm 1.0D$ .

**Results:** The distance visual acuity and corrected visual acuity were improved after treatment ( $P < 0.05$ ). There was no statistical difference in the percentage of eyes with the refractive prediction error (RPE) within  $\pm 0.25D$  for five formulas ( $P > 0.05$ ), however, within  $\pm 0.50 D$  and  $\pm 1.00 D$ , compared with other formulas, SRK/T had lower percentage of eyes with the RPE ( $P < 0.05$ ). Finally, among these formulas, the mean absolute error (MAE) of SRK/T formula was the smallest and that of Hoffer Q formula was the largest, compared with other formulas, SRK/T had lower MAE ( $P < 0.05$ ).

**Conclusion:** The SRK/T formula has the lowest PanOptix refractive prediction error and mean absolute error for Chinese cataract patients with normal axial length, and can more accurately predict postoperative refractive outcomes.

**PP-016****Precision Pulse Capsulotomy To Perform Routinely Capsulorhexis With Automated Method With Easier Control And Superior Outcomes**M Piovella.

**Objective:** Radial tears in the manual capsulorhexis increase the rate of surgical complications. Zepto precision pulse capsulotomy (PPC) technology (Centricity Vision - Fremont, California) is compared with manual continuous curvilinear capsulorhexis (CCC) outcomes by the reproducibility, uniformity, circularity, diameter size and complications rate. Also with FLACS capsulotomy.

**Methods:** A novel mechanical capsulotomy method and technology called PPC and trade named Zepto was adopted on 526 consecutive eyes with cataract. Incision size 2,4 mm. Suction time 10 seconds. Minimum Anterior chamber depth 2mm. Callisto system adoption to better center the cup

**Results:** Preoperatively the ACD was  $2.77 \pm 0.43$ . ECC preop was  $2378 \pm 443$  and 6 months postop  $2268,20 \pm 241$  with a 4.61 % lost cells. We experienced 30 anterior radial tears (5.7%) during the learning curve and later in difficult cases.

**Conclusion:** The Zepto PPC technology creates a precise circular anterior capsulotomy. This technique allows cataract surgeons to reduce the rate of capsulorhexis and cataract surgery complications

PP-017

### Safety, efficacy, and predictability of the LENSAR enabled arcuate incisions for correction of astigmatism during cataract surgery

S Salguti, S Ganesh<sup>1</sup>, S Brar<sup>1</sup>.

<sup>1</sup>PhacoRefractive Department, Ophthalmology., Nethradhama Superspeciality Eye Hospital, Bangalore, India, bangalore, India

**Objective:** To evaluate the safety, efficacy, and predictability of the arcuate incisions created by LENSAR FS Laser for management of preoperative astigmatism at the time of cataract surgery

**Methods:** This prospective study included 38 eyes from 38 patients who underwent femtolasers assisted cataract surgery with the LENSAR Femtolasers System (LENSAR), and received anterior penetrating arcuate incisions to treat corneal astigmatism up to 2.00 D. The LENSAR Femtolasers System imports the Pentacam topography (obtained in the supine position) and calculates the required axis and arc length of the arcuate incision using an in-built nomogram. Furthermore, image acquisition is coupled with the LENSAR FS laser to allow for iris registration, on which astigmatism correction is based during cataract surgery. All incisions were opened using a Sinsky's hook at the end of the procedure. Follow-ups were conducted at 1 week, 1 month and 3 months post-op

**Results:** The mean age of the study participants was  $65.86 \pm 6.83$  years and the mean pre-operative keratometric astigmatism (Pentacam) was  $1.03 \pm 0.29$  D (0.7 to 1.7 D). Average degree of intra-operative cyclorotation noted was  $5 \pm 1.8$  degrees. At 3 months post-op, corneal astigmatism reduced significantly to a mean value of  $0.71 \pm 0.35$  D, p-value =  $<0.001$ . EIGHTY FOUR % eyes were within  $\pm 0.5$  D of refractive astigmatism. The incisions were well tolerated by all patients and no eye developed complications such as persistent epithelial defects or infection in the post-op period.

**Conclusion:** The arcuate incisions achieved by LENSAR FS Laser system were safe, effective and demonstrated good predictability for astigmatism correction using femtolasers technology.



**PP-018****Comparison of the accuracy of five intraocular lens power calculation formulas for eyes after myopic LASIK**

H D Bhavsar, S Ganesh<sup>1</sup>, S Brar<sup>1</sup>.

<sup>1</sup>Department of phaco- refractive surgery, Nethradhama superspeciality eye hospital, Bangalore, India, Bangalore, India

**Objective:** To assess the accuracy of five IOL power calculation formulas for eyes with cataract with history of prior myopic LASIK

**Methods:** This retrospective case series included patients with history of prior myopic LASIK undergoing cataract extraction. IOL power was calculated using Barrett True-K , Barrett True-K TK, Holladay EKR, Haigis-L and Ray tracing formula. Prediction error, Mean absolute error (MAE) and median absolute error (MedAE) of predicted refraction were compared for each formula.

**Results:** 40 eyes of 24 patients were analysed. Mean prediction error (PE) for Barrett True-K TK, Barrett True-K, Haigis L, Holladay EKR and Ray tracing formula were  $-0.34 \pm 0.54$  D,  $-0.34 \pm 0.47$  D,  $-0.33 \pm 0.53$  D,  $-0.28 \pm 0.51$  D and  $-0.32 \pm 0.54$  D respectively, all of which were significantly different from zero ( $p < 0.001$ ). However, there was no significant difference observed between MAE of all the formulas ( $0.42 \pm 0.40$  D for the Barrett True-K,  $0.43 \pm 0.46$  D for the Barrett True-K TK ,  $0.39 \pm 0.43$  D for Holladay EKR,  $0.45 \pm 0.43$  D for the Haigis-L and  $0.43 \pm 0.54$  D for Ray tracing),  $p > 0.05$ . Similarly, the MedAE of all the formulas was also not found to be statistically significant,  $p > 0.05$ . Percentage of eyes within  $\pm 0.50$  D was 59.4%, 58.9%, 56.3%, 57.7% and 56.3% for Barrett True-K TK, Barrett True-K, Haigis L, Holladay EKR and Ray tracing formula respectively.

**Conclusion:** All the five modern post refractive surgery IOL calculation formulas were effective and resulted in comparable accuracy.

**PP-019****Real World Visual Performance and Patient Satisfaction Outcomes of a Novel Wavefront Shaping Presbyopia-Correcting IOL**

R Lapid-Gortzak, C Perez-Vives<sup>1</sup>.

<sup>1</sup>Alcon Labs, Fort Worth, United States

**Objective:** To report real world visual outcomes and patient satisfaction in a large cohort implanted bilaterally with Acrysof IQ Vivity and/or Acrysof IQ Vivity Toric presbyopia correcting IOL models DFT015, DFT215, DFT315, DFT415, and DFT515 through routine clinical practice.

**Methods:** Multicenter, ambispective registry study conducted in Europe, the UK, Australia and New Zealand. After a minimum of 3 months post-op follow up after second eye surgery per local clinical practice standards, subjects implanted with the AcrySof IQ Vivity and/or AcrySof IQ Vivity Toric IOL in both eyes underwent visual performance assessments of visual acuity at distance, intermediate (66 cm) and near (40 cm). Subject satisfaction and spectacle independence recorded via validated questionnaires and patient reports of visual disturbances are reported. This cohort includes 4% post corneal refractive surgery subjects and 25% with ocular comorbidities.

**Results:** To date, 757 subjects aged 66.9 (9.52) years were enrolled. Binocular mean UCVA was  $0.014 \pm 0.102$  logMAR (20/20 Snellen), mean UCVA was  $0.085 \pm 0.122$  logMAR (~ 20/25 Snellen) and mean UCNVA was  $0.247 \pm 0.158$  logMAR (~20/32 Snellen). 91.4% of patients reported to be satisfied with their sight and 75.3% report no difficulty seeing the prices of goods when shopping. The % of subjects reporting never/rarely needing to wear eyeglasses to see up close was 59.4%, or at arm's length 88.7% or far away 92.9%. Subjects reporting "None" for halos was 91.8%, glare 92.1% or starbursts 94.9%.

**Conclusion:** In this large cohort real world study of patients bilaterally implanted with AcrySof IQ Vivity and/or AcrySof IQ Vivity Toric presbyopia correcting IOLs, we have observed very good distance (20/20), intermediate (~20/25), and functional near visual acuity (~ 20/32) outcomes. Very high percentages of spectacle independence from distance to intermediate, great subjects' visual satisfaction with patients reporting none or low difficulty to perform daily activities as well as very low visual disturbances.

## PP-020

**Reduced graphene oxide nano-coating modified on intraocular lens for photothermal therapy of posterior capsular opacification**

Y Yu<sup>1</sup>, C Zhang<sup>1</sup>.

<sup>1</sup>Eye Center, the Second Affiliated Hospital, School of Medicine, Zhejiang University, Hangzhou, People's Republic of China

**Objective:** The most common complication of cataract surgery called posterior capsular opacification (PCO) leads to a secondary visual impairment. Near-infrared (NIR) light-triggered photothermal therapy is an attractive noninvasive treatment for PCO prophylaxis. Herein, we fabricate a new type of IOL with photothermal conversion property through surface modification technique for photothermal therapy of PCO.

**Methods:** Polymethyl methacrylate (PMMA) sheets were used as IOL model materials, and reduced graphene oxide (rGO)/polyethyleneimide (PEI) nano-coatings were prepared on the surface of PMMA by electrostatic layer-by-layer (LBL) self-assembly method. The physical and chemical properties and photothermal conversion properties of rGO@PMMA were characterized by infrared spectra, Raman spectra, electrokinetic analyzer, spectroscopic ellipsometry, scanning electron microscopy, atomic force microscopy, contact angle goniometer measuring system, digital thermometer and so on. The cytotoxicity and cell-killing properties of rGO@PMMA were characterized by cell counting kit-8, Live/dead staining assay and Annexin V-FITC apoptosis detection kit. The rGO@IOL was fabricated in the same way for the *in vivo* experiments. In the rabbit PCO models, the efficiency of PCO prophylaxis was evaluated by the slit-lamp photography and histopathological assays.

**Results:** The change of surface characteristics and photothermal conversion ability demonstrated the successful rGO/PEI nano-coating fabrication by LBL self-assembly method. And the photothermal performance of rGO@PMMA was affected by the number of rGO/PEI bilayers. rGO@PMMA caused no cytotoxicity but induced the lens epithelium cells (LECs) apoptosis through NIR radiation (808 nm, 2.5 W/cm<sup>2</sup>). Furthermore, the rGO/PEI coating was fabricated on the surface of the peripheral ring zone (1 mm width) of the commercially hydrophobic acrylic IOL without influencing the central optical quality. The new photothermal IOL namely rGO@IOL was implanted into the rabbit model for five-week further investigation. *In vivo* studies demonstrated the group of rGO@IOL with NIR treatment exhibited superiority in inhibiting PCO over other groups, and the difference was statistically significant.

**Conclusion:** The rGO@IOL, with good biocompatibility, stable and great photothermal conversion property, has a promising prospect for a clinical application in PCO prevention.

## PP-021

### Factors associated with the time between cataract surgery and Nd:YAG treatment in the biggest eye center of northwest china

H Yan, Y Zhang<sup>1</sup>, J Liang<sup>1</sup>, X Xie<sup>1</sup>.

<sup>1</sup>Shaanxi Eye Hospital, Xi'an People's Hospital, Xi'an, People's Republic of China

**Objective:** To retrospectively analyze the clinical data of large samples of YAG laser posterior capsulotomy, and to explore the influencing factors of time from cataract surgery to YAG laser capsulotomy (TFCSTLC), so as to provide reference for the occurrence and treatment of real-world posterior capsular opacification (PCO).

**Methods:** A total 1093 patients (1093 eyes) with PCO who underwent YAG laser posterior capsulotomy from 2014 to 2019 in largest eye center of northwest China were analyzed retrospectively. The gender, age, systemic complications, material, and design of intraocular lens (IOL) and TFCSTLC were recorded. The t test and Wilcoxon rank sum test were used to analyze and compare the average TFCSTLC values under different factors, and the relationship between each factor and TFCSTLC was analyzed using multiple linear regression.

**Results:** The average TFCSTLC was 19.2 (range, 7.9-31.2) months. Comparative analysis of the TFCSTLC among different study variables were conducted. There were significant statistical differences in TFCSTLC among the implanted single focus versus multifocal IOLs ( $P < .001$ ), diabetic versus non-diabetic patients ( $P < .001$ ), high myopia versus non-high myopia patients ( $P = .003$ ). No statistically significant differences between the hydrophilic IOL and hydrophobic IOL ( $P = 0.27$ ), 1-piece and 3-piece IOL implanted ( $P = 0.87$ ). Multiple linear regression analysis demonstrated that TFCSTLC was negatively correlated in patients with diabetes versus no history of diabetes (coefficient,  $-5.36$ ; 95% confidence interval [CI],  $-8.30$  to  $-2.41$ ;  $P < .001$ ), and multifocal IOL versus a single focus IOL implanted (coefficient,  $-5.56$ ; 95% CI,  $-9.01$  to  $-2.11$ ;  $P = .002$ ).

**Conclusion:** This study is the first to report the analysis of the influencing factors of TFCSTLC in a large sample of Chinese Ophthalmic single center based on the data of patients with YAG laser posterior capsulotomy. The YAG laser posterior capsulotomy time was sooner in patients with a history of diabetes mellitus and multifocal IOL implanted.

## PP-022

**Risk factors associated with intraocular lens decentration after cataract surgery**

J Xu<sup>1</sup>, P Lin<sup>1</sup>, S Zhang<sup>1</sup>, Y Lu<sup>1</sup>, T Zheng<sup>1</sup>.

<sup>1</sup>Eye and ENT Hospital of Fudan University, Shanghai, People's Republic of China

**Objective:** To identify risk factors associated with intraocular lens (IOL) decentration after uneventful phacoemulsification with IOL implantation.

**Methods:** All patients underwent a general ophthalmologic examination. One month postoperatively, the magnitude and orientation of IOL decentration relative to the visual axis center were assessed using an OPD-Scan III aberrometer, and the vertical and horizontal decentration values were determined. Univariate and multivariate linear regression analyses were performed to evaluate the association between the IOL decentration and ocular biometric parameters.

**Results:** In total, 143 eyes of 143 patients were enrolled. The mean decentration magnitude was  $0.27 \pm 0.15$  mm, and the decentration axis appeared at any orientation, with no orientation tendency. The horizontal and vertical decentration were  $-0.02 \pm 0.22$  mm and  $0.01 \pm 0.22$  mm, respectively. Multivariate regression analysis showed that the white-to-white distance (WTW) and the magnitude of angle  $\alpha$  were positively associated with the decentration magnitude ( $P < 0.001$ , adj.  $R^2 = 0.121$ ), the horizontal angle  $\kappa$  and horizontal angle  $\alpha$  were positively associated with the horizontal decentration ( $P < 0.001$ , adj.  $R^2 = 0.209$ ), and the anterior chamber depth (ACD) and vertical angle  $\kappa$  were positively associated with the vertical decentration ( $P < 0.001$ , adj.  $R^2 = 0.152$ ).

**Conclusion:** The IOL decentration magnitude was greater in patients with a larger WTW and a larger angle  $\alpha$ , the horizontal decentration was greater in patients with a larger horizontal angle  $\kappa$  and a larger horizontal angle  $\alpha$ , and the vertical decentration was greater in patients with a deeper ACD and a larger vertical angle  $\kappa$ . In these patients, premium IOLs should be implanted cautiously.

PP-025

### A Brief Screening Protocol for Identifying Cataract Patients with Binocular Vision Anomalies

Q Tan<sup>1</sup>, C Lan<sup>1</sup>, X Liao<sup>1</sup>, M Scheiman<sup>2</sup>.

<sup>1</sup>Ophthalmology, Affiliated Hospital of North Sichuan Medical College, Nanchong, People's Republic of China,

<sup>2</sup>Pennsylvania College of Optometry, Salus University, Elkins Park, United States

**Objective:** Previous studies reported that the preexisting binocular vision problems were the main etiology for post-surgical binocular vision complications of cataract surgery. A minimal testing battery will facilitate the risk screening for binocular vision problems pre-surgery. This study aimed to compare the effectiveness of a brief binocular vision screening to a comprehensive binocular vision examination for detecting binocular vision anomalies in cataract patients.

**Methods:** This study consecutively enrolled cataract patients of 50 years or older. A comprehensive test battery of binocular vision including stereopsis, measurement of phoria by cover test, assessment of positive (PFV) and negative fusional vergence (NFV) by step vergence testing, vergence facility testing by 3BI/12BO prism, near point of convergence by accommodative target and the convergence insufficiency symptom survey were administered. A detailed classification protocol was applied to identify the presence of binocular vision anomalies. A receiver operating characteristic (ROC) curve was plotted to illustrate the diagnostic ability of each test for diagnosing binocular vision anomalies. For those tests showing a significant diagnostic ability, ROC curve was plotted for their combinations to seek a more powerful screening protocol.

**Results:** A total of 73 patients were included, in which 46 patients were diagnosed as non-strabismic binocular vision anomalies. Significant differences were shown in ROC analysis for the difference in phoria from distance to near measured by the cover test ( $AUC=0.96$ ,  $P<0.01$ ), step vergence testing of PFV at distance ( $AUC=0.71$ ,  $P<0.01$ ) and near ( $AUC=0.77$ ,  $P<0.01$ ), compared to the reference line with an AUC of 0.5. The other tests did not show statistically significant differences from the reference line ( $P>0.05$ ). A combination protocol of difference in distance and near phoria, and PFV at distance and near, demonstrated a more robust measure of diagnostic ability than any individual test ( $AUC=0.98$ ,  $P<0.01$ ). Using a cut-off point of a 3 $\Delta$  difference between the distance and near phoria, a cut-off point of 13 $\Delta$  for distance and 15 $\Delta$  for near PFV break, the combination protocol obtains a sensitivity of 91.3% and a specificity of 100%.

**Conclusion:** A combination of the cover test and positive fusional vergence test is as effective for identifying cataract patients with binocular vision anomalies as a comprehensive binocular vision examination protocol.

**PP-026****The effect of uncomplicated phacoemulsification surgery on posterior hyaloid attachment**B Taskiran Kandeger.

**Objective:** Observe the changes of the posterior vitreous attachment after uncomplicated phacoemulsification surgery.

**Methods:** In this retrospective study, medical records of 55 patients (61 eyes) aged  $64.65 \pm 7.59$  with cataract (lens opacity of grade II according to the Lens Opacities Classification System) were analyzed. All patients underwent uncomplicated phacoemulsification and intraocular lens implantation in posterior chamber surgery. Participants with peripheral vitreoretinal degeneration, retinal diseases, and high myopia were excluded from the study. . Optic coherence tomography was performed on all patients preoperatively and postoperatively on the 3rd day, 4th, and 8th week.

**Results:** Sixty-one eyes of 55 patients were included in this study. Of these patients, 27 (49.1%) were female, and 28 (50.9%) were male. 27 eyes were with partial posterior vitreous detachment (PPVD) without traction, and 34 eyes with full attached the posterior vitreous (non-PVD) preoperatively. In the PPVD group, complete PVD was observed in one eye (3.7 %) three days after the operation, and in four eyes (14.8 %) at 4th week. In the non-PVD group, partial PVD was observed in one eye (2.94 %) three days after the operation, and in one eye (2.94 %) at 4th week and remained the same at 8th week in all groups. While the mean age in the PPVD patients that developed complete PVD ( $66.5 \pm 5.78$ ) was similar to the mean of the entire patient group, the incidence of diabetes mellitus accompaniment was 75%, and it was considerably higher than the whole group (34.5%).

**Conclusion:** The present study shows a tendency for progression of PVD after uncomplicated phacoemulsification surgery, which seems to be higher in diabetic patients.

**PP-027****Tear Film Dysfunction after Clear Corneal Phacoemulsification in Diabetics And Non-Diabetics.**A Momin, A Nikose.

**Objective:** To study the incidence of tear film dysfunction and its recovery in diabetics and non-diabetics after clear corneal phacoemulsification.

**Methods:** 50 diabetics and 50 non-diabetics underwent clear corneal phacoemulsification. Schirmer's I test (SIT), Tear film break up time (TBUT), Corneal staining with Ocular Surface Disease Index (OSDI) assessment were done preoperatively, postoperatively at 7 days, 1 month and 3 months in both groups to assess tear film function.

**Results:** Both groups showed decreased SIT and TBUT values on postoperative Day 7, after which they gradually improved. SIT and TBUT values in diabetics were significantly lower than that in non-diabetics at postoperative day 7, 1 month and 3 months ( $p < 0.001$ ). At 3 months, SIT in non-diabetics reached baseline while it remained below preoperative levels in diabetics. OSDI scores reached peak levels in both groups on postoperative day 7, but were higher in diabetics than non-diabetics ( $p < 0.001$ ). OSDI scores gradually improved over 3 months but remained over baseline levels in both groups. Corneal staining was positive in 22% diabetics and 8% non-diabetics at postoperative day 7. However, none of the patients had corneal staining at 3 months.

**Conclusion:** Tear film dysfunction after clear corneal incision occurs in both groups, but is more severe and recovers more slowly in diabetics than non-diabetics.



PP-028

## Mild Temperature Photothermal Assisted Anti-bacterial and Anti-inflammatory Treatment for Post-cataract Surgery Endophthalmitis

Y Ye<sup>1</sup>, J He<sup>1,2</sup>, M Zhou<sup>1,2</sup>, K Yao<sup>1</sup>.

<sup>1</sup>Eye Center, The Second Affiliated Hospital of Zhejiang University, School of Medicine, <sup>2</sup>Institute of Translational Medicine, Zhejiang University, Hangzhou, People's Republic of China

**Objective:** Endophthalmitis, which is one of the severest complications of cataract surgeries, can seriously threaten vision owing to bacterial infection and severe inflammation. It is usually caused after pathogens spread into eyes while MRSA is a common pathogen with poor prognosis. With the overuse and misuse of antibiotics, the treatment of single antibiotic therapy is impeded. Herein, we developed AuAgCu<sub>2</sub>O-bromfenac sodium nanoparticles (AuAgCu<sub>2</sub>O-BS NPs), which was designed to combine anti-bacterial and anti-inflammatory effects for integrated therapy of endophthalmitis after cataract surgery.

**Methods:** The hollow AuAg core were coated with Cu<sub>2</sub>O outer shell layer, and BS was loaded to develop AuAgCu<sub>2</sub>O-BS NPs. After phacoemulsification, IOL implantation and establishment of endophthalmitis, NPs were injected into the anterior chamber. Bacterial colony counting, TEM and SEM were used to verify the *in vitro* antibacterial efficacy. As for *in vivo* therapeutic capability, anterior segment images, etiological and histological analyses were applied to demonstrate treatment outcome in MRSA-infected endophthalmitis model. Local and whole biosafety was further verified.

**Results:** After the AuAgCu<sub>2</sub>O-BS NPs were developed, photothermal conversion effect and the release of BS and ions were measured. Both *in vitro* and *in vivo*, the AuAgCu<sub>2</sub>O-BS NPs could eradicate MRSA relied on PDT and metal ions mediated by mild PTT. Released BS can significantly reduce local inflammation and promote rehabilitation. Through slit lamp image and the clinical grading scale the group treated with AuAgCu<sub>2</sub>O-BS NPs plus NIR reached an optimal effect including less exudation and sooner transparency. Importantly, the mild PTT not only promoted the release of metal ions and drug but also avoided the thermal damage which was more suitable for the application of eye due to the complex structure. Moreover, superior biocompatibility was approved by the preliminary toxicity investigations.

**Conclusion:** In summary, we developed an AuAgCu<sub>2</sub>O-BS NPs to eliminate MRSA, alleviate inflammation and protect the ocular thermal damage for postcataract endophthalmitis. The metal ions could kill MRSA effectively *in vitro* and *in vivo*. BS ensured the anti-inflammatory effect to improve the prognosis. Importantly, mild PTT can control the thermal damage to surrounding tissue. Thus, we have verified a promising nanosystem to provide antibacterial and anti-inflammatory effects to treat postcataract endophthalmitis with great potential for clinical translation.

PP-029

**Characteristics of Anterior Segment in Congenital Ectopia Lentis: An SS-OCT Study**K Ng<sup>1</sup>, H Qi<sup>1</sup>, G Jin<sup>1</sup>, D Zheng<sup>1</sup>.<sup>1</sup>Zhongshan Ophthalmic Center, Sun Yat-sen University, Guangzhou, People's Republic of China

**Objective:** To investigate the characteristics of anterior chamber angle parameters in congenital ectopia lentis (CEL) patients and to evaluate the sensitivity and specificity of anterior segment parameters in distinguishing CEL from healthy controls.

**Methods:** 35 CEL patients and 35 age- and sex-matched healthy controls were recruited. Axial length (AL) and anterior segment parameters including anterior chamber width (ACW), angle open distance (AOD), angle recess area (ARA), trabecular-iris space area (TISA) and trabecular-iris angle (TIA) were measured. All the above parameters and ratio index of angle parameters, which was defined as the angle parameter value of the narrower side to that of the contralateral side, were compared between CEL and controls. Receiver operating characteristic (ROC) curves were also plotted to evaluate the diagnostic performance of anterior chamber angle parameters in CEL patients.

**Results:** All angle parameters of the contralateral side to the dislocated lens side were significant smaller than those of the dislocated lens side in CEL (all  $P < 0.05$ ). For diagnostic performance of anterior chamber angle parameters, the ratio index of TIAr500 combined with TIAr750 had the best diagnostic performance for CEL screening (AUC=0.798), and TIAr500 of 0.887 and TIAr750 of 0.917 were detected to be the optimal cut-off points, representing a sensitivity of 89.8% and specificity of 68.7%.

**Conclusion:** The contralateral side to the dislocated lens side in the CEL had narrower anterior chamber angle. TIAr500 combined with TIAr750 is the optimal combination strategy for ectopia lentis screening. Especially for mild lens dislocations that are imperceptible under slit lamp examination.

**PP-030****Clinical Outcome of Toric IOL Implantation for the Correction of Pre-existing Irregular Corneal Astigmatism in Cataract Patients**

X Bai, S Bu, Y Jiang, J Yang, X Chen, S Lin, Y Gao, F Tian, H Zhang.

**Objective:** To analyse the clinical outcomes of toric IOL implantation for cataract patients associated with irregular corneal astigmatism.

**Methods:** Retrospective cohort study. The medical documents of cataract patients associated with irregular corneal astigmatism who received toric IOL implantation were reviewed. The pre-operative uncorrected visual acuity (UCVA), best corrected visual acuity (BCVA), pre-operative corneal astigmatism, post-operative UCVA and BCVA, residual astigmatism, post-operative refraction and iTrace objective visual quality were documented. We also calculated the prediction error of the residual astigmatism and spherical equivalence (SE).

**Results:** Twenty-eight eyes were included in the current study. The post-operative UCVA and BCVA were significantly improved ( $P < 0.05$ ). The residual astigmatism was  $0.82 \pm 0.61$  D (range 0~2.43 D), which was significantly reduced compared to the pre-operative astigmatism ( $2.04 \pm 0.98$  D, range 1.08~5.24 D). The prediction error for residual astigmatism was  $0.83 \pm 0.56$  D. The percentage of eyes had prediction error for SE within  $\pm 0.25$  D range and  $\pm 0.50$  D range were 32.1% and 75%, respectively. The iTrace objective visual quality test showed that the MTF values at 5, 10, 15, 20, 25 and 30 cpd spatial frequencies were significantly improved after Toric IOL implantation.

**Conclusion:** Toric IOL implantation could effectively reduce the postoperative astigmatism and improve the visual performance in selected cataract patient associated with certain type of pre-existing irregular corneal astigmatism.

**PP-031****“Seeing through the mist”- Visual impact of Intra Ocular Lens (IOL) opacification**

S Jain<sup>1</sup>, T Singh<sup>2</sup>, S Iyengar<sup>3</sup>, S Makhija<sup>4</sup>.

<sup>1</sup>Refractive cataract surgery, phaco development and Cornea, <sup>2</sup>General ophthalmology, <sup>3</sup>Resident, <sup>4</sup>Cornea, Khan Bahadur Haji Bachooali charitable eye hospital, Mumbai, India

**Objective:** To evaluate the qualitative visual loss in pts with opaque IOLs

**Methods:** Several parameters were taken into consideration both subjective and objective in this study. Six patients with opaque IOLs who presented to our outpatient department in the six-month period from September 2021 to February 2022 were evaluated. Parameters that were assessed were visual acuity, refractive error, Dysfunctional Lens Index (DLI) and Modulation Transfer Function (MTF). We also looked for any association between the duration of the surgery and presentation of patient with symptoms of visual loss and we evaluated in detail about the lens material and design that were used in these cases.

**Results:** On evaluating the ray tracing aberrometry, the patients had significant objective symptoms of blurring of vision, double vision, starburst and night myopia amongst others. We also consistently found a significant drop in DLI in all these patients and significant opacity on opacification map. The MTF in these cases were also found to be significantly reduced on evaluating the internal optics on ray tracing aberrometry.

**Conclusion:** The mere evaluation of visual acuity is not a good indicator of quality of vision in patients with opaque IOLs. It is mandatory to perform aberrometry to evaluate the effect of this opaque IOL on patient's quality of vision. Having done so we are in a better position to plan for an early IOL explantation and reimplantation of secondary IOL with the view of restoring patient's vision back to normal.

PP-032

**Analysis of factors associated with residual astigmatism after Toric intraocular lens implantation**L Wang.

**Objective:** To analyze the influencing factors of cataract removal combined with Residual Astigmatism after Intraocular Lens Implantation.

**Methods:** In a prospective study, patients undergoing cataract phacoemulsification surgery combined with Toric intraocular lens were collected, and the difference between postoperative 1mo residual astigmatism and expected astigmatism ( $\Delta$  CYL) was grouped,  $\Delta$  CYL  $<0.5$ D was group A,  $\Delta$  CYL  $\geq 0.5$ D was group B, and biometric measurements such as preoperative vision examination and Pentacam examination were performed, and after intraoperative epibloc, seat marker combined with intraoperative Callisto Eye navigation system positioning was analyzed, and postoperative 1d, 7d, 1mo were analyzed. Optimal corrected vision (BCVA) of 3mo, delausic rate, axial rotation of intraocular lens, rotational stability of intraocular lens after surgery (including postoperative 3mo anterior capsule orifice contraction and offset), and correlation between various influencing factors and  $\Delta$  CYL.

**Results:** There was no statistical difference ( $P>0.05$ ) between BCVA and descaling rate ( $P>0.05$ ) between the two groups after surgery ( $P<0.05$ ), and there was a significant positive correlation between 1d  $\Delta$  CYL and white diameter, residual astigmatism, Kappa angle, anterior chamber depth and anterior chamber angle after surgery ( $P<0.05$ ), and 7d, 1mo, 3mo  $\Delta$  CYL and eye axis length, lens thickness, intraocular lens axis position, spherical aberration, higher order aberration. The diameter of the pupil was significantly positively correlated ( $P<0.05$ ), the posterior surface astigmatism of the cornea was significantly positively correlated with residual astigmatism ( $P=0.03$ ) and the axial position of astigmatism was significantly negatively correlated ( $P=-0.034$ ); Patient gaze ability and intraocular lens stability were significantly positively correlated with postoperative intraocular lens rotation ( $P=0.000$ ), and there were statistical differences in eye axis length, patient gaze, intraocular lens stability, and navigation and positioning accuracy in group B compared with group A ( $P<0.05$ ).

**Conclusion:** Residual astigmatism after Toric intraocular lens implantation is related to multivariate, among which the astigmatism residue of  $\Delta$  CYL  $\geq 0.5$ D or more after surgery is closely related to the length of the eye axis, the patient's gaze, the accuracy of marker positioning and the stability of the intraocular lens.

**PP-033****Bimanual Prechop Fragmentation Technique**

J Diaz<sup>1</sup>, A Díaz<sup>2</sup>, N Gonzalez<sup>3</sup>.

<sup>1</sup>Oftalmologia, Hospital Universitario del Rio, <sup>2</sup>Oftalmologia, <sup>3</sup>Hospital Universitario del Rio, Cuenca, Ecuador

**Objective:** To describe a technique for mechanical nuclear fracture before phacoemulsification, to facilitate surgery and minimize the risk of damage to the corneal endothelium by using less CDE. (Cumulative dissipated energy)

**Methods:** We performed the proposed surgical technique on 200 patients.

**Surgical Technique**

We start with the standard steps of a usual phacoemulsification technique, after filling up the chamber with dispersive OVD, performing the *continuous circular capsulorhexis*, hydrodissection, and rotation of the nucleus, then we proceed to perform our proposed technique, for which we will use two instruments:

The first is a 1.5mm Phaco Chopper (Nagahara type), introduced by the paracentesis. The second is a lens pusher, a vertical Y-shaped instrument (Bechert), whose arms measure 1mm each, and is introduced by the 2.2 mm incision. The Y-shaped pusher is used to hold the nucleus by the anterior lower central area, while the chopper is first directed horizontally towards 7 o'clock, then when we reach the edge of the nucleus, we rotate it downwards, then we perform an approach maneuver from one instrument towards the other when the instruments are almost in contact, we move them in opposite directions, accomplishing the nucleus fragmentation into two halves. Then the same maneuver can be performed with the obtained halves to achieve more than two fragments, to subsequently execute phacoemulsification as usual.

**Results:** We performed this technique successfully in 200 patients, N0 to N6 cataract grades (BCN-10 Barraquer Decimal Classification System) without incidents, observing a significant decrease in total ultrasound energy, aspiration time, and volume of solution irrigation.

**Conclusion:** The technique proved to be safe and effective in achieving nuclear fragmentation. Nuclear division without using any extra ultrasound energy or BSS irrigation before introducing the phacoemulsification tip results in a less invasive form of cataract surgery.

PP-036

### Comparison of the Actual Diameter of Capsulotomy and Predicted Diameter of Capsulotomy after Femtosecond Laser-assisted Capsulotomy

W Luo, Y wang<sup>1</sup>, S Hu<sup>2</sup>, H Zheng<sup>2</sup>, S Zhou<sup>2</sup>, J Ortega-Usobiaga<sup>3</sup>.

<sup>1</sup>Ophthalmology, Aier Eye Hospital of Wuhan University, <sup>2</sup>Ophthalmology, Aier Eye Hospital of Wuhan University, Wuhan, People's Republic of China, <sup>3</sup>Ophthalmology, Department of Cataract and Refractive Surgery, Clinica Baviera, Aier Eye Hospital, Bilbao, Spain

**Objective:** To compare the consistency between the actual diameter of capsulotomy (ADC) and the predicted diameter of capsulotomy (PDC) in femtosecond laser cataract surgery (FLCS), and analyze the factors that influencing the deviation of the diameter of capsulotomy (DDC) between the actual diameter and the predicted.

**Methods:** This was a retrospective observational case series. The patients who underwent femtosecond laser-assisted cataract surgery at Aier Eye Hospital of Wuhan University from March 2020 to March 2021 were reviewed. The ADC in FLAS were measured by computer-assisted image analysis (Image-pro plus 6.0) and compared with the PDC. The effects of age, gender and biometrics on the DDC were analyzed.

**Results:** 412 eyes of 336 patients were included. The mean age was  $53.0 \pm 0.91$  (range 3 to 91 years). The results showed that ADC was  $5.21 \pm 0.21$  mm when PDC was set to 4.50 mm, and the difference between them was significant ( $P < 0.05$ ); however, the ADC was  $5.10 \pm 0.38$  mm when PDC was set to 5.2 mm, without statistically significant differences between them ( $P > 0.05$ ). No correlation was found between DDC and axial length (AL), anterior chamber depth (ACD), or average keratometry (Km) ( $P > 0.05$ ), but a significant negative correlation was found between DDC and lens thickness (LT) ( $r = -0.21$ ;  $P < 0.05$ ) and age ( $r = -0.70$ ;  $P < 0.05$ ). For patients under 40 years old, the younger the age, the larger the DDC, but for patients over 40 years old, the DDC was small and tended to be zero. Using curvilinear regression analysis, an age-depending correction formula was developed, predicted  $ADC = PDC + 1.23 - 0.30 \ln(\text{age})$  [ $\text{age} \geq 3$ ] ( $R^2 = 0.65$ ;  $F = 752.39$ ;  $P = 0.00$ ).

**Conclusion:** Age and LT were the main factors that influenced the consistency of ACD and PCD. For patients under 40 years old, the younger the age, the larger the DDC. For patients over 40 years old, the DDC was small. The thicker the LT, the smaller the DDC.

**PP-037****Long-term results of femtosecond laser arcuate keratotomy for correction of corneal astigmatism during cataract surgery**

Z Zhang.

**Objective:** To investigate corneal astigmatism reduction after penetrating femtosecond laser arcuate keratotomy (FLAK) during long term follow-up.

**Methods:** 35 eyes of 35 patients with age-related cataract and corneal astigmatism between 0.5 and 3.0 diopters (D). FLAKs were placed at a diameter of 8.0 mm with a depth of 90%. Corneal astigmatism was measured before surgery, 3 months and 1 year after surgery. Vector analyses were performed.

**Results:** Mean preoperative corneal astigmatism ( $1.35 \pm 0.70$  D) were significantly reduced to  $0.67 \pm 0.40$  D at 3 months and  $0.69 \pm 0.43$  D at 1 year after surgery respectively ( $p=0.113$ ). Surgery induced astigmatism were  $1.06 \pm 0.72$  D at 3 months and  $1.02 \pm 0.66$  D at 1 year ( $P=1.000$ ). Geometric mean of the correction index was 0.78 at 3 months and 1 year after surgery ( $P=1.000$ ). Mean of flatten effect was  $-0.95 \pm 0.77$  D at 3 months and  $-0.90 \pm 0.71$  D 1 year ( $P=0.257$ ).

**Conclusion:** Femtosecond laser arcuate keratotomy for correction of low to moderate astigmatism has achieved stable correction at 3 months postoperatively. At 1-year follow-up, no significant regression was found.



## PP-038

**An OCT-based deep learning algorithm for visual acuity prediction of highly myopic eyes after cataract surgery.**

X Zhu<sup>1,2</sup>, L Wei<sup>2</sup>, W He<sup>2</sup>, K Zhang<sup>3</sup>, Y Lu<sup>2</sup>.

<sup>1</sup>Eye & ENT Hospital, Fudan University,, <sup>2</sup>Eye & ENT Hospital of Fudan University, <sup>3</sup>Eye & ENT Hospital of Fudan University,, Shanghai, People's Republic of China

**Objective:** Due to complicated and variable fundus status of highly myopic eyes, their visual benefit from cataract surgery remains hard to be determined preoperatively. We therefore aimed to develop an optical coherence tomography (OCT) based deep learning algorithms to predict the postoperative visual acuity of highly myopic eyes cataract surgery.

**Methods:** The internal dataset consisted of 1,415 highly myopic eyes having cataract surgeries in our hospital. Another external dataset consisted of 161 highly myopic eyes from Heping Eye Hospital. Preoperative macular OCT images were set as the only feature. The best-corrected visual acuity (BCVA) at 4 weeks after surgery was set as the ground truth. Five different deep learning algorithms including ResNet-18, ResNet-34, ResNet-50, ResNet-101, and Inception-v3 were used to develop the model aiming at predicting the postoperative BCVA and an ensemble learning were further developed. The model was further evaluated in the internal and external test datasets.

**Results:** The ensemble learning showed the lowest mean absolute error (MAE) of 0.1566 logMAR and lowest root mean square error (RMSE) of 0.2433 logMAR in the validation dataset. Promising outcomes in the internal and external test datasets were revealed with MAEs of 0.1524 and 0.1602 logMAR, and RMSEs of 0.2612 and 0.2020 logMAR, respectively. Considerable sensitivity and precision were achieved in the BCVA < 0.30 logMAR group, with 90.32% and 75.34% in the internal test dataset, and 81.75% and 89.60% in the external test dataset, respectively. The percentages of the prediction errors within  $\pm 0.30$  logMAR were 89.01% in the internal, and 88.82% in the external test dataset.

**Conclusion:** Promising prediction outcomes of postoperative BCVA was achieved by the novel OCT-trained deep learning model, which will be helpful for the surgical planning of highly myopic cataract patients.

PP-039

### Comparisons of visual outcomes between bilateral implantation and mix-and-match implantation of three types intraocular lenses

S Ke<sup>1</sup>, W WAN<sup>1</sup>, C LI<sup>1</sup>.

<sup>1</sup>Ophthalmology, The First Affiliated Hospital of Chongqing Medical University, CHONGQING, People's Republic of China

**Objective:** To compare binocular visual acuity, stereopsis, contrast sensitivity and dynamic visual acuity of 5 combinations of bifocal IOLs, trifocal IOLs and EDOF IOLs in age-related cataract patients.

**Methods:** 212 eyes of 106 patients who underwent cataract surgery in the ophthalmology department of the First Affiliated Hospital of Chongqing Medical University were involved. Subgroups included group MM(27patients, bilaterally ZMB00), group TT(23patients, bilaterally AT LISA tri839MP), group XX(29patients, bilaterally ZXR00), group MX(16patients, ZMB00+ZXR00) and group TX(11patients, AT LISA tri839MP+ZXR00). The uncorrected visual static acuity (UDVA, UIVA and UNVA), uncorrected dynamic visual acuity (UDDVA, UIDVA and UNDVA), near and distance stereopsis, and contrast sensitivity(CS) were assessed 3 months postoperatively.

**Results:** Subgroups of TT, XX and MX showed better UIVA than MM(P=0.045, 0.011 and 0.042, respectively). MX showed better UNVA than MM and TX(P=0.026 and 0.011, respectively). MX group had the optimal outcomes of both near and distance stereopsis. In the UDDVA, XX group and MX group showed better outcomes than TX group at 24fps(frames per second) (P=0.024 and 0.020, respectively). XX group and MX group showed optimal outcomes at almost all speeds of UIDVA (P=0.000, 0.002, and 0.009, respectively). As the speed increased, the XX group and the MX group showed better UNDVA than the MM group and the TT group (P=0.016, 0.006, and 0.000, respectively).

**Conclusion:** Mix-and-match implantation of bifocal IOLs and EDOF IOLs provides excellent and stable binocular visual outcomes including SVA, strereopsis and DVA in distant and near distances.

PP-040

### E3 ubiquitin ligase SKP2 ubiquitination modifies OGG1 in UVB-induced oxidative damage in lens epithelial cells

王.

**Objective:** Objective To investigate the mechanism of ubiquitination degradation of the E3 ubiquitin ligase SKP2-mediated base excision repair protein 8-oxoguanine-DNA glycosylase (OGG1) in the development of age-related cataract (ARC).

**Methods:** Immunoprecipitation assays were used to detect the ubiquitination modification of OGG1 and its ability to bind to SKP2. A model of oxidative damage was constructed using medium-wave ultraviolet (UVB) irradiation of a lens epithelial cell line (SRA01/04). Immunoblotting assays were performed to detect protein expression after cell irradiation and after overexpression of SKP2.

**Results:** Changes in OGG1 protein were observed by transfection of SKP2 plasmids. The UbiBrowser software predicted a potential E3 ubiquitin ligase binding to OGG1 and demonstrated an interaction between SKP2 and OGG1 by immunoprecipitation assays. Furthermore, after oxidative damage, SKP2 protein expression levels showed a trend of decreasing followed by a gradual increase, with the most significant decrease in SKP2 expression at 10 min. The relative expression of SKP2 was  $1.04 \pm 0.007$ ,  $0.92 \pm 0.008$  and  $1.33 \pm 0.02$  in the control, transfected control plasmid Flag and transfected overexpressed plasmid SKP2 groups, respectively, with a significant increase in SKP2 protein expression compared to the transfected empty plasmid group ( $P < 0.05$ ). The relative expression of OGG1 in the control group, UVB-treated group, UVB+transfected control plasmid group and UVB+transfected overexpressed SKP2 group were  $1.05 \pm 0.01$ ,  $5.05 \pm 0.16$ ,  $5.2 \pm 0.07$  and  $3.83 \pm 0.1$ ; compared with the UVB  $\pm$  transfected empty plasmid Flag group, the OGG1 in SRA01/04 cells after overexpression of SKP2 protein expression levels were significantly lower in SRA01/04 cells after overexpression of SKP2 compared with the UVB  $\pm$  transfected empty plasmid Flag group, and the differences were statistically significant ( $P < 0.05$ ).

**Conclusion:** The E3 ubiquitin ligase SKP2 can promote ubiquitinated degradation of OGG1, leading to the accumulation of damaging DNA inside lens epithelial cells and thus to the development of ARC.

**PP-041****What's done can be undone : A case series of descemet's membrane detachment following cataract surgery and management strategies**

S Jain, S Makhija, T Singh.

**Objective:** To demonstrate management strategies of a multitude of different presentations of post operative Descemet's membrane detachment(DMD).

**Methods:** We report a case series of 6 patients with Descemet's membrane detachment post cataract surgery. The cases included a variety of presentations such as total DMD, partial or subtotal DMD (inferior/superior), a case of DMD with Descemet's membrane tear with a scroll as well as long standing DMD. We discuss threadbare the different management strategies undertaken whilst customizing the plan of descemetopexy in each of these varied Descemet membrane presentations.

The markers for successful descemet's membrane reattachment were visual acuity, corneal clarity (reduced corneal edema) and confirmation on ASOCT.

**Results:** All the 6 cases in our series had a successful reattachment of the Descemet's membrane in it's entirety. Anterior segment Optical Coherence Tomography confirmed settlement of the detachment in all cases. The various management strategies undertaken to settle these eyes have been discussed in detail in this paper.

**Conclusion:** Descemet's membrane detachment is not an uncommon complication following cataract surgery. A high index of suspicion should exist in patients presenting with postoperative corneal edema. Early diagnosis is mandatory and can be achieved by performing ASOCT. A descemetopexy should be attempted irrespective of the duration and timing of diagnosis. If carefully planned, we are likely to achieve an optimal end result of an attached descemet's membrane, a clear cornea and good vision.

PP-043

**Lens Extraction Device For Low Energy Cataract Fragmentation**B Kusa, M Piovella<sup>1</sup>.<sup>1</sup>*Piovella Global Center For Ophthalmology, Piovella Global Center For Ophthalmology, MONZA, Italy*

**Objective:** The new miLOOP (Carl Zeiss Meditec) is a micro interventional device designed to provide endocapsular lens fragmentation in dense cataract and complicated cases. Single use device, finger controlled. Every cataract extraction is based on the needs to divide the nucleus minimum by two.

**Methods:** miLOOP was adopted in 242 eyes of 144 patients with medium/hard cataract to split the nucleus in two parts or more. The metal loop was inserted in the capsular bag and opened through the edge of the posterior capsule. Once the loop is in the proper position, the loop is retracted to split the nucleus. The learning curve needs 50 cases of experience. Use of a proper amount of viscoelastics is mandatory.

**Results:** The nucleus was split in two or more pieces in all patients. It is necessary to have a learning curve adopting the device in simple cases to be confident in the proper use to avoid device-related complications. In one case, the loop did not match the capsular bag and caused zonula damage with no important complication.

**Conclusion:** miLOOP adoption in medium dense cataract and in complicated cases makes hard nucleus cataract removal more controlled and safe. A proper learning curve is needed.

PP-044

**Pinhole Intraocular Lens To Correct Presbyopia And Astigmatism In Eye With Regular And Irregular Cornea**G Scaltrini, M Piovella<sup>1</sup>.<sup>1</sup>*Piovella Global Center For Ophthalmology, Piovella Global Center For Ophthalmology, MONZA, Italy*

**Objective:** To demonstrate visual performance of the IC-8 small aperture IOL (AcuFocus, Irvine, CA) implanted in patients in whom a cataractous lens has been removed. Pinhole IOLs technology demonstrated to be the best available technology to be implanted in patients that have experienced previous RK or with irregular corneal astigmatism

**Methods:** Methods: 29 eyes with cataract, corneal astigmatism  $1.50 \pm 2.57$ , had IC-8 IOL implantation. 21 patients experienced IC-8 IOL in the non-dominant eye and a monofocal IOL in the dominant eye. 4 Patients had bilateral IC 8 IOL implantation. One pateint 20 years after RK Results

**Results:** The IC8 musk decreases halos and glare in aberrate cornea At 6 years in the IC-8 eye, UDVA is 20/20,56 UIVA is 20/20 at 80cm and 67 cm and UNVA is 20/20.5.In the monofocal eye, UDVA is 20/18,UIVA is 20/23 at 80cm 20/25.7 at 67cm and UNVA is 20/50.Binocular UDVA is 20/18,UIVA is 20/18.3 (80 cm and 67cm)and UNVA is 20/20.5

**Conclusion:** Pinhole effect normally corrects up to two diopters of corneal astigmatism and overcome toric IOL management within this range. IC 8 is the most effective solution to correct presbyopia and astigmatism in eyes with irregular cornea

PP-046

**Comparison of the clinical outcomes of Eyecryl and Tecnis toric intraocular lenses- a real-world study**M Thulasidas, A Sasidharan<sup>1</sup>.<sup>1</sup>*Sankara Eye Hospital, Tamil Nadu, India*

**Objective:** To compare the postoperative uncorrected distance visual acuity (UDVA) and refractive outcomes of cataract patients with astigmatism following implantation of Eyecryl™ and Tecnis® toric intraocular lenses (IOLs).

**Methods:** We conducted a single-centre, retrospective study including patients who had undergone phacoemulsification and implantation with either Eyecryl™ toric (Group 1) or Tecnis® toric (Group 2) IOL. The primary outcome measures included postoperative UDVA and residual astigmatism at 3 months. The secondary outcome measure was IOL misalignment > 10° throughout the follow-up period.

**Results:** One hundred and eight eyes of 76 patients (44 males and 32 females) were analyzed. Twenty nine patients (38 eyes) received Eyecryl™ toric IOL (Group 1), and 47 patients (70 eyes) received Tecnis® toric IOL (Group 2). Group 1 and 2 showed a mean postoperative logMAR UDVA of  $0.09 \pm 0.11$  and  $0.06 \pm 0.09$ , respectively, at 3 months ( $P = 0.114$ ). In both groups, all the eyes achieved a postoperative UDVA of  $\leq 0.3$  logMAR. The postoperative residual astigmatism of group 1 and group 2 was  $-0.29 \pm 0.34$  D and  $-0.16 \pm 0.27$  D, respectively ( $P = 0.038$ ). Postoperative astigmatism was within  $\pm 1.00$  D in all the eyes. No eyes had an IOL misalignment >10° throughout the follow-up period.

**Conclusion:** Both Eyecryl™ and Tecnis® toric IOLs provided significant improvement in uncorrected visual acuity and astigmatism correction postoperatively. The Tecnis® toric IOL provided statistically significant lower residual astigmatism than Eyecryl™ toric IOL. However, the difference in postoperative astigmatism between the two IOLs was clinically insignificant.

PP-047

**IOLCon, the roadmap for reliable IOL calculation.****New features of international data-base for updated and optimized IOL constants**

S Scholtz<sup>1</sup>, O Vitovska<sup>2</sup>, T Eppig<sup>1</sup>, M Schwemm<sup>1</sup>, A Langenbacher<sup>1</sup>.

<sup>1</sup>Saarland University, Institute of Experimental Ophthalmology, Homburg/Saar, Germany, <sup>2</sup>Eye Clinic, Bogomolets University, Kyiv, Ukraine

**Objective:** The Internet database IOLCon ([www.iolcon.org](http://www.iolcon.org)), founded in 2017, established itself meanwhile as a reliable, worldwide available source for optimized IOL constants and specifications. Based on modern optimization strategies, IOLCon also offers individually optimized IOL constants free of charge for ophthalmic surgeons. Recently, IOLCon supports ophthalmic surgeons e.g. in selecting the individual IOL by its new "Lens Power Calculation Module" (LPCM).

**Methods:** Close cooperation with Institute of Experimental Ophthalmology, University Homburg/Saar (Germany) and Eye Clinic, Bogomolets University, Kyiv (Ukraine).

**Results:** The method used by IOLCon to optimize IOL constants is characterized as an "intelligent IOL constant optimization strategy", which uses modern nonlinear optimization methods. Optimizations of the constants for the following published formulae can be found on IOLCon: Haigis, Hoffer-Q, Holladay 1, SRK/T - and now also for the new Castrop formula. The prerequisite is the use of current measurement techniques that precisely measure all distances of the eye. IOLCon's newly launched online calculator, LPCM, is based on the Castrop formula, and supports ophthalmic surgeons when selecting the individual IOL power. The calculator is intended to be used for scientific purpose only and in combination with comprehensive eye exams, respective diagnostics and measurements required for patients undergoing cataract surgery.

**Conclusion:** A modern database for optimized IOL constants and lens specifications that meets the demands of today's cataract surgery is just as urgently needed today as modern online calculation tools that serve as a decision-making aid when selecting the individual IOL power. IOLCon offers both: with its (individually) optimized IOL constants and the online calculation tool "Lens Power Calculation Module", it is an essential instrument for modern cataract surgery and will also meet future demands of ongoing developing ophthalmic surgery.



PP-048

**Clinical Outcome of AcrySof® IQ PanOptix™ Trifocal Intraocular Lens in Chinese Eyes**J Chang<sup>1</sup>.<sup>1</sup>*Department of Ophthalmology, Hong Kong Sanatorium & Hospital, Hong Kong, Hong Kong, China*

**Objective:** To report visual outcomes and quality of vision and life after bilateral refractive lens exchange or cataract surgery with AcrySof® IQ PanOptix™ Trifocal IOL.

**Methods:** In this prospective study, subjects implanted with bilateral AcrySof® IQ PanOptix™ Trifocal IOLs were included. Postoperative assessments included photopic and mesopic VA at distance, intermediate (60cm) and near (40cm); photopic and mesopic contrast sensitivity (with and without glare); defocus curve; questionnaire on dysphotopsia, satisfaction and spectacle independence.

**Results:** Mean binocular uncorrected VA at distance, intermediate (60 cm), and near (40 cm) were  $-0.05 \pm 0.06$ ,  $0.06 \pm 0.10$ , and  $0.04 \pm 0.05$  in logMAR, respectively. No eye lost >1 line of corrected distance VA. Contrast sensitivity was similar to the age norm. Mean halo, glare, and starburst scores were 2.4, 0.2, and 1.4 out of 5 respectively. The mean satisfaction score was 4.3 out of 5. One hundred percent spectacle independence was achieved. No IOL exchange was required. Across the defocus powers from +0.50D to -3.00D, vision was satisfactory and was better than 20/25.

**Conclusion:** In conclusion, AcrySof® IQ PanOptix™ Trifocal IOLs were safe and effective. It offered satisfactory vision at various distances, high degree of satisfaction and spectacle independence, with minimal dysphotopsia.

PP-049

**Optical aberrations following implantation of multifocal IOLs: a systematic review and meta-analysis**

C Henein<sup>1,2</sup>, C E Fang<sup>3</sup>, I Barai<sup>4</sup>, D Bokre<sup>1</sup>, Y Bouremel<sup>1</sup>, A Adan<sup>5</sup>, M Khan<sup>5</sup>, M Nanavaty<sup>6,7</sup>.

<sup>1</sup>University College London, Institute of Ophthalmology, <sup>2</sup>NIHR Moorfields Biomedical Research Centre, London, <sup>3</sup>Manchester Royal Eye Hospital, Manchester University NHS Foundation Trust, Manchester, <sup>4</sup>Western Eye Hospital, Imperial College Healthcare NHS Trust, London, <sup>5</sup>School of Medicine, University of Liverpool, Liverpool, <sup>6</sup>Sussex and Brighton Medical School, University of Sussex, <sup>7</sup>Sussex Eye Hospital, University Hospitals Sussex NHS Foundation Trust, Brighton, United Kingdom

**Objective:** Multifocal Intraocular Lenses (mIOL) restore vision at different focal distances, a technology that is constantly advancing. We aimed to systematically review patient reported optical aberrations and spectacle independence following implantation of, diffractive, refractive and hybrid (refractive + diffractive) mIOLs to treat presbyopia.

**Methods:** We conducted electronic database searches in MEDLINE, EMBASE, Cochrane Central Register of Controlled Trials, Web of Science, Scopus, and ClinicalTrials.gov. Eligibility criteria included RCTs written in English and containing data on optical aberrations in adults receiving mIOLs for presbyopia. Methodological quality was assessed using Cochrane Handbook 6.2. Metaprop command in Stata 17 was used to pool the proportion of patients reporting optical aberrations. 95% confidence intervals were computed and Freeman-Turkey double arcsine was used for transformation of proportions.

**Results:** Of the 1140 abstracts screened, 36 full texts met the eligibility criteria and 19 RCTs were included in the meta-analysis. For diffractive, refractive and hybrid mIOLs, proportions of patients reporting glare were 0.26 (0.05-0.53), 0.35 (0.25-0.46) and 0.05 (0.00-0.19) ( $p=0.01$ ); reporting halos were 0.27 (0.14-0.43), 0.44 (0.29-0.59) and 0.17 (0.02-0.39) ( $p=0.11$ ) and those with spectacle independence was 0.82 (0.76-0.87), 0.63 (0.47-0.77) and 0.86 (0.70-0.97) ( $p=0.03$ ) respectively.

**Conclusion:** There is moderate evidence to suggest fewer patients report optical aberrations of glare and halos with better spectacle independence following implantation of diffractive or hybrid mIOLs following refractive lens exchange for presbyopia.

PP-050

## The impact of bilateral cataract surgery on Hemoglobin A1c and cardiovascular risk in type 2 diabetes mellitus patients

M Matias<sup>1</sup>, P Alves-Peixoto<sup>2</sup>, A Rocha<sup>1</sup>, J Chibante-Pedro<sup>1</sup>.

<sup>1</sup>Centro Hospitalar de Entre o Douro e Vouga, Santa Maria da Feira, <sup>2</sup>Centro de Medicina de Reabilitação da Região Centro - Rovisco Pais, Cantanhede, Portugal

**Objective:** To assess Hemoglobin A1c (HbA1c) and cardiovascular risk (CVR) evolution in type 2 diabetes mellitus (T2D) patients following bilateral phacoemulsification cataract surgery.

**Methods:** We randomly selected 28 patients who underwent uncomplicated cataract surgery at Centro Hospitalar de Entre o Douro e Vouga between 2018 and 2019. All patients did not have other known ophthalmological pathology. Furthermore, all of them were previously diagnosed with T2D and their records of lipid profile, blood pressure, body mass index (BMI) and HbA1c were available before and up to 6 months following surgery. We also subdivided our patient cohort in 2 different groups: group 1 – mild visual impairment,  $\leq 0.50$  LogMAR; group 2 – moderate to severe visual impairment,  $> 0.50$  LogMAR. The previously mentioned variables were compared in our patient cohort and between subgroups 1 and 2, before and after surgery, using paired samples Student's T test or Wilcoxon rank, and repeated measures ANOVA with Tukey Post Hoc tests, respectively.

**Results:** Phacoemulsification cataract surgery resulted in markedly improved visual acuity (VA) regardless of baseline VA. Outstandingly, our patient cohort showed reduced HbA1c levels, BMI, systolic arterial pressure, triglycerides levels and CVR within 6 months of cataract surgery. Despite the fact that before surgery, the two subgroups were comparable for all the assessed variables, excluding VA, following surgery, HbA1c levels, systolic blood pressure and CVR were only improved in group 2, but not in group 1.

**Conclusion:** Our results suggest that phacoemulsification cataract surgery may be an important tool in improving T2D patients' overall glycemic control and CVR. Yet, this improvement appears to be only present in patients with worse prior VA.

PP-051

**Correlation between *FBN1* mutations and ocular features with ectopia lentis in the setting of Marfan syndrome**Z Chen.

**Objective:** To investigate genotype-phenotype correlations of fibrillin-1 (*FBN1*) mutations in the ocular system.

**Methods:** Patients with congenital ectopia lentis (EL) were screened using panel-based next-generation sequencing and complemented with multiplex ligation dependent probe amplification. In a total of 125 probands with *FBN1* mutations, the ocular phenotypes were analyzed in relation to *FBN1* mutations.

**Results:** Premature termination codons were associated with less severe EL and a thinner central corneal thickness (CCT) than the inframe mutations. The eyes of patients with mutations in the C-terminal region had a higher incidence of posterior staphyloma than those in the middle and N-terminal region. Mutations in the TGF- $\beta$  regulating sequence had larger horizontal corneal diameters (white-to-white, WTW), higher incidence of posterior staphyloma, but less severe EL than those with mutations in other regions. Mutations in the neonatal region were associated with thinner CCT. Longer axial length (AL) was associated with mutations in the C-terminal region or TGF- $\beta$  regulating sequence after adjusting for age, EL severity, and corneal curvature radius.

**Conclusion:** The *FBN1* genotype-phenotype correlations were established in some ocular features, including EL severity, AL, WTW, CCT, etc. TGF- $\beta$  signaling is likely to contribute to the megaloglobus in the eyes of patients with *FBN1* mutations.

**PP-052****Comparison of the Early Visual Performance after Implantation of four types Multifocal Intraocular Lenses**

X Tan.

**Objective:** To compare the visual acuity and contrast sensitivity in patients implanted with four types multifocal intraocular lenses (MIOLs) after cataract surgery.

**Methods:** This retrospective observational case series enrolling eyes that received the Symfony, the ReSTOR, the ZMBOO, or the AT Lisa tri 839MP in Shanxi Eye Hospital. The near, intermediate, and distant visual acuities, contrast sensitivity under photopic (85 cd/m<sup>2</sup>) and mesopic (6 cd/m<sup>2</sup>) conditions with and without glare were assessed. Follow-up was carried out after 1 month in all patients.

**Results:** This study included 107 patients (161 eyes) implantation with different MIOLs: the Symfony (59 eyes), the ReSTOR (39 eyes), the ZMBOO (38 eyes), and the AT Lisa tri 839MP (25 eyes). There was no statistically significant difference among groups regarding in UDVA ( $P>0.05$ ). The ZMBOO group had worse UIVA than the Symfony and AT Lisa tri 839MP groups ( $P<0.05$ ). The UNVA was significantly worse in the Symfony group ( $P<0.05$ ). The eyes with ReSTOR, Symfony, and ZMBOO showed preferred contrast sensitivity than those AT Lisa tri 839MP at spatial frequencies of 18 cpd in photopic and mesopic conditions with and without glare ( $P<0.05$ ) and 6, 12 cpd in mesopic conditions without glare ( $P<0.05$ ).

**Conclusion:** All the tested multifocal lenses provided satisfied distance vision. However, the ZMBOO lenses led to unsatisfactory outcomes in intermediate vision, and the Symfony lenses led to unsatisfactory outcomes in near vision. Eyes implanted with the AT Lisa tri 839MP IOL showed worse photopic and mesopic CS at high spatial frequencies than other IOLs.

PP-053

### The application value of the Callisto Eye navigation system in astigmatism-corrected intraocular lens implantation

L Wang.

**Objective:** To investigate the application value of Callisto Eye navigation system in astigmatism-corrected intraocular lens implantation.

**Methods:** In retrospective control analysis, 25 patients (25 eyes) with cataract phacoemulsification surgery combined with implantation of astigmatism-corrected intraocular lenses were collected in our hospital, and according to the corneal astigmatism axial marking method, the manual corneal margin labeling method combined with the intraoperative Callisto Eye navigation system was positioned as group A (15 eyes), the simple manual corneal labeling was group B (10 eyes), the two groups of patients were manually labeled with corneal margin marker pens in the preoperative sitting position, and the patients in group A were jointly applied callisto during surgery. The Eye navigation system guides the position of the incision and the position of the astigmatism axis after the implantation of the astigmatized intraocular lens. The optimal corrected vision (BCVA), de-mirror rate, intraocular lens axial rotation degree, and astigmatism prediction difference of 1d, 7d and 1mo were analyzed.

**Results:** There was no statistical difference between the two groups of patients with optimal corrected visual acuity in 1d, 7d and 1mo after surgery ( $P > 0.05$ ), and there was a significant statistical difference in the de-lens rate of 1d, 7d and 1mo after surgery ( $P < 0.05$ ). The difference between the axial rotation and astigmatism prediction of the intraocular lens in group A is less than that of group B ( $P < 0.05$ ).

**Conclusion:** The Callisto Eye navigation system has important application value in the implantation of astigmatism-corrected intraocular lens in cataract surgery, which can guide corneal incisions and annular tearing sacs, accurately locate the axial position of intraocular lens astigmatism, maintain intraocular lens neutrality, and improve postoperative visual quality, which has important clinical application value.

**PP-054****Analysis of visual quality after surgery of continuous vision-range intraocular lens implantation at TECNIS Symphony**L Wang.

**Objective:** Observation of visual quality after cataract phacoemulsification surgery combined with TECNIS Symphony continuous-range intraocular lens implantation.

**Methods:** Retrospective controlled clinical studies, including 50 (50) eyes of cataract patients treated in our hospital from June 2020 to June 2021, were divided into Symphony intraocular lens group A (30) eyes and monofocal aspherical intraocular lens B group (20) eyes according to the different types of intraocular lenses implanted during surgery, and the main sensory refraction was performed at 7d, 1 month and 3 months after surgery, respectively, to observe far, medium and near vision, correct far vision, equivalent spherescopy, and the contrast sensitivity was measured by the optic function tester Statistics of postoperative de-mirroring rate, halo and glare incidence, plotting out-of-focus curves for 3 months after surgery, and conducting visual quality satisfaction questionnaires.

**Results:** There were no serious complications after surgery in both groups; one case in group A showed mild halo and glare after surgery, 12 cases in group B had moderate halo and glare ( $P<0.05$ ); there was no obvious statistical difference between the far vision and optimal corrected far vision of patients in 7 days, 1 month and 3 months after surgery ( $P>0.05$ ); Visual acuity and near vision were significantly better than those in group B ( $P<0.05$ ) in 1 month and 3 months; postoperative contrast sensitivity in group A was significantly better than that in group B ( $P<0.05$ ); desuphrosopic rate in group A was 96.6%, and postoperative descending rate in group B was 52% ( $P<0.05$ ); the defocusing curve in group A was peaked at 0.0D and -2.0D in 3 months after surgery, forming a plateau and decreasing steadily, and group B showed a steep trend decline after peaking at 0.0D and -0.25D ( $P<0.05$ ); The MIOL Postoperative Quality of Life Questionnaire scored higher in group A than group B ( $P<0.05$ ).

**Conclusion:** Cataract surgery combined with TECNIS Symphony continuous-range intramersal lens implantation can provide good continuous vision and contrast sensitivity throughout the process, low incidence of postoperative optical interference, high visual quality and satisfaction, and is worthy of clinical promotion and application.

PP-057

### Comparison of the accuracy between two Toric IOL power calculation methods

Z Yang<sup>1</sup>, Y Zhou<sup>1</sup>.

<sup>1</sup>Shenyang Aier Eye Optometry Hospital, Shenyang, People's Republic of China

**Objective:** To investigate the accuracy of a manufacturer's online Toric calculator with the measured total corneal astigmatism (TCA) values used compared with the online Barrett Toric Calculator with standard keratometry values used.

**Methods:** This study was a retrospective case series . Patients who had underwent uneventful phacoemulsification and Toric IOL implantation subsequently were reviewed . The IOL spherical equivalent was determined by the Barrett Universal II formula with the standard keratometry value produced by IOL master 700. The IOL toric power and axis was determined by the first generation of online Alcon Toric calculator with the 4.0mm apex/ring total corneal refractive power (TCRP) values in the distribution map produced by Pentacam. The preoperative and postoperative biometry measurements were extracted from patient medical records. The postoperative residual astigmatism prediction error was calculated . The intended IOL expected by Barrett Toric calculator were mathematically inserted after the actual one was mathematically taken out . The “back-calculation” was conducted to produce the second postoperative residual astigmatism values and the prediction error between the two calculators was compared.

**Results:** 70 eyes from 56 patients were included .The centroid of the prediction errors were  $0.3 \text{ D @ } 178^\circ \pm 0.61 \text{ D}$  ,  $0.11 \text{ D @ } 102^\circ \pm 0.68 \text{ D}$  ( $P=0.365$ ) for Alcon Toric calculator with TCRP and Barrett Toric calculator with standard keratometry respectively . The mean absolute refractive prediction error were  $0.6 \pm 0.32\text{D}$ ,  $0.59 \pm 0.35\text{D}$  respectively ( $p=0.406$ ) .The centroid of the prediction errors within with-the-rule (WTR) subgroup were  $0.34 \times 176^\circ \pm 0.64$  for Alcon Toric calculator and  $0.1 \times 77^\circ \pm 0.76$  for Barrett Toric calculator ( $P=0.022$ ) .

**Conclusion:** In the total group , the Alcon Toric calculator with TCRP 4.0 mm readings had similar accuracy with Barrett Toric calculator with standard keratometry .But in the WTR subgroup ,the Barrett Toric calculator was more accurate . In all groups the Alcon Toric calculator with TCRP 4.0 mm readings tend to result in against-the-rule astigmatism .



PP-058

## Tear Film Instability Affects Preoperative Corneal Refractive Power Measurement and IOL Calculation for Cataract Surgery

X Bai, Y Jiang, H Wang, S Bu, S Lin, F Tian, H Zhang.

**Objective:** To evaluate the impact of tear film stability on corneal refractive power measurement and preoperative intraocular lens (IOL) power calculation for cataract surgery.

**Methods:** Preoperative cataract patients were enrolled in this prospective case-control study. Based on the results of OCULUS Keratograph 5M (K5M), subjects with a tear film stability classification of Level 2 were included in the study group and those with Level 0-1 were included in the control group. Two valid measurements were performed using the IOL Master 700, Pentacam HR and iTrace, respectively, at a 10-min interval. The keratometric corneal refractive power (Kf, Ks and simK), keratometric corneal astigmatism (KCA), total corneal refractive power (TKf, TKs and TK) and total corneal astigmatism (TCA) were recorded. The results of the two biometry measurements measured by IOL master 700 were substituted into the SRK-T, SRK-T TK, Haigis, Haigis TK, Barrett Universal II and Barrett Universal II TK formulas, respectively, to calculate the IOL power. The absolute value of the difference between the two measurements or between the two IOL power calculation results was considered as the degree of variation ( $\Delta$ ). The differences of variability between the two groups were compared, and the agreements between the two measurements and calculations were evaluated.

**Results:** The median values of  $\Delta$ Kf,  $\Delta$ KCA,  $\Delta$ TKf, and  $\Delta$ TK measured by IOL master 700 were significantly higher in the study group (all  $P < 0.05$ ). The difference in variability between the two groups was not significant when measured either with Pentacam HR or iTrace. When measured with the master 700, the Bland-Altman analysis showed that the 95% limits of agreement (95%LoA) were significantly wider for the study group than for the control group. In contrast, the 95% LoAs for both groups were wide when measured by Pentacam HR and iTrace, and showed no significant difference between groups. When the SRK-T formula was used to calculate the IOL power, the variability was significantly higher in the study group than in the control group ( $P < 0.05$ ), whereas there was no significant difference between the two groups when other formulas were used.

**Conclusion:** Tear film instability can cause errors in the measurement of preoperative corneal refractive power and corneal astigmatism, especially for the equipment relied on the reflecting of the anterior corneal surface. Dry eye may increase the prediction error of the SRK-T formula for IOL power calculation.

## PP-061

**Combination of femtosecond laser and piggyback MIOL implantation applied in patients with super-high myopia complicated cataract**

W Luo<sup>1</sup>, S Hu<sup>2</sup>, L zhu<sup>3</sup>, Y wang<sup>2</sup>, Z zhang<sup>4</sup>.

<sup>1</sup>Ophthalmology, Yangtze University Health Science Center, Jingzhou, <sup>2</sup>Ophthalmology, Aier Eye Hospital of Wuhan University, Wuhan, <sup>3</sup>Orthopedics, The First People's Hospital Affiliated of Yangtze University, <sup>4</sup>Ophthalmology, Jingzhou First People's Hospital, The First Affiliated Hospital of Yangtze University,, Jingzhou, People's Republic of China

**Objective:** The study aims to observe the clinical effect of the combination of femtosecond laser and piggyback multifocal intraocular lens (IOL) implantation applied in patients with super-high myopia complicated with cataract.

**Methods:** This is a prospective controlled study. We compared the 32patients (32eyes) who underwent femtosecond laser-assisted cataract + piggyback IOLs implantation(two IOLs were implanted into the capsule) with 32 patients (32eyes) who also underwent femtosecond laser-assisted cataract surgery (one IOL implanted into the capsule) due to super-high myopia complicated with cataract in Wuhan Aier Eye Expert Hospital between January 2019 and October 2020. All patients were followed up with for three months after surgery.The observation indexes was uncorrected distant visual acuity, uncorrected intermediate visual acuity (UCIVA), uncorrected near visual acuity (UCNVA), best corrected distant visual acuity, distance-corrected intermediate visual acuity (DCIVA), distance-corrected near visual acuity (DCNVA), postoperative spectacle independence, postoperative visual interference, equivalent spherical lens, defocus curve, IOL tilt, and IOL eccentricity were observed and compared.

**Results:** Three months after operation, the UCIVA, UCNVA, DCIVA, and DCNVA were  $0.49 \pm 0.07$ ,  $0.38 \pm 0.15$ ,  $0.47 \pm 0.09$ , and  $0.36 \pm 0.12$  in the research group respectively, and  $0.56 \pm 0.18$ ,  $0.72 \pm 0.22$ ,  $0.55 \pm 0.13$ , and  $0.69 \pm 0.15$  in the control group respectively; the differences between the two groups were statistically significant ( $P < 0.05$ ). The spectacle independent rate was higher in the research group (93%) than in the control group (13%). The overall satisfaction regarding postoperative visual quality was also higher in the research group than that in the control group. The absolute mean value of spherical equivalents was  $0.48 \pm 0.28$  D in the research group and  $0.62 \pm 0.33$  D in the control group; the difference between the two groups was statistically significant ( $P < 0.05$ ).

**Conclusion:** The combination of femtosecond laser and piggyback multifocal intraocular lens can expand the range of multifocal intraocular lens application, ensure safety and effectiveness of surgery, and satisfy the patients with super-high myopia complicated with cataract who were eager to see both near and far.

**PP-062****To study the efficacy of air descemetopexy in the management of various types of descemet membrane detachment**

S Singh, S singh<sup>1</sup>.

<sup>1</sup>*ophthalmology, MLN medical college , Prayagraj, India*

**Objective:** To study the efficacy of air descemetopexy in the management of various types of descemet membrane detachment (DMD) and to know the role of other gases Perfluoropropane (14% C3F8) and sulphur hexafluoride (20% SF6) in failed cases of air descemetopexy.

**Methods:** After ethical committee approval, clinical data of 40 patients during the period of December 2017 to December 2018, who developed DMD after cataract surgery were analysed.

**Results:** Majority of patients (n= 32, 80%) had severe generalized corneal edema, n = 4 had moderated corneal edema & n = 4 had localized mild corneal edema. Only air was sufficient to reattach DMD in majority of the patients (n=36, 90% cases), only 4 patients who had very large dmd failed to attach by air. In these patients repeat descemetopexy by 14% C3F8 gas was done which lead to attachment of descemet membrane with improvement of visual acuity in 3 cases. Complications due to increase intraocular pressure were noted with these gases.

**Conclusion:** Air descemetopexy is a safe & efficacious option for DMD repair in most of the cases and it is associated with less postop complications.

## PP-063

**Influence of Ocular Biometry Parameters on the Predictive Accuracy of IOL Calculation Formulas in High Myopic Cataract Patients**

A Miao<sup>1</sup>, P Lin<sup>1</sup>, S Ren<sup>2</sup>, D Qian<sup>1</sup>, Y Lu<sup>1</sup>, T Zheng<sup>1</sup>.

<sup>1</sup>Eye and ENT Hospital of Fudan University, <sup>2</sup>Fudan University, Shanghai, People's Republic of China

**Objective:** To investigate the influence of ocular biometry parameters on the predictive accuracy of IOL calculation formulas in cataract patients with high myopia (HM).

**Methods:** We analysed 202 eyes of 202 patients in this prospective cohort study. According to the axial length (AL), the eyes were divided into HM group (AL  $\geq$  26.50; N = 108) and non-HM group (AL < 26.50 mm; N = 94). Ocular biometry was measured before surgery, using a Pentacam HR for the Q value, a Tomey EM-3000 for the central corneal thickness (CCT), and an IOLMaster 700 for the AL, keratometry (K), white-to-white (WTW), anterior chamber depth (ACD), and lens thickness (LT). The predicted refraction was calculated using 11 formulas: Barrett Universal II (BU-II), EVO, Haigis, Holladay 2, Hoffer QST, Kane, K6, Olsen, SRK/T, T2, and VRF. The relationship between the ocular biometry parameters and the PE one month postoperatively was assessed by multiple linear regression. The mean absolute PE (MAE) and median absolute PE (MedAE) were also calculated.

**Results:** In HM group, the MAE of the K6, EVO, Olsen, and BU-II formulas (0.409, 0.394, 0.422, and 0.466 D, respectively) was significantly lower than that of the Haigis, Holladay 2, Hoffer QST, Kane, SRK/T, T2, and VRF formulas (0.534, 0.793, 0.549, 0.511, 0.548, and 0.672 D, respectively). Meanwhile, The PE of the K6, EVO, Olsen, and BU-II formulas had no association with the biometry parameters (all P > 0.05). For the other 7 formulas, a longer AL was associated with a myopic outcome (for Hoffer QST, Kane, and VRF), or a hyperopic outcome (for Haigis, Holladay 2, SRK/T, and T2). The hyperopic shift of the IOL power calculation in HM eyes was associated with greater K (for VRF, T2, and Holladay 2), smaller WTW (for Haigis), deeper ACD (for Kane, Hoffer QST, T2, and Holladay 2), and larger LT (for Hoffer QST, T2, and Holladay 2), respectively (all P < 0.05). Neither CCT nor Q value was associated to the PE for each formula used in high myopes (all P > 0.05). In non-HM group, no difference in the MAE was detected among each formula (all P > 0.05). The associations between the biometry parameters and the PE in HM eyes did not exist in non-HM eyes (all P > 0.05).

**Conclusion:** In high myopes, the accuracy of K6, EVO, Olsen, and BU-II was not influenced by the biometry parameters and was better than that of the other seven formulas, which was influenced by biometry parameters including K, WTW, ACD, LT, and AL.

PP-065

**Observation of Binocular Visual Quality after Unilateral Monofocal and Contralateral Implanted with Different Types of Multifocal**F Zhang<sup>1</sup>, L Wu<sup>1</sup>.<sup>1</sup>Aier Eye Hospital, Chengdu, China, Chengdu, China

**Objective:** The clinical outcomes of unilateral monofocal intraocular lens (IOL), contralateral implanted multifocal IOL (SBL-3/SN6AD1), and binocular monofocal IOLs were compared.

**Methods:** Sixty senile cataract patients underwent phacoemulsification and IOL implantation at Chengdu Aier Eye Hospital. All patients were divided into three groups: monofocal IOL implanted in dominant eye and SBL-3/SN6AD1 multifocal IOL implanted in non-dominant eye (group A: 36 eyes; group B: 38 eyes); both eyes were implanted monofocal IOL (control group: 46 eyes). Three months after operation, the results of binocular vision and visual quality of the three groups were evaluated and compared.

**Results:** Three months after surgery, there was no significant difference in the uncorrected and corrected distant visual acuity among the three groups ( $P > 0.05$ ). The uncorrected and corrected intermediate and uncorrected near visual acuity of both groups A and B were significantly better than those of the control group, and the difference was statistically significant ( $P < 0.05$ ). The scores of Catquest 9SF-CN scale showed that both groups A and B were more satisfied than the control group ( $P < 0.05$ ). The rate of lens removal of groups A and B were significantly higher than those of the control group, and group B was higher than group A with statistical significance ( $P < 0.05$ ).

**Conclusion:** Patients with monofocal implanted on one side and SBL-3/SN6AD1 multifocal lens implanted on the opposite side can obtain better full-range visual acuity than binocular monofocal IOL, less postoperative adverse visual symptoms, and higher patient disengagement rate and satisfaction.

PP-067

## Lid Scrub And Thermal Pulsation Treatment To Improve Tears Film Quality And Biometry Accuracy To Adopt Presbyopic Iols Routinely

B Kusa, M Piovella<sup>1</sup>.

<sup>1</sup>*Piovella Global Center For Ophthalmology, Piovella Global Center For Ophthalmology, MONZA, Italy*

**Objective:** To evaluate two systems Blephex for Lid Scrub(Alcon – Fort Worth Texas) and LipiFlow (J&J - Santa Ana Ca) for the thermal pulsation treatment of Meibomian Gland Dysfunction(MGD) to improve quality of the surface of the cornea to get better IOLs power biometry calculations

**Methods:** Since 2017, 378 patients (mean age  $66.58 \pm 11.55$  years) were treated for MGD. Patients received a LipiFlow treatment to remove obstructions and restore meibomian gland function. 123 of these patients received also Blephex treatment immediately before since September 2019.

**Results:** Postop quality of vision improved in all patients, and regular cornea surface provided more precise and stable biometry results. The adoption of lipiflow and blephex treatments provided 97% of eyes inside the planned refractive postoperative outcome.

**Conclusion:** These treatments have a priority role in adopting implants to correct refractive defects and treat presbyopia in cataract patients.

PP-069

**Application of Excel VBA in Cross-sectional Survey of Cataract Surgery Quality**C Liu<sup>1</sup>, H Bi<sup>1</sup>, D Liu<sup>1</sup>, C Li<sup>1</sup>, Y Li<sup>1</sup>.<sup>1</sup>*Affiliated Eye Hospital of Shandong University of Traditional Chinese Medicine, Jinan City, P.R.China, People's Republic of China*

**Objective:** To explore the application of Excel VBA in the cross-sectional survey of cataract surgery quality, so as to carry out the quality control of cataract surgery through information means.

**Methods:** In this study, the statistical items and their domain values were determined according to the clinical pathway diagnosis and treatment specifications of cataract. By compiling Excel VBA code, the cross-sectional survey software of cataract surgery quality based on Excel VBA was independently developed by medical personnel. Using this software, the medical records of 368 patients with simple cataract who underwent surgery in the Affiliated Eye Hospital of Shandong University of Traditional Chinese Medicine in May 2020 were investigated. Combined with Excel PivotTable, the postoperative visual acuity, the incidence of intraoperative and postoperative complications and the implementation of diagnosis and treatment norms were analyzed.

**Results:** In this program designed by using VBA language, the field values of survey items are automatically formed into multiple options and automatically saved in the questionnaire. The survey content is standardized and the interface is easy to operate. The index items can be quickly counted by using Excel pivot table, which improves the efficiency and accuracy of statistics.

**Conclusion:** The independent development and application of the survey software improves the work efficiency and management ability of the quality management team, lays a foundation for the management of single disease in the hospital, and also provides a new idea for the development of disease quality control management tools.

## PP-070

**Energy efficiency and intraocular safety comparisons of two torsional phacoemulsification tips**

Y Sun<sup>1,2</sup>, R Cao<sup>2</sup>, Z Liu<sup>1</sup>, H Xia<sup>1</sup>, Y Cen<sup>1</sup>, L Gao<sup>2</sup>.

<sup>1</sup>Ophthalmology, Peking University Third Hospital, Beijing, <sup>2</sup>Ophthalmology, Peking University Third Hospital Yan-an Hospital, Yan-An, People's Republic of China

**Objective:** During cataract phacoemulsification surgery, an Intrepid® balanced (IB) tip can achieve a larger amplitude, which may lead to higher energy efficiency than a Kelman (K) tip when paired with a torsional phaco platform. In this retrospective cohort study, we compared their energy efficiency and damage to the cornea under a new energy setting.

**Methods:** The medical records of 104 eyes of 79 patients were reviewed, with 47 eyes belonging to the IB group and 57 eyes to the K group. All surgeries were performed on an Alcon Centurion® platform with gravity infiltration. Surgical parameters, visual outcome, central corneal thickness (CCT) changes, and endothelial cell density (ECD) loss rate were recorded and calculated.

**Results:** No significant differences in postoperative best corrected visual acuity (BCVA), intraocular pressure (IOP), total ultrasound time, estimated fluid aspirated, CCT changes, or ECD loss rate were observed between the two groups. We divided the included eyes into soft nucleus and hard nucleus subgroups and found lower cumulative dissipated energy (CDE,  $8.15 \pm 8.02$  vs  $14.82 \pm 14.16$ ,  $P=0.023$ ), cumulative torsional energy (CTE,  $8.06 \pm 7.87$  vs  $14.13 \pm 13.02$ ,  $P=0.027$ ), and cumulative longitudinal energy (CLE,  $0.09 \pm 0.17$  vs  $0.69 \pm 1.37$ ,  $P=0.017$ ) in the IB group than in the K group, implying less energy used and higher energy efficiency of the IB tip.

**Conclusion:** Lower CLE in the IB group indicates fewer phaco tip obstructions and a higher capability to conquer hard nuclei with IB tips with statistical significance. With an ultra-perfusion cannula, the balanced tip does not cause more corneal damage.



## PP-071

## The use of different surgical approaches and OVDs in cataract surgery has an impact on intraoperative intraocular pressure

A Alani<sup>1,2</sup>, W Sekundo<sup>3</sup>, D Handzel<sup>1</sup>.

<sup>1</sup>Augenärzte im Altstadt-Carree, <sup>2</sup>MVG GmbH, Fulda, <sup>3</sup>Ophthalmology, University Eye Hospital, Marburg, Germany

**Objective:** The use of different ophthalmosurgical viscoelastic devices (OVD), different instruments and techniques facilitates to take individual characteristics and requirements of the eye into account during cataract surgery. While creating the capsulorhexis a controlled execution determines the further course and the success of the procedure significantly.

This study investigated the influence of different OVD and different instruments on the intraocular pressure (IOP) prior and after the creation of the capsulorhexis as a parameter of a stable situation in the anterior chamber.

**Methods:** This is an prospective experimental study investigating the IOP during cataract surgery before and after the creation of the capsulorhexis.

Surgery was carried out on enucleated porcine eyes. Surgical steps matched exactly those in a routine cataract surgery on a human eye. IOP was measured before and after the creation of the capsulorhexis using the iCare-Rebound-Tonometer.

The study investigated cohesive and dispersive OVD and the use of Utrata forceps and 23g-microforceps.

**Results:** The use of the Utrata forceps using the main incision generated a drop in IOP from the beginning to the end of the capsulorhexis from 65,5mmHg (SD ± 5,87) to 12,5 (SD ± 2,54) using hyaluronic acid and from 61,8mmHg (SD ± 6,74) to 10 (SD ± 4,32) using hydroxy propylmethylcellulose.

The use of 23g-microforceps using the sideport incision generated a drop in IOP from the beginning to the end of the capsulorhexis from 64,3mmHg (SD ± 6,78) to 35,8 (SD ± 4,84) using hyaluronic acid and from 66,4 mmHg (SD ± 9,59) to 37,3 (SD ± 7,33) using hydroxy propylmethylcellulose.

**Conclusion:** The use of different OVD showed no significant differences in respect to a drop of IOP during the capsulorhexis. The use of different instruments and different incisions showed a significant difference.

After the creation of the capsulorhexis using the 23g-microforceps a higher IOP was measured compared to the use of the Utrata forceps. This can be advantageous in difficult situations like elevated vitreous pressure or elevated intracapsular pressure.

**PP-072****Safety and Efficacy of Plasmin in the Prevention of Posterior Capsular Opacification**

X Bai<sup>1</sup>, S Bu.

<sup>1</sup>Tianjin Medical University Eye Hospital, Tianjin, People's Republic of China

**Objective:** To evaluate the efficiency and safety of plasmin on the prevention of posterior capsular opacification (PCO).

**Methods:** Forty patients (18 males, 22 females, age:  $71.3 \pm 9$  49-86 years old, without other ocular diseases) who underwent phacoemulsification were included in this study. 41 anterior capsule samples were obtained during the operation. They were randomly divided into control group, experimental group 1 (0.01% mg/mL plasmin group) and experimental group 2 (0.001% mg/mL plasmin group). The anterior capsule membrane was digested for 5min in experimental groups 1 and 2, while the capsule in the control group was rinsed in PBS. DAPI staining was used for fluorescence microscope imaging. The numbers of residual LECs on the anterior capsule were counted using ImageJ software. Four rabbits were randomly divided into the control group and the experimental group. After lens removal using phacoemulsification tip, 0.001% mg/mL plasmin was injected into the capsular bag and maintained for 5 minutes. The control group was injected with BBS in the capsular bag for 5 minutes. The corneal clarity, anterior chamber inflammation and the degree of posterior capsular opacity of rabbits at 1 week, 1 month and 2 months were observed and documented by slit lamp.

**Results:** The numbers of residual LECs on the anterior capsule membrane of 0.01% ( $274 \pm 258.6\text{mm}^2$ ) and 0.001% mg/mL ( $168 \pm 190.7/\text{mm}^2$ ) plasmin groups were significantly reduced compared with the control group ( $1012 \pm 798.8\text{mm}^2$ ). ( $P < 0.05$ ). The treatment of plasmin to the capsular bag resulted in a significantly clearer posterior capsule in the plasmin treatment group compared to the control. The cornea clarity and the degree of anterior chamber inflammation remained the same in the treatment group and the control group.

**Conclusion:** Plasmin can prevent PCO by inducing LECs detachment with no obvious adverse effect to the ocular tissue, which could be a promising treatment option for the prevention of PCO

PP-073

**LENTIS Comfort Toric intraocular lens implantation postoperative visual quality analysis**L Wang.

**Objective:** To investigate the visual quality of LENTIS Comfort Toric intraocular lens implanted in cataract surgery.

**Methods:** In retrospective controlled clinical studies, 31 patients (31 eyes) with cataract phacoemulsification and LENTIS Comfort Toric intraocular lens implantation assisted by digital navigation were collected, group A (16 eyes) was implanted with LETTIS Comfort Toric (MF15T), and group B (15 eyes) was implanted with monofocal Torch intraocular lens. Residual astigmatism, de-mirror rate, postoperative 1mo visual quality DLI index, postoperative 3mo out-of-focus curve change, etc.

**Results:** There were no serious complications in both groups, no intraocular lens axial rotation occurred in group A, no statistical difference in naked-eye far vision and optimal corrected far vision in group A and group B after surgery ( $P>0.05$ ), no significant difference in visual acuity and near vision in group A ( $P<0.05$ ), no significant statistical difference in residual astigmatism in group A ( $P>0.05$ ), 98.7% in postoperative de-mirroring in group A and 45% in group B. ( $P<0.05$ ); the postoperative 1mo visual quality DLI index was  $9.37 \pm 0.71$  in group B, and  $8.95 \pm 0.53$  in group B, and there was a statistical difference between the two groups ( $P<0.05$ ); the off-focus curve of the postoperative 3mo A group peaked at 1.0D and -1.0D, forming a platform and decreasing gently, and group B showed a steep trend decline after peaking at 0.25D and -0.25D ( $P<0.05$ ).

**Conclusion:** Compared with the unfocal Torch intraocular lens, LENTIS Comfort Toric intraocular lens can provide personalized choice for cataracts and astigmatism populations, which can solve the astigmatism and obtain full vision at the same time, and the incidence of postoperative optical interference is low, and the visual quality and satisfaction are high, which is worthy of clinical promotion and application.

PP-074

### The Function and Mechanism of GSK-3 $\beta$ -dependent Nrf2 Proteasomal Degradation-mediated Ferroptosis involved in Lens Aging

Y Qin<sup>1</sup>, D Ma<sup>1</sup>, J Liu<sup>1</sup>, X Zhi<sup>1</sup>, L Wang<sup>1</sup>, L Luo<sup>1</sup>.

<sup>1</sup>Department of Ophthalmology, The Fourth Affiliated Hospital of China Medical University, Eye Hospital of China Medical University, Key Lens Research Laboratory of Liaoning Province, Shenyang, People's Republic of China

**Objective:** The investigation intended to explore the role and mechanism of Nrf2 involved in lens aging in a new light of ferroptosis via studying the regulation of GSK-3 $\beta$ -dependent Nrf2 proteasomal degradation.

**Methods:** The characteristic changes of ferroptosis, the expression of Nrf2 and Keap1, the susceptibility towards ferroptosis between Nrf2 knockout mice and wild type littermates, the expression of GSK-3 $\beta$  and  $\beta$ -TrCP, as well as the protein-protein interaction with Nrf2 were detected by TEM, qPCR, WB, Co-IP and FerroOrange respectively in the lens tissue of patients with age-related cataract and aged mice, as well as oxidative stress induced cataract model in mice. The expression of Nrf2 in both cytoplasm and nucleus and the iron level in cytoplasm were detected in oxidative stress induced ferroptosis model in LECs after treated with GSK-3 $\beta$  inhibitor.

**Results:** A significantly reduced mitochondrial number and size, up-regulation of TfR1, and down-regulation of GPX4, Fpn, FTH1, Nrf2 and Keap1 were observed in the lens tissue of patients with age-related cataract and aged mice. An elevated susceptibility to ferroptosis was observed in Nrf2 knockout mice compared to wild type littermates, as well as high expression of GSK-3 $\beta$ ,  $\beta$ -TrCP, and PPI with Nrf2. GSK-3 $\beta$  inhibitor stimulated the stable expression of Nrf2 in both cytoplasm and nucleus, as well as the iron level in cytoplasm in oxidative stress induced ferroptosis model in LECs.

**Conclusion:** In the progression of lens aging, oxidative stress could influence the transcriptional activity of Nrf2 through GSK-3 $\beta$ -dependent Nrf2 proteasomal degradation pathway, give rise to the aberrant transcription of multiple iron metabolism-related genes downstream, induce LECs ferroptosis occurrence, lead to lens aging, and ultimately result in age-related cataract.

PP-075

## Outcomes of a New Method for Calculating IOL Power after Myopic Excimer Laser Correction with Corneal Decentered Ablation

Z Li<sup>1</sup>, C Li<sup>1</sup>.

<sup>1</sup>Department of Ophthalmology, The First Affiliated Hospital of Chongqing Medical University, Chongqing, People's Republic of China

**Objective:** This article is aimed to assess the visual and refractive outcomes of a new method for calculating IOL power after Myopic excimer laser correction with corneal decentered ablation in a 12-month follow-up.

**Methods:** This retrospective case series included cataract patients who had previously underwent myopia excimer laser correction with corneal decentered ablation in 1<sup>st</sup> affiliated hospital of Chongqing Medical University from January 2021 to December 2021, excluding those with other ocular disease might affect visual quality after surgery. The IOL power was calculated through a new method, which take the average curvatures from 3 different parts of cornea (zones centered on pupil center with 3mm, 4mm diameter and zone centered on cornea vertex with 3mm diameter) into formulae or calculators like Barrett True K, SRK(T), EagleCal IOL calculator, FY-L(Post-LASIK) and ASCRS calculator series for calculation. The IOL degree was made as a comprehensive decision when all the results and the decentered ablation have taken into consideration. Follow-up was done at 12-month to assess the visual outcomes. Outcome measures were uncorrected distance, intermediate and near visual acuity (UDVA, UIVA, UNVA), manifest refraction, best corrected visual acuity (BCVA), defocus curve, mean refractive error, mean absolute refractive error (MAE), OSI, MTF-cutoff and aberration.

**Results:** Five eyes (2 eyes with SIOL implanted and 3 eyes with MIOL implanted) from 4 patients, aged from 47 to 57, with the ocular axial length (AL) were 26.044 mm ~32.422 mm (28.429 mm ± 1.166 mm) were included. Mean monocular UDVA, UIVA, UNVA and BCVA (logMAR) at 12-month were -0.02 ± 0.04, 0.06 ± 0.07, 0.10 ± 0.09 and -0.04 ± 0.04 respectively. Mean postoperative spherical equivalent (SE) was -0.375D ± 0.168D. The defocus curve showed extended functional range of visual acuity. The higher order aberration (HO Total), coma, spherical aberration and trefoil were 0.706 ± 0.174 μ, 0.549 ± 0.192 μ, 0.158 ± 0.083 μ and 0.236 ± 0.066 μ respectively.

**Conclusion:** The new method which take curvatures from different parts into multi-formulae calculation has showed inspiring outcomes for cataracts with previous myopic excimer laser corrections and corneal decentered ablation. The decentered ablation has reshaped the cornea into cornea stairs, inducing higher order aberrations possibly, which helps extend the depth of focus and improve visual quality.

PP-076

**Effects of Systemic Probiotic Administration on Lens in Diabetic Rats**S Kivanc, B Akova<sup>1</sup>.<sup>1</sup>Uludag University, Bursa, Türkiye

**Objective:** Diabetes mellitus has long been known to cause cataract formation. In this study our aim was to investigate the effects of systemic probiotics at gene expression level on the crystalline lenses of the diabetic rats.

**Methods:** Twenty-four Sprague Dawley rats were included in the study. The rats were divided into 4 groups as diabetic rats, diabetic rats with probiotic intake, rats with probiotic intake and control group. The diabetes mellitus was induced by streptozocin 20mg/kg. The systemic probiotic used in the study was Lactobacillus rhamnosus312. After 2 months the lenses of the rats were removed. Total RNA isolation from the lens material was performed with total RNA purelinkRNA minikit. The amount of RNA was detected by Qubit fluorometer. The genes used for the study were VEGF, IL-1beta, Aldolaz, NF-KB. This study complies with the guiding principles for experimental procedures found in the Declaration of Helsinki and this research project has been approved by Institutional Review Board (IRB).

**Results:** Cataract formation was evaluated under light microscopy all animals had cataract formation in diabetic rats group. Cataract formation rate was lower in diabetic rats with probiotic intake. The gene expression values of VEGF, NF-KB, Aldolase on crystalline lenses were significantly different among groups.(p=0.029, p<0.001, 0.003 respectively, One Way Anova)

**Conclusion:** Systemic probiotic administration may reduce cataract formation and may have protective effects on lens in diabetic rats.

## PP-077

### Clinical study on capsulotomy enlargement after femtosecond laser treatment among cataract patients of different age groups

? 马.

**Objective:** Larger-than-planned capsulotomy can occur, but its association with age and eye parameters is poorly understood. To assess capsulotomy enlargement after femtosecond laser treatment in cataract surgery and explore the possible relationship between capsulotomy enlargement and the patients' age and eye parameters.

**Methods:** This prospective case series included consecutive patients diagnosed with cataracts between 05/2018 and 11/2019. The patients <18, 18-49, and  $\geq 50$  years of age were assigned to the childhood cataract (CC), young adult cataract (YAC), and age-related cataract (ARC) groups. The capsulotomy enlargement coefficient (CEC), age, degree of cataract, lens thickness (LT), axial length (AXL), and anterior chamber depth (ACD) were collected.

**Results:** A total of 155 participants (179 eyes) were enrolled. The CEC was significantly different among the three groups (CC: 1.245 vs. YAC: 1.060 vs. ARC: 1.029,  $P < 0.001$ ). In the CC group, age ( $\beta = -0.011$  (0.001),  $P < 0.001$ ) and LT ( $\beta = -0.049$  (0.017),  $P = 0.006$ ) were independently associated with the CEC. Only age ( $\beta = -0.004$  (0.001),  $P = 0.002$ ) was independently associated with the CEC in the YAC group. Only LT ( $\beta = -0.014$  (0.007),  $P = 0.048$ ) was independently associated with the CEC in the ARC group.

**Conclusion:** The capsulotomy enlarges after femtosecond laser treatment in cataract surgery, especially in CC. Age was a determinant of the CEC in the CC and YAC groups, while LT was an independent determinant of the CEC in the CC and ARC groups. And they should be taken into consideration for a more precisely sized capsulotomy.

PP-078

**Six-Year Incidence and Postoperative Visual Outcome of Cataract Surgery in Rural Southern China: The Yangxi Eye Study**X Gong, L Deng, Z Yao, X Liang, W Huang.

**Objective:** To investigate the 6-year incidence and visual outcome of cataract surgery in elder population in rural China.

**Methods:** This population-based study included rural residents aged 50 and above in southern China at baseline in 2014. All baseline participants were invited for a 6-year follow-up with comprehensive eye examinations in 2020. Cataract surgery incidence was defined as surgery on either eye during the 6-year period. Postoperative visual impairment (PVI) was defined as presenting visual acuity (PVA) < 20/63 in the better-seeing eye.

**Results:** Three thousand one hundred and forty-one (64.9%) of 4,839 eligible survivors attended the 6-year follow-up examination, and 3,065 participants without previous binocular cataract surgery were eligible for analysis. Their mean age was  $64.9 \pm 9.0$  at baseline. The overall 6-year incidence of any cataract surgery was 273 of 3,065 patients (8.9% [95% confidence interval 7.9%-10.0%]). Compared with those with baseline PVA <20/63 due to cataract but had not had surgery, participants undergoing incident cataract surgery were younger ( $70.1 \pm 8.1$  vs.  $74.1 \pm 8.2$ ), more likely to be male (48.0% vs. 32.1%) and had worse baseline PVA in the worse-seeing eye (all,  $P < 0.05$ ). Among the 341 operated eyes, 71.0% (242/341) had BCVA  $\geq 20/63$  after surgery. However, 187 of 274 with incident cataract surgery (68.5%) persons had PVI mainly due to untreated cataracts in the other eye (19, 21.1%), posterior capsule opacification (15, 16.7%), refractive error (8, 9.9%) or other diseases.

**Conclusion:** The 6-year cataract surgery incidence in elder population in rural China had improved but was still lower than that in developed countries, especially in the female and elder groups, suggesting substantial unmet needs in cataract population as well as gender and age inequality. Most patients undergoing surgery still suffered from PVI due to a lack of postoperative visual care or untreated cataracts in the non-operative eye.



**PP-081****The optical quality of an extended depth of focus intraocular lens implanted with micro-monovision approach**

X Tan.

**Objective:** To evaluate the optical quality and performance of an extended depth of focus (EDOF) intraocular lens (IOL) implanted with micro-monovision approach.

**Methods:** This case series enrolling a total of 38 eyes of 19 patients who had bilateral implantation of Tecnis Symphony with micro-monovision. Near, intermediate, and distance visual acuities, defocus curve, contrast sensitivity (CS) and National Eye Institute Visual Functioning Questionnaire-14 for Chinese people (VF-14-CN) were evaluated during a 1-month follow-up.

**Results:** Mean postoperative binocular UDVA, UIVA and UNVA were  $-0.07 \pm 0.09$ ,  $-0.02 \pm 0.08$  and  $0.15 \pm 0.10$  logMAR, respectively. The binocular UDVA was maintained on average over a value of 0.30 logMAR for the range of defocus levels between +1.00 and -3.00 D. There was no significant difference between the dominant eye and non-dominant eye in monocular VAs and CS values and CS values were within the normal range for both eyes. The final score of the VF-14-CN were 93.42. Ten (53%) and fifteen subjects (79%) had a final score of  $\geq 95$  and  $\geq 90$ , respectively.

**Conclusion:** The implantation of the Symphony EDOF IOL after cataract surgery seems to provide functional levels of distance, intermediate and near visual acuity. The near visual performance with this IOL might be significantly enhanced using a micro-monovision approach.

PP-083

### Effective of Capsule Protection Technique in Femtosecond Laser-Assisted Cataract Surgery in Patients with Abnormal Corneal Endothelium

R Ju.

**Objective:** To evaluate the effectiveness of capsule protection technique in femtosecond laser-assisted cataract surgery in patients with abnormal corneal endothelial cells.

**Methods:** A retrospective review of patients with abnormal corneal endothelial cells who underwent femtosecond laser-assisted phacoemulsification with intraocular lens (IOL) implantation was conducted. During the procedure, capsule protection technique was used by an isolated capsulorhexis flap lifted it up carefully with OVD until the capsule flap attached to the corneal inner layer. It kept steady during the phaco phase, and been removed by I/A tip after intraocular lens implantation. Patient baseline characteristics, levels of nuclear cataract, pre-operative specular microscopic parameters, intraoperative information (cumulative dissipated energy [CDE], mode of phacoemulsification, and complications), and central corneal thickness, corneal light backscatter, corneal densitometry, and central corneal endothelial cell count and hexagonality (noncontact endothelial cell microscope), and corrected distance visual acuity (CDVA) were assessed preoperatively and at day 1, 30, and 180 postoperatively.

**Results:** Totally 17 patients (9 women) were included. There was no complications during the surgery. The corrected distance visual acuity improved from  $0.51 \pm 0.32$  logMAR preoperatively to  $0.32 \pm 0.48$  logMAR and  $0.24 \pm 0.31$  after 30 days and 180 days postoperatively. The mean preoperative CCT was  $562 \pm 73 \mu\text{m}$  and  $578 \pm 21 \mu\text{m}$  and  $557 \pm 68 \mu\text{m}$  at 30 days and 180 days after surgery respectively. The mean ECD was  $1184 \pm 378$  cells/ $\text{mm}^2$ ,  $798 \pm 203$  cells/ $\text{mm}^2$  and  $803 \pm 204$  cells/ $\text{mm}^2$ , respectively. One eye suffered from corneal decompensation.

**Conclusion:** Capsule protection technique was an safe and effective approach to protect the endothelial cell and has a low risk of corneal decompensation in patients with abnormal corneal endothelial cells.

PP-084

**Use of Capsular Tension Ring in Phacoemulsification in different degrees of subluxated lens: Modified Technique.**

S Singh, S Singh<sup>1</sup>.

<sup>1</sup>*ophthalmology, MLN MEDICAL COLLEGE, Prayagraj, India*

**Objective:** To ease difficulty encounter during routine procedure and to prevent further intraoperative complications and making surgery smooth and safe certain modification has been made.

**Methods:** It was a prospective, interventional consecutive case series of 29 eyes of 29 patients.

**Results:** Total 29 eyes of 29 patients were included in the study. Patients ranged from 13 to 60 years of age, with maximum patients in age group 30- 40 years. In 22 patients, subluxation ranged from 30 - 180 degrees and in rest 7 patients subluxation was more than 180 degrees. Four types of CTR were used, standard CTR in 12 patients, Cionni(model 1R) in 7 patients, Cionni (model 1L) in 3 patients and Cionni(model 2L) in 6 patients.

**Conclusion:** With our modified technique of implantation of endocapsular ring in the bag it can be smoothly implanted in almost all cases without stress to the zonules and capsular tear. The modification allows easy passing and feeding of bent curve 26 gauze needle, avoiding any damage to capsule.

PP-086

**Treatment Outcomes of Post Cataract Surgery Endophthalmitis in Kingdom of Bahrain**H Alaali<sup>1</sup>.<sup>1</sup>*Ophthalmology, Salmaniya Medical Complex, Manama, Bahrain*

**Objective:** Endophthalmitis after cataract surgery is an uncommon but extremely feared and devastating complication, which requires prompt recognition and appropriate treatment in order to prevent a poor visual outcome. This study was conducted to evaluate the incidence, clinical features, causative organisms, and the final visual outcomes associated with endophthalmitis post cataract surgery.

**Methods:** This is a retrospective study of all eyes with endophthalmitis within 6 weeks of cataract surgery between January 1, 2014 till December 31, 2018, and with at least 3 months follow-up.

**Results:** The 5-year incidence of acute-onset endophthalmitis after cataract surgery was 293.9 per 100,000 (0.29%): 263.5 per 100,000 (0.26%) for phacoemulsification and 545 (0.54%) for ECCE (P= 0.294). The main presenting features were pain (100%), corneal edema (90%) and vitritis (90%). The culture reports showed 2 cases of *Staphylococcus epidermidis*, 2 cases of *Streptococcus* species, 1 case of *Candida*, 1 case of *Enterococcus*, and 1 case of gram-negative bacilli. Of the 10 patients, 2 (20%) had a final best corrected visual acuity (BCVA) of 20/200 or better, 3 (30%) had visual acuity of counting fingers, 3 (30%) had a final BCVA of light perception and 2 (20%) had a final BCVA of NPL.

**Conclusion:** The final visual outcomes of post cataract surgery endophthalmitis are generally poor and only 20% of the eyes achieved a BCVA  $\geq$  20/200. Prevention and care of post cataract endophthalmitis play a key role in the prevention and treatment of blindness.

PP-087

**The relationship among intraocular lens weight, IOP and PCO-- patients in prone position after vitreous combined cataract surgery**

X Luo, D *xue*, Y *Zhang*.

**Objective:** To analyze the effect of intraocular lens weight on intraocular pressure and posterior capsular opacification(PCO)in patients after vitreous cataract surgery (need to maintain prone position)

**Methods:** 113 patients (need to maintain prone position) who underwent combined vitreous cataract surgery in our hospital from January 2021 to December 2021 were divided into four groups according to the type and weight of intraocular lens used. The incidence of postoperative high intraocular pressure and PCO rate were analyzed.

**Results:** Intraocular lens weight was positively correlated with postoperative high intraocular pressure, but there was no statistical significance. It is negatively correlated with the occurrence of PCO and has statistical significance

**Conclusion:** For patients undergoing vitreous cataract surgery, the weight of intraocular lens may be related to postoperative intraocular pressure and the occurrence of PCO, which has been neglected in the past.

PP-088

**Chondroitin Sulfate-Hyaluronic Acid Ophthalmic Viscosurgical Devices for Corneal Protection in Cataract Surgery: A Meta-Analysis**B D Ayres<sup>1</sup>, J Pan<sup>2</sup>, H Cheng<sup>2</sup>, R Ghafouri<sup>3</sup>, N Ferko<sup>3</sup>.<sup>1</sup>Thomas Jefferson University Hospital, Philadelphia, <sup>2</sup>Alcon, Fort Worth, United States, <sup>3</sup>EVERSANA, Burlington, Canada

**Objective:** Ophthalmic viscosurgical devices (OVDs) are well-established for use during cataract surgery to minimize surgical trauma and help protect the corneal endothelium. A systematic literature review and meta-analysis were conducted to assess the clinical evidence of OVDs composed of chondroitin sulfate-hyaluronic acid (CS-HA) versus other OVDs in minimizing endothelial cell loss (ECL) and corneal thickness (CT) increase.

**Methods:** The literature was searched systematically in MEDLINE and EMBASE databases, from 2000 to 2020. Randomized controlled trials (RCTs, N ≥ 20 per group) comparing an OVD containing CS-HA (ie, VISCOAT®, DuoVisc® or DisCoVisc®) to other any other OVD were included. Non-comparative studies and pre-clinical evidence were excluded. Identified comparators consisted of OVDs composed of HA-only or hydroxypropyl methylcellulose (HPMC). Outcomes of focus included ECL from baseline to 3 months and CT increase from baseline to 24 hours (12 studies included, 5 studies reported both ECL and CT). Meta-analyses were performed using R software, to assess mean differences (MD) in ECL and CT change between CS-HA OVDs and HA-only or HPMC OVDs.

**Results:** A total of 966 abstracts were screened and data were extracted from 12 RCTs. Meta-analyses using a random-effects model revealed significantly lower percent (%) ECL for CS-HA OVDs compared to both HA-only (MD: -4.10%; 95% CI: -5.81 to -2.40; p < 0.0001; 9 studies) and HPMC (MD: -6.47%; 95% CI: -10.41 to -2.52; p = 0.001; 2 studies) products. Similarly, % CT change was significantly lower with CS-HA than with HA-only OVDs (MD: -3.22%; 95% CI: -6.24% to -0.20%; p = 0.04; 4 studies). There were no significant differences when comparing % CT change between CS-HA and HPMC OVDs (MD: 2.65%; 95% CI: -0.43% to 0.95%; p = 0.4; 2 studies).

**Conclusion:** OVDs composed of CS-HA lead to less postoperative loss of endothelial cells relative to other OVDs, thus may be a preferable option for protection of the corneal endothelium during cataract surgery. Further studies assessing outcomes at multiple time-points may be needed to solidify these observed trends.

PP-089

### Comparison of corneal endothelial cell loss in femtosecond laser-assisted cataract surgery and conventional phacoemulsification

A Altansukh<sup>1</sup>, K Ma<sup>2</sup>, H Hung<sup>3</sup>, D Adiyabazar<sup>4</sup>, E Kang<sup>3</sup>, D Ma<sup>3</sup>.

<sup>1</sup>Department of Ophthalmology, Health Center of Bayangol District, Ulaanbaatar, Mongolia, <sup>2</sup>Department of Medicine, Catholic University of the Sacred Heart Rome, Roma, Italy, <sup>3</sup>Department of Ophthalmology, Chang Gung Memorial Hospital, Taipei, Taiwan, China, <sup>4</sup>Department of Ophthalmology, Gegeen Melmii Eye Hospital, Ulaanbaatar, Mongolia

**Objective:** In the past few years, the benefit of femtosecond laser-assisted cataract surgery in reducing corneal endothelial damage has been extensively studied. However, almost all of the studies were focused on changes in the central cornea. This study aims to compare changes in corneal endothelial cells in different part of the cornea following femtosecond laser-assisted or conventional phacoemulsification (phaco).

**Methods:** This is a single center, retrospective study. Methods Patients who received femtosecond laser-assisted (Alcon LenSx System) or conventional phaco (Alcon Infiniti System) from 2018 and 2021 were recruited. Before and 6 M after OP, patients were examined by a NIDEK CEM-530 specular microscope, which allowed simultaneous measurement of endothelial density at different parts of the cornea. The electronic medical records were reviewed, and following data were retrieved: 1. Total phaco energy. 2. Total phaco time. 3. Pre-OP and post-OP 6 M corneal endothelial density at central cornea (position 1), nearest (position 2), and farthest from entrance wound (position 3). Changes expressed as percentage of the original density were compared. Independent sample t-test, and Mann-Whitney test were used for data comparison.

**Results:** 46 eyes from 41 patients receiving LenSx, and 65 eyes from 60 patients receiving phaco were enrolled. The mean age was  $61.8 \pm 14.0$  and  $64.2 \pm 12.0$  y/o respectively ( $p=0.212$ ). The total phaco energy and time was significantly lower in the LenSx group ( $17.7 \pm 13.9$  vs  $23.0 \pm 10.7$  CDE,  $p=0.001$ ;  $50.87 \pm 18.3$  vs  $73.1 \pm 37.6$  sec,  $p=0.001$ ). At post-Op 1 month, changes in endothelial density in position 1, is  $-2.16\%$  vs  $-3.97\%$ , ( $p=0.447$ ) and at post-Op 6 month,  $-0.13\%$  vs  $-2.7\%$  ( $p=0.093$ ). At post-Op 1 month, changes in endothelial density in position 3, is  $-4.1\%$  vs  $-2.5\%$ , ( $p=0.7$ ) and at post-Op 6 month,  $1.73\%$  vs  $-2.36\%$  ( $p=0.036$ )

**Conclusion:** Compared with conventional phaco, LenSx required significantly less phaco energy and time to complete the surgery, and caused less endothelial cell loss. Of note, despite the fact that endothelial cell loss rate in both the LenSx and phaco group at position 2 was much higher than position 1 and 3, less endothelial loss was found in the LenSx group, suggesting that compared with entrance wound formation by knife, wound formation by the laser did not cause further damage to corneal endothelium. For the position 3, endothelial damage is significantly lower in LenSx group at post-Op 3 and 6 month.

PP-090

**Advantages of 3D Visualization Systems for Teaching in Ophthalmology**D O'Boyle<sup>1</sup>, R Ghafouri<sup>2</sup>, K Thomas<sup>2</sup>.<sup>1</sup>Alcon, Enniscrone, Ireland, <sup>2</sup>EVERSANA, Burlington, Canada

**Objective:** Trainee ophthalmic surgeons are often impacted by the difficulty in obtaining the best operative view. Visualization and depth perception are critical in surgical teaching, but with conventional microscopes the surgeon looks through binoculars of the scope, while trainees observe through a secondary monitor, lacking the same resolution or light output as the microscope. A literature review was conducted to understand benefits of 3D visualization systems for teaching and education in ophthalmic surgery.

**Methods:** MEDLINE was searched without language restriction from Jan-01-2001 to Sept-30-2021 using terms related to ophthalmology (eg, ophthalmic, eye surgery, cataract) combined with terms related to a digital device (eg, 3D visualization, heads-up, digitally-assisted) and teaching outcomes (eg, education, teaching, learning curve). Reference lists from relevant articles were also scanned.

**Results:** Of 445 sources screened, 11 studies evaluating the utility of 3D visualization systems for education in ophthalmology were identified, all of which noted a benefit for surgical training with the use of a 3D display. Four surveys comparing surgeon preferences for 3D displays versus conventional microscopes (CM) reported that the majority of surgeons (69%-100%) expressed greater preference and higher satisfaction scores for 3D visualization, with educational advantages noted as a key benefit. A randomized controlled trial found that the 3D group had a significantly higher rating of satisfaction for use during cataract surgery than the CM group ( $P<0.001$ ) across several parameters, including educational value. In an evaluation of macular hole surgeries by trainee surgeons, closure rate was significantly higher ( $P<0.004$ ) when trainees used 3D displays than with CM, with viewing technique being the only significant variable between the groups. While recently, 3D visualization has been used with high satisfaction for telementoring and live training in corneal surgery. Overall, studies noted that 3D platforms provide excellent trainee and staff viewing and should be an integral component in trainee education.

**Conclusion:** The current body of evidence demonstrates that 3D visualization systems can provide considerable advantages for teaching and education when compared with conventional microscopes. The 3D digital display allows the surgeon to share the surgical experience with trainees, thus augmenting educational impact. Future studies assessing trainee experience would strengthen these observed trends.



**PP-091****Correlation factors of posterior arch height after posterior chamber intraocular lens implantation**W Cui.

**Objective:** Investigate the factors affecting vault after ICL implantation. Establish regression formula to predict vault, and verify the formula.

**Methods:** 40 patients (80 eyes) who planned to receive ICL implantation in our hospital from August 2020 to May 2021 were included. Curvature (K), ocular axis (AL), anterior chamber depth (ACD), lens thickness (LT), corneal transverse diameter (WTW), ICL diameter (ICLD), distance from ciliary sulcus to ciliary sulcus (STS), the distance from lens vertex to the line between opposite ciliary sulci (SL), the distance from ciliary process to ciliary process (CTC) and the distance from lens vertex to the line between opposite ciliary processes (CL) were measured by OA-2000 and UBM before surgery.

Vault was measured with UBM about 1 month after surgery. The correlation between vault and preoperative measurement parameters and ICL diameter was analyzed. The preoperative measurement parameters and ICL diameter were taken as independent variables, at the same time vault was taken as dependent variables, and multiple linear regression analysis was carried out by stepwise method. At last, the regression formula was obtained. In addition, 21 patients (42 eyes) who planned to receive ICL implantation in our hospital from May 2021 to September 2021 were included in the prediction group, and the predicted vault was obtained by the regression formula. The actual vault was measured using UBM one month after surgery and compared the two results.

**Results:** Vault was correlated with CTC, CL, SL, ACD, LT, WTW and ICLD ( $P < 0.05$ ). Correlation coefficients were ( $r = -0.227, -0.367, -0.479, 0.355, -0.357, 0.266, 0.250$ ).

The regression formula is  $\text{Vault} = -1.122 - 0.264 * \text{CTC} - 0.643 * \text{SL} + 0.089 * \text{WTW} + 0.302 * \text{ICLD}$

The predicted vault of the prediction group calculated by the formula was  $(0.55 \pm 0.15)$  mm, while the actual vault measured by UBM was  $(0.54 \pm 0.20)$  mm. The results were analyzed for consistency, and bland-Altman plot was drawn to show that only a few results were outside the 95% consistency limit.

**Conclusion:** In this study, vault has certain correlation with CTC, CL, SL, ACD, LT, WTW and ICLD, while other measured values have no obvious correlation with vault. At the same time, the prediction formula obtained by multiple linear regression has high accuracy in predicting vault.

PP-092

**Senescence-associated LncRNA PINT influences the development of age-related cataracts through epigenetic modifications****B Li<sup>1</sup>, X Zhu, T Wang, S Song, C Hang.**<sup>1</sup>*Ophthalmology, Affiliated Hospital of Yangzhou University, Yangzhou, People's Republic of China***Objective:** To investigate the effect of senescence-associated long non-coding RNA (LncRNA) PINT (p53 induced noncoding transcript) on the development of age-related cataract (ARC).**Methods:** In this study, the expression of aging-related LncRNAs was determined by collecting epithelial cells from different types of ARC and clear lens, and the differentially expressed aging-related LncRNA PINT was identified by comparing the ARC group with the control group. Quantitative Real-time PCR (qRT-PCR) was performed to detect the expression levels of LncRNA PINT in the lens epithelial cells of the ARC group and the control group. Microarray assays and bioinformatics analysis were used to identify potential LncRNA PINT target genes, and chromatin immunoprecipitation assay (ChIP) was used to verify the status of LncRNA PINT target gene candidates. Oxidative damage/aging model and overexpression/knockdown model were established to detect the expression levels of LncRNA PINT and related target genes, cellular antioxidant damage capacity, cell proliferation and apoptosis.**Results:** Compared with the control group, the expression of LncRNA PINT was significantly higher in the ARC group ( $P<0.05$ ); the expression of LncRNA PINT was significantly higher in the oxidative damage/aging model ( $P<0.05$ ); and the expression of LncRNA PINT was significantly lower in the knockdown model ( $P<0.05$ ), the expression level of related target genes was significantly higher ( $P<0.05$ ), and the antioxidant capacity of lens epithelial cells was enhanced ( $P<0.05$ ). In the overexpression model, lens epithelial cells showed decreased proliferation and increased apoptosis ( $P<0.05$ ).**Conclusion:** Altered expression of senescence-associated LncRNAs may affect aging and senile disease formation in the organism through epigenetic modifications, which are associated with the development of ARC.

PP-093

### Ergonomic Benefits of 3D Visualization for Ophthalmic Surgeons

D O'Boyle<sup>1</sup>, R *Ghafouri*<sup>2</sup>, K *Thomas*<sup>2</sup>.

<sup>1</sup>*Alcon, Enniscrone, Ireland*, <sup>2</sup>*EVERSANA, Burlington, Canada*

**Objective:** Occupational musculoskeletal disorders (MSDs) are prevalent in ophthalmic surgeons and can impact surgeon well-being and productivity. 3D visualization systems can improve upon conventional microscopes by reducing ergonomic stress, with a growing body of literature demonstrating favorable ergonomics for 3D displays compared to traditional visualization techniques. A literature review was conducted to further substantiate ergonomic benefits of 3D visualization systems for ophthalmic surgeons.

**Methods:** MEDLINE was searched without language restriction from Jan-01-2001 to Sept-30-2021 using terms related to ophthalmology (eg, ophthalmic, eye surgery, cataract) and ergonomics. Reference lists from relevant articles were also scanned.

**Results:** Of 445 sources screened, eight studies evaluating ergonomic benefits of 3D visualization systems for ophthalmic surgeons were identified. Across seven comparative studies, benefits related to preference, comfort and improved ergonomics for 3D displays compared to conventional microscopes during surgeries were reported. Among these, a cross sectional survey of US cataract, retinal, and glaucoma surgeons, many agreed or strongly agreed that the use of a 3D display reduced the severity (64%) and frequency (63%) of pain and discomfort, improved posture (73%), and improved overall comfort (77%). A similar survey in Japan revealed that use of visualization system led to improvements in eyestrain (54%), less pain and discomfort while operating (72%) and improvements with MSDs (63%). A study from Malaysia reported that postgraduate trainees had significantly better experience with 3D visualization systems for eye strain ( $P=0.008$ ), neck and upper back strain ( $P=0.000$ ), lower back pain ( $P=0.019$ ), and comfortable environment ( $P=0.001$ ). While in a consecutive case-control study of vitreoretinal surgeries in China, surgeons and residents rated ergonomics higher in the 3D visualization group than the conventional microscopy group using a 5-point scale ( $P<0.001$ ).

**Conclusion:** This literature review indicates that 3D visualization displays may be an important tool to improve comfort and wellness in the operating room, benefiting surgeons across several ergonomic measures and procedure types. Future studies designed to specifically compare objective methods of ergonomic assessment would be useful to provide additional information related to the value of 3D systems.

PP-094

**Analysis of capture data consistency between ANTERION and IOL Master 700**

Y Jinhao, W xiaogang, C shuimiao.

**Objective:** To investigate the acquired rate, ocular biometrics parameters, and predicted intraocular lens (IOL) power consistency between ANTERION and IOL Master 700 under different axial lengths.

**Methods:** Enrolled participants randomly received data captured from the two devices and grouped into three groups according to the axial length (AL) values from IOL Master 700 (short eye group:  $AL \leq 22$ mm; normal eye group: 22mm

**Results:** A total of 257 patients (363 eyes) were included in the final data analysis. There were 22 eyes, 250 eyes, and 91 eyes for short eye, normal eye, and long eye groups, respectively. IOL Master 700 demonstrated a higher acquired rate than ANTERION for all the three groups. For short eye group, ACD, CCT, LT, and keratometry values showed significant differences between the two devices (all  $P < 0.014$ ), but not for AL, WTW, and astigmatism values. For normal eye group, AL, astigmatism magnitude, J0, and J45 demonstrated no significant difference between the two devices, but statistically different was found for all the other parameters (all  $P < 0.008$ ). For long eye group, no significant difference was found for astigmatism axis, J0, and J45 between the two devices, but statistical differences were found for all the other parameters (all  $P < 0.003$ ).

**Conclusion:** IOL Master 700 demonstrated a better capture rate than ANTERION. Ophthalmologists should notice each group's uninterchangeable data (including ACD, LT, CCT, IOL power, etc.) in clinic.

PP-095

**Characteristics and influencing factors of corneal higher-order aberration in patients with cataract**S Zhou, Y Wang<sup>1</sup>, W Luo<sup>1</sup>, H Zheng<sup>1</sup>.<sup>1</sup>Aier Eye Hospital of Wuhan University, Wuhan, People's Republic of China

**Objective:** To observe the distribution characteristics of corneal high-order aberrations in cataract patients, and analyze the relationship between high-order aberrations (HOAs) and patients' age, gender and ocular biometric parameters.

**Methods:** This cross-sectional study review the patients undergoing cataract surgery in Wuhan Aier Eye Department from January to December 2020. Corneal HOAs were measured by Wavefront Aberrometer (OPD-Scan III; Nidek Inc, Tokyo, Japan). From the Zernike coefficients, we calculated the root mean square (RMS) of the total corneal HOA, spherical aberration(SA), coma and trefoil aberration for a corneal central region of 4mm and 6mm. The biometric parameters including axial length (AL), mean keratometry (Km), central corneal thickness (CCT), anterior chamber depth (ACD), lens thickness (LT) and pupil diameter (PD) were measured by partial coherence laser interferometry (OA-2000; TOMEY Corp, Aichi, Japan). Multiple linear regression analyses were used to determine whether HOAs were associated with age, gender and ocular biometric parameters.

**Results:** A total of 976 patients (976 eyes) enrolled in this study, aged 65 (55-72) years. The median RMS of total corneal HOAs at central 4mm and 6mm optic zone were respectively 0.17  $\mu$  m and 0.55  $\mu$  m, while the median RMS of SA were 0.06  $\mu$  m and 0.27  $\mu$  m. There are 88.63% of patients with total HOA at central 4mm optical zone lower than 0.3  $\mu$  m. Females were with higher SA at central 4mm optic zone, and higher SA, coma and total HOA at central 6mm zone than males. The RMS of total HOA, coma and trefoil aberration of both 4mm and 6mm optic zone were increasing with older age. As AL increased, total HOA, SA and trefoil at central 6mm optic zone tended to decrease first and then increase. Multiple linear regression analysis revealed the relationships between HOAs and age, gender and ocular biometric parameters. Total HOA (4mm) = 0.348+0.187 Age+0.287 Astigmatism- 0.126CCT (R<sup>2</sup>=0.136 p<0.01); Total HOA (6mm) =2.971+ 0.241 Astigmatism - 0.254 Km - 0.148 CCT (R<sup>2</sup>=0.147 p<0.01).

**Conclusion:** Aspheric intraocular lens implantation is recommended for Chinese cataract patients. Total HOA, coma and trefoil were positively relevant with age, while there was no significant correlation between SA and age. HOAs are mainly determined by corneal condition, keratometry and CCT are the most relevant factor with HOAs. The accuracy for HOAs prediction based on ocular biometric parameters is not well and personalized measurements of wavefront aberration is required.

PP-096

**Case Series of Severe TASS Secondary to Retained Surgical Pack Debris**A Gulani, N Shaikh.

**Objective:** To identify the etiology and treat post operative inflammatory reactions seen in patients after routine cataract surgery.

**Methods:** Retrospective review of patients who underwent uncomplicated phacoemulsification surgery and presented postoperatively with increasing inflammation in the eye between Dec 2018 and July 2019 at the Orlando VA Medical Center. All patients were treated for chronic inflammation with steroids and/or surgical washout. Patients were followed for a period of 12 months or until complete resolution of inflammation. Variables studied included duration and clinical presentation of ocular inflammation, presence of foreign body in eye, intraocular pressure and pre- and post-treatment visual acuity.

**Results:** 28 eyes of 26 patients presented with increasing or recurring inflammation from 1 week to 3 months post-cataract surgery. The average time to presentation after surgery was 28.2 days ( $\pm 21.4$ ). Treatments included topical steroids in all cases with or without intraocular steroids/antibiotic injection or anterior chamber washout. Average time to resolution was 4.29 months: topical steroid drops alone (n=29) at 4.4 ( $\pm 2.8$ ) months; drops plus anterior chamber washout (n=8) at 2.9 ( $\pm 1.80$ ) months; and drops plus steroid injections (n=5) at 3.0 ( $\pm 2.83$ ) months.

**Conclusion:** These patients presented with a delayed, severe toxic anterior segment syndrome (TASS) reaction secondary to foreign bodies from surgery packs. Corticosteroid injections with steroid drops were proven to be the most efficacious nonsurgical option for treatment after cataract surgery compared to topical drops alone. Anterior chamber washouts had a similar effect as the injections but were more invasive.

PP-097

**Update in ophthalmological surgical practice: Bimanual microincision in cataract surgery**F Niveló, J Paredes.

**Objective:** Determine the advantages of bimanual microincision (MICS) in cataract surgery compared to other techniques.

**Methods:** This systematic review was carried out applying the health descriptors: "cataracts", "surgical practice", "microincision", "microincisional surgery", "surgical effectiveness", "visual acuity", "phacoemulsification", in the following search engines: PubMed, Medigraphic, Scielo, Dialnet, Scopus, Elsevier.

Inclusion and exclusion criteria were applied: studies published in the last 10 years, publications in English and Spanish, studies that contain the variables from the studio.

The search process began with the identification of 675 articles in the search engines; which finally 20 articles were selected.

**Results:** MICS has procedures such as B-MICS and C-MICS, which have focused on significantly reducing the mean time compared to other techniques. MICS takes less time than phacoemulsification, however, the shorter surgical time that its practice implies of approximately 9 minutes and the lower cost allows it to be a more profitable and financially viable option, making it a valuable alternative to perform high-performance cataract surgeries. volume, especially in developing countries. It generates a lower degree of surgically induced astigmatism, rapid wound healing, better postoperative vision, better biomechanics and more stability of the corneal section.

The complications that were evidenced in the surgical practice of cataracts include intraoperative complications such as: eyes with posterior capsule rupture (PCR) with or without vitreous loss, the most frequent of these being zonular dialysis, vitreous loss, as well as early bilateral complications (endophthalmitis, anterior segment toxic syndromes, ocular hypertension), late bilateral complications (refractive surprise, corneal decompensation), among others.

**Conclusion:** MICS focuses on significantly reducing mean time compared to other techniques, making it cost-effective in high-volume surgeries such as cataract surgery in developing countries. It has benefits such as a lower degree of surgically induced astigmatism, rapid wound healing, better postoperative vision, better biomechanics, and more stability of the corneal section. There are early and late complications that can occur, such as endophthalmitis. CPR is the most frequent intraoperative complication and posterior capsular opacity is the most frequent of the possible postoperative complications.

## PP-098

**Georg Joseph Beer (1763-1821), A pioneer in Ophthalmology, ophthalmic surgeon specialist, and a great teacher**

G Balanikas<sup>1</sup>, D Pirounides<sup>1</sup>, I Chalkias<sup>1</sup>, M Angelou<sup>2</sup>, N Makris<sup>2</sup>, P Rasoglou<sup>3</sup>, K Boboridis<sup>4</sup>, D Christodoulou<sup>5</sup>.

<sup>1</sup>A' Ophthalmologic Clinic, AHEPA Hospital, Aristotle University, THESSALONIKI, <sup>2</sup>Ophthalmologic Clinic,

Ophthalmiatreio, Athens, <sup>3</sup>Ophthalmologic Clinic, Ophthalmica Institute, <sup>4</sup>C' Ophthalmologic Clinic, AHEPA Hospital,

<sup>5</sup>Laboratory of History of Medicine, Medical School, Aristotle University, THESSALONIKI, Greece

**Objective:** Georg Joseph Beer (1763-1821) was an Austrian physician in Vienna in the early 19th century. After his graduation from the University of Vienna in 1786 was an assistant to Joseph Barth (1745-1818), professor of surgery and ophthalmology in Vienna; and later worked as a general practitioner but was distinguished in ophthalmology and surgery. His life, career, work, and teachings are the objects of this presentation.

**Methods:** We study the life and career of Geor Joseph Beer and his scientific writings, the famous '*Lehre von den Augenkrankheiten, als Leitfaden zu seinen öffentlichen Vorlesungen entworfen*' and in English his work 'A Manual of the Diseases of the Human Eye'.

**Results:** Georg Joseph Beer became a physician studying at Vienna Medical School and graduated in 1786. He tried to focus on ophthalmic surgery under professor Joseph Barth under a brutal behavior when he was the anatomical illustrator for seven years. However, he later made his efforts of Daviel's method and became an expert and performed many outstanding surgical operations. After his training in medicine and general surgery, he limited his practice to diagnosing and treating eye disorders.

**Conclusion:** In the early 19th century Georg Joseph Beer contributed to the establishment of Ophthalmology as an independent specialty of medicine. He was a great physician and surgeon, focusing mainly on Ophthalmology and surgical procedures, but beyond all, he was a dedicated teacher. The most distinguished ophthalmologists of the next generation were his pupils, Friedrich Jaeger his assistant and son in law, Anton von Rosas, his successor as a professor of Ophthalmology at the Imperial Royal University of Vienna, Philipp Franz von Walter, Carl Ferdinand von Graefe, Max Tetzler, Johann Nepomuk Fischer, Konrad Johann Martin Langenbeck, Franz von Chelius, Friedrich von Ammon, Carl Heinrich Weller, Friedrich Philipp Ritterich, Carl Heinrich Dzondi, Traugott Wilhelm Gustav Benedikt, Francesco Fraerer, Giuseppe Albin, Johann Gottlieb Fabini, Walther Flemming, William Mackenzie and George E. Frick. His pupils, after they returned to their countries and homes, became professors of Ophthalmology and attracted many students establishing ophthalmology as a medical subspecialty early in the 19th century in Europe



PP-099

**Nicotinamide improves *in vitro* lens regeneration in a mouse capsular bag model**X Liu, Z Li<sup>1</sup>, L Xie<sup>1</sup>.<sup>1</sup>Eye Institute of Shandong First Medical University, Qingdao, Hong Kong, China

**Objective:** Mammalian lens regeneration holds great potential as a cataract therapy. However, the mechanism of mammalian lens regeneration is unclear, and the methods for optimization remain in question.

**Methods:** We developed an *in vitro* lens regeneration model using mouse capsular bag culture and improved the transparency of the regenerated lens using nicotinamide (NAM). We used D4476 and SSTC3 as a casein kinase 1A inhibitor and agonist, respectively. The expression of lens-specific markers was examined by real-time PCR, immunostaining, and western blotting. The structure of the *in vitro* regenerated lens was investigated using 3,3'-dihexyloxycarbocyanine iodide (DiOC6) and methylene blue staining, terminal deoxynucleotidyl transferase dUTP nick end labeling (TUNEL), and transmission electron microscopy.

**Results:** The *in vitro* lens regeneration model was developed to mimic the process of *in vivo* mammalian lens regeneration in a mouse capsular bag culture. In the early stage, the remanent lens epithelial cells proliferated across the posterior capsule and differentiated into lens fiber cells (LFCs). The regenerated lenses appeared opaque after 28 days; however, NAM treatment effectively maintained the transparency of the regenerated lens. We demonstrated that NAM maintained lens epithelial cell survival, promoted the differentiation and regular cellular arrangement of LFCs, and reduced lens-related cell apoptosis. Mechanistically, NAM enhanced the differentiation and transparency of regenerative lenses partly by inhibiting casein kinase 1A activity.

**Conclusion:** This study provides a new *in vitro* model for regeneration study and demonstrates the potential of NAM in *in vitro* mammalian lens regeneration.

**PP-100****Efficacy of the Clareon Toric Intraocular Lens platform in a large, private ophthalmic retrospective cohort**

M Lawless<sup>1,2</sup>, D Ng<sup>1</sup>, T Roberts<sup>1,2</sup>, G Sutton<sup>1,2</sup>, C Chan<sup>1,2</sup>, C Hodge<sup>1,2</sup>.

<sup>1</sup>Vision Eye Institute, Chatswood, <sup>2</sup>University of Sydney, Sydney, Australia

**Objective:** Residual astigmatism will impact unaided visual acuity and patient satisfaction following cataract surgery. A critical goal of surgery must be to minimise all refractive error. The use of Toric Intraocular Lenses (IOLs) is increasingly common to reduce postoperative astigmatism.

The objective of this study is to assess the efficacy of the Clareon Toric IOL in treating astigmatism in a real-world cohort undergoing cataract removal and IOL insertion.

**Methods:** This is a retrospective review of consecutive patients undergoing cataract surgery with the Clareon Toric IOL. The VERION system (Alcon) was used for eye registration and used to guide toric IOL alignment at surgery. Precorneal tear film was optimised prior to surgery as appropriate. Biometry and keratometry were undertaken with the IOLMaster 700.

Standard pre and post-operative visual acuity and refractive variables from the first eye only of patients receiving a Clareon Toric IOL will be included for analysis. Standard refractive efficacy parameters including residual astigmatism will be presented. The percentage of secondary Toric IOL rotation procedures will be provided.

**Results:** This study will include 202 eyes of 202 patients. 46.5% of patients had a low toric (T2) IOL inserted. 10.9% of eyes had a toric IOL power of T5 or greater. Efficacy results to be provided.

**Conclusion:** The aim of the Clareon Toric IOL platform is to provide excellent visual quality and minimise postoperative refractive astigmatism.

PP-104

**Bilateral Progressive Anterior & Posterior Lenticonus: its significance & management with Toric IOL**

V Singh, V kumar, R Kusumesh, M raj.

**Objective:** we aimed at highlighting the importance of detection of lenticonus in otherwise asymptomatic patients for early diagnosis and management of Alport syndrome and addressing the challenges in performing clear lens extraction with toric IOL to eliminate irregular astigmatism for better visual rehabilitation.

**Methods:** Patient presented with complains of **bilateral painless gradual progressive diminution of vision since last 1 year, was not improving with glass. Provisional diagnosis of Alport syndrome with bilateral anterior and posterior lenticonus was made based on history, examination and investigations. Managed by both eye clear lens extraction with phacoemulsification with foldable toric IOL implantation**

**Results:** Treatment with clear lens extraction by phacoemulsification with foldable toric IOL implantation can be done successfully in bilateral lenticonus.

**Conclusion:** Bilateral anterior and posterior lenticonus is rare but can be managed successfully with clear lens extraction and foldable toric IOL implantation & for early diagnosis and management of Alport syndrome in otherwise asymptomatic patients.

PP-105

**CORRELATION BETWEEN CCT WITH DEGREE OF MYOPIA, AXIAL LENGTH, AND ANTERIOR CHAMBER DEPTH IN SOUTH INDIANS**K Y<sup>1</sup>, A Anusha.<sup>1</sup>MS Ramiah Medical College, Bangalore, India

**Objective:** The purpose of our study was to investigate the correlation between central corneal thickness(CCT), axial length(AL), and anterior chamber depth(ACD) with a degree of myopia.

**Methods:** This is a prospective observational study of 106 eyes carried out in a tertiary care center. Individuals between 8 and 55 years of age with spherical equivalents ranging from -0.50 to -10 diopters after cycloplegic refraction were divided into three groups based on degree of myopia i.e, mild(<-3D), moderate(-3 to-6D), and severe(>-6D) were included in the study.

**Results:** The mean central corneal thickness(CCT) of our study population is  $535 \pm 4$  microns, anterior chamber depth(ACD) is  $3.60 \pm 0.1$  and axial length(AL) is  $24.6 \pm 2.2$ . CCT and ACD, CCT and ACD were statistically not significantly ( $P > 0.05$ ) associated with a degree of myopia. But there is a positive correlation between axial length and degree of myopia ( $p < 0.05$ ).

**Conclusion:** Hence we conclude that there is no correlation between CCT and ACD with the degree of myopia but there is a correlation between an increase in the AL with a severe degree of myopia in the south Indian population.

**PP-106****Evaluation of the effect of femtosecond laser cataract surgery combined with symmetrical arc incision in correction of corneal ast**

H Zunxia.

**Objective:** Evaluate the correction effect of femtosecond laser symmetrical arc incision on cataract patients with corneal astigmatism.

**Methods:** Methods: Forty-four patients (60 eyes) with cataract complicated by  $\geq 0.75$ D corneal regular astigmatism were collected, symmetrical arc corneal incision was used to correct corneal astigmatism during the operation. The arc-shaped incision was set at a corneal diameter of 8 mm, 85% depth. The arc-shaped incision was separated by an opening gauze. Corneal astigmatism was recorded by Pentacam analysis system before operation and 3 months after operation. The astigmatism correction effect was compared and analyzed by subgroups according to the type of astigmatism, age, and arc length. Using Alpins vector analysis method, the observed data are: target-induced astigmatism, surgically induced astigmatism, difference vector, correction index, dislocation angle, success index, etc.

**Results:** There were no complications such as corneal penetration, epithelial injury, corneal epithelial hyperplasia, and incision infection in all patients during and after operation. The preoperative corneal astigmatism was  $1.23 \pm 0.31$ D, and the corneal astigmatism decreased to  $0.69 \pm 0.45$ D 3 months after the operation, and the difference was statistically significant ( $t=4.645$ ,  $P=0.000$ ). Vector analysis of the changes of corneal astigmatism before and after surgery showed that the target-induced astigmatism was  $0.80 \sim 2.10 (1.23 \pm 0.31)$ D, the surgically induced astigmatism was  $0 \sim 1.71 (0.63 \pm 0.47)$ D, and the difference vector was  $0.26 \sim 1.70 (0.84 \pm 0.33)$  D, the correction index was  $0.52 \pm 0.31$ , and the ideal value was 1, indicating that the overall was undercorrected. The error angle is 50% (29 eyes) within  $15^\circ$ . The mean success index was  $0.77 \pm 0.34$ , suggesting that most of the astigmatism remained uncorrected. There was no significant difference in the correction effect between age、arc length groups ( $t=-0.375$ ,  $P=0.709$ ;  $t=-1.415$ ,  $P=0.163$ ); the correction effect of ATM was higher than WTW ( $t=-2.839$ ,  $P=0.006$ ).

**Conclusion:** Femtosecond laser symmetrical arc incision is safe and effective in correcting corneal astigmatism, but the correction index is not ideal. The calculation method of corneal astigmatism based on nomogram needs to improve its predictability through extensive, in-depth and long-term research.

## PP-107

**Itchy eyes: is it more prevalent in keratoconus patients?**

M Torres Arteche<sup>1</sup>, R Silveira de Maman<sup>2</sup>, A Dementshuk Lengler<sup>1</sup>, M Puerari Pieta<sup>2</sup>, A Stumpf Martins<sup>1</sup>, D Ruschel Marinho<sup>3</sup>, M Tartarella<sup>4</sup>, P Ioschpe Gus<sup>3</sup>.

<sup>1</sup>Universidade Federal do Rio Grande do Sul, <sup>2</sup>Pontifícia Universidade Católica do Rio Grande do Sul, <sup>3</sup>Ophthalmology, Universidade Federal do Rio Grande do Sul, <sup>4</sup>Ophthalmology, Universidade Federal de São Paulo, Porto Alegre, Brazil

**Objective:** Keratoconus is a progressive ectatic disease characterized by thinning and protrusion of the cornea with decreased best corrected visual acuity and risk of corneal blindness. This study aimed to test the ability of a questionnaire to identify patients at increased risk.

**Methods:** 64 healthy schoolchildren and 64 keratoconus patients under care at the Ophthalmology Service of Hospital de Clínicas de Porto Alegre were included. All participants agreed to answer the questionnaire.

**Results:** An association between keratoconus and eye rubbing, being advised not to rub the eyes and the use of eye drops were found between groups (respectively,  $p < 0,05$ ,  $p < 0,01$  e  $p < 0,01$ ).

**Conclusion:** All eye care professionals should proactively ask their patients about having itchy eyes, pay attention to possible allergic keratoconjunctivitis or simply dry eye for excessive near work activities, even if the patients do not refer to the symptoms spontaneously.

## PP-108

**Clinical Evaluation of a New Biomimetic Silicone Hydrogel Daily Wear Monthly Replacement Contact Lens**

H Lorentz<sup>1</sup>, A Morrow<sup>2</sup>, J Chin<sup>3</sup>, M Perry<sup>4</sup>.

<sup>1</sup>Alcon Research, LLC, Johns Creek, GA, <sup>2</sup>SUNY College of Optometry Clinical Vision Research Center, New York, NY,

<sup>3</sup>Kurata EyeCare Center, Los Angeles, CA, <sup>4</sup>Vision Health Institute, Orlando, FL, United States

**Objective:** To evaluate clinical performance of a new biomimetic (lehfilcon A) soft contact lens (SCL) compared to commercially available Biofinity (comfilcon A) SCL after 3 months of daily wear.

**Methods:** This was a prospective, randomized, controlled, double-masked, parallel-group, daily wear clinical study conducted in the US (NCT04422990). Of the 160 subjects targeted for enrollment, the goal was to have ~75% of Asian descent (Chinese/Japanese/Korean/Mongolian) with a focus on Chinese ancestry. Subjects aged  $\geq 18$  years who were adapted daily wear reusable spherical SCL wearers (bilateral) in the past 3 months ( $\geq 5$  days/week;  $\geq 8$  hours/day), with best spectacle corrected visual acuity (VA) of 20/20 or better in each eye and cylinder correction of  $\leq 0.75$  D in each eye were included. Subjects were randomized (2:1 ratio) to receive lehfilcon A or comfilcon A for daily wear with monthly replacement. Subjects used CLEAR CARE contact lens solution for daily cleaning and disinfection. Endpoints included: contact lens corrected distance visual acuity (CLCDVA; assessed using Snellen VA, converted into logMAR), lens fit (movement and centration) and surface assessments (front surface wettability and front/back surface deposits).

**Results:** Overall, 146 subjects were included for analysis (lehfilcon A, 96; comfilcon A, 50), of which the Asian subgroup had 112 subjects (lehfilcon A, 75; comfilcon A, 37). Overall, mean (SD) age of subjects was  $33.1 \pm 10.4$  years, with 69.2% being female. At 3 months, mean (SD) CLCDVA logMAR was -0.06 (0.06) for lehfilcon A and -0.05 (0.07) for comfilcon A. Majority of subjects in both groups had optimal lens movement/fit (lehfilcon A, 86.3%; comfilcon A, 87.0%) and centration (lehfilcon A, 93.2%; comfilcon A, 95.7%). There were no ratings of “unacceptably tight/loose fits” or “unacceptable decentration” in either group. Front surface wettability (lehfilcon A, 89.5%; comfilcon A, 77.2%) and surface deposits (front: lehfilcon A 84.7%, comfilcon A 85.9%; back: lehfilcon A 92.1%, comfilcon A 92.4%) were graded as 0 in majority of subjects in both groups. There were no serious adverse events in both groups. The Asian subgroup had similar VA, lens fit, surface assessments, and safety results compared to the overall population.

**Conclusion:** Overall, lehfilcon A contact lens showed good visual acuity, optimal lens fit, a clean and wettable surface, and a good safety profile after 3 months of daily wear, with no clinical differences in the Asian subgroup.

PP-109

**Comparison of lens refractive parameters in myopic and hyperopic eyes of 6–12-year-old children**

J Shang<sup>1</sup>, Y Hua<sup>2</sup>, Y Wang<sup>1</sup>, J He<sup>3</sup>, X Zhou<sup>1</sup>, X Qu<sup>1</sup>.

<sup>1</sup>Fudan University Affiliated Eye Ear Nose and Throat Hospital, <sup>2</sup>Shanghai Jiaotong University Affiliated Sixth People's Hospital, Shanghai, People's Republic of China, <sup>3</sup>New England School of Optometry, Boston, United States

**Objective:** To evaluate the influence of cycloplegia on lens refractive parameters in 6–12-year-old children with myopia and hyperopia for exploring the pathogenesis of myopia.

**Methods:** One hundred eyes of 100 patients (50 boys) were included. In the myopic group, 50 subjects (25 boys and 25 right eyes) were enrolled with a mean age of  $9.20 \pm 1.69$  years. IOLMaster 700 measurements were performed pre- and post-cycloplegia. The pictures were marked using semi-automatic software. The lens curvature and power were obtained using MATLAB image processing software. Paired and independent sample *t*-tests were used for data analysis. Statistical significance was set at  $P < 0.05$ .

**Results:** Anterior and posterior lens curvatures in myopic eyes were larger than those in hyperopic eyes, both pre- and post-cycloplegia (both  $P < 0.001$ ). The refractive power in myopic eyes was lower than that in hyperopic eyes without cycloplegia, both pre- and post-cycloplegia (both  $P < 0.001$ ). The changes in anterior lens curvature and refractive power between pre- and post-cycloplegia in hyperopic eyes were larger than those in myopic eyes (both  $P < 0.05$ ). No significant difference was found in the change in posterior lens curvature and refractive power after cycloplegia in hyperopic and myopic eyes ( $P > 0.05$ ).

**Conclusion:** Anterior and posterior surfaces of the lens were flatter and the refractive power was lower in the myopia group than in the hyperopia group. Myopic and hyperopic patients showed a tendency for lens flattening and refractive power decrease after cycloplegia. Hyperopic patients had more changes in anterior lens curvature and refractive power after cycloplegia.



**PP-110****Slowing Myopia Progression with Low Intensity Red Diode Laser Therapy with 12 Months Randomized Control Trial Evidence**

Q Kaikai, L Zhou<sup>1</sup>.

<sup>1</sup>Optometry, Ningbo Eye Hospital, Ningbo, People's Republic of China

**Objective:** To assess the efficacy of Low Intensity Red Diode Laser Therapy (LIRDLT) with wavelength of 635nm for myopia control.

**Methods:** A single-masked randomized clinical trial with two groups of 50 consecutive eligible children aged 8 to 12 years with  $\leq -0.75$ D of spherical component myopia and  $< 2.50$  D astigmatism were enrolled. Participants were randomly assigned to LIRDLT (n = 25) group, or single-vision spectacles (as Control, n = 25) group. Changes in axial length from the baseline were compared between two groups at 3-, 6-, 9-, and 12- month follow-ups, respectively. The other 4 parameters, including choroidal thickness, anterior chamber depth, central cornea refractive power, and cycloplegic refractive error were also analyzed.

**Results:** Among 50 randomized participants, 78% were included in the final analyses (mean [SD] age, 9.7 [1.5] years; 60.5% were male; mean [SD] spherical equivalent refractive error, -2.56 [1.70] D). The mean difference between two groups at 12-month from baseline in axial length elongation was 0.47mm (LIRDLT vs Control,  $-0.02\text{mm} \pm 0.11$  vs  $0.45\text{mm} \pm 0.25$ ,  $P < .001$ ); And the mean difference between two groups at 12 month from baseline in cycloplegic refraction in spherical equivalence was 1.23D (LIRDLT vs Control,  $+0.26\text{D} \pm 0.27$  vs  $-0.97\text{D} \pm 0.25$ ,  $P < .001$ ); And 6- and 3-month from baseline in axial length elongation was 0.27 mm (LIRDLT vs Control,  $-0.07\text{mm} \pm 0.12$  vs  $0.20\text{mm} \pm 0.10$ ,  $P < .001$ ), and 0.21mm (LIRDLT vs Control,  $-0.09\text{mm} \pm 0.10$  vs  $0.12\text{mm} \pm 0.06$ ,  $P < .001$ ) at 3-month, respectively. Neither of the other parameters obtained statistically significant difference between the two groups.

**Conclusion:** LIRDLT is an efficacy way to control myopia progression in Children.

**Trial registration:** ChiCTR2100043619.

PP-111

**Quality of life and functional difficulties of children with unaddressed refractive error, in Bong County, Liberia**G Trotignon.

**Objective:** The objective of the study was to assess quality of life and functional difficulties of children with unaddressed refractive error, in Bong County, Liberia.

**Methods:** In this study, we present data from a school-based vision screening and deworming programme implemented in four counties of Liberia (Bong, Grand Kru, Maryland, and Sinoe). The model consisted of a simple vision screening conducted by teachers after being trained by optometrists. Teachers would refer children to mobile refraction teams if they failed the vision screening (vision worse than 6/9). The mobile refraction teams provided ready-made eyeglasses or a prescription for pre-paid custom-made eyeglasses that were ordered and delivered to the child when available or made referrals to the nearest eye clinic if further treatment was needed.

As part of this programme, a quality of life and functional disability study has been conducted among children taking part of the programme in Bong County. The aim was to quantify potential differences in quality of life and functional difficulties between children with unaddressed refractive error and children without. We used the Child Health Utility instrument (CHU-9D) to measure health related quality of life and the Washington Group / UNICEF Child Functioning Module for children aged between 5 and 17 Years to measure functional disabilities.

**Results:** Out of the 636 children selected, 61 were referred for eye examination and then eyeglasses. The average health utility score measured (0 to 1 scale, 1 equal perfect health) was significantly lower for children with unaddressed refractive error 0.8557 against 0.9007 for children without unaddressed refractive error ( $p \leq 0.006$ ). Children with unaddressed refractive error also presented a difference, not statistically significant, with more functional difficulties (excluding vision difficulties) with 25% of children with non-visual difficulties whereas among children without unaddressed refractive error 14% were identified as having functional difficulties ( $p \leq 0.073$ ).

**Conclusion:** These results emphasize the need for more interventions supporting the provision of eye health services and products as early as possible as children, even at young age, have their health-related quality of life affected by unaddressed refractive error.

PP-114

**PROSE LENSES : INDICATIONS AND OUTCOMES IN A TERTIARY EYE CARE CENTER IN NORTHERN INDIA**G Budhiraja<sup>1,2</sup>, V Sangwan, N Kapur.<sup>1</sup>Self, <sup>2</sup>Dr. Shroff's Charity Eye Hospital, Delhi, India

**Objective:** 1. To analyse the indications of PROSE (Prosthetic replacement of ocular ecosystem) lenses in various corneal disorders and delaying the corneal transplantation in such cases.

2. Determine the outcomes of the PROSE lenses in various corneal disorders in terms of comfort and wearing time.

**Methods:** This was a retrospective study conducted for the patients seen in the contact lens clinic from January 2018 to July 2019, at a tertiary eye care center in India. We have followed the declaration of Helsinki protocol during the study.

94 lens trials were included in the study.

**Results:** In our study, we analysed all the 94 trials done in the study period of 1.5 years.

1. Indications for PROSE trials were Ocular surface diseases in 31/94 (32.9%) and irregular corneas in 63/94 (67.02%).

2. Visual acuity improvement was noted in 79/94 trials.

3. All the patients who were dispensed the lenses were comfortable in wearing the lenses, except one patient, who reported tight fit and had CLARE (contact lens related red eye).

**Conclusion:** In conclusion, we found that the PROSE lenses serve as a good alternative for patients suffering from advanced ectasias which maybe beneficial in delaying the keratoplasties.

They can also be a successful treatment modality for the vast majority of ocular surface diseases, which also require multiple surgical interventions.



PP-115

**SHORT TERM VISUAL OUTCOME WITH SCLEROCORNEAL CONTACT LENS ON IRREGULAR CORNEA:**H K.

**Objective:** To study the change in visual acuity obtained with sclerocorneal contact lens (SCL) in patients with irregular corneal astigmatism.

**Methods:** A prospective pre-post observational study was designed to include consecutive consenting patients with irregular corneal astigmatism and best corrected visual acuity worse than 6/12 and fitted with SCL. Visual acuity was assessed using Snellen charts before fitting SCL and one week after the fit and converted to the equivalent logMAR units for analysis.

**Results:** We included 51 eyes of 41 patients with a mean age of  $26.31 \pm 8.86$  of which 32(78%) were men. Keratoconus was the commonest indication (n=42 eyes, 82.35[GU1] %), followed by corneal scar (n=3, 4%), post keratoplasty (n=2, 4%), high myopia (n=2, 4%), pellucid marginal degeneration (n=1, 2%), and aphakia (n=1, 2%). The mean overall uncorrected visual acuity improved significantly ( $p < 0.001$ ) with SCL from  $1.18 \pm 0.34$  logMAR (6/120 Snellen's equivalent) to  $0.27 \pm 0.15$  (6/9 Snellen's equivalent) at 1 week post SCL fitting. The mean overall best spectacle-corrected visual acuity improved from  $0.89 \pm 0.45$  logMAR (6/36 Snellen's equivalent) to  $0.26 \pm 0.15$  (6/9 Snellen's equivalent) at 1 week post SCL fitting.

**Conclusion:** Sclerocorneal contact lens improves visual acuity significantly in patients with irregular corneal astigmatism and reduces the need for corneal transplantation.

PP-117

**Public Schoolchildren Refractive Errors in Brazil**

M Torres Arteché<sup>1</sup>, R *Silveira de Maman*<sup>2</sup>, A *Dementshuk Lengler*<sup>1</sup>, M *Puerari Pieta*<sup>2</sup>, A *Stumpf Martins*<sup>1</sup>, D *Ruschel Marinho*<sup>3</sup>, M *Tartarella*<sup>4</sup>, P *Ioschpe Gus*<sup>3</sup>.

<sup>1</sup>*Universidade Federal do Rio Grande do Sul*, <sup>2</sup>*Pontifícia Universidade Católica do Rio Grande do Sul*, <sup>3</sup>*Ophthalmology, Universidade Federal do Rio Grande do Sul*, <sup>4</sup>*Ophthalmology, Universidade Federal de São Paulo, Porto Alegre, Brazil*

**Objective:** Myopia has been recognized as a public health issue by the WHO since 2015. The highest prevalence is concentrated in East Asia exceeding that of any other region in the world. Nevertheless, the increasing prevalence of myopia became a concern in Brazil in 2019, after reports detecting prevalence ranges from 9% to 20.4%. This study aims to identify the actual prevalence of refractive errors among schoolchildren in southern Brazil.

**Methods:** this is a convenient sample cross sectional study which recruited 330 public schoolchildren from 5 to 21 yo, enrolled between 2019 and 2021 for a complete ophthalmologic evaluation. The primary outcome analyzed was the prevalence of myopia, defined as all cycloplegic spherical equivalent refraction equal to or less than -0.50D. Secondary outcomes were the identification and quantification of hyperopia and/or astigmatism. Spherical equivalents +2.00D were defined as hyperopia and cylinders -1.00 D as astigmatism. Visual acuity, cycloplegic refraction, axial length measurements, corneal tomography, dilated fundus exam and slit lamp biomicroscopy were performed. A detailed questionnaire about demographics, use of near work devices, medical and family history was conducted.

**Results:** Prevalence of refractive errors was 17.4% to myopia, 7.7% to hypermetropia and 25.6% to astigmatism. No statistically significant difference between male and female was found ( $p=0,7$ ), with median myopia of -2.00D among females and -1.50D among males. Considering the cut off of high myopia of -6.00D, the prevalence of high myopia was 4%.

**Conclusion:** Myopia prevalence is also rising in Brazil and the prevalence of high myopia was surprisingly higher than expected. Our results indicate that myopia prevalence overtook hyperopia's spot as the second most prevalent refractive error in Brazil. Astigmatism maintains itself as the most frequent refractive error, due to the possibility of coexisting with either myopia or hyperopia.

## PP-118

## Long-term rotational stability of AcrySof IQ Toric IOLs in Chinese cataract patients with myopia

J Luo, Y liu.

**Objective:** To investigate the long-term rotational stability of AcrySof IQ Toric IOLs in Chinese cataract patients with myopia.

**Methods:** A retrospective case series. Cataract patients with preoperative axial length between 24mm and 30mm and corneal astigmatism  $>1.50\text{D}$ , who implanted with AcrySof IQ Toric IOL under the guidance of Verion were recruited in this study. The results of preoperative and postoperative examinations of recruited subjects were extracted and analyzed. These parameters included the absolute IOL rotation at the subject's last visit, proportion of eyes with IOL rotation of less than 5 and 10 degrees, rotational direction, residual astigmatism and uncorrected distance visual acuity (BCDVA).

**Results:** A total of 120 unique cases (78 patients) were included. The average follow-up was 34.27 months (from 24 months to 48 months). The mean rotational degree was  $2.73 \pm 1.29^\circ$ . Patients were divided into two groups: Group A (High myopia ( $AL \geq 26\text{mm}$ )): 60 eyes, Group B (Low-to-moderate myopia ( $24\text{mm} \leq AL < 26\text{mm}$ )): 60 eyes. The rotational degree of group A ( $2.87 \pm 1.31^\circ$ ) was slightly larger than that of group B ( $2.59 \pm 1.27^\circ$ ) ( $P < 0.05$ ). There was no significant difference in IOL rotation between the two groups at 2-3 years and 3-4 years after operation ( $P > 0.05$ ). Among the observed patients, no patient had rotational degree greater than  $10^\circ$ , and the ratio of rotational degree  $\leq 5^\circ$  was 98.22%. The mean BCDVA of all patients was  $0.13 \pm 0.03$  logMAR after surgery, and the visual acuity after surgery was significantly improved compared with that before surgery ( $\chi^2 = 76.79, P < 0.05$ ). The mean preoperative corneal astigmatism was ( $2.17 \pm 1.08$ ) D, and the estimated residual astigmatism was ( $0.41 \pm 0.26$ ) D, the difference between preoperative corneal astigmatism and postoperative residual astigmatism was statistically significant ( $t = 4.281, P < 0.05$ ).

**Conclusion:** AcrySof Toric IOL can effectively correct corneal astigmatism and has good long-term rotational stability in Chinese cataract patients with myopia.

PP-120

**Development of Anisometropia in School-Aged Children before and after the COVID-19 Pandemic**Y Huang.

**Objective:** The purpose of this study was to investigate the annual incidence rates of anisometropia between 2009 to 2020 among Chinese school-aged children and to evaluate its association with COVID-19 pandemic.

**Methods:** All children aged 6 to 14 years attending the children clinic at the Joint Shantou International Eye Center of Shantou University and the Chinese University of Hong Kong during 2009-2021 were recruited. Cycloplegic refraction and the progression data were collected among myopic children with 1 to 2 years of follow-up. Anisometropia was defined as interocular spherical equivalent (SE) difference  $\geq 1.0$  D. The annual incidence rate of anisometropia were compared between 2020 (after home confinement) and the previous years. Variables associated with the incidence rates of anisometropia were examined using Cox proportional hazards model.

**Results:** Among the 10255 myopic children without anisometropia at baseline, 505 children (4.9%) developed anisometropia during 1 to 2 years of follow-up. The mean interocular SE difference in all children at baseline was  $0.29 \pm 0.26$  D and increased to  $0.38 \pm 0.35$  D when anisometropia developed or the participants were last seen. The Cox proportional hazards regression model showed that the year of 2020 (hazards ratio [HR]: 3.07; 95% CI: 1.81, 5.22) and greater initial interocular SE difference (HR: 12.92; 95% CI: 10.35, 16.13) were significantly associated with a greater risk of anisometropia development.

**Conclusion:** We found that home confinement during the COVID-19 pandemic appeared to be associated with the incidence of anisometropia in Chinese school-aged children, which may be related with the increased rate of myopia progression during the COVID-19 pandemic.



PP-121

**Amplitude of Accommodation in Pre-presbyopic Diabetic patients**

P Gangopadhyay<sup>1</sup>, S Thakur<sup>1</sup>, A Srivastava<sup>1</sup>.

<sup>1</sup>Midnapore Medical College, Kolkata, India

**Objective:** To determine the effect of Type I and II Diabetes Mellitus on the Amplitude of Accommodation in Pre-presbyopic patients.

**Methods:** A cross-sectional study was performed among 54 diabetic patients between 30-40 years of age and 50 age-matched controls. Using the best corrected distance visual acuity, the amplitude of accommodation was measured by Subjective Push-up Technique using RAF Scale.

**Results:** The mean amplitude of accommodation in the diabetic group was  $6.67 \pm 2.33D$  which was significantly lesser than that in the control group ( $8.74 \pm 2.17D$ ) ( $p=0.000004$ ). There were negative correlations between amplitude of accommodation with duration of Diabetes ( $r=-0.31$ ,  $p=0.02$ ) and the level of HBA1c ( $r=-0.14$ ,  $p=0.007$ ).

**Conclusion:** Thus, we can conclude that patients with Diabetes showed a lower Amplitude of Accommodation in comparison to healthy controls making them susceptible to Early-onset Presbyopia. Longer duration and poor control of Diabetes also showed significant influence.

PP-122

**Prediction of Insufficient Vault After Implantable Collamer Lens Implantation Using iris Morphology**L Zhao, M *Khan*, D *Lin*.

**Objective:** To investigate the factor related to the iris morphology that are predictive of outcomes of insufficient vault ( $< 100 \mu\text{m}$ ) after Implantable Collamer Lens V4c Implantation.

**Methods:** In this retrospective case-control study, 27 eyes of 27 patients who presented with insufficient vault ( $< 100 \mu\text{m}$ ) following implantation of an ICL V4c were matched in a 1:2 ratio with those who presented with a normal vault (250 to 750  $\mu\text{m}$ ) on anterior chamber depth, white-to-white distance, and ICL size. The preoperative biometric parameters and clinical outcomes were compared between the two groups. The relationship between the postoperative vault and various variables was assessed by multiple linear regression analysis. Conditional logistic regression models were used to estimate the risk factors for insufficient vault.

**Results:** The postoperative vault was associated with preoperative iris curvature and crystalline lens vault ( $P < 0.05$ ). In the conditional regression logistic analysis, the iris curvature was associated with an increased risk of insufficient vault after ICL implantation ( $P < 0.05$ ).

**Conclusion:** Eyes with an extremely concave iris were associated with a higher rate of insufficient vault after ICL implantation, so the size of the ICL may need to be adjusted in these patients.

PP-128

### Cystoid macular edema following Descemet's membrane endothelial keratoplasty in a referral center for keratoplasty in Spain

N Moura-Coelho<sup>1234</sup>, R Papa-Vettorazzi<sup>4</sup>, I Santiesteban-García<sup>4</sup>, A Dias-Santos<sup>256</sup>, F Manero<sup>4</sup>, J Cunha<sup>35</sup>, J Güell<sup>147</sup>.

<sup>1</sup>Ophthalmology, European School for Advanced Studies in Ophthalmology (ESASO), Lugano, Switzerland,

<sup>2</sup>Ophthalmology, NOVA Medical School | Faculdade de Ciências Médicas, <sup>3</sup>Ophthalmology, Escola Superior de Tecnologias da Saúde de Lisboa (ESTeSL), Lisbon, Portugal, <sup>4</sup>Cornea and Refractive Surgery Unit, IMO Grupo Miranza Barcelona, Barcelona, Spain, <sup>5</sup>Ophthalmology, Hospital CUF Cascais, <sup>6</sup>Ophthalmology, Central Lisbon Hospital Centre, Lisbon, Portugal, <sup>7</sup>Ophthalmology, Universidad Autónoma de Barcelona, Barcelona, Spain

**Objective:** To analyze the outcomes of eyes with visually significant cystoid macular oedema (vs-CMO) after Descemet membrane endothelial keratoplasty (DMEK) in a referral center for keratoplasty in Spain.

**Methods:** Retrospective, single-surgeon case series of eyes that developed vs-CMO after DMEK between January 2011 and December 2020. Data collected included: indication for DMEK; biometric data; presence of ocular comorbidities; past medical history; time to detection of vs-CMO after DMEK (T, weeks); best-corrected visual acuity (BCVA, logMAR) and central retinal thickness (CRT,  $\mu\text{m}$ ) at diagnosis of vs-CMO, after resolution of CMO, and at last follow-up; and management strategy. Main outcomes analyzed were improvement in BCVA and CRT after treatment of vs-CMO.

**Results:** Of 291 consecutive DMEK surgeries, 14 eyes of 14 patients (4.8%) developed vs-CMO. Four eyes (28.6%) had history of CMO, and 35.7% had ophthalmic comorbidities. Median (P25-P75) T was 4 (3-7.5) weeks. Treatment success was observed in 13 eyes (92.9%), two of which required second-line treatment. In successful cases (median time-to-resolution 3.0 (2.2-4.0) months), median BCVA improved from 0.70 (0.45-0.80) logMAR to 0.20 (0.10-0.40) logMAR ( $p = 0.001$ ) after treatment, and median CRT improved from 445.0 (304.5-594.0)  $\mu\text{m}$  to 291 (275-323)  $\mu\text{m}$  ( $p = 0.015$ ).

**Conclusion:** In our study, we found a 4.8% rate of vs-CMO after DMEK, with most cases occurring in the first 3 months after surgery. Good functional and anatomical outcomes are expected in most eyes, without treatment-related complications or implications in graft outcomes. Additional studies are encouraged to determine a standardized protocol for post-DMEK vs-CMO.

PP-129

**Anti-oxidative and Anti-inflammatory Micelles: Break the Dry Eye Vicious Cycle**S Li, H Han, K Yao, J Ji.

**Objective:** Dry eye disease (DED) impacts approximately 30% of the world's population and causes serious ocular discomfort and even visual impairment. Current therapy merely targets inflammation, one core cause of the DED vicious cycle, a multifactorial deterioration. However, there are also reactive oxygen species (ROS) regulating inflammation and other points in the cycle from the upstream, leading to treatment failure. Accordingly, we develop micelle-based eye drops (more specifically p38 MAPK inhibitor Losmapimod (Los)-loaded and ROS scavenger Tempo (Tem)-conjugated cationic polypeptide micelles, designated as MTem/Los) for safe and efficient DED management.

**Methods:** TEM imaging, DLS, <sup>1</sup>H-NMR, EPR, UV-vis spectra, HPLC, Q-PCR, Western Blotting, RNA-sequencing, In vivo imaging, H&E staining, PAS staining, ROS staining, immunofluorescence staining, TUNEL staining, tear break-up time test, Schirmer test, slit lamp observation, sodium fluorescein staining, CCK-8, Live/Dead, body weight et, al.

**Results:** Cationic MTem/Los improve ocular retention of conjugated water-soluble Tem and loaded water-insoluble Los *via* electrostatic interaction with negatively charged mucin on the cornea, enabling an increase in therapeutic efficiency and a decrease in dosing frequency. Mechanistically, MTem/Los effectively decreases ROS over-production, reduces the expression of proinflammatory cytokines and chemokines, restrain macrophage proinflammatory phenotypic transformation, and inhibit cell apoptosis. Therapeutically, the dual-functional MTem/Los suppresses the inflammatory response, reverses corneal epithelial defect, saves goblet cell dysfunction, and recovers tear secretion, thus breaking the vicious cycle and alleviating the DED. Moreover, MTem/Los exhibit excellent biocompatibility and tolerability.

**Conclusion:** MTem/Los could efficiently rescue DED deterioration through breaking its vicious circle comprising suppressions of inflammation, ROS generation, and apoptosis, with excellent biosafety and ocular tolerance for its future application in DED treatment or other inflammation-based diseases.

**PP-130****A Novel synthetic material to prevent Symblepharon in chemical injury**

D Venugopal.

**Objective:** The purpose of this study is to evaluate the outcomes of Gore-tex, to prevent the recurrence of growth in eyes with symblepharon following chemical injury, along with AMG/CLAG/CLAL/SLET, with a long-term follow-up.

**Methods:** A retrospective review of 11 eyes of 10 patients who underwent symblepharon lysis from January 2011 through December 2019 was done. The data were analyzed for demographic details, visual acuity, anterior and posterior segment details, preoperative diagnosis, and previous surgical details in recurrent cases, surgical procedures, final visual acuity, surgical outcomes, and complications.

**Results:** Our study included 11 eyes of 10 subjects with symblepharon, with a median age of 17 years. The median follow-up was 36 months. In all 11 eyes, the symblepharon was due to moderate to severe grade chemical injury. Among them, 3 eyes had recurrent symblepharon. The mean interval between initial surgery and Gore-Tex application was  $17.33 \pm 6.1$  months. Among 11 eyes, five eyes (45.4%) had symblepharon less than 180 degrees of the limbus, in 2 eyes (18.1%) up to 270 degrees of the limbus and four eyes had total symblepharon with severe forniceal shortening and complete loss of extra ocular movements. Complete epithelialization was achieved in all 11 (100%) eyes. The mean duration of epithelisation was  $5.27 \pm 0.74$  weeks. The average preoperative best-corrected visual acuity (BCVA) was 1.78 log MAR units, and the postoperative BCVA was 0.48 log MAR, which was statistically significant ( $p$ -value = 0.016). The complications included pyogenic granuloma in 4 eyes after three weeks, spontaneous extrusion of Gore-tex in 2 eyes after 4 weeks of insertion, recurrence of symblepharon noted in 4 eyes (36.3%) with more than 180 degrees of symblepharon, and fungal infection of Gore-tex was seen in one eye. The mean duration of recurrence was  $6.75 \pm 3.6$  months. Among four eyes with recurrence, two eyes underwent repeat procedures. The patient with infected Gore-Tex had localized fungal infection, and the adjacent ocular surface was normal. After removing Gore-tex, antifungal eye drops were added for two weeks. Six eyes had stable ocular surface (54.5%) and were considered as successful following Gore-tex implantation; achieved partial success in 4 eyes (36.4%) and failure in one eye (9.1%).

**Conclusion:** Gore-tex seems to be a vital adjunctive treatment option commercially available for preventing the recurrence of Symblepharon along with AMG/CLAG/SLET/MMG. It has proven safe in young individuals.

## PP-131

**The eliminating of reactive oxygen species and alleviation of dry eye disease by ultra-small cerium-based metal organic framework**

J Huang, Z Chen<sup>1</sup>, N Tang<sup>2</sup>.

<sup>1</sup>Fudan University, Shanghai, <sup>2</sup>Wenzhou Medical University, Zhejiang, People's Republic of China

**Objective:** The purpose of this study is to explore the ability of Cerium-based Metal-organic Frameworks (Ce-MOF) nanoparticles to scavenge ROS and its application prospect in dry eye diseases (DED).

**Methods:** Three kinds of Ce-MOFs with different particle sizes were prepared by hydrothermal method, which were labeled Ce-MOF 1, Ce-MOF 2 and Ce-MOF 3, respectively. The phase structure, functional groups, morphology, particle size, Zeta potential, element composition and ROS scavenging ability of Ce-MOFs were characterized. Subsequently, the CCK-8 and ocular irritation test were used to determine the cytotoxicity. In H<sub>2</sub>O<sub>2</sub>-induced ROS model, the ability of cleaning out intracellular ROS in human corneal epithelial cell (HCEC) was tested. Finally, the effect of CeMOF 3 on mouse DED was evaluated by slit lamp observation, corneal epithelial staining.

**Results:** Three kinds of Ce-MOFs were obtained: 500 nm, 50 nm and 3 nm. The phase structure, functional group and thermal stability in Ce-MOFs show no significant difference. CeMOFs showed the concentration-dependent SOD-like and ROS scavenging activities. The cellular and ocular compatibility were confirmed. In HCECs, Ce-MOF 3 show greater antioxidant capacity which reduced ROS level. In the DED treatment, corneal epithelial defect was significantly reduced by Ce-MOF 3.

**Conclusion:** We had successfully constructed three kinds Ce-MOFs which own antioxidant enzyme and ROS scavenging activity in *vitro*. Further, the Ce-MOF 3 not only showed good biocompatibility, it also effectively alleviated DED. The new ultra-small Ce-MOF provides a new method for alleviating dry eye disease.

## PP-133

**Epi-off versus Epi-on Corneal Collagen Crosslinking: A qualitative analysis by In Vivo Confocal Microscopy**

H Sabur, M Acar<sup>1</sup>, N Arslan<sup>1</sup>.

<sup>1</sup>Health Sciences University, Diskapi Training and Research Hospital, Ankara, Türkiye

**Objective:** To compare the corneal microstructural changes in patients with progressive keratoconus who underwent transepithelial (epi-on) and standard (epi-off) corneal crosslinking (CXL).

**Methods:** This prospective comparative study included the 34 eyes of 17 patients with progressive keratoconus who underwent CXL on both eyes. One eye of each patient was treated by epi-on CXL while the other 17 eyes underwent epi-off CXL. The Epi-on CXL procedure included instillation of ParaCel (Part 1: containing 0.25% riboflavin, benzalkonium chloride, EDTA, and HPMC with NaCl; Part 2: containing 0.22% riboflavin with NaCl) and UVA treatment at 45 mw/cm<sup>2</sup> with a total energy of 7.2 j/cm<sup>2</sup>. The Epi-off CXL procedure included corneal deepithelization (9-mm diameter), VibeXRapid instillation (containing 0.1% riboflavin, saline, and HPMC), and UVA treatment at 3 mw/cm<sup>2</sup> with a total energy of 5.4 j/cm<sup>2</sup>. Patients were assessed by HRT III- RCM in vivo confocal microscopy (IVCM) preoperatively and 1, 3, and 6 months after treatment.

**Results:** The mean preoperative corneal thickness was 471 ± 17 μm in the epi-off CXL group and 375 ± 22 μm in the Epi-on CXL group. Early IVCM analysis after Epi-off CXL revealed the disappearance of the subepithelial nerve plexus and anterior-midstromal nerves. However, compared to Epi-off CXL, subepithelial and anterior-midstromal nerve fibers were detectable at all IVCM scans after Epi-on CXL, showing only minor apoptotic damage with increased reflectivity. While keratocyte apoptosis was seen in the anterior to midstroma (depth was; ~310 μm, range, 260–345 c) in Epi-off CXL, the maximum penetration depth of the apoptotic effect was approximately 120 μm with an uneven distribution in Epi-on CXL. No variation in endothelial cell count or mosaic was observed after both procedures.

**Conclusion:** Although Epi-off CXL preserves the subbasal plexus and anterior midstromal nerves, IVCM revealed that its apoptotic effect is limited to the anterior stroma and is less effective than the standard Epi-off procedure for improving corneal biomechanical strength.

PP-134

**Efficacy of intense pulsed light in the treatment of recurrent chronic hordeolum**

Y Wen, K Yang, L Zhu, J Bao, S Li, Y Wang, J Feng, L Tian, Y Jie.

**Objective:** To evaluate the effect of intense pulsed light (IPL) in the treatment of recurrent chronic hordeolum.

**Methods:** Consecutive 20 patients with recurrent subacute hordeolum were enrolled in this prospective observational study. According to the severity of hordeolum, the patients were treated with IPL 3 to 5 times. Patients' satisfaction and visual analog scale (VAS) scores for ocular discomfort symptoms were collected. The number, congestion, long diameter, short diameter, and area of nodules were also measured and recorded separately. Finally, eyelid margin signs, meibum quality, meibomian gland (MG) expressibility, meibomian gland dropout (MGDR), tear meniscus height (TMH), and corneal fluorescein staining (CFS) were scored. Meanwhile, adverse reactions were recorded.

**Results:** 55 nodules of 20 patients were enrolled in this study. All patients had 1 to 5 recurrences. Before treatment, they showed one or more congestive and swollen nodules with mild to moderate congestion in eyelids. The eyelid margins were congestive and swollen, with blunt rounding or irregularity. The meibum was cloudy or toothpaste-like. There were various degrees of reduction in MG expressibility, MGDR and TMH. The cornea showed scattered fluorescein staining. We can find that the VAS score, Clinician Erythema Assessment score, and size of nodules were reduced after 3 to 5 times IPL treatment, which is statistically different. Eyelid margin sign, meibum quality, MG expressibility, TMH and CFS scores were improved. MGDR had no significant change. No adverse reactions occurred during treatment.

**Conclusion:** IPL treatment is a safe and effective new approach for treating recurrent chronic hordeolum.



**PP-137****The EndoArt: 2.5 years of experience with a new corneal endothelial prosthesis for the treatment of corneal edema.**

R Lapid-Gortzak<sup>1</sup>, I van der Meulen<sup>1</sup>.

<sup>1</sup>*ophthalmology, Amsterdam UMC, Amsterdam, Netherlands*

**Objective:** To report the outcomes after 2.5 years of the Dutch cohort of the first in human safety study in terms of safety, device adherence, adverse effects, and visual acuity.

**Methods:** In a prospective safety study patients with endothelial failure, and poor visual prognosis caused by posterior segment pathology were included. Previous glaucoma or corneal surgery was an exclusion criterium. In 7 patients the diseased endothelium was removed and replaced by the Endoart, a novel artificial endothelial device. The Endoart is a discoid device placed against the corneal endothelium, thus forming a barrier against fluid egress into the corneal stroma, and allowing for equilibration of the corneal fluid and thickness and increased clarity of the diseased cornea.

**Results:** In 7 patients the endoart device was implanted. In all 7 the endoart remained adherent during the study period. Follow up time ranges from 9 months to 34 months. In 3 out of 6 patients the visual acuity improved (even though this was not expected). In 4 out of 6 a suture was used to aid initial adherence. No pathological thinning of the cornea seen, neither were any other adverse effects observed. Central cornea thickness on OCT was reduced by a mean of 26%. In 1 patient no effect was seen.

**Conclusion:** The endoart remained in situ in all patients of this cohort. In most patients intended corneal thinning and alleviation of stromal edema was observed. No ocular or other side effect or complications were seen. Adherence improved by use of a suture. The first in human endpoint of safety and adherence were met in all 7 patients.

PP-138

### Evaluation of Clinical & Histological Effects of KGF-2 & NGF on Corneal Wound Healing in an Experimental Alkali Burn Rabbit Model

S Kaya Ergen<sup>1</sup>, S Subasi<sup>2</sup>, S Furat Rencber<sup>3</sup>, G Duruksu<sup>4</sup>, Y Yazir<sup>3</sup>.

<sup>1</sup>Department of Ophthalmology, Karamursel State Hospital, <sup>2</sup>Department of Ophthalmology, <sup>3</sup>Department of Histology and Embryology, <sup>4</sup>Stem Cell and Gene Therapies Research and Applied Center, Kocaeli University Faculty of Medicine, Kocaeli, Türkiye

**Objective:** The aim of this study was to investigate the clinical and histopathological effects of keratinocyte growth factor-2 (KGF-2) and nerve growth factor (NGF) treatments in a rabbit model of corneal alkali burn.

**Methods:** After establishment of an alkali burn model, 24 rabbits were divided equally into three groups: control group, KGF-2 group, and NGF group. Clinical parameters including epithelial healing, opacification, neovascularization and central corneal thickness were evaluated on the first (D1), seventh (D7) and fourteenth (D14) days after injury. Histological parameters were examined in hematoxylin/eosin (H&E) and Masson trichrome-stained corneal sections. Immunohistochemical staining for matrix metalloproteinase-2 (MMP-2), MMP-9 and transforming growth factor- $\beta$  (TGF- $\beta$ ) was performed.

**Results:** On D14, the percentage of epithelial defect and opacity were significantly less in the KGF-2 and NGF groups compared to the control group ( $p < 0.05$ ). There was no significant difference between the groups in central corneal thickness. In the evaluation of neovascularization on D14, the NGF group was significantly less vascularized than the control group ( $p = 0.011$ ). Histological examination showed a significant increase in stromal edema and inflammation in the control group compared to both treatment groups ( $p < 0.05$ ). There was also a significant difference between the NGF and control groups in histological evaluation of epithelial repair and vascularization ( $p < 0.05$ ). When immunoreactivity of MMP-2, MMP-9 and TGF- $\beta$  was examined, there was a significant increase in the control group compared to the NGF group ( $p < 0.05$ ).

**Conclusion:** Both NGF and KGF-2 treatments were effective for early re-epithelialization and decrease in inflammation, opacity and neovascularization after corneal alkali burn. The inhibitory effect of NGF treatment on chemical-induced neovascularization was found to be superior to KGF-2 treatment.

## PP-139

**The treatment effect of cyclosporine 0.05% and artificial tears for the lid wiper epitheliopathy of dry eye after cataract surgery**

I Lin<sup>1</sup>, Y Chen<sup>2</sup>, M Tai<sup>2</sup>, C Liang<sup>3</sup>, C Chang<sup>4</sup>, D Lin<sup>5</sup>, T Wang<sup>6</sup>, T Weng<sup>2</sup>.

<sup>1</sup>Department of Ophthalmology, Nobel Eye Institute, Tainan, <sup>2</sup>Department of Ophthalmology, Tri-Service General Hospital, National Defense Medical Center, <sup>3</sup>Department of Ophthalmology, Oscar Eye Clinic, <sup>4</sup>Department of Ophthalmology, Nobel Eyes Clinic, <sup>5</sup>School of Medicine, National Defense Medical Center, <sup>6</sup>Department of Ophthalmology, Taipei Medical University Hospital, Taipei, Taiwan, China

**Objective:** Postoperative complaints of dry eye disease may occur after cataract surgery. In this report, we evaluate the effectiveness of cyclosporine 0.05% and artificial tears for the lid wiper epitheliopathy of dry eye disease after phacoemulsification surgery.

**Methods:** In the cyclosporine group, a total of 58 eyes of 42 patients newly diagnosed with dry eye disease at 1 week after phacoemulsification surgery received a twice-daily treatment of cyclosporine 0.05% eye drop (RESTASIS®, Allergan Inc., Texas, U.S.A) for 2 months, plus antibiotic eye drops (Cravit® ophthalmic solution, Santen Pharmaceutical Co., Osaka, Japan) every 3 Hours (Q3H) for one week and steroid eye drops (ECONOPRED® Plus suspension, Alcon Laboratories, Inc., Texas, U.S.A.) Q3H for one week. In the artificial tear group, 39 eyes of 30 newly diagnosed patients with dry eye disease 1 week after phacoemulsification surgery received a treatment of artificial tears (SYSTANE® ULTRA Lubricant Eye Drops, Alcon Laboratories Inc., Singapore) four times a day for 2 months, plus antibiotic eye drops (Cravit®) every 3 Hours (Q3H) for one week and steroid eye drops Q3H (ECONOPRED®) for one week. In the control group, 14 eyes of 11 newly diagnosed patients with dry eye disease 1 week after phacoemulsification surgery only received a treatment of antibiotic eye drops (Cravit®) Q3H for one week and steroid eye drops (ECONOPRED®) Q3H for one week, and did not receive any treatment of cyclosporine or artificial tears.

**Results:** Compared to the control group, grading of lid wiper epitheliopathy of upper eyelid in the cyclosporine group and artificial tear group both showed a significant decrease at 1 month ( $p=0.04$ ) and 2 months ( $p=0.02$ ), and showed a trend of decrease without significance and at 1 week; Grading of lid wiper epitheliopathy of lower eyelid in the cyclosporine group and artificial tear group both showed a significant decrease at 2 months ( $p=0.047$ ), and showed a trend of decrease without significance at 1 week and 1 month.

**Conclusion:** Our findings suggest that cyclosporine 0.05% or artificial tears eye drop can be an effective treatment for the lid wiper epitheliopathy of dry eye disease after phacoemulsification surgery.

PP-140

## Synergistic Effect of Thalidomide and Doxycycline in the Treatment of Laryngo-onycho-cutaneous (Shabbir) Syndrome

B Lee<sup>1,2,3</sup>, S Dance<sup>4</sup>, W Melbourne<sup>5</sup>, K Tran<sup>6</sup>, D Murrell<sup>7</sup>, M Coroneo<sup>1,2</sup>.

<sup>1</sup>Ophthalmology, Prince of Wales Hospital, <sup>2</sup>Faculty of Medicine, University of New South Wales, <sup>3</sup>Sydney Medical School, University of Sydney, <sup>4</sup>Ophthalmology, University of New South Wales, <sup>5</sup>Immunohistochemistry Lab, <sup>6</sup>Pathology, <sup>7</sup>Dermatology, St George Hospital, Sydney, Australia

**Objective:** Laryngo-onycho-cutaneous (LOC) syndrome is an autosomal recessive orphan disease. It is a multisystem disorder characterised by a disruption of laminin-332 synthesis in the epithelial basement membrane, resulting in extensive aberrant granulation tissue formation in the conjunctiva, upper airway, and periungual/subungual sites. Ocular complications begin in infancy, are highly aggressive, and recalcitrant to existing topical and surgical treatment modalities. LOC syndrome is associated with a reduced life span.

**Methods:** Interventional clinical study on the novel combination therapy of oral thalidomide and doxycycline in the first Caucasian male with LOC syndrome. Ocular and cutaneous tissue samples were collected pre- and post-treatment and underwent histopathological and immunofluorescent analysis.

**Results:** Ocular involvement was first observed at 15 months of age with ulceration of the eyelid and granulation tissue formation in the conjunctiva bilaterally. By 13 years, development of cicatrising conjunctivitis led to recurrent painful corneal erosions, recurrent symblepharon, epiphora, severe photophobia, and visual decline (OD: 1/60, OS: 2/36). This occurred despite maximal medical therapy consisting of lubricants, antibiotics, anti-inflammatories, and immunosuppressants, as well as numerous surgical excisions and ocular surface transplantation.

At 15 years of age, following multidisciplinary discussions, he was commenced on oral thalidomide (50mg/day) and doxycycline (100mg/day) therapy. Within 3 months, he reported significantly less pain, epiphora, and photophobia. His vision improved (OD: 6/12, OS: 6/18), he had accelerated physical growth, and no new cutaneous lesions formed. He successfully underwent further excision of granulation tissue with ocular surface transplantation. Wary of long-term safety, treatment was temporarily ceased, but this led to a resurgence of clinical disease. This was controlled by reintroduction of therapy every second day which was well tolerated. At 20 years, he had no further recurrence of lesions and maintained an improved quality of life.

Histopathology and immunofluorescent analysis of ocular and cutaneous tissue demonstrated a significant decrease in tumour necrosis factor and laminin-332 expression following treatment.

**Conclusion:** Thalidomide and doxycycline therapy may have potential in managing the ocular and cutaneous manifestations of LOC syndrome. It may also be associated with an improvement in general health and increased life span.

PP-141

**Anti-oxidative and Mucin-compensating Dual-functional Nano Eye Drops for Synergistical Treatment of Dry Eye Disease**K Jin.

**Objective:** Oxidative stress plays a central role in dry eye disease (DED), which can destroy the mucin layer on the ocular surface. The currently available eye drops are palliative and short-lived. Thus, a therapy that can continuously scavenge the overexpressed reactive oxygen species (ROS) and promote mucin production in DED is quite necessary. Thus, we have developed a synergistic nanoparticle (NP) that can treat DED by scavenging ROS and promoting mucin production. Mesoporous polydopamine (mPDA) NPs were prepared by one-pot synthesis and loaded with melatonin (Mel) and tavilermide (Tav) (mPDA@Mel-Tav).

**Methods:** The mPDA NPs loaded with 20% Mel and 2% Tav showed good cytocompatibility. Mel and Tav were continuously released from mPDA@Mel-Tav NPs, and the release of Mel was slower than that of Tav. The ROS level and apoptosis ratio were decreased in the presence of mPDA@Mel-Tav, indicating the central role of Mel in ROS scavenging and antioxidant effect. Meanwhile, Tav promoted the production of mucins on the ocular surface.

**Results:** The retention time of mPDA was longer than that of normal eye drops. The corneal fluorescence staining score of mice with DED in mPDA@Mel-Tav treatment group was lower than in other treated groups, indicating the good therapeutic effect of mPDA@Mel-Tav in DED.

**Conclusion:** In summary, we synthesized the mPDA@Mel-Tav NP eye drop to achieve a sustained release of Mel and Tav, which could effectively treat DED by scavenging ROS and promoting mucin production. This dual-functional NP represents a promising treatment strategy for DED and other multi-cause diseases.

PP-142

**The effects of *Demodex* on human ocular epithelial cells in vitro**M Tu<sup>1</sup>, R Liu<sup>1</sup>, L Liang<sup>1</sup>.

<sup>1</sup>State Key Laboratory of Ophthalmology, Zhongshan Ophthalmic Center, Sun Yat-sen University, Guangzhou, People's Republic of China

**Objective:** To investigate the effects of *Demodex* on human corneal epithelial cells (HCECs) and human meibomian gland epithelial cells (HMGEs) through an *in vitro* co-culture system.

**Methods:** Living *Demodex* mites were collected from eyelashes and quantified by the microscope, all the *Demodex* mites were picked and transferred with a self-made mite pick needle. To establish the co-culture system, a certain density of HCECs/HMGEs was inoculated in the lower layer of Transwell in advance, and then the *Demodex* was placed in the upper layer of Transwell after three-times washing by cell medium containing 5% Penicillin-Streptomycin. HCECs/HMGEs were co-cultured with living *Demodex* mites in a number-dependent manner (10/20/30). Trypan blue staining, TUNEL staining, immunofluorescence, and ELISA were performed to analyze cell viability, apoptosis, functional phenotype, and proinflammatory cytokines response, respectively.

**Results:** 80% of *Demodex* mites maintained normal activity and survived for more than 5 days in the co-culture system. Compared with the control group, there was no significant difference in the cell viability and apoptosis of HCECs and HMGEs in the 10/20/30 living *Demodex mites* co-culture group. Immunofluorescence showed that 30 *Demodex mites* failed to induce the expression of cytokeratin 10 (CK10) in HCECs. Ki67 and LipidTox staining also showed that 30 *Demodex* mites could not affect the differentiation and lipid production of HMGEs. There was also no marked alteration in the secretion of proinflammatory cytokines (TNF- $\alpha$ , IFN- $\gamma$ , GM-CSF, IL-1 $\beta$ , IL-6, IL-8) in HCECs and HMGEs stimulated by *Demodex*.

**Conclusion:** *Demodex* showed no significant effect on cell viability, apoptosis, functional phenotype, and proinflammatory cytokines response of HCECs and HMGEs within an *in vitro* co-culture system, suggesting that *Demodex* may play an indirect pathogenic role in the *Demodex*-related ocular surface diseases.

PP-143

**MSC-EVs treat dry eye disease by regulating dendritic cells and promoting tissue repair**R Guo<sup>1</sup>, K Hu<sup>1</sup>.<sup>1</sup>Medical school of Nanjing University, Gulou district, Nanjing, Jiangsu, People's Republic of China

**Objective:** In this study, we explored the therapeutic efficacy of Mesenchymal stromal cells -derived extracellular vesicles (MSC-EVs) in a mouse model of dry eye disease (DED) and assessed its ability to modulate immune responses and promote tissue repair in dry eye disease.

**Methods:** DED was induced in female C57BL/6 mice by exposure to controlled environment chamber and subcutaneous injection of 0.5mg/0.2mL scopolamine hydrobromide four times per day for 14 days. Mice were grouped and treated with either MSC-EVs or PBS eye drops for comparison purposes. Samples of cornea, conjunctiva and draining lymph nodes were collected after treatment. Dendritic cells (DCs) were detected by immunofluorescence and flow cytometric analysis to assess its number and the expression of MHC-II and CD86. Th17 cells were detected by flow cytometric analysis to evaluate the antigen-presenting function of DCs. RT-qPCR was performed to determine the mRNA expression of inflammatory cytokines in cornea and conjunctiva. In vitro, human corneal epithelial cells (HCEC) were cultured in hyperosmotic media and treated with MSC-EVs. Then cell viability was assessed by CCK8, and expression of inflammatory cytokines was detected by RT-qPCR.

**Results:** MSC-EVs-treated mice presented more tear production ( $P < 0.05$ ) and lower corneal fluorescein staining scores ( $P < 0.05$ ). DED upregulated the number of DCs and their maturation level, and treatment with MSC-EVs effectively reduced the number of DCs and suppressed the expression of MHC-II ( $P < 0.01$ ) and CD86 ( $P < 0.05$ ). Reduction of Th17 cells was also observed in cornea and draining lymph nodes. Compared with untreated control group, expression of inflammatory cytokines was downregulated in cornea and conjunctiva of MSC-EVs-treated mice. In vitro, MSC-EVs protected HCECs against loss of cell viability induced by hyperosmotic stress. MSC-EVs also reduced the expression of inflammatory cytokines, including TNF- $\alpha$ , IL-1 $\beta$ , IFN- $\gamma$  and IL-6.

**Conclusion:** The results of our study revealed the role of MSC-EVs in regulating DC functions and promoting tissue regeneration in DED mice. MSC-EVs hold a great promise as a novel treatment method for DED and other ocular surface diseases.

PP-144

### A Comparison of Outcomes & Complications - Deep Anterior Lamellar Keratoplasty vs Penetrating Keratoplasty in Keratoconus Patients

A Cheema, A *Khattak*.

**Objective:** To compare visual acuity, refraction, topography, and complications of deep anterior lamellar keratoplasty (DALK) and penetrating keratoplasty (PKP) performed in patients with keratoconus (KCN).

**Methods:** In this retrospective interventional non-randomized clinical study, patients with moderate to severe KCN that underwent either PKP or DALK for optical corrections were enrolled. The final outcome analysis was performed after complete suture removal for both groups of patients. Best corrected visual acuity, spherical equivalent, refractive cylinder, average keratometry, corneal astigmatism, and endothelial cell density as well as early and late complications such as cataract, glaucoma, corneal edema, elevated intraocular pressure without visual field defect or optic disk changes, rejection, loose suture, and re-suturing were compared.

**Results:** Two hundred and seven eyes were enrolled: 108 eyes underwent DALK, and 99 eyes underwent PKP for keratoconus. The mean follow-up time was  $28.06 \pm 12.62$  months for DALK group and  $29.29 \pm 12.71$  months for PKP. The study groups demonstrated comparable final outcome in terms of best corrected visual acuity:  $0.25 \pm 0.22$  LogMAR and  $0.28 \pm 0.24$  LogMAR ( $p = 0.415$ ), spherical equivalent:  $-4.80 \pm 4.55D$  and  $-3.58 \pm 3.58D$  ( $p = 0.067$ ), refractive cylinder:  $-3.37 \pm 2.00D$  and  $-4.00 \pm 2.15D$  ( $p = 0.061$ ), average keratometry:  $45.51 \pm 2.30D$  and  $44.85 \pm 2.36D$  ( $p = 0.077$ ), corneal astigmatism:  $4.89 \pm 3.07D$  and  $4.63 \pm 2.61D$  ( $p = 0.569$ ) in DALK ( $n = 85$ ) and PKP ( $n = 72$ ), respectively. However, the postoperative endothelial cell density in DALK ( $n = 61$ )  $2250 \pm 450$  cell/mm<sup>2</sup> differs significantly from it in PKP ( $n = 55$ )  $1795 \pm 616$  cell/mm<sup>2</sup>  $p < 0.001$ . Eyes that had DALK ( $n = 99$ ) had significantly more risk of loose suture (RR 5.2) and re-suturing (RR 3.6) than PKP ( $n = 108$ ). However, the risk of cataract following DALKs was less than PKP (OR 0.4).

**Conclusion:** The vision, refractive error, and corneal astigmatism following DALK and PKP were comparable; however, DALK had lower incidence of long-term complications.



PP-145

**Sutureless Femtosecond laser-assisted DALK: An innovative technique.**S Khullar<sup>1</sup>, A Sati<sup>1</sup>, S Kumar Mishra<sup>1</sup>.<sup>1</sup>Ophthalmology, Government, NEW DELHI, India

**Objective:** To evaluate the outcomes of suture less pre-descemetic deep anterior lamellar keratoplasty (DALK) assisted by femtosecond laser.

**Methods:** Prospective, non-randomized clinical study.

Ten eyes with corneal scar underwent deep anterior lamellar keratoplasty.

Femto second laser was used to create cuts on both donor and recipient corneas.

Outcome measures include best corrected visual acuity, keratometry and complications.

**Results:** Mean age of 10 patients (6male and 4 females) was  $64.7 \pm 17.7$  years with a mean follow-up of  $9.2 \pm 2.0$  months.

Mean corneal thickness at apex and mean corneal depth of corneal scar was  $376 \pm 53$  mm and  $328 \pm 51$  mm respectively.

Mean thickness /diameter of donor and recipient lenticules were  $370 \pm 102$  mm /  $7.5 \pm 0.2$  mm and  $325 \pm 90$  mm /  $7.5 \pm 0.2$  mm respectively.

Mean best corrected visual acuity and astigmatism at 6 months postoperative were  $0.47 \pm 0.16$  (logMaR) and  $2.1 \pm 0.16$  respectively.

No intraoperative and postoperative complications .

**Conclusion:** Suture less femtosecond laser assisted deep anterior lamellar keratoplasty is a a novel technique with absence of suture related complications.

## PP-146

**Comparison of Three Different Intense Pulsed Light Devices for Meibomian Gland Dysfunction – objective and subjective outcomes**

J Marques, C Castro<sup>1</sup>, A Marta<sup>1</sup>, P Baptista<sup>1</sup>, D José<sup>1</sup>, P Sousa<sup>1</sup>, I Barbosa<sup>1</sup>.

<sup>1</sup>Centro Hospitalar Universitário do Porto, Porto, Portugal

**Objective:** To study the benefit of intense pulsed light (IPL) with three different devices for the treatment of meibomian gland dysfunction, regarding an objectively ocular surface analysis and patient reported outcomes.

**Methods:** Prospective interventional longitudinal study that included 93 patients allocated to 3 groups (31 patients in each group): group 1 (IPL with Eye-Light® followed by low level light treatment with My Mask®), group 2 (IPL with E>Eye®, E-SWIN) and group 3 (IPL with Thermaeye Plus®). Subjects were evaluated at baseline and 1 month after the last treatment session with (1) IDRA® Ocular Surface Analyzer reporting non-invasive break-up time (NIBUT), eye blink quality (EB), lipid layer thickness (LLT), loss area of the meibomian glands (LAMG) and tear meniscus height (TMH); (2) tear osmolarity (TearLab® Osmolarity System); (3) Schirmer test type 1 and (4) corneal fluorescein staining (CFS). Symptoms were analyzed with the validated OSDI questionnaire. Paired t-tests were used for longitudinal comparisons within each group and ANOVA tests with Bonferroni post-hoc analysis for comparison among multiple groups. Chi-square test was used for categorical variables. Significance was set at  $p < 0.01$ .

**Results:** Significant changes after treatment were, in group 1, LLT (+19.3um,  $p < 0.001$ ), EB (+9.8%,  $p = 0.002$ ), Schirmer test (+1.6mm,  $p = 0.009$ ), and OSDI (-22.6,  $p < 0.001$ ); in group 2, LLT (+14.3um,  $p < 0.001$ ) and OSDI (-24.4,  $p < 0.001$ ) and in group 3, LLT (+10.9um,  $p = 0.002$ ) and OSDI (-20.0,  $p < 0.001$ ). A three-group comparison showed a significant difference in EB improvement ( $p < 0.001$ , significant between groups 1 and 2 and groups 1 and 3) and LLT ( $p = 0.001$ , significant between groups 1 and 3). The rate of CFS increased by 5% in group 1 ( $p = 0.001$ ) and decreased by 56% ( $p = 0.005$ ) and 45% ( $p = 0.005$ ) in groups 2 and 3. The rate of patients that reported feeling “better” after treatment was 81%, 97% and 94% ( $p = 0.006$ ), in groups 1, 2 and 3 respectively.

**Conclusion:** Dry eye symptoms and objectively measured lipid layer seem to improve with the three devices. Aqueous tear production and eye blink quality may further improve with the Eye-Light®. Additionally, the improvement in the lipid layer may also be superior in the latter. However, the objective superiority of Eye-Light® was not accompanied by better patient reported outcomes. The slight differences among the devices and the apparent increase in corneal staining should motivate future investigation.

**PP-147****Comparison of sicca syndrome's clinical aspects during Gougerot Sjögren's syndrome according to the etiology: prospective study.**N Benmerzouga Mahfoudi.**Objective:** 473 / 5 000

The main etiologies of secondary GSS are: rheumatoid arthritis (RA), thyroiditis, scleroderma and systemic lupus erythematosus (SLE). The objective of our study is to describe the clinical aspects of severe sicca syndrome encountered during secondary GSS and to identify the clinical particularities according to the etiology.

**Methods:** We carried out a non-randomized monocentric prospective descriptive study conducted over a period of 3 years including 74 eyes of 60 patients. We included patients with severe dry eye syndrome secondary to GSS's syndrome with a Schirmer test less than or equal to five millimeters. All patients underwent an examination of the best corrected visual acuity, a complete ophthalmological examination and an eye tone measurement. We evaluated the state of the ocular surface by performing an examination before staining (Schirmer 1 test, static and kinetic examination of the eyelids as well as the Meibomian glands. We examined the conjunctiva and the cornea after staining with fluorescein and lissamine green, and perform a measurement of the BUT as well as the height of the lacrimal meniscus. We completed the examination by performing a corneal topography.

**Results:** The average age of our patients was 58.02 years  $\pm$  11.15 with extremes ranging from 45 to 88 years, with a sex ration of 8 men for 52 women. We found 38 cases of rheumatoid arthritis, 14 cases of thyroiditis, 5 of scleroderma and 3 cases of systemic lupus erythematosus. The most serious corneal damage was found in the case of rheumatoid arthritis: the best corrected visual acuity was less than 1/20th in 21% of cases, 72% of cases which presented stage 3 OSS, 27% of those who presented with a corneal ulcer and 20% of those who presented with corneal new vessels. 20% of patients with rheumatoid arthritis had zero schirmer and 32% had BUT less than 2 seconds. The HOA score analyzed by aberrometry was less than 0.25 in 41% of patients.

**Conclusion:** The analysis of the results obtained and their comparison with the data of the literature made it possible to confirm the seriousness of the damage to the ocular surface secondary to the sicca syndrome during rheumatoid arthritis. Systemic lupus erythematosus remains a rare condition responsible for few serious lesions. knowledge of these clinical aspects and their severity will prevent the occurrence of disabling ocular complications by systematically carrying out a complete ocular examination during GSS, especially during rheumatoid arthritis

PP-148

**Drug-Repository contact lens hasten healing & minimize antimicrobial loading doses in bacterial keratitis: RCT results**L Daniel Raj Ponniah.

**Objective:** To compare efficacy of novel drug-depo CL that increases corneal antimicrobial contact time with conventional antibiotic alone in bacterial keratitis(BK)

**Methods:** Bacterial keratitis was randomized into Group-1, treated with a topical antimicrobial alone, in Group-2, a drug reservoir contact lens with characteristic dual base curves resulting in a central reservoir along with fenestrations to enable capture of applied topical antimicrobial, was implanted. In both the groups, moxifloxacin 0.5% in a standard regimen of 4-Hrly for two days, 6-Hrly for next 12 days was instituted. Ulcer size, Bacterial Keratitis Severity Scores, depth, AC reactions, corneal haze were studied. Followed-up on 12 hours, Days-1,3,5 & 14. Pain was evaluated on a 10 pt scale every visit. A study on the availability of the drug in the central reservoir was analyzed over a time curve

**Results:** 40 cases were randomised. 3,2 cases in Groups 1 & 2 did not complete the study. Presenting pain was 7.88+/- 0.70 in Gr-1, 7.67+/-0.78 in Gr-2, which reduced by 4.77 points in Gr-2 & 1.88 points in Gr-1 at Day-1( $p<0.001$ ), by 6.13 points in Gr-2 by Day-3( $p<0.001$ ). Corneal-infiltration (BK severity) on presentation in Gr-1 was 2.62+/-0.82mm, in Gr-2 was 2.66+/-0.39mm( $p=0.92$ ). Resolution by 12 hours in Gr-2 was 0.28mm, in Gr-1 was 0.04mm, by Day-1 was 0.94mm in Gr-2, 0.18mm in Gr-1( $p=0.03$ ), by Day-3, 1.96 in Gr-2 Vs 0.93 in Gr-1( $p<0.0001$ ), completely resolved in Gr2 within 5 days and within 2 weeks in Gr1. AC-reaction resolved in Group-2 faster within 3days. Drug availability in reservoir, the pre-corneal space was evidenced upto 4 hours

**Conclusion:** The concept of using a novel drug repository contact lens is effective in prolonging corneal antimicrobial availability and drug contact time over the lesion and has demonstrated in this study that corneal healing hastens, which may affect the overall outcomes in bacterial keratitis. Using a drug-depo contact lens may reduce the regimen of antibiotics, decrease treatment burden on the medical staff, improve patient tolerance, and reduced toxicities, overcoming the loading dose concept

\*Author has no financial interests

PP-149

## Influence Of Cataract Surgery On Meibomian Glands, Tear Film & Ocular Surface In Diabetic & Non-Diabetic Population

L Daniel Raj Ponniah.

**Objective:** To evaluate and compare the morphological changes of meibomian glands and the functional changes of the tear film and its impact in diabetic and non-diabetic subjects who underwent uneventful phacoemulsification procedures

**Methods:** A Prospective investigator masked comparative clinical trial. Cataracts with and without Diabetes were recruited based on age & grouped as Group 1 (No DM and age <60 yrs; N=43) Group 2 (DM and age <60 yrs; N=39) Group 3 (No DM and age >60 yrs; N=51), Group 4 (DM and age >60 yrs; N=67). Preoperative meibography and functional tear film assessments using quantitative measurements of tear meniscus studies, non-invasive tear break-up time (NIBUT), blink rate were analysed & compared with 21 days and 3 months post-surgery. Ocular Protection Index (OPI) was calculated as a function of ocular surface health by dividing tear break up time by interblink interval.  $OPI < 1$  was considered susceptible to surface damages

**Results:** Baseline NIBUT was 11.80, 9.50, 10.30 & 7.88 sec. respectively across Gr 1 through 4, which reduced to 8.34, 7.31, 7.36 and 6.11 21days post surgery, restored to baseline at 3 months. Mean OPI was 1.37 at baseline, 0.97 at 21days, 1.10 at 3 months. ANOVA for OPI had significant time effect, Wilk's Lambda = 0.813,  $p < 0.0001$ . Preop OPI was 1.88, 1.26, 1.67 and 0.88 respectively across Gr 1 through 4, which reduced to 1.68, 0.91, 1.03 and 0.75 at 21days, restored to baseline at 3 months. Gr-4 had poor OPI score of less than 1 at all time points No significant difference in tear meniscus height across the groups. Age adjusted DM influence on Meibomian gland- loss was 12.1% compared with non-DM, 6.64%. Elderly, diabetics were 6.29 & 1.79 times more susceptible to damages respectively than their counterparts.

**Conclusion:** Subjects over 60 years of age irrespective of concomitant DM had borderline OPI, are susceptible to develop surface damages post cataract surgery. Subjects with DM irrespective of age had borderline OPI, likely to suffer surface damages post- cataract. Subjects who are over 60 years with co-existing DM had suboptimal OPI & require a long-term ocular surface protectors.

\*Author has no financial interests



**PP-150****Application of low temperature plasma ablation in the treatment of Recurrent Corneal Erosions**

X Huang, Y zhang.

**Objective:** To observe the therapeutic effect of low temperature plasma ablation in the treatment of patients with recurrent corneal erosions (RCE).

**Methods:** From 2020 to 2022, a total of 37 voluntary participants with unilaterally RCE were enrolled in this study. 37 eyes of 37 patients were treated with low temperature plasma ablation. After operation, all patients were followed up regularly at the outpatient clinic at 1 week, 4 weeks, 3 months, and 6 months. During every visit, each patient underwent an evaluation of ocular symptoms that utilized: visual acuity, intra-ocular pressure, slit-lamp biomicroscopic examination, dry eye analysis, corneal topography, optical coherence tomography (OCT) and corneal in vivo confocal microscopy (IVCM). A questionnaire regarding the preoperative and postoperative difference in the intensity of pain and frequency of corneal erosion was provided.

**Results:** OCT images revealed that the recurrent deposits were located primarily in the epithelial layer and impacted the anterior corneal stroma (80–150um). Morphologic abnormalities included deformation and relaxation of corneal epithelium, disorganized stromal fibers, reduced nerve fiber density and disordered organization, and inconspicuous keratocyte nuclei, which were occasionally accompanied with decreased keratocyte and endothelial cell density. Of the patients who had low temperature plasma ablation, 26 eyes (70.3%) were completely symptom free, 8 eyes (21.6%) had mild pain but no evidence of recurrent corneal erosion, which could be related to dry eye diseases (DED), and 3 (0.08%) eyes had repeated episodes of recurrent corneal erosion. In one case, corneal edema astigmatism became larger, which may be related to the high instantaneous energy when the operation did not flush timely, and recovered after 6 months. There were no obvious difference in visual acuity, intra-ocular pressure, corneal curvature and corneal thickness before and after treatment. IVCM showed solid and tightly connected epithelial cells after low temperature plasma ablation. No other adverse reaction was observed during follow-up.

**Conclusion:** Low temperature plasma ablation is an effective and simple procedure to treat patients with recurrent corneal erosions. It has been shown to reduce both the frequency and intensity of symptoms.

PP-151

**Red Filter Meibography by Smartphones in patients with Meibomian Gland Dysfunction: a Pilot Study**G Anissa, R Nora, S Widyawati, R Sitompul, P Yusuf.

**Objective:** Meibomian Gland Dysfunction (MGD) is an abnormality of Meibomian glands which commonly encountered in practice and is a leading cause of Dry Eye Disease. Meibography is an imaging technique of the Meibomian glands but is rarely performed because infrared devices are costly and not readily available. This study attempted a novel technique for assessing Meibomian Gland dropout using the red filter meibography by smartphone and determining its validity and reliability compared to the infrared technique of meibography.

**Methods:** Meibomian glands were photographed using two smartphones (Samsung S9 and iPhone XR) on a slit-lamp with an added custom red filter. An analytical cross-sectional study was done with a total of 35 subjects (68 eyes) with suspected MGD based on symptoms and lid morphological abnormalities. Images were assessed subjectively using meiboscore by the two raters and dropout percentages were objectively assessed by ImageJ.

**Results:** Red filter meibography by smartphones produced adequate images for daily clinical use especially to demonstrate the meibomian glands to patients using a simple and inexpensive procedure. However, low agreement in meiboscore and dropout percentages indicates that the image quality was not optimal for grading. Several shortcomings include very bright light reflections, low contrast, and more difficulties with visualization in the upper lid. We also found that subjective grading using meiboscore was not ideal as inter-rater reliability showed no agreement between two raters and intra-rater reliability demonstrated weak agreement in rater 1 and no agreement in rater 2.

**Conclusion:** We successfully demonstrate the potential of a non-contact, affordable, and simple technique of red filter meibography by smartphones as an alternative to the infrared system. However, the validity and reliability of this technique were not satisfactory in evaluating dropout. Further research on developing a standard procedure for image capture and refinement of the red filter must be carried out to produce high-quality images. Moreover, additional study on subjective assessment of meibography was deemed necessary due to poor results of intra- and inter-rater reliability.



PP-152

**Artificial cosmetic iris implant: comparison of 2 different techniques for removal**M Calatayud-Pinuaga.

**Objective:** Cosmetic artificial iris implants are available in the market for any patient even though the truth is there is no study based on clinical evidence regarding safety, tolerability and long term results, but there are some papers describing complications like corneal decompensation, glaucoma, cataracts and other eye diseases that are directly related with this prosthesis.

**Methods:** A 32-year-old young woman came to our clinic in December 2020 with glaucoma diagnosis. She referred cosmetic iris implants in both eyes 4 years ago in Lebanon, with good visual and aesthetic results according to her opinion. Uncorrected visual acuity was 0.8 right eye and 1.0 left eye. Clinical examination revealed mild ptosis in both eyes with anterior chamber blue-colored iris prosthesis in both eyes, corneal epithelial edema in the right eye with peripheral bulla and clear cornea left eye. Intraocular pressure (IOP) was 40 mmHg.

At the operating room we performed a kind of "divide and conquer" the prosthesis in small pieces with retina forceps and scissors, but the material is very difficult to manipulate, slippery and difficult to move without damaging the endothelium. This iris device has also 3 hooks which are embedded in the peripheral trabeculum and iris, so the more you move it, the higher the risk of angle bleeding. For the second eye we used bigger instruments with good results and shorter surgery time. We describe both surgeries in 2 different videos.

**Results:** One week after surgery, BCVA right eye was counting fingers, left eye 1.0. Right eye cornea had edema with bullae in the lower area, improving with bandage contact lens. The patient also was diagnosed of map-dot-fingerprint epithelial dystrophy, which complicated more the management. Left eye presented no complications and intraocular pressure was under control with topical treatment. DSAEK was performed after one month in the right eye to treat decompensated cornea

**Conclusion:** Needless to mention our very bad opinion about this prosthesis, which should be prohibited by health authorities, we consider there is a rule which should be followed when planning removal: the less pieces, the easiest will be manipulation and extraction. The bigger the fragments allow a better traction with forceps. The incision size should be our last concern in these cases, we recommend a 3.0 blade to open the limbus, long Vannas scissors and Pac-Man Zaldivar-Kraff ICL forceps to make easier the procedure and diminish the iatrogenic endothelial loss.

PP-153

**Assessment of systemic inflammatory markers in Dry eye Disease patients in a tertiary care hospital**A Majumdar<sup>1</sup>, J Dutta<sup>2</sup>.

<sup>1</sup>Ophthalmology, Regional Institute of Ophthalmology, Kolkata, Kolkata, <sup>2</sup>Ophthalmology, Government Medical college and Hospital, Purulia, Purulia, India

**Objective:** To assess the Monocyte-to-high density lipoprotein (HDL) cholesterol ratio (MHR), neutrophil-to-lymphocyte ratio (NLR), as an indicator of inflammation in patients with Dry eye diseases patients.

**Methods:** It is an institutional observational prospective study. 76 patients of Dry eye Disease patients were selected who had come to OPD, had OSDI score  $\geq 13$ , Schirmer I test (without anesthesia) was  $\leq 5$  mm/5 minutes and/or break up time  $< 10$  seconds. Serum NLR, MHR were determined in those patients (Group A) and also in 76 similar age, gender-matched population (Group B), those who have no dry eye disease, and compared.

**Results:** Before treatment, the mean MHR value was  $16.83 \pm 8.23$  in Group A and  $7.05 \pm 4.03$  in Group B ( $p < 0.001$ , t-test). The mean NLR value was  $3.66 \pm 1.42$  in group A and  $1.86 \pm 0.55$  in group B ( $P = 0.002$ , t-test).

**Conclusion:** There is a statistically significant increase in systemic inflammatory biomarkers in dry eye patients

PP-155

**Corneal Perforation after Immune Checkpoint Inhibition Treatment**Z Chen<sup>1</sup>, L Liang<sup>1</sup>.<sup>1</sup>Zhongshan Ophthalmic Center, Guangzhou, People's Republic of China

**Objective:** Immune checkpoint inhibition (ICI) in advanced cancer therapy related to T-cell mediated autoimmune response may be associated with immune keratitis and corneal perforation, a rare but serious adverse event. This study aims to describe 3 patients who developed corneal perforation after treatment with the programmed death 1 (PD-1) axis inhibitor monotherapy or plus tyrosine kinase inhibitor therapy.

**Methods:** Retrospective review of three patients treated with sintilimab plus arotinib, nivolumab plus regorafenib, and pembrolizumab for metastatic lung adenocarcinoma, metastatic colon adenocarcinoma and lung squamous cell carcinoma, respectively, who presented with immune keratitis and corneal perforation. Slit-lamp examination and in vivo confocal microscopy (IVCM) were used to characterize cornea abnormalities.

**Results:** Immune keratitis in both eyes developed at 2<sup>nd</sup>-4<sup>th</sup> cycle of anti-PD-1 treatment in those patients. Bilateral corneal perforation was noted in 1 patient and unilateral corneal perforation was noted in 2 patients at 3-6 months after cessation of anti-PD-1 therapy. The infiltration and activation of lymphocytes and Langerhans cells was detected in corneas under IVCM in all patients. Topical steroid and tacrolimus were used in all patients. Multilayer amniotic membrane transplantation was performed successfully in 4 eyes with corneal perforation.

**Conclusion:** Immune keratitis related to anti-PD-1 therapy may be persistent and progress to perforation even after cessation of anti-PD-1 therapy.

**PP-156** **$\epsilon$ -poly-L-lysine-modified polydopamine nanoparticles for targeted low-temperature photothermal therapy of MRSA-induced keratitis**

W Fan.

**Objective:** To investigate  $\epsilon$ -poly-L-lysine (EPL) modified polydopamine nanoparticles (EPL@PDA NPs) based antibacterial photothermal therapy (aPTT), and cope with intractable methicillin-resistant *Staphylococcus aureus* (MRSA) induced keratitis.

**Methods:** PDA NPs were fabricated via the self-polymerization of dopamine in alkaline aqueous conditions, and surface-modified by cationic EPL. The in vitro bactericidal activities of the PTT platform were characterized by observing the selective adhesion between EPL@PDA NPs and MRSA and calculating the sterilization rate. A murine MRSA-induced keratitis model was constructed to investigate the in vivo anti-infection effect. After the treatments, slit lamp micrograph and corresponding clinical score, and histopathologic and immunohistochemical evaluation were utilized to evaluate the severity and recovery of corneal infection. Besides, blood examination and major organs histological evaluation were conducted to investigate the biotoxicity of the PTT platform.

**Results:** EPL@PDA NPs exhibited brilliant concentration-dependent and laser intensity-dependent photothermal properties. The positively charged EPL@PDA NPs were inclined to adhere to the bacteria, which was observed via a scanning electron microscope (SEM). According to the results of typical dilution-plate method, the sterilization rate of EPL@PDA NPs was up to 99.96% ( $300 \mu\text{g mL}^{-1}$ ). As for the in vivo anti-infection activity, EPL@PDA NPs-based low-temperature ( $41.8^\circ \text{C}$ ) PTT significantly reduced the bacteria burden and accelerated the recovery progress. Further H&E and immunohistochemical evaluation indicated that the PTT also contributed to relieving inflammation and restoring the regularity of corneal structures. In addition, EPL@PDA NPs-based PTT platform displayed brilliant biocompatibility in the hematology and tissue morphology examination.

**Conclusion:** EPL-modified PDA nanoparticles (EPL@PDA NPs) were synthesized to conduct a targeted PTT-mediated antibacterial process and effectively manage MRSA-induced keratitis under low ambient temperature. Apart from maintaining the balance between bactericidal performance and tissue protection, this platform exhibited excellent biocompatibility. Unlike conventional antibiotics-based keratitis treatment, EPL@PDA NPs based PTT does not encourage the evolution of resistant bacteria. As a prospective antimicrobial PTT platform, it displays a huge clinical transformation potential for the management of intractable bacterial keratitis.

PP-157

## Cell Wall Destruction and Internal Cascade CDT/PDT/PTT Synergistic Antifungal Strategy for Fungal Keratitis Treatment

Y Ye<sup>1</sup>, J He<sup>1,2</sup>, M Zhou<sup>1,2</sup>, K Yao<sup>1</sup>.

<sup>1</sup>Eye Center, The Second Affiliated Hospital of Zhejiang University, School of Medicine, <sup>2</sup>Institute of Translational Medicine, Zhejiang University, Hangzhou, People's Republic of China

**Objective:** Fungal keratitis is one of the most common blind-causing diseases. Cell wall and biofilm are two important protective factors for the unsatisfactory treatment. The cell wall provides a protective effect against environment and plays an important role in pathogenicity and adherence. Besides, biofilm is a complex of extracellular matrix and microorganisms with the resistance to antifungal agents. Hence, the strategy to eradicate fungi with antibiofilm ability is urgently needed. Here, AgCu<sub>2</sub>O-EDTA nanoparticles (AgCuE NPs) were developed to efficiently kill fungi, disrupt the structure and integrity of cell wall and treat fungal keratitis with biofilms destruction.

**Methods:** AgCuE NPs were developed through template method. The characterization of AgCuE NPs were tested. Fungal colony count, cell wall staining, TEM, and gene transcriptome test were used for *in vitro* antifungal efficacy on *C. albicans*. The antibiofilm effect to prevent and destruct biofilms was verified. *In vivo* anterior segment images, cornea confocal microscope and ERG were applied to verify the treatment effect. Bimodal imaging monitors including OCT and PA were applied for AgCuE NPs and therapy. Etiological and histological analyses were used to analyze the antifungal and anti-inflammatory effects.

**Results:** AgCuE NPs were developed, the characterizations of photothermal enhanced Fenton-like and photocatalytic ROS generation were tested. Both *in vitro* and *in vivo*, the AgCuE NPs could eradicate *C. albicans* relied on the cascade synergistic effect of ion-chemotherapy, chemo-dynamic therapy (CDT), photodynamic therapy (PDT), and mild photothermal therapy (PTT) with cell wall ruptured and biofilm destruction. The group treated with AgCuE NPs plus NIR reached an optimal effect with the lowest clinical grading scale. The bimodal imaging could both monitor the drug residue and therapy effect which was detected after 48 h. Pathology analysis verified that AgCuE could kill fungi, reduce inflammation and promote wound healing with well biosafety.

**Conclusion:** In this study, we developed the AgCuE NPs to eliminate *C. albicans*, destroy the biofilm and achieve the therapeutic efficacy against fungal keratitis, based on the rupture of the fungal cell wall and synergistic therapy of ion-chemotherapy, CDT, PDT and mild PTT. The AgCuE could remain on the corneal surface and monitored through OCT and PA. Importantly, the treatment did not show toxic side effects and dysfunction with great potential for clinical translation.

PP-158

## Cell Wall Specific Degradation and Intrinsic Metabolic Interference Antifungal Strategy for Fungal Keratitis Treatment

J He<sup>1,2</sup>, Y Ye<sup>1</sup>, K Yao<sup>1</sup>, M Zhou<sup>1,2</sup>.

<sup>1</sup>Eye Center, The Second Affiliated Hospital of Zhejiang University, School of Medicine, <sup>2</sup>Institute of Translational Medicine, Zhejiang University, Hangzhou, People's Republic of China

**Objective:** Fungal keratitis has been one of the common corneal infection blind-causing diseases. In general, frequent topical antifungal drugs are the main choice to treat fungal keratitis in clinical practice. However, the limited curative effect and inappropriate administration cannot meet all clinical requirements. Hence, alternative antifungal strategies with effective therapeutic competencies are warranted to treat fungal keratitis.

**Methods:** Therefore, we present a glucan degradation enzyme, and gallium ions integrated nanosystems (LyMGa), which could specifically degrade cell wall and biofilm matrix, then kill the *Candida* through the released-gallium ions. The antifungal effects were evaluated in *Candida* and their biofilm, including preventing biofilm formation and destructing mature biofilms. The underlying mechanisms of gallium ions were investigated using a gene transcriptome assay. We further evaluated *in vivo* antifungal effects and cornea healing in fungal keratitis models. Moreover, the safety was systematically verified from the cell to the mouse.

**Results:** LyMGa nanosystems were successfully synthesized, with uniform gallium ions loading and nearly 100% enzyme encapsulation. The gallium ions and enzyme could be sustained-released from LyMGa. The results of the morphology test revealed that the cell wall and biofilm matrix degraded, and the cytoplasm leaked after incubated with LyMGa nanosystems. Further, many genes of *Candida* were upregulated or downregulated after treatment with LyMGa, including genes related to antioxidant, iron-related competitive metabolism, and other related aspects. In a fungal keratitis mouse model, the LyMGa treated group had less corneal epithelium defect, relieving local inflammation, and physiological functions. The retention and release behavior of the LyMGa could be visualized by the Raman-photoacoustic imaging during the treatment process. Finally, LyMGa showed great advantages in biological safety, and there are no obvious ophthalmology and toxic side effects.

**Conclusion:** We designed enzyme-metal ions co-loaded nanosystems for the specific degradation both of cell walls and their biofilm matrix, then cascade intrinsic metabolic interference by released gallium ions. The novel antifungal strategy achieved excellent therapeutic capability against fungal keratitis with negligible toxicity. Our work may provide a potential approach for the effective treatment of fungal keratitis in clinical practice.

PP-159

**Reversed manual dissection: an optional surgical technique for obtaining lamellar donor grafts**X Liu<sup>1,2</sup>, Y Bi<sup>1,3</sup>.

<sup>1</sup>Ophthalmology, Tongji Hospital, School of Medicine, Tongji University, Shanghai, <sup>2</sup> Ophthalmology, Guizhou Provincial People's Hospital, Guiyang, <sup>3</sup>Tongji Eye Institute, Tongji University School of Medicine, Shanghai, People's Republic of China

**Objective:** To evaluate surface quality and thickness uniformity of lamellar donor grafts using reversed manual dissection (RMD) in porcine corneas and to compare visual outcomes and corneal densitometry (CD) at the donor-host interface after anterior lamellar keratoplasty (ALK) for keratoconus patients using RMD and conventional manual dissection (CMD).

**Methods:** In animal experiment, 48 porcine corneas were divided into 6 groups. Each group contained 8 corneas. For Groups I, II, and III, 30%, 50%, and 70% of the entire corneal thickness was dissected using CMD. For groups IV, V, and VI, 70%, 50%, and 30% of the entire corneal thickness was dissected using RMD. The residual stromal thickness was examined by anterior segment optical coherence tomography to assess the thickness uniformity and scanning electron microscopy (SEM) to assess the surface quality. In clinical trial, 18 progressive keratoconus eyes who underwent ALK. Nine donor grafts were dissected using RMD and the other nine were dissected using CMD. Best corrected visual acuity (BCVA), topographic parameters, CD and endothelial cell density (ECD) were conducted at 6, 12 and 24 months after surgery.

**Results:** In animal experiment, the thickness uniformity of the lamellar grafts between each paired group was not significantly different. The qualitative surface roughness grading evaluated by masked observers through SEM was significantly higher in RMD groups ( $p < 0.001$ ). The quantitative surface roughness grading acquired from the Mountains software was significantly lower in RMD groups ( $p < 0.001$ ). In clinical trial, BCVA in RMD group was better than that in the CMD group ( $p = 0.044, 0.039$ , respectively) at 12 and 24 months postoperatively. There was no significant difference in the thinnest point of cornea, mean keratometry and ECD between the two groups. Compared to RMD group, CD was statistically higher in CMD group. CD of central layer and donor-host interface were strongly correlative to BCVA ( $r_s = 0.630, p = 0.005$ ).

**Conclusion:** We firstly provided RMD as an optional surgical technique for preparing donor grafts. In animal experiment, though the thickness uniformity of RMD is comparable to that of CMD, a smoother surface with fewer ridges and roughness is achieved in RMD. In clinical trial, the use of RMD made the surgical outcome better than CMD in visual acuity and corneal transparency. CD could detect subclinical haze and the interface densitometry could provide more information about corneal clarity.

**PP-160****Efficacy of Intense Pulsed Light Combined Blood Extract Eye Drops for Treatment of Nociceptive Pain in Dry Eye Patients**

X Huang, Y *wu*, Y *mou*.

**Objective:** To investigate the efficacy of intense pulsed light (IPL) combined with deproteinized calf blood extract (DCBE) eye drops for dry eye disease (DED) patients with nociceptive ocular pain.

**Methods:** In this prospective, one-center, interventional study, 23 subjects with DED and ocular pain were treated with a combination of IPL and DCBE eye drops for four sessions at a four-week interval. Subjective and objective assessments on nociceptive pain and dry eye were examined and analyzed.

**Results:** The visual analog scale (VAS), ocular surface disease index, ocular pain assessment survey (OPAS), patient health questionnaire-9 items, generalized anxiety disorder (GAD-7), Athens insomnia scale, corneal fluorescein staining score, meibomian gland secretion quality, and expressibility scores were significantly reduced after the treatment. Tear break-up time and Schirmer I test increased significantly. The band density of corneal nerves and neuropeptide substance P also significantly increased. OPAS, GAD-7, meibomian gland secretion quality, and expressibility scores were essential factors affecting the VAS changes.

**Conclusion:** IPL combined with DCBE drop therapy was effective for DED patients with ocular pain. With such treatment, both DED symptoms and the sensation of ocular pain may be improved.



PP-161

## Long-term Effect of Intense Pulsed Light Combined with Low-Level Light Therapy in the Treatment of Meibomian Gland Dysfunction

B Barbosa Ribeiro<sup>1</sup>, J Heitor Marques<sup>1</sup>, P Baptista<sup>1</sup>, D José<sup>1</sup>, P Sousa<sup>1</sup>, I Barbosa<sup>1</sup>.

<sup>1</sup>Ophthalmology Department, Centro Hospitalar Universitario do Porto, Porto, Portugal

**Objective:** This study aimed to evaluate the efficacy of intense pulsed light combined with low-level light therapy in the treatment of Meibomian Gland Dysfunction (MGD).

**Methods:** We conducted a double-arm, non-randomized, prospective study from the outpatient clinic of the Ophthalmology Department of a tertiary hospital. Adult patients with Meibomian Gland Dysfunction were eligible for participation. Patients were consecutively assigned to either intense pulsed light therapy combined with low-level light therapy (group 1 - Eye-Light® line by Expansione Group, Italy) or intense pulsed light therapy alone (group 2 - E>Eye® by ESW vision, France). In both arms, subjects were evaluated at baseline and 1 and 6 months after the last treatment session. The main outcomes were the variation of the validated Dry-Eye Related Questionnaire (OSDI-12) and automated ocular surface analysis (IDRA® Ocular Surface Analyzer SBM Sistemi, Italy), such as non-invasive tear break-up time (NIBUT), eye-blinking patterns, lipid layer thickness (LLT), meibography, menisc height, Schirmer's test and tear film osmolarity.

**Results:** This study enrolled 124 eyes of 62 subjects: 31 in group 1 and 31 in group 2. Nineteen (19, 30.6%) were male, and the mean age was 65.7 years, with no significant difference between groups ( $p=0.168$ ). Eyes from both groups had statistically significant improvement of eye-blinking patterns (at 6 months,  $p<0.001$  in group 1 vs.  $p<0.004$  in group 2) and lipid layer thickness at 1 ( $p<0.001$  in both groups) and 6 months ( $p<0.001$  in both groups) of follow-up. At 1 and 6 months, both groups showed improvement of the Ocular Surface Disease Index (OSDI) score ( $p<0.001$  in both groups at 1 and 6 months), with greatest improvement in patients from group 2 (mean difference [MD]  $\pm$  standard deviation [SD],  $-36.2 \pm 20.4$ ,  $p<0.001$  vs.  $-19.6 \pm 25.6$ ,  $p<0.01$ ). Only eyes from group 1 showed significant improvement between 1 and 6 months ( $p<0.001$  for group 1 vs.  $p=0.086$  for group 2). No adverse effects were reported.

**Conclusion:** Intense Pulsed Light is an effective and safe treatment choice for Meibomian Gland Dysfunction. However, this study suggests that the advantages of combined therapy with low-level light remain uncertain.

## PP-162

mutation analysis of the *tgfb1* gene in pedigrees of lattice corneal dystrophy in eastern china

T Li, L Li<sup>1</sup>.

<sup>1</sup>*ophthalmic, tianjin eye hospital, tianjin, People's Republic of China*

**Objective:** To delineate the mutations of the TGFBI gene in Eastern China by whole-exome sequencing(WES) in eight Chinese families with lattice corneal dystrophy (LCD).

**Methods:** This retrospective study included eight families with LCD from Eastern China. Clinical features were examined using slit-lamp examination, anterior segment optical coherence tomography, and in vivo confocal microscopy. Peripheral blood samples of probands were collected for WES, and saliva samples from family members were collected for TGFBI screening using Sanger sequencing. The physicochemical effects of mutations were investigated using bioinformatics tools.

**Results:** Family 1 presented a classic LCD I with a p.R124C mutation of the TGFBI gene, while the other seven families were diagnosed with LCD IIIA. Six of the seven LCD IIIA families had heterozygous single gene mutations (p.A546D, p.L565 H, p.T621P), and one had a compound heterozygous (cis) mutation (p. P501T and p.N622 H). The mutation of p.L565 H was the first time of integrated family report in contrast to the cases reported in 2019, and the p.T621P mutation was first reported in a Chinese population. Notably, the family with the compound mutation was associated with an obvious early-onset (in the 2nd decade of life) compared to the LCD IIIA patients with each single mutation (p.P501T or p.N622 H) showing late onset (in the 7th decade of life).

**Conclusion:** WES is efficient for the genomic testing of LCD and genetic relationship identification in different families with the same mutated gene. We identified a compound heterozygous mutation (p. P501T and p.N622 H) and two mutations (p.T621P and p.L565 H) uncommon in China.

**PP-163****Topographic & visual outcomes post pterygium surgery- a prospective study in a tertiary eye care hospital in India**

A Heda, S Joshi<sup>1</sup>.

<sup>1</sup>*Cornea, H V Desai Eye Hospital , Pune, India*

**Objective:** To compare the corneal topography changes in astigmatism, keratometry& pachymetry, pre & post Pterygium Excision with Conjunctival Autograft surgery

**Methods:** In this single centric prospective study, 150 eyes of 150 patients with primary nasal pterygia of grade 1 or more were included. Exclusion criteria were double headed & recurrent pterygia and pterygia with cataract. All patients underwent Pterygium Excision with Conjunctival Autograft using Fibrin Glue. On Follow up visits, at 1 & 3 months, changes in Best Corrected Visual Acuity (BCVA), Spherical Equivalent, topographic astigmatism, Nasal & Central pachymetry were noted using Oculus Pentacam

**Results:** Considerable improvement in spherical equivalent (SE) was seen post surgery, more so, in patients with Grade III (Preoperative SE -3.30+/-0.95 , Post op. SE -0.72+/-0.38) & Grade IV (Preop. SE -4.7+/-1.3, Postop. SE -1.38+/- 0.75) pterygia. Statistically significant ( $P < 0.0001$ ) reduction in topographic astigmatism was seen in patients with Grade II ,III & IV pterygia at 1 month & 3 months. Nasal pachymetry showed significant changes at 1 & 3 months postoperatively, whereas central pachymetry showed no changes irrespective of grade of pterygia. Postoperatively, 56% of patients showed myopic with the rule astigmatism & 40% against the rule astigmatism. There was hematoma under the graft in 7 cases, granuloma formation in 3 cases & displaced graft in 1 case. No recurrence of pterygium was observed in our series.

**Conclusion:** Given the high incidence of pterygium & morbidity like with chronic irritable eye, reduced vision due to pterygium, in tropical country like ours, surgery is a very safe & efficacious treatment option with good visual outcomes & predictable results

## PP-165

**Dry eye disease and diabetes mellitus: a cross-sectional study**

M Afonso<sup>1</sup>, J Marques<sup>1</sup>, P Baptista<sup>1,2</sup>, D José<sup>1</sup>, P Sousa<sup>1</sup>, I Barbosa<sup>1,2</sup>.

<sup>1</sup>Ophthalmology, Centro Hospitalar Universitário do Porto (CHUPorto), <sup>2</sup>Instituto de Ciências Biomédicas Abel Salazar (ICBAS), Oporto, Portugal

**Objective:** The objective of this study was to evaluate the ocular surface and tear film characteristics in diabetic patients as compared with that in nondiabetic patients.

**Methods:** Cross-sectional study that included patients followed in the ocular diabetes consultation and patients scheduled for a routine eye examination. Study endpoints included non-invasive break-up time (NIBUT), blink rate (BR), lipid layer thickness (LLT), loss area of meibomian glands (LAMG), tear meniscus height (TMH), tear osmolarity (TO), Schirmer test (ST), presence of corneal fluorescein staining (CFS) and dry eye symptoms. Schirmer test I was used to evaluate tear production. Tear osmolarity was measured by TearLab® Osmolarity System (Tearlab, San Diego, CA, USA). The NIBUT, blink rate, lipid layer thickness through autointerferometry, loss area of the meibomian glands through meibography, and tear meniscus height were measured by IDRA® Ocular Surface Analyser (SBM SISTEMI, Italy).

**Results:** Five hundred and thirty-eight eyes of 269 patients were included in this study, 328 in the diabetic group and 210 in the nondiabetic group. 50.6% of patients in the diabetic group and 65.7% in the nondiabetic group were females ( $p = 0.001$ ). A significantly lower median NIBUT (10.2 vs 11.0 sec,  $p = 0.03$ ) and ST (10.0 vs 11.5 mm,  $p < 0.001$ ) was observed in the diabetic patient group. Median TO was significantly superior in the diabetic patient group (305 vs 301 mOsm/L,  $p = 0.002$ ). Nondiabetic patients had lower TMH (0.27 vs 0.30 mm,  $p = 0.01$ ). No statistically significant differences were observed between patient groups for BR, LLT and LAMG. The presence of CFS was significantly higher in the diabetic group (39% vs 25%,  $p = 0.009$ ), although, the presence of dry eye symptoms was not significantly different between the two groups.

**Conclusion:** In this study, the eyes of diabetic patients had worse results in 3 tear film parameters and had worse ocular surface status when compared to nondiabetic patients. This highlights the possible higher prevalence and severity of dry eye disease in diabetes mellitus.

PP-166

**CORNEAL STROMA DENSITOMETRY EVOLUTION IN A CLINICAL MODEL OF CELLULAR THERAPY FOR ADVANCED KERATOCONUS**

M El Zarif, J Alió Del Barrio<sup>1</sup>, J Alió<sup>1</sup>, K Abdul Jawad<sup>2</sup>.

<sup>1</sup>Ophthalmology, Miguel Hernandez University, Alicante-Spain, Alicante, Spain, <sup>2</sup>Optometry, Optica General, Saida, Lebanon

**Objective:** To report the corneal stromal densitometry (CD) evolution studied by Scheimpflug tomography, anterior segment optical coherence tomography (AS-OCT), and confocal microscopy changes, in keratoconus patients included in a clinical experience of advanced cell therapy using autologous humans adipose-derived adult stem cells (ADASCs), and corneal decellularized or ADASCs-recellularized human donor corneal lamins in advanced keratoconus.

**Methods:** Interventional prospective, consecutive, randomized, comparative series of cases. Fourteen keratoconic patients were randomly distributed into three groups for three types of surgical interventions: group 1 (G-1), autologous ADASCs implantation (n = 5); group 2 (G-2), decellularized human corneal stroma (n = 5); and, group 3 (G-3), autologous ADASCs + decellularized human corneal stroma (n = 4). Participants were assessed with Scheimpflug-based Oculus Pentacam CD module, AS-OCT (Visante, Carl Zeiss), and confocal microscopy (HRT3 RCM Heidelberg).

**Results:** The central and total CD were statistically significantly higher in G-2 compared with G-1, and G-3 compared with G-1 at the studied annular zones centered on the corneal apex (0-2mm, 2-6mm, and 6-10mm). There was statistical significance higher in G-3 compared with G-2 at the central corneal stroma at (0-2mm, 2-6mm). The confocal microscopy findings, as well as the AS-OCT reflected the densitometry changes.

**Conclusion:** The intrastromal implantation of ADASCs produced very subtle changes in CD at the level of the central corneal stroma. However, the intrastromal implantation of decellularized corneal lamins increases it slightly, but with lower values than the implantation of recellularized lamins with ADASCs.

PP-167

**Impaired Sleep Quality in Children with Allergic Conjunctivitis and Their Parents**J Li, L Liang<sup>1</sup>.<sup>1</sup>Zhongshan ophthalmic center, Guangzhou, People's Republic of China**Objective:** To investigate the sleep quality in children with allergic conjunctivitis (AC) and their parents.**Methods:** Seventy-three children aged 4-12 years with AC and their parents, and 81 age matched healthy children and their parents. General information and ocular manifestations of children with AC were recorded. The sleep quality of the children and parents were assessed using the verified Chinese version of Children's Sleep Habits Questionnaire (CSHQ) and Pittsburgh Sleep Quality Index (PSQI), respectively. Poor sleep quality was diagnosed when CSHQ score  $\geq 41$  and PSQI score  $> 7$ .**Results:** Children with AC and their parents had reduced sleep quality (children' CSHQ:  $48.3 \pm 6.55$  vs.  $38.8 \pm 4.63$ ; parental PSQI:  $5.62 \pm 2.12$  vs.  $3.40 \pm 1.90$ , both  $p < 0.001$ ) and significantly higher prevalence of poor sleep quality (Children: 89% vs. 23.5%; Parents: 18.5% vs. 1.23%, both  $p < 0.001$ ) when compared to the control. Children with AC scored worse on subcomponents of CSHQ including sleep onset delay, sleep duration, parasomnia, sleep-disordered breathing, and daytime sleepiness. Parents scored worse on subcomponents of PSQI including sleep duration, sleep disturbances, use of sleeping medication, and daytime sleepiness. Poor sleep quality in children with AC was associated with follicles (OR:3.95; 95% CI: 1.88 to 8.31  $p < 0.001$ ) and keratitis (OR:6.03; 95% CI: 1.29 to 28.3,  $p = 0.028$ ). Parental poor sleep quality was associated with follicles (OR:7.14; 95% CI:2.06 to 24.8,  $p = 0.002$ ) and keratitis (OR:4.49; 95% CI:1.27 to 15.9,  $p = 0.02$ ) in children.**Conclusion:** AC is associated with reduced sleep quality in pediatric patients and their parents, especially in those children with severe clinical signs and worse vision. The results suggest including sleep quality assessment and care in a better chronic disease management of AC.

PP-169

**Sensory nerves promote corneal inflammation resolution via CGRP mediated macrophages to the M2 phenotype through PI3K/AKT pathway**X Huang, K *yan*.**Objective:**

To explore the role of the corneal sensory nerves in *Pseudomonas aeruginosa* (*P. aeruginosa*) keratitis, the synergistic effect between the sensory neurons and macrophages in calcitonin gene-related peptide (CGRP) release, and the functional mechanisms of CGRP-mediated transformation of macrophages to the M2 phenotype.

**Methods:** Corneal nerve loss, macrophage recruitment, and CGRP expression were evaluated. To explore the synergistic effect between the sensory neurons and macrophages, RAW 264.7 cells were challenged with lipopolysaccharide (LPS), then trigeminal ganglion (TG) sensory neurons were isolated and co-incubated with macrophages, and CGRP expression was tested. To investigate the biological function of cornea neuron-initiated immune responses mediated by CGRP, BIBN 4096BS was used to inhibit CGRP in vivo and  $\alpha$ -CGRP was used to simulate CGRP in vitro. The expressions of inflammatory cytokines (IL-1 $\beta$ , IL-6, TNF- $\alpha$ , and IL-10), M1 (CD80/CD86), M2 (CD163/CD206) macrophage markers, and signal transducers (PI3K/AKT) were detected.

**Results:** *P. aeruginosa* infection induced corneal nerve loss, macrophage recruitment, and CGRP up-expression. CGRP was co-localized with macrophages. Co-culture showed that sensory neurons and macrophages can mediate CGRP release. More CGRP was released when the two types of cells were combined to respond to LPS. BIBN 4096BS promoted pro-inflammatory cytokines and inhibited the anti-inflammatory cytokines and signal transducers, while,  $\alpha$ -CGRP inhibited the pro-inflammatory cytokines and M1 markers and promoted the anti-inflammatory cytokine, M2 markers, and signal transducers.

**Conclusion:** *P. aeruginosa* infection induces corneal sensory neuron activation, macrophage recruitment, and CGRP up-expression. The synergistic effect between the sensory neurons and macrophages promotes CGRP release. CGRP inhibits corneal inflammation and promotes the transformation of macrophages to the M2 phenotype through the PI3K/AKT signaling pathway.

PP-170

## Single-Cell Transcriptomics Identifies a Unique Entity and Signature Markers of Transit Amplifying Cells in Human Corneal Limbus

J Li, Y Gao<sup>1</sup>, C Cheng<sup>1</sup>, C Li<sup>1</sup>, Y Liu<sup>1</sup>, Y Wang<sup>1</sup>, J Tang<sup>1</sup>, Y Ma<sup>1</sup>, R Lu<sup>1</sup>.

<sup>1</sup>State Key Laboratory of Ophthalmology, Zhongshan Ophthalmic Center, Sun Yat-sen University, Guangzhou, People's Republic of China

**Objective:** Differentiated from adult stem cells (ASC), transit-amplifying cells (TAC) play an important role in tissue homeostasis, development and regeneration. However, it is unclear whether TAC is a real entity or functional concept. This study aimed to identify the unique entity and signature markers of TACs in human cornea at single-cell resolution.

**Methods:** Single cells were isolated from corneal limbal basal epithelium for scRNA-Seq using 10x Genomics platform, followed by clustering cell types through the graph-based visualization methods and unbiased computational informatic analysis. Together with BrdU proliferation assays, immunofluorescent staining and real-time RT-qPCR, multiple culture models of primary human limbal epithelial cells (HLECs) were performed to characterize the TAC entity.

**Results:** Single-cell transcriptomics of 16,360 limbal basal cells revealed 12 cell clusters. A unique cluster (3.21% of total cells) was identified as the TAC entity based on its less differentiated progenitor status and enriched exclusive proliferation marker genes with 98.1% cells in S and G2/M phases. The cell cycle-dependent genes are uncovered to be largely enriched by TAC population. A group of top genes were characterized morphologically and functionally at protein and mRNA levels. The specific expression patterns of RRM2, TK1, CENPF, NUSAP1, UBE2C and CDC20 were well correlated at time-/cycle-dependent manner with proliferation stages in cell growth and regeneration models.

**Conclusion:** We for the first time identified the unique TAC entity and uncovered a group of cell cycle-dependent genes as TAC signature markers. The findings provide insight into ASC/TAC concept and lay the foundation for understanding corneal homeostasis and diseases.



PP-171

**Ocular Surface Complications in Children Undergoing General Anesthesia**

D El Hadi<sup>1</sup>, S Hoyeck<sup>2</sup>, E Rachid<sup>1</sup>, Z El Moussawi<sup>1</sup>, J Torbey<sup>1</sup>, M Aouad<sup>2</sup>, C Al-Haddad<sup>1</sup>.

<sup>1</sup>Ophthalmology, <sup>2</sup>Anesthesia, American University of Beirut Medical Center, Beirut, Lebanon

**Objective:** To identify the incidence and possible risk factors of post-operative ocular surface complications in a tertiary care center.

**Methods:** This is a prospective study for pediatric patients, undergoing general anesthesia (GA). An ophthalmologist performed the ocular examination after surgery. Data collected: patient age, gender, ASA class, type and length of surgery, intra-operative positioning, eye protection, and post-operative complications. Parameters assessed: Tear Break up time (TBUT), corneal staining for punctate epithelial erosions (PEEs) and corneal abrasions (CA). Multivariate logistic regression model was used to assess risk factors.

**Results:** 108 pediatric patients were recruited. Thirty-nine from 108 (36.1%) patients showed abnormal corneal findings. From the total cohort, 32 (29.6%) had decreased TBUT, 3 (2.7%) had PEEs, 3 (2.7%) had both PEEs and decreased TBUT and 1 (0.9%) was found to have a unilateral CA post-operatively. 66.7% of surgeries were performed in the head and neck region and 71% received tape as intra-operative eye protection. Younger patients were more likely to sustain ocular surface complications (odds ratio:0.89; 95%CI:0.80-0.99, p=0.04). The duration of surgery was significantly associated with corneal findings post-operatively (odds ratio: 1.18; 95%CI:1.05-2.91, p=0.03). In surgeries in the head and neck region, the odds of having post-operative ocular surface findings were 3.20 times as high (95%CI:1.09-9.41, p=0.03) compared to patients having other types of surgeries.

**Conclusion:** In our cohort the rate of post-operative corneal findings in children undergoing GA was 36.1%. Post-operative ocular surface complications were associated with younger age, prolonged surgery, and surgery in the head and neck region.

PP-172

**Meibomian Gland Area and Length after IPL and IPL associated with Low Level Light Therapy**C Castro, J Marques<sup>1</sup>, P Baptista<sup>1</sup>, P Sousa<sup>1</sup>, D José<sup>1</sup>, I Barbosa<sup>1</sup>.<sup>1</sup>Ophthalmology, Centro Hospitalar Universitário do Porto, PORTO, Portugal

**Objective:** To evaluate the effect of Intense Pulsed Light (IPL) and IPL in association with Low-Level Light Therapy (LLLT) in the meibomian gland morphology and function, together with patients' subjective complains.

**Methods:** Prospective comparative study that included 63 patients, randomly assigned to one of two treatment arms: group 1 (31 patients, 62 eyes) received treatment with IPL and LLLT (IPL with Eye-Light®, followed by low level light treatment with My Mask®); group 2 (32 patients, 64 eyes) received treatment with IPL alone (E>Eye®). All treatments were performed in 3 sessions and patients were evaluated before treatment, 1 month and 6 months after treatment. To evaluate the meibomian gland morphology, an infrared meibography was performed (IDRA® Ocular Surface Analyser), followed by binarization to automatically calculate gland area (MGA) and skeletonization to measure gland length (MGL), using Image J®. Patients' symptoms were evaluated using the Ocular Surface Disease Index (OSDI).

**Results:** One month after treatment, there was an increase in the MGA in group 1 ( $\Delta = +20.7 \pm 4.6\%$ ,  $p < 0.001$ ) and group 2 ( $\Delta = +8.9 \pm 16.1\%$ ,  $p = 0.002$ ). Regarding MGL, after 1 month, there was also an increase in group 1 ( $\Delta = +18.7 \pm 13.9\%$ ,  $p < 0.001$ ) and group 2 ( $\Delta = +10.8 \pm 9.9\%$ ,  $p = 0.002$ ). The increase in MGA was similar in both groups ( $p = 0.08$ ). The OSDI score improved in 88.7% of eyes in group 1 and in 87.5% in group 2 ( $p = 0.526$ ). Comparing month 6 with month 1, there were no changes in MGA in groups 1 and 2 ( $p = 0.200$  and  $p = 0.063$ , respectively) or in the MGL ( $p = 0.061$  and  $p = 0.105$ ). Regarding the OSDI score, there was an improvement in 78.6% of eyes in group 1 and 37.1% in group 2 ( $p < 0.001$ ). In groups 1 and 2, respectively, 3.6% and 43.5% had a worse OSDI score compared to month 1 ( $p < 0.001$ ).

**Conclusion:** IPL and IPL associated with LLLT lead to an increase in the MGA and MGL and a decrease in patient's symptoms. Despite this, adding LLLT to IPL seems to lead to a more sustained improvement in patient's symptoms over time.

PP-173

**Differential expression and its significance of TGF- $\beta$  1 receptors ALK1/ALK5 in pterygium and normal conjunctiva**H Wang, C Zhang, M Li.

**Objective:** To investigate the expression and significance of activin A receptor like kinase (ALK) in pterygium and normal conjunctiva.

**Methods:** 40 cases of pterygium specimens and 40 cases of conjunctiva specimens were included in this study. The expression and localization of ALK1 and ALK5 was detected by immunohistochemical staining, and the percentage of positive cells was counted. Reverse transcription polymerase chain reaction (RT-PCR) was used to detect the expression of ALK1 and ALK5 mRNA in pterygium and conjunctiva; while the protein expression of ALK1 and ALK5 was detected by Western blot.

**Results:** The expression profile of ALK in pterygium was significantly different from that in normal conjunctiva. ALK1 was highly expressed in the whole layer of pterygium epithelial cells, but only in the basal layer of epithelial cells in normal conjunctiva; The expression of ALK5 was found in the basal layer of normal conjunctival epithelial cells, but it was significantly decreased in pterygium. There was a significant difference in the proportion of ALK1 and ALK5 positive cells between the two groups ( $P < 0.05$ ). RT-PCR results showed that compared with conjunctival tissue, the expression of ALK1 mRNA in pterygium was significantly increased, and the expression of ALK5 was significantly decreased ( $P < 0.05$ ). Western blot showed that the expression of ALK1 and ALK5 protein was consistent with RT-PCR results.

**Conclusion:** The expression of ALK in pterygium was significantly different from that in normal conjunctiva, indicating the different activation states of TGF- $\beta$  signaling pathways, which provide a basis for further study on the pathogenesis of pterygium.

PP-175

**LncRNA003946 protects rat corneal allograft via inhibiting the expression of HDAC10 and promoting macrophages M2 polarization**K Liu, X Lu, S Zhao.

**Objective:** Our previous study found that IL-10-overexpressing bone marrow-derived mesenchymal stem cells promoted rat corneal allograft survival by upregulating the expression of lncRNA003946 in macrophages. Bioinformatics analysis indicated that histone deacetylase 10 (HDAC10) could be a potential target for this novel lncRNA. Here we verified the hypothesis that lncRNA003946 suppresses corneal allograft rejection by targeting HDAC10 to promote M2 macrophage polarization.

**Methods:** Corneal allograft rejection models were established with Wistar rats as the donor and Lewis rats as the host. Lentiviral vectors were subconjunctival injected to overexpress or knockdown lncRNA003946. The clinical signs of the allografts were evaluated according to Larkin grading criteria. Phenotypes of the macrophages in the cornea and the draining lymph nodes were detected by immunofluorescence staining and flow cytometry respectively. Rat bone marrow-derived macrophages (BMDMs) were induced with 10 ng/ml rat M-CSF for in vitro mechanistic studies. In the loss- and gain-of-function experiments of lncRNA003946, qPCR and western blot were used to verify mRNA and protein expression level of HDAC10 and macrophages polarization-related factors. BrdU tests were performed to detect the proliferation level of PBMC co-cultured with BMDMs. Macrophages phenotypes and polarization-related factors were detected to evaluate the effect of Bufexamac (a HDAC10 inhibitor) in lncRNA003946-knockdown BMDMs.

**Results:** lncRNA003946 effectively prolonged the cornea allograft survival time and increased the proportion of CD68+CD163+ macrophages in grafts and draining lymph nodes. The expression level of HDAC10 were significantly reduced in lncRNA003946-overexpressing BMDMs, and HDAC10 protein tended to translocate to the nucleus. BrdU assay indicated that macrophages overexpressing lncRNA003946 suppressed lymphocyte proliferation. Furthermore, overexpression or silence of lncRNA003946 affected the expression of various macrophage polarization-related factors especially PD-L1. HDAC10 inhibitor reversed low expression of PD-L1 caused by knockdown of lncRNA003946, dramatically.

**Conclusion:** Our results demonstrate that lncRNA003946 upregulates the expression of PD-L1 via inhibiting HDAC10, which promotes M2 polarization of macrophages and ultimately suppresses rat corneal allograft rejection. The data indicate that HDAC10 is a promising therapy target for corneal graft rejection.

PP-177

**The Use of Contact Lenses Among Keratoconus Patients in Saudi Arabia: Prevalence, Habits and Complications**S Alanazi.

**Objective:** To determine the prevalence of contact lens use as well as the attitudes toward contact lens usage and its complications among keratoconus patients.

**Methods:** This cross-sectional study included 112 keratoconus patients who were treated with contact lenses; subjects were from different areas of Saudi Arabia. A voluntary self-administered questionnaire was used to collect data regarding prevalence, habits and outcomes of contact lens use among keratoconus patients.

**Results:** Of 112 respondents, 84.8% were treated with hard lenses, while 23.2% used soft lenses. Complications were reported among 57.1%, the most common being dry eyes. Regarding hygiene habits, 66.3% reported washing their hands before wearing their lenses, while 33.7% did not. Moreover, 69% of the participants made sure that there were no scratches or breaks in the edges of the contact lenses before wearing them. The majority of participants reported that they had never slept with lenses on (68.4%), while 13.7% kept their lenses on during naps.

**Conclusion:** The results of this study highlight negative habits of contact lens use and complications experienced by users. Although the study shows good practice among keratoconus patients, health education on contact lens hygiene is recommended to improve patient behaviour and prevent severe complications. In addition, further research must be undertaken to evaluate the awareness of contact lens related complications among KC patients.

PP-178

**Single-Cell Transcriptome Profiling of Human Corneas Reveals the Pathogenesis of Keratoconus**S Ouyang.

**Objective:** The aim of this study was to elucidate the cellular heterogeneity and underlying pathogenesis of KC by single-cell RNA sequencing (scRNA-seq).

**Methods:** Single cells isolated from central mature corneas of donor (HD) and KC patients were used for scRNA-seq via the 10x Genomics platform. Functional changes of cell types were analyzed by enrichment analysis. Pseudotime analysis as well as cell communication analysis were performed to reveal the cellular heterogeneity of KC. Immunofluorescence was used to validate target protein.

**Results:** Here, we performed single-cell RNA-seq sequencing to construct a transcriptomic atlas of 64,239 cells in KC and HD corneas. Among 11 cell types we identified, we revealed a decrease in the proportion of basal cells and an increase in the proportion of wing cells and superficial cells in KC. In addition, we characterized cell subtype-specific molecular changes in the epithelium in detail and demonstrated the upregulation of interferon signaling specifically involved in KC epithelium. Furthermore, we showed a shift in the cell status of epithelial subtypes in KC and blockade of the immune interferon factor *IFI27* might delay its development. Finally, we uncovered that extracellular matrix degradation signals occur mainly in keratocytes and aberrant interactions between the subtypes of epithelial and stromal cells underlie pathological manifestations in KC.

**Conclusion:** Our study provides new insights into the pathogenesis of KC and clues about potential molecular targets for nonsurgical treatment.

PP-179

**Extranasal Neurostimulation Improved Basal Signs of Dry Eye Disease (DED)**A Ng<sup>1</sup>, E Wong<sup>2</sup>, T Bai<sup>3</sup>, E Shusterman<sup>4</sup>, M Gertner<sup>4</sup>, Q Liu<sup>5</sup>.<sup>1</sup>Hong Kong Ophthalmic Associates, <sup>2</sup>Arctic Vision Hong Kong Limited, Hong Kong, Hong Kong, China, <sup>3</sup>Arctic Vision Biotechnology Limited, Beijing, People's Republic of China, <sup>4</sup>Olympic Ophthalmics, Issaquah, United States, <sup>5</sup>Arctic Vision Biotechnology Limited, Shanghai, People's Republic of China**Objective:** To evaluate the use of extranasal neurostimulator in improving basal signs of dry eye disease (DED).**Methods:** A multicenter, open-label, single-arm clinical trial has investigated the use of the device in patients with Schirmer score (with local anaesthesia) of  $\leq 10$ mm in at least one eye. Patients were instructed to apply the study device at least twice per day for 30 seconds bilaterally to the extranasal nerve. Apart from the tear production and symptoms evaluation, the signs of DED including Meibomian gland expression and secretion, tear break-up time (TBUT), corneal and conjunctival staining by NEI grading were evaluated prior to stimulation at each office visit. Schirmer score (with local anaesthesia), the Meibomian gland expression and secretion was assessed again immediately after stimulation at each time point. The measurement before stimulation throughout the study period is referred to the temporal basal value of the patients.**Results:** 101 subjects were enrolled in the study and completed the study visit at Day 30 while 58 subjects completed the optional follow up up to Day 180. The mean pre-stimulation Schirmer score at baseline was  $6 \pm 3.8$ mm, increased to  $28 \pm 8.5$  mm upon first stimulation. The pre-stimulated Schirmer score improved to  $9.4 \pm 9.3$ mm at Day 30 and  $10.9 \pm 7.1$ mm at Day 180. The basal Meibomian gland expression was  $12.2 \pm 10.2$  and stimulated to  $17.5 \pm 13$  upon first stimulation. The basal expression improved to  $19 \pm 13.5$  at Day 30 ( $p < 0.0001$ ) and sustained at  $18.9 \pm 14$  to Day 180. The basal clear liquid secretion improved from  $1.7 \pm 3.1$  at baseline to  $3.5 \pm 4.9$  upon first stimulation. The basal secretion improved to  $4.1 \pm 5.1$  at Day 30 ( $p < 0.0001$ ) and  $4.2 \pm 5.1$  at Day 180 ( $p < 0.0017$ ). TBUT increased from  $5.0 \pm 3.6$  sec at baseline to  $6.7 \pm 6.0$  sec at Day 30 ( $p = 0.0035$ ) and  $7.5 \pm 9.6$  sec at Day 180 ( $p = 0.0802$ ). Corneal staining reduced from  $3.4 \pm 3.4$  at baseline to  $1.9 \pm 2.5$  at Day 30 ( $p < 0.0001$ ) and to  $1.8 \pm 2.5$  at Day 180 ( $p < 0.0003$ ) while for conjunctival staining from  $5.3 \pm 4.4$  at baseline to  $3.8 \pm 3.6$  at Day 30 ( $p < 0.002$ ) and to  $2.5 \pm 2.7$  at Day 180 ( $p = 0.0001$ ). OSDI changed from  $40.3 \pm 22.9$  at baseline to  $25.4 \pm 18.6$  at Day 30 and to  $23.9 \pm 19.4$  at Day 180. Representative patient cases will be shared.**Conclusion:** Extranasal neurostimulation improved both signs and symptoms of DED and represents a novel drug-free approach for DED management.

PP-180

### The Validation of Phenol Red Thread Test in Chinese Population

Y Hao<sup>1</sup>, L Tian<sup>1</sup>, Y Jie<sup>1</sup>.

<sup>1</sup>Beijing Tongren Hospital, Capital Medical University, Beijing, People's Republic of China

**Objective:** To evaluate the validation of phenol red thread (PRT) test in Chinese population by assessing its intraobserver repeatability and interobserver reproducibility, determining the correlations among PRT test and other dry eye disease (DED) parameters, and testing the accuracy of the diagnosis of PRT test.

**Methods:** A total of 108 eyes of 63 subjects were recruited and divided into experimental group and control group. Each subject accomplished the following examinations orderly: Ocular Surface Disease Index (OSDI) questionnaire, non-invasive tear breakup time (NIBUT), tear meniscus height (TMH) assessment, phenol red thread (PRT) test for 3 times, Schirmer I test, fluorescein tear breakup time (FBUT), corneal fluorescein staining. The repeatability and reproducibility of the PRT test were assessed by the intraclass correlation coefficient (ICC) and the Bland-Altman analysis, the correlations were evaluated by the Spearman rank-order correlation and the accuracy of diagnosis was tested by the Receiver operating characteristic (ROC) curve analysis.

**Results:** The repeatability was good in both experimental group and control group, with 0.747 and 0.723 respectively of the ICC, -4.008 to 4.468 and -5.227 to 4.738 respectively of the Bland-Altman 95% limits of agreement. And the reproducibility was relatively good in both groups, with 0.588 and 0.610 respectively of the ICC, -5.597 to 4.732 and -4.908 to 6.041 respectively of the Bland-Altman 95% limits of agreement. Also, the PRT test had correlations with Schirmer I test and TMH assessment, with the Spearman rank correlation coefficients of 0.385 and 0.306 respectively. Furthermore, using the PRT test to diagnose DED is relatively accurate with 0.806 of the area under the curve (AUC) and 0.556 of the Youden index at the cutoff point of 8.83mm.

**Conclusion:** The PRT test provided a comfortable, time-saving and less irritating approach to screening and diagnosing DED with quite acceptable validation, which could be generalized as a practical and efficient measurement in the busy clinical service.



PP-181

**Miltefosine - Related Keratitis: Clinical Characteristics and Therapeutic Approach**R Kusumesh<sup>1</sup>, B Sinha<sup>1</sup>, A Ambasta<sup>1</sup>, L Arya<sup>2</sup>.<sup>1</sup>Ophthalmology, <sup>2</sup>Microbiology, Indira Gandhi Institute of Medical Sciences, Patna, India

**Objective:** To describe the characteristic clinical features and management of keratitis in the patients receiving miltefosine for post-kala-azar dermal leishmaniasis (PKDL).

**Methods:** The medical records of five PKDL patients presenting with keratitis were reviewed retrospectively from April 2018 to December 2020. The evaluation included a thorough medical history including details on drugs used, particularly miltefosine. The drug causality assessment was also performed. The clinical and microbiological characteristics of keratitis were noted.

**Results:** The ocular symptoms included pain, redness, watering, photophobia, and diminution in vision. Slit-lamp biomicroscopy revealed peripheral, paralimbal, ring-shaped, full thickness stromal infiltration resulting in ulcerative keratitis in all cases. Two patients had unilateral keratitis, while three had bilateral. All five patients received miltefosine for an average period of 48 days before the onset of keratitis. The corrected distant visual acuity (CDVA) at presentation ranged from hand movement to 20/125. The causality assessment revealed a “probable” association between the adverse drug reaction and miltefosine in all patients. Discontinuation of miltefosine and initiation of corticosteroid therapy resulted in resolution of keratitis in all cases. The unilateral cases had excellent outcomes with topical steroids, but poor outcomes were found in the patients with bilateral disease.

**Conclusion:** These observations indicate that prolonged use of miltefosine might cause keratitis that resembles infectious keratitis. Early diagnosis with discontinuation of the drug and initiation of corticosteroid therapy is the key to successful management.

PP-183

### Outcomes of Descemet Membrane Endothelial Keratoplasty in Eyes with Glaucoma, Maculopathy, and Previous Corneal Transplants

E N Nche<sup>1</sup>, A Katzir<sup>2</sup>, T Batash<sup>2</sup>, D Wajnzstajn<sup>2</sup>, K Safadi<sup>2</sup>, A Solomon<sup>2</sup>, I Lavy<sup>2</sup>.

<sup>1</sup>Ophthalmology, Regional Hospital Buea, Buea, Cameroon, <sup>2</sup>Ophthalmology, Hadassah Medical Center, Jerusalem, Israel

**Objective:** To report and analyze the outcomes of Descemet Membrane Endothelial Keratoplasty (DMEK) in eyes with corneal edema and associated ocular morbidities (glaucoma, maculopathy, and eyes after corneal transplants) in comparison to eyes without.

**Methods:** A retrospective study of seventy-seven (77) DMEK cases was done. Eyes after combined surgeries, vitrectomy, and eyes with anterior chamber intraocular lenses were excluded. Main outcome measures were best corrected distance visual acuity (BCDVA) and graft survival. Eyes were separated into six groups as follows and analyzed: glaucoma only (GO), glaucoma and maculopathy (GMC), glaucoma and previous corneal transplant (GCT), previous corneal transplant (CT), maculopathy only (MO) and no associated glaucoma, maculopathy or corneal transplant (N).

**Results:** Overall, median BCDVA improved from 2.0 [0.2, 3] logMAR before surgery to 0.3 [-0.1, 2.0] logMAR 12 months after DMEK ( $p < 0.001$ ) with no difference between the groups at 1 month, 3 months, 6 months and 12 months follow up times ( $p < 0.05$ ). Median BCDVA logMAR from before surgery improved significantly at 12 months in the N group; 1 [0.4, 3] to 0.2 [-0.1, 0.7] ( $p < 0.001$ ), CT group; 2 [0.2, 3] to 0.4 [0.1, 2] ( $p < 0.01$ ) and the GCT group; 2 [0.7, 3] to 0.4 [0.2, 2] ( $p < 0.05$ ) but was not significant in the GO group; 1 [0.3, 3] to 0.3 [0.18, 2] ( $p > 0.05$ ), the MO group; 0.6 [0.2, 3] to 0.45 [0.1, 8] ( $p > 0.05$ ), and the GMC group; 1.0 [0.3, 3] to 0.4 [0.1, 0.6] ( $p > 0.05$ ). Overall graft survival rate was 77.9% at 12 months. Highest in the N group (89.5%) and lowest in the GCS group (63.3%) ( $p = 0.71$ ).

**Conclusion:** DMEK offers visual rehabilitation in eyes with associated ocular morbidity. The least improvement in visual acuity is seen in patients with associated glaucoma, or maculopathy, or a combination of glaucoma and maculopathy. Eyes with glaucoma after previous corneal transplantation experience a significant improvement in vision at 12 months, but graft survival is 29% lower than in normal eyes.

PP-184

**PRGF treatment in sequelae of adenovirus conjunctivitis**E Uribe<sup>1,2,3</sup>, J Merayo<sup>4</sup>, R Sanchez<sup>5</sup>.

<sup>1</sup>Corneal and external disease - Uveitis, Instituto Universitario Fernandez Vega - Universidad de Oviedo, Oviedo, Spain, <sup>2</sup>Corneal and external disease - Uveitis, Clinica Delgado, <sup>3</sup>Universidad San Martin de Porres, Lima, Peru, <sup>4</sup>Ocular Immunology and Uveitis, <sup>5</sup>Ocular Immunology and External disease, Instituto Universitario Fernandez Vega - Universidad de Oviedo, Oviedo, Spain

**Objective:** To provide data about efficacy and safety of Plasma Rich in Growth Factors (PRGF) eye drops in sequelae of adenovirus conjunctivitis (SAC), and to analyze the possible influence of certain variables on treatment outcomes.

**Methods:** This retrospective study included patients of IUFV (Fernández-Vega University Institute) Eye Surface Unit between 2012 and 2013, without response to standard therapy (artificial tears, corticosteroids, cyclosporine, autologous serum) and presence of SEI (sub-epithelial infiltrates). The treatment given was PRGF eye drops 4 times/ day ± standard therapy. Primary endpoint was the resolution time of SEI. The Best Corrected Visual Acuity (BCVA) and intraocular pressure (IOP) were also evaluated. Safety assessment was also performed.

**Results:** Twenty-eight eyes (14 patients) were evaluated, mean age was  $46.5 \pm 19.3$  (21-79) years, previous time with SEI was  $10.1 \pm 13.8$  (0.5-36) months. The patients needs  $2.07 \pm 0.6$  (1-3) PRGF cycles (1 cycle = 6 weeks) to achieve corneal transparency. Ninety percent of patients continued with their standard therapy plus PRGF eye drops. Twenty four patients (86%) resolved SEI, follow up time was  $19.1 \pm 12.8$  (2.3-40.5) months. The BCVA improve 24.4% ( $p < 0.01$ ), and no statistical change in IOP. No adverse events were reported.

**Conclusion:** PRGF eye-drops could be a effective therapeutic option for patients with SEI because sequelae of adenovirus, improving BCVA and safe in its use.

PP-185

**Effect of Anti-allergic Therapy on Sleep Quality of Children with Allergic Conjunctivitis and Their Parents**B Yang, L Liang.

**Objective:** To assess the effect of anti-allergic therapy on sleep quality of children with allergic conjunctivitis (AC) and their parents.

**Methods:** This prospective single-arm intervention study includes 54 AC and 50 age-matched health control child-parent dyads. Standardized anti-allergic therapy was prescribed to AC children. Chinese version of Children's Sleep Habits Questionnaire (CSHQ) and Pittsburgh Sleep Quality Index (PSQI) was used to assess the sleep quality of children and their parents, respectively. All the AC symptoms, signs and sleep quality were evaluated before and after treatment. AC successfully controlled was set as the endpoint.

**Results:** After  $8.93 \pm 5.07$  weeks treatment, the total score of CSHQ and PSQI were significantly decreased (both  $P < 0.001$ ), with less AC children (74.1% vs. 94.4%,  $P = 0.003$ ) and parents (9.3% vs. 31.5%,  $P = 0.002$ ) had poor sleep quality. The CSHQ subscales of bedtime resistance ( $P = 0.072$ ), sleep duration ( $P = 0.174$ ) and daytime sleepiness ( $P = 0.078$ ) in AC group were improved to the normal level. For parents, all the PSQI subscale scores were comparable to health control group except the sleep disturbances ( $P < 0.001$ ). The greater improvement of sleep quality in children and parents were both associated with longer treating duration (children:  $\beta = 0.291$ ,  $P = 0.011$ , parents:  $\beta = 0.167$ ,  $P = 0.002$ ), and with higher baseline total score of CSHQ ( $\beta = 0.556$ ,  $P < 0.001$ ) and PSQI ( $\beta = 0.630$ ,  $P < 0.001$ ), respectively.

**Conclusion:** Successful management of AC improves sleep quality in both child and their parents, especially for those with longer treatment and worse baseline sleep quality. This study highlights the importance of treatment for AC on sleep health of child and parent.

PP-186

**Eyelid Dynamics in Blepharospasm based on Moderate-to-severe Dry Eye Disease**J Wang.

**Objective:** To investigate the effect of eyelid dynamics on blepharospasm based on moderate-to-severe dry eye disease (DED).

**Methods:** Cross-sectional comparative study. This study included 35 eyes of moderate-to-severe DED patients without blepharospasm and 40 eyes of moderate-to-severe DED patients with blepharospasm. The ocular surface parameters and eyelid dynamics parameters of all patients were used to explore the relationship between eyelid dynamics, ocular surface parameters and blepharospasm based on moderate-to-severe DED.

**Results:** The upper eyelid pressure was higher ( $101.91 \pm 23.48$  and  $88.37 \pm 18.08$ ,  $P=0.009$ ), the corneal fluorescein staining (CFS) was lower ( $2.95 \pm 1.61$  and  $4.66 \pm 1.87$ ,  $P=0.042$ ), the partial blink rate (PBR) was lower ( $0.58 \pm 0.36$  and  $0.89 \pm 0.23$ ,  $P<0.001$ ), the total blink (TB) was higher ( $7.14 \pm 4.07$  and  $6.20 \pm 4.18$ ,  $P=0.016$ ), the grade of meibum expressibility ( $1.32 \pm 0.65$  and  $0.58 \pm 0.56$ ,  $P<0.001$ ) was higher and the grade of meibum quality ( $0.59 \pm 0.63$  and  $0.24 \pm 0.36$ ,  $P=0.033$ ) was higher in moderate-to-severe DED patients with blepharospasm than those without blepharospasm. The eyelid pressure, the PBR, and the grade of meibum expressibility were positively associated with blepharospasm based on moderate-to-severe DED (OR 1.123, 95% CI 1.016-1.240, and 0.036, 95% CI 0.000-0.755, and 10.804, 95% CI 1.157-100.886,  $P=0.023$  and  $P=0.036$  and  $P=0.037$ , respectively).

**Conclusion:** This study demonstrated that moderate-to-severe DED patients with blepharospasm had higher eyelid pressure, lower CFS, lower PBR, higher TB, higher grade of meibum expressibility and higher grade of meibum quality than those without blepharospasm. Moderate-to-severe DED patients with higher eyelid pressure, lower PBR and worse meibum expressibility have higher risk of blepharospasm. Eyelid dynamics should be taken more attention in the clinical diagnosis and treatment of DED and blepharospasm.

PP-187

**Quantitative evaluation of corneal changes after phacovitrectomy using corneal densitometry: a prospective single arm trial**X Liu<sup>1,2</sup>, Y Bi<sup>1,3</sup>.

<sup>1</sup>Ophthalmology, Tongji Hospital, School of Medicine, Tongji University, Shanghai, <sup>2</sup>Ophthalmology, Guizhou Provincial People's Hospital, Guiyang, <sup>3</sup>Tongji Eye Institute, Tongji University School of Medicine, Shanghai, People's Republic of China

**Objective:** To quantitatively investigate corneal changes and the correlation between corneal densitometry (CD) and endothelial parameters after phacovitrectomy.

**Methods:** Thirty-eight eyes with idiopathic full-thickness macular hole (iFTMH) and cataracts underwent phacovitrectomy. Examinations were conducted at baseline and 1 day, 7 days, 1 month, and 3 months postoperatively. CD and central corneal thickness (CCT) were measured using Pentacam. Corneal endothelial cell density (ECD), coefficient of variation (CD), and hexagonality (HEX) were measured using specular microscopy.

**Results:** ECD and HEX significantly decreased after surgery ( $p < 0.001$ ), and the change in HEX occurred prior to CV. CCT increased immediately after surgery and recovered three months postoperatively. CD values in all layers and annular zones increased significantly 1 day after surgery and then gradually decreased. For CD in the 0-2 mm zone, it took 1 month to recover in the central and posterior layers and 3 months in the anterior and total layers. For CD in the 2-6 mm zone, the central layer recovered at day 7, the anterior and total layers recovered at 1 month, and the posterior layer did not recover until 3 months postoperatively. The CD within all layers in the 0-2 mm zone was positively correlated with CCT. Posterior CD in the 0-2 mm zone was negatively correlated with ECD and HEX.

**Conclusion:** CD is an objective, rapid, and noninvasive tool that reflects corneal health and monitors the process of lesion repair. Understanding the lesion area in advance can effectively avoid iatrogenic injury, especially in patients with subclinical lesions.

PP-188

**Risk of Pterygium in eyes with Short Axial Length**P Gangopadhyay<sup>1</sup>, S Thakur<sup>1</sup>, S Sarkar<sup>1</sup>, P Khatua<sup>1</sup>.<sup>1</sup>Midnapore Medical College, Midnapore, India**Objective:** To assess the relationship of the prevalence of Pterygium with Axial Length.**Methods:** A prospective cross-sectional study was performed to compare 63 eyes of 52 patients with primary pterygium in at least 1 eye with 60 age matched normal eyes. Each patient was subjected to measurement of axial length using USG A scan.**Results:** Eleven patients had bilateral pterygium. Twenty-six eyes had stage I, 20 had stage II and 17 had stage III pterygium. The average axial length in the pterygium group was  $22.77 \pm 0.92$  mm which was significantly shorter than the control group which was  $23.81 \pm 1.02$  mm ( $p=0.0002$ ). The average axial length among the patients with stage I was  $23.06 \pm 0.95$  mm, stage II was  $22.72 \pm 0.9$  mm and stage III were  $22.09 \pm 0.55$  mm. The average axial length was significantly shorter in stage III pterygium ( $p=0.008$ ) in comparison to stage I and II. The prevalence of hyperopia in the pterygium group was higher than that in the normal population. It also should be noted that outdoor time and sunlight exposure are related to pterygium.**Conclusion:** Thus, we can conclude that shorter axial length is related to the prevalence and progressive nature of pterygium.

PP-189

**Accuracy of automated software for assessing endothelial cell loss on trypan-stained, peeled DMEK**

A Bae<sup>1</sup>, P Bedard<sup>1</sup>, S Lee<sup>1</sup>, C Yuan<sup>1</sup>, J Hou<sup>1</sup>.

<sup>1</sup>Lions Gift of Sight, St. Paul, MN, United States

**Objective:** To compare the accuracy of automated image analysis software against manual segmentation software and evaluator estimates for assessment of area of endothelial cell loss (ACL) in peeled DMEK.

**Methods:** 50 transplant-grade donor corneas were peeled, stamped, and trephined. Endothelium was stained with trypan blue and imaged under a dissecting microscope with diffuse backlighting. Images were then assessed for ACL using automated software, manual software, and evaluator estimates. Automated analysis was performed using a custom macro built on Aphelion software (ADCIS, S.A., Saint-Contest, France) to instantly segment and calculate ACL. Manual analysis was performed by two experienced, blinded operators using the trainable Weka segmentation Fiji plugin in ImageJ software (NIH, Bethesda, MD). Evaluator estimates were obtained by two experienced, blinded evaluators trained in the Diabetes Endothelial Keratoplasty Study protocol.

**Results:** There was no statistically significant difference in mean ACL between automated analysis ( $6.3\% \pm 1.5\%$ ), manual analysis ( $6.0\% \pm 1.5\%$ ), and evaluator estimates ( $6.1\% \pm 3\%$ ) ( $p=0.66$ , one-way ANOVA). There was a statistical difference in mean ACL between operators for both manual analysis ( $p<0.01$ , t-test) and evaluator estimates ( $p<0.01$ , t-test). On linear regression analysis, automated ACL correlated positively with the manual ACL ( $r^2 = 0.25$ ). Evaluator estimates were more likely than automated ACL to miss the manual ACL by  $>5\%$  (8% vs 0% of samples).

**Conclusion:** Automated software can accurately calculate ACL on trypan-stained, peeled DMEK grafts and may be useful for assessing post-processing endothelial quality.



PP-190

**EARLY MANAGEMENT OF CORNEAL TRANSPLANT REJECTION**

T Elongo, L Kora<sup>1</sup>, M Issa Mahamat Adoudou<sup>1</sup>, G Daghouj<sup>1</sup>, L Elmaaloum<sup>1</sup>, B Allali<sup>1</sup>, A Elkettani<sup>1</sup>.

<sup>1</sup>*Pediatric ophthalmology, Hôpital 20 août 1953, Casablanca, Morocco*

**Objective:**

Corneal allograft rejection is the main complication and the leading cause of full-thickness keratoplasty failure. The aim of our work is to present the results of the management of corneal transplant rejections in our structure.

**Methods:** This is a retrospective study of 10 patients followed in our structure for penetrating keratoplasty complicated by rejection; carried out over a period of 5 years.

**Results:** The average age at the time of rejection was 36.4 years with a male predominance.

The signs of calls were dominated by a red eye and a decrease in visual acuity.

The majority of patients had visual acuity less than 3/10 at the time of graft rejection.

Endothelial rejection was the most frequently found type of rejection.

The main risk factor for rejection found was corneal neovascularization.

The treatment associated hospitalization, systemic corticosteroid therapy by intravenous bolus for 3 days then oral relay, locoregional corticosteroid therapy, topical corticosteroid therapy; but also and above all the management of the underlying risk factors for rejection.

Visual recovery after the transplant rejection episode was at least 5 lines of visual acuity in 70% of cases

**Conclusion:** Corneal allograft rejection is a complex immunological process that can affect the different layers of the cornea, endothelial rejection being the most serious form. In some cases, rejection will lead to permanent graft failure.

Knowing the risk factors makes it possible to adapt surveillance and establish early and effective treatment in the subjects most at risk. It is essential to consult the patient before any warning sign.

PP-191

**Demographic Profile and Etiology of Limbal Stem Cell Deficiency**V Singh, R Kusumesh, V kumar.

**Objective:** we aimed to determine demographic features and underlying causes of LSCD in eastern state of India

**Methods:** This was a tertiary hospital based single centre Prospective case series done during April 2019 to March 2020. Medical records of all the patients with a diagnosis of LSCD were recorded and analyzed. In order to make the sample representative of the whole population, no preference was given to age, gender, ethnicity or religion.

**Results:** A total of 183 eyes of 122 patients with LSCD were included in our study, age ranging from 5 – 85 years ( $35.0 \pm 19.4$  years). Most common presenting complains were decrease in vision 118 (96.7%) followed by photophobia 77 (63.1%) then redness 68 (55.7%), tearing 64 (52.5%) and blepharospasm 16 (13.1%). Out of 122 patients, 35 (28.7%) patients were of chemical injury, 31 (25.4%) patients were of SJS/TEN followed by 15 (12.3 %) patients of VKC.

**Conclusion:** LSCD cases require different approach of management depending upon underlying causes, laterality and severity of disease.

PP-193

**Corneal Striae in Thyroid Associated Orbitopathy**X Liao<sup>1</sup>, K Lai<sup>1</sup>, C Pang<sup>1</sup>, C Tham<sup>1</sup>, K Chong<sup>1</sup>.<sup>1</sup>Department of Ophthalmology and Vision Sciences, The Chinese University of Hong Kong, Hong Kong, Hong Kong, China**Objective:** To compare the orbital and ocular surface parameters of eyes with and without corneal striae (CS) in thyroid associated orbitopathy (TAO) patients.**Methods:** A prospective cohort of TAO patients managed at the Chinese University of Hong Kong from January 2021 to March 2022. Orbital parameters including 7-item clinical activity score(CAS), intraocular pressure(IOP) at primary and upgaze, margin reflex distance of the upper and lower eyelid(MRD1 and MRD2), lateral flare, lagophthalmos, and Hertel exophthalmometry were evaluated by a single orbital surgeon. Ocular surface parameters included the score of ocular surface disease index(OSDI), tear meniscus height(TMh), non-invasive tear break up time(NIKBUT) by keratography; partial blinking rate, lipid layer thickness(LLT) by interferometry, meibomian gland dropout(Meiboscore) on infrared meibography, Schirmer's test, and slit-lamp evaluation of CS after fluorescent staining.**Results:** A total of 80 consecutive TAO patients (female=59) were recruited. 22 eyes (from 15 patients) were found to have CS. Fifteen(19%) patients had one eye developing CS while 7 bilaterally. Eyes with CS have higher CAS, IOP, MRD1, Lateral flare, OSDI, Lipid layer thickness, TMh, and more severe lagophthalmos, incomplete blinking than eyes without CS (all P<0.05). In the multivariable analyses, the CAS (OR:2.28, 95%CI: 1.49,3.48), primary-gaze (OR:1.18, 95%CI: 1.00, 1.40), upgaze IOP(OR:1.12, 95%CI: 1.01, 1.25), MRD1 (OR:1.45, 95%CI: 1.04, 2.03), Lagophthalmos (OR:3.14, 95%CI: 1.79, 5.53) and OSDI (OR:1.06, 95%CI: 1.03, 1.10) were significantly associated with the presence of CS (All P<0.05).**Conclusion:** In this cross-sectional study, CS was significantly associated with higher CAS, IOP, MRD1, Lagophthalmos, and OSDI. CS should be further evaluated as non-invasive biomarker reflecting ocular surface and eyelid involvement in TAO.

PP-194

**Ocular Graft Host Disease after allogeneic stem cell transplant: Unique risk factors and outcomes**

M Abdel Fattah<sup>1,2</sup>, G ElGohary<sup>3,4</sup>, H Shahrukh K.<sup>5,6</sup>.

<sup>1</sup>Ophthalmology , King Faisal Specialist Hospital & Research Center, Riyadh, Saudi Arabia, <sup>2</sup>Ophthalmology , College Of Medicine Kasr AlEini Hospital- Cairo University , Cairo, Egypt, <sup>3</sup>Medicine: Hematology/Oncology Division(Oncology center), College of Medicine, King Khaled University Hospital, King Saud University, Riyadh, Saudi Arabia, <sup>4</sup>Adult Hematology/Internal Medicine Department, Ain Shams University , Cairo, Egypt, <sup>5</sup>Medicine, Mayo Clinic, Rochester, MN, United States, <sup>6</sup>Medicine, Sheikh Shakhbout Medical City, Abu Dhabi, United Arab Emirates

**Objective:** Formulate retrospective, observational & descriptive study to investigate the ocular findings in long-term survivors after allo-HSCT

**Methods:** Chronic ocular GVHD inclusion was based on following: history of allogeneic HSCT, post-HSCT self-reported onset of dry eye symptoms (OSDI score > 13) required frequent topical eye drops, signs of ocular surface disease included any two of the following: decreased Schirmer test ( $\leq 11$  mm), presence of corneal fluorescein staining and low TBUT:  $\leq 10$  sec. Patients with probable or definite ocular GVHD based on ICCGVHD were included. VA, TBUT, corneal fluorescein staining, Schirmer test, slit lamp and dilated ophthalmoscopy were recorded

**Results:** 394 patients were diagnosed as having chronic GVHD within the first 5 years after transplantation. Ocular GVHD detected in 81 patients (20.5%), which were divided into Group 1 (65 patients) with mild to moderate ocular GVHD while group 2 (16 patients) with severe one. Mild- moderate ocular GVHD defined as  $\leq 3$  corneal staining, 13-32 points OSDI, schirmer test: 6-15 mm while severe ocular GVHD defined as  $> 4$  corneal staining,  $\geq 33$  points OSDI,  $\leq 5$  mm schirmer test. HLA matched donor with identical MSD in 72 patients, peripheral blood was the source of stem cell in 61 patients. Myeloablative conditioning regimen in 73 patients. NIH score for all patients ranged from 2-7. Conjunctival injection was detected in 54 patients, 26 patients showed corneal staining, 4 patients developed corneal ulcers, 9 patients developed bilateral MGD, 2 patients had NLD or canalicular obstructions, 1 patient with acute dacryocystitis, 1 patient showed recurrent conjunctivitis. Retinal changes were detected in 5 patients, optic disk changes in 2 patients, steroids-induced PDR: 3 patients, old BVO: 1 patient. VA was 20/20 in 16 patients in Group 1, 3 patients in group 2, mild impaired VA (20/22-20/50) was detected in 43 patients in group 1 and 9 patients in group 2. Moderate impairment of the VA (20/70- $>$  20/200) was recorded in 6 patients of group 1 and one patient in group 2. Severe decline ( $\leq 20/200$ ) was found in 3 patients in group 2 while no patients in group 1. All patients with identical MSD showed normal or mildly to moderate impaired VA except for 2. All patients responded to topical eye drops except for 9 requiring surgical procedure. 59 patients of group 1 showed normal or mild impaired VA with statistical significance. 42 male patients/29 female had normal or mild impaired VA with statistical significance.

**Conclusion:** Ocular GVHD is a complex disease in our unique population

PP-195

**ROLE OF TEAR FILM MUCOUS FERNING TEST IN MEIBOMIAN GLAND DYSFUNCTION**N Adlakh<sup>1</sup>.<sup>1</sup>SHKM GMC MEWAT, GURUGRAM, India**Objective:** To evaluate the role of tear mucus ferning test for Meibomian gland dysfunction**Methods:** A prospective observational study was carried out on 104 eyes of 104 patients with Meibomian gland dysfunction. Informed consent was obtained from all the subjects. All subjects had a comprehensive ophthalmological examination including evaluation of tear film using Schirmer test I, Tear film breakup time (TBUT) and tear ferning test. 1  $\mu$ l of unstimulated tears were collected using a capillary tube and allowed to air dry at room temperature for 10 min. Tear ferning pattern (TFP) was observed using light microscope and photographs of each sample were taken immediately to avoid any changes in the ferning pattern. Rolando's tear ferning classification was used to categorise the ferning pattern.**Results:** The maximum numbers of patients (40%) were in the age group 30-40 years. The mean TBUT was  $6.9 \pm 0.5$  seconds. The mean Schirmer tear test score was  $14.8 \pm 4.6$  mm. Abnormal fern pattern type III was observed in 14 (28 %) eyes and type IV in 9 (18 %) with Meibomian gland dysfunction.**Conclusion:** As pattern of ferning depends on tear composition, so ferning test is easy and cost effective for assessing tear film quality at a gross biochemical level and can be used in Meibomian gland dysfunction. A combination of tear ferning test with other tear film tests in the clinic may then provide a real evaluation of the tear film and dry eye and may help in the management of dry eye.

PP-196

**An Assessment of Ocular Surface in Patients with Thyroid Disorder**A Saini.

**Objective:** To undertake a comparative study on ocular surface health in patients with thyroid disorder, with and without eye signs, as compared to controls in terms of measures of dry eye .

**Methods:** A Cross-sectional, Observational and Comparative Study was conducted between November 2019 to April 2021 at UCMS Medical College, New Delhi.

90 subjects were recruited for the study and be divided into 3 groups as follows-Group A [Thyroid Disorder without eye disease] =30, Patients Group B [Thyroid Eye disease] = 30 Patients, Group C [Controls] = 30 Subjects Detailed ocular examination was done and Tests which were carried out included Hertel exophthalmometry, IOP measurement, Schirmer's test-I,BST, TUBT, Impression cytology and tear ferning.

For statistical evaluation only the right eye of Group 1 and controls were taken. In group 2, the affected eye of the patients was taken. The data thus collected was analyzed with appropriate statistical tests

**Results:** • **Mean Schirmer I score was significantly more in Thyroid disorder group (group 1+2) than controls (p=0.016)**

- **Patients with thyroid disorder, with and without eye signs, had significantly more severe grades of Schirmer I test as compared to controls (p=0.002).**
- Average BST was significantly lower in thyroid disorder group (Group 1+2) compared to control (p=0.015).
- **Patients with thyroid disorder (Group 1+2), with and without eye signs, had significantly severe grades of BST as compared to control (p=0.007)**
- Mean TBUT was significantly more in Thyroid disorder group (Group 1+2) as compared to controls (p=0.008). Thyroid eye disease group had a significantly lower TBUT score compared to controls (p=0.016)
- **Grading of TBUT showed a significant difference between the three groups (p=0.042) with 40.6% patients of thyroid eye disease**
- **A significant correlation between Schirmer's I test and amount of proptosis was seen**

**Conclusion:**

- Thyroid disorder, irrespective of eye signs, **showed a significant correlation with dry eye tests- Schirmer I test, BST and TBUT. Between thyroid eye disease and thyroid disorder without eye signs, impression cytology was found to be significantly different** but other tests didn't differ significantly.

- Thyroid eye disease and controls differed significantly in Schirmer I test, BST and TBUT.
- Thyroid disorder without eye signs significantly differed from controls in Schirmer I test and BST only.

PP-198

**Retrospective Analysis of 326 Cases of Keratoplasty in Southern region of Liaoning**X Wu<sup>1</sup>, H Dong<sup>1</sup>, L Zhang<sup>1</sup>.<sup>1</sup>Ophthalmology department, The Third People's Hospital of Dalian, Dalian, People's Republic of China

**Objective:** To investigate the epidemiological characteristics and spectrum of corneal primary diseases of keratoplasty patients in southern region of Liaoning province, and to study the changing trend of transplantation types.

**Methods:** The medical records of 326 patients who received keratoplasty in department of Ophthalmology of The Third People Hospital of Dalian from 2017 to 2021 were retrospectively analyzed. The age, gender, primary corneal disease types and transplantation types were statistically analyzed.

**Results:** A total of 326 patients who received keratoplasty were performed during the 5 years. The average age of patients was  $(54.77 \pm 16.64)$  years old, ranging from 5 years old to 90 years old. There were 200 males (61.3%) and 126 females (38.7%), with a ratio of 1.59:1. Among the primary corneal diseases, keratitis was the most common (129 cases, 39.6%), followed by corneal leucoma (49 cases, 15.0%), corneal graft rejection (28 cases, 8.6%), corneal endothelial decompensation (33 cases, 10.1%), keratoconus (19 cases, 5.8%), corneal dystrophy and degeneration (22 cases, 6.9%), traumatic corneal injury (including chemical injury, thermal burn, post-traumatic corneal scar and opacity, 24 cases, 7.4%), immune corneal ulcer (15 cases, 4.6%) and corneal tumor (7 cases, 2.1%). According to the detailed etiology of infectious keratitis, the order was fungal keratitis (69 cases, 21.2%), bacterial keratitis (36 cases, 11.0%), viral keratitis (23 cases, 7.1%) and acanthamoeba keratitis (1 case, 0.3%). According to the classification of corneal transplantation methods, there were penetrating keratoplasty (PKP) (162 cases, 49.7%), deep lamellar keratoplasty (DALK) (65 cases, 19.9%), lamellar keratoplasty (LKP) (49 cases, 15.0%), endothelial transplantation (EK) (18 cases, 5.5%), and therapeutic keratoplasty (TK) (32 cases, 9.8%).

**Conclusion:** Among corneal primary diseases of keratoplasty patients in southern region of Liaoning province, the leading indication is infectious keratitis, followed by corneal leucoma, corneal graft rejection, corneal endothelial decompensation, keratoconus, corneal dystrophy and degeneration, traumatic corneal injury, immune corneal ulcer and corneal tumor, and fungal infection is the first cause of infectious keratitis. PKP is still the most popular corneal transplantation method, but the proportions of DALK, LKP and EK are increasing. TK is relatively stable as an emergency operation when no fresh corneal graft is available.

PP-199

**Microbial keratitis and associated microorganisms in optic, therapeutic and non-contact lens users**

K Saldaña Rodríguez<sup>1</sup>, K Mohamed Noriega<sup>1</sup>, G Villarreal Mendez<sup>1</sup>, F Morales Wong<sup>1</sup>, A Cavazos Tamez<sup>1</sup>, D Rodriguez Medellin<sup>1</sup>, B Velasco Sepulveda<sup>1</sup>, J Mohamed Hamsho<sup>1</sup>.

<sup>1</sup>Ophthalmology, Hospital Universitario Dr. José Eleuterio González, Monterrey, Nuevo Leon, Mexico

**Objective:** To compare demographic characteristics, severity of presentation, microorganisms involved, and prognosis of perforation in microbial keratitis among users of optic contact lenses, therapeutic contact lenses, and non-contact lens users

**Methods:** Retrospective, cross-sectional, observational, descriptive study. The database of patients diagnosed with infectious keratitis from the Department of Ophthalmology of University Hospital of the Autonomous University of Nuevo León for the period 2009-2020 was retrospectively reviewed. The patients were studied in demographics, clinical characteristics of presentation, degree of severity, risk factors for perforation and associated microorganisms and were compared between users of optic contact lens (OCL), therapeutic (TCL) and non-users of contact lens (NCL)

**Results:** 651 patients with infectious keratitis were studied. The most frequent indication for TCL in our population was corneal epithelial defect (60%), followed by bullous keratopathy (34.7%). OCLs are more common in women under 30 years of age. ( $p < 0.001$ ). TCLs are more frequent in men older than 40 years ( $p < 0.001$ ). The clinical presentation characteristics of the different groups are very similar to each other. The diameter of the lesion is greater in OCL users than in TCL. The presence of hypopyon is more frequent in CL users and they have a severe presentation. ( $p < 0.001$ ). Having bullous keratopathy, central lesions greater than 5mm with thinning have a higher risk of hypopyon. Positive culture was obtained in 55% of patients. Pseudomonas aeruginosa was the most frequent microorganism in all groups, even in the presence of surface disease.

**Conclusion:** There are differences in relation to the added risk factors and severity among optic contact lens wearers, therapeutic contact lens wearers, and non-contact lens wearers. Microbial keratitis in contact lens wearers with or without ocular surface disease is at increased risk for Pseudomonas aureginosa.



## PP-200

## Analysis of Image feature based on tear film dynamic changes in dry eye patients

J Ding<sup>1</sup>, J Xue<sup>1</sup>, X Han<sup>1</sup>.

<sup>1</sup>The affiliated Eye Hospital of Nanjing Medical University, Nanjing, Jiangsu Province, People's Republic of China

**Objective:** To investigate the image features of dynamic changes of fluorescein tear film breakup combined with its tear film lipid layer (TFLL) dynamic changes in patients with dry eye and its value of diagnosis in dry eye.

**Methods:** A prospective study. A total of 132 eyes in 66 patients with dry eye admitted to our hospital during 2019-09/2020-12 were divided into five groups: area break-up group (AB, n = 28 eyes), circle break-up group (CB, n = 27 eyes), line break-up group (LB, n = 28 eyes), spot break-up group (SB, n = 24 eyes) and random break-up group (RB, n = 25 eyes) according to the different fluorescein tear film breakup patterns (BUPs). The image features of FL tear film dynamic changes, TFLL grading, first non-invasive tear film break-up time (NIBUT<sub>f</sub>), average non-invasive tear film break-up time (NIBUT<sub>av</sub>), tear meniscus height (TMH) and fluorescein staining (FL) score were compared among the five groups.

**Results:** A statistically significant difference was observed among the five groups for the NIBUT<sub>f</sub> ( $F = 113.62$ ,  $P < 0.001$ ). Except that there was no difference between SB and RB ( $P = 0.881$ ), other groups had significant differences in pairwise comparisons (all  $P < 0.05$ ) for NIBUT<sub>f</sub>. There was statistically difference among the five groups for NIBUT<sub>av</sub> ( $F = 100.96$ ,  $P < 0.001$ ). Except that there was no difference between SB group and RB group ( $P = 0.997$ ), other groups had significant differences in pairwise comparisons (all  $P < 0.05$ ) for NIBUT<sub>av</sub>. There was statistically difference among the five groups for TMH ( $F = 23.71$ ,  $P < 0.001$ ). Except that there was no difference between CB group and LB group ( $P = 0.986$ ), between SB group and RB group ( $P = 0.993$ ), other groups had significant differences in pairwise comparisons (all  $P < 0.05$ ) for TMH. Difference of FL scores of five groups was statistically significant ( $H = 33.291$ ,  $P < 0.001$ ). There was statistically significant difference among five groups for FL scores ( $H = 33.291$ ,  $P < 0.001$ ) and TFLL grading ( $H = 70.855$ ,  $P < 0.001$ ).

**Conclusion:** It is shown that different fluorescein BUPs intuitively reflects the tear film structure of the pathological changes according to evaluation and analysis of images feature of dynamic changes of FL tear film and TFLL combined with the results of static examination of tear film. It is helpful for clinicians to identify subtypes of dry eye, which has potential clinical value for the diagnosis and classification of dry eye.

**PP-201****Femto-laser for rehabilitating patients with Fuch`s endothelial dystrophy and PBK using one donor cornea for 2 recipients.**

A Pashtaev<sup>1</sup>, D Sushencova<sup>1</sup>, T Kuznecov<sup>1</sup>.

<sup>1</sup>S.N. FEDOROV NMRC "MNTK "EYE MICROSURGERY", Moscow, Russian Federation

**Objective:** To develop a method of preparation of 2 ultrathin grafts for posterior lamellar keratoplasty using 1 donor cornea and femtosecond laser and to evaluate early clinical outcomes of surgical treatment of patients with Fuch`s endothelial dystrophy and pseudophakic bullous keratopathy.

**Methods:** Alcon Wavelight FS-200 femtosecond laser was used to cut out an ultrathin graft for posterior lamellar keratoplasty with a diameter of 10 mm and a thickness of 130  $\mu\text{m}$ . Then the obtained disc was divided into 2 equal parts. One part corresponds to the graft area with a diameter of 7.2 mm. Eight patients underwent surgical treatment: 4 with Fuch`s endothelial dystrophy and 4 with pseudophakic bullous keratopathy. Each of them underwent posterior lamellar femto-keratoplasty using  $\lambda$  of a donor cornea posterior layer graft.

**Results:** at the follow-up period of 1 month, transparent engraftment was obtained in all cases. BSCVA was 0.3. Corneal astigmatism was  $1.1 \pm 1$  D. ECD -  $1605 \pm 434$  cells/ $\text{mm}^2$

**Conclusion:** the developed method allowed to obtain 8 transplants for posterior lamellar keratoplasty from 4 donor corneas and to perform surgical treatment for 8 patients with achievement of transparent engraftment at the period of observation of 1 month.

## PP-202

**How to collect tear film for biomarkers analysis – Description of a new method of tear samples collection**

A Moleiro, R Vilares-Morgado<sup>1</sup>, I Mendes-Pinto<sup>2</sup>, J Barbosa-Breda<sup>1</sup>, A Rocha-Sousa<sup>1</sup>.

<sup>1</sup>Department of Ophthalmology, São João Hospital, São João University Hospital Center, Porto, <sup>2</sup>International Iberian Nanotechnology Laboratory, Braga, Portugal

**Objective:** Tear fluid constitutes a byproduct of blood, having the potential to provide biomarkers of both ocular and systemic diseases. However, no standardized methods are described to allow the comparison of results. We describe a method developed by our team able to collect, prepare and analyze inflammatory markers in tear.

**Methods:** A sponge (Merocel® ophthalmic sponge) was placed behind the lid margin at the junction of the lateral and middle thirds of the lower eyelids, without an anaesthetic, and kept in place for 2 to 5 min with the eyes closed. The sponges were removed and placed into a sterile 2-ml centrifuge filter tube, centrifuged on 16000 G during 10 minutes at 22°C.

Analysis of tear was performed by previous approved ELISA methods to compare samples regarding to prove the efficacy and reproducibility of our method.

**Results:** This process allows the obtention of tear volumes varying from 1 to 30 uL per sample. The amount of sample obtained is dependent on the time of sponge persistence in the conjunctival cul-de-sac.

Inflammatory biomarkers (IL-6 and TNF-alfa) in each sample are detected with consistent values between different ELISA analysis.

**Conclusion:** Tear sampling provides a readily accessible method, potentially allowing for ambulatory at-home measurement and an easy-to-use option for clinical trials and clinical practice. We provide a simple method that can be easily performed.

PP-203

**Advances in the understanding, diagnostic and treatment of keratoconus**

A Pons Talaya<sup>1</sup>, J *Panthakey*<sup>1</sup>, T *Ayoub*<sup>1</sup>.

<sup>1</sup>*Imperial College Healthcare NHS Trust, London, United Kingdom*

**Objective:** Keratoconus is a bilateral and asymmetric eye condition in which the cornea's structure is affected and thins, causing a cone-shaped bulge to develop. This results in progressive loss of vision and impairs the ability of the eye to focus. The demographic profile of keratoconic patients has prompted the development of novel approaches to diagnosis, early detection, and treatment for visual rehabilitation all contributing to addressing the socio-economic burden of this disease in the past two decades. We aim to review the current landscape to demonstrate the progress made in clinical practice as well as avenues of research being pursued to develop a better understanding of the disease, its aethiology, and diagnostic and therapeutic options

**Methods:** The literature search for this review was carried out on PubMed/MEDLINE and was performed with the help of MeSH from December 2021 to April 2022. Overall, 46 studies were included in this review, dating from 1992 to 2022. Two independent observers have reviewed the totality of the cited literature for accuracy.

**Results:** Although the pathophysiology of keratoconus remains uncertain, the classical non-inflammatory definition has been questioned in the last decade. Advances in diagnostic techniques such as corneal epithelial thickness mapping allow the description and potential early treatment of subclinical stages of keratoconus. Treatment options have evolved greatly over the period reviewed. Newer contact lens modalities have become available for conservative non surgical management and surgical options such as collagen cross linking with the option to combine with laser refractive procedures including topography guided ablation, INTACS, phakic IOLs and there have been further developments in techniques for corneal grafting.

**Conclusion:** Although there have been substantial advances in detecting and treating keratoconus in the past two decades, the ability to perform detailed corneal screening in primary optometric practices remains a specialist application in most areas. Patient awareness and practitioner education tools would make reasonable routes to improving early keratoconus detection in the population.

PP-204

**Long term safety and efficacy of corneal collagen crosslinking with hypoosmolar riboflavin solution in progressive keratoconus**O Ucakhan<sup>1</sup>, T Celik Buyuktepe<sup>1</sup>.<sup>1</sup>Department of Ophthalmology, Ankara University School of Medicine, Ankara, Türkiye

**Objective:** To compare the long-term visual, refractive, topographic and aberrometric changes after corneal collagen crosslinking (CXL) with or without hypoosmolar riboflavin solution in the treatment of progressive keratoconus patients with thin corneas.

**Methods:** Files of keratoconus patients with thin corneas (preoperative central corneal thickness less than 450 µm) who underwent corneal collagen CXL with or without hypoosmolar riboflavin solution were analyzed retrospectively. Uncorrected distance visual acuity (UDVA), best spectacle-corrected distance visual acuity (CDVA), manifest refraction, slit lamp biomicroscopy, corneal tomography, corneal aberrometry and endothelial cell counts were evaluated at baseline and yearly at all postoperative follow-up examinations until month-36. The outcomes were analyzed by dividing the patients according to the use of only isoosmolar riboflavin versus isoosmolar and hypoosmolar riboflavin solution.

**Results:** Twenty-three eyes (19 patients) in the hypoosmolar and 30 eyes (28 patients) in the isoosmolar groups completed 3 years follow-up. Compared to baseline, the mean UDVA, CDVA and keratometric readings improved statistically significantly in both groups at postoperative year-3, without any statistically significant between-group differences. Progression was not observed in any patient eye in either group. There was no change in the mean endothelial cell density ( $p>0.05$ ) or no sight threatening complication.

**Conclusion:** Corneal collagen CXL using hypoosmolar riboflavin solution seems to be safe and effective in halting progression in the thin corneas with keratoconus. The refractive and topographic outcomes of corneal collagen CXL using hypoosmolar riboflavin were comparable to conventional CXL in keratoconic eyes with thin corneas.

## PP-205

**Efficacy of Transepithelial Corneal Collagen Crosslinking on Optical Quality of the Cornea in Keratoconus: 12-month Follow-up**

S Kaya Ergen<sup>1</sup>, S Subasi<sup>2</sup>.

<sup>1</sup>Department of Ophthalmology, Karamursel State Hospital, <sup>2</sup>Department of Ophthalmology, Kocaeli University Faculty of Medicine, Kocaeli, Türkiye

**Objective:** The aim of the study was to evaluate the effect of transepithelial corneal collagen cross-linking (CXL) treatment in progressive keratoconus patients on corneal optical performance between baseline and 1 year after CXL.

**Methods:** The 12-month results of transepithelial cxl treatment in 110 eyes of 67 patients diagnosed with progressive keratoconus were analyzed. The following corneal optical aberrations over the 4-mm-diameter pupil were recorded via Sirius dual-scanning corneal tomography: total, anterior and posterior amount of corneal higher order aberrations [HOAs], vertical coma, horizontal coma, vertical trefoil, oblique trefoil, and spherical aberration, and Strehl ratio of point spread function (PSF). The correlation among HOAs, topographic metrics, and visual acuity changes was also investigated.

**Results:** At 12 months, there was a significant improvement in mean uncorrected visual acuity (UCVA) ( $P < 0.001$ ), and best corrected visual acuity (BCVA) ( $P < 0.001$ ). There were significant improvements in mean root mean square error values for corneal total HOA ( $P = 0.003$ ), total coma ( $P = 0.006$ ), anterior HOA ( $P = 0.007$ ), anterior coma ( $P = 0.004$ ), and vertical coma ( $P = 0.002$ ) following CXL. No significant changes were found in the posterior parameters. In addition, PSF value did not change after CXL ( $P > 0.05$ ). The corneal topographic measurements not revealed a change in the mean simulated keratometry-1, simulated keratometry -2, and maximum keratometry compared with the baseline measurements ( $P > 0.05$ , for all). Most corneal aberrations correlated significantly with postoperative BCVA, but changes in HOAs were not statistically associated with improvements in visual acuity.

**Conclusion:** Transepithelial CXL was effective in stabilizing the keratometric indices and improving the visual acuity and most corneal aberrations in eyes with progressive keratoconus 1 years after the procedure. However, these improvements were not enough to increase corneal the Strehl ratio of PSF.

PP-206

**Reliability of Web-Based Version of OSDI-6 Questionnaire in a Chinese Population**G Qin, E Pazo<sup>1</sup>.<sup>1</sup>He Eye Specialist Hospital, No.128 North Huanghe Street, Shenyang, People's Republic of China

**Objective:** The aim of this study was to virtually evaluate the reliability of the Chinese translation version of OSDI-6 questionnaire for dry eye.

**Methods:** A total of 270 participants (136 males, 50.4% and 134 females, 49.6%) with a mean age of  $28.22 \pm 9.01$  years were assessed, diagnosed under the criteria put forth by Dry eye workshop (DEWS) completed the Chinese translated version of the OSDI-12 questionnaire (C-OSDI-12). Validity, and psychometric properties were analyzed using the study data on the selected items (a new approach called virtual validation). For implementation in the new, shorter C-OSDI-6 questionnaire, 6 items were extracted from the C-OSDI-12 as suggested by the authors of OSDI-6 and compared. Demographic characteristics, validity of total score were evaluated with Spearman rank correlation, and Rasch analysis.

**Results:** The total scores of C-OSDI-12 and C-OSDI-6 were  $30.27 \pm 13.19$  and  $6.95 \pm 3.53$  respectively. Significant reliability was found between total C-OSDI-6 score and total C-OSDI-12 score ( $r = 0.865$ ,  $p < 0.001$ ). Infits and outfits of the C-OSDI-6 were between 1.26 and 0.78.

**Conclusion:** The C-OSDI-6 proved to be valid, and psychometrically responsive in Chinese dry eye participants. The findings of this virtual validation study need to be confirmed in a longitudinal validation study on the real-world use.

PP-207

**Vascular-homing peptide-dexamethasone nano-prodrug for targeted drug delivery and improving corneal neovascularization therapy**Q Yin<sup>1</sup>, X Shentu<sup>1</sup>.<sup>1</sup>Eye Center of the Second Affiliated Hospital, School of Medicine, Zhejiang University, Hangzhou, People's Republic of China

**Objective:** Corneal neovascularization (CNV) is a major cause of vision loss and the bioavailability of traditional drug treatments is limited, due to rapid precorneal removal and absent precise delivery. To overcome these drawbacks, we have developed dexamethasone (Dex) modified by polyethylene glycol (PEG)-conjugated vascular-homing peptide (Ala-Pro-Arg-Pro-Gly, APRPG), to obtain a novel prodrug (Dex-PEG-APRPG, DPA). This study is to investigate the effect of DPA for inhibiting CNV by targeting neovessels effectively.

**Methods:** The prodrug was prepared by conjugation of Dex to PEG modified vascular-homing peptide (PEG-APRPG) and self-assembled into a nanoparticle. Cell-targeted capacity study was performed in human umbilical vein endothelial cells. C57BL/6 mice were subjected to unilateral corneal burn induced by NaOH and topically treated with normal saline (NS), Dex solution (0.2 mM, DMSO/H<sub>2</sub>O: 0.1%), and DPA (0.2 mM), three times daily for 14 consecutive days. Clinical examinations were performed under a slit lamp microscopy and anterior segment optical coherence tomography on days 3, 7, 14. After mice were euthanized on day 14, eyeballs were harvested for histologic analysis and corneas were immune-stained to quantify angiogenesis. Besides, polymerase chain reaction was taken to measure the expression of VEGFs, MMPs and IL-6 in whole cornea lysates.

**Results:** DPA, with its small diameter and good biocompatibility in ophthalmic drug delivery, showed a specific target on vascular endothelial cells. Mice treated with DPA had significantly reduced CNV area (4.74 mm<sup>2</sup>) and less inflammatory cells, compared by the treatments of NS (6.72 mm<sup>2</sup>) and Dex (5.88 mm<sup>2</sup>). The immunofluorescence staining of CD31 suggested decreased neovessels in the DPA group. Similarly, remarkable downregulations of VEGF-A, VEGF-C, VEGF-D, MMP-9, MMP-2, and IL-6 mRNA levels were exhibited in the treatment of DPA.

**Conclusion:** DPA, as a novel prodrug, is able to target neovascularization and possesses enhanced therapeutic benefit compared to Dex, which has the potential to become a safe and efficient treatment of CNV.



PP-209

## Comprehensive Bioinformatics Analysis to Reveal Key RNA Targets and Hub Competitive Endogenous RNA Network of Keratoconus

S Ouyang.

**Objective:** Keratoconus (KC) is the most common corneal ectatic disease with its pathological mechanisms unclear. We mainly performed bioinformatics approaches to reveal core RNA targets, hub competitive endogenous RNA (ceRNA) network and explored the potential regulatory mechanisms of ceRNA in KC.

**Methods:** The high-throughput sequencing datasets GSE77938 and GSE151631 were downloaded from the Gene Expression Omnibus (GEO) database. We identified the differential expression of mRNAs and lncRNAs using DESeq2 package. Functional enrichment analyses and protein-protein interaction (PPI) were performed. Then, the hub genes were filtered and molecular docking analysis was performed. Moreover, we predicted miRNAs through website database and validated using quantitative PCR (qPCR). Eventually, lncRNA-miRNA-mRNA regulatory network was constructed by Cytoscape.

**Results:** We revealed that 428 intersected differentially expressed mRNA (DEGs) and 68 intersected differentially expressed lncRNA (DELs) were shared between the two datasets. Functional enrichment results novelty showed that ubiquitin – dependent protein catabolic process was upregulated in KC. The pathway enrichment showed DEGs were mainly involved in NF- $\kappa$ B signaling and neurodegenerative diseases. In addition, we uncovered top 20 hub genes in which FBXW11, FBXO9, RCHY1 and CD36 were validated by qPCR. Particularly, a small molecule drug, Triptolide was predicted by molecular docking as candidate drug for treating KC. Moreover, we innovatively predicted and validated 4 core miRNAs (miR-4257, miR-4494, miR-4263 and miR-4298) and constructed ceRNA network which contained 165 mRNA, 8 lncRNAs and 4 core miRNAs. Finally, we proposed a potential regulatory mechanism of KC.

**Conclusion:** Overall, we uncovered a hub ceRNA network that might underlie a critical post-translational regulatory mechanism in KC, in which miR-4257, miR-4494, miR-4263 and miR-4298 could be valuable biomarkers and provided core RNAs therapeutic targets for KC.

**PP-210****Clinical outcome and course of Tenon's patch graft in corneal perforations and descemetocelles**

R Kusumesh<sup>1</sup>, A Singh<sup>1</sup>, N Mohan<sup>1</sup>, A Ambasta<sup>1</sup>.

<sup>1</sup>Ophthalmology, Indira Gandhi Institute of Medical Sciences, Patna, India

**Objective:** To determine the efficacy and course of TPG for corneal perforation and descemetocelle.

**Methods:** Medical records of 83 patients (85 eyes) who underwent TPG for corneal perforation (58, 68%) or descemetocelle (27, 32%) between July 2018 and October 2021 were reviewed retrospectively. Grafts were secured with fibrin glue and overlay sutures using 10-0 monofilament nylon. Clinical examination and anterior segment optical coherence tomography (AS-OCT) were performed at every follow-up visit. Clinical success was considered as restoration of the structural integrity with formation of scar and anterior chamber.

**Results:** The mean size of the corneal lesion (corneal perforation or descemetocelle) was  $4.20 \pm 1.01$  mm. The mean follow-up period was  $9.2 \pm 5.48$  months. The common underlying etiologies were infectious keratitis in 48% and autoimmune disorders in 35% of cases. TPG successfully restored the globe integrity in 74 (87%) eyes (83% in perforation, and 96% in descemetocelle). Graft failure occurred in 11 eyes (13%). The failures were due to graft dehiscence (8 eyes), graft ectasia (1 eye), and scarring with flat anterior chamber (2 eyes). Median time to epithelialization and scar formation were 3 weeks (range, 2 to 5 weeks) and 15 weeks (range, 12 to 20 weeks), respectively. Predictors of a successful outcome included descemetocelle, non-infective etiology, viral keratitis in infective etiology, and paracentral or peripheral lesions.

**Conclusion:** TPG can be considered as an effective and inexpensive treatment for restoring the structural integrity in the eyes with perforations and descemetocelles, particularly when the donor tissue is unavailable. AS-OCT is a valuable non-invasive tool for monitoring the graft status.

PP-212

**Reduced Quality of Life in Ocular Graft-versus-Host Disease After Hematopoietic Stem Cell Transplantation**Y Liao<sup>1</sup>, L Liang<sup>1</sup>.<sup>1</sup>State Key Laboratory of Ophthalmology, Zhongshan Ophthalmic Center, Sun Yat-sen University, Guangzhou, People's Republic of China

**Objective:** To compare the vision-specific and cancer-specific quality of life (QOL) between patients with and without ocular graft-versus-host disease (oGVHD) after allogeneic hematopoietic stem cell transplantation (alloHCT).

**Methods:** This cross-sectional observational study analyzed 142 patients after alloHCT including 94 patients with oGVHD and 48 without. oGVHD was diagnosed according to International Chronic Ocular GVHD Consensus Group (ICOGCG) criteria. QOL was assessed by using the 25-item National Eye Institute Visual Function Questionnaire (NEI VFQ-25) and the European Organization for Research and Treatment of Cancer Quality of Life Questionnaire-Core 30 (EORTC QLQ-C30).

**Results:** Compared with non-oGVHD patients, patients with oGVHD had worse vision-specific (NEI VFQ-25:  $64.8 \pm 20.1$  vs.  $77.2 \pm 19.1$ ,  $P=0.001$ ) and cancer-specific (EORTC QLQ-C30:  $59.9 \pm 20.3$  vs.  $67.4 \pm 17.5$ ,  $P=0.03$ ) QOL, as well as impaired cognitive function ( $72.7 \pm 22.1$  vs.  $82.3 \pm 19.0$ ,  $P=0.01$ ). The vision-specific QOL was significantly correlated with post-alloHCT medical expense ( $\beta = -6.25$ , 95%CI: -10.86 to -1.64,  $P=0.008$ ) and ICOGCG score ( $\beta = -1.84$ , 95%CI: -3.30 to -0.38,  $P=0.02$ ). While cancer-specific QOL was strikingly correlated with post-alloHCT medical expense ( $\beta = -9.91$ , 95%CI: -14.43 to -5.39,  $P<0.001$ ), frequency of ophthalmic medication ( $\beta = -0.93$ , 95%CI: -1.64 to -0.21,  $P=0.01$ ), education ( $\beta = -6.97$ , 95%CI: -13.31 to -0.62,  $P=0.03$ ) and peripheral blood stem cell use ( $\beta = -6.42$ , 95%CI: -12.59 to -0.25,  $P=0.04$ ).

**Conclusion:** Patients with oGVHD experienced significant impairment in both vision-specific and cancer-specific QOL including cognitive function when compared with those without after alloHCT. Multidimensional QOL assessment should be included in the long-term alloHCT survivorship care.

PP-213

**Ocular Wnt/ $\beta$ -Catenin Pathway Inhibitor XAV939-Loaded Liposomes for Treating Alkali-Burned Corneal Wound and Neovascularization**Y Zhong.

**Objective:** Corneal wound involves a series of complex and coordinated physiological processes, leading to persistent epithelial defects and opacification. An obstacle in the treatment of ocular diseases is poor drug delivery and maintenance.

**Methods:** In this study, we constructed a Wnt/ $\beta$ -catenin pathway inhibitor, XAV939-loaded liposome (XAV939 NPs), and revealed its anti-inflammatory and antiangiogenic effects.

**Results:** The XAV939 NPs possessed excellent biocompatibility in corneal epithelial cells and mouse corneas. In vitro corneal wound healing assays demonstrated their antiangiogenic effect, and LPS-induced expressions of pro-inflammatory genes of IL-1 $\beta$ , IL-6, and IL-17 $\alpha$  were significantly suppressed by XAV939 NPs. In addition, the XAV939 NPs significantly ameliorated alkali-burned corneas with slight corneal opacity, reduced neovascularization, and faster recovery, which were attributed to the decreased gene expressions of angiogenic and inflammatory cytokines.

**Conclusion:** The findings supported the potential of XAV939 NPs in ameliorating corneal wound and suppressing neovascularization, providing evidence for their clinical application in ocular vascular diseases.

PP-214

**New application possibilities in the Use of Oxygen Therapy for the Treatment of Corneal Degenerations**I Shargorodska, O Sas<sup>1</sup>.<sup>1</sup>*Ophthalmology, Shupyk National Healthcare University of Ukraine, Kyiv, Ukraine*

**Objective:** Degenerative-dystrophic changes of the cornea affect millions of people worldwide and are common ophthalmic diseases. Today a hot issue of ophthalmology is the search for new treatment options, one of which is oxygen therapy.

**Methods:** We observed 80 patients (160 eyes) with corneal epithelial-endothelial dystrophy, herpetic and metaherpetic keratitis, neurotrophic keratitis (diabetes mellitus and glaucoma), neuromyolytic keratitis (lagophthalmos), which consisted of 4 groups. For research, we used a device allowing to obtain a new level of quality of liquid gas saturation. Different aspects of the therapy were studied: duration, density, concentration, etc. Clinical-laboratory and instrumental methods of examination of patients with degenerative diseases of the eye cornea were used in this study.

**Results:** For the first time, the role of components of the system of oxidative and mixidative stress in the development of degenerative-dystrophic diseases of the cornea has been established. New scientific knowledge on the importance of components of oxidative and mixidative stress in the mechanisms of vascular damage in corneal degeneration and the dependence of the detected disorders on the content of superoxide radical, hydroxyl radical, diene conjugates and malonic dialdehyde, which can open new possibilities in prevention and treatment of this pathology, was obtained.

**Conclusion:** The search for and research of new treatment options for patients with degenerative-dystrophic corneal diseases is relevant, as untimely and ineffective treatment can have significant implications for individual and public health. However, the still unsolved scientific and applied task of modern ophthalmic science is to study the effect of oxygen therapy on dystrophic corneal diseases and the functional state of the optic and nervous system which determined the aim and objectives of this work.

PP-215

## Ocular Graft-Versus-Host Disease and Sleep Quality in Patients After Allogeneic Hematopoietic Stem Cell Transplantation

Y Liao<sup>1</sup>, L Liang<sup>1</sup>.

<sup>1</sup>State Key Laboratory of Ophthalmology, Zhongshan Ophthalmic Center, Sun Yat-sen University, Guangzhou, People's Republic of China

**Objective:** To evaluate the association between ocular graft-versus-host disease (oGVHD) and sleep quality in patients after allogeneic hematopoietic stem cell transplantation (alloHCT).

**Methods:** This cross-sectional observational study analyzed 142 patients after alloHCT including 94 patients with oGVHD and 48 without. Fifty healthy controls were also enrolled. Sleep quality was measured by Chinese version of the Pittsburgh Sleep Quality Index (CPSQI). Poor sleep quality was defined as CPQSI score >6. Potential risk factors of poor sleep quality were evaluated by binary logistic regression.

**Results:** Patients after alloHCT had significantly worse sleep quality than those of controls (7.0 [IQR 5.0-10.0] vs. 5.5 [IQR 4.8-7.0],  $P=0.002$ ), especially in oGVHD subgroup (7.5 [IQR 5.0-11.0] vs. 6.0 [IQR 5.0-8.0],  $P=0.04$ ) with nearly double prevalence of poor sleep quality (58 [62%] vs. 18 [37%];  $P=0.006$ ). Poor sleep quality was associated with age, number of organs involved in active systemic GVHD, systemic immunosuppressants, oGVHD diagnosis and severity, Ocular Surface Disease Index, tear film break-up time (TFBUT), lid margin abnormality (all  $P<0.05$ ), but not with other demographic and clinical characteristics including duration since alloHCT. After adjustment, poor sleep quality was still correlated with oGVHD diagnosis (adjusted OR=2.55; 95%CI: 1.02-6.34;  $P=0.04$ ) and severity (adjusted OR=1.20; 95%CI: 1.03-1.39;  $P=0.02$ ), systemic immunosuppressants (adjusted OR=2.61; 95%CI: 1.32-5.71;  $P=0.02$ ) and TFBUT (adjusted OR=0.85; 95%CI: 0.74-0.99;  $P=0.04$ ).

**Conclusion:** Patients after alloHCT experienced significant impairment in sleep quality, particularly in those with oGVHD. Detailed assessments of ocular surface and sleep quality should be included in the long-term alloHCT survivorship.

## PP-216

**Lycium barbarum polysaccharide promotes epithelial repair after corneal injury**

H Wong<sup>1</sup>, Y Bu<sup>1</sup>, Y Chan<sup>1</sup>, K Shih<sup>1</sup>.

<sup>1</sup>Department of Ophthalmology, the University of Hong Kong, Hong Kong, Hong Kong, China

**Objective:** 1) To assess the effectiveness of *Lycium barbarum* polysaccharide (LBP), a goji berry extract, in promoting epithelial repair after corneal alkaline injury.

2) To evaluate the role of LBP in reducing corneal inflammation and stromal edema after alkaline injury.

**Methods:** C57BL/6J mice were pre-treated with topical phosphate-buffered saline, as control, or LBP (0.2/ 2/ 20 mg/mL) for 7 days 4 times per day, followed by 0.1M sodium hydroxide injury for 30 seconds and washing with distilled water for another 30 seconds. Epithelial defect area and corneal thickness were evaluated using sodium fluorescein staining with slit lamp biomicroscopy and hematoxylin and eosin stain respectively. The cornea opacity was as well evaluated using a slit lamp. The amount of corneal apoptotic cells was assessed by TUNEL assay. Levels of pro-inflammatory cytokines, including interleukin-1 beta (IL-1 $\beta$ ), matrix metalloproteinase 12 (MMP12), platelet-derived growth factor-B (PDGF-BB), and aquaporin 5 (AQP5), a water channel, were assessed using immunolabelling and Western blotting.

**Results:** 0.2, 2, 20 mg/mL LBP topical solution did not induce significant corneal cell apoptosis. No significant difference in the total corneal, epithelium and stromal thickness was found between control and LBP pre-treated groups of all concentrations. Mice with 2 mg/mL LBP pre-treatment revealed a significant decrease in epithelial defect area after injury ( $p=0.025$ ), with increased epithelial layer thickness ( $p=0.004$ ), compared to the injury group. The corneal opacity was significantly reduced in the group with 2 mg/mL LBP pre-treatment followed by injury ( $p=0.02$ ). In the group with optimized dose of 2 mg/mL pre-treatment, the expression of MMP12 ( $p=0.033$ ), PDGF-BB ( $p=0.03$ ), and AQP5 ( $p=0.02$ ) showed significantly decreased expression level compared to the injury group.

**Conclusion:** The study demonstrated the efficacy of topical 2 mg/mL LBP pre-treatment, with a safety profile, in promoting corneal epithelial repair. We have also showed the promising therapeutic effect of LBP in promoting the restoration of corneal transparency after injury, which is attributable to its anti-inflammatory effect. Our findings suggest that LBP may be considered as a potential natural ingredient as a topical formulation against chemically-induced cornea defects, particularly those related to alkali burn injury.

PP-217

**Preferred practices of Descemet's Membrane Endothelial Keratoplasty (DMEK) surgeons in the UK: A national survey**

R Diab, M Zarei-Ghanavati, A Shalaby Bardan, A Vasquez-Perez, G Liu, M Bahgat Goweida, C Liu.

**Objective:** To collect information about the variation and preferred practices of Descemet's Membrane Endothelial Keratoplasty (DMEK) procedure among corneal surgeons performing DMEK in the UK.

**Methods:** An electronic survey was emailed to 150 practising UK corneal consultants through the Bowman Club. The survey used 17 questions covering different aspects of DMEK surgery including years of experience, the number of DMEK procedures they had performed, preferred anterior chamber tamponade, re-bubbling technique, graft staining and orientation, type of intraocular lens (IOL) and long-term use of steroid eye drops.

**Results:** Of the 150 surgeons surveyed, 30 surgeons responded (20% response rate). Air tamponade is preferred over SF6 gas tamponade by 66.67% of the respondents and is also used by the majority (83.33%) for re-bubbling. For graft staining 63.33% used membrane blue and 33.76% used vision blue. Seventy percent of the respondents reported using orientation marks (all forms with peripheral arrows being the predominant followed by F stamp). Peripheral iridotomy or iridectomy is performed by 70% of respondents. Hydrophobic IOL is favoured by 56.67% for combined cases and cases planned or destined for cataract surgery. Long term steroids eye drops are prescribed by 70% with FML (fluorometholone 0.1%) being the most frequently prescribed drop (38%).

**Conclusion:** There is significant variation in all steps of DMEK surgery and post-operative management. Understanding this variability would be the first step towards the standardisation of DMEK which can ease the learning curve and increase transition from DSAEK. Based on the published literature, we have provided recommendations on best practice. Future studies should aim to correlate practices and outcomes.



PP-219

**Combined lipidomic and proteomic studies reveal altered lipid metabolism and signaling in age-related meibomian gland dysfunction**Y Cai<sup>1</sup>, L Chen<sup>1</sup>, H Sun<sup>1</sup>, Y Fu<sup>1</sup>.<sup>1</sup>Department of Ophthalmology, Shanghai Ninth People's Hospital, Shanghai Jiao Tong University School of Medicine, Shanghai, People's Republic of China

**Objective:** Meibomian gland dysfunction (MGD) has a strong link with aging and is the main cause of dry eye disease, the most common ocular disorder in an aging population. Abnormal lipid composition and secretion in meibum have been associated with age-related MGD. However, the underlying lipid metabolism and signaling have yet to be elucidated. Our work aims at investigating age-related MGD using combined lipidomic and proteomic analyses.

**Methods:** Two-month and two-year old female mouse meibum were collected for lipidomic and proteomic profiling. Nontargeted lipidomic analyses were performed by liquid chromatography with tandem mass spectrometry (LC-MS/MS) experiment, allowing to quantify over 1000 lipid species from 25 classes. The proteomic profiles were analyzed for determination of potential therapeutic targets and signaling pathways by LC-MS/MS method.

**Results:** Lipidomic analyses revealed 47 differentially expressed lipid species, spanning 4 classes. The most remarkable changes were decreased levels of cholesteryl esters (ChEs) in aged group. Significant differences in lipid unsaturation patterns for ChEs and triacylglycerols (TG) were also observed. For proteomic profiling, 375 proteins were differentially abundant between the two groups. Combining the results of gene ontology (GO), eight proteins were screened and validated by immunohistochemistry (IHC). GO and Kyoto Encyclopedia of Genes and Genomes (KEGG) indicated the involvement of AMPK and PPAR signaling pathway, along with metabolic processes of cholesterol metabolism, unsaturated fatty acid biosynthesis and fatty acid beta-oxidation.

**Conclusion:** Our study provides evidence for altered lipid metabolism and related signaling pathways in age-related MGD, as well as potential therapeutic targets for disease prevention and treatment.

PP-220

**Staphylococcus-associated acute marginal keratitis secondary to pterygium surgery: case report**X Liu<sup>1,2</sup>, Y Bi<sup>3,4</sup>.

<sup>1</sup>Ophthalmology, Tongji Hospital, School of Medicine, Tongji University, Shanghai, <sup>2</sup>Ophthalmology, Guizhou Provincial People's Hospital, Guiyang, <sup>3</sup>Ophthalmology, Tongji Hospital, School of Medicine, Tongji University, <sup>4</sup>Tongji Eye Institute, Tongji University School of Medicine, Shanghai, People's Republic of China

**Objective:** Staphylococcus-associated acute marginal keratitis is an immune-mediated corneal disorder mainly secondary to chronic blepharoconjunctivitis. We report a rare case of Staphylococcus-associated acute marginal keratitis following pterygium excision.

**Methods:** We report a case of a 50-year-old woman who suffered from pterygium in the left eye and underwent pterygium surgery. After surgery, slit-lamp examination showed an incomplete ring-shaped creamy white infiltrate. Corneal pathogenic microbial detection was negative. Staphylococcus aureus was found on the upper eyelid margin of the affected eye.

**Results:** The patient was clinically diagnosed with Staphylococcus-associated marginal keratitis. The infiltrate was gradually absorbed after steroids, topical antibiotics, and lubricant eye drops were administered. After 3 years of follow-up, neither corneal infiltrate nor pterygium recurrence was observed.

**Conclusion:** Staphylococcus-associated marginal keratitis is an immune reaction mainly secondary to chronic blepharoconjunctivitis, which usually activates an antigen-antibody reaction with complementary activation and neutrophil infiltration in patients sensitized to staphylococcal antigens. Early detection and treatment is of great importance. Topical steroids are effective and should be initiated early once pathogenic microbial infections are excluded. Although chronic staphylococcal blepharoconjunctivitis is a common disease, ophthalmologists should pay more attention to it to avoid potential complications.

PP-222

**Wings of Fumes: Pterygium in Wood and Coal users- a Case Series**

A Onkar.

**Objective:** To report a case series of bilateral pterygium in five young females using wood and coal for cooking.

**Methods:** Five young females in the age 22-29 years reported to Ophthalmology outpatient department with complaints of reddish mass of varying duration in both eyes. All belonged to rural, traditional background with indoor stay for most part of the day, with minimal exposure to intense sunlight and dust. Cooking on wood or coal for all meals for a period of 1 year or more was documented. Schirmer's test and tear break up time were done.

**Results:** Bilateral nasal pterygium was documented all the five patients with history of cooking on wood/coal being the common denominator. Tear breakup time was abnormal in all the cases and dellen formation noted as well.

**Conclusion:** Fumes from cooking on coal and wood could be a possible causative factor in pterygium formation. Advice regarding using eye protection or using alternate means of cooking should be encouraged and advised.

PP-223

**Long-Term Outcomes of Corneal Topography and Visual Acuity in Progressive Keratoconus Following Accelerated Collagen Crosslinking**J C Reddy, S Gawde.

**Objective:** This study aimed to evaluate the long term corneal tomographic and visual acuity changes among patients who underwent epithelium-on accelerated corneal collagen cross-linking (CXL) for progressive keratoconus

**Methods:** This retrospective single-arm hospital-based cohort study included 1966 eyes of 1563 patients who underwent CXL between February 2016 and October 2020. Patients with a history of a previous corneal procedure, corneal trauma, or any corneal scarring were excluded. All eyes underwent accelerated corneal collagen cross-linking at 9 mW/cm<sup>2</sup> for 10 minutes. The corrected distance visual acuity (CDVA) and tomographic changes (maximum keratometry- KMax, Thinnest pachymetry- TCT) were measured preoperatively and 1 month, 3, 6, 12, 24, 36, 48, and 60 months postoperatively.

**Results:** The mean age was  $17.92 \pm 6.64$  (ranges from 4 to 79) years. The mean KMax increased from pre-operative  $62.74 \pm 8.43$ D to  $64.23 \pm 8.19$ D at post-operative 1 month follow up visit and flattened from 3 to 60 months. The mean TCT decreased from pre-operative  $425.98 \pm 43.08 \mu\text{m}$  to  $395.17 \pm 48.94 \mu\text{m}$  at post-operative 1 month follow up visit and increased over a period of time. The mean LogMAR CDVA decreased from pre-operative  $0.37 \pm 0.30$  to  $0.43 \pm 0.27$  at post-operative 1 month follow-up visit and improved over the followup visits with no statistical significance between visits. Nine eyes (0.45%) underwent a repeat procedure for progression over the follow-up period.

**Conclusion:** This study revealed that accelerated CXL procedure is safe and effective in stabilising the corneal topography and visual acuity parameters over a period of 60 months in patients with progressive keratoconus.

PP-224

## SWIMMING GOGGLES IN EXPOSURE KERATOPATHY - A CASE REPORT

S Ramani, D DS, A Anusha.

**Objective:** The effectiveness of swimming goggles in a patient with exposure keratitis.

**Methods:** An 87-year-old male who presented with right-sided facial nerve palsy, was diagnosed to have exposure keratopathy. He was treated with ocular lubricants-carboxymethyl cellulose hourly and hydroxypropylmethylcellulose. As he was unwilling to undergo temporary tarsorrhaphy he was advised to use swimming goggles to ensure humidification around the eye.

**Results:** Two days after starting treatment, there was marked improvement of the keratopathy in the right eye. There was no evidence of punctate epithelial erosions.

**Conclusion:** Swimming goggles create a moist chamber and are an effective and accessible method of treating exposure keratopathy.

PP-225

### A Man with Primary Bulbar Conjunctival Sporotrichosis

H Qi, Y Huang<sup>1</sup>.

<sup>1</sup>*ophthalmology, Chinese PLA General Hospital, Beijing, People's Republic of China*

**Objective:** Sporotrichosis is a subacute or chronic fungal disease caused by *Sporothrix* infection, mainly in tropical regions. The infection usually occurs on the skin, causing infection of the subcutaneous tissue. Only very rarely, *Sporothrix* can cause primary infections outside the skin, including the eyes, lungs, bones and joints, and the central nervous system. Ocular adnexal infections include eyelid, conjunctiva, and lacrimal sac infections. Intraocular infections include extrinsic or intrinsic endophthalmitis. According to the latest review of sporotrichosis published in 2021, only 56 patients with conjunctival infection of sporotrichosis have been reported worldwide.

**Methods:** This article reports the first case of primary *S. bulbar* conjunctiva infection in my country, from the clinical manifestations, diagnosis and differential diagnosis, and treatment methods of the disease are reported in detail. The diagnosis of sporotrichosis is confirmed by biopsy of conjunctival tissue from the affected site, fungal culture, isolation of sporothrix, and genome sequencing. In the treatment, we adopted an innovative method. In the early stage, the patients were given oral posaconazole for antifungal treatment, and in the later stage, low-concentration hormones were used to control the inflammation, and a very positive effect was achieved.

**Results:** At the time of the patient's visit, there was a large amount of fish-like tissue in the bulbar conjunctiva surrounding the limbus. After one month of treatment with posaconazole 300 mg/d, the conjunctival congestion and edema were significantly reduced, the new conjunctival tissue subsided, and the inflammatory reaction of the anterior chamber was relieved; fungal infection was found. After control, local eye instillation with low concentration hormone was added to suppress inflammation, and the inflammation subsided after two weeks of hormone treatment. The patient's visual acuity increased from 0.1 before treatment to 0.6, and the intraocular pressure decreased to normal.

**Conclusion:** Eye infection caused by sporotrichosis is very rare, and this patient is the first case of conjunctival infection in China, which has clinical guiding value. Northeast my country is the endemic area of the bacteria, so we should improve the awareness of the disease, early diagnosis, and early correct treatment, so as to reduce the occurrence of ocular complications.

PP-226

**Adenosquamous carcinoma of the bulbar conjunctiva invading the cornea and lacking MAML2 translocation: a case report**H Liu.

**Objective:** ASC is a highly aggressive tumor, which is rare occurring in the bulbar conjunctiva<sup>[1-3]</sup>. It has been frequently diagnosed as squamous cell carcinoma (SCC) or MEC<sup>[4]</sup>. In 2018, the consensus meeting for the WHO Classification of Tumours of the Eye decided that conjunctival MEC should be reclassified as ASC. The authors describe herein a rare case of ASC of bulbar conjunctiva invading the cornea and lacking *MAML2* translocation.

**Methods:** We reported 1 case of conjunctival ASC which was diagnosed as a mucoepidermoid carcinoma (MEC).

**Results:** a 38-year-old male presented with a right eye bulbar conjunctiva mass for 1 week, growing in the direction of cornea and invading part of cornea. The patient underwent local tumor resection and enucleation. Pathologic findings showed that the tumour consists of two types of cells, a number of tumor cells demonstrated squamous differentiation with intercellular bridges and keratinized beads, while other tumor cells were arranged in a glandular tube or be signet ring-like cells which distributing in single or small nests with abundant intracellular mucus; AB-PAS showed blue intracytoplasmic mucin deposit in the signet ring-like cells, the adenocarcinoma area stained by CK7, the squamous cell carcinoma area marked by P40 and P63. The case underwent FISH for MAML2 translocation and showed the absence of *MAML2* translocation.

**Conclusion:** This case has squamoid tumour cells, adenocarcinoma cells and mucous cells, without intermediate cells and the MAML2 translocation, although it mimic MEC closely which should be diagnosed as ASC.

PP-227

**Capture The Alkaptonuria**N Vyas Joshi, S jain, S makhija.

**Objective:** Our objective is to present a rare case of Alkaptonuria presenting with ocular manifestations in our Cornea and ocular surface out patient department . Alkaptonuria is a rare condition, affecting 1 in 250,000 to 1 million people worldwide. Alkaptonuria is caused by rare mutations within the homogentisate 1,2-dioxygenase (HGD) gene located on Chromosome 3. It has an autosomal recessive inheritance pattern.

**Methods:** We report a rare case of a 58 year old male who was referred to our out patient department for ophthalmic evaluation, with chief complaints of bluish black mass over the eyes for the past 1 year. A full dilated fundus evaluation with refraction and retina reference was done. Patient was thereafter referred to a general physician and orthopaedician to rule out involvement of other organs/systems.

**Results:** On proper physical and systemic evaluation we were able to figure out the diagnosis of Alkaptonuria, though the patient did not follow up for further treatment. The patient was started on Vitamin C 1 g daily with a low protein diet and was advised cataract surgery subject to physician fitness. He was also prescribed frequent topical lubricants for symptomatic relief. Surgically We originally planned to do a mass excision and biopsy with a conjunctival autograft with glue for further evaluation and understanding of the disease but could not go ahead as the patient was lost to follow up.

**Conclusion:** Early diagnosis and clinical suspicion are necessary to a prompt recognition of the disease, discoloration of diapers often offers the earliest opportunity to suspicion in childhood.

Aim is to Educate medical professionals, specifically ophthalmologists regarding this disease who can help in Screening of siblings and parents for the affected gene and ensure proper genetic counselling is done.



**PP-228****Management of recurrent scleral thinning with circular scleral patch grafts in a case of necrotizing scleritis**P K.**Objective:** To describe the technique of circular scleral patch grafts in the management of necrotizing scleritis**Methods:** A 45 years old female presented with pain and redness for 1 month in the right eye with presenting BCDVA 6/36. On examination, a circular area of scleral thinning with ciliary staphyloma was noted in the superotemporal area in the sclera of the right eye. The left eye was found to be within normal limits with a BCDVA of 6/6. She was diagnosed to have necrotizing scleritis in the right eye. Her anti-CCP levels were also found to be elevated on systemic workup. A scleral patch graft was planned under general anesthesia to avoid any risk of perforation during retrobulbar/ peribulbar block. The area of scleral thinning was measured to be 7.5mm using Castrovejo calipers. The circular scleral thinning was managed with a scleral patch graft of 7.5mm cut using disposable trephines patched over the defect after performing a localized peritomy and sutured with 10-0 nylon sutures. The peritomy was then closed using 8-0 vicryl sutures. The patient presented with another area of sequential thinning in the temporal part involving 2.5mm of the sclera 2 weeks later. Another sequential scleral patch was done in the same eye after marking the size of the scleral patch required using gentian violet dye and dissecting the graft using corneoscleral scissors using copy-paste technique. The patient was eventually treated with topical and systemic steroids and immunosuppressants to reduce further inflammation.**Results:** The hypotony and inflammation in the patient gradually subsided. There were no signs of graft melt or repeated inflammation or thinning in the grafted area.**Conclusion:** Necrotizing scleritis can thus be managed with repeated scleral patch grafts if required. The scleral graft can aid in salvaging the visual potential of the eye in such cases and provide a window for further evaluation of systemic causes.

PP-229

**Atypical Cogan's Syndrome in a Pediatric Filipino Patient: A Case Report**B Santos.**Objective:** To report a rare case of Cogan's syndrome in a Filipino pediatric patient.**Methods:** This is a case report on a Filipino female who presented at age 12 with recurrent bilateral eye redness and photophobia. A month after, patient developed hearing loss, tinnitus, vertigo, polyarthralgia, low-grade fever and fatigue. She was managed independently by different physicians for conjunctivitis, bilateral sensorineural hearing loss and rheumatoid arthritis. At age 15, she gradually developed bilateral blurring of vision, pallor, and lower extremity claudication. Patient presented with tachycardia, hypertension with wide pulse pressure on all extremities, neck vein engorgement and cardiac murmur. Slit lamp examination showed bilateral chronic interstitial keratitis. Laboratory tests revealed elevated inflammatory markers, microcytic anemia, neutrophilic leukocytosis, and thrombocytosis. Echocardiography showed severe atrial regurgitation. Patient tested negative for syphilis, tuberculosis, and other rheumatologic conditions.**Results:** The patient satisfied the criteria for diagnosis of Cogan's syndrome and is maintained on topical and oral steroids, methotrexate, and anti-hypertensives. Musculoskeletal, cardiovascular, and ocular symptoms improved, however auditory manifestations were no longer responsive to medical treatment, which is consistent with characteristics described for other patients with Cogan's syndrome in literature. Chronic inflammation and cardiovascular manifestations such as those seen in our patient are significantly associated with unfavorable prognosis.**Conclusion:** This case report emphasizes the importance of having a high index of suspicion for Cogan's syndrome when ocular inflammatory manifestations are associated with audio-vestibular symptoms. Variability of manifestations in atypical cases and lack of specific diagnostics can delay diagnosis and management, thus causing irreversible and life-threatening complications. Thorough medical history, physical exam and appropriate diagnostic testing are crucial to rule out mimickers such as syphilis and tuberculosis. Optimal management requires early recognition and a multidisciplinary team with coordinated efforts to treat multisystem involvement and monitor complications of treatment.

PP-230

**Three-Year Clinical Outcomes of Accelerated Epithelium-Off Corneal Collagen Cross-linking for a Case of Superior Keratoconus**A Mounir<sup>1</sup>, E Mostafa<sup>1</sup>.<sup>1</sup>*Ophthalmology, Sohag University, Sohag, Egypt*

**Objective:** To report the long-term outcome of accelerated epithelium-off corneal collagen cross-linking for a case of superior keratoconus which is a rare type of Keratoconus.

**Methods:** A 26-year-old male presented with progressive loss of vision in both eyes , The Uncorrected Visual Acuity (UCVA) in the right eye (RE) was 0.1 in decimal corrected to 0.4 by a refraction of -1.00Ds -3.5 0Dc @107, while the UCVA in the left eye (LE) was 0.01 corrected to 0.3 by a refraction of +2.00 Ds -5.50Dc @31. Slit-lamp examination of both eyes revealed a superior corneal protrusion without associated scarring or vascularization. Both eyes were diagnosed as grade 1 Keratoconus with superior cone by Scheimpflug corneal tomography.

**Results:** Accelerated epithelium-off corneal cross-linking was done for each eye separately in 2 consecutive sessions. The patient was followed up for 3 years, visual acuity as regards UCVA and BCVA and the improvement of the corneal topographic parameters, including keratometry, corneal elevation, and pachymetry.

**Conclusion:** Accelerated epithelium-off corneal collagen cross-linking stabilized and halted the progression of superior keratoconus after long-term follow-up.

PP-231

### Clinical Outcomes of Accelerated Epithelium-Off Corneal Collagen Cross-linking For A Case of Ultrathin Postlasik Ectatic Cornea

A Mounir<sup>1</sup>, M Korishy<sup>1</sup>, E Mostafa<sup>1</sup>.

<sup>1</sup>Ophthalmology, Sohag University, Sohag, Egypt

**Objective:** To report the clinical outcomes of accelerated epithelium-Off corneal collagen cross-linking For a case of ultrathin postlasik ectatic cornea

**Methods:** 29-year-old male with left eye diagnosed as post Lasik ectasia with extremely thin cornea after 3 years of uneventful Lasik surgery diagnosed by Scheimpflug based tomography device (Oculus Inc., Wetzlar, Germany), The uncorrected visual acuity (UCVA) in the left eye (LE) was 0.1 in decimal corrected to 0.4 by a refraction of -6.75Ds – 4.5 0Dc @120, while the UCVA in the right eye (RE) was 1 in decimal without correction. Accelerated epithelium-off corneal cross-linking with pachymetric-guided corneal epithelial removal by (Avedro, USA) was done for the affected eye.

**Results:** The patient was followed up for one year with improvement of visual acuity as regards UCVA and BCVA and improvement of corneal topographic parameters including keratometry including mean K, K max and Belin ABCD keratoconus staging.

**Conclusion:** Accelerated epithelium-Off corneal collagen cross-linking after pachymetric-guided corneal epithelial removal was found to be safe and effective method in stabilizing and improving a case of ultrathin post Lasik ectatic cornea after one year follow up.

PP-232

### Atypical Presentation of Peripheral Ulcerative Keratitis in a Young Filipino Female: A Case Report

J Lapidés<sup>1</sup>, R Lim Bon Siong<sup>1</sup>, G Sosuan<sup>1</sup>.

<sup>1</sup>Ophthalmology and Visual Sciences, Philippine General Hospital, Manila, Philippines

**Objective:** To report an atypical presentation of peripheral ulcerative keratitis in a Filipino female patient with unilateral chronic red eye

**Methods:** A 32-year-old Filipina presented with a two-year history of eye redness, tearing, and ocular surface pain on the left. After initial assessment of an inflamed eye by a rural health physician, she was maintained on chronic oral steroid therapy, albeit with erratic intake pattern. Patient had cushingoid features on systemic physical exam, while ophthalmologic examination revealed an unusual finding of unilateral peripheral corneal thinning without any infiltrates, but with adjacent elevated nodular conjunctiva. Steroid was gradually tapered with the help of an endocrinologist, while tissue biopsy and systemic work up were facilitated.

**Results:** Peripheral ulcerative keratitis is a rare inflammatory disease of the peripheral cornea characterized by juxtalimbal crescent-shaped corneal epithelial defect, stromal thinning and inflammatory stromal infiltrate. It is associated with a myriad of local and systemic infectious and non-infectious conditions, and may rarely be idiopathic in nature. Autoimmune peripheral ulcerative keratitis occurs most often in association with rheumatoid arthritis, systemic lupus erythematosus, and granulomatosis and polyangiitis, accounting for more than half of all cases of PUK. The patient's case was a diagnostic challenge – nodular scleritis, tuberculous conjunctivitis, and conjunctival intraepithelial neoplasia with dellen formation were all considered during the course of her care. Typical signs of peripheral ulcerative keratitis only became more evident when the dose of steroid was much lower. Patient was referred to rheumatology for comanagement.

**Conclusion:** Evaluation of patients with suspected PUK focuses on determining the underlying etiology, as this will determine the appropriate management. Steroids are extensively used in ophthalmology, but it may modify the clinical course and presentation of ocular diseases, making diagnosis more challenging. Side effects especially in chronic use must be monitored as well, and use of other immunomodulatory therapies must be explored.

## PP-234

**Descemet membrane dehiscence from misdirected viscoelastic into the corneal stroma during intervention for postoperative hypotony**

M Pavel<sup>1</sup>, M Abu-Bakra, L Pelosini.

<sup>1</sup>Ophthalmology, King's College Hospital NHS Foundation Trust, London, United Kingdom

**Objective:** To present the surgical management for Descemet's membrane detachment from inadvertent intrastromal injection of viscoelastic for anterior chamber reformation following a Preserflo microshunt in primary open angle glaucoma(POAG).

**Methods:** An 81 year old female presented with HM vision in the right eye, flat anterior chamber (AC) with iridocorneal touch, hypotony (3 mmHg) and choroidal effusion six days following the insertion of a standard Preserflo microshunt and 0.4mg Mitomycin for uncontrolled POAG. Sodium Hyaluronate 1% (Z-hyalin, viscous-cohesive OVD) emergency injection into the AC was attempted at the slit lamp to reform the AC and restore the intraocular pressure (IOP). The following day, a double anterior chamber and a central round area of Descemet's membrane dehiscence measuring 4mm in diameter was observed at the slit-lamp. An emergency drainage of the OVD was performed on the same day with superior clear corneal access, internal incision from the superior aspect of the dehiscence and 80% air fill of the AC. The AC air injection resulted in increased IOP likely secondary to partial blockage of Preserflo microshunt device. A second surgical intervention with Preserflo exchange and 4 anterior corneal stab incisions was performed one week later for the control of the IOP and further drainage of OVD from the Descemet's dehiscence.

**Results:** The Descemet's dehiscence reduced by 60% within 24 hours and the central corneal thickness decreased from 939  $\mu$  to 609  $\mu$  over a period of one week. The corneal stroma cleared within 6 weeks with full resolution of the dehiscence and a final vision outcome of 6/18 Snellen.

**Conclusion:** Inadvertent injection of OVD into the corneal stroma with Descemet's dehiscence has been reported as a iatrogenic complication of emergency management of hypotony following glaucoma surgery. This is the first report of such a complication following Preserflo microshunt implant and using a viscous-cohesive OVD. The surgical drainage of the OVD in the early stage of this complication expedited the resolution of corneal oedema and the visual rehabilitation. The small size of the Preserflo microshunt increases the risk of possible blockage from air or residual OVD in the anterior chamber with partial failure of the drainage function. In this case, the early surgical drainage of the OVD from a combined posterior and anterior approach associated with the exchange of the Preserflo microshunt allowed the resolution of the corneal oedema, as well as a optimal control of the IOP.

PP-235

**Recalcitrant fungal keratitis in DALK: report of a case**M Calatayud-Pinuaga.

**Objective:** To describe a case of *Candida* sp keratitis with atypical presentation , masquerading inflammatory immune complexes at the interface and graf-host junction, 2 months after an uneventful DALK procedure. Treated with intrastromal injections and penetrating keratoplasty

**Methods:** One patients diagnosed of severe keratoconus in his right eye was treated with deep anterior lamellar keratoplasty (DALK) in November 2021. The procedure was uneventful and vision improved from counting fingers to 20/40 after one month. 6 weeks after the surgery the patient was visited and some white symmetrical spots in the graft-host superficial junction were detected. Steroid dose was increased as we suspected immune complexes at the interface. 2 weeks later the previous infiltration disappeared and some white cotton-like new infiltration appeared at the interface between stroma and descemet's membrane . We treated it with several voriconazole intrastromal injections which improved the case but there were recurrences after one week. 4 months after DALK the infection spreads through the interface and we performed penetrating keratoplasty , iodine diluted 5% and Amphotericin B irrigation before removing descemet 's membrane.

**Results:** 6 months after the last procedure the patient is still on topical Amphotericin B and close follow up, the graft is clear and best corrected visual acuity is 20/30, with no recurrent fungal infection.

**Conclusion:** Fungal infections after anterior corneal lamellar surgery are challenging cases due to the "encapsulation" of the germ at the interface, which makes difficult for the surgeon to clean it completely and make the infection disappear. Intrastromal anti-fungal medication may help but the only way to stop it completely needs the graft removal and interface cleaning with antiseptic povidone and anti fungal agents. Lamellar keratoplasty offers many advantages over penetrating keratoplasty but infections at the interface are extremely difficult to treat.

PP-236

**Microsporidial Keratitis Post-Lamellar Keratoplasty Following Transepithelial Photorefractive Keratectomy**

M Alabduljabbar, F *Sirajuddin*, R *Alshabeeb*.

**Objective:** To report a case of microsporidial keratitis post-deep anterior lamellar keratoplasty following photorefractive keratectomy at King Khaled Eye Specialist Hospital in Riyadh, Saudi Arabia.

**Methods:** Case report.

**Results:** A 41-year-old female with keratoconus underwent deep anterior lamellar keratoplasty (DALK) followed by transepithelial photorefractive keratectomy (t-PRK) and presented with recurrent episodes of eye pain, redness, and photophobia. The patient was treated as a case of herpetic stromal keratitis with antiviral medication and topical steroids. During the last attack, the condition deteriorated despite maximum treatment. She was admitted and started on fortified antibiotics. Eventually, therapeutic lamellar keratoplasty was performed, and the histopathology report revealed a microsporidial infection. The patient was discharged with complete corneal epithelial healing, and no signs of recurrence during follow-up.

**Conclusion:** Microsporidial infection is a rare cause of stromal keratitis that affects both immunocompetent and immunosuppressed patients. We reported a unique case of microsporidia keratitis post trans-epithelial photorefractive keratectomy that was successfully treated with therapeutic lamellar keratoplasty without recurrence. Microsporidia keratitis should be suspected after surface ablation refractive surgery if the patient presents with symptoms of viral keratitis and is recalcitrant to conventional treatment. To the best of our knowledge, this is the first case of its kind in the literature.



PP-238

**First report of Pre-Descemet corneal dystrophy in Armenia, with unusual presentation**

L Kambulyan, O *Ginoyan*, A *Kirakosyan*, A *Hambardzumyan*, A *Hovakimyan*.

**Objective:** To present three cases of pre-Descemet corneal dystrophy associated with X-linked recessive ichthyosis.

**Methods:** Pre-Descemet corneal dystrophy is characterized by the presence of tiny polymorphic opacities immediately anterior to Descemet membrane. Onset is usually after 30 years of age and the vision is not affected. According to classification of Corneal dystrophies (IC3D), there are two types of PDCD (1) isolated PDCD, with unknown genetic locus (2) PDCD associated with X-linked ichthyosis, a deletion of steroid sulfatase gene on chromosome Xp22.3. X-linked ichthyosis commonly affects males within the first year of life and occurs with “fish scale” appearance of the skin.

**Results:** Three male patients were referred to Cornea- Uveitis department at Malayan Eye clinic, Yerevan, Armenia. Past medical history was remarkable for X-linked ichthyosis. The cutaneous examination demonstrated scaling and flaking skin of the arms and legs. Slit lamp biomicroscopy revealed multiple, tiny, greyish opacities immediately anterior to Descemet membrane in both eyes. Slit lamp examination of anterior segment and fundus were otherwise normal. The patients were diagnosed with PDCD associated with X-linked ichthyosis. One of this patients was 11-year-old, which is unusual. The child had allergic conjunctivitis and we prescribed him Fluorometalone eye drops 2 times a day.

**Conclusion:** Punctate corneal stromal opacities located anterior to Descemet membrane, the most common ocular manifestation associated with X-linked ichthyosis. In our country the common types of corneal dystrophies are Granular, Lattice and Macular dystrophies respectively. These 3 patients illustrate a rare presentation of PDCD associated with X-linked ichthyosis in our country with 11-year-old child having the disease already.

PP-239

**Giant Mucinous Cystadenoma of the Eyelid**D Desai, S Desai<sup>1</sup>.<sup>1</sup>Tarabai Desai Eye Hospital, Jodhpur, India**Objective:** To Report a rare case of a giant Mucinous Cystadenoma of the eyelid.**Methods:** This is the case report of a 30 year old male patient who presented at our clinic with a large, firm, painless, spherical mass in his left upper eyelid measuring about 30 mm round. The mass was firm and adherent to underlying structures and showed minimal mobility. Both lids were fused together as a sequale of alkaline burn that occurred 4 years ago. Magnetic resonance imaging (MRI) revealed a small shrunken globe and a well-defined cystic mass within the upper eyelid which extended into the anterior orbit, lying extraconally on the anterolateral aspect of the globe with its posterior most part abutting on the lateral rectus muscle. A working diagnosis of Dermoid cyst was made and the patient posted for surgery. A skin incision was made and the mass was excised in toto and was sent for histopathological examination. The skin and muscle of the lid were sutured to close the wound.**Results:** Gross pathology of the excised sample showed a 3.4 x 2.8 x 2.6 cms well encapsulated cystic mass with an irregular surface. On cutting open the cyst it was found to have very smooth inner wall and was filled with mucus. Histopathological examination of sections showed the cyst wall was lined with benign columnar mucin secreting cells confirming a diagnosis of mucinous cystadenoma.**Conclusion:** A giant Mucinous Cystadenoma of the Eyelid is described because of its rarity. Eyelid cysts rarely reach such a huge size and are usually excised when they are still small. This benign cyst probably arose from mucin producing goblet cells of the palpebral conjunctiva and because of the extensive damage produced by the alkali burn to tissue architecture and the globe, it grew both, anteriorly under the eyelid as well as posteriorly into the orbit. When a giant eyelid mass in a blind eye is present, a Mucinous Cystadenoma must be kept as a differential diagnosis.

PP-240

**The Monster - Herpes Zoster Ophthalmicus in Childhood**N Vyas Joshi, S jain, S makhija.

**Objective:** To discuss a rare case presented in our Cornea and ocular surface out patient department of Herpes zoster ophthalmicus with corneal ulcer and perforation in a 7 year old healthy child and how it was managed medically and surgically. Herpes zoster ophthalmicus is a potentially devastating visual disease with variable presentation caused by the re-activation of a latent infection of the trigeminal ganglion by the Varicella zoster virus.

**Methods:** We report a rare case of HZO in a 7 year old complicated by corneal ulceration and perforation in a 2 weeks span. Patient presented with history of Vesicular eruptions involving the skin of the left half of the forehead and eyelids since 15 days with complaints of watering, pain, photophobia and blurring of vision in his left eye. A proper ophthalmic and systemic evaluation was done for the child with involvement of a paediatrician and dermatologist.

**Results:** Patient was initially medically managed with oral and topical antivirals, prophylactic topical antibiotics and cycloplegics. A USG Bscan was performed and it was within normal limits. As the parents were keen on going ahead with the understanding that it was a high risk penetrating keratoplasty we planned for an OKP after 6 months but eventually the graft failed with total corneal opacification and vascularisation.

**Conclusion:** Our observation stresses the need for taking proper prenatal, vaccination and systemic history in these children as they could either be immunodeficient or there could be possibility of history of varicella zoster virus infection during pregnancy. This would help in planning a proper management with multidisciplinary approach.

**PP-241****Case series of two contrasting presentations of Paecilomyces fungal keratitis**P K.

**Objective:** To report the two contrasting presentations of Paecilomyces fungal keratitis which were resolved with medical management.

**Methods:** Paecilomyces is a rarely reported cause of fungal keratitis. Here, we report the management of two contrasting presentations of the fungus in culture proven clinical cases. A 65-year-old female who presented with recalcitrant keratitis after Small-incision cataract surgery, with Paecilomyces growth on fungal culture, was initially treated with topical (Voriconazole 1%) and oral antifungal (Tab Voriconazole 200 mg BD), later had to be given multiple intrastromal and intracameral injections of voriconazole (6 times every 3 days). In contrast, a 45-year-old male who presented with keratitis post-trauma, with Paecilomyces growth on fungal culture could be treated with topical and oral antifungal drugs.

**Results:** Repeated Intrastromal voriconazole injections were useful in the resolution of recalcitrant Paecilomyces keratitis in the 65-year-old female patient, whereas early presentation in the 45-year-old male could be managed with topical and oral antifungals.

**Conclusion:** Non-resolving Paecilomyces fungal keratitis can be treated with repeated injections of intrastromal voriconazole before contemplating therapeutic keratoplasty.

PP-242

## Effects of Ocular Perfusion Pressure on Differential Gene Expression in the Retina of Chronic Ocular Hypertension (COH) Rats

Y Yang<sup>1</sup>, L Shu<sup>1</sup>, X Sun<sup>1,2,3</sup>.

<sup>1</sup>Department of Ophthalmology & Visual Science, Eye & ENT Hospital, Shanghai Medical College, Fudan University,

<sup>2</sup>NHC Key Laboratory of Myopia, Chinese Academy of Medical Sciences, and Shanghai Key Laboratory of Visual Impairment and Restoration (Fudan University), <sup>3</sup>State Key Laboratory of Medical Neurobiology and MOE Frontiers Center for Brain Science, Institutes of Brain Science, Fudan University, Shanghai, People's Republic of China

**Objective:** Explore the differential gene expression in COH rat retinal cells with different ocular perfusion pressures.

**Methods:** Chronic IOP elevation induced more severe RGCs loss in Low MOPP rats COH rat model was established by microbead (MB) injection in the anterior chamber. The blood pressure of the tail artery of the rats was detected by a small animal non-invasive sphygmomanometer. Microbead-injected rats whose blood pressure meets the standard saying "SBP<110mmHg, DBP<70mmHg, MBP<80mmHg" are regarded as the low perfusion pressure group (Low MOPP); while the other MB-injected rats are regarded as the normal perfusion pressure group (Normal MOPP). Rats without MB-injection and exhibiting normal blood pressure were used as the control group (Control). RGCs densities were calculated, and the differences between the three groups were analyzed. Agilent 8x60K Microarray was applied to analyze differential gene expression in rat retina in the above groups. The standards for differently expressed genes were that p-value was lower than 0.05 and absolute fold change was above 2. Real-time qPCR and immunofluorescence were applied to verify the microarray data, and the protein levels of targeted proteins were detected by Western Blot.

**Results:** Chronic IOP elevation induced more severe RGCs loss in Low MOPP rats than Normal MOPP rats. The Agilent microarray analysis showed that COH induced increased expression of genes encoding immune responses and inflammatory responses. The complement activation in the Low MOPP group was weaker compared to the Normal MOPP group. Immunofluorescent assay showed that the number of iba1<sup>+</sup> microglia in MB rats' retina was significantly increased than the control group, and the Normal MOPP group was even higher than the Low MOPP group. Western blotting showed that chronic IOP elevation induced phosphorylation of MEK. The Low MOPP group exhibited increased ERK1/2 phosphorylation, decreased Akt phosphorylation, and increased Histone H2A.X phosphorylation compared to the Control group. Besides, the phosphorylation of Histone H2A.X was lower in the Normal MOPP group than that in the Low MOPP group.

**Conclusion:** Lower ocular perfusion pressure is a risk factor for RGCs injury in COH rats. Neuroinflammation and complement system activation induced by COH are more potent in the Normal MOPP group than in the Low MOPP

group. The MEK/ERK and PI3K/Akt pathways may be involved in the regulation of retinal tolerance to COH injury in rats with different ocular perfusion pressures.

PP-243

**UBM-based AI in Differentiating Primary and Secondary AAC**L Cheng<sup>1</sup>, S Liu<sup>2</sup>, J Hong<sup>3</sup>, H Chen<sup>1</sup>, J Lin<sup>1</sup>, J Huang<sup>1</sup>.

<sup>1</sup>State Key Laboratory of Ophthalmology, Zhongshan Ophthalmic Center, Sun Yat-sen University, Guangdong Provincial Key Laboratory of Ophthalmology and Visual Science, Guangdong Provincial Clinical Research Center for Ocular Diseases, <sup>2</sup>School of computer science, Guangdong Polytechnic Normal University, Guangdong Key Laboratory of Big Data Analysis and Processing, <sup>3</sup> School of Medical Information Engineering, Guangzhou University of Chinese Medicine, Guangzhou, People's Republic of China

**Objective:** To construct two Artificial Intelligence (AI) models based on ultrasound biomicroscopy (UBM) images and UBM biological parameters, and to construct a multi-mode AI model based on UBM images binding parameters, in order to distinguish acute primary angle closure glaucoma (APACG) and acute secondary angle closure associated with zonular laxity (ASAC-ZL) or with lens subluxation (ASAC-LS) before surgery, and to evaluate the diagnostic efficacy of the model.

**Methods:** Patients diagnosed with acute angle-closure glaucoma (AACG) with an acute attack of one eye, treated with phacoemulsification, and diagnosed with APACG, ASAC-ZL or ASAC-LS during phacoemulsification in our hospital were recruited. Healthy subjects without any history of eye disease or surgery were also included in the study. UBM images of the affected eye of patients with AACG and a random eye of healthy subjects were taken. Moreover, biological parameters of both eyes were measured using UBM, including central anterior chamber depth (ACD), lens vault (LV), iris lens angle (ILA), ILA maximum difference, ACD difference and LV difference of both eyes. We construct three AI models based on convolutional neural network (CNN). Single-mode CNN models based on UBM images and UBM biological parameters were constructed with EfficientNet respectively. Two models were then combined using Bayesian decision rules to create a multi-mode CNN model based on UBM images and biological parameters. The macro-Area Under Curve (AUC) and accuracy were calculated to evaluate the classification performance of the models.

**Results:** The macro-AUC of single-mode CNN model based on UBM images was 0.9046, with an accuracy of 76.09%. The macro-AUC of single-mode CNN model based on UBM biological parameters was 0.8246, with a 77.1% accuracy. Meanwhile, the macro-AUC for the multi-mode CNN model based on UBM images combined with biological parameters was 0.8791, and the accuracy was 79.4%. According to statistics, the single-mode CNN model based on UBM images had the best classification performance.

**Conclusion:** All three models had good performance in the classification of APACG and secondary acute angle-closure glaucoma with zonular laxity or lens subluxation, suggesting that they could be useful in clinical application. Following a horizontal comparison of the three models, the single-mode CNN model based on UBM images had the best efficacy.

PP-244

## Systematic Review of the Effectiveness of MLT vs. SLT in Reducing Intraocular Pressure in Primary Open Angle Glaucoma

A Robart<sup>1</sup>, N Shoham-Hazon<sup>2,3</sup>.

<sup>1</sup>Faculty of Medicine, Memorial University of Newfoundland, <sup>2</sup>Ophthalmology, Memorial University Faculty of Medicine, St. John's, <sup>3</sup>Ophthalmology, Dalhousie University, Miramichi, Canada

**Objective:** Limited long-term data exists comparing MLT to SLT in POAG with studies referencing follow-up of 1 hour to 18 months. MLT has shown similar IOP lowering capacity to SLT, however, there are contradictory results in different patient populations.

The purpose of this study is to review all existing literature comparing the effectiveness of Micropulse Laser Trabeculoplasty (MLT) vs. Selective Laser Trabeculoplasty (SLT) in reducing intraocular pressure (IOP) in Primary Open Angle Glaucoma (POAG) and Ocular Hypertension (OHT).

**Methods:** This review was conducted in accordance with PRISMA guidelines. Ovid, Embase, Scopus, and Central were searched using terms including *Trabeculoplasty, Micropulse (MLT, MDLT, & SPLT), Selective (SLT & ND:YAG)*. Original research of all languages and dates was included, up to March 24th, 2022. The search yielded 116 unique articles, with 10 meeting inclusion criteria after being reviewed by two researchers with conflicts resolved by a 3rd independent researcher. Levels of evidence ranged from II to IV.

**Results:** A total of 643 eyes were included, 311 eyes receiving MLT with an average of 64 eyes per study (SD +/- 40.2). 90% (9/10) of the papers cited no statistically significant difference in IOP reduction between 1-18 months, and 5/10 papers cited SLT having more IOP spikes post-op however only 2 were statistically significant.

**Conclusion:** Overall, the studies had significant variability in MLT laser frequency, however, the best available evidence suggests that MLT and SLT are similar in reducing mean IOP, but SLT requires more post-op interventions.



PP-245

**Bio-modulation of Scaring Glaucoma Filtration Surgery Using a Novel Application of Coated Magnesium**X Li<sup>1</sup>, R Filek<sup>2</sup>, H Liu<sup>3</sup>, Y Wang<sup>4</sup>, C Hutnik<sup>5</sup>, L Xie<sup>1</sup>.<sup>1</sup>Ophthalmology, The Third Affiliated Hospital, Chongqing Medical University, Chongqing, People's Republic of China,<sup>2</sup>Ophthalmology, Ivey Eye Institute, St. Joseph's Health Care London, London, <sup>3</sup>Ophthalmology, Ivey Eye Institute, St.Joseph's Health Care London, London, Canada, <sup>4</sup>Collage of Material Science & Engineering, Chongqing University,Chongqing, People's Republic of China, <sup>5</sup>Ophthalmology, Ivey Eye Institute, St. Joseph's Health Care London,

London, Canada

**Objective:** To evaluate the vitro and vivo corrosive properties, biocompatibility and anti-proliferative properties of differently coated magnesium in a primary culture of HTCFCs and in rabbit glaucoma filtration surgery.

**Methods:** In vitro, primary HTCFCs were seeded on differently coated magnesium disks(HA, DCPD, DCPD+SA) with glass and titanium disks used as controls. SEM observed images of HTCFCs seeded different disks. The MTT and LDH assays were used to determine cellular metabolic activity and cytotoxicity during the logarithmic phase of HTCFCs, respectively. The BrdU assay was used to evaluate cellular proliferation. WB was used to assess the expression of  $\alpha$ -SMA. In vivo, New Zealand rabbits underwent a standard primary trabeculectomy with a titanium disk, pure magnesium disk and the three coated magnesium disks placed under a scleral flap, the procedure of trabeculectomy alone used as control. 0.1ml of aqueous was extracted before the rabbits were euthanized, which was used to analyze the ion concentration of samples. The sections of eye were stained with hematoxylin and eosin for histology analysis. Western blot was used to assess the expression of  $\alpha$ -SMA and Collagen-1. RT-PCR analysis was used to detect  $\alpha$ -SMA and Collagen-1 mRNA in the tissue of rabbit's tenon's .

**Results:** The results show the number and shape of HTCFCs seeded on different coatings showed less quantity and poor cell morphology. Each type of coated magnesium demonstrated significantly decreased metabolic activity of HTCFCs. DCPD + SA showed higher cytotoxicity than the other coatings. Significant inhibition of proliferation was observed with the DCPD + SA coating. The expression of  $\alpha$ -SMA was decreased in the cells when seeded on all of the coated magnesium disks. In vivo, no significant difference existed for any of the different samples regarding different ion concentrations in the aqueous humor. The inflammatory response in the titanium, DCPD and DCPD + SA treated eyes was more intense than in the trabeculectomy alone and HA groups. Western Blot analysis showed that collagen-1 and  $\alpha$ -SMA expression was significantly lower in the titanium, HA, DCPD and DCPD+SA groups compared with controls.

**Conclusion:** Different coatings on magnesium were able to influenced the morphology and function of HTCFCs. HA coated magnesium may be considered a very promising biodegradable material for the future of glaucoma drainage devices.

## PP-246

**Ab interno canaloplasty combined with phacoemulsification for primary open-angle glaucoma and cataract: one-year results**

D Lyu<sup>1</sup>, K Yao<sup>1</sup>.

<sup>1</sup>Eye Center of Second Affiliated Hospital of Zhejiang University School of Medicine, Hangzhou, People's Republic of China

**Objective:** To evaluate the efficacy and safety of ab interno canaloplasty (ABiC) combined with micro-incision phacoemulsification for treating primary open angle glaucoma (POAG) combined with cataract.

**Methods:** Prospective case series study. Patients diagnosed with POAG and concurrent cataract were enrolled to receive ABiC combined with micro-incision phacoemulsification and intraocular lens implantation in Eye Center of the Second Affiliated Hospital of Zhejiang University School of Medicine. Intraocular pressure (IOP), use of hypotensive medications, visual acuity, visual field, and optic nerve at baseline as well as at 1 day, 1 week, 1 month, 3 months, 6 months, and 12 months were assessed. Success rate and complications were analyzed.

**Results:** A total of 68 eyes in 42 patients completed follow-up of 12 months. Compared to the baseline IOP under medical control ( $18.25 \pm 2.65$  mmHg), the mean postoperative IOP at 1 month ( $14.31 \pm 3.25$  mmHg), 3 months ( $14.00 \pm 3.09$  mmHg), 6 months ( $14.58 \pm 2.93$  mmHg), and 12 months ( $14.84 \pm 2.73$  mmHg) were all significantly reduced ( $P < 0.05$ ), respectively. The median (upper quadrant, lower quadrant) of baseline hypotensive medication number was 2.5 (2, 3), while being 0 (0, 1) at 1 month postoperatively, and 0 (0, 0) at 3, 6, and 12 month postoperatively, which were all significantly reduced compared to baseline ( $P < 0.05$ ), respectively. The complete success rate and qualified success rate at 12 months were 80.88% and 89.71%, respectively. Overall, no deterioration in visual field or optical coherence tomography scan of the optic nerve were observed at 12 months compared to baseline. Hyphema and transient IOP spike were the most common complications, yet no severe case was present so far.

**Conclusion:** ABiC combined with micro-incision phacoemulsification is considerably effective and safe in the treatment of POAG combined with cataract in Chinese population.

PP-247

## Effect of Tafluprost on Macular and Peripapillary Capillary Vessel Density in Patients with Open-angle Glaucoma

Y Li<sup>1</sup>, J Huang<sup>1</sup>.

<sup>1</sup>State Key Laboratory of Ophthalmology, Zhongshan Ophthalmic Center, Sun Yat-sen University, Guangdong Provincial Key Laboratory of Ophthalmology and Visual Science, Guangdong Provincial Clinical Research Center for Ocular Diseases, Guangzhou, People's Republic of China

**Objective:** This study aimed to investigate the effect of Tafluprost on Macular and Peripapillary Capillary Vessel Density (VD) in patients with primary open-angle glaucoma (POAG) and normal tension glaucoma (NTG) using optical coherence tomography (OCTA).

**Methods:** Topical Tafluprost treatment was administered to 34 enrolled POAG and NTG patients (55 eyes) for 3 months. The macular and peripapillary VD were measured automatically by OCTA at baseline, after 1 month, and after 3 months of administering the drug. The retinal nerve fibre layer (RNFL), ganglion cell complex (GCC) thickness, intraocular pressure (IOP) in each subject were assessed during each follow-up.

**Results:** Compared with the baseline, the parafovea VD, superior hemi-parafovea VD, tempo-parafovea VD were higher ( $43.48 \pm 5.32$  versus  $44.53 \pm 6.50$ ,  $P = .024$ ;  $43.04 \pm 5.31$  versus  $44.27 \pm 6.29$ ,  $P = .028$ ;  $44.28 \pm 5.34$  versus  $45.31 \pm 6.59$ ,  $P = .036$ ) 1 month after administration of Tafluprost. After administration of Tafluprost for 3 months, the tempo superior VD of radial peripapillary capillary was higher ( $48.10 \pm 10.18$  versus  $49.90 \pm 10.41$ ,  $P = .047$ ) compared with the baseline, while IOP and average RNFL thickness were decreased compared to baseline ( $18.28 \pm 4.34$  versus  $15.74 \pm 3.22$ ,  $P = .007$ ;  $74.92 \pm 14.27$  versus  $72.92 \pm 13.95$ ,  $P = .033$ ), and no significant difference was found in average GCC thickness ( $74.57 \pm 9.47$  versus  $74.94 \pm 9.50$ ,  $P = .636$ ).

**Conclusion:** Tafluprost effectively increased superficial macular capillary VD, and peripapillary capillary VD in patients with POAG and NTG. This finding indicates that Tafluprost not only lowers IOP, but may also enhance retinal blood flow in POAG and NTG patients.

PP-249

**Neuroprotection of SRT2104 in Murine Acute Ocular Hypertension via Enhancing SIRT1 Deacetylation**X Bai<sup>1</sup>, Y Xu<sup>1</sup>, J Huang<sup>1</sup>.<sup>1</sup>State Key Laboratory of Ophthalmology, Zhongshan Ophthalmic Center, Sun Yat-sen University, Guangdong Provincial Key Laboratory of Ophthalmology and Visual Science, Guangzhou, People's Republic of China

**Objective:** Neuroprotection is always the core problem to be solved in acute glaucoma. SRT2104 is a micromolecular activator of silent information regulator 1 (SIRT1) and shows neuroprotective effects in central nervous system and retinal degeneration. Here we investigated whether SRT2104 could protect retina in murine acute ocular hypertension (AOH) and explored the underlying mechanisms.

**Methods:** SRT2104 was injected intravitreally immediately after inducing AOH injury. The structure and function of inner retina were evaluated by hematoxylin and eosin staining, optical coherence tomography and scotopic electroretinogram, respectively. Retinal ganglion cells (RGCs) survival rate, cleaved caspase-3 expression in RGCs, reactive gliosis (macroglia and microglia) and retinal vascular inflammation were quantified by immunofluorescence staining. RGCs apoptosis and senescence were evaluated by TUNEL assay and SA-beta-Gal staining. SIRT1 and inflammatory factors (IL-1 $\beta$ , TNF- $\alpha$ , IL-8, CCL2) levels were detected by western blot. Moreover, the expressions of total-p53, NF- $\kappa$ B-p65, STAT3 and acetyl-p53, NF- $\kappa$ B-p65, STAT3 were determined by western blot to investigate the neuroprotective mechanisms of SRT2104

**Results:** SRT2104 administration significantly reversed the downregulated expression of SIRT1 protein, preserved retinal thickness thinning especially inner retina and retinal ganglion cells (RGCs) survival rate, also partly resumed retinal dysfunction after AOH. Additionally, the results showed that SRT2104 intervention could effectively protect RGCs from caspase-3 dependent apoptosis and cell senescence, reduce reactive gliosis (macroglia and microglia) and ameliorate retinal vascular inflammation, suppress the release of inflammatory factors (IL-1 $\beta$ , TNF- $\alpha$ , IL-8, CCL2) induced by AOH injury. Mechanistically, increased expression of acetyl-p53, NF- $\kappa$ B-p65, STAT3 caused by AOH were significantly reversed by SRT2104 intervene.

**Conclusion:** SRT2104 administration confers neuroprotection on retinal AOH injury through enhancing SIRT1 deacetylation and subsequent suppression of apoptosis, senescence and neuroinflammation-related pathways.

## PP-250

**Surgical outcomes after combined surgery versus cataract extraction alone in pseudoexfoliation glaucoma.**

R Dcruz, A Rao<sup>1</sup>.

<sup>1</sup>*glaucoma, Ivpei, bhubaneswar, India*

**Objective:** To compare the long-term surgical outcomes of cataract surgery alone versus combined surgery in pseudoexfoliative glaucoma(XFG) in terms of intraocular pressure, IOP, reduction

**Methods:** All patients with XFG who underwent either cataract surgery alone (group1-either phacoemulsification-PHACO/manual small incision cataract surgery-SICS, n=35) or combined surgery (Group 2- (phacotrabeculectomy, PHACOT or small incision cataract surgery +trabeculectomy, SICST, n=47) from 2013-2019 by a single trained surgeon, were screened and recalled for a detailed clinical examination, including Humphrey visual field analyzer (24-2 SITA standard strategy and 10-2 when indicated) at 3 monthly intervals for a minimum of 2 years

**Results:** A total of 81 eyes of 67 patients with XFG were included in this study, that included 35 eyes in group1 and 46 eyes in group 2 eyes. Both groups achieving 26-40% IOP reduction from pre-operative IOP levels,  $p < 0.001$ , with cataract surgery alone achieving a  $>23\%$  IOP reduction at final follow up. Surgical success rates were similar in both groups (complete success 66% in group1 and 55% in group2,  $p=0.4$ ), and qualified success 17% in group1 versus 24% in group2,  $p=0.8$ ). Group 2 eyes had more post-operative transient ( $n=32$  vs 21) and late complications (21 vs 5) than group 1, with transient post-operative IOP spikes being the most common post-operative early complication. Kaplan-Meier analysis showed a marginally better survival rate for group1 (75% (55-87%) than group 2, 66% (50-78%), at 2years which was not significantly different

**Conclusion:** Cataract surgery can be as effective as combined surgery in XFG eyes. The final visual acuity, IOP profile, and complication rates are comparable between the two procedures

PP-253

**Automatic measurement of vertical cup/disk ratio on mobile devices: valuable for non-specialist glaucoma doctors**W Jiang, M Hu<sup>1</sup>, Y Wu<sup>2</sup>.<sup>1</sup>East China Normal University, <sup>2</sup>Department of Ophthalmology, Ninth People's Hospital Affiliated to Shanghai Jiao Tong University School of Medicine, Shanghai, People's Republic of China

**Objective:** Glaucoma is currently one of the leading causes of irreversible blindness in the world. A large number of previous studies have shown that larger vertical CDR is closely associated with progression of glaucoma. Although not necessarily relevant, CDR is very useful in clinical practice and evaluation of glaucoma. However, determination of CDR varies among doctors and can be influenced by subjectivity. Besides, some non-specialist doctors do not know enough about CDR, which may affect their judgment of the condition. In view of this, we plan to develop a CDR measurement system that can be deployed on mobile devices, as a reference for doctors to diagnose and treat.

**Methods:** We train a segmentation model on public datasets with a neural network—and the generalization ability of the obtained model is insufficient. On the original dataset, it can precisely split the optic disk/cup. In practical application, after printing and taking a photo to upload, the quality of the images is seriously compromised. It greatly affects the segmentation effect. To handle this situation, we collect a large number of fundus photos from the actual diagnosis. A professional glaucoma doctor annotates the photos. We use this data to do incremental learning on the original model. The left and right eye automatic discrimination and auto-cropping of images are added to make the operation easier. We design a WeChat applet and deploy these features to the server. Users can easily access these functions through the developed WeChat applet.

**Results:** Our model performs well on public datasets. The dice of optic disk/cup segmentation is 0.961 and 0.872. With more actual diagnostic images added, it has an increasingly good segmentation effect in practical application. The WeChat applet makes the CDR automatic measurement function easily accessible to doctors and even patients.

**Conclusion:** AI has great potential in medical. CDR automatic measurement is a concrete application of AI in it. Our system is proved valuable clinically, especially for non-specialist glaucoma doctors.

PP-254

## Comparison of the Diagnostic Efficacy of UBM-based AI with Ophthalmologists in Differentiating Primary and Secondary AAC

J Huang<sup>1</sup>, L Cheng<sup>1</sup>, Y Ling<sup>1</sup>.

<sup>1</sup>Zhongshan Ophthalmic Center, Sun Yat-sen University, Guangzhou, People's Republic of China

**Objective:** To compare the comprehensive diagnostic efficacy (considering both accuracy and time of diagnosis) of an ultrasound biomicroscopy (UBM)-based artificial intelligence (AI) model with ophthalmologists in differentiating acute primary angle closure (APAC) and acute secondary angle closure associated with zonular laxity (ASAC-ZL) or with lens subluxation (ASAC-LS).

**Methods:** Patients diagnosed with APAC, ASAC-ZL and ASAC-LS were recruited. The diagnosis of the above diseases was according to the status of lens during phacoemulsification. Healthy subjects without any history of eye disease or surgery were also included. UBM images of the affected eye (normal subjects chose one random eye) were collected, and biological parameters of both eyes were measured by UBM. EfficientNet was used to construct an AI model based on UBM images of the affected eyes. Macro-Area Under Curve (AUC), diagnostic accuracy and time spent were calculated and compared to a traditional logistic regression analysis model based on biological parameters of UBM calculated manually in both eyes. In addition, 200 randomly ordered UBM images of each type of subjects' affected eyes were read and diagnosed by three ophthalmologists with different qualifications (primary, junior and senior). Meanwhile, all the 200 images were input into the AI model. The diagnostic accuracy and time spent by the ophthalmologists were calculated and compared to the AI model.

**Results:** The macro-AUC of the logistic regression models was 0.9373 with an accuracy rate of 79.45%, which was higher than the AI models (macro-AUC was 0.9046, and the accuracy rate was 76.1%). The average diagnostic accuracy of ophthalmologists was 64.17% when reading 200 UBM images, compared to 70% for the AI model. The average time spent by AI model (13.03 seconds) was significantly less than that of the logistic regression model (1200.00 seconds) and the ophthalmologists' reading diagnosis time (20.13 seconds).

**Conclusion:** The diagnostic accuracy rate of AI was slightly lower than that of the logistic regression model, but it was higher than that of ophthalmologists' reading diagnosis. However, the AI model had an absolute advantage in terms of diagnosis time. As a result, AI outperformed ophthalmologists in differentiating acute primary and secondary angle closure associated with zonular abnormality.

PP-255

**Combined Trabeculotomy-Non-penetrating Deep Sclerectomy for Glaucoma in Sturge-Weber Syndrome**L Huang.

**Objective:** To evaluate the efficacy and safety of combined trabeculotomy-non-penetrating deep sclerectomy (CTNS) for the treatment of Sturge-Weber syndrome (SWS) secondary glaucoma.

**Methods:** This retrospective study reviewed cases underwent CTNS as initial surgery for SWS secondary glaucoma at our Ophthalmology Department center from April, 2019 to August, 2020. Success was defined as an intraocular pressure (IOP)  $\leq 21$  mm Hg with (qualified success) or without (complete success) the use of anti-glaucoma medications at last follow-up. IOP  $> 21$  mm Hg or  $< 5$  mm Hg despite all necessary application of anti-glaucoma medications at the last follow-up, or with vision-threatening complications were classified as failure.

**Results:** A total of 23 eyes of 22 patients were included. Mean IOP at last follow-up time ( $18.7 \pm 4.1$  months) was significantly lower than that before surgery ( $17.1 \pm 5.3$  mmHg vs  $25.6 \pm 5.5$  mmHg;  $p < 0.0001$ ). Complete success was achieved in 14 (60.9%) and overall success in 20 (87.0%) eyes at the last follow-up. Postoperative complications included transient hyphema (12/23, 52.2%), transient 1 degree shallow anterior chamber (1/23, 4.3%), and retinal detachment (1/23, 4.3%). No other severe complications were detected during the follow-up.

**Conclusion:** CTNS, with low complication rates, is an effective surgery tackling the pathogenesis of SWS secondary glaucoma. CTNS in SWS secondary glaucoma patients is safe and effective for short and medium period. Long-term outcome of CTNS deserve further exploration.



PP-258

**Adherence to Antiglaucoma Medications and Effect of Telephone Reminders Amongst Patients at University College Hospital, Ibadan**

A Ata<sup>1</sup>, T Sarimiye<sup>1</sup>, O Olawoye<sup>1</sup>, C Bekibele<sup>1</sup>.

<sup>1</sup>Ophthalmology, University College Hospital, Ibadan, Ibadan, Nigeria

**Objective:** To determine adherence to antiglaucoma medications and effect of telephone reminders on adherence amongst glaucoma patients at the University College Hospital, Ibadan, in order to provide evidence that would guide appropriate and cost effective interventions for improving antiglaucoma medication adherence.

**Methods:** A total of 118 glaucoma patients were recruited into this study and were randomized into two arms using sealed opaque envelopes into control and intervention groups, comprising 59 persons per arm. Adherence amongst these patients was assessed using the 8-item Morisky Medication Adherence Scale (MMAS-8). The intervention group received daily phone SMS reminders for 66 days. MMAS-8 was then used to assess adherence at the end of the study period. A study questionnaire including the socio-demographics and clinical characteristics, MMAS-8, Belief about Medicines Questionnaire (BAMQ) were used to determine factors associated with medication adherence. This study is registered with Pan African Clinical Trials Registry, PACTR202110860145835.

**Results:** Overall adherence level was 46%. The mean age of the respondents was 64.7+14.0 and there was no difference in the socio-demographics between those randomised into intervention and control groups. Higher perceived necessity of glaucoma medications ( $p=0.010$ ) was associated with more likelihood of being adherent while a higher perceived concerns about glaucoma medications ( $p=0.017$ ) was associated with being non-adherent. At the end of the intervention, mean adherence ( $7.49 \pm 1.18$ ) was significantly better ( $p=0.022$ ) amongst those who received the intervention and percentage change in adherence (26.92%) ( $p<0.001$ ) was statistically significant.

**Conclusion:** Daily phone SMS reminders had a significant positive effect on patient's adherence to their medications. We recommend adoption of a cheap means to remind patients to use their medication and continued education to aid in intentional adherence.

PP-259

**Risk Factors of combined Phacoemulsification and excisional goniotomy for Angle-closure Glaucoma**Q Qian, D Lin<sup>1</sup>.<sup>1</sup>Changsha aier eye hospital, Changsha, People's Republic of China**Objective:**

To evaluate the therapeutic success, and risk factors for combined phacoemulsification and Kahook Dual Blade excisional goniotomy (Phaco/KDB) in primary Angle-closure glaucoma (PACG).

**Methods:**

A retrospective chart review was conducted on glaucoma patients who underwent Phaco/KDB between September 2019 and August 2021 at 2 ophthalmology centers. Complete success was defined as unmedicated intraocular pressure (IOP)  $\leq 18$ mmHg with no loss of light perception and no further glaucoma surgery, while the medicated IOP  $\leq 18$ mmHg was defined as qualified success with lesser medications than at baseline.

**Results:**

72 eyes (64 patients) with a mean age of  $67.1 \pm 8.1$  years were included in this study, and 70.2 % were female. The mean medicated baseline IOP decreased from  $23.4 \pm 8.1$  to  $16.6 \pm 3.9$  mmHg at an average of  $11.6 \pm 3.7$  months follow-up (-29.1%;  $P < 0.00$ ). Medications decreased from  $2.6 \pm 1.3$  to  $0.4 \pm 0.9$  (-82.6 %;  $P < 0.001$ ). Complete success and qualified success were achieved in 65.3 % and 79.2 % of eyes, respectively. Risk factors for surgical failure including high medicated baseline IOP, short axial length, combined goniosynechialysis procedure, and male gender (all  $P < 0.05$ ). Hyphema, postoperative shallowing anterior chamber, and IOP spike were the most common complications. The cumulative survival proportion for qualified success at 22 months was 51.7%.

**Conclusion:**

Phaco/KDB provided acceptable therapeutic success rate and may therefore be recommended in patients with coexisting cataract and PACG. Identifying patients with risk factors preoperatively may help clinicians predict surgical success.

## PP-260

**Phaco-Endocycloplasty versus Phaco alone in an exclusive cohort of mild-to-moderate Primary Angle Closure Disease**V Pathak Ray.

**Objective:** To investigate the efficacy and safety of endocycloplasty when it is combined with phacoemulsification versus phacoemulsification alone in medically controlled or uncontrolled primary angle-closure (PAC) or glaucoma (PACG) after laser peripheral iridotomy (LPI).

**Methods: Design:** Retrospective, interventional, comparative.

**Participants:** Subjects with PAC/PACG aged 30 years or more after LPI with visually significant cataract. Retrospective review of consecutive patients who underwent phaco-endocycloplasty (P-E) or phaco alone (P-A); subjects had controlled or uncontrolled mild-to-moderate glaucoma not threatening or involving fixation.

**Main outcome measures:** Primary outcome measure was intraocular pressure (IOP). Secondary outcome measures were best-corrected visual acuity (BCVA), number of antiglaucoma medications (AGMs), complications, and complete success.

**Results:** 49 eyes were included; 26 eyes underwent P-E, and 23 eyes underwent P-A. Mean follow-up was  $12.5 \pm 8.3$  and  $14.9 \pm 12.0$  months in the P-E group and PA groups respectively. Age of the patients did not differ between groups ( $p=0.395$ ). Mean preoperative IOP ( $23.9 \pm 11.8$  and  $20.1 \pm 5.2$  mmHg in P-E and P-A groups respectively,  $p=0.718$ ) BCVA did not differ between the groups, but AGM did ( $3.0 \pm 1.1$  and  $2.0 \pm 1.1$ ,  $p=0.002$ ). However, post-operatively both IOP ( $14.1 \pm 2.4$  in P-E and  $16.6 \pm 3.6$  mmHg in P-A,  $p<0.001$ ) and AGM ( $0.5 \pm 0.9$  in P-E and  $1.4 \pm 1.0$  in P-A,  $p<0.001$ ) were significantly reduced in the P-E group. The BCVA ( $p=.147$ ) and rate of complications ( $p=.565$ ) were similar between groups.

Complete success (defined as IOP  $>5$  and  $<21$  with no medication) was greater in the PE group (69.2% vs. 21.7%,  $p<.001$ )

**Conclusion:** Both procedures are efficacious in lowering IOP and AGM in PACG, but phaco-endocycloplasty does so with significantly greater efficacy and lesser use of AGM, without compromising safety. A randomised control trial is underway between the two to determine validity of this pilot study.

PP-262

### Comparison between RNFL thickness using a new SD-OCT and corresponding Octopus Perimetry Cluster Analysis

Z I Khatib.

**Objective:** To study the structure function correlation between the RNFL layer thickness on a new spectral domain OCT system and the corresponding visual field defects using the Cluster Analysis software on the Octopus Perimeter.

**Methods:** In this retrospective study from a tertiary care center, patients (normal and Glaucomatous) who underwent Perimetry testing (Octopus 600 Perimeter) and OCT RNFL thickness analysis (Optopol Revo60 SD-OCT) were included. The primary outcome measure was to see the correlation between thickness of each of the 10 OCT RNFL sectors and the Visual Field mean deviation in the corresponding 10 sectors of Cluster Analysis on Octopus Perimeter. Using logistic regression analysis, the probability of each OCT RNFL sector to predict a corresponding field defect and the RNFL thickness below which a field defect is likely was determined, along with the ability of the OCT RNFL thickness to predict presence or absence of Glaucoma.

**Results:** In 100 eyes of 62 patients, out of the 10 OCT RNFL sectors analyzed, 4 sectors showed a significant correlation with their corresponding visual field cluster defects. These included the sectors that make up the supero-temporal arcuate fibres (Sector 3: Correlation Coefficient -0.59 with  $p < 0.001$ , Sector 4: Correlation Coefficient -0.62 with  $p < 0.001$ ) and the infero-temporal arcuate fibres (Sector 7: Correlation Coefficient -0.51 with  $p = 0.004$ , Sector 8: Correlation Coefficient -0.40 with  $p < 0.03$ ). The above 4 RNFL sectors were able to predict significant field defects in their corresponding Perimetry clusters, and were also able to predict the presence or absence of glaucoma with good sensitivity and specificity. The remaining 6 OCT RNFL sectors showed no significant correlation with visual fields.

**Conclusion:** RNFL analysis on the Revo60 OCT correlates well with Octopus Perimetry and is capable of accurately predicting glaucomatous visual field defects.

PP-263

### Correlation Between the Orbital and Intraocular Portions of The Optic Nerve in Glaucomatous Patients

S Thakur<sup>1</sup>, A Dey Sarkar<sup>1</sup>, A Dey Sarkar<sup>2</sup>, S Sarkar<sup>1</sup>.

<sup>1</sup>Ophthalmology, Midnapore Medical College & Hospital, Midnapore, <sup>2</sup>Ophthalmology, NRS Medical College and Hospital, Kolkata, India

**Objective:** Introduction: Glaucoma is a progressive optic neuropathy in which there is apoptosis of ganglion cells leading to thinning of retinal nerve fiber layer and neuro retinal rim. With the advent of spectral domain optical coherence tomography (SD OCT) the structural defects can be documented at an early stage. But in patients with opaque media, disc evaluation, automated perimetry and OCT cannot help in diagnosis. It has been observed that optic atrophy leads to thinning of retrobulbar optic nerve. So, estimation of retrobulbar optic nerve diameter can play an important role in diagnosis of glaucoma.

Objective: To investigate the correlation between orbital and intraocular portions of optic nerve among Glaucoma patients.

**Methods:** Methods: One eye of 32 volunteers of newly diagnosed Glaucoma patients underwent optic disc and retinal nerve fiber layer (RNFL) analysis using Spectral domain Optical Coherence Tomography and echographic measurements of the retrobulbar optic nerve. All the correlations between orbital and intraocular portions of optic nerve parameters have been calculated using Spearman's rho( $r_s$ ) as the index of correlation

**Results:** Results: The male-to-female ratio was 18:14, and the mean age of our sample ( $\pm$ SD) was 50.53  $\pm$  10.19years. Orbital optic nerve diameter and cross-sectional area correlated significantly and positively with neuroretinal rim area (OND: p value=0.00001; ONCSA: p value=0.00001) and average nerve fibre layer thickness (OND: p value=0.0001; ONCSA: p value=0.00002) and with Cup-disc ratio significantly negative (OND: p value=0.00002; ONCSA: p value=0.00006). Retrobulbar optic nerve cross-sectional area-to-disc area ratio (ONCSA/D) was found to have a statistically demonstrable positive correlation with neuroretinal rim area/disc area ratio (NR/D) (p=0.00003). The ONCSA/D is also negatively correlated with disc area ( $r_s = -0.34397$ , p = 0.07) and significantly correlated with average RNFL thickness ( $r_s = 0.668$ , p = 0.0001).

**Conclusion:** Conclusion: Orbital optic nerve dimensions correlate well with the neuroretinal rim characteristics of the optic disc. Hence, echographic measurements of the retrobulbar optic nerve may be a useful addition to the traditional triad for diagnosis of Primary Open Angle Glaucoma (POAG) especially in patients with opaque media.

PP-265

**Automated, affordable and accurate glaucoma screening through Easy- to- use AI is now a reality**

S Upadhyaya<sup>1</sup>, D Rao<sup>2</sup>, F Savoy<sup>3</sup>, K Negiloni<sup>4</sup>, V Rengaraj<sup>1</sup>.

<sup>1</sup>*Glaucoma, Aravind Eye Hospital, Pondicherry, India*, <sup>2</sup>*Artificial Intelligence, Remidio Innovations Private Limited, Baltimore, United States*, <sup>3</sup>*Artificial Intelligence, Medios Technologies Remidio Innovative Solutions, Singapore, Singapore*, <sup>4</sup>*Artificial Intelligence, Remidio Innovative Solutions, Bengaluru, India*

**Objective:** To assess the performance of a novel, automated screening tool for referable glaucoma using an offline AI deployed on a smartphone-based fundus camera.

**Methods:** A cross-sectional study was conducted in 6 satellite vision centers (VC) of a tertiary eye hospital in India. 303 subjects underwent 2 disc centered fundus images of sufficient quality on a validated portable fundus camera by minimally trained ophthalmic assistants. The images were analyzed by an offline AI and the diagnosis was recorded in three categories- normal, glaucoma or disc suspect. Same images were graded into the same 3 categories by VC doctors masked to the diagnosis given by the AI through tele-ophthalmology based on a pre-defined criteria. Additionally, 58 (19%) subjects deemed referable by either the AI or the VC doctor were referred to a glaucoma specialist at the tertiary eye hospital. The AI output was compared against VC doctor and specialist diagnosis.

**Results:** Sensitivity of the offline AI to detect confirmed glaucoma was 91.30% (95%CI 71.96- 98.93) and specificity 92.14% (95%CI 88.35-95.01) when compared against the VC tele-ophthalmology doctors. Combining glaucoma and suspects as referable, the sensitivity and specificity of the AI algorithm was 74.4% (95%CI 63.9 - 83.2) and 98.6% (95%CI 96 - 99.7). For the subjects referred to the base hospital, sensitivity of AI to pick up glaucoma was 96.7% (95% CI 82.8- 99.9) for the specialist vs 53.3% (95% CI 34.3 – 71.7) for the VC doctor.

**Conclusion:** The AI showed excellent performance in detecting glaucoma with minimal over referral of normal cases. The performance on disc suspect category was moderate, as it being a gray area requiring additional investigations. The AI performance to detect glaucoma based solely on fundus images was comparable to a specialist with full examination. The AI can potentially be used as a clinical decision support tool to improve diagnostic consistency of VC doctors for glaucoma.

PP-266

**Ultrasound cyclo-plasty for moderate glaucoma : 18-month results from a prospective study**W Ruixue<sup>1</sup>, C Xiaoya<sup>1</sup>.<sup>1</sup>The Affiliated Xuzhou Municipal Hospital of Xuzhou Medical University, Xuzhou, People's Republic of China

**Objective:** To evaluate the long-term clinical efficacy and molecular effects of ultrasound cyclo-plasty (UCP) in the treatment of moderate glaucoma.

**Methods:** An 18-month clinical study was conducted in 32 moderate glaucoma patients. The primary outcome was evaluated by the surgical success, which was defined as the intraocular pressure (IOP) reduction of greater than or equal to 20% from the baseline and the IOP value of greater than 5 mmHg at the last follow-up. The secondary outcome referred to quality of life, complications, and the mean of the IOP at each follow-up. In the animal experiment, 20 New Zealand rabbits were used to establish high IOP model and implement UCP. The distribution of Aquaporin 4 (AQP4) in ciliary body and the tissues change under electron microscope were observed after surgery. Most patients had good postoperative quality of life.

**Results:** The mean IOP of patients 18 months after UCP decreased from  $34.9 \pm 4.9$  mmHg to  $23.5 \pm 5.2$  mmHg. No vision loss occurred in all patients. Some patients had postoperative complications, but the symptoms were mild and disappear within 3 months after surgery. Histology showed that AQP4 remained in the ciliary muscle after UCP, and only the bilayered epithelium cells showed coagulative necrosis. Also, electron microscopic observation revealed the destruction of ciliary process cells covered by ultrasound after UCP.

**Conclusion:** UCP has mild postoperative reaction and mild treatment of ciliary tissue, which is a safe and effective method for reducing IOP in moderate glaucoma.

PP-267

**Magnolol limits NF- $\kappa$ B-dependent inflammation by targeting PPAR $\gamma$  to protect retina in mice following acute ocular hypertension**

N Wang, Y Yang, Y Liu, L Huang, M Gu, Y Wu, L Xu, H Sun, W Guo.

**Objective:** Glaucoma is the leading cause of irreversible blindness in the world. Elevated intraocular pressure (IOP) is recognized as one of the most critical factors, but the loss of retinal ganglia cells (RGCs) often persists when IOP is controlled. Recently, a large number of studies focus on the inflammatory and immune responses in the occurrence and development of glaucoma. Magnolol (MAG), the principal ingredient of magnoliae officinalis cortex, as a previous reported anti-inflammatory substance, but its role on retinal protection was unclear.

**Methods:** The neurodegeneration of retina in mice model following acute hypertension (AOH) injury was evaluated by immunohistochemistry and TdT-mediated dUTP nick-end labeling (TUNEL). The structure and function of retina were checked by hematoxylin and eosin (H&E) staining and Electroretinography (ERG). The anti-inflammatory and immunoregulatory effect of MAG were detected by quantitative RT-PCR, western blot, immunohistochemistry and Flow cytometry. Inhibitor of PPAR $\gamma$  was used to test the target of MAG's retinal protective effect, followed by verification with H&E staining and western blot assays.

**Results:** We found MAG relieved AOH-induced retinal damages and inflammation. Further studies revealed MAG alleviated NF $\kappa$ B-dependent inflammatory process by preserving I $\kappa$ B $\alpha$ , and it decreased the polarization of M1-type (pro-inflammatory) microglia and promoted the polarization of M2-type (anti-inflammatory) microglia after AOH injury. MAG also relieved the down regulation of blood-retinal barrier (BRB) related proteins induced by AOH in retinas and the promotion of Th cell differentiation in eye's draining lymph nodes. Peroxisome proliferator-activated receptor- $\gamma$  (PPAR $\gamma$ ) is a primary target of MAG, and treatment with PPAR $\gamma$  inhibitor GW9662 attenuated the neuroprotective and anti-inflammatory effects of MAG in retinas.

**Conclusion:** Our findings revealed that MAG targeting PPAR $\gamma$  suppressed nuclear factor kappa B (NF $\kappa$ B)-dependent inflammatory processes in mice retinas following AOH. MAG could be developed to a novel anti-inflammatory therapeutic agent for relieving the progression of glaucoma.



PP-268

## Gonioscopy-assisted Transluminal Trabeculotomy is Effective in Treating Chinese Open-angle Glaucoma Patients

Y Qiao, J Chen<sup>1</sup>.

<sup>1</sup>Ophthalmology, Eye and ENT Hospital of Fudan University, Shanghai, People's Republic of China

**Objective:** To assess the efficacy and safety of prolene gonioscopy-assisted transluminal trabeculotomy (GATT) in Chinese patients with open-angle glaucoma.

**Methods:** Seventy five eyes of 54 consecutive patients were included in this retrospective case series and underwent prolene GATT as a standalone treatment between December 2019 and September 2021. For eyes with baseline intraocular pressure (IOP) > 21 mmHg, surgical success was defined as  $6 \text{ mmHg} \leq \text{IOP} \leq 18 \text{ mmHg}$  and  $\geq 20\%$  IOP reduction with (partial success) or without (complete success) IOP-lowering medications. For eyes with initial IOP  $\leq 21 \text{ mmHg}$ , surgical success was defined as  $6 \text{ mmHg} \leq \text{IOP} \leq 18 \text{ mmHg}$  with less (partial success) or without (complete success) medications.

**Results:** Sixty eight eyes had primary glaucoma (58 juvenile-onset and 10 adult-onset), seven eyes were diagnosed with secondary glaucoma (5 pigmentary and 2 steroid-induced). The mean ( $\pm$  SD) age at surgery was  $32.68 \pm 11.49$  years. The median follow-up time was 269 days. The preoperation IOP was  $28.21 \pm 11.69 \text{ mmHg}$  on  $3.58 \pm 0.62$  drugs. After GATT, IOP and number of medications were both reduced significantly at all follow-up visits (all  $p < 0.0001$ ). One year after surgery, the average IOP was  $15.24 \pm 4.15 \text{ mmHg}$  on  $1.38 \pm 1.57$  drugs. The cumulative proportion of partial success was 72.38%, while that of complete success was 44.82%. Sixteen eyes experienced IOP spike during the first post-operation month and 11 eyes required additional anti-glaucoma procedures. The occurrence of IOP spike (HR=2.2,  $p=0.03$ ) was identified to be the risk factor for surgical failure.

**Conclusion:** GATT is an effective treatment for open-angle glaucoma in Chinese patients. IOP should be closely monitored after surgery.

## PP-270

**Efficacy and safety of ultrasonic cycloplasty (UCP) and valve implantation in the treatment of fundus disease-related neovascular**

F Fan, S Li.

**Objective:** To compare the efficacy and complications of ultrasonic cycloplasty (UCP) combined with anti-VEGF and Ahmed glaucoma drainage valve implantation combined with anti-VEGF in the treatment of fundus disease-related NVG.

**Methods:** The clinical data of 45 eyes of 43 patients with fundus disease-related NVG who underwent UCP combined with anti-VEGF and Ahmed glaucoma drainage valve implantation combined with anti-VEGF from August 2020 to November 2021 were analyzed retrospectively, with 14 cases (15 eyes) in UCP group and 29 cases (30 eyes) in Ahmed group. The main outcome measures included the success rate of the surgery, and the secondary outcome measures included the comparison of IOP and baseline IOP at each review, pain relief, the use of IOP reducing drugs, intraoperative and postoperative complications, etc. Adopt spss24.0 statistical software for chi square test, rank sum test, variance homogeneity test and other statistical analysis, with  $P < 0.05$  as the difference was statistically significant.

**Results:** The success rate of valve group and UCP group was 100% 3 months after surgery; the success rates of Ahmed group and UCP group were 90.0% (27/30) and 86.7% (13/15) 6 months after surgery. The IOP, IOP lowering drugs and the subjective pain scores of patients in Ahmed group and UCP group after surgery were significantly lower than that before surgery, and the difference was statistically significant (all  $P < 0.05$ ). One day after surgery, the IOP, IOP lowering drugs and the subjective pain scores of patients in Ahmed group were significantly lower than those in the UCP group, and the difference was statistically significant (all  $P < 0.05$ ). The comfort scores of patients at 1 and 7 days in the Ahmed group after surgery were significantly higher than those in the UCP group ( $P < 0.05$ ). Conjunctival congestion and low IOP occurred in both groups. Compared with UCP group, the incidence of complications in Ahmed group was higher and more complex, including intraoperative and postoperative bleeding, postoperative shallow anterior chamber, Ahmed tube clamping, Ahmed tube exposure and other serious complications.

**Conclusion:** Compared with Ahmed group, UCP group has the same success rate in the treatment of fundus disease-related NVG, and the IOP can be significantly improved; However, the safety of UCP group is higher. Incision free surgery can improve the postoperative comfort of patients, and provide a new choice for the clinical treatment of fundus disease-related NVG, which can be further popularized.

PP-272

**Microglia depletion does not rescue retinal ganglion cells in a mouse model of glaucoma**Z Tan.

**Objective:** To test whether depletion of microglia in the optic nerve head has a beneficial effect on retinal ganglion cell numbers and function in a mouse model of glaucoma.

**Methods:** Microglia were depleted by oral administration of the CSF1R antagonist PLX5622. Ocular hypertension was induced by unilateral injection of magnetic microbeads into the anterior chamber. Retinal ganglion cell function was assessed with pattern electroretinography and measurement of visual acuity by observation of the optomotor reflex. Gene expression patterns in optic nerve astrocytes were tested on freshly dissociated astrocytes.

**Results:** PLX5622 efficiently depleted microglia in the retina and the optic nerve head, but about 20% of microglia persisted in the myelinated optic nerve proper even after prolonged exposure to the drug. PLX5622 had no effect on ganglion cell function by itself. Elevation of the IOP for 4 weeks led to the expected decrease of visual acuity and pattern ERG amplitude. Microglia ablation had no effect on these parameters. Ganglion and axon numbers were counted histologically post mortem. Mice in the microglia depletion group showed a moderate but significantly greater loss of ganglion cells than the control group. Gene expression patterns in optic nerve head astrocytes are consistent with an A2 (or neuroprotective) pattern. Microglia depletion blunted the up-regulation of A2 genes in astrocytes.

**Conclusion:** Microglia depletion is unlikely to be protective of retinal ganglion cells in early glaucoma.

PP-273

**Investigation on the role of Piezo1 in the regulation of activation of rat optic nerve head astrocytes under pressure**G Xiaodan.

**Objective:** Glaucoma is a chronic neurodegenerative disease characterized by progressive degeneration of retinal ganglion cells (RGCs) and loss of optic nerve fibers. High intraocular pressure (IOP) is the most clear and the most important risk factor for glaucoma. Astrocytes are the major glial cells in the region, which may serve as a link between high IOP and axonal degeneration. The optic nerve head astrocytes can early feel and response to the fluctuation of intraocular pressure induced by mechanical stimulation, and it's sensitive to mechanical stimulation. Piezo1 is a newly discovered mechanical sensitive ion channels, with mechanical sensitivity, and mechanical force can be directly activated. This study observes the activation of astrocytes under pressure through glaucoma hydrostatic pressure cell culture apparatus invented by our group, and discuss how the novel mechanical sensitive ion channel Piezo1 regulate the activation of astrocytes in response to ocular hypertension.

**Methods:** 1. Optic nerve head astrocytes extracted from rats were under pressure of 0,20,40,60mmHg for 10h and 24h. 2. Cells were treated with specific inhibitors of GsMTx4, ALLN and transient transfection,

**Results:** 1. Gradient pressure (0,20,40,60mmHg) were added to rat optic nerve astrocytes for 10h, 24h. The marker protein of astrocytes- GFAP, the number of migration, and the expression of TNF alpha increased with the increase of pressure. The variation trend of Piezo1 with pressure and time was consistent with the change of GFAP, the number of migration, and TNF  $\alpha$ . 2. We found that TNF  $\alpha$  increased and the number of migration decreased. The expression of GFAP did not change.

**Conclusion:** In conclusion, we demonstrated that the activation of astrocytes under pressure may cause the increase of the number of cell migration and the expression of TNF  $\alpha$  and GFAP. The mechanism may be associated with the expression of ion channel Piezo1 which may cause the increase of calcium influx and the activation of calpain. So we can draw the conclusion Piezo1 under pressure involved in the activation of astrocytes, and plays an essential role in GFAP; results show that under the pressure of Piezo1, calpain, integrin beta 1 did not participate in the GFAP generation process. The results of GFAP showed that Piezo1, calpain and integrin beta 1 did not participate in the formation of GFAP.

PP-274

### Comparison Of Optic Disc Perfusion In RPC (Perfusion Percentage, Flux Index) Using Angioplex OCTA In Glaucomatous And Normal Eyes

M Sankaran<sup>1</sup>, A Singaram<sup>2</sup>, S Mohan<sup>3</sup>, N Anand<sup>2</sup>.

<sup>1</sup>Dr.Agarwal's eye hospital, <sup>2</sup>Glaucoma, <sup>3</sup>Rajan eye care hospital, Chennai, India

**Objective:** This study aims to compare the optic disc perfusion in the RPC (perfusion percentage and flux index values) using Angioplex OCTA in glaucomatous and normal eyes.

**Design:** This is a cross sectional observational study.

**Methods:** Subjects: In this study, 68 normal subjects and 67 glaucoma subjects are studied.

One eye of each subject is studied using OCTA on Zeiss angioplex. This study divides the glaucoma group into primary open angle glaucoma, primary angle closure glaucoma and normal tension glaucoma. They are also divided into stages as mild, moderate and severe glaucoma.

**Results:** Main Outcome measures: The study compares optic nerve head angiography values provided, between normal and glaucomatous eyes. This study also correlates the values of flux index with corresponding OCT RNFL of the subjects. Results: Flux index and perfusion percentage values prove to be significantly lower ( $p < 0.05$ ) than normal eyes in the global and in superior - inferior quadrants over the spectrum of glaucoma suggesting and confirming the fact that glaucoma affects the superior and inferior neural rim first. The OCTA flux index values in mild glaucoma is also found to be significantly lower ( $p < 0.05$ ) than in normal subjects. Flux index values also show correlation with OCT RNFL values.

**Conclusion:** Conclusion: Peripapillary RNFL vascular microcirculation measured as blood flux index and perfusion percentage by optical microangiography showed significant differences among the spectrum of glaucoma and these values also correlated with corresponding OCT RNFL values. Retinal nerve fiber layer microcirculation measurement using OMAG may help physicians monitor glaucoma and add to the existing investigations in the diagnosis of early glaucoma. This is one of the few studies done comparing the values obtained on Angioplex software across the disease spectrum of glaucoma. The values in this study are from angioplex software, its relationship with values from Angiovue is yet to be studied.

PP-275

**Surgical Outcomes Of Keiki Mehta Valve Versus Ahmed Glaucoma Valve Implantation In Refractory Glaucoma**A Mitra, T Ray Bhadra<sup>1</sup>.<sup>1</sup>Regional Institute of Ophthalmology, Kolkata, Kolkata, India

**Objective:** Keiki Mehta BP valve is a new glaucoma drainage device that works on the mechanism of body pressure. The aim of our study is to compare the surgical success and outcomes of Keiki Mehta valve and Ahmed glaucoma valve (AGV) implantation in refractory glaucoma.

**Methods:** Comparative, retrospective study. Patients aged >18 years, who underwent either Keiki Mehta valve or AGV implantation from January 2017 to December 2018 were included. Mean follow up was 30±3 months. 21<IOP<6 mm Hg without any anti-glaucoma medications was defined as complete success while that with medications was qualified success. Cumulative survival rates and intraoperative or postoperative complications along with IOP profiles were compared between the two groups.

**Results:** 40 patients (20 eyes with Keiki Mehta and 20 with AGV) were included. The mean baseline IOP in the two groups was not statistically different (32.7±4.5 mm Hg in Keiki Mehta and 30.8±4.2 mm Hg in AGV, p=0.12). The mean postoperative IOP at 30 months was not statistically different in the two groups (14.6±6.5 mm Hg in Keiki Mehta and 15.8±5.6 mm Hg in AGV, p=0.08). Keiki Mehta had 65% qualified success rate while AGV had 70% qualified success rate at the end of 30 months. Hypotony was the most common postoperative complication in both groups.

**Conclusion:** Keiki Mehta valve has an acceptable safety profile and success rate in refractory glaucoma that is comparable to AGV and can serve as a cost-effective treatment option.

PP-277

**Clinical Characteristics of Childhood Glaucoma in Tertiary Eye Hospital, Eastern Province, Saudi Arabia.**M Alwalmany<sup>1</sup>, A *Alhabash*<sup>2</sup>, S *Yassen*<sup>2</sup>, A *Aldawood*<sup>1</sup>.<sup>1</sup>*ophthalmolgy, Dhahran eye specalist hospital, Dhahran,* <sup>2</sup>*ophthalmolgy, Imam abdulrahman alfaisal hospital, khobar, Saudi Arabia*

**Objective:** To study childhood glaucoma in our region by using the Childhood Glaucoma Research Network (CGRN) classification system and to understand the clinical presentation, course, and outcome among patients presented to Dhahran Eye Specialist Hospital ( DESH ), Saudi Arabia.

**Methods:** A retrospective study where all medical files of patients 16 years old and younger who presented to the glaucoma clinic at DESH between Jan 2007– Dec 2017 were reviewed and data regarding demographic ( age at the presentation – Sex – Family history - Nationality), the clinical presentation and clinical outcome including ( Visual Acuity, Intraocular pressure (IOP), Horizontal corneal diameter, Cup/Disc ratio, Axial length, and refraction ), Number and type of medication and number and types of surgeries were collected and analyzed

**Results:** A total of 259 patients ( 442 eyes ) were included. Males were 56%, and females 44 %; most of the patients were from Saudi Arabia 93.1%. Bilateral involvement was found in 81.3%. Primary childhood glaucoma was observed more than secondary, with Primary congenital glaucoma (PCG) accounting for 48.2% and Juvenile open-angle glaucoma 9%. Glaucoma after cataract surgery was the most common secondary childhood glaucoma in our study accounting for 14% followed by glaucoma with ocular anomaly 12.9%; glaucoma with acquired conditions 10%, and finally glaucoma with systemic disease or syndrome 5.9 %. The oldest presenting age was observed with glaucoma with the acquired condition and the youngest age with PCG. Corneal opacity 22% and large cornea 19.2% were the most common presenting complaints. The highest IOP of  $29.56 \pm 9.33$  mmHg was seen in glaucoma with an acquired condition, and the lowest IOP of  $22.38 \pm 8.75$  mmHg was seen in glaucoma with a systemic disease or syndrome. The most common primary surgery was CCT +MMC, secondary surgery was Ahmed Valve implantation, tertiary surgery was cyclophotocoagulation. Beta-blocker was the most common antiglaucoma medication to be used, followed by carbonic anhydrase inhibitors, then prostaglandin analogs. The overall surgical success rate was found in 89.2% of the patients.

**Conclusion:** In this study , we used the CGRN classification to present a profile of childhood glaucoma in DESH which is considered one of the main referring centers for ophthalmology in Saudi Arabia, this study could be the first step toward greater collaboration between hospitals for a better understanding of childhood glaucoma profile in our region.

PP-278

**Differences in outcomes of *ab externo* trabeculectomy performed by residents versus assistants**

M Lima Fontes<sup>1</sup>, A Faria Pereira<sup>1</sup>, M Leuzinger Dias<sup>1</sup>, M Silva<sup>1</sup>, J Barbosa Breda<sup>1,2,3</sup>, J Araújo<sup>1</sup>, S Estrela Silva<sup>1</sup>, A Benevides Melo<sup>1</sup>, F Alves<sup>1</sup>, J Tavares Ferreira<sup>1</sup>.

<sup>1</sup>Ophthalmology Department, Centro Hospitalar Universitário de São João, <sup>2</sup>UnIC@RISE, Department of Surgery and Physiology, Faculty of Medicine of the University of Porto, Porto, Portugal, <sup>3</sup>Research Group Ophthalmology, Department of Neurosciences, KULeuven, Leuven, Belgium

**Objective:** To compare outcomes of *ab externo* trabeculectomy between residents and assistants.

**Methods:** A retrospective study including all consecutive eyes submitted to *ab externo* trabeculectomy in a tertiary center from January 2017 to June 2020. Patients under 18 years old were excluded. Data collected included patients' age and gender, glaucoma type, systemic and ocular comorbidities, lens status, type of surgeon, and if the procedure was combined with phacoemulsification and intraocular lens implantation. Best-corrected distance visual acuity (BCVA, logMAR), intraocular pressure (IOP), and number of different classes of hypotensive drops required before surgery and during follow-up were compiled, as well as intra and postoperative complications and subsequent interventions. Postoperative procedures such as bleb needling, tube shunt implantation and laser cyclophotocoagulation were considered as re-interventions.

**Results:** 68 eyes from 63 patients (43,6% female) were included. Mean age at surgery was  $64,75 \pm 15,06$  years. Mean follow-up time was  $33,05 \pm 14,98$  months. The most common type of glaucoma was primary open-angle glaucoma (48,5%, n=33), followed by pseudoexfoliative glaucoma (29,4%, n=20). 29,4% (n=20) of the eyes were phakic and 7,4% (n= 5) had previous glaucoma surgery. There were no significant pre-operative differences between groups, namely regarding IOP or glaucoma type. 14,7% (n=10) of the trabeculectomies performed were combined with phacoemulsification. 19,1% (n=13) of the procedures were performed by residents. No relevant intraoperative complications were described in either the residents or assistants' groups. IOP at 3-, 6- and 12-months after surgery was significantly higher in the resident's group (17,31 vs 12,92 mmHg, p=0,014; 17,33 vs 11,35 mmHg, p=0,010; 15,15 vs 12,04, p=0,037, respectively). The most common postoperative complications were bleb leak (33,8%, n=23), tight scleral flap sutures and cataract (both 19,1%, n=13), choroidal detachment (16,2%, n=11) and encapsulated bleb (10,3%, n=7), with no significant differences between residents and assistants (p>0,05). Reintervention rate was higher in the residents' group (38,5%, n=5 vs 10,9%, n=6, p=0,029).

**Conclusion:** To our knowledge, this is the first European study comparing the outcome of *ab externo* trabeculectomy performed by resident trainees and staff surgeons. We report significantly higher postoperative IOPs at 3-, 6- and 12-months and higher reintervention rates in the residents' group.



PP-279

**Patients' Experiences in a Glaucoma Virtual Clinic: a Qualitative Evaluation**

C C Ferreira<sup>1</sup>, P Martins<sup>1</sup>, J Fernandes<sup>1</sup>, E Saraiva<sup>1</sup>, J Sequeira<sup>1</sup>, D Meira<sup>1</sup>.

<sup>1</sup>Department of Ophthalmology, Centro Hospitalar Vila Nova de Gaia/Espinho, Vila Nova de Gaia, Portugal

**Objective:** A virtual clinic is a new model of glaucoma care service in which the ophthalmologist is removed from the face-to-face patient consultation. Implementation of virtual clinics within the hospital setting is intended to improve both patient experience and clinic capacity. In this study, we aimed to examine the experiences and perceptions of patients attending a glaucoma virtual clinic and provide guidance for future care delivery.

**Methods:** A prospective study was conducted including patients with low risk of glaucoma progression attending for the first time a glaucoma virtual clinic service. Patients were enrolled over a one-year period in a single ophthalmic center in Vila Nova de Gaia, Portugal. All patients had a previous face-to-face appointment with their consultant ophthalmologist, where informed consent was obtained. Qualitative-based research was conducted using a patient satisfaction questionnaire performed after the virtual clinic visit.

**Results:** A total of 128 patient satisfaction questionnaires were completed, with an overall response rate of 65.0%. Primary open angle glaucoma (49.2%) and ocular hypertension (26.6%) were the most prevalent diagnoses in our sample. Most responders rated the information provided about the appointment prior to attending as 'Excellent' (65,2%). Nevertheless, 25.0% stated to be unaware that they would not be seeing a doctor during their visit. Both the efficiency and quality of care during the appointment were considered 'Excellent' by most patients (74.1% and 88.4%, respectively). When questioned about how confident patients felt about attending a virtual clinic, only 5.5% reported to feel poorly confident. At the end of the questionnaire patients were asked for an open-ended commentary, in which patient-doctor relationship, previous experience of care within the hospital, level of information about the disease status, and knowledge about the virtual clinic service were found to be important factors for acceptance of this model of care. Greater efficiency and less waiting times at the appointment were pointed by patients as strengths of the virtual clinic.

**Conclusion:** Our findings suggest that high levels of satisfaction can be achieved in patients attending a glaucoma virtual clinic. Acceptance to move to this form of care delivery appears to be improved by effective doctor-patient communication, including reassurance about disease status and information on the virtual clinic service.

## PP-280

### Comparative Profile Of Early Vs. Late Onset Primary Angle Closure Glaucoma: A Pilot Study At Tertiary Care Centre Of North India

S Gupta<sup>1</sup>, S Sapkal<sup>1</sup>, S Yadav<sup>1</sup>, K Mahalingam<sup>1</sup>, V Gupta<sup>1</sup>, T Dada<sup>1</sup>.

<sup>1</sup>R P Centre of Ophthalmic Sciences, AIIMS Delhi, New Delhi, India

**Objective:** This prospective observational pilot study aimed at comparing the etiology and clinical profile of early (18-40year) with late ( $\geq 50$ year) onset primary angle closure glaucoma (PACG).

**Methods:** The early and late onset PACG patients without any surgical intervention or any other pathology (leading to secondary angle closure) were enrolled. One eye of each patient was considered for analysis. Clinicodemographic details of the patients were noted. Anterior segment optical tomography (CASIA2, Tomey Corporation, Japan), Ultrasound biomicroscopy (Vumax, Sonomed, NY) were done to identify the etiopathogenesis among two groups.

**Results:** Total 76 patients, 45 in early onset (PACGY) and 31 in late onset group were included in the study. Mean age of participants were  $32.8 \pm 7.8$  years (early onset, n= 45) and  $55.83 \pm 6.7$  years (late onset, n=31). Relative pupillary block (90.32%, n=28) was the commonest mechanism of angle closure in late onset group while non pupillary block [66.67% n=31] was the commonest mechanism in early onset group with [44.44% pseudoplateau iris (n=20), 24.44% plateau iris (n=11)]. The early onset group had significantly shorter axial length ( $22.1 \pm 1.1$  vs  $22.93 \pm 1$  p=0.003), thinner lens ( $4.35 \pm 0.3$  vs  $4.6 \pm 0.2$  p=0.01), More anterior relative lens position ( $0.19 \pm 0.01$  vs  $0.2 \pm 0.01$  p=0.007), lesser anterior chamber depth ( $2.1 \pm 0.3$  vs  $2.3 \pm 0.32$  p=0.01), lesser anterior chamber area ( $15 \pm 3.3$  vs  $16.7 \pm 3.4$  p=0.04), shorter temporal angle-opening distance at ( $0.08$  vs  $0.12$  p=0.03), temporal angle recess area ( $0.01$  vs  $0.03$  p=0.03), temporal trabecular iris space area ( $0.01$  vs  $0.03$  p=0.03) at  $250 \mu\text{m}$  from scleral spur compared to late onset group. Early onset PACG had greater lens vault ( $0.79 \pm 0.4$  vs  $0.61 \pm 0.2$  p=0.01) compared to late onset PACG. In early onset PACG 15.55%, n=7 (versus none in late onset PACG) had nanophthalmos.

**Conclusion:** Non pupillary block mechanisms are more common in early onset PACG as compared to late onset PACG. Despite thinner lens, the early onset group has greater lens vault and more angle crowding.

PP-281

**Glaucoma screening in family members of glaucoma patients in eastern region of Nepal**R Bhandari<sup>1</sup>.<sup>1</sup>*Glaucoma, Dhangadhi Netralaya, Dhangadhi, Nepal*

**Objective:** The objective of the study was to determine the prevalence of glaucoma in first degree relatives of Primary open angle glaucoma (POAG) and Primary angle closure glaucoma (PACG) patients. The awareness of glaucoma among the first degree relatives was also assessed.

**Methods:** A hospital based cross sectional study designed to examine and diagnose glaucoma among first degree relatives of patients with POAG and PACG, attending the outpatient department at Ramlal Golchha Eye Hospital in the Eastern region of Nepal from June 2016 to May 2017. A comprehensive eye examination was conducted by a glaucoma specialist at the hospital.

**Results:** Two hundred and twenty-seven first degree relatives of 72 patients were invited for the examination. Out of 227 individuals, 143 (males 61%, females 39%) attended the hospital for glaucoma screening. A total of 23 (16%) individuals were diagnosed with glaucoma, 10 (43.47%) as POAG and 13 (56.52%) as PACG. Among the first degree relatives diagnosed with glaucoma, 78.3% were unaware of glaucoma.

**Conclusion:** The prevalence of glaucoma is higher among first degree relatives of glaucoma patients. Promoting awareness on glaucoma and the timely screening of family members can lead to early detection and prevention of blindness from the disease.

PP-282

**Topical Treatment of Elevated Intraocular Pressure in Patients with Graves' Orbitopathy**M S Nowak, M Guminska<sup>1</sup>.<sup>1</sup>*Ophthalmology, Contact-Med Eye Clinic, Lodz, Poland*

**Objective:** In this study, we evaluated the efficacy of topical hypotensive treatment and/or systemic corticosteroids therapy in patients with elevated intraocular pressure and Graves' orbitopathy (GO).

**Methods:** 172 eyes in 86 individuals with duration of GO  $\geq$  3 months, intraocular pressure in either eye  $\geq$  25.0 mmHg and GO ranked  $\geq$  3 at least in one eye in modified CAS form, were included. The study subjects were divided into three treatment subgroups: subgroup I was administered latanoprost QD; subgroup II was administered a combined preparation of brimonidine and timolol BID; subgroup III was the control group, not receiving any topical hypotensive treatment. All the study participants received systemic treatment – intravenous corticosteroid therapy at the same dose, according to the EUGOGO guideline

**Results:** On the final visit, the mean IOP value was significantly lower in all treatment subgroups comparing to the initial values. In both subgroups receiving topical treatment the IOP reduction was higher than in the control group receiving systemic corticosteroids only. However, the latanoprost eye drops decreased intraocular pressure more effectively than drops containing brimonidine and timolol.

**Conclusion:** Topical ocular hypotensive treatment is effective in reducing intraocular pressure in GO and decreases intraocular pressure more effectively than systemic corticosteroid therapy alone.

PP-283

## The Structure Changes of Neurosensory Retina and Macular Function in Patients with Glaucoma after The Binocular Virtual Reality

Y Lu<sup>1</sup>.

<sup>1</sup>Ophthalmology, Beijing Shijitan Hospital, Capital Medical University, Beijing, People's Republic of China

**Objective:** To explore the effect of binocular virtual reality (VR) visual training on neurosensory retinal structures and macular function in patients with glaucoma.

**Methods:** A total of 51 eyes of 27 glaucoma patients with stable intraocular pressures were trained by the binocular virtual reality training for 3 months. The thickness of peripapillary retinal nerve fiber layer (pRNFL) and the macular ganglion cell layer-inner plexiform layer (mGCIPL) and the mean macular sensitivity (mMS) were evaluated before and after training for 3 months. By dividing the patients into groups according to the visual field index (VFI), mean defect (MD) values and ages, the effects of the binocular virtual reality visual training under different influence factors were analyzed.

**Results:** The mean age of the subjects was  $49.2 \pm 13.3$  years old, the median visual acuity was 1.0, the mean IOP was  $15.29 \pm 2.66$  mmHg, the mean VFI was  $71.57 \pm 27.51\%$ , and the mean MD value was  $-11.00 \pm 9.81$ dB. After the binocular VR training for 3 months, the mean value of cpRNFL average was increased by  $0.63 \pm 3.65 \mu\text{m}$  ( $Z=-0.642$ ,  $P=0.521$ ), the mean value of mGCIPL average was increased by  $0.57 \pm 2.12 \mu\text{m}$  ( $t=1.916$ ,  $P=0.061$ ), the mean value of mGCIPL minimum was increased by  $1.31 \pm 5.46 \mu\text{m}$  ( $Z=-1.428$ ,  $P=0.153$ ), and the mMS was increased by  $0.88 \pm 3.65$ dB ( $Z=-2.259$ ,  $P<0.05$ ). In the group with  $VFI \geq 80\%$  (28 eyes), the mean mMS global increased by  $1.20 \pm 3.20$ dB ( $Z=2.163$ ,  $P<0.05$ ) after binocular vision training for 3 months. In the group with  $VFI < 50\%$  (11 eyes), the mean mGCIPLT average and mMS global were increased by  $1.36 \pm 1.86 \mu\text{m}$  ( $Z=-2.023$ ,  $P<0.05$ ) and  $2.21 \pm 2.94$ dB ( $Z=-2.312$ ,  $P<0.05$ ) respectively after training. While in the group with  $MD > -6.00$ dB (20 eyes), the mean mMS global increased by  $1.45 \pm 3.46$ dB ( $Z=-2.371$ ,  $P<0.05$ ), and in the group with  $MD < -12.00$ dB (19 eyes), the mean mGCIPLT average increased by  $1.00 \pm 1.49 \mu\text{m}$  ( $Z=-2.692$ ,  $P<0.05$ ) after the binocular VR training for 3 months. The mean mGCIPLT average and the mean mGCIPLT minimum in the young group ( $< 45$  years old,  $n=20$ ) increased by  $1.70 \pm 2.60 \mu\text{m}$  ( $Z=2.834$ ,  $P<0.05$ ) and  $3.50 \pm 7.83$  ( $Z=-2.781$ ,  $P<0.05$ ) respectively.

**Conclusion:** The binocular VR training can significantly improve the function of macular fovea. In the patients with younger age and severe visual field injury, the inner structure of retina changed obviously after visual training.

PP-284

**Secondary Glaucoma with Vitreous Opacity in two siblings**J Liu<sup>1</sup>, C Liang<sup>1</sup>, J Huang<sup>1</sup>, J Huang<sup>1</sup>.

<sup>1</sup>State Key Laboratory of Ophthalmology, Zhongshan Ophthalmic Center, Sun Yat-sen University, Guangdong Provincial Key Laboratory of Ophthalmology and Visual Science, Guangdong Provincial Clinical Research Center for Ocular Diseases, Guangzhou, People's Republic of China

**Objective:** To present a case of familial amyloid polyneuropathy in two siblings with systemic involvement. Ocular features included bilateral secondary glaucoma with vitreous opacities.

**Methods:** For these two sisters, all previous data was reviewed, and the measurement of best-corrected visual acuity, intraocular pressure, gonioscope, B-scan ultrasound and visual fields as well as slitlamp and ocular fundus examinations were conducted and compared.

**Results:** These two siblings presented bilateral vision reduction with eye pain and redness, had a past ophthalmic history of bilateral vitreous opacity and had vitrectomies in both eyes. The oldest sister was diagnosed with ATTR(transthyretin) amyloidosis in 2018. Her best-corrected visual acuity was 0.4 in the right eye, and the light perception in the left eye was inaccurate. The intraocular pressure in both eyes was about 20mmHg(after LASIK). B-scan ultrasound showed vitreous opacity. The cup disc ratio was 0.5 for the right eye and 0.9 for the left eye.

The younger sister suffered from severe vomiting during pregnancy and had a miscarriage due to placental abruption; and she had glomerulonephritis when she was a child. In physical examination, her best-corrected visual acuity was 0.4 in the right eye and 0.3 in the left eye. The intraocular pressure was 46mmHg in the right and 44mmHg in the left eye. Wool-like opacity was noted in the vitreous in both eyes, and the cup disc ratio was 0.9 in both eyes.

For family history, her father and her paternal aunt had very poor vision. Her father died at the age of 40 due to stomach disease (gastroparesis suspected). A heterozygous pathogenic mutation of c.191T>C (p.Phe64Ser) was detected in exon 2 of TTR gene, which is capable of producing amyloidosis. Bilateral trabeculectomy with mitomycin C augmentation was performed for the patient. One week after the surgery, the intraocular pressure was under good control, with the eye pain significantly relieved.

**Conclusion:** We have presented a case of glaucoma secondary to amyloidosis in two siblings which is a hereditary condition caused by amyloid deposition. Systemic and ocular presentations such as vitreous opacity and secondary glaucoma could be found in the patient with amyloidosis. For glaucoma patients with systemic symptoms, more attention should be paid to investigating the underlying causes. Meanwhile, it is also vital to ask carefully about family history when we write a case report.

PP-285

**Frequency-doubled Nd: YAG Laser Trabeculoplasty as an adjuvant therapy for open angle glaucomas**S Nadeem.

**Objective:** The *thermal* frequency doubled Nd: YAG laser has been used scantily for trabeculoplasty. Our objective was to assess the efficacy and safety of single/multiple session frequency doubled Nd: YAG laser trabeculoplasty as adjuvant therapy with anti-glaucoma drugs for open angle glaucomas.

**Methods:** 41 eyes of 22 adults with open angle glaucomas were treated with single/multiple sessions of 180° /360° of laser trabeculoplasty using the thermal frequency doubled Nd:YAG (Neodymium: yttrium-aluminum-garnet) laser [Nidek GYC-500° 532 nm (green)][50 µm spot size, 0.1 second duration, and power range of 450-1000 mW (average 761 mW)]. The patients were observed for intraocular pressure (IOP) reduction, control and complications at 1 hour, 1 week, and then monthly for 1 year, to assess the effect of laser.

**Results:** Primary open angle glaucoma was the predominant diagnosis in 31 (75.6 %) eyes. The mean pre-laser baseline IOP was  $18.87 \pm 3.66$  mmHg. The mean IOP at Week 1 was  $14.9 \pm 2.54$  mmHg ( $p=0.000$ ), at Month 1, it was  $14.65 \pm 2.50$  mmHg ( $p=0.000$ ), at Month 3;  $14.53 \pm 2.60$  mmHg ( $p=0.000$ ), at Month 6, it was  $15.85 \pm 2.30$  mmHg ( $p=0.000$ ), and at Month 12 was  $15.14 \pm 2.17$  mmHg ( $p=0.000$ ). A significant percent reduction of IOP at 1, 3, 6 and 12 months was achieved; 21.78 %, 22.48 %, 16.73 % and 18.53% respectively. The mean pre-laser topical drugs used by the patients were  $2.73 \pm 1.00$ . There was a significant reduction of medicines post-laser on all occasions, at 1, 3, 6 and 12 months, with the mean number of drugs reduced to  $2.29 \pm 0.98$ ,  $1.95 \pm 0.86$ ,  $1.83 \pm 0.77$  and  $2.05 \pm 0.92$  respectively ( $p=0.000$  on all occasions). Complications included some degree of peripheral anterior synechiae (PAS) observed in 20 (51.3%) eyes, IOP spike in 1 patient only, bilaterally (5.1%) at 1 hour after therapy, and mild anterior uveitis.

**Conclusion:** Frequency doubled Nd: YAG laser trabeculoplasty is safe and effective; in terms of IOP lowering, drug reduction and complications; when used as an adjuvant therapy in open angle glaucomas.

PP-286

**Comparative Study of Outcomes of Newly Developed Prolene Based Modified trabeculectomy And Glaucoma Shunt Surgery in NVG Patients**D Raybhadra.

**Objective:** To evaluate the outcome and usefulness (cost-benefit ratio) of a newly developed prolene based modified trabeculectomy in comparison to conventional shunt surgery for NVG patients

**Methods:** Hospital based prospective interventional study. 60 NVG patients were included, out of which 40(66.6%) undergone modified trabeculectomy and 20(33.3%) glaucoma shunt surgery during 2 years period. An 18-month follow up done at regular intervals. A multivariate prospective analysis of surgical outcomes was done in respect to the cost-benefit ratio, but it was mainly based on IOP control.

**Results:** In the follow-up, no significant difference ( $P>0.05$ ) was found in the surgical outcomes between both groups in immediate and late postoperative periods. Complete success rate 50% and qualified success rate 20% found in both groups. But the cost of shunt surgery is significantly higher ( $P<0.0001$ ).

**Conclusion:** Modified trabeculectomy may be considered as treatment option in developing countries like india in Neovascular glaucoma patients with comparable outcome benefits.



PP-287

**Amniotic membrane-umbilical cord (AM-UC) grafts reflecting new rays towards Glaucoma shunt surgery**

D Raybhadra, A Paul<sup>1</sup>, A Mitra<sup>1</sup>, A Majumdar<sup>1</sup>.

<sup>1</sup>Ophthalmology, RIO (Regional institute of Ophthalmology) Kolkata, kolkata, India

**Objective:** To determine the safety and efficacy of amniotic membrane-umbilical cord (AM-UC) graft in Glaucoma shunt surgery for reducing glaucoma shunt tube exposure.

**Methods:** Hospital based prospective interventional study. 50 eyes of 50 patients with refractory glaucoma underwent glaucoma shunt surgery using Ahmed valve. Tubes are inserted in anterior chamber (n = 45), pars plana (n= 5). Tubes were covered with AM-UC patch grafts. AS- OCT were used to assess the patch graft stability and host tissue integration with a focus on tube exposure, graft thinning and graft-related complication.

**Results:** The average age was 50 +/- 5 years. The mean follow-up 24 +/- 3 months. Tube exposure occurred in 1 eye (2%) at 3 months. Sequential AS-OCT showed excellent host tissue integration. Early graft thinning <3 months occurred in 6 eyes (12%) and late thinning occurred in 2 eyes (4%). No evidence of graft rejection or infection was associated with AM -UC graft.

**Conclusion:** AM-UC grafts are well tolerated and its high-tensile strength, low immunogenicity and excellent host-tissue integration offer good tectonic support in glaucoma shunt surgery.

PP-288

**Bibliometric analysis of neuroprotection for glaucoma over the period 2018-2022**S Man<sup>1</sup>.<sup>1</sup>*Department of Ophthalmology, Sichuan University West China Hospital, Chengdu, People's Republic of China*

**Objective:** The term glaucoma describes a group of neurodegenerative eye diseases characterized by progressive impairment of visual function due to loss of retinal ganglion cells (RGC). Neuroprotection is a treatment strategy improving neurons and/or their environment to encourage the survival and function of the neurons, especially in environments that are deleterious to the neuronal health. Recent evidence has demonstrated that neuroprotective approaches could be a promising strategy for protecting against glaucoma. We aimed to evaluate the global scientific output of research of neuroprotection for glaucoma and explore the hotspots and frontiers from 2018 Janu to 2022 April, by bibliometric analysis.

**Methods:** Data were taken from the Web of Science (WoS) website. We applied the bibliometric analysis software Citespace to generate and analyze visual representations of the complex data input, including number of publications, research performances in journals, authors, institutions, countries and co-occurrence networks of keywords and co-citation references.

**Results:** A total of 277 references were obtained, and the total number of publications continually increased over the investigated period. Most of the articles were written by American researchers, and the number of literature published by Chinese researchers was ranked the second. INVESTIGATIVE OPHTHALMOLOGY & VISUAL SCIENCE contained 22 papers, ranked No. 1 with the most articles related to neuroprotection for glaucoma, indicating that they were important platforms for related research. Calkins DJ and David Calkins are the authors with the highest number of publications related to neuroprotection for glaucoma, and it is noteworthy that these 2 authors have close cooperation in this field. The institutions with the most publications are Harvard Med Sch. The results of cluster analysis showed that subject terms were mainly grouped in 8 categories, which were retinal ganglion cells, intraocular pressure, induced pluripotent stem cells, gene therapy, optic nerve crush, neuroinflammation, n-methyl-d-aspartate receptor, primary open-angle glaucoma and hyaluronic acid. Williams P' 2017 study published in SCIENCE was cited for 14 times showing it is important in this field.

**Conclusion:** This study provides an insight into neuroprotection for glaucoma by bibliometric analysis, which may support valuable information for researchers to identify hot topics and explore research frontiers in this field.

PP-289

**NEUROPROTECTIVE TREATMENT OF PATIENTS WITH PRIMARY OPEN-ANGLE GLAUCOMA**D Tuychibaeva<sup>1</sup>, N Yangieva.<sup>1</sup>*Ophthalmology, Tashkent state dental institute, Tashkent, Uzbekistan*

**Objective:** Investigation of neuro-protective efficacy of complex treatment combined with Ronocite in primary open angle glaucoma (POAG) with normal intraocular pressure (IOP) level basing on clinical and functional evaluation of visual organs indices.

**Methods:** Sixty patients aged  $60,75 \pm 12,83$  years, on the average, with POAG at I,II,III stages have been examined by us. All the patients were subdivided into 2 groups: main and control ones. The control group included 28 patients (47 eyes), they were treated by traditional methods. The main group (32 patient 58 eyes) was treated by the traditional therapy combined with Ronocite. All patients underwent: visometry with the best correction, biomicroscopy, gonioscopy, computer perimeter on Humphrey vision field analyzer (HFA II 740), tonography, examination of the fundus with a VOLK lens, optical coherence tomography (OCT).

**Results:** Treatment of patients with POAG by the recommended scheme has demonstrated reliable improvement in visual acuity to 0,08-0,2, being 4 times higher if compared to that by the traditional therapy. The patients of the main group with POAG shaved reliable improvement of CFFPD indices: to 14,5% at I stage, to 13,9% - II stage, and in the control group to 2,7 and 2,4%, on the average, respectively. Rinocite provides more marked neuro-protective effect in POAG by rendering the nerve tissue effective deference and delaying the apoptosis.

**Conclusion:** Analysis of the obtained results indicated the high enough clinical effect of Ronocite (citicolinum) used for the conservative treatment of patients with the POAG with compensative IOP. Along with the improvement of clinical and functional indices of the visual organs, we have noted improvement of the general state, attention and working ability of the patients too.

**PP-290****Outcome of tube shunt surgeries in patients with Secondary Glaucoma in Iridocorneal Endothelial Syndrome.**

A Paul, T Ray Bhadra<sup>1</sup>.

<sup>1</sup>*Ophthalmology, Regional Institute of Ophthalmology, Kolkata, Kolkata, India*

**Objective:** To evaluate efficacy of tube shunt surgery in patients with Secondary Glaucoma in a rare disease of ICE Syndrome.

**Methods:** It is a Hospital based prospective interventional study. Monitoring of IOP with Visual Acuity was done in 6 eyes of 6 patients. Close evaluation of corneal endothelium was also done. Complete Success is defined as IOP  $\leq$  21 mm Hg without using any anti glaucoma medications, Qualified success rate is defined as  $\leq$  21 mm Hg and failure was defined as IOP  $\leq$  6 or  $\geq$  21 mm Hg.

**Results:** Patients were at first started with Anti glaucoma medications and in regular follow up raised IOP with corneal oedema with dimness of vision were noted. Tube shunt surgeries were performed and follow up of 2 years showed Complete success rate of 80% and Qualitative success rate of 10% and failure rate of 10%.

**Conclusion:** When medical therapy is unsuccessful in controlling IOP, surgical therapy with filtering procedure are done. Use of Anti fibrotic agents with trabeculectomy surgeries still have high risk of failure. Tube shunt surgeries is reasonably successful in controlling IOP with minimal corneal complications.

## PP-291

**Combined treatment with  $\alpha$  - tocotrienol and sunitinib has synergistic effects to inhibit TGF- $\beta$  1-induced HTFs fibrosis**

Y Zhao<sup>1</sup>, X Duan<sup>2</sup>.

<sup>1</sup>Glaucoma, Aier Eye Hospital, <sup>2</sup>Glaucoma, Changsha Aier Eye Hospital, Changsha, People's Republic of China

**Objective:** Sunitinib, a multi-targeted tyrosine kinase inhibitor, as efficient anti-angiogenesis agents, have been applied in the cancer treatment. The present study aims to determine whether low-dose sunitinib combined with  $\alpha$  - tocotrienol reduces side effects and maintains the anti-proliferative effects on HTFs.

**Methods:** Human Tenon's capsule fibroblasts (HTFs) were treated with 10ng/ml TGF- $\beta$  to compare the function of anti-proliferation and anti-fibrosis effects of drug treatments, such as mitomycin C (MMC), sunitinib,  $\alpha$  -tocotrienol, sunitinib or MMC combined with  $\alpha$  -tocotrienol. To mimic the effect of short-term administration of drug, the treatment length of each group was 5 minutes. At 12-hours, 1-, 2-, 3-, and 4- days after drug treatment, observe the cell morphology to evaluate the toxicity of the drug on HTFs; MTT measures the proliferation and cell viability; LDH kit detects the drug toxicity; Flow cytometry detects cell Annexin V/PI double staining to determine the level of apoptosis; Western Blot detects apoptosis-related proteins (caspase-3, -9 and PARP) and fibrosis-related proteins ( $\alpha$  -SMA, Col-1) ) expression level.

**Results:** Compared with  $\alpha$  -tocotrienol and sunitinib, MMC shows a strong anti-proliferative function with irreversible pro-apoptotic effect in the early stage of HTFs differentiation.  $\alpha$  -tocotrienol regulates the activity of cell lysosomes and has a reversible inhibitory effect on HTFs proliferation. Sunitinib also has the effect of inhibiting cell proliferation. In the combination of  $\alpha$  -tocotrienol and MMC drugs, the living cells were significantly increased. In the combination of  $\alpha$  -tocotrienol and sunitinib, the ability to resist cell proliferation is enhanced.  $\alpha$  -tocotrienol, sunitinib, and MMC all have anti-fibrosis effects. Treated with sunitinib, in TGF- $\beta$  induced HTFs Western Blot results showed that: sunitinib activates caspase-3, -9 and PARP cleavage, and down-regulates the expression of Bcl-xL and Bax proteins, suggesting that the apoptosis induced by sunitinib is mediated through the mitochondrial pathway. In addition, the results also showed that the expression of extracellular matrix proteins such as  $\alpha$  -smooth muscle actin and type I collagen decreased, suggesting that sunitinib inhibits TGF - $\beta$  -induced cell fibrosis.

**Conclusion:** Alone or in combination, the use of  $\alpha$  -tocopherol and sunitinib is more safer than MMC. By suppressing the cytotoxic effects of other antifibrotic agents, a-tocopherol is a promising drug for improving the effects of sunitinib.

PP-292

**Frequency of Strabismus after Tube Shunt Surgery in the Adult versus Pediatric Populations**M Guzman Aparicio<sup>1,2</sup>, T *Chen*<sup>1,2</sup>.<sup>1</sup>Harvard Medical School, <sup>2</sup>Department of Ophthalmology, Glaucoma Service, Massachusetts Eye and Ear Infirmary, Boston, United States**Objective:** To determine the frequency of strabismus after tube surgery in adults versus pediatric patients.**Methods:** A chart review of Ahmed (New World Medical) and Baerveldt (Abbott Medical Optics, Inc.) surgeries performed by a single surgeon (TCC) from September 1998 to September 2021. Pediatric patients were younger than 18 years of age at the time of surgery. Patients were excluded if they had less than 6 months of follow-up data.**Results:** There were 371 tube surgeries in 344 eyes of 322 patients. Of these 371 procedures, 230 procedures of 216 eyes of 196 patients met the inclusion criteria. Twenty patients had bilateral procedures. Of the 216 eyes, 203 eyes had 1 tube, 12 eyes had 2 tubes, and 1 eye had 3 tubes. Of these 196 patients, 163 (83.2%) were adults and 33 (16.8%) were pediatric. Of the 33 pediatric patients, 3 eyes of 3 patients (9.1%) had new-onset strabismus after tube surgery at last follow-up, compared to 0 adults (p-value = <0.01).**Conclusion:** Compared to adults, pediatric patients have more issues with strabismus after tube shunt surgery.

PP-293

## 24-MONTH OUTCOMES OF MODIFIED GONIOSCOPY-ASSISTED TRANSLUMINAL TRABECULOTOMY FOR CONGENITAL GLAUCOMA

M Lemos, M Cunha<sup>1</sup>, B Faria<sup>2</sup>, F Daga<sup>3</sup>, A Scoralick<sup>1</sup>, F Kanadani<sup>1</sup>, T Prata<sup>1,3</sup>.

<sup>1</sup>*Glaucoma Instituto, Belo Horizonte, São Paulo*, <sup>2</sup>*Glaucoma, The Federal University of Rio Grande do Norte, Natal*,

<sup>3</sup>*The Federal University of São Paulo - UNIFESP, São Paulo, Brazil*

**Objective:** To report a case series of primary congenital glaucoma (PCG) patients submitted to modified gonioscopy-assisted transluminal trabeculotomy (GATT) surgery.

**Methods:** This is a retrospective case series about 9 eyes with PCG. Modified GATT was performed in all eyes by the same surgeon along 24 months. The data collected, before and after treatment, were intraocular pressure (IOP), postoperative complications, such as hyphema and number of eye drops. We also evaluated the extension of treatment, which means the number of quadrants GATT were performed. The IOP values before and after modified GATT, were compared with a paired T-test, with a 95% confidence interval.

**Results:** 9 eyes of different patients with PCG underwent modified GATT surgery with a follow-up of 24 months. Surgical interventions were performed on patients aged since 3 months to 10 years (mean 3.9 years). Only 2 patients (22.23%) had not previously been submitted to trabeculotomy and/or goniotomy surgery. GATT was performed in all quadrants in 8 of 9 eyes (88.89%), while 1 eye had only 1 quadrant (90°) treated. Hyphema was a common complication found in 7 of 9 eyes (77.8%). Mean IOP before surgery were 25.89 mmHg [standard deviation (SD) = 4.26]. All patients were in use of at least 3 hypotensive drops (mean of 3.11 drops with a SD of 0.34). 8 patients were in use of 3 hypotensive drugs and 1 patient in use of 4 drugs. The mean IOP after 30 days of surgery was 11.12 mmHg (SD = 1.76), with a mean number of 1.23 hypotensive drops (SD = 0.97). The difference of the mean IOP before and after modified GATT surgery was statistically significant.

**Conclusion:** In this case series, modified GATT surgery has shown to be efficient and safe in the management of PCG. This technique was able to reduce mean IOP and hypotensive drugs in all patients of the study. Adopting a less invasive technique, achieving disease control and reducing the number of drugs, GATT surgery reached its role to improve patient's quality of life.

**PP-294****Predicting a reduction in intraocular pressure in glaucoma patients in the early period after a trabeculectomy**

W Ruixue<sup>1</sup>, C Xiaoya<sup>1</sup>.

<sup>1</sup>*The Affiliated Xuzhou Municipal Hospital of Xuzhou Medical University, Xuzhou, People's Republic of China*

**Objective:** To identify the factors associated with a reduction in intraocular pressure (IOP) in the early postoperative period after a trabeculectomy and to develop a predictive nomogram to guide clinical care.

**Methods:** This study included clinical data on 588 glaucoma patients ( $N = 588$  eyes) who underwent a trabeculectomy in our hospital between January 2016 and December 2021. There were 412 eyes in a training cohort and 176 eyes in a validation cohort. We used logistic regression analysis to evaluate whether these factors were related to a decrease in IOP in the early period postsurgery and established a predictive model by combining features selected in a univariate analysis. We used external validation for evaluation. The standard for IOP reduction was that the IOP decreased to the normal range (10–21 mmHg) 1 month after the trabeculectomy.

**Results:** Among the patients in the training cohort, 82.8% met the standard for IOP lowering. There were 11 meaningful differences among the enrolled predictors, but the logistic regression analysis only showed significant differences with anterior chamber angle closed, age, preoperative IOP, axial length, and visual field mean sensitivity (MS). The C-index of the model was 0.910 (95% confidence interval [CI]: 0.869-0.951). The C-index was 0.956 for external validation of the model.

**Conclusion:** This new nomogram can be used to predict whether the IOP will reach the standard in the early stages after a trabeculectomy. The anterior chamber angle closed, age, preoperative IOP, axial length, and visual field MS are independent risk factors.



PP-295

**IL-22/IL-22R1 promotes HTF cell proliferation and regulates fibrosis through STAT3 signaling pathway**Y Zhao<sup>1</sup>, X Duan<sup>2</sup>.<sup>1</sup>*Glaucoma, Aier Eye Hospital,* <sup>2</sup>*Glaucoma, Changsha Aier Eye Hospital, Changsha, People's Republic of China*

**Objective:** Most anti-glaucoma surgeries fail because of scarring of the filtering trace, but the mechanism remains to be elucidated. The present study investigated the mechanism by which the interleukin (IL)-22/IL-22 receptor 1 (IL-22R1) signaling pathway regulates scar formation in glaucoma patients.

**Methods:** A total of 31 glaucoma patients who had been previously treated with trabeculectomy surgery and the intraocular pressure was uncontrollable because of scarring and 19 strabismus patients as control patient group were included in the present study. ELISA was performed to measure the content of IL-22 in peripheral blood. Serum from glaucoma patients was used to incubate HTFs cells and IL-22 antibody rescued the effect of IL-22 on the biological functions of HTFs cells. Reverse transcription-quantitative PCR was performed to determine IL-22R1 mRNA expression levels and western blotting was performed to measure IL-22R1 protein expression. Flow cytometry was performed to assess the cell cycle distribution of HTFs cells and the Cell Counting Kit-8 assay was used to analyze cell proliferation.

**Results:** The IL-22 content of serum from glaucoma patients was higher than that from healthy group significantly. The result of IL-22 content showed that  $29.80 \pm 5.1$  ng/ $\mu$ l and  $5.21 \pm 0.9$  ng/ $\mu$ l respectively in patients' serum and healthy serum. After incubated with patients' serum, the proliferation and activation of HTFs cells were promoted. IL-22 mediates the biological function of HTFs cells via binding IL-22RA1 directly. When transfection of siR-IL-22RA1 or IL-22RA1 gene, the HTFs cells shown significantly anti-fibrosis or pro-fibrosis separately. By using STAT inhibitor BAY in IL-22R1 overexpression group, IL-22-induced proliferation were reduced in HTFS cells.

**Conclusion:** The present study suggested that IL-22 expression in glaucoma patient after surgery. The present study indicated that the IL-22/IL-22R1 signaling pathway promoted fibroblasts cell proliferation and  $\alpha$ -SMA by activating the STAT3 signaling pathway, thereby potentially regulating glaucoma filtration trace fibrosis.

PP-296

## Replacing Preserved Prostaglandin Analog to Preservative-Free Tafluprost in Open-Angle Glaucoma: A Systematic Review

C Chrystelle<sup>1</sup>, S Rizki<sup>1</sup>, R Elbert<sup>1</sup>, J Irma<sup>2</sup>.

<sup>1</sup>Faculty of Medicine, <sup>2</sup>Department of Ophthalmology, Faculty of Medicine, Pelita Harapan University, Tangerang, Indonesia

**Objective:** Benzalkonium chloride (BAK) is the most common preservative used in eye drops. However, the toxic effect of BAK has been well documented on its effects on the ocular surface. Preservative-free Tafluprost is the first prostaglandin analogue approved for reducing intraocular pressure (IOP) in patients with open-angle glaucoma. This systematic review aims to evaluate the safety and efficacy of replacing preserved prostaglandin analog with preservative-free (PF) prostaglandin analog Tafluprost.

**Methods:** We systematically searched PubMed, PMC, Science Direct, Google Scholar, and Europe PMC on February 25th, 2022, using a combination of keywords associated with Open Angle Glaucoma, Preservative-free Tafluprost, and Preserved Prostaglandin Analogue about their safety and efficacy in lowering IOP. Publications included are limited to English manuscripts published in the past 10 years. Patients with open-angle glaucoma that had received preserved prostaglandin analog monotherapy prior were included. Patients with underlying diseases that may cause corneal disorders, contact lens users, and prior eye surgery were excluded. The quality of each included study was assessed using the Jadad Scale.

**Results:** We identified a total of 5 clinical trial studies involving 469 patients. Based on JADAD, 2 studies showed good quality, and 3 showed poor quality. All studies showed that replacing preserved prostaglandin analog with PF Tafluprost in open-angle glaucoma has no significant advantages in lowering IOP. However, PF Tafluprost prolonged tear break-up time (TBUT) and had fewer side effects on ocular symptoms, tear production, and eye discomfort.

**Conclusion:** Replacing preserved prostaglandin analog with PF Tafluprost in open-angle glaucoma may be considered for its advantage in fewer side effects. However, further reliable clinical trials should be conducted to confirm the result.

PP-298

**Outcomes of Early versus Delayed Trabeculotomy in Primary Congenital Glaucoma**

S Cronemberger<sup>1</sup>, A Veloso<sup>1</sup>, P Lins<sup>1</sup>, A Melo<sup>1</sup>, A Gonçalves da Silva<sup>1</sup>, L de Figueiredo Barbosa<sup>1</sup>, M Placedino Martins<sup>1</sup>.

<sup>1</sup>Ophthalmology, UFMG, Belo Horizonte, Brazil

**Objective:** The normal eye growth is roughly three times greater from birth to six months than from six to twelve months of life. Considering this, we compare in primary congenital glaucoma (PCG) the outcomes of ab-extern trabeculotomy (TROC) in children until six months (early TROC) with those aged >6 months (delayed TROC).

**Methods:** We compared intraocular pressure (IOP), horizontal corneal diameter (HCD), central corneal thickness (CCT), and axial length (AL) before TROC and at follow-up of 1, 3, 6 and 12 months in children with PCG who underwent TROC until six months' age and those who had undergone TROC after six months' age. AL was also compared with healthy age-matched eyes examined under the same conditions.

**Results:** TROC was performed in 43 children: 18 children, 33 eyes aged six months, and 25 children, 37 eyes, aged >6 months. Mean age was  $86.56 \pm 53.64$  and  $504.48 \pm 448.14$  days respectively. At 12 months, mean pre- and postoperative IOP were respectively  $15.97 \pm 4.78/16.62 \pm 4.85$  and  $9.77 \pm 2.88/10.93 \pm 4.83$  mmHg and delayed TROC was associated with abnormal AL in 31 (88.6%) out of 37 eyes, while after early TROC only 13 (41.9%) out of 33 eyes had abnormal AL (chi-square, 8.00;  $P=0.03$ ). In multivariable analysis, each 1 mmHg higher of pre-operative IOP was associated with 0.25 mmHg IOP increase at 12 months ( $P=0.04$ ). On average, delayed TROC showed 3.72 mmHg IOP higher at 12 months than early TROC (95% CI=0.44 to 6.99;  $P=0.02$ ).

**Conclusion:** Early TROC is associated with lower IOP and substantial reduced incidence of abnormally AL compared with TROC after six months' age.

PP-299

**Management of ocular hypertension following intravitreal dexamethasone implant (Ozurdex) with minimally invasive techniques**J Xiao, M Qiu.

**Objective:** Ozurdex is an intravitreal dexamethasone implant used to manage diabetic macular edema (DME), retinal vein occlusion (RVO), and uveitis. We examined ocular hypertension (OHT) following Ozurdex implant and characterized its management with minimally invasive glaucoma techniques.

**Methods:** Medical chart review following 109 intravitreal Ozurdex implants at a tertiary care academic center from 2014 – 2022. After excluding eyes with previous diagnosis of neovascular glaucoma or concurrent intravitreal administration of other steroids, 61 implants (19 patients, 23 eyes) were analyzed during the following 12-month period. OHT was defined as reaching an IOP of either  $\geq 30$  mmHg or  $\geq 10$  mmHg increase from baseline.

**Results:** Ozurdex implants were indicated for diabetic macular edema (52.5%), retinal vein occlusion (34.4%), and uveitis (13.1%). Ten (43.5%) eyes received single implant, while 13 eyes (56.5%) received multiple implants. OHT occurred in seven (11.5%) of Ozurdex implants within one year. Medical drops were initiated following eleven (18.0%) implants to control elevated IOP. Selective laser trabeculoplasty (SLT) was performed in two (3.3%) cases. Surgical procedures were utilized in four (6.6%) cases, specifically two (3.3%) instances with Kahook Dual Blade goniotomy and two instances (3.3%) with gonioscopy-assisted transluminal trabeculotomy.

**Conclusion:** Associated OHT following Ozurdex implantation can be managed with several modalities. Historically, eyes refractory to medical therapy received trabeculectomy or shunt. In addition to conservative medical therapy, here we demonstrate that SLT or minimally-invasive angle surgery may prove effective and/or delay interventions that are traditionally associated with greater risk.

PP-300

**Publication and Outcome Reporting Bias Based on The Registration Status in Glaucoma Surgical Trials: A Systematic Review**R Michael<sup>1</sup>, A Toren<sup>2</sup>, L Cape<sup>1</sup>.<sup>1</sup>Université Laval, Québec, Canada, <sup>2</sup>Ophthalmology Department, Université Laval, Québec, Canada

**Objective:** Despite the optimum of quality evidence randomized controlled trials (RCTs) provide, biases may be introduced and hinder their application. The primary objective of this study is to investigate outcome reporting bias and publication bias in RCTs investigating the surgical treatment of glaucoma.

**Methods:** A literature review was conducted in MEDLINE, EMBASE and CENTRAL databases. Inclusion criteria included RCTs published in English between 2007 and 2021 that focused on the surgical treatment of patients of all ages with glaucoma or elevated intraocular pressure. Exclusion criteria included cadaveric and animal studies. Studies quality was assessed based on the Jadad score.

**Results:** 7,561 citations were screened after deleting duplicates. 161 RCTs were eligible and included between 13 and 556 participants. 91% of them studied an adult population suffering predominantly from primary open-angle glaucoma (71%). Among included studies, 63% were not registered and 47% had statistically significant results. An upward correlation in registration was observed with time. However, 37% of the studies showed discrepancies between objectives in clinical trial registries and the published results. Risk factors for studies at higher risk of bias will be identified in further statistical analyses.

**Conclusion:** Recording of RCTs is essential to ensure greater transparency and appropriate interpretation in the surgical management of patients with glaucoma. It would allow assessment of the quality, internal validity and external validity of the studies and help guide clinical decisions for a better care.

## PP-301

**Assessment of eye drop instillation techniques among patients with primary open angle glaucoma in a Nigerian tertiary hospital.**

O Sam-Oyerinde<sup>1</sup>, O Onyekwelu<sup>2</sup>, K Musa<sup>3</sup>, O Aribaba<sup>3</sup>, I Ayo<sup>3</sup>, S Agboola<sup>3</sup>, O Idowu<sup>4</sup>, A Adenekan<sup>3</sup>, F Akinsola<sup>1</sup>.

<sup>1</sup>Ophthalmology, Guinness Eye Centre, Lagos University Teaching Hospital, Lagos, Nigeria, <sup>2</sup>Ophthalmology, Hywel Dda University Health board, Wales, United Kingdom, <sup>3</sup>Ophthalmology, Guinness Eye Centre, Lagos University Teaching Hospital, Lagos, Nigeria, <sup>4</sup>Ophthalmology, University of California San Francisco, San Francisco, United States

**Objective:** To assess the technique of eye drop instillation and its determinants among patients with primary open angle glaucoma (POAG) attending a Nigerian tertiary hospital.

**Methods:** This study was a cross-sectional observational study conducted among 130 participants. Systematic sampling technique was used. Inclusion criteria were the presence of POAG, in individuals  $\geq 18$  years, and self-instilling their ocular hypotensive medications for at least 6 months. Demographic data and clinical characteristics were obtained using an interviewer-administered questionnaire and clinical examination. All participants underwent eye drop instillation of sterile water. Administration techniques were observed and graded using a comprehensive grading scheme. Patients with poor techniques were educated. Determinants of poor eye drop administration technique were also explored.

**Results:** One hundred and thirty patients with POAG were studied with a female to male ratio of 1.36:1 and mean age of  $57.13 \pm 13.20$  years. Sixty three percent of the patients had poor eye drop administration technique. Previous education on instillation technique and near visual impairment were found to significantly ( $p = 0.04$  and  $0.02$  consecutively) influence instillation technique on bivariate analysis. However, on multivariate logistic regression, only previous eye drop instillation education found to influence eye drops instillation technique significantly ( $p = 0.02$ ; OR = 3.230; 95% CI = 1.173 - 8.896). Of the participants, 128 (98.5%) did not wash their hands, 29 (22%) touched the eyelids with the bottle tip, 47 (36%) touched the globe and 126 (97%) did not occlude the punctum. Among the 103 (80%) patients who self-reported no challenges using their eye drops, 66 (64%) had poor technique following an objective assessment of their instillation technique. Sequel to the training, mean score of subjects improved from  $2.8 \pm 1.1$  to  $4.1 \pm 1.3$  with  $p$  value  $< 0.001$ , paired  $t$  test.

**Conclusion:** This study demonstrated that a high proportion of POAG patients had poor eye drop instillation technique despite long-term self-use of topical medication. Thus, this aspect of therapy deserves periodic scrutiny by the clinician.

**PP-302****A Systematic Review of Quality of Life Before and After Glaucoma Surgery: How do the surgeries impact patient's life?**

C Adirespati<sup>1</sup>, M Ismail<sup>1</sup>, R Kusumahapsari<sup>1</sup>.

<sup>1</sup>Faculty of Medicine, Universitas Indonesia, Jakarta, Indonesia

**Objective:** To compare the quality of life of glaucoma patients before and after undergoing glaucoma surgery.

**Methods:** A systematic literature search was conducted on four databases, including PubMed, EuropePMC, LILACS and Cochrane Library. Studies considered in this review were the ones that evaluated adult glaucoma patient who underwent glaucoma surgery with the outcome of quality of life, compared between preoperative and postoperative state. Screening of articles were performed independently by three authors. Inclusion of studies to be reviewed were achieved through consensus. Risk of bias were assessed using Cochrane RoB 2 for RCT and Newcastle Ottawa Scale for non-RCT. Results were synthesized by tabulation and narrative texts.

**Results:** Seven studies, including 4014 patients, were reviewed. Quality of life was measured using EuroQoL-5 Dimensions five level version (EQ-5D-5L), Glaucoma Utility Index (GUI), Glaucoma Symptom Scale (GSS), Glaucoma Quality of Life-15 (GQL-15), Health Utility Index-mark 3 (HUI-3), National Eye Institute Visual Function Questionnaire 25 items (NEI-VFQ-25). Follow-up was done between 6 weeks and 36 months. Thirteen measurements of QoL were conducted across seven studies. QoL was improved in six measurements, reduced in five measurements, and was comparable in two measurements.

**Conclusion:** Patient's quality of life is influenced by glaucoma surgeries. However, current studies were still not able to show consistent results of the impact of glaucoma surgeries on quality of life. Current studies elucidate the lack of evidences that solely compare preoperative and postoperative QoL. Future researches with uniform QoL parameters are required to provide data for a meta-analysis.

## PP-304

**Three Letters Designations for the Glaucoma Medications to facilitate faster EHR Documentation**

S Vattiyam<sup>1</sup>, S Sonty<sup>1,2</sup>.

<sup>1</sup>Glaucoma, Midwest Eye Centers, Calumet City, <sup>2</sup>Glaucoma, University of Illinois @ Chicago, Chicago, United States

**Objective:** To create three letter universal drug codes to the Glaucoma Medications for faster documentation in the Electronic Health Records

**Methods:** Current mostly used Glaucoma Medications have many letters to document the full names of the Glaucoma Medications like mostly used Latanoprost (11 Letters) Dorzolamide ( 11 Letters) Brimonidine ( 11 Letters) Timolol ( 7 Letters) Acetazolamide (13 Letters) Pilocarpine ( 11 Letters) Netarsudil ( 10 Letters) Latanoprost Synod ( 16 Letters) especially the Generic Medications The Brand Medications have Less no. of Characters Azopt (5) Trusopt(7) Alphagan( - (9) Xalatan ( 7) Lumigan (7) Travatan ( 8) Rocklatan ( 9) Rhopressa ( 9) Vyzulta( 7) Xalacom (7), Duotrav( 7) Ganfort( 6 )

**Results:** In a recent 3 Months Study of a Glaucoma Practice (SS) 363 medications were prescribed to 193 Patients Latanoprost (88) Dorzolamide ( 38) Lumigan (31) Travatan (27) Timolol (23) Brimonidine ( 19) Alphagan( 15) Combigan ( 10 ) & 9 other medications (30) Three Letter designations assigned were LTP - Latanoprost ( -8 Ltrs) TTN- Travatan ( -5) LGN- Lumigan ( - 4) BMN - Brimonidine ( - 8) DZL- Dorzolamide ( - 8) TIM- Timolol ( -4 ) XTN - Xalatan ( - 4) AGN - Alphagan( -5 ) Other 3 Ltr designations were TPT- Travoprost, ZPT - Zioptan, TFT- Tafluprost, CRT - Carteolol, LBN - Levobunolol, BTM- Betimol AZT- Azopt, CST- CoSopt, TST - Trusopt RCK -Rocklatan, VYZ - Vyzilta etc. Of the 363 Medications documented saved 1632 Characters were saved. ( avg -4 Ltrs) Accumulates to 50 pts X 2 Meds ( 100x 4 = 400 Ltrs) Per month 30 X 400 = 12,000) Year 12 X 12,000 = 144,000

**Conclusion:** 1. A total of 363 Medications were prescribed to 193 pts that included 88 LTP, 38 DZL, 31 LGN, 27 TTN, 23 TIM, 19 BMN, 15 AGN, 10 CGN, 30 for 9 others. Total No.of Letters Saved 1632 for 193 Prescriptions

( Avg -4 Ltrs)

2.This Can accumulate to Avg pts per day 50X 2 = 100 x 4 Ltrs = 400 Per month 30 x 400 = 12,000 Per Year 12 X 12,000 = 144,000

3. Leads to LESS STRESS for the Physician/Technicians to document full names of the Long named Medications Accuracy can be maintained with Practice and self corrections A simplified THREE LETTER CODES may be used to document these Long Named Glaucoma Medications



PP-306

**Bedside ASOCT-assisted reattachment of severe hemorrhagic DMD after ab externo 360-degree suture trabeculotomy with trabeculectomy**S Liu<sup>1</sup>, J Wang<sup>1</sup>.<sup>1</sup>*weifang eye hospital, weifang, People's Republic of China*

**Objective:** To our knowledge, there are no reports on the management of severe hemorrhagic Descemet membrane detachment (HDD) following ab externo 360-degree suture trabeculotomy (ST). Herein, we present a case of surgical management of severe HDD after ab externo 360-degree ST combined with trabeculectomy.

**Methods:** A 60-year-old woman with advanced glucocorticoid-induced glaucoma underwent ab externo 360-degree ST with trabeculectomy in both eyes. The procedure was performed uneventfully in the left eye with well-controlled intraocular pressure. However, severe Descemet membrane detachment (DMD) and hemorrhage were observed in the right eye during the operation, and anterior segment optical coherence tomography (ASOCT) confirmed that the Descemet membrane failed to reattach on the first postoperative day because the anterior chamber (AC) bubble escaped through the ostium. The following procedures were performed: watertight suture of the scleral flap, peripheral partial thickness incision, and air injection incision in the temporal cornea with the guidance of the bedside ASOCT, gentle sliding on the cornea with a cannula to evacuate blood under the condition of a flat AC, air tamponade, and reperformance of the ASOCT to ensure that the Descemet membrane reattached completely.

**Results:** The Descemet membrane reattached completely and the cornea became clear. The patient underwent uneventful cataract surgery 3 months later and achieved visual improvement and well-controlled intraocular pressure without medication.

**Conclusion:** Severe HDD is a rare but potential complication of ab externo 360-degree ST, leading to vision impairment. Bedside ASOCT and a flat AC are helpful for placing corneal incision and confirming reattachment of Descemet membrane. A watertight flap closure is important for HDD air tamponade in the eyes with ostium.

PP-307

**Secondary Glaucoma due to Epithelial Downgrowth Post-Penetrating Ocular Trauma:  
a Rare Case Report**

G Kusumowidagdo<sup>1</sup>, C Gunawan<sup>1</sup>, N Aljufri<sup>1</sup>, A Nugroho<sup>1</sup>, A Sieman<sup>1</sup>, E Luminta<sup>1</sup>, A Witjaksono<sup>1</sup>, V Oktariana<sup>1</sup>.

<sup>1</sup>Department of Ophthalmology, Faculty of Medicine Universitas Indonesia, Jakarta, Indonesia

**Objective:** Epithelial downgrowth is a rare but aggressive complication following ocular trauma and ocular surgery. Increased intraocular pressure (IOP) could result from blockage of trabecular meshwork due to the cells and the mucin secreted as well as synechia formation. We would like to report a case of a nine-year old boy with history of penetrating ocular trauma who came to our center with elevated IOP.

**Methods:** Patient previously suffered from a penetrating trauma and had been treated with primary repair and cataract extraction. Patient was then referred for further treatment and received secondary implant. However, upon examination, IOP of left eye (LE) was still 35 mmHg and visual acuity (VA) of light perception (LP) despite maximum anti-glaucoma medications. There was microcystic edema on the cornea along with corneal leukoma extending vertically from 11 to 5-o'clock with neovascularization. Upon closer examination, there was epithelial downgrowth of these scar invading to the anterior chamber with peripheral anterior synechiae (PAS) on inferior. Iris and pupil were irregular with intraocular lens in place. Posterior segment was hard to be evaluated.

**Results:** Patient was then planned for glaucoma drainage device (GDD) implantation of LE. Post-operatively, IOP was reduced to seven mmHg without anti-glaucomatous medications.

**Conclusion:** As a conclusion, long-term effect of ocular trauma in children could be devastating due to long years ahead of their lives. Secondary glaucoma due to epithelial downgrowth post-penetrating ocular trauma is one of the complications that could occur, requiring prompt treatment. Continuous monitoring should be carried out in children post-ocular trauma.

PP-308

**SMILE Lenticule Assisted Modified Technique of Ahmed Glaucoma Valve Implantation.**

A Pandey<sup>1</sup>, R *Shah*<sup>1</sup>, B *Jariwala*<sup>1</sup>.

<sup>1</sup>*Centre for Sight, Surat, India*

**Objective:** To describe the application of a modified technique of Ahmed Glaucoma Valve (AGV) implantation surgery, to decrease surgical time, minimize the risk of complications and provide better outcomes.

**Methods:** Data of a patient implanted with AGV using the surgical technique described was analysed, retrospectively. Patient underwent AGV implantation for uncontrolled glaucoma, despite a previous trabeculectomy. Postoperatively, Intraocular pressure (IOP) measurement and ophthalmic examination were done at weekly intervals for a month, to detect complications like wound leak, conjunctival retraction, hypotony, choroidal detachment or haemorrhage.

The modified surgical technique consisted of using 2 corneal lenticules acquired from one patient who underwent Small incision lenticule extraction (SMILE) for myopia correction. These lenticules were placed over the subconjunctival part of the AGV tube in a manner to provide a triple layered covering over it.

**Results:** IOP reduced from preoperative value of 38 mm Hg to 12 mm Hg at 1 month follow up. No wound leakage, conjunctival retraction, hypotony or hypotony related posterior segment complications were noted in all the follow-ups. Patient remained comfortable and had no complains of foreign body sensation during this period.

**Conclusion:** SMILE lenticule can be a better alternative to preserved partial thickness corneal/scleral graft, conventionally used in AGV implantation to prevent tube exposure. Ease of manipulation, lack of epithelial/uveal tissue remnants, potentially lower chances of retraction, better patient comfort and cosmesis are some of the various advantages noted of using this technique.

PP-309

**Ocular manifestations of COVID 19 patients in tertiary care hospital of rural Maharashtra - A cross-sectional study**K Bhat Shah<sup>1</sup>.<sup>1</sup>Ophthalmology , JMF'S ACPM Medical College Dhule, Dhule, India

**Objective:** To study profile of ocular manifestations in recovered post COVID 19 patients and to suggest recommendations based on observations.

**Methods:** Prospective hospital-based case analysis study.

Total number of patients: 104

Study Period: April 2020 to June2021

**Results:** It was a hospital-based case analysis done at tertiary care hospital of rural north Maharashtra during period of April 2020 to June2021. We studied 104 cases of various types of ocular symptoms in patients with recent history of COVID 19 infection. Males outnumbered females in the ratio of 2:1. Diabetes mellitus is most common associated factor observed. Viral conjunctivitis was observed in 52 cases .2 cases reported subconjunctival hemorrhage. Retinal vein occlusions were seen in 3 cases. Total ophthalmoplegia with No Perception of light (PL) was seen in 23 cases & pupil sparing severe ptosis was seen in 14 cases. Orbital cellulitis with mucormycosis was documented in 12 cases. Orbital apex syndrome with an impending intracranial spread in 4 case required orbital exenteration. ENT and dental consultation were done. Peribulbar Amphotericin B was given in 3 cases and intravenous and oral antifungals also given simultaneously.

**Conclusion:** COVID 19 infection can lead to various ocular symptoms like allergic conjunctivitis to orbital mucormycosis. Early diagnosis by high degree of suspicion and prompt treatment with multidisciplinary approach is required for better visual outcome.

**PP-310****Low-intensity red light therapy in slowing the progression of myopia and the rebound effect after its cessation in myopic children**X Wang.

**Objective:** To observe the low-intensity red light (LRL) therapy in myopic children for one year and investigate the rebound effect after LRL cessation for 3 months.

**Methods:** A prospective randomized controlled clinical trial. A total of 102 myopic children aged 6 to 13 were collected in strict accordance with the inclusion and exclusion criteria, and randomized into LRL group (n=51) and single-focus spectacles (SFS) group (n=51). All participants adequate corrected their refractive error through wearing spectacles all day. 3-, 6-, 9- and 12-month follow-up visits, and the ophthalmic examination including the best-corrected visual acuity (BCVA), spherical equivalent refraction (SER) after cycloplegia, axial length (AL), subfoveal choroidal thickness (SFCT) and accommodation. After the end of the one-year control trial period, the subjects in the LRL group stopped the LRL therapy for 3 months and were examined SER, AI and SFCT.

**Results:** There were 46 cases in LRL group and 40 cases in control group completed the controlled trial. The mean changes of AL in LRL group was  $0.01 \pm 0.20$  mm, which was significantly less than  $0.39 \pm 0.19$  mm in SFS group, SER and SFCT in LRL group was  $0.05 \pm 0.47$  D and  $21.57 \pm 32.22$   $\mu$  m, which was significantly more than  $-0.64 \pm 0.42$  D and  $-11.30 \pm 18.97$   $\mu$  m in SFS group. Only accommodative response (AR) and positive relative accommodation (PRA) had crossover effect between times and groups, AR in LRL group decreased from  $0.26 \pm 0.44$  D to  $-0.01 \pm 0.23$  D, and PRA decreased from  $-1.87 \pm 0.78$  D to  $-2.34 \pm 0.77$  D. There were no side effects happened during the LRL therapy. After 3 months of LRL cessation, SER and AL increased by  $-0.20 \pm 0.19$  D and  $0.16 \pm 0.17$  mm, and SFCT decreased by  $22.67 \pm 19.27$   $\mu$  m compared with that before LRL cessation. There were no significant difference in SER, AL and SFCT between the data at 15th month and at baseline.

**Conclusion:** LRL therapy for one year can effectively control the progression of myopia in myopic children, and improve the lag of accommodation and PRA. Myopia will rebound after LRL cessation for 3 months.

PP-311

**Prevalence of dry eye disease among visual display terminal office users in Uyo, Nigeria**E Abraham<sup>1</sup>, E Jack, O Motilewa<sup>2</sup>, E Itina<sup>1</sup>.<sup>1</sup>*Ophthalmology, university of uyo teaching hospital, <sup>2</sup>Public Health, university of uyo teaching hospital, Nigeria, uyo, Nigeria*

**Objective:** Dry eye disease (DED) results from loss of tear film homeostasis. Increase use of visual display terminals (VDT) by individuals and professionals increases the risk of DED. This study is aimed to determine the prevalence of dry eye disease among office workers who use visual display terminals in Uyo, Nigeria.

**Methods:** A descriptive, cross-sectional study of VDT office workers aged 19-65 years. Multi-stage sampling technique was used to recruit participants. Self-administered IDEEL questionnaire and ocular examination was done to gather data; such data was analyzed using SPSS version 22.0

**Results:** Prevalence of dry eye disease (DED) was 5.8% (95% CI 3.44 - 8.16). Mean Schirmer's 1 was  $21.60 \pm 9.29$ mm, mean TBUT was  $9.74 \pm 2.48$ s, mean IDEEL score was  $76.15 \pm 25.47$ . There was a statistically significant association between DED and educational level 7.56(p-value 0.02), hours of visual display terminal use per day 10.72(p-value 0.013), and use of air conditioning 7.66(p-value 0.006). Multivariate regression analysis to identify predictors of dry eye was statistically significant for module 1(Symptom bother) of the dry eye questionnaire (p-value 0.01, odds ratio 12.71,), tear break up time in the left eye (p-value 0.00, odds ratio 38.67), and Schirmer 1 test in the right eye (p-value 0.00, odds ratio 30.83)`.

**Conclusion:** The prevalence of DED increases with the number of hours spent on VDT. Periodic medical and psychological evaluation of VDT users to identify office workers most at risk should be carried out by employers of labour.

PP-312

## Understanding Treatment Drivers and Unmet Needs in Ocular Surface Disease Management: Perspectives from Eyecare Professionals

S Dubois<sup>1</sup>, F Alfaro<sup>2</sup>, K Ooi<sup>3,4</sup>, J Shimazaki<sup>5</sup>, N Yokoi<sup>6</sup>, F Stapleton<sup>7</sup>, J Yuan<sup>8</sup>, H Gao<sup>9</sup>, C Wei<sup>10</sup>, P Li<sup>11</sup>, A Cooney<sup>12</sup>, C Lau<sup>13</sup>.

<sup>1</sup>Novartis Pharmaceuticals Canada Inc., Dorval, Canada, <sup>2</sup>Novartis de Colombia S.A., Santafé de Bogotá D.C., Colombia, <sup>3</sup>Save Sight Institute, Sydney Eye Hospital Campus, University of Sydney, <sup>4</sup>School of Medical Sciences, UNSW, Sydney, Australia, <sup>5</sup>Tokyo Dental College, Ichikawa General Hospital, Ichikawa, <sup>6</sup>Kyoto Prefectural University of Medicine, Kyoto, Japan, <sup>7</sup>School of Optometry and Vision Science, UNSW, Sydney, Australia, <sup>8</sup>Zhongshan Ophthalmic Center, Sun Yat-sen University, Guangzhou, <sup>9</sup>Eye Hospital of Shandong First Medical University, Jinan, <sup>10</sup>Eye Hospital, Wenzhou Medical University, Wenzhou, <sup>11</sup>Beijing Novartis Pharma Co., Ltd., Beijing, People's Republic of China, <sup>12</sup>Novartis Pharmaceuticals Australia Pty Ltd, NSW, Macquarie Park, Australia, <sup>13</sup>Novartis Pharmaceuticals Corporation, East Hanover, NJ, United States

**Objective:** Dry eye disease (DED) is a common multifactorial disease of the ocular surface characterized by a loss of homeostasis of the tear film, which can lead to corneal surface damage and declining vision, if left untreated. A group of experts were asked to identify key unmet needs in DED management and to understand the key drivers affecting decision making by eyecare professionals (ECPs) in Australia, China, and Japan.

**Methods:** Academics and DED specialists from Australia (n=2), China (n=3), and Japan (n=2) participated in a 2-week discussion via a virtual platform from October to November 2021. During this period, ECPs were asked 29 predefined questions regarding aspects of DED care including diagnosis and screening, barriers to DED treatment, treatment approaches, patient educational needs, and assessed a range of cultural, environmental, and priority factors that can influence treatment decisions.

**Results:** A perceived lack of effective treatments and barriers to access therapies prevented the patients from accessing treatment, whereas ECPs suggested that the DED treatment varied due to lack of chair time, objective disease endpoints, and understanding of the progressive nature of DED. Multiple factors influence DED treatment decisions, with severity of DED being the main factor across all regions. The most preferred treatment option for mild DED is artificial tears, although multiple personalized approaches are available for different DED types. The factors influencing DED treatment decisions were broadly classified under cultural, geographical/environmental, and ECP priorities and data showed there were mixed opinions among countries. Most of the patients appeared to follow trusted physicians' advice but usually researched online pre-/post-consultations. Patients either preferred natural remedies or short-term pharmaceutical treatments to reduce medication reliance. Dry weather affected the severity of DED symptoms, whereas air pollution or quality did not. Patients' DED symptoms relief and improvement, and referrals are considered important priorities for ECPs.

**Conclusion:** Educational needs vary among these countries; however, awareness of information including new research and therapies, and regional guidelines appear to be some of the key unmet needs for ECPs. The key treatment initiation drivers are multifactorial and influenced by severity, treatment accessibility or healthcare environment of different countries.



**PP-313****Use of Traditional Eye Treatments (TET)- An experience from Liberia, West Africa**

N Pehere.

**Objective:** To study the pattern of patients presenting to an eye clinic in Liberia, West Africa with prior history of taking traditional eye treatments.

**Methods:** This is a retrospective study of patients who had taken some form of traditional eye treatments (TET) before presenting to our clinic over a period of 2 years. Following details were noted for each patient- diagnosis, details of the TET, time gap between taking TET and presenting to us, visual acuity in the affected eye, access to eye care facility.

**Results:** Total 42 patients were included in the study (male 24, females 18). Their mean age was 47.16 years (range 18-79 years). Thirty-two patients (76.19%) lived counties which had no eye care facilities available and 10 (23.8%) patients lived in counties where an ophthalmologist was available. Following were the most common causes for seeking TET- mechanical injury (20, 47.62%), corneal ulcers (12, 28.57%), chemical injury (2, 4.76%), pterygium (2, 4.76%), retinitis pigmentosa (2, 4.76%), allergic conjunctivitis (2, 4.76%), cataract (1, 2.38%) and refractive error (1, 2.38%). The average gap between onset of eye problem and reaching our clinic was 8.6 years. Details of treatment done were available in 4 patients, which mostly included putting an extract of some tree leaves. Thirty patients (71.43%) were blind in the affected eye, 5 (11.9%) patients had best corrected visual acuity (BCVA) ranging between 20/40-20/200 and 7 (16.66%) patients had BCVA of 20/20. The cause of visual morbidity in most patients was corneal scar (30, 85.71%), cataract (3, 8.57%) and decompensated cornea (2, 5.71%). Two patients benefited from refractive correction and one patient underwent cataract surgery. Medical treatment was given for patients with active corneal ulcers (2) and allergic conjunctivitis (2).

**Conclusion:** Most of the patients taking TET were from counties with no access to eye care. This underlines importance of setting-up a good primary eye care system in these areas where patients would get at least first aid and appropriate guidance for further care. Even in counties with some eye care, there is need to spread awareness about availability of services so that patients do not fall prey to TET. Looking at the visual morbidity, there is need for public education about harmful effects of TET.

PP-315

### Practice Patterns and Needs Assessment of Ophthalmologists for Inherited Eye Disorders in Turkey

F Yaylacioglu Tuncay<sup>1,2</sup>, E Karaismailoglu<sup>3</sup>, S Ozdek<sup>4</sup>.

<sup>1</sup>Medical Biology, University of Health Sciences, Ankara, Türkiye, <sup>2</sup>National Institutes of Health, National Eye Institute, BETHESDA, United States, <sup>3</sup>Medical Informatics, University of Health Sciences, <sup>4</sup>Ophthalmology, Gazi University, Ankara, Türkiye

**Objective:** To evaluate the current practices, knowledge and needs of ophthalmologist at various clinical settings in Turkey regarding inherited eye disorders. Also, we aimed to understand the need for a subspecialty of ophthalmic genetics in a country where the rate of consanguinity and inherited eye diseases is higher.

**Methods:** A 29-question self-administered survey with branching algorithm was developed through Google forms and the survey link was sent to 2983 ophthalmologists practicing at various clinical settings in Turkey during February to June 2021. The survey assessed participants' occupational characteristics, current practices and preferences, knowledge about available diagnostic and therapeutic options, proposals to improve continuing education and healthcare services related to the inherited eye disorders.

**Results:** Four hundred and fourteen ophthalmologists (20.8%) completed the survey, 236 of which (57%) were specialist, 178 (43%) were academic faculty. Of the respondents, 107 (25.9%) were in private practice (private clinic and/or private hospital), 71 (17.1%) were practicing in state hospitals, 129 (31.2%) in research and training hospitals, and 107 (25.8%) in university-foundation hospitals. The respondents were distributed in 66 different provinces including all 7 geographical regions of Turkey. 192 (46.4%) respondents were general ophthalmologists and 222 (53.6%) were subspecialist. Only 43.2 % of ophthalmologists reported presence of medical geneticist in their facility. Majority of the respondents reported being uninformed about genetic diagnostic tests (82.4%), available genetic tests in their facility or in their province (78.5%), and which genetic diagnostic tests were covered by health insurance system (93%). Nearly 90 % of ophthalmologists thought that training after residency (continued education) was inadequate and 94 % expressed the need for a subspecialty of ophthalmic genetics.

**Conclusion:** In the current era of next-generation genetic diagnostic tests and gene therapies, practice patterns and needs of ophthalmologists were revealed for the first time in a setting of higher disease rates due to consanguinity and with fewer specialists interested in inherited eye diseases as an ophthalmologist and/or medical geneticist.

PP-316

## The Current State of Research on Teleophthalmology: A Bibliometric Analysis

D Pavlenko<sup>1</sup>.

<sup>1</sup>*Department of Ophthalmology, Bogomolets National Medical University, Kyiv, Ukraine*

**Objective:** This study aimed to investigate the current state of research on teleophthalmology publications using a bibliometric approach.

**Methods:** An advanced search with relevant keywords was performed within titles of all records using the Core Collection of Clarivate Web of Science electronic database. Only publications until 2021 were included. The "Citation Report" function was used to determine the h-index of the research topic and the number of citations. "Bibliometrix" and "Biblioshiny" (Aria, M. & Cuccurullo, C., 2017) R-packages (RStudio, PBC, Boston, MA) were utilized to perform scientific production, author, authors collaboration, and keywords analyses.

**Results:** Between 1996 and 2021, the search yielded 359 items published in 119 sources by 1,418 authors. The papers were written mostly in English language (n=346; 96.4%), and articles comprised 47.6% (n=171). There were 14 (3.9%) single-authored documents, 0.3 documents per author, and 4.0 authors per document. The collaboration index was 4.1. The annual growth rate was 5.5%, and 2021 was the most productive year (n=69; 19.2%). The most prolific journals included *Investigative Ophthalmology & Visual Science* (n=64; 17.8%), *Journal of Telemedicine and Telecare* (n=29; 8.1%), and *Telemedicine and E-Health* (n=22; 6.1%). Tennant MTS (n=16; 4.5%), Rudnisky CJ (n=12; 3.3%), and Greve MDJ (n=11; 3.1%) contributed mostly. Each of them already had at least 3 publications in 2000. The L V Prasad Eye Institute (India; n=27; 7.5%), University of Alberta (Canada; n=25; 7.0%), and University of Wisconsin (USA; n=21; 5.9%) were the most prolific institutions. The corresponding author most likely was from the USA (n=120; 39.1%), India (n=47; 15.3%), and Australia (n=22; 7.2%). "Diabetic retinopathy", "covid-19", "screening", "smartphone", and "artificial intelligence" were among the most used author keywords. The h-index of the field was 32. The total number of citations was 3,487, with average citations per document of 9.7 and average citations per year per document of 1.6.

**Conclusion:** The current study has quantitatively summarized the results of 25 years of the teleophthalmology research field and suggests its growth, especially after the COVID-19 pandemic began, interest for researchers, and collaboration between them.

PP-317

**INFRASTRUCTURE AND HUMAN RESOURCE TOWARDS RETINOPATHY OF PREMATURITY SCREENING PROGRAM IN THE REFERRAL HOSPITALS IN DAR ES SALAAM**J Youze.

**Objective:** To assess knowledge, infrastructure and human resources for retinopathy of prematurity screening at selected referral hospitals in Dar es Salaam.

**Methods:** This was a hospital based descriptive cross-sectional study that was conducted in five referral hospitals, which have neonatal units in Dar es Salaam region from July to December 2020. One hundred eighty doctors and nurses working in pediatric units were recruited. Quantitative data was collected using a questionnaire, and an observational checklist was used to check for the availability of screening equipment. Data was entered into and analyzed using Statistical package for social science software (SPSS) version 20. A p-value of <0.05 was considered significant for assessing associations.

**Results:** A total of 180 health workers, working in pediatric departments from the 5 referral hospitals in Dar es Salaam participated in this study. There were 66 (36.7%) males and 114 (63.3%) females. Half (52.2%) of participants had average knowledge about Retinopathy of prematurity. One third 59(32.8%) of participants had good knowledge, and a small proportion (15.0%) had poor knowledge.

Two hospitals had indirect ophthalmoscopes which were in good working conditions. MNH had all the required medication for ROP screening. Other hospitals had 2 or less of the required types of medications. Ophthalmologists were found in 4 hospitals. There were 17 ophthalmologists in total who are unevenly distributed with MNH having 11(64.7%) of all the ophthalmologists.

**Conclusion:** Majority of the pediatricians, pediatric residents and medical officers had good knowledge about retinopathy of prematurity screening than nurses. Apart from MNH, the other referral hospitals in Dar es Salaam have inadequate tools and medications for ROP screening. There is unequal distribution of ophthalmologists among referral hospitals which was so significant that can hinder the screening program.

PP-318

**Prospective Comparative study on Tele-Ophthalmology and Face-to-face Consultations in Patients with Chronic Visual loss**

J Wong<sup>1</sup>, M Zhu<sup>1</sup>, J Lam<sup>1</sup>, K Leung<sup>1</sup>, J Lian<sup>2</sup>, C Lam<sup>3</sup>, K Shih<sup>1</sup>, J Lai<sup>1</sup>.

<sup>1</sup>Department of Ophthalmology, The University of Hong Kong, <sup>2</sup>School of Optometry, The Hong Kong Polytechnic University, <sup>3</sup>Department of Family Medicine and Primary Care, The University of Hong Kong, Cyberport, Hong Kong, China

**Objective:** To investigate the diagnostic accuracy of tele-ophthalmology and the agreement level between tele-ophthalmology and face-to-face consultation in the diagnosis of cataracts, glaucoma and age-related macular degeneration (AMD).

**Methods:** Non-diabetic subjects, aged 40 and over, who were referred to the eye clinic of Grantham Hospital, Hong Kong for blurring of vision for three months or more were independently assessed by both tele-ophthalmology and face-to-face assessment. Agreement level between the two modalities for diagnosis and severity were compared using kappa statistic. Diagnostic accuracy of tele-ophthalmology was determined by sensitivity and specificity using the face-to-face consultation serving as the gold standard. Costs were compared by calculating the downstream costs generated by each modality in terms of investigations and treatment.

**Results:** 860 eyes from 430 patients were enrolled during the study period. Tele-ophthalmology had high agreement with face-to-face consultation. The Kappa values between the two modalities for establishing the diagnosis of cataract, glaucoma or AMD ranged from 0.79 to 0.96, while the kappa values for determining their severity ranged from 0.72 to 0.88. In terms of diagnostic accuracy, tele-ophthalmology reached a sensitivity and specificity greater than 99% for the diagnosis of AMD. There was a specificity of 99.4% but a sensitivity of 87.3% for diagnosing cataracts, and a specificity of 98.7% but a slightly lower sensitivity of 75.7% for diagnosing glaucoma. Downstream costs were similar between groups.

**Conclusion:** Tele-ophthalmology consultations are accurate and comparable to face-to-face consultations for diagnosis and grading of cataracts, glaucoma and AMD.

PP-319

## EXTRAOCULAR USE OF INTRAOCULAR LENS

C Mahatme<sup>1</sup>, R Chacko<sup>1</sup>, P Chandrakanth<sup>1</sup>, H Gosalia<sup>1</sup>.

<sup>1</sup>Aravind Eye Hospital, Coimbatore, Coimbatore, India

**Objective:** EXTRAOCULAR USE OF INTRAOCULAR LENS

•Keywords: Intraocular lens, innovation and smartphone

•Purpose: to evaluate efficacy of Anterior segment photography with intraocular lens (ASPI) to capture images of sufficient quality, to identify ocular findings, to reassess reproducibility and subjective image quality.

**Methods:** •Study design: Hospital Based Comparative study,

•Sample size : 169 Inclusion criteria : patient of any Age, Gender, with anterior segment finding randomly selected for the study who have given their consent to take anterior segment photograph,

•Exclusion criteria : patient with photophobia and patient who did not consent for the study,

•Data collection : Informed & written consent, detailed history, age, sex, visual acuity, ocular examination by a medical officer using a slit lamp bio-microscope - gold standard diagnosis, Images obtained from both slit lamp camera and ASPI were then transferred to an Ipad and given to two different medical officers each for diagnosis & grading of image quality

**Results:** •ASPI SENSITIVITY 93% SLIT LAMP CAMERA SENSITIVITY 98.5%

**Conclusion:** •ASPI is an easy DIY tool – reusable, cheap, accessible device which can be used to Diagnose/ Screen ophthalmic findings at setups like remote clinics, hospitals, camps, PHC's having no access to slitlamps. This device gives near best results compared to slit lamp which can lead to early diagnosis and treatment of various diseases.

PP-320

**An Enhanced mobile web service based interactive system for effective diagnosis and management of Uveitis patients**T Pradeep, V Beekanhalli<sup>1</sup>, A Bhandary<sup>2</sup>.<sup>1</sup>Information and science, Ramaiah Institute of Technology, <sup>2</sup>Ophthalmology, M.S.Ramaiah medical College, Bangalore, India

**Objective:** To design and develop an enhanced mobile web service based interactive system for effective diagnosis and management of Uveitis patients

**Methods:** Management of uveitis requires detailed past history along with an integrated systemic and ocular diagnosis to reach a clinical conclusion for individual patients based on their conditions. Such situations and the type of diagnosis can be handled with daily interactions with doctors and patients, along with the previous history of specified patient using suitable visualization platform for real time analysis. In order to tackle the above processes and management of Uveitis patients along with laboratory investigations with continuous interaction with patients for possible etiology of uveitis a mobile web service based interactive system is modeled.

**Results:** A mobile computer application was developed for Uveitis patients which aimed to address the issues of educating the uveitis patients about their disease. It included an interactive platform for real time monitoring of the patient's self-reported symptoms and signs as recorded by the clinicians. For the patients a personalized healthcare assistant is installed on the mobile device with several healthcare features such as uveitis status summaries, regular medication reminders and appointment reminders. Uveitis data were synchronized into the healthcare cloud computing service (Web server system and Web server dataset) to corroborate the monitoring system. For the Clinicians a Web page application was developed which increased the accessibility to uveitis data by either medical professionals or family members.. The application helps to document and assess the progress of the patients as uveitis requires a multi-specialty treatment and also requires long follow up. Multiple stake holders interactive system is built to connect with doctors, clinicians, family members and pharmacist The Delphi method was used to validate the application and obtain feedback from subject experts to enhance the application development.

**Conclusion:** An interactive mobile health application was developed for effective monitoring of Uveitis patients

PP-321

**Post Pandemic Boom: A surprise for Ophthalmologists**S Sarkar<sup>1</sup>, A Dey Sarkar<sup>1</sup>, S Thakur<sup>1</sup>.<sup>1</sup>Ophthalmology, Midnapore Medical College and Hospital, Midnapore, India

**Objective:** Post Pandemic Boom, a concept in the world of stock market and economics, refers to an inflation in revenue generation for a sustainable time period after pandemic, when world came to standstill with all sectors of human resources being severely affected. Health sector also suffered immensely during the pandemic by nationwide lockdown in India. In world of Ophthalmology, although all elective procedures including cataract surgeries and adequate delivery of out-patient department treatment were severely hampered during pandemic, there has been a considerable positive shift in approach towards seeking adequate health care services among masses post pandemic.

Objective: To compare statistical supremacy of patients undergoing cataract surgeries at a tertiary Eye Care Centre in Pre-Covid versus Post-Covid period.

**Methods:** It was a retrospective single-centre consecutive case series audit for the International Classification of Diseases, Tenth Revision (ICD-10) final diagnosis codes B18 and B19 encompassing cataract removal, on patients attending Ophthalmology OPD and emergency of a tertiary care centre. The study has compared the same time duration of consecutive 8 months from August'19 to March'20 (Group A) and August'20 to March'21 (Group B), only separated by nationwide lockdown due to COVID 19. All the pertinent ophthalmological parameters were recorded in details for the comparison. The official records regarding OPD attendance, indoor admission and cataract surgeries were collected from the Hospital authority and Departmental record register.

**Results:** In this study, Group A contained 29563 patients, while Group B contained 22416 patients. Average daily OPD attendance in Group A and B were 146.7 and 111.2 ( $p=0.004$ ) respectively. But average monthly cataract surgery done in these 2 groups were 88.4 and 121.6 ( $p<0.001$ ) respectively. Cataract Counselling to OT conversion rate was 47% in Group A while that in Group B was 72%. Other eye cataract surgery has increased from 21% to 39% in post-Covid era. Emergency cataract surgery rate has also increased by 78%. There was 66% increase in Lens induced glaucoma cases attending to our institution. On comparing the outcome, there has been an increase in percentage (13%) of aphakia due to increased numbers of advanced and challenging cataracts.

**Conclusion:** In view of the prevailing uncertainties due to Covid 19 situation, there has been a steep inclination to seek prompt medical and surgical care for cataract among the patients in Ophthalmology.



PP-322

**Professional quality training and ability improvement of ophthalmic nurses based on ORBIS STEER platform**B Hu<sup>1</sup>, C Liu<sup>1</sup>, X Liu<sup>1</sup>, W Jia<sup>1</sup>.

<sup>1</sup>*Affiliated Eye Hospital of Shandong University of Traditional Chinese Medicine, Jinan City, P.R.China, People's Republic of China*

**Objective:** To improve the professional quality and ability of ophthalmic nurses with scientific teaching methods, based on the ORBIS STEER project platform.

**Methods:** Through participating in ORBIS STEER project, we trained 29 ophthalmic nurses in county hospitals. We adopt the advanced teaching methods of ORBIS, such as PBL teaching method, problem list, failure model, hand-held teaching, etc. on the basis of completing the teaching syllabus, we have carried out targeted theoretical and skill training according to the needs of advanced nurses, improving the teaching quality and learning effect ; At the same time, the above methods were applied to the eye standardized training of nurses in our hospital, and the special training of flipped classroom, integrated medical care teaching ward round, "clinical special disease knowledge + operation room cooperation + symptom care + nursing routine" was carried out. The medical treatment, nursing and operation were integrated to improve the overall understanding of nurses on eye diseases, and the nursing specialty was cultivated for the development of integrated medical care mode in the hospital Talents.

**Results:** Through the development of the STEER project, the effect of "To-Teach-Is-To-Learn" has been significantly reflected. Our hospital has not only established a standardized management process for advanced nurses, with high satisfaction of advanced nurses, and successfully completed the STEER training task, but also significantly improved the teaching level and professional quality of nurses, comprehensive ability and academic influence of nursing team. The integration mode of nursing and medical team has been successfully carried out, and the sense of gain and achievement of nurses has been significantly improved, and the patient satisfaction is clear significantly improved.

**Conclusion:** STEER project has advanced training concept, scientific teaching methods, and is suitable for adults' learning and education. It can promote the standardization of ophthalmic nurses' training, the establishment of nurses' clinical comprehensive thinking ability, the improvement of nurses' comprehensive quality and specialized nursing ability, and establish standard and criterion for the cultivation of ophthalmic specialized nurses.

PP-323

**The Philippine peso bill as an alternative near visual acuity chart in Filipino eyes: a pilot study**L Briones<sup>1</sup>, J Gomez<sup>2</sup>, E Leuenberger<sup>1,2</sup>.<sup>1</sup>Ophthalmology, UERMMMCI, Quezon City, <sup>2</sup>Ophthalmology, Asian Eye Institute, Makati City, Philippines

**Objective:** This study aimed to determine if near visual acuity measurements using a Philippine peso bill are comparable to a standard Jaeger chart.

**Methods:** This is a cross-sectional study comparing the near visual acuity measurements of a Philippine peso bill and a Jaeger chart among sixty subjects. LogMAR scores from the two methods were analyzed using Wilcoxon Mann-Whitney test. The relationship of the logMAR scores between these methods was determined using Spearman rank order correlation. The Bland-Altman plot was used to determine the comparability between quantitative measurements for near visual acuity using the standard Jaeger chart (reference) and the Philippine peso bill.

**Results:** There were no significant differences in the proportion of Jaeger scores and mean logMAR equivalents between the two methods ( $p > 0.05$ ). The scatter plot diagram shows a positive upward trend with a very strong and significant correlation between logMAR scores of Jaeger chart and Philippine peso bill methods ( $r = 0.9258$ ,  $p < 0.0001$ ). With a concordance correlation coefficient of 0.9505, there is a high agreement between these two measures. The Philippine peso bill overestimates the Jaeger chart visual acuity by 0.04 logMAR units. We suspect that the contrast between the background color and the serial numbers of the peso bill may have brought about this outcome.

**Conclusion:** The Philippine peso bill may be used as an alternative measuring tool for near visual acuity. However, there is a tendency to overestimate the scores obtained using the Philippine peso bill. Future studies are recommended to validate the results in a tele-ophthalmology setting.

PP-324

**Folding Phoropter as an appropriate tool for refraction in a resource limited setting- an experience from Liberia, West Africa**

J Copeland<sup>1</sup>, N Pehere, S Marmamula<sup>2</sup>.

<sup>1</sup>Liberia Eye Center- L V Prasad Eye Institute, John F Kennedy Medical Center, Monrovia, Liberia, <sup>2</sup>Gullapalli Pratibha Rao International Center for Rural Eye Care, L V Prasad Eye Institute, Hyderabad, India

**Objective:** To compare the results of refraction using Folding Phoropter (FoFo) and retinoscopy at an eye clinic in Liberia, West Africa.

**Methods:** FoFo is a tool for objective refraction developed by the L V Prasad Eye Institute, India. We did a cross sectional study of 53 patients enrolled over a period of 3 months. An experienced vision technician (VT) performed retinoscopy and another VT did FoFo. They were masked to each other's readings. Spherical equivalent calculated from the retinoscopy reading was compared with the FoFo reading for each patient. Mean difference between the two methods was compared. Ease of use for the VT and patient was also assessed.

**Results:** Total 53 patients were included in the study. Their age ranged from 18-70 years. Data of the right eye was used for analysis for each patient. Mean spherical errors difference between retinoscopy and FoFo was -0.025 dipoters (Range: -2.8 to 4.4; SD:1.3 D). The Intra Class Correlation coefficient (ICC) was 0.80 (95% CI: 0.68-0.88). The VT found FoFo easy to use, except in some of the elderly individuals who had difficulty in understanding the procedure. In all cases FoFo gave an appropriate starting point for subjective refraction.

**Conclusion:** The FoFo reading and the SE from retinoscopy were comparable and hence FoFo can be a good starting point for subjective refraction in a setting where other methods of objective refraction like retinoscopy or autorefractometer are not available. Being inexpensive, ease of use and portability are other additional advantages. Thus in a resource limited setting, FoFo can be considered an appropriate tool for refraction, especially for places like community outreaches and school screenings.

PP-325

**Gender equity in the need and uptake of cataract surgery in a secondary and tertiary hospital-based setting**J C Reddy, A Das, J Keefe, S Prashanthi.

**Objective:** To assess the gender-based difference in the prevalence, need and uptake of cataract surgery services in a hospital based setting in southern India.

**Methods:** This cross-sectional study included 443,160 patients ( $\geq 40$  years) presenting between 2017 and 2018 with a clinical diagnosis of cataract in at least one eye were included. The data were collected using an electronic medical record system.

**Results:** Overall, 231,766 patients were diagnosed with cataract (52.30%) in at least one eye.

The overall prevalence of cataract was significantly higher in women (55.38%). A higher percentage of women presenting from rural areas and the lower socioeconomic groups had cataracts. Irrespective of geographic location the uptake of cataract surgery was high in women ( $p < 0.05$ ). Women with presenting visual acuity (PVA) worse than moderate visual impairment ( $< 6/18$ ) underwent cataract surgery in unilateral cataracts but women with bilateral cataracts irrespective of PVA, the odds of undergoing surgery were higher. Irrespective of interocular difference in PVA the odds of having a surgery were high in women with bilateral cataracts. Irrespective of geographic location cataract surgery coverage (CSC) was higher in women with unilateral cataracts compared to bilateral cataracts. Women less than 80 years had higher CSC than men.

**Conclusion:** The prevalence of cataract, the need for cataract surgery and uptake was higher in women in the younger age group, residing in rural areas, belonging to low socioeconomic conditions, associated with bilateral cataracts and presenting with moderate to severe visual impairment. Measures to decrease this gender disparity should be implemented to deliver equitable eye care.

PP-326

### Using Rapid Assessment of Avoidable Blindness (RAAB) Data and Digital Technology to Measure Reach and Meet Eye Health Needs

M *Iqbal*, D *Minnies*, Z Hussain Awan, S *Latorre Arteaga*, M *Katibeh*, E *Watts*, A *Bastawrous*.

**Objective:** To quantify the effectiveness of the first iteration of a community eye health programme to strengthen and integrate eye care services from community-level to specialised hospital services and to estimate the reach of this programme at each stage in Matiari district, Pakistan.

**Methods:** A community eye health programme was implemented in Matiari district, Sindh province, in Pakistan, led by the Sindh Institute of Ophthalmology & Allied Visual Sciences (SIOVS), Hyderabad. 'Lady Health Visitors' in Basic Health Units assisted in screening programme in health facilities for ophthalmic problems using an online referral system and Peek technology. A Rapid Assessment of Avoidable Blindness (RAAB) survey was also conducted in the same region simultaneously. Therefore, it was possible to compare the needs surfaced by the RAAB survey with the service delivered, and estimate the effectiveness of the programme to meet those needs during its first year.

**Results:** Between September 2020 and September 2021, 103,012 people were enrolled in the programme. Of them, 10,880 (10.56%) were aged over 50. Among over 50 attendees, 3597 (33.55%) were identified to have a distance visual impairment (VI, visual acuity <6/12) in the better eye. Using extrapolation of RAAB survey data, the programme successfully reached an estimated 21.47% of people (n=3,283/15,289) with uncorrected refractive errors (UREs), 17.00% (n=2,496/14,677) with cataract, and 56.10% (n=124/221) with glaucoma in this age group in this region, in addition to many younger people. Among those with UREs causing VI, 18.15% (n=596/3283) received spectacle prescriptions. Furthermore, 31.40% (n=1031/3283) of all those with cataract, and 64.51% (n=80/124) of people with glaucoma who were identified in the programme went on to attend hospital eye services.

**Conclusion:** The programme reached a high proportion of those with unmet need and connected them to services, even though the implementation phase coincided with the global pandemic of COVID-19. If this programme continues to reach people at these rates it could cover a considerable proportion of unmet need for eye care in the region. Prioritisation of spectacle provision, and appropriate hospital referral, will be important to achieve effective refractive error coverage and effective cataract surgical coverage.

PP-327

**'LEAVE NO ONE BEHIND in EYE HEALTH IMPROVEMENT in INDONESIA: From the Lens of The Fred Hollows Foundation's Support to the NTB**E Douren.

**Objective:** Ending avoidable blindness globally, requires we address gender disparities locally. Women and girls account for 55% of the world's blind & vision impaired. The reasons are complex & intertwined yet critical to understand. Indonesia ranks second globally with the highest prevalence of avoidable blindness and visual impairment. Women in Indonesia have higher cataract prevalence rates than men. Since 2012, The Fred Hollows Foundation has aligned goals and interventions to support national efforts to improve eye health services in West Nusa Tenggara (NTB). Though our partnerships & programming has increased accessibility of eye health services, challenges continue to exist in increasing women's access & uptake of services. Indonesia's government developed the Roadmap for Visual Impairment Control Program (2017–2030) which calls for joint efforts to address avoidable visual impairment. Sub-national health offices are in the process of developing local implementation plans. Against this national backdrop and the increasing inequities caused by the pandemic, the Fred Hollows Foundation & the Indonesian Ophthalmologists Association (PERDAMI) commissioned Center for Strategic & International Studies, to conduct mixed-methods research on the challenges of communities accessing eye health services in 2021 to inform national & local eye health strategies & programming.

**Methods:** The study used an intersectional framework to understand the ways that dimensions such as GAPPED+ (gender, age, place of residence, social-economic status, ethnicity & disability) may lead to increased incidence of sight impairment. The study conducted in-depth interviews and focus groups with community members, and eye health workers to understand the layered dimensions which contributed to inequality, social injustice, marginalization & discrimination.

**Results:** We will present the findings of the mixed-method research conducted in 2021 to identify the challenges and opportunities in delivering equitable eye health services amidst this ongoing pandemic. The study finds that multiple factors determine the knowledge, barriers, and agency regarding eye health issues, especially among women. The intersection between gender and other aspects demonstrates the complexity of problems experienced by women to obtain eye health.

**Conclusion:** The findings offer an opportunity to explore how eye health partners, funders, and governments might respond to worsening inequality and use it as a catalyst to shape a healthier, more equitable future.

**PP-328****Social Demographic Factors in Pediatric Cataract Diagnostics and Treatment**D Afanasyeva.

**Objective:** The aim of this study is to find out the sociodemographic factors leading to delay in pediatric cataract diagnostics and surgery in Russia.

**Methods:** A retrospective interview-based analytical study was conducted on 62 children operated for either unilateral or bilateral congenital/developmental cataracts in 2018-2021. Their caregivers were interviewed via telephone with focus on the first signs of cataract in their child and conditions they were noticed, as well as family anamnesis, age of the first presentation to a tertiary care ophthalmic hospital, reasons for possible delay of surgery, and aspects of postoperative care.

**Results:** In 19% of cases, mothers were the first who noticed visual impairment in children aged 0-3 months. However, there is still a lack of ophthalmological care in some rural areas that results in a time gap between first signs of visual impairment noticed by parents and ophthalmological examination. Healthcare workers diagnosed 58 % of cataracts during a routine eye screening for children, mostly at age of 1 y.o. (19%) or at 6-7 y.o. before school enrollment (28%).

The most common cause identified for delay of the surgery (up to 6 months) was legal paperwork. In some cases, clinical signs of cataracts allowed some delay for better simultaneous IOL implantation. Only in two cases, fear of surgery and small age were also some of the contributing factors for the delay.

In our study we revealed no effect of the mother's educational status and having of older sibs on the time of cataract recognition. This lay in contrast to reports from developing states like India and Nigeria.

The most common method for optical correction after pediatric cataract surgery and IOL implantation stays wearing eyeglasses. Nonetheless, some children do not use any optical correction due to ophthalmological comorbidities and very low postoperative vision acuity.

**Conclusion:** Eye screening for children plays a crucial role in diagnostics of pediatric cataract. The efforts should be focused on provision of the thorough ophthalmological examination to all children before three months of age.

## PP-330

**Programming and designing ophthalmic information management system with Excel VBA led by nurses**

C Liu<sup>1</sup>, H Bi<sup>1</sup>, B Hu<sup>1</sup>, H Ji<sup>2</sup>.

<sup>1</sup>Affiliated Eye Hospital of Shandong University of Traditional Chinese Medicine, <sup>2</sup>The First Affiliated Hospital of Shandong First Medical University, Jinan City, P.R.China, People's Republic of China

**Objective:** Through the independent research and development of refractive surgery information management system, to make up for the lack of information collection and data analysis function of his system in the hospital under the condition of limited interface of special equipment, strengthen the construction of nursing information, contribute to the standardization of refractive surgery information registration, and improve the work efficiency of workload statistics and data analysis.

**Methods:** Using Excel VBA programming, nurse led design, independently developed refractive surgery information management system. The basic information, diagnosis, operation position, operation mode, surgeon, assistant, nurse, operation process and other items of the patient are edited in the structured user window. The nurse directly clicks, and the entered data is automatically stored in the Excel table; the patient information list interface is designed to query the history record and modify the habits, so as to protect the Excel database data. Through VBA program coding, the refractive surgery information and workload of one key statistical analysis, to achieve efficient and overall presentation of data and charts.

**Results:** This system has run more than 4000 pieces of data, and there is no data deviation. Compared with the traditional manual work, the registration information time of refractive surgery information management system designed and developed by Excel VBA is shortened from 96s per case to 26s, and the time of monthly workload summary and statistical analysis is shortened from 120min per case to less than 1min. According to the calculation of 500 cases per month, the time can be saved as much as 660min, the work efficiency is significantly improved, and the registration of nursing information is standardized and unified. It improves the level of nursing information in the refractive operating room and realizes the paperless management of nursing information registration in the refractive operating room.

**Conclusion:** The Refractive Surgery Information Management System, which is developed by the nurse using Excel VBA programming, has a clear and simple interface, meets the actual needs of nursing, optimizes the working process, and improves the efficiency significantly.



**PP-333****Effectiveness and safety of conbercept in polypoidal choroidal vasculopathy: results from the real-world, multicenter, observation**

Y Chen, X Zhang.

**Objective:** To observe the effectiveness and safety of intravitreal conbercept in Chinese PCV patients in the real world.

**Methods:** START is a 3-year, open, non-randomized, multicenter, prospective and observational study. It was conducted from June 2018 to July 2021 at 27 clinical sites across China. Patients were treated with intravitreal conbercept injection. The primary efficacy indicators were the changes of the best corrected visual acuity (BCVA). The other efficacy indicators included the changes of OCT features, changes of indocyanine green fundus angiography features, and changes of patients' quality of life before and after treatment. Safety analysis included the changes of vital signs and laboratory indicators, as well as occurrence of adverse events and serious adverse events.

**Results:** 484 PCV patients from 27 centers across China were enrolled, and 478 patients were analyzed. There were 57.44% of the patients were male. The average age was 66.9 years old. 97.48% of the patients were Chinese Han nationality. At baseline, average BCVA was 49.8 letters; Mean number of polyps was 2.3 and 43.69% of the patients had single polyp; mean CMT was 411.9um; Patients with sharp-peaked PED, PED notch, sub-RPE ring-like lesion, double-layer sign, subretinal fluid, and intraretinal fluid accounted for 67.13%, 65.5%, 15.17%, 84.74%, 87.41% and 46.62%, respectively. At the last follow-up, the average number of intravitreal injections of conbercept was 3.3 times. 261 patients have completed the study. 26.05%, 15.13% and 39.50% of PCV patients had BCVA improvement within 5 letters, 5-10 letters and more than 10 letters, respectively. The multivariate analysis showed that the baseline BCVA and CMT were statistically significant influencing factors of the BCVA at the last visit. After treatment, the CMT and PED height decreased significantly compared with baseline ( $P < 0.05$ ). The proportion of patients with subretinal fluid decreased significantly. Adverse events occurred in 9 patients, including 3 cases of serious adverse events, and 2 of them withdrew from the study.

**Conclusion:** Conbercept was effective and safe in the treatment of PCV in China. Regular follow-up and treatment are conducive to the improvement of patients' vision and the stability of their condition.

## PP-334

**Early functional retinal damage associated with hydroxychloroquine.**

B Bajén Espuña<sup>1</sup>, R Maroto Cejudo<sup>1</sup>, C Blanco Marchite<sup>1</sup>, J García García<sup>1</sup>, S Copete Piqueras<sup>1</sup>.

<sup>1</sup>Complejo Hospitalario Universitario de Albacete, Albacete, Spain

**Objective:** To analyse the thickness of retinal layers by using spectral-domain optical coherence tomography (SD-OCT) in patients undergoing hydroxychloroquine (HCQ) therapy and with prior alterations in multifocal electroretinogram (mfERG).

**Methods:** In this transversal study, a tomographic analysis was carried out on patients with both anomalous mfERG study results and either associated risk factors or at least five years of treatment with HCQ. These tomographic images obtained with SD-OCT were automatically segmented. In addition, visual field tests and autofluorescence were also performed. The patients' eyes were divided according to the presence or absence of early mfERG alterations. p value <0.05 was considered statistically significant.

**Results:** Seventy-eight eyes of thirty-nine patients with a mean age of  $54.8 \pm 15.4$  years were included. Forty eyes presented incipient retinal toxicity in the mfERG results, with a mean duration of HCQ treatment of  $8 \pm 4.4$  years. No difference in age between groups was observed. Those patients with no damage in the mfERG secondary to HCQ showed alteration in the visual field, autofluorescence or the external retina. However, eleven patients in the mfERG-altered group had damage in the visual field, six in the autofluorescence and two in the external retina. Total retinal thickness was lower in patients with central mfERG and external ring damage. There were statistically significant differences in the following layers: Ganglion cells (external ring), internal plexiform (external ring), internal nuclear (lower), and external plexiform (lower and temporal). There were no differences in either the outer nuclear layer nor the pigment epithelium of the retina.

**Conclusion:** Early damage in the multifocal electroretinogram caused by the administration of hydroxychloroquine is accompanied by a thinning of the internal retina from very early stages, even before any tomographical changes in the external retina are described.

PP-335

**Angiopoietin-2 Signalling and Vascular Stability With Faricimab in Diabetic Macular Edema****S Fraser-Bell**<sup>1,2,3</sup>, **A Jousseaume**<sup>4</sup>, **R Maturi**<sup>5</sup>, **P Westenskow**<sup>6</sup>, **J Willis**<sup>7</sup>, **Z Haskova**<sup>7</sup>.

<sup>1</sup>The University of Sydney, <sup>2</sup>Sydney Eye Hospital, <sup>3</sup>Royal North Shore Hospital, Sydney, Australia, <sup>4</sup>Department of Ophthalmology, Charité Universitätsmedizin Berlin, Berlin, Germany, <sup>5</sup>Midwest Eye Institute, Indiana University School of Medicine, Indianapolis, United States, <sup>6</sup>Roche Pharma Research and Early Development, Roche Innovation Center, F. Hoffmann-La Roche AG, Basel, Basel-Stadt, Switzerland, <sup>7</sup>Genentech, Inc., South San Francisco, United States

**Objective:** Angiopoietin (Ang)-2 and vascular endothelial growth factor (VEGF)-A are key drivers of vascular instability in diabetic macular edema (DME). The objective of this study was to explore the impact of dual Ang-2/VEGF-A inhibition compared with anti-VEGF alone on vascular stability in DME using preclinical and phase 2/3 trial data.

**Methods:** In JR5558 mice (spontaneous choroidal neovascularisation [CNV] model), the effects of anti-Ang-2, anti-VEGF-A, both (VA2) or none/immunoglobulin G (IgG; control) on vascular stability (neovascular leakage and subretinal inflammation [Iba1+, CD11b+, CD45+]) were evaluated at 1 week (1W), 3W and 5W post treatment. In the phase 2 BOULEVARD trial (NCT02699450), the effect of faricimab, a bispecific Ang-2/VEGF-A neutralising antibody, on sustained retinal stability (SRS; achievement and maintenance [ $< 10\%$  worsening] of central subfield thickness [CST]  $\leq 325 \mu\text{m}$  to W24) was assessed. In the phase 3 YOSEMITE/RHINE trials (NCT03622580/NCT03622593), vascular stability with faricimab every 8W (Q8W) or treat-and-extend-based personalised treatment interval (PTI) dosing up to Q16W was compared with aflibercept Q8W using anatomical endpoints measured on optical coherence tomography, and the proportion of patients in the faricimab PTI arms receiving Q4W, Q8W, Q12W or Q16W dosing over time.

**Results:** In JR5558 mice, CNV lesion leakage was reduced at 1W with anti-Ang-2, anti-VEGF-A and VA2 versus controls; at 3W/5W, CNV leakage reduction was maintained with anti-Ang-2 and VA2 only. Compared with IgG, VA2 treatment reduced Iba1+, CD45+ and CD11b+ cell infiltration at 1W; at 5W, only anti-Ang-2 and VA2 reduced Iba1+ infiltration. In BOULEVARD, SRS was achieved by  $> 50\%$  of patients receiving faricimab at W16, compared with W20 for patients receiving ranibizumab. In YOSEMITE/RHINE, reductions in CST, absence of DME (CST  $< 325 \mu\text{m}$ ) and absence of intraretinal fluid through W100 favoured faricimab Q8W and PTI up to Q16W over aflibercept Q8W. In the faricimab PTI arms, anatomic improvements were achieved with most patients on extended dosing: 52% of patients achieved Q16W dosing at W52 and 76% of these patients maintained Q16W dosing without an interval reduction through W96.

**Conclusion:** Preclinical and clinical data suggest that dual inhibition of Ang-2/VEGF-A with faricimab improves vascular stability and reduces inflammation, with potential for greater anatomic outcomes and improved durability over anti-VEGF alone in patients with DME.

PP-337

**Real World Efficacy, Durability and Safety of Faricimab in Neovascular Age-Related Macular Degeneration: The TRUCKEE Study**

A Khanani<sup>1,2</sup>, T Ewing<sup>2</sup>, H Khan<sup>1,2</sup>, A Aziz<sup>1</sup>, H Khan<sup>2</sup>, H Sulahria<sup>2</sup>, O Mojumder<sup>2</sup>, A Saulebayeva<sup>2</sup>.

<sup>1</sup>University of Nevada Reno School of Medicine, <sup>2</sup>Sierra Eye Associates, Reno, United States

**Objective:** The FDA approved faricimab for the treatment of neovascular age-related macular degeneration (nAMD) in late January 2022. Current anti-VEGF agents drastically improved patient outcomes but real-world patients show decline in visual acuity due to frequent injections and high treatment burden. This study evaluates the efficacy, safety and durability of faricimab in real-world patients afflicted by nAMD.

**Methods:** Treatment-naïve patients and patients switched to faricimab from other anti-vascular endothelial growth factor (VEGF) agents are evaluated. Demographics, previous treatment interval, early treatment diabetic retinopathy study (ETDRS) visual acuity (VA), central subfield thickness (CST) and changes in pigment epithelial detachments (PED) were collected. VA, CST, and sub/intraretinal fluid (SRF/IRF) improvements are evaluated as averages. Adverse events are collected and reported.

**Results:** Data collection is currently ongoing. Thus far, 29 nAMD eyes were evaluated at baseline faricimab treatment. Mean [SEM] age is 80.23 [2.90] years. Adjusted mean baseline ETDRS and CST values are 53.55 [1.65] letters and 482.33 [12.54]  $\mu\text{m}$ , respectively. Seven patients completed at least one follow-up visit 4-7 weeks following initial injection with an average of +2 ETDRS letters and mean CST reduction of  $-98.71 \mu\text{m}$ . No adverse events have been reported.

**Conclusion:** VA and CST improvements have been noted in Phase III clinical trials, demonstrating durability of faricimab in nAMD patients. Faricimab will continue to be evaluated in real-world patients to evaluate efficacy and safety.

PP-338

**GATHER1: Subgroup analysis of baseline patient characteristics and mean growth rate in GA area**C Danzig<sup>1,2</sup>.

<sup>1</sup>Rand Eye Institute, Deerfield Beach, <sup>2</sup>Florida Atlantic University, Charles E. Schmidt School of Medicine Boca Raton, Boca Raton, United States

**Objective:** Avacincaptad pegol (ACP), a PEGylated RNA aptamer, binds to and specifically inhibits complement C5. The GATHER1 study was a prospective, randomized, double-masked, phase 2/3 trial that evaluated ACP compared to sham for the treatment of geographic atrophy (GA). Here we present subgroup analyses evaluating the impact of ACP on the mean rate of growth in GA area by pre-specified baseline characteristics.

**Methods:** The GATHER1 study enrolled 286 GA patients with disease inside and/or outside of the 1.5 mm diameter foveal area. In the original pre-specified analysis, the least squares mean change from baseline to Month 18 in square-root GA lesion area was 0.599 mm in sham-treated (n=110) patients vs 0.430 mm in avacincaptad pegol 2 mg-treated (n=67) patients (28% reduction; P<.0014). Subgroups evaluated included size of baseline GA [ $< 4$  Disc Area (DA) vs  $\geq 4$  DA]; baseline VA  $< 50$  ETDRS letters (20/100 Snellen equivalent) vs  $\geq 50$  ETDRS letters; pattern of fundus autofluorescence (FAF) at the junctional zone of GA (none/focal vs banded/diffuse); and patients from Part 1 vs Part 2 of the study.

**Results:** When comparing subgroups, the mean rate of growth in GA area from baseline in the avacincaptad pegol-treated groups was consistently lower than the sham-treated groups by baseline GA ( $<4$  DA vs  $\geq 4$  DA) and by Part 1 and Part 2. Too few patients were available to allow for a proper analysis and draw meaningful conclusions for the subgroup analyses by baseline VA ( $<50$  ETDRS letters vs  $\geq 50$  ETDRS letters) or by pattern of FAF at the junctional zone of GA (none/focal vs banded/diffuse). Similar results were observed at Month 18, although the differences in lesion growth between the treatment groups increased from Month 12 to Month 18

**Conclusion:** In a subgroup analysis of GATHER1, the mean rate of growth in GA area from Baseline in the avacincaptad pegol-treated groups was consistently lower than the sham-treated groups regardless of baseline subgroup.

PP-340

### One-year Results of Chinese Retinal Vein Occlusion Patients treated with Dexamethasone Implant 700 $\mu$ g in Chinese clinical setting

X Xu<sup>1</sup>, K Liu<sup>1</sup>, Y Cu<sup>2</sup>, M Han<sup>3</sup>, Y Chen<sup>4</sup>, W Chen<sup>5</sup>, J Min<sup>6</sup>.

<sup>1</sup>Ophthalmology, Shanghai General Hospital, Shanghai, <sup>2</sup>Ophthalmology, Qilu Hospital of Shandong University, Jinan, Jinan, <sup>3</sup>Ophthalmology, Tianjin Eye Hospital, Tianjin, <sup>4</sup>Ophthalmology, Peking Union Medical College Hospital, Beijing, <sup>5</sup>Ophthalmology, Joint Shantou International Eye Center of Shantou University and The Chinese University of Hongkong, Shantou, <sup>6</sup>Ophthalmology, AbbVie China, Shanghai, People's Republic of China

**Objective:** To evaluate the safety and efficacy of Dexamethasone Implant 700  $\mu$ g in the treatment of macular edema due to retinal vein occlusion (RVO) in treatment naïve patients in current Chinese clinical settings.

**Methods:** A 12-month, open-label, multicenter study conducted in a real-world setting that recruited 70 patients from 9 sites in China. Patients with macular edema due to RVO were treated with dexamethasone implant 700  $\mu$ g per investigator assessment. The primary efficacy endpoints were mean change from baseline in best-corrected visual acuity (BCVA) and central retinal thickness (CRT) at month 6, proportion of patients with BCVA improvement of 15 letters or more compared to baseline and BCVA average change from baseline in area under the concentration-time curve (AUC) analysis. Additionally, mean number of injections during the 12-month study and retreatment interval were also evaluated.

**Results:** 70 treatment-naïve patients with macular edema due to RVO were enrolled. The mean (standard deviation [SD]) age was 56.4 (10.6) years, 64.3% (45 patients) were branch retinal vein occlusion (BRVO) and 35.7% (25 patients) were central retinal vein occlusion (CRVO). At month 6, mean BCVA values improved 12 letters ( $p < 0.001$ ) and 7 letters ( $p = 0.039$ ) from baseline in BRVO and CRVO, respectively. The proportion of patients with a BCVA improvement of  $>15$  letters increased from 18.6% at month 1 to 32.9% at month 12. AUC for BCVA average change increased from baseline throughout the study, all increases were significant with  $p$ -values  $< 0.001$  at all visits. Mean CRT decreased from baseline at month 6 by  $-236.5 \mu\text{m}$  ( $p < 0.001$ ), although mild fluctuations were observed throughout the study, mean CRT changes from baseline were generally between  $-290.5 \mu\text{m}$  to  $-236.5 \mu\text{m}$ . The mean number of injections administered was 2.3 (range of 1 to 4 injections). The mean time to the second injection from the first was 138 days (range of 86 to 312 days).

**Conclusion:** One-year results from Yangtze study showed a clinically meaningful BCVA and CRT improvement in Chinese RVO patients with macular edema treated with dexamethasone implant 700  $\mu$ g. Mean number of injections was 2.3 throughout 12 months. No new safety signals were observed.

PP-341

**Retinal vascular morphology monitoring for progression of severity of Chronic Pulmonary Artery Hypertension - A Pilot Study**

A Iyer<sup>1</sup>, G Pillai<sup>2</sup>, N Radhakrishnan<sup>2</sup>.

<sup>1</sup>Ophthalmology, Aditya Jyot Eye Hospital, Mumbai, Mumbai, <sup>2</sup>Ophthalmology, Amrita Institute of Medical Sciences, Kochi, India

**Objective:** Retinal evaluation is the best way to study blood vessels in vivo without performing any invasive tests. This study was done to examine the microvascular system of the retina for any changes specific to chronic Pulmonary Arterial Hypertension (PAH), and to investigate morphological changes in the retinal vessels along with increasing severity of PAH, so that it can be used as a prognostic indicator of PAH / screening tool.

**Methods:** Observational Case Control Study on 25 patients who were diagnosed cases of chronic PAH, confirmed by right heart catheterisation underwent thorough ophthalmological evaluation and fundus photography. 25 age and sex matched normal also underwent the same. The fundus photos were numbered and four ophthalmologists blinded to the study were asked to examine the fundus photos and comment about AV ratio, presence or absence of arterial dilatation, venous dilatation and vessel tortuosity. The photos were then matched to the cases and controls, and statistical analysis was carried out.

**Results:** Out of 50 eyes of 25 patients in the case group, 11 eyes (44%) had an AV ratio of 3:4, 12 eyes (24%) had retinal venous dilatation, 24 eyes (48%) had retinal arterial dilatation and 26 eyes (52%) had retinal vessel tortuosity. Comparison of retinal vascular morphological changes – AV ratio, Arterial dilatation (AD), venous dilatation (VD) and vascular tortuosity between WHO FC II and III was done. The percentage of patients with higher AV ratio was higher in patients with WHO Functional Class III (83.3%) than Class II (31.6%), patients with arterial dilatation was higher in patients with WHO Functional Class III (100%) than Class II (36.8%), patients with venous dilatation was higher in patients with WHO Functional Class III (100%) than Class II (68.4%) and patients with retinal vessel tortuosity was higher in patients with WHO Functional Class III (100%) than Class II (31.6%)

**Conclusion:** From this study it can be concluded that patients with PAH have a higher arteriovenous ratio (3:4), and show the presence of retinal arterial dilatation, retinal venous dilatation and retinal vessel tortuosity, which is more predominant with the increase in the WHO functional class of PAH from Class II to Class III. This can be examined using an indirect ophthalmoscope and documented using a fundus camera so that on subsequent visits, the ophthalmologist can look for worsening of retinal vascular changes and correlate the same with increasing severity of PAH.



PP-342

## Interactions Between Diabetic Retinal Microvasculopathy and Neuronal Degeneration Assessed by Swept-Source OCT and OCT Angiography

X Zhang, B Qiu<sup>1</sup>.

<sup>1</sup>Ophthalmology, Beijing Tongren Eye Center, Beijing, People's Republic of China

**Objective:** To provide clinical evidence of the associations between retinal neuronal degeneration and microvasculopathy in diabetic retinopathy (DR).

**Methods:** This cross-sectional study included 77 patients (113 eyes) with type 2 diabetes mellitus (DM), refraction error between -3.0 and +3.0 D. The eyes were assigned into DM (without DR), non-proliferative DR (NPDR), and proliferative DR (PDR) groups. Age-, sex-, and refractive error-matched normal subjects were enrolled as controls. The Early Treatment Diabetic Retinopathy Study mean thickness of the retina (mtTR), the relative mean thickness of the retinal nerve fiber (rmtRNFL, rmtRNFL/rmtTR) layer, ganglion cell (rmtGCL) layer, ganglion cell complex (rmtGCC) layer, and the foveal avascular zone (FAZ) were assessed by swept source optical coherence tomography and OCT angiography. Group comparison and Spearman partial correlation coefficient analysis were applied to evaluate the correlation between these morphological parameters and systemic factors.

**Results:** The rmtRNFL significantly increased with the DR severity and duration of diabetes. Statistical differences were detected in the rmtRNFL thickness between the normal, DM, NPDR, and PDR groups ( $P < 0.0001$ ,  $P_{Normal/NPDR} < 0.0001$ ,  $P_{Normal/PDR} < 0.0001$ ). The rmtRNFL was significantly increased in the DM groups with a disease course of 1–10, 11–19, and  $\geq 20$  years than that in the normal control group ( $P_{Normal vs. 1-10yrs} = 0.031$ ,  $P_{Normal vs. 11-19yrs} < 0.0001$ ,  $P_{Normal vs. \geq 20yrs} < 0.0001$ ). Also, the rmtGCL decreased with the DR severity ( $P = 0.003$ ,  $P_{PDR vs. Normal} = 0.013$ ,  $P_{PDR vs. DM} < 0.0001$ ,  $P_{PDR vs. NPDR} = 0.002$ ). The FAZ area significantly increased with the DR severity ( $P < 0.0001$ ;  $P_{PDR vs. DM} = 0.0001$ ,  $P_{PDR vs. NPDR} < 0.0001$ ;  $P_{Normal vs. PDR} < 0.0001$ ). rmtRNFL and FAZ area were significantly correlated with the severity of DR after controlling the age, sex, and duration of diabetes, and hypertension ( $P_{rmtRNFL} < 0.0001$ ,  $P_{FAZ} = 0.001$ ), while rmtGCL was negatively correlated with FAZ area ( $P < 0.0001$ ).

**Conclusion:** The degree of rmtRNFL and FAZ area enlargement is correlated with the severity of DR. rmtRNFL is a stronger predictor of the progression of DR than FAZ area. The ganglion cell body loss is highly correlated with FAZ area enlargement in the progression of DR.

## PP-343

### The Efficacy And Safety of Conbercept Ophthalmic Injection For Macular Edema Secondary to Branch Retinal Vein Occlusion (BRAVE)

W Wei, X Shi, X Li, X Li, Q Han, Q Zhang, X Sun, J Ye, Y Chen, M Zhang, X Liu, P Wang, L Wang, G Su, Y Wang, Q Zhang, Q Liu, Y Zhang, M Huang, L Tang, F Yuan, H Dou, L Lv, Y Song, S Wang, T Liu, L Qin, L Yang, K Yao, X Chen, Z Liu.

**Objective:** To assess the long-term efficacy and safety of intraocular injections of 0.5 mg conbercept injection in patients with macular edema following branch retinal vein occlusion (BRVO).

**Methods:** Phase III, randomized, sham injection-controlled, double-masked, multicenter clinical trial. In the core period, patients received either 0.5mg intravitreal conbercept (conbercept group) or sham injections(control group) every month from Day 0 to Month 5. In the extension period, the conbercept group received conbercept as needed (pro re nata). After a true injection of 0.5mg conbercept, the sham group received conbercept as needed until the end of the twelveth month. Meanwhile, laser photocoagulation was a rescue treatment for the patient who met the criteria. The primary efficacy outcome was mean changes in Best-Corrected Visual Acuity (BCVA) from baseline at month 6. Secondary efficacy outcomes included mean changes in central retinal thickness (CRT) and total macular volume (MV) from baseline to month 6. Efficacy endpoints at 12 months were exploratory.

**Results:** For 249 patients in the full analysis set (FAS), the mean age of patients was 58.2 years in the treatment group and 59.9 years in the control group. The proportions of males were 51.2% and 45.1% in the treatment group and control group, respectively. The mean change from baseline BCVA letter score at month 6 was  $17.0 \pm 9.8$  ( $P < 0.0001$ ) and  $8.4 \pm 11.7$  ( $P < 0.0001$ ) in the treatment group and the control group, respectively ( $P < 0.0001$  for treatment group vs control group). The mean change of BCVA letter score from month 6 to month 12 was  $0.3 \pm 6.4$  in the treatment group ( $P=0.6100$ ), and  $4.6 \pm 6.2$  letters in the control group ( $P < 0.0001$ ). The mean reduction CRT from baseline was  $296.7 \pm 171.3$  um in the treatment group and  $215.7 \pm 209.6$  um in the control group at month 6 ( $P < 0.0001$ ). The incidence rate of laser rescue therapy was 7.87% (95% CI: 3.84%, 14.00%) in the conbercept group and 27.05% (95% CI: 19.41%, 35.84%) in the control group ( $P < 0.001$ ). The most frequent ocular serious adverse event from baseline to month 12 was intraocular pressure (14.35%), conjunctival hemorrhage (8.86%), and retinal ischemia (2.95%) in patients treated with conbercept.

**Conclusion:** Treatment with intravitreal conbercept provided significant functional and anatomic benefits after 6 months as compared with sham. The improvements largely were maintained until month 12 with as-needed dosing.

PP-344

**Relationship between baseline OCT (OCTA) imaging features and responsiveness to anti-VEGF therapy in diabetic cystoid macular edema**X Zhou<sup>1</sup>, J Pu<sup>1</sup>.<sup>1</sup>Ophthalmology, The second affiliated hospital of Chongqing Medical University, Chongqing, People's Republic of China

**Objective:** To determine the association between baseline OCT(OCTA) imaging features and short-term anatomical responsiveness to anti-VEGF therapy in diabetic cystoid macular edema.

**Methods:** A retrospective observational study included 52 eyes from 48 patients who were diagnosed with treatment-naive diabetic cystoid macular edema and treated with 3 monthly intravitreal injections of ranibizumab. Participants were divided into nonresponders (macular thickness reduction rate <10%) and responders (macular thickness reduction rate ≥10%) according to the changes in macular thickness after 3 consecutive anti-VEGF treatments. Basic information and OCT(OCTA) images before and after treatment were obtained and imaging parameters including cystoid space characteristics (vertical diameter, horizontal diameter, area and optical density ratio), hyperreflective abnormalities (hyperreflective foci and hyperreflective spots), vitreomacular interface abnormalities, ELM and EZ continuity, microaneurysms, FAZ features (diameter, area, contour damage degree), vessel density were assessed and compared between two groups. Logistic binary regression model was used to determine the independent predictors of anti-VEGF anatomical responsiveness.

**Results:** The differences in diabetic retinopathy stage, triglycerides (TG), Serum creatinine (Scr) were significant between responders and nonresponders. Significantly different indicators in baseline OCT image included CMT, vesicle ODR, hyperreflective foci and hyperreflective spots, central choroid thickness (CCT), vitreomacular interface abnormalities ( $P < 0.05$ ); Significantly different indicators in baseline OCTA image included deep and total microaneurysms, superficial and deep FAZ contour damage degree, DCP and TCP vessel density ( $P < 0.05$ ). Logistic binary regression revealed that a greater baseline DCP vessel density was associated with a lower nonresponsiveness risk (OR=0.365, 95% CI: 0.138-0.967,  $P=0.043$ ).

**Conclusion:** OCT and OCTA imaging features may help predict the anti-VEGF responsiveness in patients with diabetic cystoid macular edema. Long-term observations of larger cohorts can give more insights.

PP-345

**Adaptive Optics Ophthalmoscopy in Diabetic Retinopathy**A Mirescu<sup>1,2</sup>, I Tofolean<sup>3,4</sup>, I Cristescu<sup>3</sup>, G Balta<sup>1</sup>, S Jurja<sup>2</sup>, F Balta<sup>1,3,4</sup>.<sup>1</sup>Clinical Ophthalmology Emergency Hospital, Bucharest, <sup>2</sup>Ophthalmology Department, "Ovidius" University of Medicine, Constanta, <sup>3</sup>"Retina" Clinic, <sup>4</sup>"Carol Davila" University of Medicine, Bucharest, Romania**Objective:** The current research assesses the retinal arterioles status of healthy volunteers and diabetic patients, using adaptive optics ophthalmoscopy (AOO), a cutting edge, non-invasive imaging technique.**Methods:** Sixty-nine eyes from sixty-nine patients seen between 2020-2022 in the Retina Clinic, Bucharest, Romania, were divided into two study groups: healthy controls and diabetic patients with nonproliferative or proliferative diabetic retinopathy. All participants underwent a complete ophthalmologic examination, including medical history, best corrected visual acuity (BCVA), intraocular pressure (IOP) and slit lamp examination of the anterior and posterior segments. rx1™ adaptive optics retinal camera (Imagine Eyes, Orsay, France) was further used for the evaluation of the vessels. Using the manufacturer's software (AO detect artery, Imagine Eyes, France), the following vascular parameters were automatically generated for the selected regions of interest: vessel diameter (VD), lumen diameter (LD), mean wall thickness (WT), wall to lumen ratio (WLR) and cross-sectional area of the vascular wall (WCSA). IBM SPSS Statistics software was used for data analysis. The results were expressed as mean ± standard deviation. Given the normal distribution of the data, the Independent Samples t Test was adopted in order to evaluate the statistical significance (considered for  $p$  values under 0.05).**Results:** A total number of 38 type I - (34.21%) and type II - (65.79%) diabetic patients (29 males and 9 females, mean age  $55.94 \pm 11.95$  years), having the mean duration of diabetes mellitus  $14.61 \pm 9.80$  years, and 31 healthy volunteers (12 males and 19 females, mean age  $41.64 \pm 13.43$  years) were included in the current study. All five studied vascular parameters were found to have higher values in diabetic patients, when compared to healthy volunteers. For mean wall thickness (WT), wall to lumen ratio (WLR) and cross-sectional area of the vascular wall (WCSA), the differences were statistically significant ( $p \leq 0.002$ ).**Conclusion:** AAO provides useful data regarding the retinal vasculature status, being a promising tool to detect retinal vascular changes in diabetes. Further studies are needed in order to quantify its prognostic role in the more complex stage of diabetic retinopathy progression.

PP-347

**Variation of Visual Field Parameters with Glycosylated Hemoglobin in Type 2 Diabetics Without Retinopathy**S Aldaham.

**Objective:** To assess the relation between visual field parameters and the glycosylated hemoglobin (HbA1c) in type 2 diabetics without retinopathy with well controlled glucose.

**Methods:** A cross-sectional study included 28 healthy subjects and 16 type 2 diabetics without retinopathy, with age and sex matched. Full threshold C-20 program was used for visual field testing in the Frequency Doubling Technology perimeter. Mean sensitivities for each visual field location (foveal, nasal, and temporal), mean deviation (MD), and pattern standard deviation (PSD) were calculated. The HbA1c (%) was grouped into 6 groups; group 1(5.0-5.6), group 2(5.7-6.3); group 3(6.4-7.0); group 4(7.1-7.7); group 5 (7.8-8.4); group 5 (8.5-9.1), showing group 1 as the controls.

**Results:** The PSD varied significantly with HbA1c [ $F_{(4, 45)} = 3.65, p = 0.012$ ]. In groups with HbA1c 5.7-6.3, 6.4-7.0, and 7.8-8.4% (groups 2, 3, and 5) PSD values were greater significantly in comparison to PSD values of the control group. The MD and the visual field locations showed no significant relation with HbA1c.

**Conclusion:** The PSD was the only visual field parameter to vary with the HbA1c in type 2 diabetics without retinopathy, making it a potential parameter for early visual field loss detection before the onset of retinopathy.

PP-348

## Comprehensive Analysis of the Transcriptome-Wide m6A Methylome in RPE Degeneration by MeRIP Sequencing

Y Tan, D Liu<sup>1</sup>, B Qin<sup>1</sup>.

<sup>1</sup>Shenzhen Aier Eye Hospital Affiliated to Jinan University, Shenzhen, People's Republic of China

**Objective:** The role of RNA m6A methylation in controlling RPE function and maintenance has been well-documented. However, a comprehensive and in-depth analysis of its role and profile in the AMD is still lacking. In this study, we characterized m6A modification patterns on a genome-wide scale in the course of RPE degeneration.

**Methods:** A global m6A assay was conducted to determine RNA m6A modification levels in sodium iodate-induced RPE degeneration. M6A demethylation genes ALKBH5, and FTO were detected by Western blot analysis. The genome-wide RNA m6A modification analyses of RPE degeneration were performed using m6A RNA immunoprecipitation and high-throughput sequencing (MeRIP-Seq). A bioinformatic analysis was conducted on genes that have been affected by the m6A marks in RPE degeneration.

**Results:** Compared to normal, m6A RNA modification levels were significantly lower in cells with RPE degeneration. ALKBH5 expression levels were significantly upregulated in RPE degeneration. MeRIP-Seq identified a typical pattern of global m6A methylation displayed at exons, introns, stop codons, 5' UTR, and 3' UTR regions. A complex m6A-mRNA regulatory network has been identified in RPE degeneration through bioinformatics analysis.

**Conclusion:** In our study, we investigated how RNA m6A was modified genome-wide to determine whether epitranscriptomic mechanisms could play a role in RPE degeneration.

PP-349

**An Investigation of Inflammatory Cytokines Expression in Diabetic Retinopathy**X Jiang.

**Objective:** To investigate the relationship between anti-inflammatory and pro-inflammatory cytokines in aqueous from patients with diabetic retinopathy (DR).

**Methods:** Aqueous samples were from DR and control cataract patients and analyzed using multiplex immunoassay for 12 inflammatory cytokines (IL-1b,IL-2,IL-4,IL-5,IL-6,IL-8,IL-10,IL-12P70,IL-17,TNF-a,IFN-a,IFN-y). A total of 23 patients with DR and 12 controls were included. T-tests were performed for comparisons of patient demographics and inflammatory cytokines. Correlation of inflammatory cytokines levels with LogMAR, medical history of diabetic duration, diabetic retinopathy duration, with/without vitrectomy, with/without panretinal laser photocoagulation and sub-foveal retinal thickness (SFT) were also performed in DR patients.

**Results:** The study group included 23 patients with DR and 14 controls. The mean and standard deviation of subjects age was  $54.5 \pm 13.0$  years. The controls were older than the DR patients ( $63.9 \pm 14.8$  years vs.  $49.6 \pm 8.9$  years;  $P > 0.05$ ). Of the 12 inflammatory cytokines examined, IL-5, IL-6 and IL-8 were significantly elevated in diabetics versus controls. At time of screening, study patients were diagnosed with diabetic mellitus (DM)  $11.56 \pm 6.93$  years and diabetic retinopathy (DR)  $11.56 \pm 6.93$  months previously. 4 patients were performed pars plana vitrectomy (PPV) and 9 patients were performed panretinal photocoagulation (PRP) previously. The mean logMAR was  $1.19 \pm 0.97$ . There was a significant correlation between IL-2, TNF-a and diabetic mellitus courses (IL-2  $r=0.49$ ,  $P=0.03$ ; TNF-a  $r=0.5$ ,  $P=0.03$ ); and a significant correlation between IL-12P70 and diabetic retinopathy courses ( $r=0.55$ ,  $P=0.01$ ). No significant correlation was proved between inflammatory cytokines and PPV/PRP previously (all  $P > 0.05$ ). There was a significant negative correlation between IFN-y with logMAR ( $r=0.51$ ,  $P=0.02$ ) and a significant positive correlation between IL-6,IL-8 with logMAR (IL-6  $r=0.75$ ,  $P < 0.001$ ; IL-8  $r=0.68$ ,  $P=0.001$ ). But no significant correlation was found between cytokines and SFT (all  $P > 0.05$ ).

**Conclusion:** This study demonstrated some inflammatory cytokines elevated in DR aqueous, a strong correlation was proved between some cytokines and DM duration and DR courses. Some inflammatory cytokines may involve in DR pathology and decrease vision of DR patients.

PP-350

**Advanced glycation end products are the biomolecular biomarkers of proliferative diabetic retinopathy**N Mishra, R Shukla, A Tiwari, S Saxena.

**Objective:** Advanced glycation end products (AGEs) serve as mediators of “metabolic memory” even after the resolution of hyperglycemia in diabetes mellitus. In the present study we have analysed the role of AGEs as the biomolecular biomarkers of proliferative diabetic retinopathy(PDR)

**Methods:** A tertiary care center based cross-sectional study was undertaken. 80 consecutive cases of type 2 diabetes mellitus were included. Diagnosis of diabetes mellitus was made using American Diabetes Association guidelines. Study subjects included: diabetes mellitus with no retinopathy (No DR) (n=20); non-proliferative diabetic retinopathy(NPDR) (n=20); and PDR (n=20) and healthy controls (n=20). All of the study subjects underwent complete ophthalmological evaluation. Best Corrected Visual Acuity (BCVA) was measured on the logarithm of the minimum angle of resolution (logMAR) scale. AGEs were assessed by assay of N  $\epsilon$  -carboxymethyl-lysine (N  $\epsilon$  -CML) using the standard protocol. N  $\epsilon$  -CML was assessed using receiver operating characteristics curve analysis and area under curve (AUC) was determined.

**Results:** The mean levels of N  $\epsilon$  -CML were  $31.3 \pm 21.2$  ng/ml,  $73.9 \pm 35.0$  ng/ml,  $91.2 \pm 66.7$  ng/ml, and  $132.0 \pm 84.0$  ng/ml in control, No DR, NPDR and PDR respectively. On ANOVA, N  $\epsilon$  -CML level was significantly different between the study groups (control, No DR, NPDR and PDR) ( $p < 0.001$ ). Mean logMAR visual acuity decreased with increased levels of N  $\epsilon$  -CML ( $p < 0.001$ ). On AUC analysis, following values were obtained- NODR=0.67, NPDR =0.69 and PDR = 0.84, showing that AGEs are most sensitive biomarkers for PDR in DR.

**Conclusion:** N  $\epsilon$  -CML, an advanced glycation end product serves as a significant biomolecular biomarker for PDR. It can be a useful parameter to indicate the disease conversion from non-proliferative to proliferative stage of diabetic retinopathy.



## PP-351

**Prevalence and Clinical Implications of Subretinal Fluid in Retinal Diseases: A real-world cohort study**

J Park<sup>1</sup>, T Felfel<sup>2,3</sup>, I Kherani<sup>1</sup>, F Altomare<sup>2,4</sup>, D Chow<sup>2,4</sup>, D Wong<sup>2,4</sup>.

<sup>1</sup>Faculty of Medicine, <sup>2</sup>Department of Ophthalmology and Vision Sciences, <sup>3</sup>Dalla Lana School of Public Health, University of Toronto, <sup>4</sup>Department of Ophthalmology, St. Michael's Hospital, Toronto, Canada

**Objective:** To characterize the baseline prevalence of subretinal fluid (SRF), and its effects on anatomical and visual acuity (VA) outcomes in diabetic macular edema (DME) and retinal vein occlusion (RVO) eyes treated with real-world variable dosing regimen of intravitreal anti-vascular endothelial growth factor (VEGF) injections.

**Methods:** Treatment-naïve DME and RVO patients who were initiated on intravitreal anti-VEGF injections for macular edema between January 2016 to December 2017 were included. The DME and RVO cohorts were subclassified into SRF or non-SRF groups based on the presence of SRF on optical coherence tomography (OCT) at baseline. All patients received injections of bevacizumab, ranibizumab or aflibercept. RVO patients were treated based on a treat-and-extend regimen while DME patients were treated according to the regimen adapted from the DRCR.net Protocol T with retreatment decisions largely dependent on the individual clinician's judgment of disease activity. Changes in visual acuity (VA) and central subfield thickness (CST) were assessed up to 24 months. Comparisons between SRF and non-SRF groups were made using the independent samples t-test and chi-square test.

**Results:** A total of 122 DME and 54 RVO patients were included. At baseline, SRF was present in 22% and 41% in DME and RVO, respectively. DME patients with SRF were more likely to have bilateral macular edema at baseline (odds ratio = 2.7, 95% confidence interval 1.1-6.4, P<0.05) compared to those without SRF. In the DME cohort, SRF eyes demonstrated a mean logMAR VA at 24-month of  $0.41 \pm 0.28$  (Snellen 20/50) that was significantly higher compared to baseline ( $0.65 \pm 0.35$  [20/90], P<0.05). Furthermore, improvement in logMAR VA at 24-month was significantly greater for the SRF eyes compared to the non-SRF eyes ( $0.25 \pm 0.29$  vs.  $-0.08 \pm 0.54$ , P<0.05). Percent reduction in CST was  $25 \pm 23$  for SRF and  $11 \pm 20$  for non-SRF at 3-month (P<0.05). In the RVO cohort, there was no association between SRF and the VA outcomes, while the percent reduction in CST was  $36 \pm 19$  versus  $18 \pm 17$  (P<0.05) at 1-month for SRF and non-SRF, respectively.

**Conclusion:** Baseline SRF is a good marker for a greater reduction in CST in both DME and RVO, but an improvement in VA associated with SRF may be only noted in DME. The presence of SRF may have significant clinical implications on patients undergoing therapy, and it may be used in clinical decision making for ophthalmologists treating DME and RVO.

**PP-352****Determine the relationship between ocular biometry and severity of diabetic retinopathy in patients with type II diabetes mellitus**

N Adlakha, M *Kaur*.

**Objective:** To calculate the intraocular lens power and to determine the relationship between ocular biometry and severity of diabetic retinopathy (DR) in patients with type II diabetes mellitus.

**Methods:** The study group included 250 type II diabetic subjects with Diabetic Retinopathy. The control group consisted of 250 type II diabetic subjects having no Diabetic Retinopathy. Axial length (AL), corneal power, and anterior chamber depth were measured using LenStar. Diabetic Retinopathy and diabetic macular edema were classified according to International DR Classification. Crystalline lens power was calculated using Barrett Universal II formula. AL to corneal radius ratio was calculated. Chi-square test was used for categorical variables.

**Results:** In multivariate logistic models adjusting for age, sex, glycosylated hemoglobin, duration of diabetes, Mean age of patients in the study group was  $62.45 \pm 4.85$  years, whereas in the control group, it was  $63.37 \pm 7.29$  years. Of the eyes with DR, 117, 76, 69, and 38 had mild NPDR, moderate NPDR, severe NPDR, and PDR, respectively. The difference in the mean duration of diabetes mellitus and glycosylated hemoglobin in both study and control groups was found to be statistically significant. A progressive decrease in the mean AL and the anterior chamber depth was observed with increasing severity of DR, and difference was statistically significant. There was a progressive increase in intraocular lens power with increasing severity of DR, and difference was found to be statistically significant

**Conclusion:** In persons with diabetes mellitus, globe elongation plays quite an important role in protective effects against DR, with contribution from intraocular lens power and other refractive components.

PP-355

**MiR-125b attenuates retinal pigment epithelium oxidative damage via targeting Nrf2/HIF-1  $\alpha$  signal pathway**J Liu<sup>1</sup>, Y qin<sup>1</sup>, D Ma<sup>1</sup>, X Zhi<sup>1</sup>.<sup>1</sup>Fourth affiliated hospital of China medical university, shenyang, People's Republic of China

**Objective:** The present study was designed to investigate the regulating mechanism of miR-125b on Nrf2/HIF-1  $\alpha$  signal pathway and evaluate its antioxidant capacity in oxidants-induced oxidative damage of retinal pigment epithelium

**Methods:** The overexpression of miR-125b in ARPE-19 cells was achieved by transfecting miR-125b mimic using Lipofectamine™ RNAiMAX while the overexpression of miR-125b in mice was achieved through intravitreal injection of miR-125b agomir, and the expression of miR-125b was detected by qPCR. The expression of HIF-1  $\alpha$ , Keap1, Nrf2, and HO-1 at both mRNA and protein level was detected by qPCR and western blot respectively. The characteristic changes of oxidative stress was determined by the detection of ROS, MDA, SOD, and EdU. The phenotypic changes of retina was assessed by H&E staining and immunofluorescence staining after a tail vein injection of NaIO<sub>3</sub>.

**Results:** The in vitro studies indicated that overexpression of miR-125b substantially inhibited Keap1 expression, enhanced Nrf2 expression and induced Nrf2 nuclear translocation. Importantly, functional studies demonstrated that forced expression of miR-125b could significantly elevate cell proliferation and superoxide dismutase (SOD) levels while reduce reactive oxygen species (ROS) overproduction and malondialdehyde (MDA) formation. Further studies showed that miR-125b had no effect when Nrf2 was silenced in ARPE-19 cells. Additionally, the results identified that Nrf2 silence induced ROS accumulation enhances HIF-1  $\alpha$  protein expression, while miR-125b could offset this effect via promoting HIF-1  $\alpha$  protein degradation. Subsequent in vivo studies demonstrated that sodium iodate induced outer retina thinner was reversed with exogenous supplementation of miR-125b, which was cancelled in Nrf2 knockout mice.

**Conclusion:** This study illustrated that miR-125b can protect RPE from oxidative damage via targeting Nrf2/HIF-1  $\alpha$  signal pathway and potentially may serve as a therapeutic agent of age-related macular degeneration.

PP-356

### Anatomical and functional changes after corticosteroids in diabetic macular edema patients according to ESASO Classification

A Moreno Martínez, C Blanco Marchite<sup>1</sup>, F Lopez Martínez<sup>1</sup>, A Donate Tercero<sup>1</sup>, S Copete<sup>1</sup>.

<sup>1</sup>Hospital Perpetuo Socorro, Albacete, Spain

**Objective:** To assess functional outcomes and anatomical biomarkers changes after corticosteroids like intravitreal dexamethasone implant (DEXI) in diabetic macular edema (DME) patients.

**Methods:** Retrospective real-world study conducted on consecutive DME patients with DEXI and were controlled at 2, 6 and 12 months. Subjects were divided in groups: naïve patients and non-responders to previously treated eyes with  $\leq 3$  antiVEGF injections (early switch) or  $> 3$  antiVEGF injections (late switch). Outcomes were best corrected visual acuity (BCVA) and anatomical biomarkers with spectral domain optical coherence tomography (OCT) according to The European School for Advanced Studies in Ophthalmology (ESASO) classification.

**Results:** A total of 112 eyes were finally included in the study. At baseline, there were no statistically significant differences between gender, BCVA, CRT, type of diabetes mellitus, DME subtype and state of the lens. At month 2, the BCVA (logMAR) changed from  $0.4 \pm 0.52$  to  $0.35 \pm 0.30$ ,  $0.52 \pm 0.46$  to  $0.40 \pm 0.52$  and  $0.70 \pm 0.35$  to  $0.52 \pm 0.44$  in naïve, early and late switch group, respectively ( $p < 0.001$  between all groups). BCVA decreased at 6 and 12-month visit in naïve and early switch group and was stable in late switch from 6 month to final visit. Retinal thickness (T) improved at month 2, 6 and 12 in all groups ( $p < 0.001$ ). There was similar size cyst (C) reduction in all groups with statistically significant differences at 2 and 6-months ( $p < 0.001$  and  $p = 0.003$ , respectively, between all groups). Presence of disorganization of the inner retinal layers (D) and subretinal fluid (F) improved at 12-month visit from baseline in all groups ( $p = 0.04$  at 6-month visit in both biomarkers). Hyperreflective foci (H) decreased in all groups over the study period ( $p < 0.01$  at final visit). We found better results in D, F and H biomarkers over study period in late switch group. We did not find differences in the ellipsoid zone and/or external limiting membrane (E) and vitreoretinal relationship (V) alterations between groups in all time investigated. 89 (79.46%) eyes received additional treatment after first DEXI.

**Conclusion:** There were similar DEXI behaviour in biomarkers in all groups with better findings in late switch group.

PP-357

**Photoreceptor layer thinning is an early biomarker for age-related macular degeneration**

S Zekavat<sup>1,2,3</sup>, S Sekimitsu<sup>4</sup>, Y Ye<sup>5</sup>, V Raghu<sup>6</sup>, H Zhao<sup>7</sup>, T Elze<sup>1</sup>, A Segre<sup>8</sup>, J Wiggs<sup>1</sup>, P Natarajan<sup>9</sup>, L Del Priore<sup>2</sup>, N Zebardast<sup>1</sup>, J Wang<sup>2,10</sup>.

<sup>1</sup>Department of Ophthalmology, Massachusetts Eye and Ear, Boston, <sup>2</sup>Department of Ophthalmology and Visual Science, Yale University, New Haven, <sup>3</sup>Broad Institute of Harvard and MIT, Cambridge, <sup>4</sup>Tufts University, Boston, <sup>5</sup>Yale University, New Haven, <sup>6</sup>Massachusetts General Hospital, Boston, <sup>7</sup>School of Public Health, Yale University, New Haven, <sup>8</sup>Department of Ophthalmology, Massachusetts Eye and Ear Institute, Boston, <sup>9</sup>Program in Medical and Population Genetics, Broad Institute of Harvard and MIT, Cambridge, <sup>10</sup>Northern California Retina Vitreous Associates, Mountain View, United States

**Objective:** Despite widespread use of optical coherence tomography (OCT), an early-stage imaging biomarker for age-related macular degeneration (AMD) has not been identified. Pathophysiologically, the timing of drusen accumulation in relation to photoreceptor degeneration in AMD remains unclear, as are the inherited genetic variants contributing to these processes. Here, we jointly analyzed OCT, electronic health record, and genomic data to characterize the time sequence of changes in retinal layer thicknesses in AMD, as well as epidemiological and genetic associations between retinal layer thicknesses and AMD.

**Methods:** The Topcon Advanced Boundary Segmentation algorithm was used for retinal layer segmentation. We associated 9 retinal layer thicknesses with prevalent AMD (present at enrollment) in a logistic regression model, and with incident AMD (diagnosed after enrollment) in a Cox proportional hazards model. Next, we associated AMD-associated genetic alleles, individually and as a polygenic risk score (PRS), with retinal layer thicknesses. All analyses were adjusted for age, age<sup>2</sup>, sex, smoking status, and principal components of ancestry.

**Results:** Photoreceptor segment (PS) thinning was observed throughout the lifespan of individuals analyzed, while retinal pigment epithelium and Bruch's membrane complex (RPE+BM) thickening started after age 57y. Each standard deviation (SD) of PS thinning and RPE+BM thickening were associated with incident AMD (PS: HR 1.35, 95% CI 1.23-1.47, P=3.7x10<sup>-11</sup>; RPE+BM: HR 1.14, 95% CI 1.06-1.22, P=0.00024). The AMD PRS was associated with PS thinning (Beta -0.21 SD per 2-fold genetically increased risk of AMD, 95% CI -0.23 to -0.19, P=2.8x10<sup>-74</sup>), and its association with RPE+BM was U-shaped (thinning with AMD PRS<92<sup>nd</sup> percentile and thickening with AMD PRS>92<sup>nd</sup> percentile). The loci with strongest support for genetic correlation were AMD risk-raising variants *CFH*:rs570618-T, *CFH*:10922109-C, and *ARMS2/HTRA1*:rs3750846-C on PS thinning, and *SYN3/TIMP3*:rs5754227-T on RPE+BM thickening.

**Conclusion:** Epidemiologically, PS thinning precedes RPE+BM thickening by decades, and is the retinal layer most strongly predictive of future AMD risk. Genetically, AMD risk variants are associated with decreased PS thickness. Overall, these findings support PS thinning as an early-stage biomarker for future AMD development.

PP-358

**Airborne fine particulate matter (PM2.5) induces abnormal proliferation and tight junction destruction in ARPE-19 cells**Y Gu, Y Xu, K Yao, Q Fu.

**Objective:** To investigate the effects of PM2.5 on the proliferation, migration and barrier function in human retinal pigment epithelial cell line ARPE19, and to explore the effect of PM2.5 on the function of retinal pigment epithelium (RPE) and its potential association with retinal diseases.

**Methods:** PM2.5 in haze weather was collected to prepare suspension. The ARPE19 cells were exposed to different concentrations of PM2.5 suspension for different treatment time. After treatment, the proliferation level of cells was detected by MTT assay, the migration ability of cells was detected by wound healing assay, and the changes of tight junctions between cells were observed by immunofluorescence staining. T test was used for comparison between two sample means, analysis of variance was used for comparison between multiple sample means, and linear correlation analysis was used for correlation analysis.

**Results:** The proliferation rate of each group showed a similar trend, and the proliferation rate first showed a slight downward trend with the increase of PM2.5 concentration. The proliferation rate of 0.5mg/L in 6h group was  $(95.00 \pm 1.72)\%$  compared with  $(100 \pm 2.30)\%$  in control group. Compared with the control group  $(100 \pm 3.55)\%$ , the proliferation rate of 0.5mg/L 48h group was  $(87.08 \pm 8.86)\%$  (all  $P < 0.05$ ). After that, with the further increase of PM2.5 concentration, the proliferation rate of each group gradually increased and exceeded that of the control group. In the scratch experiment, the cell migration rate slowed down with the increase of PM2.5 concentration. Immunofluorescence staining showed that with the increase of PM2.5 concentration and exposure time, the distribution of tight junction protein ZO1 in RPE cells gradually decreased, suggesting the breakdown of tight junction between cells.

**Conclusion:** PM2.5 may affect the normal function of RPE cells by inhibiting RPE cell proliferation at low concentration, promoting proliferation at high concentration, inhibiting cell migration and destroying the tight connection of RPE cells, suggesting that PM2.5 may be associated with diseases related to blood retinal barrier destruction and progression of proliferative vitreoretinopathy.

PP-359

### Smartphone based fundus imaging as a diagnostic tool in posterior segment evaluation in COVID-19 associated Mucormycosis (CAM)

R Singh, N Mishra<sup>1</sup>, A Kaur<sup>1</sup>.

<sup>1</sup>Ophthalmology, King George's Medical University, Lucknow, India

**Objective:** Smartphone based fundus imaging as a diagnostic tool in posterior segment evaluation in COVID-19 associated Mucormycosis (CAM)

**Methods:** The current analysis was done in a tertiary care hospital in north India in a span of 5 months. It is a descriptive retrospective analysis of CAM patients with posterior segment involvement.

Smartphone based fundus imaging (SBFI) is a reproducible, cost-effective (compared to conventional mobile fundus imaging equipment such as RetCam) and easy to perform by any ophthalmologist well versed with use of 2.2 dioptre lens. The illumination of indirect ophthalmoscope is replaced with the in-built torch-light illumination of the mobile phone. Various user-friendly software has come up over the past few years for this purpose, such as Open Camera Version 1.49.1 which is freely available over Google Play Store application and is compatible with Android phones and tablets, and VSCO Version 245.0 compatible with both Android and iOS users.

**Results:** A total of 290 patients with ROCM were examined out of which 194 patients had ophthalmic presentation. The range of affected patients belonged to an age group of 21-80 years. Out of 290 patients, 34.1% (99) were females and 65.8% (191) were males.

In patients with posterior segment involvement, bedside dilated fundus examination was performed to diagnose and document the findings. Out of 290 patients, 131 (45%) patients had a complaint of diminution of vision. From the subset of visual deprivation group, more than half of the patients (n= 72; 54.9% 72) had posterior segment findings such as vitreous haemorrhage, retinal vascular occlusion, optic nerve head edema.

**Conclusion:** Documentation of fundus findings is not feasible with conventional imaging equipment as most of the severe patients are not ambulatory and COVID positive patients carry a risk of spreading the infection. Moreover, there is technical hindrance in using bedside head-mount indirect ophthalmoscope due to suboptimal viewing through fogging of protective eyewear. Therefore, bedside SBFI is an important tool that aids in diagnosing and document the posterior segment findings in patients of CAM.



## PP-360

**Comparison of retrobulbar circulation in type 2 diabetics and non-diabetics using color doppler imaging**

R Kotian<sup>1</sup>, T G P<sup>1</sup>, R V<sup>2</sup>.

<sup>1</sup>Department of Ophthalmology, <sup>2</sup>Department of Radiology, M S Ramaiah Medical College Hospital, Bangalore, India

**Objective:** To compare the retrobulbar circulation using color duplex imaging in type 2 diabetic patients with healthy controls and correlate it with the grade of diabetic retinopathy amongst the diabetics.

**Methods:** Forty with type 2 DM and forty non-diabetics attending the outpatient clinic for an eye examination were enrolled after informed consent. All study participants underwent a comprehensive ophthalmic examination including dilated funduscopy. The diabetic patients were assigned to groups based on ETDRS grading of diabetic retinopathy. Color Doppler sonography (CDI) of the eye was performed on all the enrolled individuals. The peak systolic velocity (PSV), end diastolic velocity (EDV) and resistivity index readings were recorded from the ophthalmic artery (OA), central retinal artery (CRA) and the posterior ciliary artery (PCA).

**Results:** Ophthalmic Artery : Mean PSV of OA in healthy controls was 52.82 cm/s. There was a significant (p 0.000) reduction in the PSV observed in diabetics with a mean PSV of 29.56 cm/s and also with the progression of diabetic retinopathy. EDV showed significant (p 0.000) reduction in diabetics and with progression of DR. RI of OA in the two groups did not show significant difference (p 0.054)

Central retinal artery: Mean PSV of CRA in controls was 21.88 cm/s. There was a significant (p 0.000) reduction in the PSV in diabetics with a mean PSV of 17.61 cm/s and also with the progression of diabetic retinopathy. EDV and RI of CRA showed a significant (p 0.000) reduction in diabetics and with the progression of DR.

Posterior ciliary Artery : Mean PSV of PCA in healthy controls and diabetics had no significant (p 0.811) difference. EDV of PCA showed significant (p 0.000) reduction in diabetics and with the progression of DR. PCA RI showed a significant (p 0.005) reduction in diabetics and further, mild DR showing a greater reduction and subsequent increase in RI with further progression in DR.

**Conclusion:** Significant changes in the resistivity index and flow velocities were observed in the retrobulbar vessels of two groups. In this study, results of decreased flow velocity with progression of diabetes supports the rheological changes involved in pathophysiology of diabetes. The resistance index shows an increase with the progression of DR. These could be useful to predict individuals at higher risk for developing severe DR or PDR.

**PP-361****Clinical study of ocular manifestations in patients with newly diagnosed and relapsed haematolymphoid malignancies at a tertiary c**

D Rh, T GP<sup>1</sup>.

<sup>1</sup>*Ophthalmology, MS Ramaiah Medical College, Bangalore, India*

**Objective:** To estimate the proportion of ocular manifestations at the initial presentation and in relapsed cases of various haematolymphoid malignancies and to determine association between ocular manifestations and haematological parameters.

**Methods:** An observational cross-sectional study was conducted on patients with newly diagnosed or relapsed haematolymphoid malignancies. The study was conducted over a period of 15 months in the oncology department by an Ophthalmologist. Informed consent was obtained from all patients. All patients with newly diagnosed or presenting with a relapse of haematolymphoid malignancies underwent a complete ocular evaluation including both anterior and posterior segment evaluation. Data on haematological parameters were also collected. The data was then subjected to statistical analysis by using the SPSS software version 16.

**Results:** 62 patients were included out of which, there were 45 males (71.4%), and 18 were females (28.6%) with an age range of 5-76 years. Forty-two patients (41.2%) had ocular manifestations. 47.1% patients of acute leukaemia and 6.7% patients of chronic leukaemia had ocular manifestations. There was a significant association between ocular manifestations and low haemoglobin ( $P = 0.003$ ), increased TLC ( $P = 0.005$ ), and decreased platelet counts ( $P = 0.001$ ). Intraretinal haemorrhages were the most common ocular manifestation followed by Roth spots. Among acute leukaemia patients, there was a significant association between intraretinal haemorrhages and low haemoglobin (Mann-Whitney U-test = 24.001 in the myeloid group and 44.000 among lymphoblastic group,  $P = 0.005$ ). These ocular manifestations were noted more commonly in acute leukaemia as compared to chronic leukaemia.

**Conclusion:** It is important to screen all leukemic patients especially acute leukaemia due to its high association with the presence of intraretinal haemorrhages and low haemoglobin and low platelet counts. Presence of ocular manifestations in these patients indicates deranged haematological parameters. Ocular manifestations form a guiding principle for the management of patients with haematolymphoid malignancies.

PP-363

**Hyperreflective Foci in Retinitis Pigmentosa: Image Biomarkers of Adverse Visual Prognosis**M Madeira<sup>1</sup>, M Correia<sup>1</sup>, M Baptista<sup>1</sup>, M Portela<sup>1</sup>, P Arede<sup>1</sup>, A Cabugueira<sup>1</sup>, F Vaz<sup>1</sup>.<sup>1</sup>Egas Moniz Hospital (Occidental Hospital Center of Lisbon), Lisbon, Portugal

**Objective:** To investigate the presence and effect on visual acuity of hyperreflective foci (HRF), found in spectral-domain optical coherence tomography (SD-OCT) of retinitis pigmentosa (RP) patients.

**Methods:** Non-interventional, retrospective and single center analysis of seventeen RP cases (thirty eyes) followed at least during one year. Exclusion criteria comprised maculopathy and intraocular inflammation. Demographic (age, sex) and clinical (family history, phakic status, RP type) data were collected. Best corrected visual acuity (BCVA) was obtained at initial diagnosis, a year after and on the last visit in records. SD-OCT images were analyzed with attention to macular edema (ME), ellipsoid zone (EZ) disruption, presence and localization of HRF. Additionally, central macular thickness (CMT) and subfoveal choroidal thickness (CT) were measured. Statistical analysis was performed using the SPSS software and statistical significance was taken as p-value <0.05.

**Results:** At baseline, patients had a mean logMAR BCVA of  $0.34 \pm 0.24$ , decreasing to  $0.44 \pm 0.32$  on the last visit. HRF were classified accordingly to their localization in the external or internal retina and choroid. Eighteen (56.3%), twenty-three (71.9%), twenty (62.5%), nineteen (59.4%), twenty-two (68.8%) were outer-central, outer-perifoveal, inner-central, inner-perifoveal and choroidal HRF, respectively. There was positive correlation between HRF in the central retina and worst BCVA at diagnosis and EZ disruption ( $p=0.006$  and  $p=0.010$ ). Regarding BCVA, worse vision at diagnosis was strongly correlated with worse BCVA a year after and on the last observation (both  $p<0.001$ ). When studying the central retina, HRF in the external layers were found to be positively correlated with CMT and ME ( $p=0.015$  and  $p=0.010$ ), while those in the internal layers did not. The strongest associations were found for the coexistence of different HRF groups, particularly in the external retina and choroid. Outer-perifoveal HRF were correlated with inner-perifoveal HRF and choroidal HRF were correlated with outer-perifoveal, outer-central and inner-perifoveal HRF (all  $p<0.001$ ).

**Conclusion:** Accordingly to the literature, our study showed that HRF are common in RP and their presence seemed to disclose a worse prognosis, in terms of BCVA and structural alterations in regions responsible for central vision. As such, they may be considered image biomarkers with negative prognostic value in SD-OCT interpretation in the RP population.

**PP-364****The Virtualisation of Retina Clinics, a retrospective database analysis to assess outcomes of patients seen in "Virtual Clinics".**

M Hussain.

**Objective:** Limits on social interactions necessitated by the COVID-19 Pandemic put pressure on ophthalmic resources in NHS Grampian. Virtual Surgical and Medical Retina Clinics were introduced at Aberdeen Royal Infirmary to reduce the contact time between clinicians and patients. This evaluation is intended to assess the clinical outcomes of patients followed up in a virtual clinic setting, and to see if Virtual Retina Clinics can be utilised in post-COVID ophthalmic practice even when social-distancing measures can be eased.

**Methods:** A sample of patients were collected via TrakCare with the assistance of the NHS Grampian Health Intelligence department. A data set of 207 patients were identified, who were under the care of a specific Consultant Ophthalmologist between 31<sup>st</sup> July 2020 and April 2021 within either their Virtual Surgical Retina Clinic or Virtual Medical Retina Clinic. Clinics held by other consultants were not considered for this study, as the methodology differed between consultants. Outcomes of the clinic were noted per patient and compared amongst each other. Any concerns were also noted. Any instances of raised IOP were noted, and the action taken after noting were also collected.

**Results:** It was found that the virtual clinics were taken favourably with patients, with no complaints arising from utilising the process. The waiting list for specialist ophthalmology input was reduced. Of the 207 patients, 121 patients were discharged, 73 booked in for further review and 13 identified to be converted to inpatient for intervention. 78.1% of the patients were booked in for virtual review, 21.9% were required to be reviewed face-to-face. There were no patients considered to have significant IOP change due to the use of using dilating drops for ultra-widefield retinal imaging.

**Conclusion:** The results of this retrospective database study are favourable for the technician-led virtualisation of clinics. There were no significant findings of patient safety being compromised, as the threshold for converting a virtual appointment to a face-to-face appointment was low. This method seemed favourable for both patients and clinicians; efficient time use led to more patients being able to be seen with reduced wait times for specialist input. It is reasonable to suggest that an uptake of virtual medical and surgical retina clinics would be an appropriate optimised allocation of medical resources.

## PP-366

**Assessment of retinal layer metrics by SDOCT with reference to glycemic control and visual acuity in type II diabetics.**

K Chauhan<sup>1</sup>, B Sharma<sup>1</sup>, S Karkhur<sup>1</sup>, N Yadav<sup>1</sup>, S Verma<sup>1</sup>, R Nyodu<sup>1</sup>, L Banerjee<sup>1</sup>.

<sup>1</sup>Ophthalmology, All India Institute of Medical Sciences Bhopal, Bhopal, India

**Objective:** Optical coherence tomography (OCT) is a non-invasive, in-vivo imaging technique imaging modality which facilitates the cross-sectional visualization of retinal layers. It allows the detection of microscopic retinal and choroidal pathology. This study evaluates the correlation of retinal layer metrics with glycemic control (HbA1c) and visual acuity, in type 2 diabetics. Moreover, the variation in retinal layer metrics between diabetic and non-diabetic patients has also been studied.

**Methods:** It is a case control study of 248 eyes of 126 patients. Macular cube scan of 512x218 protocol was done to assess central subfield thickness (CST) and average ganglionic cell layer (GCL) - inner plexiform layer (IPL) thickness in an elliptical annulus centered on fovea. Additionally, thickness was measured for inner retina (ILM-OPL) from the internal limiting membrane (ILM) to the proximal boundary of the outer nuclear layer (ONL); outer retina (ONL-RPE) from proximal ONL boundary to the retinal pigment epithelium (RPE); ellipsoid zone (EZ) to RPE (EZ-RPE) and total retina (ILM-RPE) from ILM to RPE at fovea, juxtafoveally at 1 mm nasal and temporal to the fovea. Average retinal nerve fibre layer (RNFL) thickness was evaluated using 200x200 protocol of optic disc cube centered on the optic disc.

**Results:** Inner retina including average RNFL thickness, average GCL-IPL thickness, foveal ILM-OPL thickness; EZ-RPE and total retina (ILM-RPE) including juxtafoveal temporal and nasal thickness, showed significant reduction in diabetics. Visual acuity showed weak positive correlation with inner retinal layers. Additionally, total retina (ILM-RPE) juxtafoveal nasal parameter had weak positive correlation with BCVA in diabetics. HbA1C also showed weak negative correlation with inner retinal layers. Multivariate regression analysis showed increase in average RNFL thickness, average GCL-IPL thickness, inner retinal ILM-OPL juxtafoveal temporal thickness and total retinal ILM-RPE juxtafoveal nasal thickness were significantly associated with decreased visual acuity.

**Conclusion:** With the advent of OCT, quantitative assessment of different retinal layer metrics, could help us detect signs of retinal neuro-degeneration and impending clinical diabetic retinopathy associated with chronic hyperglycaemia. Furthermore, it would serve as a OCT biomarker to detect pre-clinical DR and initiate appropriate clinical interventions.

PP-367

**Genotype-phenotype associations in familial exudative vitreoretinopathy: a meta-analysis on more than 3200 individuals**

X Wang<sup>1</sup>, C Jun<sup>1</sup>, X Hui<sup>1</sup>, X Yu<sup>1</sup>.

<sup>1</sup>Eye Hospital, The First affiliated Hospital of Harbin Medical University, Key Laboratory of Basic and Clinical Research of Heilongjiang Province, Harbin, People's Republic of China

**Objective:** To systematically review the relationship between genotypes and clinical phenotypes of Familial exudative vitreoretinopathy (FEVR) to support risk estimation and therapeutic decisions.

**Methods:** The data of our study were collected from PubMed, Embase, Web of Science, Cochrane, CBM, China National Knowledge Infrastructure (CNKI), WAN FANG and VIP databases.

**Results:** A total of 3257 patients from 32 studies were included according to the inclusion and exclusion criteria. Among all the cases, the mutation frequencies of LRP5, FZD4, NDP, TSPAN12, ZNF408 and KIF11 were 13.6 %, 11.5%, 4.6%, 6.7%, 1.6%, and 5.7%, respectively. Review the clinical manifestations for cases with gene mutations, we found that the patients with of NDP and FZD4 suffer more severe symptoms. Retinal detachment is the most frequent symptom of patients of LRP5 and NDP mutations respectively. For the patients with the mutation of TSPAN12, retinal folds is the most common clinical manifestations, and suffer the mildest clinical phenotypes compared with the other three genes.

**Conclusion:** The results of the meta-analysis indicate that different types of genetic mutations occur at different frequencies. In addition, the clinical manifestations of FEVR are related to the type of gene mutation. Therefore, targeted treatment strategies and follow-up recommendations should be adopted for different pathogenic genes of FEVR.

PP-368

**A Prediction Model for Worsening Diabetic Retinopathy after Panretinal Photocoagulation**J Li, Z Li<sup>1</sup>.<sup>1</sup>Department of Ophthalmology, Chinese PLA General Hospital, Beijing, People's Republic of China

**Objective:** Aim is to assess the risk factors for predicting worsening diabetic retinopathy (DR-worsening) within 5 years after panretinal photocoagulation (PRP). Furthermore, we established and validated a model to assess the probability of DR-worsening.

**Methods:** We retrospectively analyzed patients who were diagnosed with severe non-proliferative diabetic retinopathy or proliferative diabetic retinopathy and treated with PRP. Patients were randomly assigned to either a training cohort or a validation cohort. The multivariate logistic regression analysis was used to screen potential risk factors in the training cohort. And the model was developed according to the estimate of each included significant risk factor. The predictive effectiveness of the model was validated using discrimination and calibration.

**Results:** A total of 271 patients were included in this study, and 56.46% patients had an outcome of DR-worsening. In the training cohort (n=135), age (odds ratio (OR) = 0.91, 95% confidence interval (CI) 0.85-0.96), original best corrected vision (OR=0.11, 95% CI 0.01-0.87), diabetic nephropathy (OR=16.83, 95% CI 1.92-147.50) and hyperlipidemia (OR=5.53, 95% CI 1.25-24.57) were screened out as the independent risk factors associated with DR-worsening. These 4 factors were incorporated into the predictive model. The area under the receiver operating characteristic curve for the model in the training and validation cohort were 0.78 and 0.79, respectively. The calibration plots showed good agreement between prediction and observation. The calibration slope in the training and validation cohort were 0.99 (95% CI 0.62-1.35) and 1.00 (95% CI 0.54-1.49), respectively. According to the model, two risk groups were developed, and the actual probability in the low risk group and high risk group was 37.42% and 85.19%, respectively.

**Conclusion:** We developed an easy-to-use model to predict the risk of DR-worsening after PRP treatment within 5 years, which can be used as a rapid risk assessment system for clinical prediction of DR-worsening and remind physicians and patients to pay attention to the associated risk factors.

PP-369

**Protective Effect of Melatonin against Sodium Iodate-Induced Ferroptosis in Photoreceptor Cells via GSK-3 $\beta$ /Nrf2 Signaling Pathway**X Zhi, Y Qin, J Liu, D Ma, L Wang, L Luo.

**Objective:** Ferroptosis is recently a non-apoptotic cell death that relies on iron and reactive oxygen species (ROS) to induce lipid peroxidation. The purpose of this study was to determine whether ferroptosis exists in the pathogenesis of dry AMD in photoreceptor cells, and to confirm that melatonin suppresses ferroptosis in photoreceptor cells by activating the GSK-3 $\beta$ /Nrf2 signaling pathway.

**Methods:** In this study, we exposed 661W cells to NaIO<sub>3</sub> (12.5mM) for 24h in vitro and treated with different concentrations of melatonin (1, 10, 100 $\mu$ M). In C57BL/6 mice injected with NaIO<sub>3</sub> (50mg/kg) through tail vein, transmission electron microscopy, western blots, and HE staining were used to confirm the presence of ferroptosis, and the role of Nrf2 in ferroptosis was investigated by Nrf2 knockout mice.

**Results:** The results showed that NaIO<sub>3</sub> induced photoreceptor cell death and lipid peroxides accumulation, and induced changes in the expression levels of ferroptosis-related factors and iron maintenance proteins, which were treated by melatonin. We found that melatonin can block Fyn dependent Nrf2 nuclear output through GSK-3 $\beta$  signaling. In addition, the therapeutic effect of melatonin was significantly inhibited after Nrf2 expression was interfered.

**Conclusion:** Therefore, we conclude that NaIO<sub>3</sub> induces ferroptosis in photoreceptor cells and melatonin has therapeutic effects on NaIO<sub>3</sub> by regulating GSK-3 $\beta$ /Nrf2 signaling pathway in vivo and in vitro.



**PP-370****Retinal Changes In Hypertensive Disorders of Pregnancy**A Kulkarni, K Y.

**Objective:** Aim: To study the retinal changes in hypertensive disorders of pregnancy and to correlate the same with the severity of hypertension.

**Methods:** Methods: A cross sectional study conducted in the department of ophthalmology and department of obstetrics and gynecology to analyze the various changes seen in the retina of patients with hypertensive disorders of pregnancy and to correlate it with the severity of the disease. The various changes in the retina was noted and graded according to the Keith Wagner grading of hypertensive retinopathy along with blood pressure measurement and analysis of f proteinuria by urine dipstick method. The above finding was correlated with the severity of pregnancy induced hypertension as classified by ISSHP criteria

**Results:** Results: A total of 120 cases were analyzed the mean age group of the patients was 25+/- 5 years. Among the 120 patient 60% of the patient presented with no obvious changes in the retina. 62.5% of the patients in the above group were found to have gestational hypertension. 25% were found to have grade 1 hypertensive retinopathy which included 60% cases of pre- eclampsia and 40% cases of gestational hypertension. 12.5% cases had grade 2 hypertensive retinopathy 75% of which were diagnosed to have pre- eclampsia, 15% eclampsia and 10% with gestational hypertension. 1.67% presented with grade 3 hypertensive and 50% of whom had eclampsia and 50% were patients with preeclampsia. 1 Patient diagnosed case of eclampsia was found to grade 4 hypertensive retinopathy with papilledema. In the patient with grade 4 hypertensive retinopathy the pregnancy was immediately terminated to prevent fetal and maternal mortality.

**Conclusion:** Conclusion: Hypertensive disorders of pregnancy is one of the leading causes of maternal morbidity and mortality and to they can present with various end organ damage. One of the organs most commonly effected is the eye. Timely diagnosis can help us diagnose the disease better and the commencement of ecosprin and appropriate anti-hypertensive drugs such as labetalol at the right time can save not only the lives of the baby and mother but also the eyesight. This study also emphasizes the importance of regular follow for patients diagnosed with PIH during every trimester

PP-371

**Meta-Analysis of The Use of Glucocorticoid In The Preoperative Application of Botanical Excision For The Treatment of RRDCD**H Linfeng.

**Objective:** To evaluate the role of vitrectomy for choroidal detachment retinal detachment with and without preoperative application of glucocorticoid in choroidal detachment retinal detachment and the effect on the success rate of retinal repositioning and the recurrence rate of retinal detachment.

**Methods:** A computerized search of CBM, Wanfang database, and China Knowledge Network was performed according to a pre-defined search strategy and supplemented by a web-based manual search. The search period was from January 1982 to December 2021. The literature of clinical studies with and without glucocorticoid application before boschotomy for the treatment of vein-denuded reticular dehiscence was included, and information was extracted on relevant parameters and data of the included literature. These included literature authors, trial type, number of eyes, number of patients, gender, follow-up time, mean age, type of hormone used preoperatively, duration of hormone use, surgical success rate, primary retinal repositioning rate, recurrence rate, and missed follow-up rate. The analysis indexes included the recurrence rate of retinal detachment  $\geq 6$  months after surgery, the success rate of surgery, and complications. Meta-analysis was performed using RevMan 5.0 software.

**Results:** A total of 19 randomized controlled trials with a total of 1119 eyes were included. Meta-analysis showed that there was a statistically significant rate of surgical success with and without hormone use prior to Pulsed retinal detachment surgery. The duration of preoperative hormone use was not statistically associated with surgical success. There was also no statistically significant difference between the use of hormones before surgery and the recurrence rate of retinal detachment  $\geq 6$  months after surgery.

**Conclusion:** There was a statistically significant difference in the rate of primary retinal repositioning with preoperative hormone use for choroidal detachment retinal detachment treated with botox, but there was no statistically significant difference in the rate of primary retinal repositioning with the length of preoperative hormone use. Due to the small amount of literature on choroidal detachment retinal detachment, and even less foreign literature and small sample size, the strength of the argumentation of the results of this systematic evaluation needs to be further tested.

PP-372

## Safety and Efficacy of Multiple Escalating Doses of RC28-E for Neovascular Age-Related Macular Degeneration

X Yu<sup>1</sup>, Y Lu<sup>2</sup>, J Fang<sup>3</sup>, H Dai<sup>2</sup>.

<sup>1</sup>Ophthalmology, Beijing Hospital, National Center of Gerontology, <sup>2</sup>Ophthalmology, Beijing Hospital, National Center of Gerontology, China., Beijing, <sup>3</sup>Shanghai Tongji Hospital, Tongji University, Shanghai, People's Republic of China

**Objective:** RC28-E is a novel bispecific antibody that simultaneously binds vascular endothelial growth factor (VEGF) and another key angiogenic factor, basic fibroblast growth factor (bFGF). A phase 1b study was conducted to assess the safety and efficacy of repeated intravitreal injections of RC28-E in patients with neovascular age-related macular degeneration (AMD).

**Methods:** This is a prospective, multicenter, open-label and multiple ascending-dose clinical trial. Patients with choroidal neovascularization secondary to AMD and a best-corrected visual acuity (BCVA) letter score of between 73 and 34 were enrolled. Treatment regimens consisted of a 3-month loading phase and a PRN maintenance phase, with escalating doses ranging from 0.5 to 2.0 mg. Safety was assessed based on ocular and nonocular adverse events (AEs), characteristics of pharmacokinetics, and the presence of anti-RC28-E antibodies. Efficacy was assessed by the mean change in BCVA and central subfield thickness (CST) from baseline to week 48.

**Results:** We enrolled 37 patients, with 12, 13 and 12 patients in the 0.5-, 1.0- and 2.0-mg groups, respectively. Most AEs were reported as mild or moderate. The most common AEs were minor injection-related conjunctival hemorrhages (16.2%). AEs did not increase with dose escalation or repeated injections, despite the increasing doses. At week 48, mean improvements in BCVA from baseline in the 0.5-, 1.0- and 2.0-mg groups were  $6.13 \pm 8.329$ ,  $9.85 \pm 10.731$  and  $7.60 \pm 9.378$  letters, respectively; mean reductions in CST in the 3 groups were  $112.1 \pm 160.54$ ,  $175.1 \pm 212.44$ , and  $128.7 \pm 145.81 \mu\text{m}$ , respectively. The serum RC28-E concentrations in 95% of patients were below the quantification limit of the assay. No significant change from baseline was observed in the mean plasma VEGF or FGF concentrations over 48 weeks of treatment. The pre-treatment antibodies to RC28-E were detected in 1 of the 37 patients. In another patient, after dosing with RC28-E for 48 weeks, antibodies to RC28-E were detected.

**Conclusion:** RC28-E was well tolerated and exhibited an overall favorable safety profile, with evidence of improvements in BCVA and anatomic parameters.

PP-374

**Vorinostat (SAHA) prevents photoreceptor degeneration in rd1 mouse**Y Dong<sup>1</sup>, K Jiao<sup>1</sup>, W xu<sup>1</sup>, Z hu<sup>1</sup>.<sup>1</sup>department of ophthalmology, Affiliated Hospital of Yunnan University, Kunming, People's Republic of China**Objective:** To investigate the efficacy of SAHA in preventing photoreceptor cell death in the rd1 mouse model for RP.**Methods:** C3H/HeA Pde6b rd1/rd1 animals (rd1) and their congenic wild-type C3H/HeA Pde6b+/+ counterparts (wt) were used for retinal explant cultures. Retinas were explanted at postnatal day 5 (P5) and treated with 1mM SAHA at P7 and P9 after two days' culture with Complete Medium. Cultures were ended on P11, after which TUNEL assay, cone-arrestin, calpain-2 immunofluorescence staining, PARP, calpain and HDAC activity assays were performed.**Results:** In rd1 mice, SAHA-treated retinas showed significantly lower positive cell rates in outer nuclear layer (ONL) than non-treated retinas ( $P < 0.05$ ). Cone-arrestin immunostaining showed the survival of cones was increased after SAHA intervention ( $P < 0.05$ ). Moreover, the activities of PARP, calpain and HDAC as well as calpain-2 activation were reduced by SAHA treatment in rd1 explants ( $P < 0.05$ ).**Conclusion:** SAHA showed a photoreceptor neuroprotective capacity for retinal explant in rd1 mice in vitro. Meanwhile, HDAC activation may occur upstream of PARP and calpain in the process of photoreceptor degeneration.

**PP-380****The relationship between the distribution of conjunctival vessels and the degree of optic nerve ischemia in patients with diabetes**

D Xue, X Luo, Y Zhang.

**Objective:** Aiming at the patients with diabetes retinopathy, we try to grade the distribution of conjunctival blood vessels and analyze the relationship between conjunctival blood vessels and the degree of optic nerve ischemia.

**Methods:** 231 patients (all with diabetes retinopathy) who underwent vitrectomy at the diabetes retinopathy center from January 2021 to January 2022 were selected. According to the results of anterior segment photography, the distribution of conjunctival blood vessels was graded (grade 0-4). At the same time, fundus photography, postoperative best corrected visual acuity, degree of proliferative diabetes retinopathy The optic disc color and other data were used as the basis of the degree of optic nerve ischemia, and the relationship between them was compared.

**Results:** The less the distribution of conjunctival vessels (above grade 3), the more severe the proliferative lesions of fundus, the more obvious the optic nerve ischemia, and the worse the best corrected visual acuity after operation. The classification of conjunctival vascular distribution is related to the degree of optic nerve ischemia.

**Conclusion:** For patients with diabetes retinopathy, the distribution of conjunctival vessels may well reflect the changes and progress of optic nerve and fundus conditions, and provide new tools and tips for ophthalmologists and patients' prognosis

PP-381

**Evaluation of the relationship between breast-feeding and the regression of retinopathy of prematurity(ROP)**

X Luo, D *Xue*, L *Yu*.

**Objective:** The effects of breast-feeding on the occurrence and regression of retinopathy of prematurity (ROP) were investigated

**Methods:** 2122 children screened for ROP in the children's eye disease center of Xi'an fourth hospital from October 2020 to February 2022 were divided into breastfeeding group and non breastfeeding group according to whether they were breastfed or not. The differences in the occurrence and development of ROP between the two groups were compared.

**Results:** The incidence of ROP in the breastfeeding group was lower than that in the non breastfeeding group, and the regression rate was higher than that in the breastfeeding group

**Conclusion:** Breastfeeding has an important impact on the occurrence and development of ROP

## PP-382

**The relationship between age and subfoveal choroidal thickness in Chinese patients with proliferative diabetic retinopathy**C Lei<sup>1</sup>, M Zhang<sup>1</sup>.<sup>1</sup>Ophthalmology, West China Hospital, Chengdu, People's Republic of China

**Objective:** To investigate the regularity of subfoveal choroidal thickness (SFCT) with age among Chinese patients with proliferative diabetic retinopathy (PDR).

**Methods:** This is a retrospective cross-sectional study. The subjects were hospitalized patients who underwent vitrectomy for PDR with type 2 diabetes at the Ophthalmology Department of West China Hospital of Sichuan University from May 2020 to February 2022, and PDR patients with contralateral eye meeting the criteria were included as subjects. All relevant laboratory tests were completed on admission. Quantitative assessments of enhanced depth imaging optical coherence tomography (EDI-OCT) included central macular thickness and SFCT were measured automatically and manually using digital calipers provided by Heidelberg Eye Explorer software, respectively.

**Results:** A total of 234 PDR subjects were enrolled in the final analysis. The mean age was  $55.60 \pm 10.03$  years old, 57.69% were male. The average axial length and SFCT were  $23.17 \pm 0.99$  mm and  $264.70 \pm 83.28$   $\mu$ m, respectively. The result of univariate analysis revealed a significantly negative association between age and SFCT in PDR patients ( $\beta = -2.44$ , 95% CI: -3.46, -1.42;  $P < 0.0001$ ). In fully adjusted model, the association between age and SFCT was consistent ( $\beta = -1.68$ , 95% CI: -2.97, -0.39;  $P = 0.0117$ ). The smooth curve fitting showed that the correlation between age and SFCT in PDR patients was nonlinear and the inflection point was the age of 54 years.

**Conclusion:** The study showed that age was negatively associated with the average SFCT of PDR patients and age around 54 might be an important turning point. Our results suggested that age is a key factor affecting choroid thickness and we should consider the non-linear association when we analyze the relationship between age and SFCT in PDR patients.

PP-383

**The association between lipid profile and subfoveal choroidal thickness in proliferative diabetic retinopathy**C Lei<sup>1</sup>, Q Ran<sup>1</sup>, M Zhang<sup>1</sup>.<sup>1</sup>Ophthalmology, West China Hospital, Chengdu, People's Republic of China

**Objective:** The association between lipid profile and subfoveal choroidal thickness in proliferative diabetic retinopathy

**Methods:** This is a retrospective cross-sectional study. The subjects were inpatients who underwent vitrectomy for PDR with type 2 diabetes at the Ophthalmology Department of West China Hospital of Sichuan University from May 2020 to February 2022, and PDR patients with contralateral eye meeting the criteria were included as subjects. Fasting laboratory values included serum lipid profile (e.g., triglyceride, total cholesterol, low-density lipoprotein cholesterol (LDL-C) and high-density lipoprotein cholesterol (HDL-C)), preoperative glycosylated hemoglobin A1c, renal profile, etc. All participants underwent enhanced depth imaging optical coherence tomography (EDI-OCT). Quantitative assessments of central macular thickness and SFCT were measured automatically and manually using digital calipers provided by Heidelberg Eye Explorer software, respectively. Multivariate linear regression analysis was used to detect the independent association between lipid profile and SFCT.

**Results:** The average age of the participants was  $55.76 \pm 9.88$  years old with 63.36% male. The average SFCT was  $276.10 \pm 92.92 \mu\text{m}$ , average axial length was  $23.22 \pm 1.02$  mm. The results of univariate analysis revealed a negative association between total cholesterol, HDL-C, and SFCT in PDR patients, respectively ( $\beta = -16.08$ , 95% CI: -29.25, -2.91;  $P = 0.0181$ ;  $\beta = -42.66$ , 95% CI: -81.44, -3.89;  $P = 0.0329$ ), while triglyceride was not significantly associated with SFCT ( $\beta = -3.01$ , 95% CI: -24.36, 18.34;  $P = 0.7828$ ). Multivariate linear regression model results showed in the fully adjusted model, triglyceride was not significantly associated with SFCT ( $\beta = 5.23$ , 95% CI: -18.57, 29.02;  $P = 0.6678$ ), while total cholesterol, HDL-C, LDL-C had a significantly negative association with SFCT, respectively ( $\beta = -16.51$ , 95% CI: -29.57, -3.46;  $P = 0.0148$ ;  $\beta = -42.65$ , 95% CI: -82.60, -2.70;  $P = 0.0390$ ;  $\beta = -17.89$ , 95% CI: -33.24, -2.54;  $P = 0.0245$ ). Furthermore, the results of stratified analysis showed that except for triglyceride, the trends of total cholesterol, HDL-C, LDL-C, and SFCT were consistent among different stratifications in PDR patients.

**Conclusion:** The cholesterol profile had a significantly negative association with SFCT in Chinese PDR patients, but triglyceride was not significantly associated with SFCT. All these systemic imbalances are prone to choroidal atherosclerotic changes and often coexist in diabetic patients.



PP-384

## CORRELATION OF CHOROIDAL THICKNESS WITH OCT BIOMARKERS IN DIABETIC MACULAR EDEMA IN INDIAN SCENARIO

I Acharya, N Yadav<sup>1</sup>, C Jayadev<sup>1</sup>, R Venkatesh<sup>1</sup>.

<sup>1</sup>retina, Narayana Nethralaya Foundation, Bangalore, India

**Objective:** To study the correlation between choroidal thickness and retinal OCT Biomarkers in Indian patients with diabetic macular edema (DME)

**Methods:** This is a retrospective observational study of 43 eyes of 30 patients with diagnosis of DME on OCT. Central Choroidal thickness (CCT) was measured subfoveally using the enhanced depth imaging (EDI) mode of spectral domain OCT on vertical line scan. A minimal follow up of 7 months was considered for the evaluation irrespective of any prior treatment received. Central foveal thickness (CFT) was also calculated.

**Results:** Mean age of our patients was  $64.97 \pm 08.95$  years with a male preponderance (72.1%). The best corrected visual acuity (BCVA) on presentation ranged from 20/20 to finger count at 1.5m. Majority had proliferative diabetic retinopathy (58.1%) followed by moderate (32.6%) to severe (9.3%) non-proliferative diabetic retinopathy. The mean CCT on presentation was  $274.51 \pm 80.03\mu\text{m}$  and mean CFT was  $456.58 \pm 189.45\mu\text{m}$ . Thicker CCT ( $>350\mu\text{m}$ ) was seen in 16.3% eyes out of which 71.4% eyes had hard exudates (HE) and ellipsoid zone (EZ)/external limiting membrane (ELM) disruption respectively. Thinner CCT ( $<250\mu\text{m}$ ) was observed in 44.2% eyes out of which 57.9% eyes had HE and 10.5% eyes had EZ disruption.

The patients were treated predominantly with intravitreal antiVEGFs (76.74%) followed by intravitreal steroids (48.84%). Few eyes also underwent focal (11.6%), modified grid (4.6%) and micropulse laser (2.3%). Mean follow up considered for final assessment was  $13.76 \pm 4.59$  months. 27.9% eyes did not receive any injection and 20.9% eyes received no treatment at all during the assessment period.

CCT was found to be decreased in 74.4% eyes and CFT in 46.5% eyes on the final assessment. Among eyes which did not receive any treatment during the evaluation period, 55.6% eyes had a reduced CCT and CFT respectively. There was no statistically significant difference in the choroidal thickness among eyes receiving treatment versus no treatment ( $p = 0.14$ ). Restoration of outer retinal layers was noted in only 6.97% eyes and all these eyes showed reduction of both CCT and CFT on the final outcome. Outer retinal layer disruption with previously intact layers was seen in 16.27% eyes among which 71.5% eyes had increased CFT and /or CCT and 28.6% eyes had decreased CFT and CCT. BCVA on the final assessment ranged from 20/20-20/200.

**Conclusion:** CCT in correlation with retinal OCT biomarkers may provide an insight to the overall prognostic outcomes in DME.

PP-385

**CLINICAL EVALUATION OF AYURVEDA-BASED INTEGRATIVE MANAGEMENT OF DIABETIC RETINOPATHY**S Sastry<sup>1</sup>, T Pradeep<sup>2</sup>, S Raman<sup>2</sup>.<sup>1</sup>Ramaiah Indic Specialty Ayurveda- Restoration Hospital, <sup>2</sup>Ramaiah Medical College Hospital, Bangalore, India

**Objective: Aim:** To evaluate the effectiveness of Ayurveda-based integrative management in reducing the manifestations of non-proliferative diabetic retinopathy such as cotton wool spots, dot-and-blot hemorrhages and macular exudates.

**Methods: Methods:** A prospective case control study was conducted with 10 patients in control group and 10 patients in the treatment group. After obtaining informed consent, all patients underwent a comprehensive Ophthalmic evaluation including anterior segment and posterior segment evaluation. Systemic investigations including the Fasting blood sugar, post prandial blood sugar and HbA1 C were recorded prior to recruitment. All patients underwent an optical coherence tomography of macula and fundus photograph at baseline and at 6 months. Patients were classified according to ETDRS classification and only those with mild and moderate NPDR without any macular involvement were included in the study. The control group were observed as per the ETDRS guidelines. The patients in treatment group were administered with ayurvedic local treatments for 7 days followed by internal medicines i.e. Nishakatakadi Kashayam, Kalashakadi Kashayam and Vasaguduchyadi Kashayam for 6 months

**Results: Results:** 10 patients in the treatment group with Ayurveda intervention, all belonging to mild to moderate NPDR. Out of 10 subjects, 8 have shown a significant reduction in the exudates and hemorrhages. 2 showed no changes in their clinical features. When compared to the control group there was an equivalence demonstrated.

**Conclusion: Conclusion:** Ayurveda can be a modality of treatment in the early stages of diabetic retinopathy thereby preventing its progression. Therapeutic strategies in Ayurveda are aimed at not only the management of diseases, but the promotion of health and well-being. The postulated preventive aspects of Ayurveda management may have an effect on the underlying pathology of diabetic retinopathy. Ayurveda advocates a whole-system approach that consists of a multipronged, personalized management strategy involving pharmacological interventions, *panchakarma* (detoxification) and modifications in diet and lifestyle.

PP-386

**Clinical findings and ocular manifestations in patients with Takayasu arteritis**Y Xiao.

**Objective:** To investigate the clinical characteristics and ocular findings of patients with Takayasu arteritis (TA) in order to improve the acknowledge of this rare inflammatory vasculitis.

**Methods:** From April 2019 to April 2022, a total of 15 TA patients were admitted to the Department of Rheumatology or Ophthalmology in Shandong Provincial Hospital. Their demographic data, clinical situations, laboratory examinations, vascular ultrasonography, ocular manifestations and detailed ophthalmic evaluations were retrospectively reviewed.

**Results:** There were 14 female patients and only 1 male patient. Mean age was  $36.4 \pm 9.9$  years. Extra-ophthalmologic manifestations of the disease include weaken or absent of peripheral pulse (10/15), numbness of limbs (8/15), cardiopathy (4/15), headache (4/15), spontaneous neck pain (3/15), fever (2/15) and hypertension (2/15). The most common classification of TA was type I (8/15), which involved aortic arch, brachiocephalic trunk, carotid and subclavian arteries. Others were type II (Abdominal aorta and/or renal arteries involved, 2/15) and type IV (combination of type I and type II, 5/15). Decreased vision was the most common ocular symptom (5/15). Best corrected visual acuity (BCVA) was NLP to 1.0. 4 eyes had a BCVA less than 0.1. 2 of them underwent cataract surgery while vision had no improvement after the surgery. 12 patients (23 eyes) underwent fundus fluorescein angiography (FFA) examination. FFA was completely normal in 8 eyes and Takayasu retinopathy was found in 13 eyes. Retinal or optic disc neovascular were observed in 5 eyes. Hypertensive retinopathy was recognized just in 1 patient. 7 patients with normal BCVA(53%) displayed obvious FFA abnormalities. Other ocular manifestations included chronic scleral hyperemia(5/30), calcific band keratopathy (1/30), iris neovascularization (2/30), dilated pupil(6/30), white cataract(1/30), posterior subcapsular cataract(2/30), vitreous hemorrhage(1/30), retinal detachment (2/30), and neovascular glaucoma (1/30).

**Conclusion:** Takayasu arteritis is a rare, inflammatory, and systemic large-vessel granulomatous vasculitis affecting mostly young women. TA has a high possibility for eye involvement and may lead to various ocular abnormalities. Chronic ischemic or hypoxia retinopathy is the most common fundus manifestations, which highlights the importance of earlier and detailed fundus examination. It is important for ophthalmologist to correctly recognize the clinical features of TA.

PP-387

**Choroidal and Retinal Abnormalities in Cushing syndrome: Correlation With Endogenous Cortisol Level**J Duan, M zhang.

**Objective:** Cushing's syndrome (CS) is associated with an increased risk of fundus changes. We aim to investigate anatomical and functional changes of retina and choroid, and evaluate their correlation with serum cortisol hormone level in CS patients with functional adrenal tumor. This research may give us a better understanding of the pathogenic mechanism of retinal and choroidal disease and provide more choices for the treatment of chorioretinopathy.

**Methods:** This study was a prospective study that included functional adrenal tumor CS patients treated by adrenalectomy. CS syndrome patients underwent a series of ophthalmologic examinations on the day before surgery and after the hormone level test was normal. The ophthalmologic examinations including visual acuity, retinal thickness and choroid thickness in different directions and level, the vessel density of retinal superficial capillary plexus and retinal deep capillary plexus, the flow signal of the choriocapillaris and choroidal large vessel. After the surgery of adrenalectomy, the hormone level of CS patients was evaluated by a urologist. We followed up with the patients after the hormone test was normal. The relationship of hormone level and baseline information, and the fundus change was evaluated in patients with functional adrenal tumor.

**Results:** In the prospective self-control study, we included 116 eyes of 58 patients of CS functional adrenal tumor. Patients had significantly greater central choroidal thickness and subfoveal retinal thickness before adrenoectomy than after adrenoectomy. The total area of choroid and the average area of the luminal to choroidal before adrenoectomy is higher than total area of choroid after adrenoectomy. The central retinal thickness in functional adrenal tumor patients was less before adrenoectomy, especially in the inferior part of fovea.

**Conclusion:** Patients with high cortisol level had a thicker choroid, larger choroidal volume and vascular area, and lower blood flow density in the choroid, compared to themselves with normal hormone levels after the surgery. It is suggested that the increase of serum cortisol leads to the dilatation of choroidal vessels, the increase of choroidal volume. This finding may suggest the pathogenesis of chorioretinopathy.

PP-389

**Eye Stroke in the Young: A Case Series**A Sandig, E Palisoc<sup>1</sup>.<sup>1</sup>*Ophthalmology, Jose Reyes Memorial Medical Center, Manila, Philippines***Objective:** To report a rare case of CRAO in two teenage patients.**Methods:** A case series.

**Results:** *Case 1:* A 16-year-old female with sudden painless visual loss in her left eye. Her best-corrected visual acuity was hand movement with good light projection in the left eye. Anterior segment and intraocular pressure (IOP) were normal except a positive relative afferent pupillary defect in the left eye. Further investigation revealed a mild aortic and mitral valve regurgitation on echocardiogram. Other ancillary tests were within reference limits. *Case 2:* A 19-year-old male with sudden painless visual loss in the left eye. He was diagnosed with Double Outlet Right Ventricle at birth. On examination, his visual acuity was 5/200 in the left eye with a left relative afferent pupillary defect. Anterior segment examination and IOP were unremarkable. Fundus exam for both patients revealed a pale retina, constriction of retinal vessels and typical “cherry-red spot” suggestive of CRAO. Ocular massage and oral carbonic anhydrase inhibitor was given. Both patients were referred to pediatrics for further evaluation and management.

**Conclusion:** The cardiac valve findings and the rare congenital heart disease may most likely be a source of paradoxical embolism leading to retinal artery occlusion. However, this report emphasized the need for a rigorous analysis to exclude treatable and serious systemic disorders. Thus, other etiologies such as connective tissue disorder and hypercoagulability states cannot be completely ruled out and must be further explored.

**PP-391****Correlation of vitamin D3 level with severity of diabetic retinopathy.**B Maji.

**Objective:** To determine the relation between vitamin D3(active metabolite of vitamin D),which is an inhibitor of angiogenesis, and progression of Diabetic retinopathy.

**Methods:** In this hospital- based cross - sectional observational study ,patient satisfying all inclusion and exclusion criteria from those presenting at the institute were included in this study pool.100 cases were included. A thorough history taking, clinical examination including Snellen chart and logMAR chart ,slit lamp examination for anterior segment, indirect ophthalmoscopy with 20 D lens examination for posterior segment was documented .Vitamin D3 level was also checked .Then all the gathered data was compared and correlation between them established. All standard statistical tools was used to analysis the data.

**Results:** In our patients, a significant( $p < 0.001$ ) decrease in vitamin D3 level was found with increase severity of diabetic retinopathy. Out of 100 patients 72 patients correlate with the findings.

**Conclusion:** Insufficiency of vitamin D3 is associated with increased severity of diabetic retinopathy. Serum vitamin D3 levels  $< 12$  ng/ml serve as an indicator for proliferative disease, among diabetic retinopathy patients.

PP-395

**Combination treatment of Pre retinal hemorrhage secondary to PDR with Intravitreal Anti-VEGF injections and PRP laser.**

M Brar, S Grewal<sup>1</sup>, D Grewal, M Sharma, M Dogra<sup>1</sup>.

<sup>1</sup>Grewal eye institute, Chandigarh, India, Chandigarh, India

**Objective:** To evaluate the outcome of intravitreal Bevacizumab/Ranibizumab injections and pan retinal photocoagulation (PRH) in fovea involving pre retinal hemorrhage in proliferative diabetic retinopathy (PDR).

**Methods:** Retrospective non-comparative cross sectional series of patients diagnosed with fovea involving PRH secondary to PDR at our institute from March 2019 to October 2021 who were treated with combination treatments of intravitreal Anti-VEGF and pan retinal photocoagulation (PRP) and has completed a minimum 6 month follow up. Primary outcome measure was serial changes in the visual acuity and PRH regression from the fovea. Secondary outcome measures were the quantitative assessment of size of PRH and to assess its association with visual acuity improvement and time to regression and also to evaluate proportion of patients who underwent PPV surgery for poor response.

**Results:** 23 eyes of 22 patients showed regression of PRH from the foveal center at 33.6 days and complete regression was seen at 140.7 days. Average number of IVT Anti-VEGF required for clearance of PRH from the fovea was 1.6. Mean Log MAR visual acuity improve from 0.54 at baseline to 0.32 at 4 weeks 0.18 at 6 months (P<0.01). Three eyes (13.6%) required vitrectomy surgery during follow up. Mean area of PRH as measured by Image J analysis was 14.1mm at baseline and 9.06mm at 4 weeks and 2.87mm at 3 months. No statistically significant difference was seen between the size of PRH and PRH clearance time and visual acuity improvement. No systemic side effects were observed following the intravitreal injections during follow up.

**Conclusion:** Intravitreal Anti-VEGF injections and pan retinal photocoagulation was found to be effective and safe treatment method for fovea involving pre retinal hemorrhage secondary to proliferative diabetic retinopathy. Long term studies are warranted to assess the long term efficacy

## PP-398

**Changes of Visual Field Defects after Selective Intra-arterial Thrombolysis for Central Retinal Artery Occlusion**

? 费<sup>1</sup>, ? 吴<sup>2</sup>, ? 赵<sup>1</sup>.

<sup>1</sup>上海交通大学医学院附属新华医院, 上海, <sup>2</sup>上海交通大学医学院, 上海市, *People's Republic of China*

**Objective:** To investigate the short-term temporal changes in visual field defects (VFDs) in eyes with acute central retinal artery occlusion (CRAO) after selective intra-arterial thrombolysis (IAT).

**Methods:** Medical records for 27 eyes of 27 patients diagnosed with acute non-arteritic CRAO within 14 days of symptoms onset were all through examination with Humphrey perimetry and treated by IAT from July 2020 until March 2022. The visual field examination results include visual field index (VFI) and mean deviation (MD) before IAT and during the early follow-up periods ( $\leq 7$ -day) were recorded to investigate the changes.

**Results:** The mean age of patients in this study was  $51.11 \pm 13.42$  years (23-71 years) including 18 males and 9 females. The mean time from symptom onset to IAT was  $112.37 \pm 94.62$  hours (16-312 hours). Comparison of the mean VFI and MD were made before and after IAT and improvements were found in both indexes. The VFI was  $19.85 \pm 27.058\%$  at the first visit,  $25.19 \pm 34.222\%$  ( $Z = -1.924$ ,  $P = 0.054$ ) after IAT within 7 days. The MD was  $-26.99 \pm 7.502\text{dB}$  vs.  $-24.84 \pm 10.554\text{dB}$  ( $Z = -2.008$ ,  $P = 0.045$ ). Improvements in the visual field were found in 7 out of 27 patients (25.9%) of all cases during the early follow-up periods ( $\leq 7$ -day). There were no significant differences of the baseline characteristics including age, gender, and symptom onset time to IAT between the two groups. However, there were significant differences of baseline MDs and VFIs between the two groups. The baseline MDs were  $-20.01 \pm 6.266\text{dB}$  and  $-29.44 \pm 6.354\text{dB}$  in the improvement group and no improvement group respectively ( $Z = -2.822$ ,  $P = 0.005$ ) while the baseline VFIs were  $45.43 \pm 25.94\%$  and  $10.90 \pm 21.54\%$  ( $Z = -2.835$ ,  $P = 0.005$ ) respectively.

**Conclusion:** Selective IAT can be helpful in patients with CRAO and the MD may be more significant than the VFI index in terms of visual field improvement. The better baseline VFI and MD indicating milder initial VFDs may be associated with better prognosis after IAT.



PP-399

**The efficacy and safety of dexamethasone intravitreal implant for DME and ME-RVO:a meta-analysis of randomized controlled trials**L Xiaodong<sup>1</sup>, X Xuejun<sup>1</sup>.<sup>1</sup>Chengdu University of Traditional Chinese Medicine, Chengdu, People's Republic of China

**Objective:** The purpose of this meta-analysis was to evaluate the efficacy and safety of dexamethasone intravitreal implant (DEX) for the treatment of diabetic macular edema (DME) with retinal vein occlusion secondary to macular edema (RVO-ME).

**Methods:** Relevant databases were searched to include randomized controlled trials (RCTs) evaluating DEX for DME and RVO-ME. The search was conducted until March 2022. Meta-analysis was performed using Rev Man 5.4.1 software after screening the literature by inclusion and exclusion criteria, extracting information and evaluating the methodological quality of the included studies.

**Results:** The study showed that DEX treatment of RVO-ME was associated with an improvement in best corrected visual acuity (BCVA) (MD= -9.08, 95% CI: -10.89—-7.27, P<0. 00001) and central retinal thickness (CRT) (MD = 93.47, 95%CI: 28.55—159.39, P=0.005) , DEX treatment of DME was significantly better than anti-VEGF treatment in terms of CRT reduction (MD = -72.35, 95%CI: -115.0—-29.69, P=0.0009); The safety study showed that the risk of cataract from RVO-ME (RR = 5. 06, 95%CI: 1.96 to 13.06, P = 0.0008) and the incidence of high intraocular pressure (RR = 6.67, 95%CI:3.46 to 12.86, P< 0.00001) were significantly higher with DEX than with anti-VEGF therapy; the risk of cataract from DME (RR=4.70, 95%CI:2.10 to 10.54, P=0.0002) was significantly higher with DEX than with anti-VEGF therapy. (RR=4.70, 95%CI: 2.10 to 10.54, P=0.0002) and the incidence of high IOP (RR=13.77, 95%CI:4.96 to 38.18, P<0.00001) were significantly higher with DEX than with anti-VEGF therapy.

**Conclusion:** In patients with DME and RVO-ME, DEX was more efficacious but slightly less safe than anti-VEGF therapy.

**PP-401****Association between integrity of foveal photoreceptor layer and visual outcome in retinal vein occlusion-macular edema**

Y RU<sup>1</sup>, Y Shi<sup>2</sup>.

<sup>1</sup>First clinical medical college, Shanxi Medical University, <sup>2</sup>Department of Ocular Fundus Diseases, Shanxi Eye Hospital, Taiyuan, People's Republic of China

**Objective:** To explore the Association between integrity of foveal photoreceptor layer and visual outcome in retinal vein occlusion-macular edema with the help of spectral—domain optical coherence tomography image features of patients with macular edema due to retinal vein occlusion.

**Methods:** This was a prospective case series study. Thirty patients (30 eyes) with RVO-ME were selected according to the Inclusion and exclusion criteria and received examinations of best corrected visual acuity, intraocular pressure, slit lamp microscope, and SD-OCT. To analyze the correlation of photoreceptor integrity with the value of visual acuity improvement after treatment; And compared the correlation of initial BCVA (LogMAR) with post-treatment BCVA.

**Results:** The value of visual acuity improvement after treatment was negatively correlated with initial CMT ( $r = -0.667$ ,  $P < 0.05$ ), initial ELM defect length ( $r = -0.824$ ,  $P < 0.05$ ), and initial EZ band defect length ( $r = -0.785$ ,  $P < 0.05$ ), but not with age of onset ( $r = -0.177$ ,  $P = 0.538$ ). There was a positive correlation between initial BCVA and post-treatment BCVA ( $r = 0.674$ ,  $P < 0.05$ ).

**Conclusion:** Photoreceptor integrity may serve as an important indicator of prognosis visual acuity in patients with RVO-ME, Visual acuity at initial diagnosis was also a significant predictor of visual acuity after resolution of edema in RVO-ME patients.

## PP-402

**Association of Cognitive Function with Neurofilament light chain in the Aqueous humor of the eye**J Bai<sup>1</sup>, Q Peng<sup>1</sup>.<sup>1</sup>Shanghai Tenth People's Hospital of Tongji University, Shanghai, People's Republic of China

**Objective:** To evaluate the clinical predictive role of Neurofilament light chain (NfL), amyloid- $\beta$  ( $A\beta$ ), glial fibrillary acidic protein (GFAP), and phosphorylated tau at threonine 181 (p-tau181) proteins in aqueous humor and to quantify retinal macular microvascular parameters by OCTA as early diagnostic markers of AD.

**Methods:** This is a prospective, single-site, cross-sectional cohort study. A total of 59 patients were recruited, including 39 patients with neovascular age-related macular degeneration and 20 individuals with senile cataract. The single-molecule array (Simoa) platform was used to quantitatively measure the levels of aqueous humor NfL,  $A\beta$  40,  $A\beta$  42, GFAP, and p-tau181. The Mini - Mental State Examination (MMSE) scores were used to assess the global cognitive function. OCTA was used to quantify the microvascular densities of superficial retinal capillary plexuses (SRCP), deep retinal capillary plexuses (DRCP) and foveal avascular zone (FAZ)-related parameters. Linear regression was used to test associations after adjustment for age, sex and the education level of patients.

**Results:** NfL,  $A\beta$  40,  $A\beta$  42, GFAP, and p-tau181 was detected in all aqueous humor samples. Individuals with Cataract had higher concentrations of NfL and p - tau181, but lower concentrations of  $A\beta$  40 and  $A\beta$  42 compared with those with nAMD. In AMD group, there is significant associations between the levels of NfL and the  $A\beta$  42 ( $P = 0.051$ ), higher levels of  $A\beta$  40 were associated with higher levels of  $A\beta$  42 ( $P < 0.0001$ ). Lower MMSE scores showed a negatively correlation with the concentration of NfL ( $P = 0.043$ ) in the aqueous humor. In addition, AD biomarkers do correlate with superficial and deep macular vessel density, FAZ area and FAZ perimeter (PERIM), but not related with retinal thickness. In cataract group, the NfL concentration mild positively correlated with the concentration of  $A\beta$  40 ( $P = 0.126$ ),  $A\beta$  42 ( $P = 0.205$ ), and GFAP ( $P = 0.021$ ). Besides, the  $A\beta$  42 concentration showed positive correlation with  $A\beta$  40 concentration ( $P < 0.0001$ ). Additionally, Lower MMSE scores showed a negatively correlation with the concentration of NfL ( $P = 0.032$ ).

**Conclusion:** This study serves as a foundation for further investigation of above AD-related biomarkers in the ocular fluids. The examination of AD-related biomarkers content in human aqueous humor and OCTA may improve ocular-based AD detection methods then contribute to forestall the progression of preclinical AD.

PP-403

### Quantitative Evaluations of Posterior Staphylomas in Highly Myopic Eyes by Ultra-Widefield Optical Coherence Tomography

N Nakao<sup>1</sup>, T Igarashi-Yokoi<sup>1</sup>, H Takahashi<sup>1</sup>, S Xie<sup>1</sup>, K Shinohara<sup>1</sup>, K Ohno-Matsui<sup>1</sup>.

<sup>1</sup>Tokyo Medical and Dental University, Bunkyo-ku, Japan

**Objective:** To determine the shape of posterior staphylomas using ultra-widefield optical coherence tomographic (UWF-OCT) images and to identify the factors contributing to the shape and grade of the staphylomas in eyes with pathologic myopia.

**Methods:** This was an observational case series study. Highly myopic patients who were  $\geq 40$ -years-old with a wide or narrow type of macular staphylomas were studied. High myopia was defined as a myopic refractive error (spherical equivalent) greater than -8.0 diopters (D) or an axial length (AL)  $> 26.5$  mm. The aspect ratio of the pixel resolution of the 12 radial scans of the UWF-OCT were equalized by the ImageJ software. The maximum diameter and depth of the staphylomas were measured in the UWF-OCT images by ImageJ and were compared between the two types of staphylomas.

**Results:** We studied 197 eyes of 138 patients with a mean age of  $64.7 \pm 10.4$  years and mean AL of  $30.0 \pm 1.9$  mm. The AL was significantly longer in the eyes with the narrow type than the wide type of staphyloma ( $P = 0.036$ ). Multiple regression analyses showed that the age had the highest significant correlation with the maximum depth/maximum diameter ratio ( $P < 0.001$ ) of the wide type staphyloma. The AL was significantly correlated with the depth/diameter ratio of the narrow type of staphylomas ( $P < 0.001$ ).

**Conclusion:** The significant correlations of the age and AL with the wide and narrow type of posterior staphylomas indicate that the factors for their formations may be distinctly different. Quantitative analyses of UWF-OCT images are helpful in determining the shape of the staphylomas.

PP-404

**Retinal vascular abnormalities in facioscapulohumeral muscular dystrophy**P Fei, N Yang, P Zhao.

**Objective:** Facioscapulohumeral muscular dystrophy (FSH) is a rare clinical syndrome characterized by severe muscle weakness started, with extramuscular manifestations such as retinal vascular tortuosity, sensorineural hearing loss and epilepsy. This study is to report retinal vascular abnormalities in facioscapulohumeral muscular dystrophy (FSH) patients.

**Methods:** Four patients of FSHD were found to have retinal vascular abnormalities. Visual acuities and fundus were examined carefully to record the retinal vascular abnormalities.

**Results:** This study included one FSHD family (the father and the daughter) and two sporadic FSH cases. There are two males and two females, with the age ranging from 7-65 years old. All these patients were diagnosed as FSHD by the neurologists. The fundamental fundus abnormality was retinal vessels telangiectasia. The severity of the retinal vascular abnormalities varied in patients, including extensive exudative retinitis resembling Coats' disease (CD), complicated central retinal vein occlusion, tortuosity of *retinal vessels* and tiny peripheral retinal vessel telangiectasia. The treatment included laser coagulation of abnormal retinal telangiectasia or anti-VEGF therapy if necessary.

**Conclusion:** Retinal telangiectasis may complicated in FSHD patients and be sight threatening. Patients with early detection of retinal vascular problems and timely treatment may have good prognosis. Wnt signaling affects both vasculogenesis and myogenic programs. It may play an important role in FSHD.

## PP-405

**Efficacy of intravitreal pegcetacoplan in patients with geographic atrophy (GA): results from the phase 3 OAKS and DERBY studies.**

R Guymer<sup>1</sup>, C Wykoff<sup>2</sup>, G Staurenghi<sup>3</sup>, R Singh<sup>4</sup>, N Steinle<sup>5</sup>, D Boyer<sup>6</sup>, J Monés<sup>7</sup>, F Holz<sup>8</sup>, C Bliss<sup>9</sup>, P Deschatelets<sup>9</sup>, F Grossi<sup>9</sup>, C Francois<sup>9</sup>, R Ribeiro<sup>9</sup>.

<sup>1</sup>Centre for Eye Research Australia, University of Melbourne, Melbourne, Australia, <sup>2</sup>Houston Methodist Hospital, Houston, United States, <sup>3</sup>Luigi Sacco Hospital, Milan, Italy, <sup>4</sup>Cole Eye Institute, Cleveland, <sup>5</sup>California Retina Consultants, <sup>6</sup>Cedars-Sinai Medical Center and Good Samaritan Hospital, Los Angeles, United States, <sup>7</sup>Institut de la Màcula Centro Médico Teknon, Barcelona, Spain, <sup>8</sup>University of Bonn, Bonn, Germany, <sup>9</sup>Apellis, Waltham, United States

**Objective:** Geographic atrophy (GA) secondary to age-related macular degeneration (AMD) is a prevalent chronic disease that leads to blindness. There are no treatments currently available for GA. The efficacy and safety of monthly or every-other-month (EOM) intravitreal pegcetacoplan injections are being evaluated in two phase 3, randomized, double-masked, sham-controlled trials, OAKS and DERBY.

**Methods:** Enrolled patients were 60 years of age or older, had a best-corrected visual acuity of 24 ETDRS letters or more, and a GA lesion area between 2.5 and 17.5 mm<sup>2</sup>, or if multifocal at baseline, at least one focal lesion 1.25 mm<sup>2</sup> or greater. Ocular history of active choroidal neovascularization in the fellow eye was not an exclusion criterion. The primary endpoint for both studies was change in GA lesion size via fundus autofluorescence imaging from baseline to Month 12. Safety measures included incidence of ocular and systemic adverse events.

**Results:** A total of 1,258 GA patients were enrolled in OAKS and DERBY. At month-12, OAKS showed statistically significant reductions in GA lesion growth compared with sham in the monthly and EOM arms by 21% (p=0.0004) and 16% (p=0.0055), respectively. DERBY did not reach statistical significance; pegcetacoplan decreased GA lesion growth compared with sham by 12% (p=0.0609) and 11% (p=0.0853) in the monthly and EOM arms, respectively.

Exudative AMD rates in the pooled studies were 6.0%, 4.1%, and 2.4% for monthly, EOM, and sham, respectively. Rate of infectious endophthalmitis was consistent with other trials with intravitreal injections. Additional efficacy and safety data up to Month 18 will be reported.

**Conclusion:** OAKS met its primary endpoint, with positive trends also observed in DERBY. Pegcetacoplan demonstrated an acceptable safety profile. Taken together with the positive results from the well-controlled phase 2 FILLY study, these findings support the efficacy of pegcetacoplan in slowing the progression of GA lesions.

PP-407

## Dosing and delivery methods of steroids for DME and ME secondary to RVO: a systematic review and meta-analysis

A Mihalache<sup>1</sup>, A Hatamnejad<sup>2</sup>, N Patil<sup>2</sup>, M Popovic<sup>3</sup>, P Kertes<sup>3,4</sup>, R Muni<sup>3,5</sup>.

<sup>1</sup>Faculty of Science, University of Western Ontario, London, <sup>2</sup>Michael DeGroot School of Medicine, McMaster University, Hamilton, <sup>3</sup>Department of Ophthalmology and Vision Sciences, University of Toronto, <sup>4</sup>John and Liz Tory Eye Centre, Sunnybrook Health Sciences Centre, <sup>5</sup>Department of Ophthalmology, St. Michael's Hospital/Unity Health Toronto, Toronto, Canada

**Objective:** We aimed to evaluate the comparative safety and efficacy of different doses and delivery methods of steroids for diabetic macular edema (DME) and macular edema (ME) secondary to retinal vein occlusion (RVO).

**Methods:** We performed a systematic literature search on OVID Medline, EMBASE, and Cochrane Central from January 2005 to November 2021 for RCTs reporting on safety and efficacy outcomes stratified by dose or delivery method for steroid injections in DME and ME secondary to RVO. Primary outcomes were BCVA and change in BCVA from baseline. Secondary outcomes were retinal thickness (RT), change in RT from baseline, and adverse events. We used a random effects model to perform meta-analysis. Risk of bias was assessed with Cochrane's risk of bias tool 2 and certainty of evidence was assessed using GRADE recommendations.

**Results:** 16 RCTs reporting on 3,708 eyes at baseline were included in this meta-analysis. Changes in BCVA from baseline were similar between 1 mg and 4 mg intravitreal triamcinolone acetonide (IVTA) ( $p=.56$ ) and between 2 mg and 4 mg IVTA ( $p=.58$ ). Changes in RT were non-significantly different between 1 mg and 4 mg IVTA ( $p=.28$ ). Patients treated with 4 mg IVTA had a significantly higher incidence of increased IOP (RR=0.38, 95%CI=[0.22,0.65],  $p=.0004$ ) and cataract surgery (RR=0.26, 95%CI=[0.10,0.71],  $p=.009$ ) than 1 mg IVTA. The risk of increased IOP was similar between 2 mg and 4 mg IVTA ( $p=.58$ ), as well as 4 mg and 8 mg IVTA ( $p=.39$ ). 8 mg IVTA was associated with a significantly better final BCVA than 4 mg IVTA (WMD=0.19 logMAR, 95%CI=[0.09,0.30],  $p=.0004$ ). Final BCVA and RT were similar between IVTA and subtenon triamcinolone acetonide (STTA) ( $p=.32$ ). Change in RT was similar between 0.35 mg and 0.7 mg intravitreal dexamethasone (IVD) ( $p=.50$ ), but high dose IVD resulted in a higher incidence of vitreous floaters (RR=0.41, 95%CI=[0.19,0.87],  $p=.02$ ). Eyes treated with 0.2 µg/d fluocinolone acetonide underwent cataract surgery less frequently than 0.5 µg/d (RR=0.92, 95%CI=[0.85,0.99],  $p=.03$ ).

**Conclusion:** The RCT evidence in this setting is currently limited for nuanced treatment decision-making. High dose IVTA was associated with better final BCVA, however 1-4 mg were similar in efficacy. 4 mg IVTA may have a less favorable safety profile than 1 mg, given a higher risk of cataract development and increased IOP. 0.35 mg and 0.7 mg IVD were similar in efficacy. Comparisons between IVTA and STTA were non-significantly different.

PP-408

**Downregulation of FABP 4  
alleviates lipid peroxidation and oxidative stress  
in DR by regulating PPAR  $\gamma$  -mediated ferroptosis**

F Xiaoe.

**Objective:** This study aims to explore the role of fatty acid binding protein 4 (FABP4) in diabetic retinopathy (DR), and to elucidate the potential regulatory mechanism.

**Methods:** We firstly developed a mouse model of DR by injection with streptozocin (STZ) into C57BL/6 male mice and a cell model of DR by induction of high glucose (HG) to ARPE-19 cells. BMS309403, an inhibitor of FABP4, was employed for treatment. The blood glucose *in vivo* was monitored and the histological changes of retinal tissues were observed by hematoxylin and eosin staining and Evans blue assay. The expression level of FABP4 was detected by western blot and Immunohistochemical staining. The critical factors related to lipid peroxidation and oxidative stress were detected using their commercial kits, respectively. Prussian blue staining, iron content assay and thiobarbituric acid-reactive substances (TBARS) assay were conducted to evaluate ferroptosis.

**Results:** As a result, FABP4 was elevated in retina and serum of STZ-induced mice and in HG-induced ARPE-19 cells. BMS309403 treatment notably alleviated reduced blood glucose, reduced histological damage, and vascular permeability. In addition, BMS309403 treatment inhibited lipid peroxidation, oxidative stress, and ferroptosis both *in vivo* and *in vitro*. Furthermore, BMS309403 promoted the activation of peroxisome proliferator-activated receptor  $\gamma$  (PPAR  $\gamma$ ). GW9662 (an inhibitor of PPAR  $\gamma$ ) or Erastin (an inducer of ferroptosis) partially weakened the suppressive effects of BMS309403 on HG-induced lipid peroxidation, oxidative stress and ferroptosis.

**Conclusion:** Taken together, FABP4 inhibition alleviates lipid peroxidation and oxidative stress in DR by regulating PPAR  $\gamma$  -mediated ferroptosis.



PP-410

## Prediction of Response to Anti-VEGF Treatment in Diabetic Macular Edema Using an OCT-based Machine Learning Method

J Cao, J Ye<sup>1</sup>.

<sup>1</sup>*Ophthalmology, the Second Affiliated Hospital of Zhejiang University, College of Medicine, Hangzhou, People's Republic of China*

**Objective:** To predict the anti-vascular endothelial growth factor (VEGF) therapeutic response of diabetic macular edema (DME) patients from optical coherence tomography (OCT) at the initiation stage of treatment using a machine learning based self-explainable system.

**Methods:** A total of 712 DME patients were included and classified into poor and good responder groups according to central macular thickness decrease after 3 consecutive injections. Machine learning models were constructed to make predictions based on related features extracted automatically using deep learning algorithms from OCT scans at baseline. Five-fold cross validation was applied to optimize and evaluate the models. The model with the best performance was then compared with 2 ophthalmologists. Feature importance was further investigated, and a Wilcoxon rank-sum test was performed to assess the difference of a single feature between two groups.

**Results:** Of 712 patients, 294 were poor responders and 418 were good responders. The best performance for the prediction task was achieved by random forest (RF), with sensitivity, specificity, and area under the receiver operating characteristic curve of 0.900, 0.851, and 0.923. Ophthalmologist 1 and ophthalmologist 2 reached sensitivity of 0.775 and 0.750, and specificity of 0.716 and 0.821, respectively. The sum of hyperreflective dots was found to be the most relevant feature for prediction.

**Conclusion:** An RF classifier was constructed to predict the treatment response of anti-VEGF from OCT images of DME patients with high accuracy. The algorithm contributes to predicting treatment requirements in advance, and provides an optimal individualized therapeutic regimen.

## PP-411

**Impact of Systemic Dexamethasone on Diabetic Retinopathy in SARS-CoV-2 Associated Intensive Care Unit Admission**

S Chuah<sup>1</sup>, T Hui<sup>1</sup>, N Kumaran<sup>2,3</sup>, R Wong<sup>1,2,3</sup>.

<sup>1</sup>Guy's, King's & St Thomas' School of Medicine, King's College London, <sup>2</sup>Ophthalmology Department, St Thomas' Hospital, Guy's and St Thomas' NHS Foundation Trust, London, <sup>3</sup>Frimley Park Hospital, Frimley Health NHS Foundation Trust, Frimley, United Kingdom

**Objective:** Dexamethasone has been the mainstay choice of treatment for SARS-CoV-2 since the publication of the RECOVERY trial findings on June 16, 2020, making it the first-time systemic steroids were prescribed at such a scale. However, glucocorticoids are known to have a profound impact on glycaemic control, reflected by the rise in steroid-induced diabetes in SARS-CoV-2 patients. Poor glycaemic control is also a major risk factor for the progression of diabetic retinopathy. This study aims to explore the impact of the SARS-CoV-2 steroid regime on the progression of diabetic retinopathy in a selected cohort admitted to the Intensive Care Unit (ICU).

**Methods:** We retrospectively analysed diabetic retinopathy data in all diabetic patients admitted to the ICU at St Thomas' Hospital, London with SARS-CoV-2 between 31/10/2020 to 16/01/2021. All patients received a regime of 6mg weaning dose of dexamethasone.

We excluded deaths, patients outside our catchment area, hospital transfers, and patients who did not attend screenings. Our final cohort was n=21 patients. Parameters of data collection included: type 1/type 2 diabetes, length of ICU admission, immediate pre-admission and post-discharge gradings for each eye, the time between screenings, and the time between discharge and follow-up screening.

**Results:** Of the 21 patients: the mean age was 58.5 years; 48% were male (n=10) and 52% were female (n=11); and all patients had type-2 diabetes. The mean time between ICU discharge and follow-up was 149.3 days (SD:  $\pm$  76.8 days) and the mean time between screenings was 648.9 days (SD:  $\pm$  286.8 days). Chi-squared tests demonstrated no statistically significant progression in either retinopathy or maculopathy ( $p = 1.00$  and  $p = 0.486$  respectively).

**Conclusion:** The use of a weaning dose of 6mg Dexamethasone was shown to have no clinically significant effect on retinopathy and maculopathy, suggesting that this is a safe regime for diabetic eye disease. Long-term follow-up studies comparing a similar cohort to a non-SARS-CoV-2 cohort are recommended to further review the safety of systemic steroids.

PP-412

## Methotrexate for the Treatment of Proliferative Vitreoretinopathy in Rhegmatogenous Retinal Detachment: A Systematic Review

M Balas<sup>1</sup>, A Abdelaal<sup>1</sup>, M Popovic<sup>2</sup>, P Kertes<sup>2,3</sup>, R Muni<sup>2,4</sup>.

<sup>1</sup>Temerty Faculty of Medicine, <sup>2</sup>Department of Ophthalmology & Vision Sciences, University of Toronto, <sup>3</sup>John and Liz Tory Eye Centre, Sunnybrook Health Sciences Centre, <sup>4</sup>Department of Ophthalmology, St. Michael's Hospital/Unity Health Toronto, Toronto, Canada

**Objective:** Proliferative vitreoretinopathy (PVR) is a severe complication of rhegmatogenous retinal detachment (RRD) repair that is characterized by ectopic fibrocellular proliferation that grows on the surface of, within, and underneath the retina and is associated with poor visual outcomes. This systematic review evaluates the role of methotrexate (MTX) as an adjunctive agent for the prevention and treatment of PVR in RRD.

**Methods:** Articles investigating the use of MTX in at least five patients with PVR or at high risk of developing PVR in patients with RRD were identified via a systematic search of OVID MEDLINE (1946-April 21, 2021), EMBASE (1946-April 21, 2021), and the Cochrane Controlled Register of Trials (up to May 2021). Results were presented using descriptive statistics. The Risk of Bias in Non-randomized Studies of Interventions (ROBINS-I) tool and the Grading of Recommendations, Assessment, Development and Evaluation (GRADE) system were used to evaluate all studies for the risk of bias and quality of outcomes.

**Results:** A total of five studies and 85 eyes from 85 patients were included. Five eyes were at high risk of developing PVR, while all remaining patients (n=80) had already developed PVR. The highest number of total MTX injections in a single eye was eight, with an average of 1.88 injections per patient and doses ranging from 250µg to 400µg. No complications related to MTX administration were reported. After 16 months of follow-up, there was an 89% retinal re-attachment rate and 0.79 logMAR improvement in visual acuity for patients receiving MTX. Control patients had a re-attachment rate of 61% and a 0.37 logMAR improvement.

**Conclusion:** Intravitreal MTX targets many pathophysiological processes of PVR through its antiproliferative, anti-inflammatory and anti-fibrotic effects. This systematic review is the first to examine the role of adjunctive intravitreal MTX in the setting of PVR and found that MTX improves retinal re-attachment rates and post-operative visual acuity across a wide range of treatment parameters while maintaining an acceptable safety profile. Further research with larger, controlled cohorts and standardized treatment regimens are needed to further characterize the role of intravitreal MTX in patients with RRD and or at high risk for PVR.

## PP-413

**Risk of intraocular inflammation after injection of anti-vascular endothelial growth factor agents: a network meta-analysis**

N Patil, A Dhoot, M Popovic, P Kertes, R Muni.

**Objective:** Recent literature suggests a potentially increased risk of intraocular inflammation (IOI) following brolocizumab relative to aflibercept. Novartis reported an association between brolocizumab dosed every four weeks and a higher risk of retinal vasculitis and retinal vascular occlusion. In the interest of patient safety, the MERLIN, RAPTOR, and RAVEN trials, which were designed to test brolocizumab dosed every four weeks, were terminated. However, it is unknown whether significant IOI is evidenced following traditional dosing regimens of brolocizumab. This network meta-analysis investigates the incidence of intraocular inflammation (IOI) following intravitreal anti-VEGF injections in neovascular age-related macular degeneration (nAMD).

**Methods:** A systematic search was performed on Ovid MEDLINE, EMBASE and Cochrane CENTRAL from January 2005 to April 2021. Study screening and selection was conducted by two independent reviewers with conflicts resolved by consultation with a third reviewer. Randomized controlled trials (RCTs) comparing IOI following intravitreal bevacizumab, ranibizumab, brolocizumab, or aflibercept in nAMD were included. Primary outcomes were sight-threatening IOI, final best corrected visual acuity (BCVA) and change in BCVA from baseline. Secondary outcomes included the incidence of other IOI events. Data were analyzed via network meta-analysis.

**Results:** Overall, 11460 unique studies were screened, of which 14 RCTs and 6759 eyes at baseline were included. There was no difference between agents for the risk of endophthalmitis and retinal vascular occlusion. Compared to aflibercept, brolocizumab had a higher incidence of generalized intraocular inflammation (RR=6.24, 95% CI=[1.40,27.90]) and vitreous haze/floaters (RR=1.63, 95% CI=[1.01,2.65]). There were no significant differences between comparators for other secondary endpoints.

**Conclusion:** There was no difference in the risk of severe sight-threatening IOI outcomes between intravitreal anti-VEGF agents. There was a significantly higher risk of generalized intraocular inflammation following brolocizumab relative to aflibercept. Our results alongside other recent safety findings suggest the need for further investigation in the risk-benefit profile of brolocizumab for the treatment of nAMD.

## PP-414

**Safety and efficacy of a treat and extend regimen for DME and ME secondary to RVO: a systematic review and meta-analysis**

N Patil, A Dhoot, P Nichani, M Popovic, R Muni, P Kertes.

**Objective:** Treat-and-extend treatment regimens are commonly used for the treatment of neovascular age-related macular degeneration. The safety and efficacy of this regimen relative to others for diabetic macular edema (DME) and macular edema (ME) secondary to retinal vein occlusion (RVO) remains poorly understood. This meta-analysis evaluates the comparative safety and efficacy of a treat-and-extend regimen relative to monthly and pro re nata (PRN) regimens using anti-vascular endothelial growth factor (VEGF) agents for DME and ME secondary to RVO.

**Methods:** A systematic literature search was conducted on Ovid MEDLINE, EMBASE, and Cochrane Library from inception to December 2021. Comparative studies evaluating the efficacy and safety of a treat-and-extend regimen relative to a monthly or PRN regimen with anti-VEGF therapy for DME or ME secondary to RVO were included. Other treatment modalities, non-comparative studies, and non-English studies were excluded. Cochrane's risk of bias tool 2 and ROBINS-I were used to assess risk of bias and GRADE evaluation was conducted to assess certainty of evidence. A random effects meta-analysis was conducted.

**Results:** Seven studies of 984 eyes were included in this analysis. Relative to a monthly regimen, treat-and-extend was not significantly different for the change in BCVA from baseline to 12 months ( $p=0.74$ ), 24 months ( $p=0.39$ ), and final follow-up ( $p=0.59$ ). There was a lower mean number of injections (WMD=-1.54, 95% CI=[-2.01, -1.06],  $p<0.00001$ ) compared to a monthly regimen. Relative to a PRN regimen, treat-and-extend was not significantly different for final BCVA or change in BCVA from baseline to 12 months ( $p=0.15$ ;  $p=0.85$ ), 24 months ( $p=0.69$ ;  $p=0.78$ ) and final follow-up ( $p=0.34$ ;  $p=0.84$ ), and was associated with a higher mean number of injections (WMD=4.74, 95% CI=[0.83, 8.65],  $p=0.02$ ). There was no difference for safety outcomes between treat-and-extend and monthly or PRN regimens.

**Conclusion:** This meta-analysis found that a treat-and extend regimen was non-inferior to monthly and PRN treatment regimens in efficacy and safety endpoints for the management of DME or ME secondary to RVO. There was a significantly greater injection frequency of a treat-and-extend regimen relative to a PRN protocol, and significantly lesser injection frequency relative to a monthly regimen. Overall, there is a paucity of literature in this domain and further investigation is warranted.

## PP-415

**Control of IOP increase in Intravitreal Injection of anti VEGF using topical beta blocker or prostaglandin inhibitor**

N *Fung*<sup>1</sup>, J *Chan*<sup>1</sup>, Y *Lau*<sup>2</sup>.

<sup>1</sup>*Department of Ophthalmology,* <sup>2</sup>*The University of Hong Kong, Hong Kong, Hong Kong, China*

**Objective:** This study aims at investigating and comparing the effectiveness of topical beta blocker and prostaglandin inhibitor in controlling the increase in IOP after intravitreal injection of Anti-VEGF. The primary outcome of the study is the change in IOP with two types of prophylactic medications and without any IOP lowering medications over multiple time periods. The secondary outcomes are the effect of intravitreal injection in IOP and the response of IOP to the number of injections, IOL and type of anti VEGF.

**Methods:** This is a prospective randomized three-arm crossover study which includes a total of 60 patients. The inclusion criteria of the study population are (a) patients with AMD, (b) not necessarily 3 month loading; (c) age > 50 and Chinese patients. Patients are randomized by envelope method into three groups which will receive all three treatments (Timolol, Hypromellose, Travatan) subsequently. Prophylactic eye drops are given according to the treatment group one hour prior to the injection and the time period is denoted as T0. IOP will be taken just before the injection as T1 and immediately after the injection all without speculum while sitting on table as T2. After 30 minutes the IOP is taken again and denoted as T3.

Linear mixed model was used to evaluate the carryover effect of the Crossover Trial. Two-way within-subjects repeated measures ANOVA was conducted to determine whether any change in IOP response was the result of the interaction between the "types of treatments" and "timepoints". Multiple linear regression analysis was used to evaluate the IOP response in correlation to number of injections, IOL and type of anti VEGF.

**Results:** A significant interaction between the types of treatments and timepoints is found. Among all three treatments, timolol shows a prominent effect in reduction of IOP at T1 and T3 while the effect of Travatan in IOP is only marginal notably lower than that in Hypomellose group. A lower IOP reduction at T3 was only significantly and independently associated with phakic eyes. Times of previous injections affect the change of IOP between T1-T0 and T3-T0.

**Conclusion:** This study shows the change of IOP is similar in all three groups in different times, but Timolol is more significantly effective in reducing IOP than Travatan. Phakic eyes and times of previous injections are found to affect the change of IOP after injections. IOP Prophylaxis is suggested for incorporated into the injection procedure.

PP-416

## Analysing the Challenges in Implementation of the RCOphth 2020 Hydroxychloroquine Retinopathy Screening Guidelines in a UK Trust

M Noor<sup>1</sup>, R Khan<sup>2</sup>, S Kafle<sup>3</sup>.

<sup>1</sup>The Rochdale Eye Unit, Northern Care Alliance NHS Foundation Trust, Rochdale, <sup>2</sup>Ophthalmology, Evolutio Care Innovations Ltd., Henley-On-Thames, <sup>3</sup>Rochdale Eye Unit, Northern Care Alliance NHS Foundation Trusts, Rochdale, United Kingdom

**Objective:** The aim of our study was to analyse the implementation of the 2020 Royal College of Ophthalmologists guidelines for hydroxychloroquine retinopathy screening at Rochdale Eye Unit, Northern Care Alliance Trusts, UK, alongwith identification of challenges and areas for development.

**Methods:** A retrospective analysis of patients visiting the department between Feb – March 2022 was performed. Using the 2020 RCOphth guidelines as a “gold standard” screening clinic checklist, data was collected determining if the patients fulfilled screening criteria, if the department’s data collection system identified patients with risk factors for developing retinopathy, the investigations undertaken, documentation and communication of the diagnosis, and selection of an appropriate outcome. Data was exported to and analysed using Microsoft Excel.

**Results:** 54 patients visited the department during Feb-March 2022, 14 males and 40 females, 100% of whom were on HCQ therapy. 37% (33/54) did not meet the screening criteria. A paper proforma comprising of drug, dose, duration, renal disease, tamoxifen use, and macular co-morbidity was completed at each screening visit, however, did not include patient’s ethnicity, weight (to calculate cumulative dose), or renal function. 96% (52/54) patients had an SD-OCT, 98% (53/54) patients underwent FAF, and 22% (12/54) undertook VF-10-2. No standardisation was used in documentation of presence/absence of investigation findings. Whilst 100% of diagnoses were communicated to the GP but there no was evidence of written information about HCQ retinopathy being sent to patients as per guidelines. 33% (18/54) patients did not have the correct outcome including re-invitation for annual review despite early treatment cessation or prior to >5 years of HCQ treatment.

**Conclusion:** To address the encountered challenges, we recommend review and if appropriate cancellation of bookings unfulfilling screening criteria (with letter to referrer and patient), devising a more comprehensive proforma including weight, ethnicity, and renal function, and a five point clinician’s checklists outlining 1) evidence based features of HCQ retinopathy changes in SD-OCT, FAF, and HVFs to standardise interpretation and diagnosis 2) prompting the use of recommended diagnostic terms, 3) prompt for giving written patient information about retinopathy screening and 4) advise to inform DVLA regarding driving 5) selection of appropriate outcome (discharge vs annual monitoring).

PP-417

**A preliminary observation on rod cell photobiomodulation in treating diabetic macular edema****Z Chen<sup>1</sup>.**

<sup>1</sup>*Ophthalmology, Second Affiliated Hospital, School of Medicine, Zhejiang University, Hangzhou, People's Republic of China*

**Objective:** To evaluate the safety and effectiveness of photobiomodulation (PBM) in the treatment of diabetic macular edema (DME).

**Methods:** It was a single-center, self-controlled prospective study. The clinical records of 12 diabetic retinopathy patients (5 males and 7 females, 20 eyes in total) who were treated with PBM for DME at the Second Affiliated Hospital, Zhejiang University School of Medicine, were analyzed. The mean age was 56 (26-68) years. All the participants received PBM treatment during darkness at night in no less than 5 days per week and no less than 8 hours per day. In the baseline check and follow-up checks (1, 2, 6, 10, and 12 months after the start of treatment), the best-corrected visual acuity, the thickness of the retina in the macula, and the changes of the fundus lesions were observed. Wilcoxon signed rank test was used to compare the results before and after treatment.  $P < 0.05$  was considered statistically significant.

**Results:**

No fundus complication was observed during follow-up checks. In baseline and 12-month follow-up checks, the best-corrected visual acuity was  $71.75 \pm 12.47$  and  $79.50 \pm 10.85$ , maximal retinal thickness in macular area was  $390.95 \pm 77.12 \mu\text{m}$  and  $354.13 \pm 55.03 \mu\text{m}$ , average retinal thickness in macular area was  $334.25 \pm 36.45 \mu\text{m}$  and  $314.31 \pm 33.28 \mu\text{m}$ , foveal thickness was  $287.00 \pm 46.79 \mu\text{m}$  and  $265.63 \pm 67.14 \mu\text{m}$ . The best-corrected visual acuity, average retinal thickness in macular area results in consecutive follow-up results except that in the 1st month showed significant difference compared with baseline results. There were significant difference between every follow-up visit and baseline results of maximal retinal thickness in macular area ( $P < 0.05$ ). All follow-up results of foveal thickness were not significantly different ( $P > 0.05$ ) from the baseline result, except that in the 6th month ( $P = 0.049$ ). Obvious improvement could be observed in retinal fundus fluorescein angiography images.

**Conclusion:** PBM is a safe and effective treatment of DME, which deserves further investigation.



PP-418

**Possible cause of retinal vein occlusion in Remdesivir treated Covid -19 case report**D Mitra, D Saha<sup>1</sup>.<sup>1</sup>*Ophthalmology, ADEA Diabetic Eye Care, Kolkata, India*

**Objective:** Remdesivir with antibiotics were administered to fight the dreadful disease of Covid -19 during the second wave in Kolkata. Covid -19 itself has reported as causative of multiple ocular symptoms. We report a case which developed a retinal branch vein occlusion after suffering from the disease and being given Injectable Remdesivir on three occasions along with Injectable Doxycycline. Injectable Meropenam, steroids in nebulizer and injectable anticoagulants .

**Methods:** A 63 year old female reported with diminished vision post hospitalisation for covid -19. She had maintained good vision in her right eye after cataract surgery one and half year back . In her left eye she had advanced cataract , diagnosed one and half year back and surgery delayed due to pandemic. She lost vision in the only functional pseudophakic right eye. Her blood glucose levels were normal and rest vitals maintained. Her vision in right eye had dropped from 6/6 postoperative to 6/24 after hospitalisation. Her left eye vision was 6/60 with advanced cataract . The fundus in right eye revealed superotemporal branch retinal vein occlusion with macular oedema . On OCT the macular thickness and nearly doubled . In left eye fundus picture was hazy but the macular thickness appeared within normal limits . She was advised antivegf in right eye and an immediate cataract surgery in left which showed good chance of recovery post operatively .

**Results:** Covid -19 disease has reported vasculitis as one of the ocular manifestations of the disease. . During hospitalisation the patient received moist oxygen 4litres per minute along with steroid in nebulizer ,anticoagulant injection ,injectables Meropenam and Doxycycline. She also received injection Remdesivir on three alternate days . Both Remdesivir and Doxycycline have rarely reported bleeding as a side effect . None have revealed any particular ocular vision threatening side effect. Simultaneous use of high dosed antibiotics with antivirals and steroids in a immunocompromised state might be a cause of retinal vasculopathy.

**Conclusion:** Covid -19 itself or because of the treatment process used to cure the disease, might be the cause of retinal vein occlusion in this case. Further such reports might throw more light on this issue .

PP-419

**Vitamin A Deficiency Nyctalopia in a Case of Alcoholic Liver Disease: Can Serum Retinol Levels be Relied Upon?**R R Nadig<sup>1</sup>, R Raman<sup>1</sup>.<sup>1</sup>Sankara Nethralaya, Chennai, India

**Objective:** Vitamin A deficiency induced night blindness has been studied extensively. However, the correlations between serum retinol levels, electroretinogram (ERG) changes and visual symptoms remain uncertain. Thus, serum retinol levels and ERG changes were assessed in correlation to visual symptoms in our case.

**Methods:** We report a curious case of a 52 year old man who presented with diminution of vision in both eyes during the night time since 15 days. Given his history of chronic alcohol consumption and jaundice 2 weeks back, vitamin A deficiency was contemplated as the most probable underlying cause.

**Results:** At presentation, Best Corrected Visual acuity (BCVA) in the right eye was 6/7.5, N6 and left eye was 6/12, N8. Both eyes were pseudophakic and revealed mild retinal pigment epithelium changes at the macula with a tessellated background on fundus examination. ERG showed diminished scotopic and photopic responses and serum retinol was 17  $\mu\text{g}/\text{dl}$ . On supplementation with Vitamin A, symptoms improved, BCVA in both eyes were 6/6, N6 with fundus examination similar to initial visit. ERG was normal, however, serum retinol levels were still low - 8.98  $\mu\text{g}/\text{dl}$ .

**Conclusion:** Thus, our case proposes that serum retinol monitoring does not necessarily indicate response to treatment and validates the need for ERG monitoring in cases of Alcoholic Liver Disease induced Vitamin A deficiency nyctalopia.

PP-420

**Occupational Photic Retinopathy: An Underestimated Cause of Unexplained Vision Loss?**V Jadhav<sup>1</sup>, S Padhy<sup>2</sup>.

<sup>1</sup>LV Prasad Eye Institute, Bhubaneswar, India, <sup>2</sup>Anand Bajaj Retina Institute, LV Prasad Eye Institute, Bhubaneswar, India

**Objective:** To demystify the probable cause of vision loss in a stage musician in the settings of coexistent photic retinopathy and ethambutol related toxic optic neuropathy.

**Methods:** A 39-year-old gentleman, a night club musician, presented with deterioration of vision with central scotoma in left eye for 1 month. He was earlier diagnosed to have tuberculosis of urinary bladder and was started on Anti-Tubercular Therapy (ATT). However, he developed blurring of vision 4 months post ATT with a subsequent diagnosis of ethambutol optic neuropathy. This culminated in stoppage of ATT with subsequent complete visual recovery. The best corrected vision at presentation was 20/20 in right eye and 20/30p in the left eye.

**Results:** The fundus was unremarkable apart from subtle temporal pallor. Optical coherence tomography revealed a well-defined sharply cut rectangular outer retinal layer loss in bilateral eyes, more prominent in the left eye. Humphreys visual field shows bilateral central scotoma corresponding to the macular lesions. Visual evoked responses revealed a delay in implicit time and a decreased amplitude of P100 waveforms. Multifocal electroretinogram documented stunted waveforms corresponding to the outer retinal pathology at the macula. Corroborating with his occupational history at a night club with exposure to laser light unprotected, led to a probable diagnosis of super added photic retinopathy in the settings of recovered toxic optic neuropathy leading to vision loss and central scotoma.

**Conclusion:** Photic retinopathy can occur as an occupational hazard in people having accidental exposure to laser lights, especially night club musicians. We here present a case of incidental finding of photic retinopathy in the settings of coexistent ethambutol related toxic neuropathy.

PP-421

**Spontaneous Resolution of Combined cilioretinal artery and central retinal vein occlusion complicating COVID-19 Infection**

R Maamouri<sup>1</sup>, Z Salem<sup>1</sup>, W Nabi<sup>1</sup>, F Nafaa<sup>1</sup>, M Ouederni<sup>1</sup>, M Cheour<sup>1</sup>.

<sup>1</sup>hospital habib thameur, Tunis, Tunisia

**Objective:** To report a case of combined cilioretinal artery and central retinal vein occlusion (CRVO) that regressed spontaneously in a COVID-19 patient.

**Methods:** A single case report.

**Results:** A 35-year-old male presented to our department with two-weeks history of rapid onset blurred vision of the right eye (OD). His past medical history was significant for symptomatic COVID-19 infection, three weeks before beginning of ocular symptomatology. Visual acuity was 20/100 OD and 20/20 in the left eye (OS). Slit lamp examination and intraocular pressure were normal. Ophthalmoscopy in OD revealed dilated and tortuous retinal vessels, disc edema, cotton-wool spots and moderate superficial hemorrhages with a limited area of retinal whitening extending from the optic disc to the macula. The OS examination was unremarkable. Complete blood tests, infectious, immunologic and hemodynamic diseases were ruled out. One week after presentation, OD visual acuity started to improve spontaneously. Two months later, after regular follow-up visual acuity was 20/20 in OU and fundus examination was normal with spontaneous complete disappearance of the cilioretinal artery and central retinal vein occlusion signs.

**Conclusion:** Central retinal venous occlusion is currently acknowledged as a potential complication of covid 19-infection. Nonetheless, it has the distinctive feature of spontaneously healing in some cases with a good visual prognosis, like in our case despite the associated ciliary artery occlusion.

## PP-422

**Effect of intravitreal anti-vascular endothelial growth factor injection on ocular structures and functions in eyes with wAMD**

J Tsui<sup>1</sup>, Y Lau<sup>2</sup>, N Fung<sup>1</sup>.

<sup>1</sup>Department of Ophthalmology, <sup>2</sup>The University of Hong Kong, Hong Kong, Hong Kong, China

**Objective:** To investigate the effect of intravitreal anti-vascular endothelial growth factor (VEGF) injections on the ocular structural and functional parameters in patients with wet AMD.

**Methods:** Patients diagnosed with wet AMD receiving at least 1 anti-VEGF injection were recruited into this study. Patients with a history of glaucoma, ocular hypertension or steroid were excluded. Studied eyes were divided into injection group and control group based on their injection history. Structural and functional measures were collected including axial length (AL), central corneal thickness (CCT), lens status, optic disc measures, best-corrected visual acuity (BCVA), intraocular pressure (IOP) and visual field. Control group was further divided according to AL, CCT and lens status to address the impact of potential confounding factors. Student's t-test and Pearson correlation coefficient were used to assess the relationship of structural and functional parameters between injection group and control group.

**Results:** 145 eyes from 73 patients were recruited to this cross-sectional study, with a total of 89 eyes receiving anti-VEGF injections and 56 fellow eyes without previous anti-VEGF injection. In injection group, 57 patients received unilateral injection, while 16 patients received bilateral injection. In the control group, a significantly reduced thickness of retinal nerve fibre layer was detected in patients with thin CCT and long AL. A significant lower density of radial peripapillary capillary (RPC) was found in patients with long AL and pseudophakic eyes. In the injection group, patients with bilateral injection showed a strong correlation in optic disc measures and IOP between the right and left eyes. In the unilateral injection group, paired t-test showed that the RPC vessel density was significantly lower in inferior-hemi peripapillary region, as compared with the control group. No significant difference was found in optic disc measures between bilateral and unilateral injection groups.

**Conclusion:** This study found that intravitreal anti-VEGF injection potentially affects the optic disc in wet AMD patients as indicated by the significant lower RPC vessel density in injection eyes than the paired control eyes. Bilateral injection, axial length, central corneal thickness, and lens status were suggested to be the correlation factors of optic disc measures in wet AMD patients.

PP-423

**Unilateral Proptosis: a Case Report of Neglected Sphenoid Wing Meningioma in Primary Health Center**I Alberta<sup>1</sup>, R Shen<sup>2</sup>, M Tjahjadi<sup>3</sup>.

<sup>1</sup>General Practitioner, Puskesmas Sumberpitu Primary Health Care, Pasuruan, <sup>2</sup>Department of Surgery, <sup>3</sup>Department of Surgery, Neurosurgery Division, School of Medicine and Health Sciences, Atma Jaya Catholic University of Indonesia, Jakarta, Indonesia

**Objective:** To report a case of unilateral proptosis from neglected sphenoid wing meningioma in primary health center.

**Methods:** We describe a patient with obvious unilateral proptosis and blurry vision on right eye for 4 years.

**Results:** On examination, there was no light perception, obvious proptosis (30 mm), exodeviation, and ophthalmoplegia. Head CT showed an regular lesion, well defined, and broad-based on the right sphenoid wing. Brain MRI also showed homogenous enhancement extra-axial mass lesion upon the right and left suprasellar regions with right sphenoid wing hyperostosis. Patient diagnosed with sphenoid wing meningioma which complicate into proptosis and blindness.

**Conclusion:** We emphasise that primary health care in low-middle income countries should overcome the low level of public education, self-awareness of health, and tendencies to reject referral process. Clinicians also have crucial role in early detection and prompt treatment to reduce further neglected case.

PP-424

**A case of retinal disease mimics optic neuropathy**S Li<sup>1</sup>.<sup>1</sup>*Department of Ophthalmology, Xiang'an Hospital of Xiamen University, Xiamen, People's Republic of China***Objective:** To evaluate a case and family with occult macular dystrophy mimic optic neuropathy.**Methods:** The patient and his parents, sister underwent ophthalmic imaging and functional tests, including vision, refraction, ultra-wide fundus photography, fundus autofluorescence, OCT, visual field, ERG and VEP, etc. Genetic testing was whole exome sequencing.**Results:** The case of proband was 10 years old, whose chief complaint is bilateral vision loss for 4 years. BCVA:OD - 8.50/-1.00 × 145=0.3, OS -7.75/-1.25 × 45=0.5. He was previously diagnosed as retrobulbar optic neuritis and Leber optic neuropathy separately, and underwent steroid pulsing therapy and genetic testing, without any positive effect and gene mutation. Moreover, the IgG tests of anti-MOG and AQP4 were negative, his orbit MRI was normal. The current ophthalmic tests showed normal fundus photograph, mildly blurred outer retina structure in OCT, decreased cone function in ffERG and mfERG, normal peak time in VEP. All these data indicated retinal disease, not optic neuropathy. The targeted next generation sequencing showed same mutations of RP1L1 in the proband, his mother and sister: c.133C>T:p.R45W. So the diagnosis is bilateral occult macular dystrophy, bilateral high myopia. The mother of the proband showed following manifestation: BCVA 1.0 in both eyes, normal OCT appearance, but mfERG showed decreased amplitude density in the central P1 wave.**Conclusion:** The phenotype of RP1L1 mutation may have heterogeneity, even in the same family. It may be helpful to evaluate OCT, ERG and VEP in this kind of disease, for the sake of differential diagnosis between retinal disease and optic neuropathy.

PP-425

**Frontal Meningioma Debuts with Ophthalmological Complications: Foster Kennedy syndrome**R Pineda Oliveros<sup>1</sup>, M Molina Pérez<sup>1</sup>, A Parra Morales<sup>1</sup>, B Framiñan Aparicio<sup>1</sup>.<sup>1</sup>Ophthalmology, Hospital Universitario de Salamanca, Salamanca, Spain

**Objective:** To describe a rare case of Foster Kennedy Syndrome (FKS) in a patient with an advanced tumor, who did not seek for medical evaluation until ophthalmological symptoms emerged secondary to high intracranial pressure.

**Methods:** Case report

**Results:** A 39-year-old woman, with a history of pregnancy less than 2 years ago, presented to our emergency department due to a sudden painless decrease in visual acuity in the right eye (RE) of 4 days. During the anamnesis, she described headaches of moderate-severe intensity of approximately 2 years duration, waking up occasionally at night from pain, transient visual obscurations and tinnitus, for which she had not consulted. On ophthalmological examination, the visual acuity was counting fingers at 1 meter on the RE and 1.0 on the left eye (LE), she also had a right relative afferent pupillary defect. Funduscopy showed a pale right optic disk with blurred temporal borders and edema of the left optic disk.

Visual field examination revealed complete field loss of the RE and concentric reduction with preservation of central vision of the LE. A cranial computed tomography demonstrated a voluminous right frontal tumor suggestive of meningioma, with bifrontal growth, causing compression of the third ventricle and dilation of the lateral ventricles. A diagnosis of FKS was established. The patient was referred to the neurosurgery department with successful surgical treatment of the lesion during the next two weeks. Over the ensuing 10 months, the papilledema in the left eye had resolved, but sadly the visual acuity didn't improve and the campimetric defects remained.

**Conclusion:** Frontal lobe tumors can dramatically increase in size causing subtle symptoms that may be overlooked before they are discovered. FKS is an infrequent entity resulting from an intracranial mass, that may cause irreversible damage to the optic nerve axons, therefore early diagnosis and treatment is important. Although, a potential correlation of hormonal changes and the natural history of meningiomas according to the literature is still questionable, meningiomas may progress following a pregnancy. Our case highlights the importance of the ophthalmologist in the initial approach to this syndrome, which should be taken into account in headaches with unusual characteristics associated with visual changes.



PP-426

**Pituitary apoplexy secondary to dengue hemorrhagic fever in acromegaly: a Rare Case**S Dewiputri<sup>1</sup>, A Permana<sup>2</sup>, T Tarigan<sup>3</sup>, R Yunus<sup>4</sup>.

<sup>1</sup>Ophthalmology, Faculty of Medicine Universitas Indonesia- Dr Cipto mangunkusumo hospital, <sup>2</sup>Neurosurgery, Faculty of Medicine Universitas Indonesia -Cipto Mangunkusumo Hospital, <sup>3</sup>Internal Medicine, Faculty of Medicine Universitas Indonesia - Cipto Mangunkusumo Hospital, <sup>4</sup>Radiology, faculty of Medicine Universitas Indonesia-Dr Cipto Mangunkusumo Hospital, Jakarta, Indonesia

**Objective:** To describe a rare case of pituitary apoplexy secondary to dengue hemorrhagic fever (DHF) in acromegaly.

**Methods:** A case report. A 34-year-old male came to the eye clinic with a right droopy eyelid and headache. Three weeks before, he was admitted to another hospital with a high-grade fever and was treated as DHF. There was a sudden blurred vision in both eyes. There was no history of vomiting, altered sensorium, seizure, weakness, head trauma, hypertension, or anticoagulant therapy. He denied any history of fatigue, decreased libido, profuse sweating, or weight loss. On examination, he was alert and oriented with normal vital signs. Clinical examination showed mandibular prognathism, broad nose, thickened lips, and prominent supraorbital ridges. Ophthalmology examination revealed best visual acuity was 6/24 and 6/12 for the right eye (RE) and left eye (LE), respectively. There was 15° exotropia, ptosis, and ophthalmoplegia of the right eye. The pupil of RE was mid dilated and sluggish in reaction. The fundus of both eyes was normal. Humphrey perimetry showed bitemporal hemianopsia, meanwhile, ganglion cell analysis showed thinning on the nasal retina. Patient was diagnosed with complete ophthalmoplegia and bitemporal hemianopsia due to suspicion of pituitary apoplexy. Urgent brain MRI showed hypo hyperintense mass in the sella-suprasellar compressed optic chiasm, right cavernous sinus, and internal carotid artery suggestive of pituitary apoplexy. His pituitary hormonal assay showed elevated plasma growth hormone, decreased level of luteinizing hormone (LH), cortisol, and thyroid-stimulating hormone (TSH). The patient received intravenous steroids and then was planned to undergo urgent trans sphenoid decompression.

**Results:** Two weeks after immediate trans sphenoid decompression, there was an improvement in visual acuity of both eyes to 6/12 and 6/6 for RE and LE, respectively and also in visual field defect. Then, patient was planned to receive octreotide acetate.

**Conclusion:** Dengue hemorrhagic fever may cause thrombocytopenia, leading to apoplexy in pre-existing pituitary adenoma. Pituitary apoplexy is a medical and surgical emergency that needs a multidisciplinary team approach with a neurosurgeon, endocrinologist, and radiologist. Prompt identification and evaluation are imperative to improve outcomes.

PP-427

**Large Ophthalmic Segment Aneurysm With Anterior Optic Pathway Compression**P Ganne<sup>1</sup>, D Syamala<sup>1</sup>, D Slesser<sup>1</sup>.<sup>1</sup>Ophthalmology, AIIMS, Mangalagiri, Guntur, India

**Objective:** Ophthalmic segment aneurysms are rare lesions that become symptomatic only when they are quite advanced or when complicated by subarachnoid hemorrhage (SAH). We report a case of ophthalmic segment aneurysm in a middle-aged lady who had presented with insidious onset of mild headache and visual disturbance.

**Methods:** A 48-year-old hypertensive lady presented with decreasing vision in both eyes and recurrent headaches. BCVA was 6/9 in the right eye (RE) and 6/6 in the left eye (LE). Color vision was grossly impaired in the RE. Extra-ocular movements were full in both eyes. RAPD was present in the RE. Fundus examination revealed temporal pallor of the optic disc and a cup-disc ratio of 0.6:1 in the RE. LE was normal. Intraocular pressure was 16mmhg in both eyes.

**Results:** Visual field testing (30-2) showed a generalized reduction of sensitivity and focal depressed points in superior and inferior visual fields in the RE and a normal visual field in the LE. OCT showed peripapillary RNFL thinning (nasal and superior quadrants) in the RE. MRI and MRA of the brain and orbits showed a large fusosaccular aneurysm (9mm × 9mm × 16mm) arising from the ophthalmic segment of the right ICA compressing the cisternal segment of the right optic nerve (ON). The patient was planned to undergo microsurgical clipping of the aneurysm.

**Conclusion:** In the current case, the visual acuity was relatively well-preserved, and visual field analysis did not reveal significant defects. However, the other findings like the presence of RAPD, disc pallor, color vision deficits, and RNFL thinning prompted us image the brain and orbits. Ophthalmologists should carefully elicit RAPD, and pick up color vision deficits and optic nerve head pallor in cases presenting with unexplained gradual unilateral or bilateral vision loss. The presence of any of these signs indicates anterior optic pathway disease and should be investigated thoroughly using visual field analysis and peripapillary RNFL thickness assessment on OCT. Contrast-enhanced MRI with thin sections along with MRA will help diagnose such aneurysms in the early stage and improve surgical and visual outcomes.

PP-428

**Concurrent posterior uveitis and optic neuritis in a patient with Crohn's disease**Q Xiao, C Du, X Lv, C SUN.

**Objective:** To report the clinical characteristics of concurrent optic neuritis and occult uveitis in a patient with Crohn's disease (CD).

**Methods:** A 54-year-old male with 20 years history of CD complained of sudden visual loss in the right eye. Ophthalmic examination revealed normal anterior segment and swollen optic disc in both eyes, accompanied by serous macular detachment in the right eye. Fundus fluorescein angiography showed fluorescein leakage and hyperfluorescence of optic disc in both eyes. Visual field test showed inferior arcuate scotoma in the right eye, and normal in the left eye. Optical coherence tomography showed macular serous detachment and parapapilla intrarenal edema in the right eye and normal image in the left eye. Ultrasonic biological microscope revealed bilateral ciliary detachment. The patient was diagnosed as optic neuritis in the right eye. Patient underwent 3 days' intravenous steroid therapy, but visual acuity didn't improve. Fourteen days later, his visual acuity in the right eye deteriorated to hand motion, and the patient was referred to our eye center.

**Results:** After intravenous steroid therapy of six days followed by sequential tapering of oral prednisone for three months. His vision increased to 14/20, Ophthalmic examination revealed normal in both eyes except pale optic disc in the right eye.

**Conclusion:** concurrent optic neuritis and occult uveitis are rare ophthalmic manifestations of Crohn's Disease. Steroid is still efficient therapeutic choice for this condition .

PP-430

**Structural and functional retinal disturbances following Sildenafil citrate overdose**

R Dhiman, V Gupta<sup>1</sup>, S Phuljhele<sup>1</sup>, R Saxena<sup>1</sup>.

<sup>1</sup>*Ophthalmology, Dr. RP Centre for Ophthalmic Sciences, New Delhi, India*

**Objective:** To evaluate the structural and functional retina changes induced by sildenafil overdose in a patient

**Methods:** Single retrospective case report

**Results:** A 32 year healthy young male presented with sudden onset bilateral photophobia following the intake of 18 tablets of sildenafil citrate (100mg each) as an act of dare. Although the visual acuity was 20/20, his color vision and contrast sensitivity were markedly affected. Visual fields revealed central scotomas. Multifocal ERG showed reduced amplitude in the macular area. Adaptive optics revealed several dark spots in the cone mosaic. On follow-up at 1 month, central visual field defects and cone mosaic abnormalities were persistent.

**Conclusion:** Overdose of sildenafil citrate, a common drug used for erectile dysfunction, can cause macular damage especially affecting the photoreceptors

## PP-431

**Bilateral papilledema as the first manifestation of meningeal carcinomatosis in a patient with lung adenocarcinoma**

B *Framinan Aparicio*<sup>1</sup>, A *Parra-Morales*<sup>1</sup>, R *Pineda Oliveros*<sup>1</sup>, M *Molina Perez*<sup>1</sup>.

<sup>1</sup>*Ophthalmology, Complejo Asistencial Universitario de Salamanca, Salamanca, Spain*

**Objective:** The term papilledema refers to the swelling of the optic disc in the context of increased intracranial pressure. We present a case with the diagnosis of meningeal carcinomatosis in a patient with lung adenocarcinoma thanks to ophthalmologic evaluation.

**Methods:** Case Report

**Results:** A 58-year-old woman with a history of T1N3M0 lung adenocarcinoma treated with chemotherapy (last cycle two months before) came to the emergency department complaining of headache and blurred vision. An ophthalmology evaluation was requested. In the examination she presented best corrected visual acuity (BCVA) of 0.5 on the right eye (RE) and of 0.63 on the left eye (LE). Fundoscopy showed a papilla with blurred edges and congestive aspect, with choroidal folds extending towards the macular area. Optical coherence tomography (OCT) showed a thickening in the retinal nerve fiber layer (RNFL) of 290  $\mu\text{m}$  in the RE and 265  $\mu\text{m}$  in the LE. Macular OCT revealed nasal macular edema in both eyes (about 390  $\mu\text{m}$ ) with partial neurosensory detachment. With the diagnosis of bilateral papilledema, cranial computed tomography was requested with normal result. Magnetic resonance imaging revealed a mild meningeal uptake. Lumbar puncture showed a positive result for malignant cells in the cerebrospinal fluid (immunohistochemistry TTF1+) indicating a pulmonary origin. Due to the diagnosis of meningeal carcinomatosis, an Omayá reservoir was placed as treatment. After 6 months of ophthalmologic follow-up, BCVA was 0.16 in the RE and 0.6 in the LE. We also found a clear decrease in NRFL thickening, especially in the RE and mild macular atrophy in both eyes (central thickness around 195  $\mu\text{m}$ ) still with slight perimacular edema in the RE.

**Conclusion:** Meningeal carcinomatosis is the invasion of the meningeal space by cancerous cells either by hematologic dissemination, cerebrospinal fluid or growth in a nerve or sheaths. The diagnosis is associated with poor prognosis and early diagnosis is of vital importance. Treatment is mainly focused on improving symptoms and prolonging survival. We emphasize the importance of considering meningeal invasion of a neoplasia when we find a patient with decreased visual acuity or diplopia without data of brain space-occupying lesion in imaging tests, especially in the context of systemic cancer, although not necessarily as in our presented case.

PP-432

**Optociliary shunt vessels in Multiple Sclerosis**S Nadeem.

**Objective: Importance:** Optociliary shunt vessels develop as a result of chronic retinal venous obstruction. Optic neuritis has not been reported as a causative influence. **Objective:** To determine whether optic neuritis predisposes to the development of optociliary shunts in patients with multiple sclerosis.

**Methods: Design:** This case series follows two patients of multiple sclerosis from 1<sup>st</sup> August, 2019 till 17<sup>th</sup> June, 2021, who developed optociliary shunt vessels after attacks of optic neuritis. **Participants:** There are only two participants in our case series, the first presented to us with optociliary shunt vessels, and whom we investigated for their cause, eventually being diagnosed with multiple sclerosis. The second lady developed shunt vessels after being diagnosed with acute neuroretinitis and later multiple sclerosis. **Exposure:** Demyelinating optic neuritis predisposes to subsequent optociliary shunt development in affected eyes. **Main outcome measure:** Chronic retinal hypoperfusion occurs as a result of multiple sclerosis leading to optociliary shunt formation.

**Results:** A 43-year-old lady presented with left visual loss and bilateral superior optociliary shunt vessels. Perimetry showed bilateral peripheral visual field loss. Optical coherence tomography showed bilateral retinal thinning and ganglion cell complex loss. Optical coherence tomography angiography showed reduced capillary density bilaterally. We investigated her and eventually diagnosed her with multiple sclerosis. The second 49-year-old lady developed right sided optociliary shunt vessels after an episode of neuroretinitis. Perimetry revealed bilateral central scotomata; Optical coherence tomography showed disc and retinal nerve fiber layer edema, and serous retinal detachment, later ganglion cell complex loss and reduced capillary density on Optical coherence tomography angiography. Neuroimaging revealed demyelination in both leading to multiple sclerosis diagnosis and therapy was instituted.

**Conclusion:** We hypothesize that demyelinating optic neuritis due to multiple sclerosis causes chronic retinal hypoperfusion leading to subsequent optociliary shunt development in affected eyes. Our cases series reveals that eyes with optic neuritis, both previous episodes and fresh cases, can contribute to sufficient retinal vein hypoperfusion, to cause development of optociliary shunts, which should be reported in literature.

PP-433

**TROCHLEODYNIA; AN UPCOMING CAUSE OF HEADACHE IN OPHTHALMOLOGY CLINICS**J Youze.**Objective:** TROCHLEODYNIA AS THE UP COMING CAUSE OF HEADACHE IN OPHTHALMOLOGY CLINICS

**Methods:** A case report of 50 years with a complain of severe headache for 6 months that was initially responding to paracetamol and got worse to a point she couldn't sleep well. She is a known hypertensive patient on regular medications. She has been attending different hospitals and only Malaria Rapid Diagnostic Test was done and it was negative before she she was refered to Ophthalmolgy department from the medical department of Muhimbili National Hospital. No History of fever, Loss of consiousness, nausea, vomitining, light/noise sensitivity throughout the time of the illness.

On examination she had BP 134/89 mmHg,

- Visual Acuity OD; **6/12 with pinhole 6/6 OS; 6/12 with pinhole 6/9**
- **Positive pull back** sing as the orbital rim was palpated
- Otherwise normal anterior and posterior segement.

Provisional diagnosis of Refractive error possibly astigmatism and trochleodynia was made

**Results:** she was sent of refraction and the results were

- OD; +0.5/-1.75\*160 – VA 6/6
- OS; +0.5/-1.25\* 160 - VA 6/6

so she was prescribed with spectacles for astigmatism correction

For trochleodynia she received flamar 1 tab for one month

injection of tranmsinolone 40mg + 1 ml 2% lignocaine stat at the supra orbital notch on the left eye and the right eye was injected 2 weeks later.

she was seen again after three months and she was free of pain by then, and she was counselled of the possiblity of requrence after six months.

For hypetension she attenns her medical clinics monthly

**Conclusion:** TROCHLEODYNIA is now recognised as a separate headache entity, not generally recognised among the ophthalmologists/physicians. Not an uncommon condition, seen in upto 5 patients in a week. It's diagnosis is mostly derived clinically with a typical history of frontal/periocular headache radiating to the tempotal aspect. Tenderness at the supraorbital notch – "PULL BACK SIGN" is the mainly associated with the condition.

PP-434

### Congenital Hemianopia Case Report & Overview Study

G Zohdy.

**Objective:** We describe a case of isolated visual field defect discovered in early adulthood.

**Methods:** Case presentation.

**Results:** Case presentation.

**Conclusion:** Isolated visual field defects during childhood are difficult to detect because visual field defects can not be demonstrated satisfactorily in children. Children are often asymptomatic although they may be suffering with dense visual field defects. Tychsen and Hoyt[1] reported two cases with unilateral polymicrogyria of the occipital lobes who had few symptoms despite having dense homonymous hemianopias. In both cases the field defects were discovered in routine ocular examination during adolescence.



PP-435

**A rare case of Inter-nuclear ophthalmoplegia with upgaze palsy due to neurocysticercosis**R Dcruz, D K Natarajan.**Objective:** To report a RARE case of internuclear ophthalmoplegia with upgaze palsy caused by cysticercosis

**Methods:** A 31-year-old young man presented with acute onset of painless vertical diplopia for 15 days for both near and distance. A complete ophthalmic evaluation involving slit lamp evaluation, IOP, PBCT (prism bar cover test), diplopia evaluation, B-scan and MRI was done. He was diagnosed as neurocysticercosis with multiple infarcts in thalami and midbrain supported by MRI. He was started on Albenadazole, systemic steroids and antiepileptics. Ocular examination revealed 10 PDXT with 14 PD LHoT on cover test. Dextroversion was Normal. On levoersion, RE adduction -2 with LE ataxic nystagmus. Upgaze was limited in BE, Pupil & Fundus – OU WNL.

**Results:** He was diagnosed as neurocysticercosis with multiple infarcts in thalami and midbrain supported by MRI. BSCAN showed evidence of cyst within SR muscle. A provisional diagnosis of right INO with upgaze palsy due to dorsal midbrain syndrome associated with neurocysticercosis and orbital cysticercosis affecting SR muscle was made. The patient was reassured and was asked to continue the medications and review in two weeks.

**Conclusion:** Cysticercosis can have a variety of presentations depending upon the site of lodgement and may mimic various neurological disorders putting the clinician on the wrong track. A basic knowledge and understanding of the disease coupled with a high index of suspicion and appropriate imaging could help us reach an early clinical diagnosis. In all cases with orbital cysticercosis, a concurrent neurocysticercosis should be suspected and ruled out.

PP-436

**Sinus anomalies and Stent-Indication Finding****A Report of a typical Case**S Antal<sup>1</sup>, K Resch<sup>2</sup>.

<sup>1</sup>Ophthalmology, LKHF Teaching Hospital Univ. Innsbruck, Feldkirch, Austria, <sup>2</sup>Neurosurgery, Univ of Guadalajara, Guadalajara, Mexico

**Objective:** IIH is a rare and difficult to diagnose and to treat entity between neurology, ophthalmology and neurosurgery. We present a typical case and follow the steps of indication finding.

**Methods:** We saw the 38y old woman with changing anisocoria left > right, flicker OS, feeling of retrobulbar tension, auto-phonic pulsation, holo-cephalic headache, arterial hypertension, hypothyreosis and sever obesity and headache since the age of 11.

At the age of 16 month, she had one seizure with reanimation and delay of developing speech and senso-motor functions.

**Results:** Examination showed good visual acuity, but sever papilledema OU and worsening of visual field defects and hypometric saccades to the left after lumbar puncture.

CT and MR presented the typical findings of idiopathic intracranial hypertension , empty sella and slit ventricle syndrome. MR-angiography showed finally venous anomalies: rectus sinus stenosis proximal and transversal sinus/sigmoid sinus stenosis on both sides.

After lumbar puncture and ICP release and the headache decreased. After interventional dilatation of transverse sinus right side, the neurological report documented a recovery from symptoms. Ophthalmological results will follow.

**Conclusion:** The therapeutic options of IIH are all difficult and not very successful. However, in this case the venous sinus anomalies provide an optimal therapeutic option by stenting. This minimally invasive intervention has a good prognosis.

Regarding the diagnostic and therapeutic difficulties, cases of stent option are lucky circumstances and therefore they should not be overseen during management.

PP-437

**Tolosa-Hunt Syndrome: When Clinical Diagnosis is the Key**V Miranda<sup>1</sup>, C Aguiar<sup>1</sup>, J Costa<sup>1</sup>, J Chibante<sup>1</sup>, R Soares<sup>1</sup>.<sup>1</sup>Ophthalmology Department, Centro Hospitalar de Entre o Douro e Vouga, Santa Maria da Feira, Portugal

**Objective:** To report on a case of Tolosa Hunt Syndrome (THS) - a rare, idiopathic disease, caused by an inflammatory process starting in the cavernous sinus and that can extend to the orbit.

**Methods:** Case report analysis.

**Results:** A 65-years-old caucasian women with a history of diabetes and depression presented in the ophthalmology emergency department (ED) with medium intensity persistent pain in her left eye (LE) for the past week. Slight eyelid swelling was described but her ophthalmologic exam was otherwise unremarkable and she was discharged with topical treatment. She presented again in the general ED after one month with persistent left frontotemporal headache which she described as sometimes feeling like “electric shocks” and paresthesias in the same region. Head CT scan and simple blood workup was normal. Trigeminal neuralgia of the first division was assumed as the diagnosis and she was discharged with oxcarbamazepine treatment. However, two weeks later, she presented again in the Ophthalmology ED with worsened headache and complaints of binocular diplopia. Best corrected Snellen visual acuity was 20/25 in her right eye and 20/40 in her LE. She failed 15 out of 17 Ishihara color plates, had a slight afferent pupillary defect, limited adduction and elevation and discrete ptosis in her LE. Fundus exam showed left optic disc swelling and peripapillary flame retinal haemorrhages. Urgent head MRI was normal. THS was proposed as a working diagnosis to explain her left cranial polyneuropathy with trigeminal, optic and oculomotor involvement and she was started on 60 mg/d prednisolone. An extensive workup to exclude secondary aetiologies including lumbar puncture and further MRI head imaging were requested but all came back normal. All the patient’s complaints and signs improved dramatically with oral corticosteroid therapy and she was carefully weaned off during months of follow-up but could never abandon corticosteroid therapy completely without a new flare of the disease. Only after 13 months since symptoms began did routine MRI imaging showed dural thickening and enhancement of the cavernous sinus and orbit, compatible with THS.

**Conclusion:** THS is a rare entity that can manifest itself with a variety of cranial neuropathies. Diagnosis is eminently clinical since imagiologic signs of the inflammatory process can only become evident late in the disease process. An extensive workup to exclude secondary aetiologies should be done before establishment of this diagnosis.

PP-438

**DOWN AND OUT BUT NOT QUITE!**S Khullar<sup>1</sup>, D Unni<sup>1</sup>, S Mishra<sup>1</sup>.<sup>1</sup>Ophthalmology, Government, NEW DELHI, India

**Objective:** To report a case of acute onset oculomotor nerve paresis referred to our center which was diagnosed as Ocular Myasthenia Gravis and was successfully managed.

**Methods:** 28 year old male presented with complaints of drooping of right eyelid and double vision diagnosed as a case of acute oculomotor nerve paresis and referred to our centre for further management. BCVA- RE- 6/6,LE-6/6. Anterior segment -RE-Severe ptosis alongwith limited movements in adduction, elevation and depression in adduction, direct and consensual pupil reflex present, no anisocoria, rest WNL. Fundus- RE- WNL. Anterior and posterior segment -LE- WNL. PBCT for distance- left eye fixing at 6 metre- 40 PD BI(XT) and 8 PD BU (Hypotropia). Duction test- worsening of ptosis -right eye with saccades. Ice pack test- Positive.

**Results:** Clinical suspicion of Ocular Myasthenia Gravis was confirmed by positive serology (Anti- MuSK and Acetylcholine receptor antibody ) and repetitive nerve stimulation test which was positive for fatigability. Neuroimaging of the brain and orbit revealed bilateral pansinusitis without any intracranial pathology. CECT chest Thymoma measuring 46x41x58 mm with multiple subcentimetric sized lymph nodes in pretracheal,paratracheal,precranial and subcarinal station. The patient was started on Tab Pyridostigmine 30 mg thrice a day by neurology team and thymectomy was done.

**Conclusion:** We report upon a unique case of pupil sparing acute oculomotor nerve paresis in right eye which was evaluated and managed at our centre. We suspected Ocular Myasthenia on the basis of worsening of ptosis and hypotropia on repeated saccades. He was diagnosed as a case of Ocular Myasthenia based on serological tests and repetitive nerve stimulation test. We detected thymoma on CECT Chest which was managed by thymectomy with good results. This case highlights the importance of keeping in mind "Ocular Myasthenia" in case of incomitant strabismus as a "Great Masquerader".

PP-440

**A Rare case of Benign Glomus Tumor with Papilledema Masquerading as Malignant Hypertension**F Yazeer.**Objective:** To report a rare case of glomus jugulare with papilledema masquerading as malignant hypertension

**Methods:** A 54-year-old male, presented with blurring of vision in both eyes with complaints of headache 2 months. There was no history of tinnitus, hearing loss or vertigo reported. Patient was a known diabetic on treatment. Best corrected visual acuity was 6/6. Fundus examination revealed bilateral marked optic disc oedema with peripapillary haemorrhages, arteriolar attenuation and arteriovenous crossing changes. Rest ocular examination was within normal limits. Blood pressure measured 170/100 mmHg. The patient was initially diagnosed as malignant hypertension and referred to physician for urgent blood pressure control. On further evaluation, cranial nerve testing showed tongue fasciculations with deviation of tongue to right consistent with right Hypoglossal nerve palsy and gaze evoked right beating nystagmus. Humphrey central fields evaluation was not possible as the patient had high fixation loss. Optical coherence tomography revealed increased average retinal nerve fibre layer thickness in both eyes consistent with the optic disc oedema. Optical coherence tomography of the macula was within normal limits. CT Brain revealed an expansile infiltrating soft tissue lesion causing lysis of the right petrous, body of sphenoid, right aspect of clivus, right aspect of basiocciput and right jugular fossa suggestive of jugular fossa tumour.

**Results:** Patient was referred to ENT department and evaluation with Pure tone audiometry revealed bilateral mild sensorineural hearing loss consistent with age and auditory brainstem response within normal limits. Patient was then referred to Neurosurgery and planned for excision of the skull base lesion for histopathological correlation with differentials as Right glomus tumour/ Chondrosarcoma/ Jugular schwannoma.

**Conclusion:** Tumours obstructing jugular outflow can caused increased intracranial pressure and vision loss requiring prompt neurosurgical intervention to avoid delayed diagnosis and treatment.

PP-442

**Neuroophthalmic Manifestations of Opportunistic Infections in HIV/AIDS in the Era of HAART Medications**J Mbekeani<sup>1,2</sup>, D Polla<sup>1</sup>, M Wieder<sup>1,2</sup>, G Rand<sup>3,4</sup>, P Mabie<sup>5,6</sup>, R Sacchi<sup>7,8</sup>.<sup>1</sup>*Surgery (Ophthalmology), Jacobi Medical Center, <sup>2</sup>Ophthalmology & Visual Sciences, Montefiore Medical Center/Albert Einstein College of Medicine, Bronx, New York, <sup>3</sup>New York Cornea, Scarsdale, New York,*<sup>4</sup>*Ophthalmology, Columbia University Medical Center, New York, New York, <sup>5</sup>Neurology, Jacobi Medical Center,*<sup>6</sup>*Neurology, Montefiore Medical Center/Albert Einstein College of Medicine, <sup>7</sup>Radiology, Jacobi Medical Center,*<sup>8</sup>*Radiology, Montefiore Medical Center/Albert Einstein College of Medicine, Bronx, New York, United States*

**Objective:** Highly effective anti-retro-viral therapy (HAART) has reduced opportunistic infections and improved survival in HIV/AIDS. We describe cases with neuro-ophthalmic manifestations of infections in non-compliant and HAART-naïve patients.

**Methods:** Three different opportunistic infections, pathogenesises and neuro-ophthalmic manifestations were documented.

**Results: Case 1:** A 28-year-old female with a history of perinatally-acquired HIV (CD4=12, viral load=436,000) and poor HAART compliance presented with binocular diplopia, dizziness, and ataxia. Eye exam revealed BCVA of 20/20 OU, reactive pupils without RAPD, full eye movements and comitant 14PD esotropia, end gaze nystagmus, jerky saccades, dysmetria and skew deviation. MRI brain showed interval cerebellar atrophy. Investigations for infections and autoimmunity, including myasthenia gravis, were negative. At one-month follow-up, esodeviation had increased to 30PD and the patient was wheelchair bound. Re-analysis of CSF revealed JC virus. Diagnosis: JCV granule cell neuronopathy.

**Case 2:** A 26-year-old male with a history of AIDS (CD4=44; viral load=18,0000), poor HAART compliance and cryptococcal meningitis two years previously, presented with diffuse head, neck and back pains. Eye exam revealed VAs of 20/40 OD and 20/25 OS, reactive pupils without RAPD, full eye movements and Frisen grade 2 papilledema OU. Visual fields revealed nasal loss OD and enlarged blind spot with constriction OS. OCT RNFL thickness was 156  $\mu$  m OD and 164  $\mu$  m OS. MRI brain/orbits was unremarkable, lumbar puncture opening pressure was 44cm H<sub>2</sub>O and CSF was positive for drug-resistant *Cryptococcus neoformans*. Diagnosis: Increased intracranial pressure secondary to cryptococcus meningitis.

**Case 3:** A 65-year-old male with type 2 diabetes mellitus presented with altered mental status. Brain MRI demonstrated multifocal infarctions. He was found to be HIV positive (CD4=54; viral load=21,000) and CSF analysis revealed lymphocytic pleocytosis and varicella zoster virus. Eye exam, requested for right sided ptosis, revealed

visual acuities of 20/200 OU and anisocoric pupils (OD>OS) without RAPD. Eye movements were consistent with right III<sup>n</sup> palsy. Review of the MRI revealed infarction to the right III<sup>n</sup> nucleus. Diagnosis: III<sup>rd</sup> nerve palsy secondary to herpes vasculitis.

**Conclusion:** Opportunistic infections in HIV/AIDS can present with unusual neuro-ophthalmic manifestations. In these cases, neuroradiology and CSF analyses were key to diagnoses, with implications for management.

PP-443

## Long-Term Visual Function of Primary Optic Nerve Sheath Meningioma Treated with Fractionated Stereotactic Radiotherapy

C Chaiwitooanukul<sup>1</sup>, T Padungkiatsagul<sup>1</sup>, P Puataweepong<sup>2</sup>, P Jindahra<sup>3</sup>, K Vanikiet<sup>1</sup>.

<sup>1</sup>Department of Ophthalmology, <sup>2</sup>Department of Radiology, <sup>3</sup>Department of Medicine, Faculty of Medicine Ramathibodi Hospital, Mahidol University, Bangkok, Thailand

**Objective:** To evaluate long-term visual function of primary optic nerve sheath meningioma (PONSMS) treated with fractionated stereotactic radiotherapy (FSRT)

**Methods:** This was a single-center, retrospective study. We included patients diagnosed with PONSMS and treated with FSRT over a 22-year period. Patients with a history of resection/biopsy were excluded. Demographic data, clinical characteristics, visual function including visual acuity (VA) and visual field (VF) mean deviation (MD) at presentation (pre-radiotherapy; pre-RT) and at last follow-up (post-radiotherapy; post-RT), follow-up magnetic resonance imaging (MRI) and complication were evaluated.

**Results:** Thirty-four patients (5 male and 29 female) with 34 affected eyes were included. Mean age at symptoms onset was 46.3 years (standard deviation (SD) 9.8 years). Median pre-RT VA and pre-RT VF MD were 0.70 logMAR (range 0.0 to 2.9 logMAR) and -15.4 decibel (dB) (range -31.4 to -3.2 dB), respectively. Mean total dose of FSRT was 50.4 Gy (SD 1.1 Gy) in 25 or 27 fractions. Median visual function follow-up time was 89 months (range 6 to 251 months). Median post-RT VA and post-RT VF MD were 0.48 logMAR (range 0.0 to 2.9 logMAR) ( $p = 0.010$ ) and -6.8 dB (range -20.6 to -1.6 dB) ( $p = 0.005$ ), respectively. A strong inversely correlation was observed between changes of VA (post-RT VA - pre-RT VA) and changes of VF MD (post-RT VF MD - pre-RT VF MD) (Spearman  $r = -0.612$ ,  $p = 0.020$ ). Of the total 34 eyes, VA was improved or stable in 85.3% (15 improved, 14 stable) and worsened in 14.7% (5 worsened). Of 14 eyes with available both VA and VF MD at pre-RT and post-RT, VF MD was improved or stable in 92.8% (10 improved, 3 stable) and worsened in 7.2% (1 worsened), while overall visual function was improved or stable in 92.8% (10 improved, 3 stable) and worsened in 7.2% (1 worsened). Tumor control rate (decreased or stable size) was 100% of eyes. Complication was observed in only 1 patient (2.9%) with radiation retinopathy.

**Conclusion:** FSRT significantly improves visual function. Most patients achieve improvement or stabilization of visual function. In addition, the complication rate is low. Therefore, this modality is an effective and safe approach in the treatment of PONSMS.



PP-444

**Binocular diplopia etiology and outcome: single-center study, analysis of 120 cases**I Conita<sup>1</sup>, R Prihatningtias<sup>2</sup>.<sup>1</sup>Resident of Ophthalmology, <sup>2</sup>Neuro-ophthalmology, Universitas Diponegoro, Semarang, Indonesia**Objective:** This study aims to investigate the outcome in managing binocular diplopia.**Methods:** Design of this study was retrospective cohort study. All patients with binocular diplopia were investigated and followed-up in a certain time. Unable to attend for evaluation were excluded. The etiology was categorized into vasculopathy, tumor, trauma, graves disease, myasthenia gravis, and idiopathic. The age-stratified by etiology, sexes, directions of diplopia, involved cranial nerve, extraocular muscle, and comorbidity were described. The outcome rates were categorized into successful and failure. Mann-Whitney U test is used to compare between groups. The correlations were analyzed using Spearman's test was also provided.**Results:** From a total of 120 samples, the etiology shows the vasculopathy has 47 (39.2%) samples following tumor 26 (21.7%), trauma 21 (17.5%), graves disease 5 (4.2%), myasthenia gravis 5 (4.2%), idiopathic 4 (3.3%) and the others 12 (10%). The age-stratified by etiology elucidate the vasculopathy, tumor, and trauma have a peak of incidence in their 50s, 40s and 20-30s, respectively. The numbers of both male and female are equal. Horizontal direction of diplopia is 91 (75.8%) while vertical 29 (24.2%). The involved single cranial nerve is 80 (66.7%) and multiple 30 (25%). Moreover, the involved single extraocular muscle is 65 (54.2%) and multiple 45 (37.5%). About fifty-nine (49.2%) samples has comorbidity which are hypertension, diabetes mellitus, dyslipidemia or its combinations. There were total of 89 sample have followed-up within twelve months, where the successful outcome rate has similar result, both of conservative management (53.9%) and surgery (53.8%). Nevertheless, involved cranial nerve and extraocular muscles are significantly difference to outcome rates with  $P=0.024$  and  $P=0.021$ , respectively. Further analysis, there is significantly positive correlation between etiology and comorbidity with  $P=0.000$ . The number of involved cranial nerve and extraocular muscles are significantly negative correlation to outcome rates with  $P=0.023$  and  $P=0.020$ , respectively.**Conclusion:** The most common etiology of binocular diplopia is vasculopathy. Each of etiologies incidence may related to age-specific and correlated with comorbidity. The more involved cranial nerve or extraocular muscles may worsen the outcome rates. Despite of the result, conservative management might be an alternative treatment to surgery in our center in managing binocular diplopia.

PP-445

### Ethambutol Induced Optic Neuropathy in India with current antituberculous treatment regimen- Another Conundrum

A B Chandran, V M Shah<sup>1</sup>.

<sup>1</sup>*Neuroophthalmology , Aravind Eye hospital , Coimbatore , India*

**Objective:** To determine the presentation, management & prognosis of Ethambutol Optic Neuropathy (EON)

**Methods:** 30 patients that presented to a tertiary eye care centre in South India ( March- April 2022)and were diagnosed with EON were included in the study. Visual acuity, Colour Vision, Humphreys perimetry, Contrast Sensitivity,Visual evoked potential and ,Magnetic resonance imaging (MRI) were done after a detailed history including the drugs & duration of antituberculous treatment & onset of visual impairment .

**Results:** Mean age of study population was 53.73 with male (70%) preponderance.HFA shows Bitemporal hemianopia for 43% (13 ), temporal field defects in 26%(8) ,centrocaecal scotoma in 17% (5) & low reliability in 10% (3).VEP amplitude was reduced in 87% (26). MRI showed enhancement in optic chiasma in 40% (12).Patients were managed with Vit B complex and Zinc supplements,after discontinuing and replacing ethambutol.On 1 month follow up,53%(16) had visual improvement after stopping ethambutol.

**Conclusion:** With the increased duration of Ethambutol in the ATT regimen, the incidence of EON has drastically risen.Patients should be screened regularly if started on ATT. Routine follow up for patients on ethambutol therapy is mandatory to avoid EON.Further studies are required to determine whether the duration or genetic factors predispose patients to EON and there is need for long term followup to assess the visual recovery. Early diagnosis of EON is needed & timely replacement of the drug with alternative is needed for good visual recovery .

PP-446

**Onset of Myasthenia Gravis Following COVID-19 Infection**C P Aguiar<sup>1</sup>, M Matias<sup>1</sup>, J Chibante-Pedro<sup>1</sup>, I Almeida<sup>1</sup>.<sup>1</sup>Ophthalmology, Centro Hospitalar de Entre o Douro e Vouga, Santa Maria da Feira, Portugal**Objective:** To present a case of a patient with an onset of myasthenia gravis following a COVID-19 infection.**Methods:** Clinical case presentation.**Results:** 53-year-old-woman followed by our corneal department due to a dry eye disease related to a rheumatoid arthritis, who presented at the medical appointment with an installation of bilateral ptosis which she referred as being worse at the end of the day. The ptosis had appeared on the week after being infected with COVID-19. The ice test was performed and a significant improvement was observed. The antibodies against the acetylcholine receptors on the serum were positive, so she was diagnosed with myasthenia gravis.**Conclusion:** Myasthenia gravis is an autoimmune neuromuscular junction disorder characterized by production of antibodies against the acetylcholine receptor, which lead to the destruction of the post-synaptic neuromuscular junction. COVID-19 infection has been associated with some neurological diseases. The installation of myasthenia gravis is another possible complication originated by the virus, since previous studies have demonstrated a possible etiological role of different viral infections in this neuromuscular disorder. The cause-and-effect relationship between myasthenia gravis and COVID-19 infection is always challenging to find. However, latent myasthenia gravis activation by the virus and molecular mimicry may play a role in the initiation of this disease.

PP-450

**Superior sagittal sinus thrombosis: a case report**

M Matias<sup>1</sup>, J Jesus<sup>1</sup>, V Miranda<sup>1</sup>, C Aguiar<sup>1</sup>, J Ambrósio<sup>1</sup>, J Chibante-Pedro<sup>1</sup>, R Soares<sup>1</sup>.

<sup>1</sup>Centro Hospitalar de Entre o Douro e Vouga, Santa Maria da Feira, Portugal

**Objective:** To describe a clinical case of superior sagittal sinus thrombosis

**Methods:** Clinical case report

**Results:** A 17 year-old girl without relevant medical past history and no current medication, presented to emergency department complaining of photophobia accompanied by a continuous frontal headache for 5 days, refractory to conventional analgesics. The patient reported night awakening in the previous 2 days and denied associated nausea and vomiting. The patient was hemodynamically stable and neurological examination was normal. Ophthalmological examination was requested to rule out optic disc swelling, showing: normal pupillary reflexes, right eye and left eye best corrected visual acuity of 20/25 and fundoscopy with bilateral nasal disc swelling. A head computed tomography (CT) and CT cerebral venogram revealed segmental thrombosis of the superior sagittal sinus and head magnetic resonance imaging (MRI) confirmed the absence of flow in the middle/distal third of the superior longitudinal sinus, giving the diagnosis of venous thrombosis. Lumbar puncture revealed elevated opening pressure (35 cmH<sub>2</sub>O) with normal constituents. Given the unknown etiology, an extensive investigation was done: searching for prothrombotic conditions, infections, autoimmune or inflammatory diseases and tumor markers and a genetic study. The etiological investigation showed negative results, without findings supporting a cause for venous thrombosis. In the meanwhile, the patient started treatment with heparin and acetazolamide with marked clinical and ophthalmological improvement, and complete recovery.

**Conclusion:** Cerebral venous sinus thrombosis is an uncommon, challenging and life-threatening condition with a wide range of clinical presentations. Symptoms and signs are usually identical to idiopathic intracranial hypertension. The diagnosis depends on prompt and appropriate neuroimaging. After the correct diagnosis, it is imperative to make a wide investigation to rule out an underlying cause. In this clinical case we reported a thrombotic event in the absence of predisposing conditions.

## PP-451

**Effect of the Mfn2 Gene in the retinal ischemia/reperfusion injury**

J Dai<sup>1</sup>, L Feng<sup>1</sup>, H Shen<sup>2</sup>, J Zhao<sup>2</sup>.

<sup>1</sup>Department of Ophthalmology, <sup>2</sup>Department of Ophthalmology, The Forth Affiliated Hospital, The eye Hospital, China medical university, Key Laboratory of Lens Research of Liaoning Province, Shenyang, People's Republic of China

**Objective:** The aim of our study was to explore retinal structure and rod/photoreceptor cell degeneration in wild type(WT) and mitofusin(Mfn)2 knockout(KO) mice after retinal ischemia reperfusion(I/R) injury.

**Methods:** Therefore, I/R was induced by increasing intraocular pressure in one eye of wild type(WT I/R) and Mfn2 KO(KO I/R) mice while the other eye was untreated. Proliferation and apoptosis of rod cells, photoreceptors and changes of retinal structure and Mfn2 were analyzed by EdU, TUNEL, immunohistochemistry, Hematoxylin and Eosin staining, Western blot and quantitative real time PCR.

**Results:**

We found Mfn2 mRNA and protein expression were comparable in the ischemic retina. We observed retinal thinning in both ischemic groups after 1, 3 and 7 days. Compared to WT I/R group, the changes of retinal thickness and the reduction of rhodopsin protein as well as Rho were more obvious in KO I/R group after 1 and 3 days, but the phenomenon is contrary after 7 days. Additionally, the number of PKC  $\alpha$  + rod cells, recoverin+ photoreceptor staining and the expression of Prkca and Rcvrn were comparable in all groups. Finally, a reduction in the number of proliferating retinal cells and an increase in the number of apoptotic cells, especially rod-photoreceptor were more significant in the KO I/R group than WT I/R group after 1 and 3 days, while it is opposite after 7 days. Collectively, KO I/R mice showed diminished rod-photoreceptor degeneration and retinal dysfunction at the beginning. Proliferate and apoptosis levels after ischemia could be related to mitochondrial dysfunction.

**Conclusion:** Our study provides novel evidence that Mfn2 protects retinal cells against early ischemia, possibly by mediating mitochondrial fusion and mitophagy. As injury worsens, Mfn2 reinforces ischemic retinal degeneration, and is maybe associated with the imbalance of mitochondrial fusion and mitophagy.

PP-452

## Occipital Hemorrhage Evacuation by Minimally Invasive Neurosurgery (MIN) enable fast Recovery of Visual Function

K Resch, S Antal<sup>1</sup>.

<sup>1</sup>Ophthalmology, LKHF Teaching Hospital Univ.Innsbruck, Feldkirch, Austria

**Objective:** In a recent series of 56 cases of ICH evacuation there were 9 cases with occipital/parieto-occipital location causing disturbance of visual function. We analyzed the ophthalmological outcome to prove the effect of functional recovery by this procedure.

**Methods:** This MIN concept combined 5 MIN-key techniques to assist microneurosurgery: high-end neuro-sonography with small probes („burr-hole-probe 8x8mm, ALOKA/ Hitachi) and mouth-tracking of the microscope, both mandatory. Additionally, we added endoscopy (Wolf, Aesculap, Storz) and LASER (Th-YAG Revolix). Sealing technique (Tachosil/ Takeda) is always used.

Ophthalmological standard techniques were peri-operatively used to meticulously document ophthalmological functions. Visual acuity, 30° visual field, RNFL and fundoscopy were examined as soon as the patient's condition did allow so.

**Results:** There were five male (73, 71, 67, 61, 42 y), three female (52, 76, 82 y) and one child (2mth) with occipital/parieto-occipital IHCs. The volume was 20 – 125 ml, 0 – 1,5 cm depth from the cortex, sono-assisted and mouth-tracked microsurgery through 7 MIN approaches (1 – 3 cm) and 2 burr-holes (1 cm) were used. Reasons of bleeding were 3 angiopathia, 1 cavernoma, 1 infarction and 4 unknown. In all angiopathia cases anticoagulants were involved. All patients recovered completely, only the 82y lady underwent during rehabilitation a TEP and was mobilized slowly and went finally home to her family. In all cases visual function recovery could be documented ophthalmologically.

**Conclusion:** - Cooperation of neurosurgery and ophthalmology can preserve visual functions.

- The superior results of MIN in ICH-evacuation can be objectively measured by ophthalmological methods.
- The most sensitive parameter for indication to evacuate the hemorrhage was the visual field disturbance.

**Key Concepts in MIN, Vol. 1+2, Basics; Resch KDM/ Springer 2020 / 22**

**PP-453****Exploring the mechanism of Ginkgo biloba in the treatment of NAION based on network pharmacology and molecular docking**Z Meng.

**Objective:** To study the potential biological mechanism of Ginkgo biloba extract in the treatment of non arteritis ischemic optic neuropathy (NAION) based on network pharmacology.

**Methods:** Firstly, the main chemical components and potential protein targets of Ginkgo biloba were collected by traditional Chinese medicine network database. Then OMIM and other databases were used to retrieve NAION disease-related targets. The above targets were imported into Venn software to obtain the intersection targets. The data were imported into the string database for protein interaction analysis, and the results were imported into the cytoscape-v3.8.2 database to construct a network diagram of medicinal-targets-pathways. Continue to use cytoscape-v3.8.2 software and its plug-ins to screen out the core targets. David database was used for bio-enrichment and signal transduction analysis, and R language was used for visualization. Finally, molecular docking simulation was carried out by using molecular docking software to verify the degree of molecular connection between drug and target.

**Results:** There were 20 active components in Ginkgo biloba , including quercetin, kaempferol, digital flavonoids of digitalis pubescens, 521 protein targets, 756 targets of NAION and 26 overlapping targets of them. Through the plug-in of cytoscape-v3.8.2, we get 8 target points of hub set, 12 MCC set and 24 mcode set, and select 8 core targets from the intersection of the three data sets, including VEGFA, JUN, EGF, RELA, APP, ESR1, FOS and MYC. The pathways involved include: tumor pathway, T cell receptor signaling pathway, PI3K-Akt signaling pathway, MAPK signaling pathway, etc., which mainly play role in anti-inflammatory, antioxidant, immune regulation and neuroprotection.

**Conclusion:** Based on the comprehensive analysis of network pharmacology, it provides a new idea for the study of the mechanism of Ginkgo biloba active ingredients in the treatment of NAION, and provides a bioinformatics basis for the later experimental verification.

PP-455

**Clinical characteristics of children with myelin oligodendrocyte glycoprotein antibody positive optic neuritis under 16 years old**H Song, S Wei.

**Objective:** Myelin oligodendrocyte glycoprotein antibody positive optic neuritis (MOG-ON) has been included in the Evidence-Based Guidelines for Diagnosis and Treatment of Demyelinating Optic Neuritis in China (2021) as a new type of optic neuritis, but there are few domestic clinical studies on MOG-ON in children. To study the clinical characteristics and prognosis of MOG-ON in children under 16 years old.

**Methods:** Clinical data about 33 children (57 eyes) with MOG-ON diagnosed by the Department of Ophthalmology of the 942 Hospital of Chinese people's Liberation Army and the Eye Hospital of People's Hospital of Ningxia Hui Autonomous Region from January 2017 to December 2020 were analyzed retrospectively. The age of onset was 3~15 ( $9.9 \pm 3.7$ ) years old, and 16 cases were male. The clinical characteristics of the children and the recovery of visual acuity after treatment were collected.

**Results:** 14 children (42.4%) had binocular optic neuritis as the first manifestation, 18 children (54.5%) had recurrence, and 24 children (72.7%) had bilateral onset at the last follow-up. At the first onset, 24 children (72.7%) had eye pain, and 23 eyes (48.9%) had optic disc edema. After 3 months of follow-up, OCT showed that the average thickness of peripheral optic disc nerve fiber layer (pRNFL) was ( $70.66 \pm 11.11$ )  $\mu$  m, and the average thickness of ganglion cell layer + inner plexus layer (mGCIPL) in macular region was ( $60.71 \pm 7.14$ )  $\mu$  m, showing varying degrees of atrophic thinning. Orbital MRI showed the long T2 signal of the optic nerve was changed in 32 cases (97.0%), some of which were accompanied by optic nerve enhancement or perioptic nerve enhancement, and the optic chiasm was involved in 4 cases (12.1%). Within two weeks of the first onset, 37 eyes (78.7%) had best corrected visual acuity (BCVA)  $\leq 0.1$ . After intravenous methylprednisolone treatment, visual function improved to varying degrees, and 46 eyes (97.9%) had BCVA  $\geq 0.5$ . The mean follow-up time was ( $34.06 \pm 17.60$ ) months. At last follow-up, 54 eyes (94.7%) had BCVA  $\geq 0.5$ .

**Conclusion:** The clinical manifestations of MOG-ON in children under 16 years old are diverse. They are sensitive to corticosteroids pulse therapy, and most of them have a good prognosis.



PP-456

**Mutation analysis of SUOX in isolated sulfite oxidase deficiency with ectopia lentis as the presenting feature: insights into geno**J Li<sup>1</sup>, Z Chen, X Chen<sup>2</sup>, Y Jiang.<sup>1</sup> Department of Neurology, Institute of Neurology, Huashan Hospital, Fudan University, Shanghai, China.,<sup>2</sup> Department of Neurology, Institute of Neurology, Huashan Hospital, Fudan University, Shanghai, China., Shanghai, People's Republic of China

**Objective:** This study aimed to report biallelic sulfite oxidase (*SUOX*) mutations in a Chinese patient whose primary symptom is ectopia lentis (EL), analyses the structure-function relevance and explore the underlying genotype-phenotype correlations.

**Methods:** Potentially pathogenic *SUOX* mutations were screened from a Chinese cohort of congenital EL using panel-based next-generation sequencing and analyzed by multiple bioinformatics tools. The genotype-phenotype correlations were evaluated by a systematic review of *SUOX* mutations within our data and those from the literature.

**Results:** A novel paternal missense mutation c.205G>C (p.A69P) and a recurrent maternal nonsense mutation c.1200C>G (p.Y400X) of *SUOX* were identified in a four-year-old boy from a Chinese cohort of congenital EL. The biochemical assays manifested elevated urine sulfite and S-sulfocysteine, accompanied by decreased homocysteine in the blood. The patient had bilateral EL and normal fundus, yet minimal neurological involvement and normal brain structure were identified. Molecular modeling simulation revealed unstable structure of the p.A69P mutant but stable affinity to sulfite. While the truncated p.Y400X mutant showed decreased binding capacity. Genotype-phenotype analysis demonstrated milder symptoms ( $P = 0.023$ ), later age of onset ( $P < 0.001$ ), and higher incidence of regression ( $P = 0.017$ ) in patients with biallelic missense mutations than that of other genotypes. No correlations were found regarding to EL and other neurological symptoms.

**Conclusion:** The data from this study not only enriched the mutation spectrum of *SUOX* but also suggest that its missense mutations might be associated with mild and atypical symptoms.

PP-457

**Effect of Heme Oxygenase-1 on Diabetic Retinopathy Rats via NF- $\kappa$ B Signaling Pathway**A Ainiwaer.

**Objective:** We investigated the protective effects of HO-1, induced by hemin, in the retinas of streptozotocin (STZ)-induced diabetic rats and documented the possible anti-inflammatory, anti-apoptotic, anti-proliferative mechanisms underlying the protection via the NF- $\kappa$ B signaling pathway.

**Methods:** Sprague-Dawley (SD) rats were induced to diabetes by intraperitoneal injection of STZ (60 mg/kg). Later, some of the rats were given intraperitoneal injections of hemin (20 mg/kg) to induce expression of HO-1. The protective effects of hemin were evaluated by examining the numbers of apoptotic retinal ganglion cells (RGC) through flow cytometric analysis. We also documented the expressions of HO-1 and P65 by Western blot analysis.

**Results:** Hemin significantly activated HO-1 expression in the retinas of diabetic rats, combined with accordant changes of p65. Retinal ganglion cells displayed greater sensitivity to apoptosis when the HO-1 level was lower. Overexpression of HO-1 was associated with a decrease in the activation of P65.

**Conclusion:** HO-1 is an essential negative regulator of NF- $\kappa$ B related signaling pathways. Overexpression of HO-1 by hemin induction protected retinal ganglion cells in diabetic retinopathy through anti-inflammatory, anti-apoptotic effects.

**PP-460****A case of frequent blinking and abnormal eyeball movement associated with generalized epilepsy.**

A Okudo<sup>1,2</sup>, O Babalola<sup>3</sup>, I Oshoku<sup>4</sup>.

<sup>1</sup>Rachel Eye Center, <sup>2</sup>Ophthalmology, Asokoro District Hospital, Abuja, <sup>3</sup>Rachel Eye Center, Abuja, FCT, <sup>4</sup>Internal Medicine, Asokoro District, Hospital, Abuja, Nigeria

**Objective:** INTRODUCTION

Eyelid myoclonus is an idiopathic generalized epileptic syndrome that can occur with or without absence seizures. Eyelid Myoclonus with Absence (EMA) is also known as Jeavons syndrome. The features include frequent blinking, an upward roll of the eyeballs, and slight backward movement of the head. It can be spontaneous or stimulated by light. Light and eyelid closure are triggers to the seizures.

**Methods:** Case Report**Results:** THE CASE

A 13-year-old young male student presented with a four months history of frequent blinking and abnormal eye movements. There was a positive history of leg tapping while asleep which started a year prior to presentation, but there was no loss of consciousness.

On presentation, the patient was a young healthy looking myope who was frequently blinked with sudden upward and left jerky movements of the eyeballs. Visual acuity was CF at 2 meters in both eyes improving from -4.50DS to 6/6. Intraocular pressures were 12 mmHg bilaterally. Anterior and posterior segment findings were normal. Brain MRI was normal, but EEG was abnormal with features suggestive of generalized epilepsy.

He was co-managed with the neurologist and placed initially on Tabs Sodium valproate 250mg for 3 months. This was modified to Tabs Sodium Valproate (controlled release) 500mg at night since there was little change. This resulted in an appreciable reduction in blinking and abnormal eye movement. The leg tapping was also reduced to once a week as compared to daily prior to treatment.

**Conclusion:** Eyelid myoclonus is a rare form of epilepsy. it is of utmost importance to create awareness of the disease among physicians. Early diagnosis and treatment are important prognostic factors of the disease.

PP-461

**Baseline prism diopter and prognostic factors in cranial nerve palsies: An observational study**

S Buragohain, H *Bhattacharjee*<sup>1</sup>, D *Das*<sup>2</sup>.

<sup>1</sup>*Comprehensive Ophthalmology*, <sup>2</sup>*Uvea, Ocular Pathology and Neuro-ophthalmology, Sri Sankaradeva Nethralaya, Guwahati, India*

**Objective:** To analyse the prognostic factors and the association of baseline prism diopter with third, fourth and sixth cranial nerve palsies

**Methods:** A total of 43 patients of cases of third (CN3), fourth (CN4), and sixth (CN6) cranial nerve palsies were included in the study according to the inclusion criteria. The amount of ocular deviation was measured with a baseline prism bar cover test (PBCT). The patients were then grouped according to the etiology and the cranial nerve which was involved. The groups were then compared based on the baseline PD and the recovery duration. Recovery was defined as less than 8 PD of deviation or absent subjective diplopia of the patient.

**Results:** The recovery rate was not associated with the etiology or the type of cranial nerve involvement. The recovery duration had a significant association between the type of cranial nerve involvement (p-Value = 0.021). The recovery was shortest in multiple cranial nerve involvement and was the longest in cases of sixth cranial nerve palsy. There was also a significant association between the baseline prism diopter and the type of cranial nerve involvement (p-Value = 0.002).

**Conclusion:** The prognosis of cranial nerve palsies depends on a number of factors. The recovery rate is not associated with the type of cranial nerve involvement or the etiology but the recovery duration depends on the type of cranial nerve involvement. There is a significant association between the baseline prism diopter and the type of cranial nerve involvement.

PP-463

**Update on Glial-antibody-mediated optic neuritis**H Song, S Wei.

**Objective:** Optic neuritis (ON) refers to inflammatory demyelinating lesions of the optic nerve, which can cause acute or sub-acute vision loss and is a major cause of vision loss in young adults. Much of our understanding of typical ON is from the Optic Neuritis Treatment Trial.

**Methods:** Glial autoantibodies to aquaporin-4 immunoglobulin (AQP4-IgG) and myelin oligodendrocyte glycoprotein immunoglobulin (MOG-IgG) are recently established biomarkers of ON that have revolutionized our understanding of atypical ON.

**Results:** The detection of glial antibodies is helpful in the diagnosis, treatment, and follow up of patients with different types of ON. AQP4-IgG and MOG-IgG screening is strongly recommended for patients with atypical ON. Research on the pathogenesis of NMOSD and MOGAD will promote the development and marketing of immune-targeted therapeutics.

**Conclusion:** The application of new and efficient drugs, such as the selective complement C5 inhibitor, IL6 receptor inhibitor, B cell depleting agents, and drugs against other monoclonal antibodies provide additional medical evidence. This review provides information on the diagnosis and management of glial-antibody-mediated ON.

PP-464

**Pembrolizumab associated optic neuropathy**J Xiong<sup>1,2</sup>, R Malik<sup>3,4,5</sup>, M Lawlor<sup>1,2,6</sup>.

<sup>1</sup>Sydney Eye Hospital, <sup>2</sup>The University of Sydney, Sydney, <sup>3</sup>Port Macquarie Base Hospital, Port Macquarie, <sup>4</sup>The University of Newcastle, Newcastle, <sup>5</sup>The University of New South Wales, Port Macquarie, <sup>6</sup>Royal Prince Alfred Hospital, Sydney, Australia

**Objective:** To describe two cases of pembrolizumab associated optic neuropathy.

**Methods:** The authors present two clinical cases, followed by a literature review of reported ocular side effects of immune check-point inhibitors, including pembrolizumab.

**Results:** A 71-year-old female presented with acute unilateral loss of vision (BCVA counting fingers), left RAPD, dense left global field defect and florid unilateral optic disc oedema. Her treatment regime for metastatic lung cancer included cycles of pembrolizumab, carboplatin and pemetrexed, which commenced 3 months prior to ocular findings. At 3 month follow up, the left eye BCVA improved to 6/90 with remaining temporal optic disc pallor. The second case is of a 69-year old male on pembrolizumab treatment for metastatic melanoma who presented with a subacute six-week history of reduced right eye vision and was found to have bilateral optic disc oedema, bilaterally he had BCVA of 6/5, normal visual fields and there was no RAPD. While a direct causative link between pembrolizumab and the optic nerve changes cannot be confirmed, extensive investigations failed to find any other cause of the optic neuropathies. Such cases require careful consideration in balancing the threat to vision as well as ongoing management of systemic disease.

Pembrolizumab is a type of immunotherapy known as an immune checkpoint inhibitor, targeted at programmed death-1 (PD-1) ligand found on T-lymphocytes. The first approved immune checkpoint inhibitor was ipilimumab, which has a less than 1% incidence of ocular adverse effects. There are documented case reports of ipilimumab associated with bilateral optic neuropathy, neuro-retinitis (bilateral optic nerve oedema with macular oedema) and several case reports of orbital inflammation. However, there is limited evidence within the literature on pembrolizumab's related neuro-ophthalmic side effects.

**Conclusion:** The two cases documenting pembrolizumab associated optic neuropathy is of clinical relevance as it contributes to the existing knowledge of potential pembrolizumab related adverse events.

PP-465

**Relationship between Cornea Epithelial Nerve plexus stimulation micro alteration dry eye with migraine and Nervous Headaches**M Masoudnaseri.

**Objective: Purpose:** Identification of relationship between the corneal epithelial superficial nervous plexus with the effective stimulations factors for the onset of the migraine and nerve headaches phases, communicate of central nervous system receptors, morphological changes, with mechanism and stimulate factors, by micro alteration in the layers of the cornea and ocular surface with the migraine and nerve headaches. control and treatment of this kind of headaches, by completely healthy and safe standards methods and drudges with Eye drops which have no side effects on other organs.

**Methods:** : study enrolled 185 of participants 77% female and 23% male with the migraine and Nervous Headaches Most people were in the 19-56 age group at 3 years after initial presentation. All of the patients with migraine and neurological headaches had reduced cell volume and irregular changes in the corneal epithelial level compared to the control group. reducing the volume of superficial conjunctiva and cornea epithelium, cells, in these groups as compared with controls (5.79 vs. 0.77,  $p < 0.001$  and 7.6 vs. 4.6  $\mu\text{m}$ ,  $p < 0.001$ ). Both parameters were highly significantly correlated with questionnaire scores (EIF:  $r = 0.778$ ;  $p < 0.001$ , range:  $r = 0.737$ ;  $p < 0.001$ ). Follow-up showed a statistically significant reduction in epithelial thickness profile variance and range of treated patients ( $p < 0.001$ ).corneal and eye surface nerve plexus stimulations. The onset of this type of headache was associated with changes in the cornea epithelial cell dimensions and dry eye, which caused irritation to the nerves associated with the onset of the migraine and nerve headache phase. After superficial morphological changes, stimulation of the corneal neural network begins

**Results:** Of 185 of participants at 3 years after initial presentation use of a Specific dose and combination of artificial Tears and gel and vitamin A in a determined time can prevent nerve headaches and avoid the entry of the migraine headaches phase. All of the patients did not use painkillers and did not experience headache at all after this procedure.

**Conclusion:** Our findings demonstrate that All of the patients with migraine and Nervous Headaches might have some correlation with corneal nerve stimulations and Effect of Desiccating Stress on eyelid Meibomian Gland Function and dry Eyes.

PP-466

**Ocular manifestations of multiple sclerosis in patients from three countries: A Web-based survey**R Zhao.

**Objective:** This study evaluates the epidemiological characteristics, ophthalmological manifestations, and different therapeutic options for patients with multiple sclerosis (MS) in China, Spain, and Cuba.

**Methods:** A self-designed questionnaire was used to conduct a comparable descriptive cross-sectional study on patients with MS. The survey included patients' demographic data, ocular manifestations related to MS, and treatment methodology followed in the three countries. mean and standard deviation, the Kruskal-Wallis test was used for non-parametric variables. Qualitative data were expressed as numerical and percentage. The chi-square test ( $\chi^2$ ) was used to compare the group's response categories. The statistical difference was considered significant when  $p < 0.05$ . mean and standard deviation, the Kruskal-Wallis test was used for non-parametric variables. Qualitative data were expressed as numerical and percentage. The chi-square test ( $\chi^2$ ) was used to compare the group's response categories. The statistical difference was considered significant when  $p < 0.05$ .

**Results:** The female-to-male ratio in all the three countries was 2-3:1, and relapsing-remitting MS (RRMS) was the most frequent in all three countries. Vision loss was slow and progressive in half of the patients from the three countries, with no significant differences ( $p = 0.524$ ). A higher percentage of steroid treatment was observed in Chinese patients in comparison with the patients from other two countries ( $p < 0.001$ ), and a similar trend was seen in the use of traditional medicines. Almost one-third of patients who did not receive any treatment recovered spontaneously in all the three countries ( $p = 0.097$ ).

**Conclusion:** MS occurs more frequently in the relapsing-remitting clinical form and there is a clear female predominance. The first ocular crisis or clinical debut of MS is characterized by slow and progressive visual impairment, increasing and adding to other ocular manifestations during its evolutionary course. Spontaneous recovery of vision after an attack of optic neuritis in the course of MS is possible.



PP-469

### Comparison of ultra-widefield swept-source OCTA and indocyanine green angiography in central serous chorioretinopathy

Q Zeng<sup>1</sup>, Y Yao<sup>1</sup>, S Li<sup>1</sup>, Z Yang<sup>2</sup>, M Zhao<sup>1</sup>.

<sup>1</sup>Ophthalmology, Peking University People's Hospital, <sup>2</sup>Engineering, TowardPi Medical Technology, Beijing, People's Republic of China

**Objective:** We aim to describe ultra-widefield SS-OCTA findings in patients with CSC, and to compare ultra-widefield SS-OCTA with traditional ICGA, as well as describe the area change of abnormalities on SS-OCTA after treatment

**Methods:** Patients with symptomatic CSC were consecutively included in this study from August 2021 to October 2021 at the Department of Ophthalmology, Peking University People's Hospital. Patients were imaged with a 400 kHz SS-OCTA instrument (BM400KB Mizar, TowardPi Medical Technology Co., Ltd, Beijing, China) that uses a laser at a central wavelength of 1060 nm with a bandwidth of 100 nm. Images of 24 x 20 mm areas were obtained. Ultra-widefield SS-OCTA and ICGA images were aligned. Abnormal areas were annotated on en face choriocapillary OCTA images, hyperfluorescence area on mid-phase ICGA images, and hypofluorescence area on early-phase ICGA images. To determine the agreement of annotations between the ICGA and SS-OCTA images, spatial overlap of the annotations was calculated separately according to Jaccard index (JI). The interobserver agreement of image annotations between the two graders was measured in the same manner according to JI. SS-OCTA findings of fellow eyes and change of SS-OCTA abnormalities during the follow-up were also analyzed.

**Results:** Three main types of abnormalities in choriocapillaris SS-OCTA images were found: type A, coarse granulated high reflective area (39 eyes [100%]); type B, roundish dark halo around Type A (32 eyes [82.1%]); and type C, coarse granulated low reflective area (39 eyes [100%]). The Mean JI of type A on SS-OCTA and hyperfluorescence area on ICGA was  $0.55 \pm 0.15$  for grader 1 and  $0.49 \pm 0.15$  for grader 2. The mean area of hyperfluorescence on SS-OCTA and ICGA was 3.976 (IQR, 2.139-8.168) and 3.043 (IQR, 1.408-4.909) mm<sup>2</sup> in the fellow eyes of CSC patients. The area of abnormalities on SS-OCTA after laser treatment or observation was 3.36mm<sup>2</sup>(IQR, 2.399-9.312), which was smaller than that in the baseline (7.311mm<sup>2</sup>, IQR 3.788-11.209, P<0.001). Change of Type A area was not significantly different between the two groups (P=0.679).

**Conclusion:** Coarse granulated high reflective area in SS-OCTA corresponded well with the hyper-permeability area in ICGA. Ultra-widefield SS-OCTA promotes noninvasive visualization and follow-up quantifications of the retinal and choroidal vasculature in CSC patients.

PP-471

## Choroidal and Retinal Anatomical Response Following Treatment of Carotid-Ophthalmic Aneurysms with Flow Diverter Stents

E *Biberoglu*<sup>1</sup>, H *Haidar*<sup>2</sup>, M *Eraslan*<sup>3</sup>, F *Baltacioglu*<sup>4,5</sup>.

<sup>1</sup>*Department of Ophthalmology, Marmara University Pendik Educational and Research Hospital,* <sup>2</sup>*School of Medicine, Marmara University, Istanbul, Türkiye,* <sup>3</sup>*Department of Ophthalmology, School of Medicine, Marmara University,* <sup>4</sup>*Department of Radiology, Marmara University School of Medicine,* <sup>5</sup>*Department of Radiology, VKV American Hospital, Istanbul, Türkiye*

**Objective:** Flow diverter stents(FDSs) are recent additions to the endovascular armament for treating ophthalmic segment aneurysms. Major concerns, however, are the hemodynamic changes and/or patency of the ophthalmic artery which is often covered after FDS deployment, and its associated ophthalmic complications. In our study we evaluated the long-term effect of FDS placement on multiple Optic Coherence Tomography(OCT) findings as well as the Best Corrected Visual Acuity(BCVA).

**Methods:** A prospective cohort study was conducted in 35 patients who were treated with a single FDS placement, between 2013 and 2018, for an aneurysm in the Ophthalmic segment of the Internal Carotid Artery. Patients with ruptured aneurysms were excluded. Enhanced depth imaging by spectral domain OCT (SD-OCT) was used to measure retinal nerve fiber layer(RNFL) thickness, ganglion cell complex(GCC) thickness, subfoveal choroidal thickness(SFCT), and other stereometric parameters. Choroidal Vascularity Index(CVI) in a 1.5mm wide subfoveal choroidal area was calculated. BCVA was assessed using Snellen chart and Intra-Ocular Pressure(IOP) with Goldmann applanation tonometry. These measurements, at final follow up, were compared to the untreated fellow eye to evaluate the long-term effect of FDS placement.

**Results:** This study included 70 eyes from 35 patients (100% female) with a mean age of  $54.9 \pm 9.8$  years and mean follow-up period of  $37.3 \pm 18.9$  months. The treated aneurysm was right sided in 14(40%) patients and left sided in the remaining 21(60%) patients. Normal Ophthalmic artery patency was reported following the endovascular intervention in all patients. The mean CVI was significantly higher in the stented side compared to the fellow normal eye ( $66.90 \pm 1.95$  vs  $65.05 \pm 1.93$ ,  $p=.001$ ) while mean SFCT was significantly reduced ( $251.23 \pm 68.54$  vs  $288.78 \pm 78.95$ ,  $p=.037$ ). However, differences in the remaining studied parameters did not reach statistical significance, this includes: BCVA, IOP, RNFL, optic nerve head volume, rim volume and cup volume.

**Conclusion:** FDSs did not cause permanent visual damage, although it caused a decrease in SFCT, and an increase in CVI in the long term. As the SFCT decreased, both the luminal- and stromal components of the choroid declined however the decline in the luminal component was more subtle compared to the stroma and consequently resulted

in an increased CVI, in the FDS side. This observation seems to stem from a reduction in ophthalmic artery flow which stimulates angiogenesis in that side.

PP-472

**Detection of diabetic retinopathy lesions by different scanning ranges using wide-field optical coherence tomography Angiography**M *LI*, M Mao, D *Wei*, J *Li*, J *Zhong*.

**Objective:** To compare the detecting rates of wide-field swept-frequency optical coherence tomography angiography (SS-OCTA) with different scanning ranges for diabetic retinopathy (DR) lesions.

**Methods:** The study recruited patients with diabetes who attended ophthalmic clinics in our hospital between November 2021 and April 2022. All participants underwent a comprehensive eye examination and OCTA scan (24mm x 20mm, 12mm x 12mm). OCTA scans were obtained using a 400 kHz wild field SS-OCTA instrument (BM-400K BMizar OCTA). It uses a swept-source Vertical-cavity surface-emitting laser (VCSEL) with wavelength of 1060 nm and with a 400,000 A-scans speed. OCTA imaging is capable of capturing images of retinal blood flow in a range of 24mm x 20mm by a single scan, and generates with a total field of view (FOV) up to 80 degrees. For each scan, the presence or absence of certain lesions were recorded: microaneurysms (MAs), intraretinal microvascular abnormalities (IRMA), neovascularization (NV), nonperfusion areas (NPAs), hard exudates (HE), and diabetic macular edema (DME), for comparing the diagnostic efficiency of 24mm x 20mm and 12mm x 12mm.

**Results:** A total of 154 eyes of 89 diabetic patients were enrolled in this study, including 44 eyes with no DR, 31 eyes with mild to moderate non-proliferative diabetic retinopathy (NPDR), 47 eyes with severe NPDR, and 32 eyes with proliferative diabetic retinopathy (PDR). The average age of the participants was  $56.35 \pm 11.90$  years; the average duration of diabetes was  $9.32 \pm 7.57$  years; 52 eyes were complicated with diabetic macular edema. In 24mm x 20mm imaging, the detection rates of MAs, IRMA, NV, NPAs, HE, and DME were 65.2%, 47.7%, 20.6%, 61.9%, 60.0%, and 33.55% respectively. The detection rates of MAs, IRMA, NV, NPAs, HE, and DME in the 12mmx12mm area were 52.3%, 36.8%, 17.4%, 49.7%, 58.1%, and 33.55% respectively. The diabetic retinopathy detection rates in the 24mm x 20mm were significantly higher than that in the 12mm x 12mm imaging ( $p < 0.05$ ). The results suggests that the larger the scanning range, the more lesions were detected. With the expansion of the scanning range from 12mm x 12mm to 24mm x 20mm, more IRMA and NV lesions were detected in 21 eyes.

**Conclusion:** The wide-field OCTA used in this study can quickly obtain capturing images of retinal blood flow in a range of 24mm x 20mm by a single scan, which can significantly improve the detection rate of DR lesions compared with the 12mm x 12mm OCTA images commonly used in most previous studies.

PP-473

**Effect of Levetiracetam on Ocular Perfusion Measure with OCT-Angiography**

A Kaderli, H Kayıloğlu<sup>1</sup>, S Tamer Kaderli<sup>2</sup>, A Karalezli<sup>2</sup>.

<sup>1</sup>Pediatric Neurology, <sup>2</sup>Ophthalmology, Mugla University, Mugla, Türkiye

**Objective:** To evaluate the macular and optic nerve head blood flow in pediatric epilepsy patients treated with levetiracetam for at least 12 months with optical coherence tomography-angiography (OCTA).

**Methods:** 33 pediatric epilepsy patients and 30 sex and age-matched healthy volunteer children were included in the study. OCTA was used to evaluate the optic nerve head and macular perfusion changes. Mean ocular perfusion pressures (MOPP) were also calculated. Patients using multiple antiepileptic drugs or prior history of different drug use were excluded from the study.

**Results:** Choriocapillaris flow area was significantly lower in the study group than the control group ( $p=0.006$ ). However, foveal avascular zone, vessel densities of macula in superficial, deep capillary plexus and optic nerve head were not significantly different from healthy eyes ( $p>0.05$ ). There was also no significant difference between the two groups in means of MOPP ( $p=0.211$ ). No obvious correlation is found between treatment duration and OCTA parameters or MOPP.

**Conclusion:** In children taking levetiracetam, choroidal perfusion was reduced compared to controls, while retinal perfusion was not affected in this OCTA study.

PP-474

**Two-Year Choroidal Thickness Attenuation and its Associations in Healthy Chinese Adults**W Cai, W Wang<sup>1</sup>, W Huang<sup>1</sup>, K Xiong<sup>1</sup>.<sup>1</sup>Preventive Ophthalmology, State Key Laboratory of Ophthalmology, Guangzhou, People's Republic of China

**Objective:** Identifying clinical associations causing attenuation in choroidal thickness (CT) among healthy Chinese adults.

**Methods:** A 2-year, longitudinal study was conducted in volunteers aged over 30 years old from China. All participants had no history of previous eye disease or surgery. All subjects underwent swept-source optical coherence tomography (SS-OCT) to measure the CT in the macular region at baseline and at 2-year follow-up. The regression models were based on the generalized estimating equation (GEE).

**Results:** A total of 603 eyes of 336 healthy participants were included in the final analysis (mean [SD] age, 58.88 [8.82] years; 74.70% female). Mean choroidal thickness (MCT) was reduced significantly from 206.62 [72.42] to 194.02 [72.08]  $\mu\text{m}$  (difference, -12.60  $\mu\text{m}$ ; 95% confidence interval [CI], -13.62 to -11.57). Among the ETDRS grid, CT at the subfoveal sector showed the greatest 2-year reduction (difference, -14.55  $\mu\text{m}$ ; 95% CI, -15.87 to -13.22). The largest 2-year change was observed in the 50-59 years group (difference, -14.51  $\mu\text{m}$ ; 95% CI, -16.71 to -12.32). Multivariate regression showed female ( $\beta = -2.85$ ; 95%CI, -5.65 to -0.56) and baseline MCT ( $\beta = -0.040$ ; 95%CI, -0.056 to -0.024) were significantly and independently associated with greater 2-year CT decrease.

**Conclusion:** These results indicated that CT among Chinese healthy adults decreased during the 2-year follow-up, and the greater choroidal thinning rate was significantly associated with female gender and larger baseline MCT.

PP-475

**Ocular microvascular alteration in Sjögren syndrome**Q Yang<sup>1</sup>, Y Shao<sup>2</sup>.

<sup>1</sup>Department of Ophthalmology, West China Hospital, Chengdu, <sup>2</sup>The First Affiliated Hospital of Nanchang University, Nanchang, People's Republic of China

**Objective:** Sjögren syndrome (SjS) is a systemic disease affecting exocrine, including ocular lacrimal glands. It is uncertain whether ocular microvascular alterations are associated with this disease. In this study, we evaluated retinal and conjunctival microvascular changes in SjS patients using optical coherence tomography angiography (OCTA).

**Methods:** Twelve SjS patients (24 eyes) and 12 normal controls (24 eyes) were recruited to this study. Three-dimensional conjunctival and retinal OCTA images of each eye were captured and microvascular density was calculated. Each image was analyzed by retinal area based on the early treatment of diabetic retinopathy study method (R, S, L, and I) hemisphere segmentation method (SR, SL, IL, and IR); and central wheel division method (C1-C6). Correlation analyses were used to look for associations between retinal and conjunctival microvascular densities.

**Results:** Superficial and deep retinal layer microvascular density was decreased in SjS patients compared with normal controls ( $P < 0.05$ ). This significant difference was found in both superficial and deep layers in S, L, SL, IL and C1-C3 regions, and additionally in the I and SR regions in the superficial layer. Conversely, in the conjunctiva microvascular density was higher in SjS patients than in controls. In SjS patients, a significant negative correlation was found between conjunctival and both superficial ( $r = -0.641$ ;  $P = 0.025$ ) and deep ( $r = -0.958$ ;  $P < 0.0001$ ) microvascular densities.

**Conclusion:** The changed microvascular densities measured in deep and superficial retinal layers and in the conjunctiva demonstrate that OCTA is a promising method in differentiating the eyes from those with SjS.

PP-476

**Assessing Retinal Blood Vessel Diameter by Optical Coherence Tomography in Patients with Raynaud's Phenomenon**T Goncu Firat<sup>1</sup>, S Esmen<sup>2</sup>, O Ağca<sup>1</sup>, O Sayın<sup>1</sup>.<sup>1</sup>Ophthalmology, <sup>2</sup>Rheumatology, Konya City Hospital, Konya, Türkiye

**Objective:** To determine the retinal vessel diameters of the patients with Raynaud phenomenon and to compare these measurements with those of healthy subjects.

**Methods:** This prospective, comparative clinical study included 26 patients with Raynaud phenomenon and 27 age and sex-matched control subjects. All participants underwent a detailed rheumatological and ophthalmological examinations. Retinal vessel diameters were obtained by using spectral domain optical coherence tomography (SD-OCT). An SD-OCT protocol consisted of a circular scan with 3,42-4,04 mm ring diameter centered on the optic disc and simultaneous infrared image of optic disc were used for vessel diameter measurements.

**Results:** No significant differences in demographic characteristics were detected between Raynaud group and controls ( $p>0.05$ ). The mean diameter of retinal artery was higher in Raynaud group compared to control group however, this difference was not statistically significant ( $86,4 \pm 18,4$  vs  $82,6 \pm 18,1$   $\mu$  m,  $p=0,068$ ). Similarly, the mean diameter of retinal vein was higher in Raynaud group compared to control group but the difference did not reach statistical significance ( $115,8 \pm 33,0$  vs  $108,5 \pm 23,5$   $\mu$  m,  $p=0,218$ ). And in four quadrants, the diameters of both retinal arteries and veins did not differ significantly in Raynaud group compared to the control group ( for all  $p>0.05$ ).

**Conclusion:** In this study we did not observe any clinically significant difference in retinal blood vessel diameter for Raynaud phenomenon.



PP-477

**Repeatability and reproducibility of the central and mid-peripheral corneal thickness measurement with a new Scheimpflug imaging**J Huang<sup>1</sup>, J Ye<sup>2</sup>, A Yu<sup>2</sup>.<sup>1</sup>Fudan University, Shanghai, <sup>2</sup>Wenzhou Medical University, Zhejiang, People's Republic of China

**Objective:** To assess the intra-observer repeatability and inter-observer reproducibility of central corneal thickness (CCT) and mid-peripheral corneal thickness (MPCT) measurements using a new Scheimpflug imaging instrument (Scansys) and compare the agreement with the rotating Scheimpflug corneal tomographer (Pentacam HR).

**Methods:** The same well-trained operator performed the measuring using the two devices, after which Scansys measurements were repeated by another operator. Both instruments required three consecutive measurements per subject. Corneal thickness measurements were obtained by each instrument, including CCT, thinnest corneal thickness (TCT), pupil corneal thickness (PCT), and MPCT. Test-retest repeatability (TRT), within-subject coefficient of variation (CoV), and intra-class correlation coefficient (ICC) were used to evaluate repeatability and reproducibility. A paired t-test was used to compare the differences between Scansys and Pentacam, and the agreement was compared with Bland-Altman plots.

**Results:** This study enrolled 112 healthy subjects. The CoV were < 0.91% and 0.55% for repeatability and reproducibility, respectively. The ICC was close to 1 in all measurements. For intra-observer repeatability in the CT2mm region, TRT was < 10.30 $\mu$ m. Moreover, TRT was < 15.26 $\mu$ m within the CT5mm region. The paired t-test showed significant differences in all corneal thickness measurements ( $P < 0.001$ ). The central region and CT2mm agreement were high, but the largest range of 95% limits of agreement (LoA) appeared in the CTnasal-5mm.

**Conclusion:** The new Scheimpflug imaging instrument showed excellent intra-observer repeatability and inter-observer reproducibility for corneal thickness measurements. The agreement analysis suggested that Scansys and Pentacam could be interchangeably used between the central region and CT2mm, except CT5mm.

## PP-480

**Does choroidal vascularity index increase in central serous retinopathy patients?**

D Kilic<sup>1</sup>, B Ayyildiz<sup>1</sup>, I Toprak<sup>2</sup>, B Akmaz<sup>3</sup>, S Koca<sup>1</sup>, E Vural<sup>4</sup>.

<sup>1</sup>Kayseri City Training and Research Hospital, Kayseri, <sup>2</sup>Pamukkale University School of Medicine, Denizli, <sup>3</sup>Bozyaka Training and Research Hospital,, Izmir, <sup>4</sup>Başakşehir Çam and Sakura City Hospital, Istanbul, Türkiye

**Objective:** To evaluate the choroidal vascularity index (CVI) in central serous retinopathy (CSR) patients and to compare with healthy controls.

**Methods:** The study was a cross-sectional study in design. There were 25 acute CSR patients and 35 healthy subjects. The CSR patients should have their symptoms in less than 6 months. After a comprehensive ophthalmological anterior segment examination and dilated fundus examination all patients had an optical coherence tomography (OCT) imaging. By using ImageJ software the choroidal images taken from OCTs were assessed. The total choroidal area (TCA), the luminal area (LA) and the stromal area (SA) of the choroidal measurements were detected from the images. The ratio of the LA to TCA was defined as CVI. The subfoveal choroidal thickness (SCT) and CVI measurements of CSR patients and controls were compared. The correlation between SCT and CVI was also assessed.

**Results:** There were 25 eyes of CSR patients and 35 eyes of controls. Age and sex were equally in both groups ( $p>0.05$ ). The mean CVI value was  $64.40 \pm 0.17\%$  in the CSR group and  $63.44 \pm 0.20\%$  in the control group ( $p=0.01$ ). The mean SCT was higher in the CSR group than in the control group ( $p=0.029$ ). There was a positive correlation with SCT and CVI in both groups ( $r=0.425$ ,  $p<0.01$  in CSR patients and  $r=0.432$ ,  $p<0.01$  in control group).

**Conclusion:** The CVI is a new diagnosing tool and it can be easily measured from the OCT images. In this study the CVI was increased in patients with CSR patients than in controls and the CVI was positively correlated with SCT.

PP-481

## A Bi-modal DCNN Approach to Distinguish Age-related Macular Degeneration (AMD) and Non-AMD Funduscopy Datasets

I Farzana<sup>1,2</sup>, S Supanji<sup>1</sup>, A Suhendar<sup>3</sup>, A Sirwan<sup>3</sup>, T Ayuningsih<sup>3</sup>, H Nugroho<sup>3</sup>.

<sup>1</sup>Ophthalmology, Faculty of Medicine Gadjah Mada University, Yogyakarta, Indonesia, <sup>2</sup>Ophthalmology, Chulalongkorn University, Bangkok, Thailand, <sup>3</sup>Artificial Intelligence Research Team, Telkom Indonesia, Limited Company, Jakarta, Indonesia

**Objective:** Age-related Macular Degeneration (AMD) is the leading cause of vision impairment which affects the retinal tissue in the elderly worldwide. AMD stages were defined in the Age-Related Eye Disease Study (AREDS) as none, early, middle, and late AMD. According to the American Academy of Ophthalmology, those with intermediate AMD should be seen at least once every two years. By 2040, it is estimated that 288 million individuals would have developed AMD, with around 10% developing intermediate AMD or worse. In general, these retinal tissues are examined subjectively by an ophthalmologist by manual screening. However, manually inspecting many fundus photographs is a time-consuming and challenging task. Additionally, the diagnostic accuracy may be influenced by the examiner's expertise.

The aim of the research was to assess the effectiveness of bi-modal deep learning algorithms in classifying funduscopy eye scan patients with Age-related Macular Degeneration (AMD) from normal datasets.

**Methods:** A total of 400 Funduscopy images acquired from publicly available dataset of AMD Grand Challenge website with a fully downloadable picture from that website comprised of 311 normal eyes, and 89 Age related macular degeneration's patients eyes. These datasets were used to develop the model. The images were split into training set and validation set. Two convolutional neural networks consisting of InceptionV3, and NasNetL were trained to classify images. Performance of each model was evaluated using cross validation technique which was done in three subsets in each model.

**Results:** On a test set of 400 fundus images from 311 normal eyes and 89 AMD eyes, the bi-modal DCNN approach demonstrated a high performance with the InceptionV3 model revealing the accuracy of training set 90.94 percent, 89.89 percent, and 91.04 percent, respectively. On the other hand, The NasNetL model, illustrated training accuracy of 91,32 percent, 90,64 percent, and 91,42 percent in consecutive tests. In the validation subset, the performance of the model for the InceptionV3 classifier is 86.66 percent, 82.71 percent, and 88.63 percent, respectively. While for NasNetL, the accuracy of validation is 88,88%, 85,71%, and 87,12% sequentially.

**Conclusion:** A bimodal DCNN for recognition and classification of AMD and non-AMD is accurate and promising for improving ophthalmic care in the future. Especially in primary care settings.

PP-482

### The Additive Value of Choriocapillaris Perfusion in SS-OCTA for Predicting the Incidence of Diabetic Retinopathy

Y Chen, W Huang, W Wang.

**Objective:** To determine the relationship of the choriocapillaris perfusion index (CPI) derived from SS-OCTA to a two-year incidence of DR.

**Methods:** In this two-year prospective cohort study, type 2 diabetic patients without DR were recruited beginning in November 2017 and followed up annually at the Zhongshan Ophthalmic Center. A total of 822 eligible subjects underwent an SS-OCTA examination (DRI-OCT Triton; Topcon Inc., Tokyo, Japan). The novel established CC perfusion parameter, CPI, was assessed with ImageJ software after segmentation of CC slab. Data on histories of patients' diabetic duration, HbA1c, and other systemic factors were collected at baseline.

**Results:** Of 822 participants, 187 subjects (22.8%) developed DR within two years. The mean [SD] age of the participants was 64.4 [8.0] years, and 60.1% were female. Patients with an incidence of DR had a lower CPI as compared with those without DR in the whole image ( $P < .001$ ). After adjustment for confounding risk factors, reduced whole image CPI was significantly associated with a two-year incidence of DR (relative risk [RR] 0.69 per 1-SD increase; 95% CI 0.55–0.87;  $P = .001$ ). Moreover, reduced CPI in the parafoveal, central field, nasal field, inferior field, and temporal field regions were associated with the incidence of DR (all  $P < .05$ ). Inclusion of whole image CPI improved the discriminative ability of the conventional prediction model based on established risk factors for two-year DR onset (AUC increased from 0.654 [95% CI 0.609–0.698] to 0.680 [95% CI 0.638–0.722],  $P < .037$ ).

**Conclusion:** A reduced CPI is associated with the incidence of DR, and the CPI can further serve as a predictor for DR onset. Our findings provide new longitudinal insights to support the role of CC perfusion parameters as a potential indicator to be considered in the prediction of DR onset in individuals with diabetes.

PP-483

**Multimodal Deep Learning with Feature Level Fusion for Identification of Choroidal Neovascularization Activity in AMD**K Jin, J Ye<sup>1</sup>.

<sup>1</sup>*Department of Ophthalmology, the Second Affiliated Hospital of Zhejiang University, Hangzhou, People's Republic of China*

**Objective:** This study aimed to determine the efficacy of a multimodal deep learning (DL) model using optical coherence tomography (OCT) and optical coherence tomography angiography (OCTA) images for the assessment of choroidal neovascularization (CNV) in neovascular age-related macular degeneration (AMD).

**Methods:** This retrospective and cross-sectional study was performed at a multicenter, and the inclusion criteria were age >50 years and a diagnosis of typical neovascular AMD. The OCT and OCTA data for an internal dataset and two external datasets were collected. A deep learning model was developed with a novel feature level fusion (FLF) method utilized to combine the multimodal data. The results were compared with identification performed by an ophthalmologist. The best model was tested on two external datasets to show its potential for clinical use.

**Results:** Our best model achieved an accuracy of 95.5% and an area under the curve (AUC) of 0.9796 on multimodal data inputs for the internal dataset, which is comparable to the performance of retinal specialists. The proposed model reached an accuracy of 100.00% and an AUC of 1.0 for the Ningbo dataset, and these performance indicators were 90.48% and an AUC of 0.9727 for the Jinhua dataset.

**Conclusion:** The FLF method is feasible and highly accurate, and could enhance the power of the existing computer-aided diagnosis systems. The bi-modal computer-aided diagnosis (CADx) system for the automated identification of CNV activity is an accurate and promising tool in the realm of public health.

PP-484

**Ophthalmic Artery Morphological and Hemodynamic Features in Acute Coronary Syndrome**L Wu<sup>1</sup>, J Wang<sup>1</sup>, Y Wang<sup>1</sup>.<sup>1</sup>Beijing Friendship Hospital, Capital Medical University, Beijing, People's Republic of China

**Objective:** To examine the morphological and hemodynamic changes of the ophthalmic artery (OA) in patients with acute coronary syndrome (ACS).

**Methods:** This cross-sectional observational study included 31 patients with ACS and 10 healthy controls (HCs). The ACS subgroups were ST-segment elevation myocardial infarction (STEMI; n = 10), non-STEMI (n = 10), and unstable angina (n = 11). OA three-dimensional (3D) models were reconstructed based on computed tomographic angiography, and morphological aspects of the OA were measured quantitatively. Moreover, numerical simulation by computational fluid dynamics was used to obtain hemodynamic information of the OA.

**Results:** The study reconstructed 41 OA models. Hemodynamic simulation revealed a significant decrease in OA blood velocity in patients with ACS compared with the HCs (median velocity, 0.046 vs. 0.147 m/s; P < 0.001). No differences in the morphological data for the OA were observed. Also, no differences in the mass flow ratio of OA to the ipsilateral internal carotid artery was found. Similar differences were observed between the ACS subgroups and HCs. OA blood velocity was negatively correlated with body mass index, abdominal circumference, left ventricular ejection fraction, and triacylglycerol and was positively correlated with early to late transmitral flow velocity, N-terminal pro-brain natriuretic peptide, serum creatinine, and potassium.

**Conclusion:** The initial OA blood velocity was slower in patients with ACS and was

associated with ACS-related clinical parameters. To our knowledge, this is the first study to analyze OA characteristics in ACS using 3D model reconstruction and hemodynamic simulation, providing new perspectives on the relationship between ischemic heart disease and ocular manifestations.

PP-485

**Quantitative evaluation of three-dimensional Choroidal Vascularity Index topographic profile in children with different refractive**F Liu, M li, X zhou.

**Objective:** To investigate the characteristics and influencing factors of three-dimensional choroidal vascularity index (CVI) in children with different refractive status.

**Methods:** A total 274 eyes from 143 consecutive children with simple myopia (78 males and 65 females) were enrolled in the study, including 56 eyes with emmetropia (EM), 151 eyes with low myopia (LM) and 67 eyes with moderate-high myopia (MHM). Swept-source optical coherence tomography (SS-OCTA) covering an area of 9 x 9 mm<sup>2</sup> centered on the fovea was performed to obtain the 3D CVI and choroidal vessel volume (CVV) and choroidal stroma volume (CSV) parameters in Early Treatment Diabetic Retinopathy Study (ETDRS) grid. Among choroidal parameters were compared in different groups at different regions and stepwise multiple regression was used to identify the independent risk factors of 3D CVI.

**Results:** Compared with the other groups, the more myopic group had significantly lower choroid vessel and stromal volume in all areas and higher 3D CVI in most areas (any two groups, all  $p < 0.05$ ). The nasal quadrant had the greatest 3D CVI and lowest CSV and CVV, and the lowest 3D CVI and greatest CSV, CVV were in temporal quadrant in three groups. As for the eccentricities alteration of 3D CVI, the perifovea region were highest, followed by pararetinal region and central fovea area in emmetropia and LM group, while the CVI of MHM group was highest in central fovea, lowest in the perifovea region. Stepwise multiple linear regression analysis after adjusting gender, age and BMI showed only AL was independently associated with the CVI of central fovea and parafovea regions (all  $p < 0.05$ ).

**Conclusion:** The CSV and CVV were higher and 3D CVI were lower in children with more myopic eyes and disturbed 3D CVI was only related to AL. The comprehensive quantitative analyses of the choroidal vasculature by 3D CVI may help to characterize the underlying pathophysiology of myopic children.



PP-486

**Evaluation and Quantification of Choroidal Morphology Using Optical Coherent Tomography**X Zhang.

**Objective:** Dysfunction of the choroid has been implicated in various retinal and choroidal diseases. The recent rapid revolution of optical coherence tomography (OCT) such as the Swept-Source OCT and OCT angiography has greatly contributed to the analysis of the morphology and physiology of the choroid precisely, especially to the choroid-scleral boundary and vasculature. In this manuscript, we highlighted the recent available evidence on the measurement methodology, the clinical significance of choroidal thickness and OCTA manifestations in various choroidal disorders.

**Methods:** We searched PubMed, Medline, Springerlink, the Cochrane Library, Google Scholar and EMBASE Medline database from year 1990 to June 28, 2022 to retrieve English articles with the following key terms: 'Swept Source Optical Coherent Tomography', 'central serous retinopathy', 'chorioretinopathy', 'polypoidal choroidal vasculopathy' and 'neovascular age related macular degeneration. The search is limited with the terms 'imaging' or 'imaging biomarkers' or 'trial' or 'randomized' to focus on the findings of randomized clinical trials, cohort study, meta-analyses, reviews and technological advancements in the past decade.

**Results:** Choroidal thickness (ChT) measuring in vivo has been reported in various diseases using different available methods/devices including ultrasound and OCT since 1979. Till now, ChT has become a vital predictive imaging biomarker for both retinal and choroidal disorders. We highlighted the methods for measuring ChT including histopathological and ultrasound, OCT (manual and automatic segmentation methods), clinical significance of ChT, OCT and OCTA parameters to describe the morphological characteristics of the choroid.

**Conclusion:** To date, there is no unified standard for ChT measurement that is carried out manually or via automatic segmentation method according to ETDRS grid. The establishment of ChT normal value needs large-scale, multicenter research in order to explore the pathogenesis of the fundus diseases and provide a new horizon on the management. In addition, whether ChT could quantitatively reflect the choroidal blood flow needs further study. OCTA and OCT provide useful parameters for diagnosis and follow up the patients.

**PP-487****Explainable Artificial Intelligence - Insights into Retinal OCT images classified by a deep learning model**A Puri.

**Objective:** To explain why a deep learning retinal OCT image classifier model gave its decision and break the myth that deep learning models are black boxes.

**Methods:** A Resnet 18 deep learning model was trained on retinal optical coherence tomography (OCT) images, to classify them into four classes - Choroidal neovascular membrane, diabetic macular edema, drusen and normal. Using the GradCam algorithm, class activation maps were generated for these images, whether correctly or wrongly classified by the model. These images highlighted the features or pixels selected by the model to classify, or in other words, give its decision. Some of the images were then modified, split and even changed in their orientation. They were presented to the model again to classify and then to generate the the GradCam images.

**Results:** The region or the group of pixels used by the model to classify the images, whether right or wrong, were highlighted by GradCam. The highlighted regions of the correctly classified images, used by the model to give its decision, were the same as those used by a clinician to arrive at the diagnosis. If there were multiple lesions, all of them were highlighted. When modified images were presented to the model, it could still find and highlight the pattern of pixels it had learnt for classifying, irrespective of their location in the image. The pattern in the highlighted regions of wrongly classified images were carefully studied and inter-class similarities were discovered.

**Conclusion:** GradCam algorithm allows a better understanding of deep learning models which till date are mostly considered as black boxes. Making it interpretable and explainable, not only enhances the confidence of the model user, but also lends scope to look back at the training image dataset and improve it further.

PP-488

**Direct Estimation of Choroidal Thickness in Optical Coherence Tomography Images with Convolutional Neural Networks**

Z Jiang<sup>1</sup>, Y Rong<sup>2</sup>, W Wu<sup>2</sup>, Q Chen<sup>2</sup>, C Wei<sup>2</sup>, H Chen<sup>1</sup>, Z Fan<sup>2</sup>.

<sup>1</sup>Joint Shantou International Eye Center, <sup>2</sup>Shantou University, Shantou, People's Republic of China

**Objective:** The present methods of estimating choroidal thickness are based on the segmentation of the boundaries, which is prone to be affected by the segmentation error. This paper proposes a novel method for directly estimating choroidal thickness based on convolutional neural networks (CNNs) without segmentation.

**Methods:** 38400 B-scan images of 150 eyes are collected from a Topcon Triton. The ground truth of choroidal thickness is computed based on the boundaries segmented by the inbuilt algorithm and manually corrected for segmentation error by an ophthalmologist. The B-scan images are cropped into several patches. A CNN model is then trained with the patch-thickness pairs. During testing stage, given an unseen B-scan image, the B-scan image is also cropped into several patches. The trained CNN model is employed to predict the choroidal thickness for each patch. The mean thickness of choroid in the B-scan is obtained by taking the average of patches.

**Results:** The mean absolute error and Poisson correlation coefficient obtained by the proposed method are 4.3001 (pixels) and 0.9274 when the patch is  $200 \times 200$ , respectively. The percentages of B-scans in the intervals of mean absolute error less than 5 and 10 (pixels) obtained by the proposed method are 75.30% and 90.86%, respectively.

**Conclusion:** Directly estimating the choroidal thickness with CNNs is a promising approach and competitive with segmentation-based methods.

PP-489

## Regional Choroidal Thickness Estimation from Color Fundus Photographs Based on Convolutional Neural Networks

Z Jiang<sup>1</sup>, Y Rong<sup>2</sup>, Q Chen<sup>2</sup>, H Chen<sup>1</sup>, Z Fan<sup>2</sup>.

<sup>1</sup>Joint Shantou International Eye Center, <sup>2</sup>Shantou University, Shantou, People's Republic of China

**Objective:** To estimate the regional choroidal thickness from color fundus photographs based on convolutional neural network (CNN), this paper attempts to explore which network structures and task learning models may be helpful to further improve the predicted accuracy.

**Methods:** 1276 normal color fundus photos and their corresponding choroidal thickness values were collected from Topcon DRI Triton OCT machine and divided into 1020 training sets, 128 test sets, and 128 verification sets. Firstly, ten common CNNs were employed to find out the most accurate one for further training. Then, single and multiple tasks learning models were applied separately to predict the average and every sub-region choroidal thickness in Early Treatment Diabetic Retinopathy Study (ETDRS) and 100-grids around the macular fovea.

**Results:** Efficientnetb0 network outperforms other networks with the lowest mean absolute error (MAE=25.61  $\mu$  m) and highest coefficient of determination ( $R^2=0.78$ ),  $P < 0.01$ . Single task model shows the highest estimated accuracy in the average choroidal thickness estimation (MAE=25.61,  $R^2=0.78$ ,  $P<0.01$ ), while single task and multiple tasks learning models in ETDRS and 100-grids sub-regions choroidal thickness estimation all show worse results (MAE>33.20  $\mu$  m,  $R^2<0.7405$  and MAE>31.10,  $R^2<0.7650$ , respectively).

**Conclusion:** Efficientnetb0 CNN of single task learning model is best for the average choroidal thickness estimation from color fundus photographs. Different task learning models cannot enhance the estimation accuracy, but multiple tasks learning model is better than single task in sub-regions choroidal thickness estimation, which is still worthy of further exploration.

PP-491

**CSO MS39 AS-OCT Corneal Epithelial Thickness Mapping: Repeatability and Agreement with Heidelberg Anterior and Optovue Avanti**Y Feng<sup>1</sup>, A Stojanovic<sup>1,2</sup>.<sup>1</sup>Faculty of Health Science, The Arctic University of Norway, <sup>2</sup>Department of Ophthalmology, University Hospital North Norway, Tromsø, Norway

**Objective:** To assess the repeatability of Corneal Epithelial Thickness Mapping (ETM) in keratoconic (KC) eyes using a novel spectral-domain (SD) optical coherence tomography (OCT) combined with Placido disk corneal topography (MS39), and to determine the agreement of the measurements with two validated devices.

**Methods:** Analysis of 60 KC eyes was performed. Three consecutive measurements of each eye were acquired with MS39, Anterior SS-OCT and Avanti SD-OCT devices, and averages of the ETMs were calculated in the central 2 mm zone as well as in the 2-5 mm and 5-7 mm diameter rings. The repeatability was analyzed using pooled within-subject standard deviation ( $S_w$ ). The agreement was assessed by paired t-tests and Bland-Altman plots.

**Results:** The repeatability ranges of MS39, Anterior and Avanti ETM measurements in KC eyes were:  $S_w$ : 0.78 - 1.37  $\mu\text{m}$ , 0.71 - 1.59  $\mu\text{m}$  and  $S_w$ : 0.75 - 1.79  $\mu\text{m}$ , respectively. All the values of the thickness measurements with MS39 were higher than Anterior's with the mean differences of  $2.59 \pm 1.15 \mu\text{m}$  ( $p < 0.001$ ), but lower than Avanti's with mean differences of  $0.99 \pm 1.17 \mu\text{m}$  ( $p < 0.001$ ). The 95% limits of agreement (LoA) were: for MS39 and Anterior, 0.336 - 4.844, for Avanti and MS39, -1.303 - 3.283, and for Avanti and Anterior, 1.258 - 5.922.

**Conclusion:** The repeatability of the MS39's ETM was lower than Anterior's but higher than Avanti's. In terms of the agreement, the epithelium measured by the MS39 was always thicker than Anterior but thinner than Avanti, making their interchangeability unsuitable without corrections.

PP-492

**WELDERS' MACULOPATHY – MYSTERY UNRAVELLED ON EN FACE OCT.**A Desai<sup>1</sup>, A Chauhan<sup>1</sup>, R Naigaonkar<sup>1</sup>, S Pohane<sup>1</sup>.<sup>1</sup>Vitreo-retina, Shri Ganapati Netralaya, Jalna, India

**Objective:** To enhance our understanding of structural changes in Welders' arc maculopathy by obtaining high resolution in vivo En face OCT images. Maculopathy associated to the use of welding devices is an infrequent entity, usually seen in under developed and developing countries. Retinal toxicity secondary to chronic exposure is more frequent. Acute toxicity caused by exposure to welding is very rare.

**Methods:** An observational study involving a case series of 6 patients (12 eyes) all males and welders by occupation who presented with blurring of vision after exposure to photo toxic radiations at Vitreoretina department at Shri Ganapati Netralaya, Jalna, Maharashtra, India.

A comprehensive ocular examination was done including BCVA (best corrected visual acuity), slit-lamp bio microscopy examination, dilated fundus examination by indirect ophthalmoscope and amsler's grid test. Image acquisition with Swept source OCT (b scans), OCT angiography (OCTA) & En face OCT (Topcon DRI Triton) and fundus photography was done.

**Results:** The age of the subjects ranged from 21 to 44 years (mean age 31.17 years). The duration of exposure varied from 1 month to 60 months (mean 19.33 months). BCVA ranged from 6/7.5-6/12 with normal anterior segment. Fundus examination showed yellow spot at the fovea in 8/12 eyes. OCT b scans revealed defect in ellipsoid & interdigitation zone at fovea in all eyes. OCTA was within normal limits. En face OCT revealed hyper reflective area with central hypo reflectivity at the level of outer retina (ellipsoid zone) in all eyes corresponding to central scotoma on Amsler's grid. The area of defect noted on En face OCT ranged from 124.10  $\mu\text{m}^2$  to 1187.57  $\mu\text{m}^2$  (mean 496.85  $\mu\text{m}^2$ ). The area of defect showed a positive correlation with the duration of exposure. Also, an inverse relationship was found between area of defect and BCVA.

**Conclusion:** To the best of our knowledge no one has studied En face OCT changes in welders' maculopathy till now. It is one of the first series to describe these observations & can be an adjunct in understanding pathology and natural history in photic retinopathies. Corresponding reflectivity changes can be seen on En face OCT, especially in the outer retina. OCTA reveals no changes in vasculature. There is a need for educating people involved in this profession who are mainly in the young age group, regarding appropriate protective measures mainly in the developing countries where the prevalence is more.

PP-494

**Evaluation of angle-to-angle, spur-to-spur, and white-to-white consistency using swept-source optical coherence tomography**X Wang, J Dong<sup>1</sup>.<sup>1</sup>First hospital of shanxi medical university, Taiyuan, People's Republic of China

**Objective:** Using swept source optical coherence tomography (SS-OCT), to investigate the iridocorneal angle-to-angle (ATA), sclera spur-to-sclera spur (STS), white-to-white (WTW) consistency and verify potential influencing factors.

**Methods:** As a prospective observational case series study. A total of 60 right eyes (60 subjects) were included in the study. The ATA, STS, WTW of 6 directions (0° - 180° , 30° - 210° , 60° - 240° , 90° - 270° , 120° - 300° , 150° - 330° ) through corneal vertex with 30 degrees interval were assessed using a SS-OCT. ANOVA test was used to compare the potential difference on each direction among the three parameters. A paired-sample t-test was used to test the difference of each parameter on all the 6 directions and the potential difference on each direction between every two parameters.

**Results:** For both ATA and STS, 90° - 270° direction was the longest and 0° - 180° direction was the shortest. For WTW, no significant difference was found between the two directions. Moreover, significant difference was found among the three parameters on 90° - 270° direction ( $F = 4.910$ ,  $P = 0.008$ ), but not the other five directions ( $P > 0.130$ ). For 90° - 270° direction scanning data, ATA was  $0.23 \pm 0.08$  mm wider than WTW ( $P = 0.005$ ), and STS was  $0.21 \pm 0.08$  mm wider than WTW ( $P = 0.010$ ), and no statistical difference was found between ATA and STS ( $P = 0.814$ ). Age was negatively correlation with all measured values. On the contrary, axial length was positively correlation with all measured values. ATA, STS, and WTW was significantly positively correlated with each other on the same direction (all  $P < 0.001$ ).

**Conclusion:** SS-OCT is able to measure the ATA, STS, WTW. Moreover, the ATA, STS of the vertical direction was longer than that of the horizontal direction, and the WTW is almost close to the circular.

PP-495

**Incidence and risk factors for Berger's space development after uneventful cataract surgery: evidence from SS-OCT**X Wang, Z Zhang<sup>1</sup>.<sup>1</sup>*Affiliated Wuxi Clinical College of Nantong University, Wuxi, People's Republic of China*

**Objective:** To investigate the incidence and risk factors for the development of Berger's space (BS) after uneventful phacoemulsification based on swept-source optical coherence tomography (SS-OCT).

**Methods:** AS a retrospective observational single-center study, cataractous eyes captured using qualified SS-OCT images before and after uneventful phacoemulsification cataract surgery were included. 6 high-resolution cross-sectional anterior segment SS-OCT images at 30° intervals were used for BS data measurements. BS width was measured at three points on each scanned meridian line: the central point line aligned with the cornea vertex and two point lines at the pupil margin.

**Results:** BS was observed postoperatively in 44 eyes (44/223, 19.7%). 13 eyes (5.8%) with insufficient image quality, pupil dilation, or lack of preoperative image data were excluded from the study. 31 postoperative eyes (13.5%) of 30 patients were included in the final data analysis. Preoperatively, only 2 eyes (0.9%) were observed to have consistent BS in all 6 scanning directions. The smallest postoperative BS width was in the upper quadrant of the vertical meridian line (90° ) with a mean value of 280  $\mu$ m. The largest BS width was observed in the temporal and inferior quadrants, which were the opposite area of the main clear corneal incision (120° ), with a mean value > 500  $\mu$ m.

**Conclusion:** Uneven-width BS is observable after uneventful phacoemulsification. Locations with a much wider BS (indirect manifestation of Wieger zonular detachment) are predominantly located in the opposite direction to the main corneal incisions.



PP-497

### Comparison of visualized retinal area between two ultra-wide field imaging systems in myopia patients: Clarus and Optos

D Yang<sup>1</sup>, F LIU<sup>1</sup>, L NIU<sup>2</sup>, M LI<sup>1</sup>, Y XIAN<sup>1</sup>, Y HUANG<sup>1</sup>, X WANG<sup>1</sup>, X Zhou<sup>1</sup>.

<sup>1</sup>Eye Institute and Department of Ophthalmology, Eye & ENT Hospital, Fudan University, <sup>2</sup>Eye Institute and Department of Ophthalmology, Eye & ENT Hospital, Fudan University, Shanghai, Shanghai, People's Republic of China

**Objective:** To compare two ultra-wide field (UWF) imaging systems: Clarus and Optos systems in detecting visualized retinal area in myopic patients.

**Methods:** 206 eyes of 106 myopic patients (76 female, 30 male) were recruited from March 2021 to July 2021 in Eye and ENT Hospital, Fudan University. UWF images were captured centrally with Optos UWFI (Daytona, Optos PLC, Dunfermline, United Kingdom) and Clarus montage UWFI (CLARUS 500TM, Carl Zeiss Meditec AG, Jena, Germany). All images were exported and reviewed in Image J. The fundus images were divided into 4 quadrants with macula in the center. To standardized the area measured, VRA were normalized to the optic disc area (DA) for each image. Generalized Estimating Equations (GEE) were performed to determine relationship between spherical equivalent and VRA of the Clarus and Optos UWFI systems.

**Results:** Clarus 500 montage image captured a larger visualized retinal area (VRA) in three directions than Optos single image: superior: 188.40 vs. 129.96, ( $P < 0.001$ ), inferior: 157.14 vs. 126.39 ( $P < 0.001$ ), nasal: 256.75 vs. 198.78 ( $P < 0.001$ ). Optos single image allowed capture of larger VRA of temporal direction than the Clarus 500 montage image (190.13 vs. 144.45,  $P < 0.0001$ ). There were no significant differences of VRA in vertical direction between the two UWFI systems ( $P > 0.05$ ). The greater spherical equivalent and longer axial length decreased the VRA of Optos UWFI system ( $P < 0.001$ ). Neither spherical equivalent ( $P > 0.05$ ) nor axial length ( $P > 0.05$ ) had an impact on the VRA in Clarus UWFI system.

**Conclusion:** Clarus 500 montage image captured a larger visualized retinal area (VRA) in superior, inferior and nasal directions, while Optos single image allowed capture of larger VRA of temporal direction. The greater spherical equivalent and longer axial length decreased the VRA of Optos UWFI system.

PP-498

### Comparison Of Tear Break UP Time Measurement Reproducibility Using Standard Fluorescein Strip On Slit Lamp And SCOOPY DOO

B Gajra<sup>1</sup>, A Prasad<sup>1</sup>, P Chandrakanth<sup>1</sup>, H Gosalia<sup>1</sup>.

<sup>1</sup>Aravind Eye Hospital, Coimbatore, Coimbatore, India

**Objective:** To compare the repeatability of Tear Break Up time (TBUt) measurement using standard 2% fluorescein strip on slit lamp with cobalt blue filter versus an innovative smartphone aided device called SCOOPY DOO (Smartphone aided CObalt Blue ocular photographY : DO it yOurself). SCOOPY DOO is a device that has an intraocular lens (IOL) attached to a smartphone camera alongwith a blue filter utilizing the smartphone flashlight or external LED light for anterior segment photography.

**Methods:** It was a prospective, randomized study of 120 eyes in which TBUt measurements were determined with the help of standard 2% fluorescein strip with both slit lamp and with SCOOPY DOO on the same eye at the same time. The results obtained by both the methods were compared.

**Results:** The p value was found to be less than 0.05. There was no statistically significant difference between the TBUt measurements of the two methods.

**Conclusion:** The TBUt results on SCOOPY DOO were comparable and found to be reliable as the TBUt results on conventional slit lamp using cobalt blue filter. Depth perception is compromised with SCOOPY DOO because of lack binocularity but an experienced user is able to focus at various distances. Image quality of the stained cornea of the two methods was found to be comparable. This was a first such study comparing the images and measurements on a smartphone with blue filter and slit lamp with blue filter. It is an easy to use, cost effective and portable device that can be used for anterior segment imaging in immobile and bedridden patients and in low resource settings where a slit lamp may not be available.

PP-499

**Longitudinal changes of choroidal and retinal thickness in diabetes patients without retinopathy: a 2-year prospective study**Y *Huang*, W Wang.

**Objective:** To evaluate the longitudinal changes of choroidal and retinal thickness in diabetic patients without clinical retinopathy (DR).

**Methods:** This prospective observational cohort study recruited type 2 diabetic patients in community registry in Guangzhou. All participants underwent systematically ocular examinations annually. The SS-OCT was used to obtain the choroid thickness (CT) and retinal thickness (RT) in macula. The rates of CT and RT between patients developed incident DR (IDR) and those without IDR were compared during 2-year follow-up.

**Results:** A total of 1460 patients (eyes) were included, with 305 (20.9%) developed IDR. Overall, CT was reduced with an average value of  $-2.65 \pm 0.95 \mu\text{m}$  to  $-14.19 \pm 0.86 \mu\text{m}$  (All  $p < 0.005$ ). Reduction of CT in patients developed IDR was significantly faster than those without IDR, with the absolute reduction of average CT by  $-12.52 \pm 1.00 \mu\text{m}$  for patients without IDR and  $-18.50 \pm 1.61 \mu\text{m}$  for those without IDR ( $p = 0.002$ ), respectively. Multivariate mixed models confirmed that the rates of average CT in patients who developed IDR was significantly faster than that in patients without IDR by  $-6.923 \mu\text{m}$  (95%CI:  $-10.248, -3.599$ ;  $p < 0.001$ ). Absolute reduction of average RT was  $-5.28 \pm 0.34 \mu\text{m}$  ( $p < 0.001$ ) in all patients but did not have a significant difference between two groups.

**Conclusion:** The rate of CT thinning was significantly different between the eyes developed IDR and eyes without IDR during the 2-year follow-up, indicating that a reduction in CT might play a role in the occurrence of DR.

## PP-500

**Evaluation of changes in retinal and choroidal vessels after hemodialysis in patients with end-stage renal disease using OCTA.**T Chang, M Zhang<sup>1</sup>.<sup>1</sup>Department of Ophthalmology, West China Hospital, Chengdu, Sichuan, People's Republic of China

**Objective:** To investigate the changes of retina and choroidal vessels in patients with end stage renal disease (ESRD) before and after a single hemodialysis as well as one year after hemodialysis.

**Methods:** Patients with ESRD treated with maintenance hemodialysis in the Dialysis Unit of West China Hospital were included in this study. Complete eye examination was completed with OCT and OCTA scans of macular region 30 minutes before and after HD as well as 1 year later. Systemic parameters such as weight, SBP and DBP were measured. Main retinochoroidal parameters were retinal thickness, choroid thickness and vessel densities in SCP, DCP, choriocapillaris layer and choroid macrovascular layer. Comparison of retinochoroidal parameters before and after a single hemodialysis as well as before and after one year's hemodialysis were performed. Pearson's correlation test was used to evaluate the correlations between changes in retinochoroidal parameters and changes in system parameters.

**Results:** Forty eyes of 25 ESRD patients were involved. The mean age was  $61.28 \pm 13.98$  in all participants. The mean eGFR was  $5.00 \pm 1.62$  ml/min/1.73m<sup>2</sup> in all participants. In the comparison of retinochoroidal parameters before and after a single hemodialysis, retinal thickness decreased from  $188.95 \pm 43.01 \mu\text{m}$  to  $187.25 \pm 43.29 \mu\text{m}$  ( $p=0.02$ ), choroid thickness decreased from  $205.85 \pm 28.09 \mu\text{m}$  to  $185.15 \pm 47.29 \mu\text{m}$  ( $p<0.001$ ), choroid macrovascular layer vessel density decreased from  $77.52 \pm 11.14\%$  to  $73.35 \pm 9.36\%$  ( $p<0.001$ ) in all patients. There were no significantly differences in vessel densities in SCP ( $21.31 \pm 9.18\%$  to  $21.64 \pm 9.37\%$ ,  $p=0.55$ ), DCP ( $22.67 \pm 8.67\%$  to  $23.16 \pm 9.84\%$ ,  $p=0.52$ ) and choriocapillaris layer ( $29.56 \pm 8.74\%$  to  $29.26 \pm 7.51\%$ ,  $p=0.72$ ). The reduction in choroid macrovascular layer vessel density correlated with the decrease in SBP ( $p=0.03$ ). In the comparison of retinochoroidal parameters before and after one year's hemodialysis, choroid macrovascular layer vessel density decreased from  $77.52 \pm 11.14\%$  to  $74.64 \pm 10.84\%$  ( $p<0.001$ ).

**Conclusion:** The choroid macrovascular layer vessel density decreased significantly after a single hemodialysis in ESRD patients and the reduction correlated with the decrease in SBP. After one year's hemodialysis, the choroidal macrovascular layer vessel density was significantly reduced. This change may be related to repeated stimulation of hemodialysis and vascular damage in chronic kidney disease.

**PP-502****Evolution and outcomes of hyperreflective crystalline deposit (HCD) on optical coherence tomography in diabetic maculopathy.**

H Nahata, R Venkatesh, R Mangla, N Yadav.

**Objective:** To report evolution and outcomes of hyperreflective crystalline deposit (HCD) on optical coherence tomography (OCT) in diabetic maculopathy (DM).

**Methods:** Patients with DM showing HCD on OCT for the first time between June 2017 and May 2021 were included in the study. Demographic, ophthalmic and OCT features were documented and analysed. Factors leading to the development of HCD and its effect on the functional outcome were analysed and described in this study.

**Results:** Sixty cases of HCD were identified in 45 (33 males) patients for the first-time during the defined study period. Mean age of the eligible patients was  $61.53 \pm 8.19$  years. Average duration of diabetes was  $13.82 \pm 7.38$  years. Mean visual acuity of these patients was  $0.902 \pm 0.438$  logMAR units (Snellen equivalent = 20/160). Patients with HCD showed subretinal hard exudates, were on anti-cholesterol medications (36, 80%) and showed reduced visual acuity (20/160) if the HCD involved the fovea. The median time taken for the development of HCD was 28 months. Mean follow-up duration of the study was  $26.19 \pm 27.98$  months. Persistence of HCD in all cases (n=42, 100%) was noted at the last follow-up visit.

**Conclusion:** Horizontal, single or multi-layered HCDs on OCT in DM represent intraretinal or subretinal cholesterol crystal precipitates evolving from the hard exudates identical to the “onion ring sign” seen in neovascular AMD. HCDs or CCs depict deranged lipid metabolism, chronic vascular leakage and can lead to substantial visual impairment if the fovea gets involved.

PP-504

**Morning Glory Syndrome Associated with Persistent Fetal Vasculature: Observations by Fundus Fluorescein Angiography**Y Cai.

**Objective:** To report the retinal vascular findings on fundus fluorescein angiography (FFA) in patients with morning glory syndrome (MGS) complicated by persistent fetal vasculature (PFV).

**Methods:** A retrospective observational study was carried out on the patients diagnosed with MGS associated with PFV in the Second Xiangya Hospital between February 2020 and December 2021. All patients underwent the FFA examination under general anesthesia. The demographic data, clinical manifestations, examination findings, and diagnosis were recorded.

**Results:** Inclusion criteria were met by 9 patients (4 male and 5 female). The mean age at presentation was  $20.8 \pm 17.9$  months (range 6 to 48). Anterior PFV was present in 7 (78%) eyes. The most frequent visible finding in affected eyes were optic disc abnormalities (8 eyes, 100%), poor foveal morphology (7 eyes, 87.5%), peripheral vessel avascularity (7 eyes, 87.5%), and aberrant circumferential vessels (7 eyes, 87.5%). The terminal supernumerary branching (5 eyes, 62.5%), peripheral vessel avascularity (3 eyes, 37.5%) and leaking spots (2 eyes, 25%) were more to be found in fellow eyes.

**Conclusion:** Our study revealed that most of MGS associated with anterior PFV, which may be related to the funnel-shaped excavation of optic disc. Retinal vascular abnormalities were present in the majority of affected and fellow eyes in patients with MGS complicated with PFV, suggesting that fundus fluorescein angiography is a powerful means to guide optimal clinical treatment, and preventing the occurrence of serious complications effectively.

PP-507

**Evaluation of Orbital Soft Tissue compliance in Patients with Thyroid Eye Disease Using Corvis**

M Kiarudi, A Moein-Rad, S Zarei-Ghanavati, A Sabermoghadam.

**Objective:** In thyroid eye disease (TED), all ocular components and adnexa such as extraocular muscles, orbital adipose tissues, eyelids, and tear glands could be affected. This study aimed to study the orbital biomechanical parameters in patients with TED, in terms of differences with healthy individuals and correlation with clinical findings, using the dynamic Scheimpflug analyzer, Corvis ST (CST, Oculus Wetzlar, Germany).

**Methods:** In this non-randomized controlled study, the authors recruited 26 consecutive patients with thyroid eye disease. Demographic data were collected, and patients with TED were assessed for exophthalmos, intraocular pressure, and clinical activity score. Biomechanical response parameters of one randomly-chosen eye of each patient, including whole eye movement length (WEMI) and time (WEMt), were evaluated and compared in patients and age- and gender-matched healthy subjects using the CST.

**Results:** The mean age of patients was  $39.88 \pm 11.61$  years old. Nine out of 26 patients with TED and nine of 26 healthy individuals were male. The median duration of thyroid disease was 36 (*IQR* 54) months and the median duration of thyroid ophthalmopathy was 27 (*IQR* 27) months. Four out of 26 patients (7.7%) had active disease. The bIOP based on CST calculations was significantly higher in the TED group ( $p = 0.002$ ). The mean WEMI was  $206.15 \pm 61.58 \mu\text{m}$  in the TED group and  $254.23 \pm 64.01 \mu\text{m}$  in the healthy group, the difference of which was statistically significant ( $p = 0.008$ ). The median of WEMt was 20.90 (1.15) msec in the TED group and 21.45 (0.93) msec in the healthy group ( $p < 0.001$ ). However, WEMt was not significantly different between groups after controlling for the potential confounding factors ( $p = .114$ ). The mean of WEMI was statistically lower in patients with active disease ( $p < 0.001$ ). Also, the patients with active disease had shorter WEMt compared to patients with quiescent disease ( $p = 0.006$ ).

**Conclusion:** The CST-derived WEMI was significantly lower in patients with thyroid eye disease compared to normal subjects. WEMI was significantly smaller, and also WEMt was significantly shorter in the patients with active TED compared to the patients with quiescent TED. Therefore, WEMI and WEMt might be useful in evaluating the compliance of the orbit in patients with TED.

PP-508

**Tomography Macular Parameters As A Non-Invasive Biomarker Of The Diabetic Polyneuropathy Severity**M Karliyuchuk.**Objective:**

to determine the peculiarities of tomography morphometric parameters of the macula depending on the severity of diabetic polyneuropathy.

**Methods:** 575 patients (1150 eyes) with type 2 diabetes mellitus (DM) and 50 healthy individuals (100 eyes) were examined. In 63.5% of diabetic patients (365 patients), the diagnosis of diabetic polyneuropathy (DPN) was excluded (stage N0). DPN was diagnosed in 36.5% of patients with DM (210 patients). Asymptomatic DPN was observed in 17.5% of patients with DM (101 patients): N1A stage - in 8.1% of patients (47 patients), N1B stage - in 9.4% of patients (54 patients); symptomatic DPN - in 15.5% of patients with DM (89 patients): N2A stage - in 8.0% of patients (46 patients), N2B stage - in 7.5% of patients (43 patients); stage of severe complications (N3 stage) - in 3.5% of patients with diabetes (20 patients). The control group consisted of 50 healthy individuals (100 eyes). In addition to standard, ophthalmic examination methods included optical coherent tomography of the retina and optic nerve.

**Results:** Patients with type 2 DM have morphometric features of macular lesions depending on the severity of DPN: the index of focal loss volume (FLV) of retinal ganglion cells in asymptomatic A DPN was 8.4 times, in asymptomatic B DPN - 8.7 times, in symptomatic A DPN - 14.1 times, with symptomatic B DPN - 14.3 times, at the stage of severe complications DPN - 15.3 times ( $p < 0,05$ ) exceeded, and the thickness of the retina in the foveolar zone of patients with asymptomatic A DPN by 9.1%, asymptomatic B DPN - by 8.9%, the stage of severe complications of DPN - by 12.7% less than the corresponding indices of healthy individuals of the appropriate age.

**Conclusion:** The obtained data indicate a direct correlation between tomography morphometric parameters of the macula and the severity of diabetic polyneuropathy. The identified morphometric features of the macula in type 2 DM can serve as a non-invasive ophthalmic biomarker of the diabetic polyneuropathy severity.



**PP-509****A pilot study: Evaluation of the effect of intrastromal injection of Bevacizumab on corneal neovascularization using OCTA.**

H M Ayoub, A Saleh Mousa<sup>1</sup>, M Hamdy<sup>1</sup>, M Ahmed Abdelrazek<sup>1</sup>, R M. Moussa<sup>2</sup>.

<sup>1</sup>Ophthalmology, Ain Shams University, <sup>2</sup>Ophthalmology, Memorial Institute for Ophthalmic Research., Cairo, Egypt

**Objective:** To evaluate the effect of intrastromal injection of bevacizumab on corneal neovascularization using Optical Coherence Tomography Angiography (OCTA)

**Methods:** A pilot study was done in a prospective manner on 10 eyes of 10 patients with corneal neovascularization with various pathologies and various depths. The patients were either scheduled for keratoplasty or have done previous keratoplasty. A single intrastromal injection of bevacizumab was injected intrastromally into the cornea using a 30 gauge needle at a concentration of 2.5%. OCTA was done for patients 48 hours before injection, 1 week and 1 month after injection. OCTA images were compared to evaluate the effect of bevacizumab on corneal neovessels. No sample size was calculated.

**Results:** At 1 week post-operative 9 cases had reduction in corneal neovascularization, 1 case stayed the same. At 1 month 8 cases have revascularized, 1 case corneal neovascularization has disappeared and 1 case stayed the same. Compared with the pre-operative period, at 1 month 8 cases had reduced vascularization, 1 case stayed the same and 1 has completely disappeared. Using the OCTA, 6 cases were estimated to be in the deep corneal tissue, 2 cases in the mid-stromal layer and 2 cases in the superficial layer. Vessels density was not calculated.

**Conclusion:** Intrastromal injection of Bevacizumab seems to be a successful option for treatment of corneal neovascularization. Using OCTA for corneal neovascularization imaging, has added an immense value especially in detecting vessels under scars and in early stages.

**PP-510****Accuracy and feasibility with AI-assisted OCT in retinal disorders community screening**

P Gao<sup>1</sup>, J Bai<sup>1</sup>, X Chen<sup>2</sup>, Q Peng<sup>1</sup>.

<sup>1</sup>Department of Ophthalmology, Shanghai Tenth People's Hospital Affiliated with Tongji University, Shanghai, <sup>2</sup>School of Electronic and Information Engineering, Soochow University, Suzhou, People's Republic of China

**Objective:** To evaluate the accuracy and feasibility of the auto-detection of 15 retinal disorders with artificial intelligence (AI) assisted optical coherence tomography (OCT) in community screening.

**Methods:** A total of 954 eyes of 477 subjects from 4 local communities were enrolled in this study from September to December 2021. They received OCT scan covering an area of 12mm x 9mm at the posterior pole retina involving the macular and optic disc, as well as other ophthalmic examinations performed with their demographic information recorded. The OCT images were analyzed using the integrated software with the algorithm previously established based on deep-learning method and trained to detect 15 kinds of retinal disorders, including pigment epidermis detachment(PED), posterior vitreous detachment(PVD), epiretinal membranes(ERM), sub-retinal fluid(SRF), choroidal neovascularization(CNV), drusen, retinoschisis, cystoid macular edema(CME), exudation, macular hole(MH), retinal detachment (RD), Ellipsoid Zone Disruption, focal choroidal excavation (FCE), choroid atrophy and retinal hemorrhage. Meanwhile, the diagnosis was also generated from three groups of individual ophthalmologists (group of retina specialists, senior and junior ophthalmologists) and compared with those by the AI. The area under the receiver operating characteristic curve (AUC), sensitivity and specificity were calculated and Kappa statistics was performed.

**Results:** Totally 878 eyes were finally enrolled, with 76 excluded due to poor image quality. In the detection of 15 retinal disorders, the ROC curves between AI and professors presented relatively large AUC (0.891~0.997), high sensitivity (87.65~100%), and specificity (80.12~99.41%). Among the ROC curves comparisons with the retina specialists, AI was the closest one to the professors compared to senior and junior ophthalmologists (P<0.05).

**Conclusion:** AI-assisted OCT is highly accurate, sensitive and specific in auto-detection of 15 kinds of retinal disorders, certifying its feasibility and effectiveness in community ophthalmic screening.

## PP-512

**Application of Self-supervised Learning Algorithms on Retinal Images of Patients with Diabetes Mellitus to Predict Renal Outcome**

W Yip<sup>1</sup>, W Chan<sup>2</sup>, J Li<sup>3</sup>, C Lee<sup>4</sup>, K Shih<sup>1</sup>, E Lam<sup>3</sup>, Y Yap<sup>4</sup>.

<sup>1</sup>Department of Ophthalmology, <sup>2</sup>The University of Hong Kong, Hong Kong Island, Hong Kong, China, <sup>3</sup>Department of Electrical and Electronic Engineering, <sup>4</sup>Department of Medicine, The University of Hong Kong, Hong Kong Island, Hong Kong, China

**Objective:** To develop self-supervised deep learning algorithms for the prediction of diabetic kidney disease in Chinese middle age to elderly adults using fundoscopic photos.

**Methods:** 13028 fundoscopic photos of 3264 Hong Kong patients were obtained. Photos were labeled as case if incident estimated glomerular filtration rate (eGFR) < 60 ml/min/1.73m<sup>2</sup> and the rest was labeled as control. There were 2 approaches, immediate prediction and 1 year prediction. The preliminary model developed with PyTorch used transfer learning of pretrained VGG-16, a convolutional neural network. The weights and biases were further fine-tuned with the fundoscopic photos.

The next steps are to increase sample size, incorporate patient demographics and kidney disease biomarkers into the model and use the self-supervised learning method to make long term prediction. Self-supervised learning is training the model with pretext tasks using unlabelled images before training with labelled images. The pretext tasks, for instance, include learning representations of input images by employing Multi Instance Contrastive learning (MICLe) where retinal images from different angles and eyes of the same patients form positive pairs that attract while images from different patients form negative pairs that repel.

**Results:** Area under receiver operating characteristic curve (AUC) of immediate approach was 0.81 and AUC of 1 year prediction was 0.80. The sensitivity, specificity, precision or positive predictive value, negative predictive value and accuracy of immediate approach were 0.58, 0.85, 0.64, 0.82 and 0.77 respectively. That of 1 year prediction were 0.71, 0.76, 0.64, 0.81 and 0.74 correspondingly. For immediate approach, the F1 score was 0.61 and Matthews correlation coefficient (MCC) was +0.4431. For 1 year prediction, the F1 score was 0.64 and MCC was +0.4557.

**Conclusion:** Using fundoscopic photos to predict diabetic nephropathy demonstrated excellent classification ability, but the sensitivity was only moderate and specificity was not excellent in the current model. Therefore, some further steps will be actualised to improve its performance.

PP-513

**Retinal Microvascular Reactivity in Chronic Cigarette Smokers and Nonsmokers: An Observational Cross-Sectional Study**H Xu<sup>1</sup>, J Chunhui<sup>1</sup>.

<sup>1</sup>Department of Ophthalmology and Visual Science, Eye, Ear, Nose and Throat Hospital, Shanghai Medical College of Fudan University, Shanghai, China, Shanghai, People's Republic of China

**Objective:** To evaluate the changes in the retinal microvasculature and its reactivity in chronic cigarette smokers.

**Methods:** Thirty-four male chronic cigarette smokers and 18 male nonsmokers were enrolled. Optical coherence tomography angiography was used to measure the perfused retinal vessel densities (PVDs) of the parafoveal and peripapillary areas at baseline and during phase IV of the Valsalva maneuver (VM-IV). Systemic blood pressure and intraocular pressure were also measured.

**Results:** The baseline PVD in the peripapillary area was significantly lower in the smokers than in the nonsmokers ( $59.56\% \pm 2.26\%$  vs  $61.67\% \pm 3.58\%$ , respectively;  $P = 0.005$ ). However, there were no significant differences in the foveal avascular zone or parafoveal PVD between the two groups. During VM-IV, the parafoveal PVD of the smokers decreased by  $5.49\% \pm 9.70\%$ , which was significantly less than the percentage change in the nonsmokers ( $-13.01\% \pm 8.39\%$ ,  $P < 0.05$ ). Similarly, the peripapillary PVD of the smokers decreased by  $1.13\% \pm 3.50\%$ , which was significantly less than that in the nonsmokers ( $-3.83\% \pm 4.26\%$ ,  $P < 0.05$ ). There were no significant differences in the percentage changes in systemic blood pressure parameters between the two groups.

**Conclusion:** The retinal microvasculature and its reactivity were impaired in chronic smokers compared with nonsmokers. The extent of impairment differed among different regions of the fundus.

PP-514

**Impact of Hemodialysis on Choroidal Thickness: A Systematic Review and Pooled Analysis of Cohorts**Z Su<sup>1</sup>, Z *wu*<sup>2</sup>, X *wang*<sup>1</sup>, F *Jiang*<sup>1</sup>.

<sup>1</sup>Department of Ophthalmology, Tongji Medical College, Union Hospital, Huazhong University of Science and Technology, <sup>2</sup>Department of Endocrinology, Union Hospital, Tongji Medical College, Huazhong University of Science and Technology, Wuhan, People's Republic of China

**Objective:** Hemodialysis optimizes the composition and volume of body fluid, reduces body weight and blood pressure, and increases colloid and interstitial osmotic pressure, which may affect choroidal thickness. However, whether hemodialysis affects choroidal thickness in patients with end-stage kidney disease (ESKD) remains controversial in previous studies. Hence, we conducted a meta-analysis to examine the effect of hemodialysis on choroidal thickness.

**Methods:** We conducted a comprehensive search from PubMed and Web of Science databases as of March 2022 for relevant studies and bibliographies. Weighted mean difference (WMD) and 95% confidence interval (CI) were used to summarize the subfoveal choroidal thickness. Heterogeneity and publication bias was assessed, and meta-analysis was performed using a random-effects model. Subgroup analyses regarding diabetes mellitus (DM) were also performed.

**Results:** A total of 15 studies with 1,010 eyes were eligible for this meta-analysis, including 552 diabetic eyes, 230 non-diabetic eyes, and the remaining 228 eyes were uncategorized. Subfoveal choroidal thickness was significantly reduced after hemodialysis [WMD =  $-13.66 \mu\text{m}$ ; 95% CI:  $-24.29$  to  $-3.03 \mu\text{m}$ ;  $P < 0.001$ ]. Similar results were obtained in sub-analysis with and without DM (DM: WMD =  $-24.10 \mu\text{m}$ , 95% CI:  $-27.39$  to  $-20.80 \mu\text{m}$ ,  $P < 0.001$ ; non-DM: WMD =  $-15.37 \mu\text{m}$ , 95% CI:  $-19.07$  to  $-11.66 \mu\text{m}$ ,  $P < 0.001$ ).

**Conclusion:** For ESKD patients, the choroidal thickness decreased significantly after hemodialysis, especially in ESKD patients with diabetes mellitus.

PP-515

**Characterization of the Retinal Microvasculature and FAZ Changes in Ischemic Stroke and Its Different Types**H Duan<sup>1</sup>, H Qi<sup>1</sup>.

<sup>1</sup>Ophthalmology, Peking University Third Hospital, Beijing Key Laboratory of Restoration of Damaged Ocular Nerve, Beijing, People's Republic of China

**Objective:** This study aimed to assess morphological changes in the retinal microvasculature and foveal avascular zone (FAZ) in patients with ischemic stroke and its different subtypes.

**Methods:** Thirty-three patients with ischemic stroke (14 with nonlacunar infarction and 19 with lacunar infarction) and twenty-seven control participants were enrolled in this study. Based on optical coherence tomography angiography (OCTA), three vascular parameters, including vascular area density (VAD), vascular fractal dimension (VFD), and vascular orientation distribution (VOD), and four FAZ-related parameters, including FAZ area (FA), FAZ axis ratio (FAR), FAZ circularity (FC), and FAZ roundness (FR), in the superficial capillary plexus (SCP) and deep capillary plexus (DCP) were extracted and analyzed.

**Results:** Logistic regression results showed that older age (OR=1.99), worse best-corrected visual acuity (BCVA) (OR=0.45), higher FAR (OR=4.93), and lower FR (OR=0.81) of the DCP were associated with an increased risk of ischemic stroke. The areas under the receiver operating characteristic (ROC) curves of FAR and FR in the DCP were 0.740 and 0.760, respectively, indicating good diagnostic accuracy. Furthermore, the VOD of the SCP and FC of the DCP were significantly increased in nonlacunar infarction compared with lacunar infarction.

**Conclusion:** Our study shows that the FAR and FR of the DCP may be potential biomarkers of ischemic stroke. Moreover, we demonstrated that OCTA showed specific damage patterns in retinal microvascular and macular morphology in different subtypes of ischemic stroke.

PP-518

**Bilateral diffuse uveal melanocytic proliferation associated with endometrial carcinoma – Multimodal imaging analysis**C Zhipeng<sup>1</sup>, Z hong<sup>1</sup>.<sup>1</sup>Eye Hospital, China Academy of Chinese Medical Sciences, Beijing, People's Republic of China

**Objective:** To report a case of bilateral diffuse uveal melanocytic proliferation (BDUMP) and the contribution of multimodal imaging to early diagnosis.

**Methods:** A 79-year-old woman with endometrial carcinoma presented with early BDUMP that we opted to observe by multimodal imaging.

**Results:** After 6 weeks, a giraffe-like pattern of signs had developed, with multiple greyish lesions that corresponded to window defects on fluorescein angiography. Loss of the retinal pigment epithelium and ellipsoid zone was evident on spectral-domain optical coherence tomography (OCT) with patchy dark areas on near-infrared reflectance and autofluorescence and on en face OCT. Orange polygonal lesions corresponding to thickening of the retinal pigment epithelium were seen on spectral-domain OCT, and increased intensity was detected on near-infrared reflectance and autofluorescence imaging and on en face OCT. OCT angiography revealed irregular hyporeflective areas in the choriocapillary slab. The patient was eventually referred to the medical oncologists for further investigation and systemic evaluation for recurrence of the primary tumour.

**Conclusion:** Multimodal imaging facilitates detection of early BDUMP and provides information concerning its pathogenesis.

PP-519

**AB variant GM2 gangliosidosis multimodal ophthalmic clinical features**Q Chen.

**Objective:** To provide ophthalmic clinical features of AB variant GM2 gangliosidosis for helping early diagnosis.

**Methods:** Case report. We collected the medical records of a patient, and performed color fundus photography, optical coherence tomography (OCT), fluorescein angiography and the whole exome genome-sequencing test.

**Results:** A seven-month-old Chinese girl presented to the hospital with nystagmus for 2 months. Her growth and development were normal, except she was unable to sit. The parents were not known to be consanguineous. Retinal examination showed a cherry-red spot with a ring of whitish infiltrate surrounding both macula. Fluorescein angiography showed normal retinal circulation and vessels. OCT revealed thickening and increased reflectivity of the inner retinal layers with a shadowing effect on outer structures. The marked thickening and hyperreflective part was within 1-2 PD area around the fovea. It was difficult to distinguish the inner retinal structure. A homozygous deletion (chr5: 150639196-150639548) of exon 2 in the GM2A gene was detected. The patient was diagnosed with AB variant GM2 gangliosidosis without obvious neurological symptoms.

**Conclusion:** AB variant GM2 gangliosidosis is an extremely rare type of lysosomal storage disease. Before typical neurological symptoms appear, the clinical features of fundus photography and OCT help us diagnose GM2 gangliosidosis.



PP-520

**Optical Coherence Tomography of Retinal Artery Occlusion Associated With Mucormycosis and COVID-19**R Kaur, B Khan, A sharma.

**Objective:** To report the Optical Coherence Tomography finding in central retinal vein occlusion associated with rhino-orbital-cerebral mucormycosis and COVID-19

**Methods:** A 41-year-old woman presented with mucormycosis-induced orbital apex syndrome following SARS-CoV-2 infection. Magnetic resonance imaging showed pansinusitis with thickening and enhancement of the extraocular muscles. A histopathological examination disclosed broad-based, filamentous, aseptate hyphae, suggestive of mucormycosis.

**Results:** A fundus examination showed signs of central retinal artery occlusion, including loss of transparency, presumably from ischemia to the ganglion cell layer and boxcarring of the retinal arterioles. Macular folds on fundus photography with separation of the neurosensory retina from the retinal pigment epithelium on optical coherence tomography were noted (Figure). Prompt treatment with systemic amphotericin B (10 mg/kg/d) and debridement of the sinuses was performed, although the eye was exenterated.

**Conclusion:** We hypothesize that choroidal congestion because of orbital apex syndrome led to separation of the neurosensory retina from the retinal pigment epithelium. Cases of COVID-19 associated with mucormycosis in the setting of corticosteroid use and diabetes as potential predisposing factors have been reported in India

PP-521

**Progressive Ophthalmoplegia In A Case Of Breast Cancer**P Ganne<sup>1</sup>, D Syamala, H Singh<sup>2</sup>.<sup>1</sup>ophthalmology, <sup>2</sup>surgical oncology, AIIMS, Mangalagiri, Guntur, India

**Objective:** Metastasis from breast cancer to the head and neck region is a rare occurrence. Usually, breast cancer metastasizes to the fat and muscles in the orbit, and involvement of the bony orbital wall is rare. We report a case of a 52-year-old lady who presented with metastasis to the left greater wing of the sphenoid and adjacent squamous temporal bone. Ophthalmoplegia and proptosis were the initial manifestations in this patient, which lead to the diagnosis of underlying breast cancer.

**Methods:** A 52-year-old lady presented with left orbital pain and drooping of the left upper eyelid for one month. She had hypothyroidism. Ophthalmic examination revealed a best-corrected visual acuity (BCVA) of 20/30 with early cataracts in both eyes. Extra-ocular movements of the left eye were restricted and there was mild proptosis. There was mild ptosis of the left upper eyelid. Pupillary reflexes and color vision were normal in both eyes. Corneal sensations were intact and fundus examination was normal bilaterally. Two weeks following the initial presentation, the drooping and restriction in ocular movements progressed to complete ptosis and external ophthalmoplegia in the left eye. A detailed systemic examination revealed a hard lump (7x5cm sized) in the left breast with retraction of nipple, peau d'orange appearance of the overlying skin, and a matted left axillary lymph node (clinical stage: T4bN2)

**Results:** A core needle biopsy of the breast lump revealed an infiltrating ductal carcinoma [estrogen receptor (ER) positive, progesterone receptor (PR) and human epidermal growth factor receptor 2 (HER2) negative]. CE-MRI of brain and orbits showed a lytic lesion in left greater wing of sphenoid and adjacent squamous temporal bone with enhancing soft tissue at orbital apex causing mass effect on orbital apical structures. PET-CT scan showed multiple osteolytic lesions involving both the appendicular and axillary skeleton. She was started on palliative radiotherapy to left orbit and chemotherapy (cyclophosphamide + adriamycin).

**Conclusion:** Presence of progressive, painful ophthalmoplegia with proptosis, and presence of lytic lesions on MRI pointed towards a possible underlying malignancy. A good systemic examination should be undertaken in such cases to look for the primary tumor. Ophthalmologists can play a crucial role in the diagnosis and prompt referral of patients with metastatic orbital cancer. This case also emphasizes the need to stress on routine breast cancer screening in all women aged >40 years.

PP-523

**Orbital retinoblastoma: Surpassing the challenge**S Chahar, S Honavar<sup>1</sup>.<sup>1</sup>Centre For Sight, Hyderabad, India**Objective:** To describe the outcome of intensive multimodal treatment protocol for orbital retinoblastoma.**Methods:** Case presentation describing the clinical features, management, and outcome in a case of primary orbital retinoblastoma treated by intensive multimodal treatment protocol.**Results:** The use of three cycles of neoadjuvant chemotherapy, enucleation, orbital external beam radiotherapy, and completion of 9 cycles of adjuvant chemotherapy in a 2-year old child with clinikoradiological diagnosis of orbital retinoblastoma showed complete resolution of orbital tumor. The child was free of local or systemic recurrence on three year follow-up.**Conclusion:** Retinoblastoma presenting as an advanced disease with extraocular extension is a common scenario encountered in developing countries like India and also the major cause of death in these patients. Intensive multimodal treatment protocol has brought about a paradigm shift in management of these patients dramatically improving the life salvage.

The combination therapy ensures shrinkage of the large tumor (chemoreduction), complete surgical clearance, treatment of the microscopic surgical residual disease in the orbit and preventing systemic micrometastasis thus improving outcomes in these advanced cases ensuring life salvage.

PP-524

**Unilateral Presentation Of Choroidal Metastasis: A Diagnostic Enigma**M Singh<sup>1</sup>, V Som<sup>2</sup>, S Kubrey<sup>2</sup>, A Dubey<sup>3</sup>, K Kumar<sup>4</sup>.

<sup>1</sup>Senior Resident, Department of Ophthalmology, <sup>2</sup>Associate Professor, Department Of Ophthalmology, <sup>3</sup>Assistant Professor, Department of Ophthalmology, <sup>4</sup>Professor and Head, Department of ophthalmology, Gandhi medical college, Bhopal, India

**Objective:** Choroid is the most common ocular site for the metastatic disease, because of its abundant vascular supply. Most common Primary tumour leading to choroidal metastasis is breast carcinoma (40-47%) followed by lung carcinoma (21-29%) worldwide. Metastasis is usually bilateral and multifocal, unilateral metastatic lesions are harder to diagnose since simulating lesions are usually unilateral and unifocal.

**Methods:** A 52 year old male patient with diminution of vision in right eye was clinically examined using fundus photography, B-scan, FFA(Fundus Fluorescein Angiography), and OCT(Optical Coherence Tomography). Intravitreal anti-VEGF injection was injected once in right eye and OCT was repeated in 3 weeks. Later on CECT (Contrast Enhanced Computed Tomography) Chest, Bronchoscopy and BAL (Bronchoalveolar lavage), FDG- PET (Fluorodeoxyglucose Positron Emission Tomography) Scan was done to investigate for primary malignancy. CE-MRI (Contrast enhanced Magnetic Resonance Imaging) brain and orbit was done to rule out any brain metastasis and EBRT (External Beam Radiation Therapy) was started.

**Results:** On fundoscopy of right eye a large sub-retinal, orange lesion with intermittent pale area in macular region was seen. FFA showed early phase hyperfluorescence with late phase pooling in detached area and surrounding tissue staining. OCT showed dense undulating lesion with deep shadowing and serous exudative detachment. B-Scan showed hyperechogenic choroidal mass with acoustic shadowing. On basis of these characteristic findings tumour was initially diagnosed as choroidal osteoma. CECT chest revealed few soft tissue nodules in lateral segment of right middle lobe and anterior basal segment of right lower lobe with multiple mediastinal lymph node with microcalcification. Bronchoscopy and BAL showed no endobronchial growth. Cytology demonstrated moderate cellularity with predominant macrophages and with no evidence of malignant or dysplastic cells. FDG-PET scan revealed FDG avid uptake soft tissue thickening in right posterolateral aspect of right eye and mass lesion in right lung upper lobe perihilar region.

**Conclusion:** Unilateral choroidal lesion should also be investigated for choroidal metastasis to know the primary malignancy and carefully rule out simulating lesions for appropriate management. Early radiation therapy is required in symptomatic progressive lesion for better visual prognosis.

PP-525

**Multiple orbital and choroidal metastasis from metastatic pituitary neuroendocrine tumor : a case report**L Luo, J Xiao.

**Objective:** Metastatic pituitary neuroendocrine tumor occurs rarely. Ocular metastasis from neuroendocrine tumors is rare with 95 cases have been reported. Metastases to the ocular from the pituitary neuroendocrine tumor (NET) has not been reported yet. We present one case of pituitary neuroendocrine tumor metastases presenting with orbital and choroidal metastasis.

**Methods:** A 51-year-old woman had blurred vision in her left eye for 3 months. The visual acuity of the right and left eyes was 1.0 and 0.12. There is a large yellow and white bulge in the subtemporal arch of the left fundus, and two small orange - red bulge in the posterior pole. FA, ICGA and OCT was performed. PETCT examination showed occupations in the right orbit and pituitary. Pituitary MRI demonstrating an enhancing mass measuring 23x17x13mm. Transsphenoidal transsphenoidal pituitary tumor resection was performed. Immunohistochemistry: Chromaffin particles A (CgA), synaptophysin (Syn), CD56, epithelial cell membrane (EMA), positive. Pathological diagnosis: pituitary adenoma. Six months later, the patient had no significant changes in the choroidal accuracy in the left eye, while the right eye had an aggravating proptosis. MRI demonstrated well-defined intraconal soft tissue masses in both orbits. And pituitary and encephaloma occupation were displayed. The orbital mass resection was performed on the right eye. Immunohistochemistry demonstrated CgA, Syn, CD56, EMA, RB, INSM1 positive, Pathological diagnosis was neuroendocrine tumor (NET).

**Results:** The diagnosis were: metastatic pituitary endocrine tumor, encephaloma metastasis, Bilateral orbital metastasis, and choroid metastasis in the left eye. The patient was recommended to the department of oncology, and the choroid lesions should followed regularly.

**Conclusion:** The orbital and fundus imaging findings were very important for diagnosis. Tumor diagnosis is mainly based on immunohistochemistry.

PP-526

**Recurrent Upper Eyelid Chalazion in 75-year-old female - going beyond Sebaceous Gland Carcinoma!**S Shah<sup>1</sup>, N Shah, K Shah.<sup>1</sup>*Ophthalmology, GURU NANAK EYE CENTRE, NEW DELHI, India*

**Objective:** Recurrent chalazion in the elderly is a known red flag for malignancy, classically sebaceous gland carcinoma (SGC). Few masquerades are also known to have a similar presentation. Here, we present a novel case of a recurrent chalazion in right upper eyelid in an old female patient, who underwent a wide excision biopsy with lid reconstruction. The histopathology proved a nodular basal cell carcinoma (BCC).

**Methods:** A 75-year-old female, presented with recurrent swelling of the lateral aspect of right upper lid for eight months. She had undergone repeated incision and curettage at a local hospital before being referred to us. On examination, a solitary 10 x 6 mm firm nodular lesion was noted on lateral one-third of the right upper eyelid. A yellowish lesion with dilated vessels, loss of eyelashes, areas of ulceration and blood clots suggested a possible diagnosis of SGC. No palpable lymph nodes were noted. Systemic metastatic workup was negative. A wide excision was performed with clear margins noted on the frozen section. Lid and lateral canthus reconstruction were done using a periosteal flap and Tenzel skin flap.

**Results:** Histopathology confirmed atypical cells with palisading - the definitive features suggestive of nodular BCC. The margins were clear for 3 mm. The patient is being followed up for six months, with no recurrence and a satisfactory cosmetic outcome.

**Conclusion:** An atypical presentation of nodular BCC in the upper eyelid, mimicking chalazion or SGC may be missed on preliminary clinical examination. Detailed histopathology of every lid mass is essential for ruling out the masquerade malignancies.

PP-527

**Microcystic adnexal carcinoma of eyelid treated by Mohs micrographic surgery**

Y Zhu.

**Objective:** To report a malignant tumor of Microcystic adnexal carcinoma with benign appearance on left upper eyelid.

**Methods:** A 46-year-old women presented with a fleshy, firm nodule measuring 20x7 mm on the left upper eyelid. She had a history of twice relapses on the same region in the past ten-year. The tumor was completely removed with margin control by Mohs micrographic surgery.

**Results:** Pathological examination showed that the tumor was Microcystic adnexal carcinoma, a rare cutaneous adnexal malignancy. The patient was followed up for 12 years without recurrence.

**Conclusion:** Because MAC often masked as a benign tumor, the clinical suspicion of whether a lesion is benign or malignant is very important for accurate treatment of eyelid tumor.

PP-528

**Bioinformatics analyses of miR-424/503 in the pathogenesis of basal cell carcinoma**X Hou, L Heindl<sup>1</sup>, M Zhang<sup>2</sup>.<sup>1</sup>Ophthalmology, University of Cologne, Cologne, Germany, <sup>2</sup>Ophthalmology, Sichuan University, Sichuan, Chengdu, People's Republic of China

**Objective:** MicroRNAs (miRNAs) exert vital functions in the occurrence and development of various tumours. The aim of this study to reveal the molecules mechanism of miRNA in the pathogenesis of basal cell carcinoma (BCC) by bioinformatics analyses.

**Methods:** The microarray data of BCC were downloaded from the Gene Expression Omnibus (GEO) database to screen differentially expressed miRNA. Based on the differentially expressed miRNAs, we predicted the target gene and transcription factors (TFs) by using targetscan, miRanda and mirSVR. Then we performed functional enrichment analysis to analyze the functions of target genes. In addition, we used String and cytoscape to analyze the interaction of its targeted regulatory proteins, and screened its core regulatory genes

**Results:** The miRNA expression profiles in BCC tumor tissues were significantly different from those in adjacent tissues, among which miRNA gene clusters (miR-424, miR-542-5p, miR-503) were highly expressed in BCC tumor tissues. A total of 1349 miR-424 targeted regulatory genes and 380 miR-503 targeted regulatory genes were obtained from the analysis, and 312 overlapping genes were further analyzed. The function of miR-424 was mainly enriched in the MAPK, mTOR and Hippo pathway, and CDC42, CCND1, VEGFA, and PIK3R1 were the core factors of targeted regulatory genes of miR-424. The function of miR-503 was mainly enriched in the MAPK, PI3K-Akt, Hippo and Rap1 pathways, and CCND1、 VEGFA、 PIK3R1 were the core factors of targeted regulatory genes of miR-503.

**Conclusion:** The expression of miR-424, miR-542-5p, miR-503 cluster were significantly different in BCC. Target gene of CCND1, VEGFA, PIK3R1 may play important roles in the development of BCC, serving as a potential therapeutic target.



**PP-530****Inhibition of CD146 lessens uveal melanoma progression through reducing tumor angiogenesis**

R Zhang, Q Hou, H Duan, J Qu.

**Objective:** As uveal melanoma develops in one of the most capillary-rich tissues, its metastasis occurs exclusively through the hematogenous route. However, most antiangiogenic drugs render no response and failed in clinical trials.

CD146 is not only a marker molecule of melanoma, but also acts as a coreceptor of VEGFR-2 in tumors to regulate tumor angiogenesis. In this study, the function of CD146 in UM tumor angiogenesis was detected in vitro and in vivo. And its molecular mechanism was preliminarily discussed. We also detected the effect of CD146 specific antibody AA98 on the development of UM angiogenesis and related molecular mechanisms.

**Methods:** (1) The expression level of CD146 in uveal melanocytes U94 and UM cell lines M17 and SP6.5 was detected by cell immunofluorescence, and the expression level of CD146 in UM nude mouse xenograft tumor model was detected by immunohistochemistry.

(2) The UM culture supernatant was collected as conditioned medium. CD146-specific siRNA was transfected to reduce the expression of CD146 in human retinal microvascular endothelial cells (HRMEC). Matrigel tube formation assay and Transwell cell migration assay were used to detect the angiogenesis ability of HRMECs induced by UM conditioned medium. Possible signaling pathways were detected by Western Blot.

(3) The subretinal spaces of nude mice were inoculated with UM cell lines to build an animal model. After xenografts, AA98 or IgG was injected subretinally. The eyeballs were taken for HE staining to detect the effect of local application of AA98 on the size of UM tumor. Immunohistochemistry was used to detect the effect of AA98 on the angiogenesis of tumor using CD31-PAS double staining.

**Results:** (1) CD146 is highly expressed on the membrane of UM tumor cells compared with U94, in nude mouse models the expression level of CD146 in UM cells and retinal blood vessels was significantly higher than that in adjacent normal tissues.

(2) Downregulation of CD146 in HRMECs can attenuate tumor-conditioned medium induced HRMEC angiogenesis through VEGF associated AKT and the P38 /NF- $\kappa$ B pathway.

(3) In M17 and SP6.5 nude mouse xenograft models, the tumor area of AA98 group was 71.2% and 78.4% lower than that of IgG group, the microvascular density (MVD) was 54.7% and 55.0% lower than that of IgG group.

**Conclusion:** CD146 plays an important role in the development of UM through modulating tumor angiogenesis and CD146 specific antibody AA98 can inhibit the formation of angiogenesis thus attenuate tumor microcirculation system formation.

PP-531

**Ultralow-dose 2/2 Stereotactic (Boom-boom) Radiotherapy and/or Local Rituximab Injection for Extra-ocular muscle lymphoma**S Chahar<sup>1</sup>, F PM<sup>2</sup>.<sup>1</sup>Centre For Sight, Hyderabad, <sup>2</sup>HORUS specialty Eye care, bangalore, India**Objective:** To present clinical characteristics and management outcomes in primary extraocular muscle lymphoma**Methods:** 4 eyes of 3 patients analyzed at a single center based on clinical characteristics, treatment protocols, histopathological diagnosis (including immunostains), management outcomes, and systemic evaluation**Results:** The study included 4 eyes of 4 patients diagnosed as extraocular muscle lymphoma median age 55 years, presenting as conjunctival mass in all cases and proptosis in 2. Extraocular muscles involved were lateral rectus (n=2), inferior rectus (n=2) medial rectus (n=1), and inferior oblique (n=1). Incision biopsy was confirmed as extra-nodal, marginal zone, B-cell NHL. No systemic involvement was present. Treatment included ultra low beam radiotherapy in 2, external beam radiotherapy standard dose in 1 and surgery in 1 and local intraorbital injection of rituximab in 3 cases showing excellent resolution**Conclusion:** Extranodal marginal zone lymphoma is the most common type with best prognosis. Bilaterality, multifocality and involvement of obliques are rare scenarios. Standard of care is external beam radiotherapy 20- 24 Gy but the change in trend seen in management is use of ultra-low-dose (boom boom ) radiotherapy that is 4 Gy in 2 fractions over 2 days that is a cost effective modality with minimal side effects. Overall response rate of 100% and complete response of 86%. Additional treatment option includes intraorbital rituximab injection.

PP-532

**Laser Treatment for Choroidal Melanoma**A Maheshwari<sup>1</sup>, P Finger<sup>1</sup>.<sup>1</sup>*New York Eye Cancer Centre, New York, United States*

**Objective:** Laser-treatment offers a relatively non-surgical alternative for eye, life and vision-sparing treatment of malignant melanoma of choroid melanoma. To perform a comprehensive critical review of laser photocoagulation for choroidal melanoma, offer safety and efficacy guidelines as well as to compare laser to radiation therapy techniques.

**Methods:** The various lasers included xenon-arc, krypton, argon laser, infrared transpupillary thermotherapy(TTT) and photodynamic laser therapy(PDT). Techniques, indications, interaction in tissues, visual acuity and local control outcomes were analyzed.

**Results:** Melanomas selected for laser treatment tended to be smaller and visibly accessible, typically located in the posterior choroid and limited to a mean pretreatment thickness of 2.5mm (range 0.5-4.5 mm). TTT showed local control rates of 81.3% as compared to 56.7%, 50.6% and 69% for xenon-arc, argon and krypton lasers respectively. Consistent with the literature, the incidence of metastatic disease was proportional to failure of local control. In that local control decreases over time, it was important to note the mean reported follow up in months after laser was 84 for xenon-arc, 68 for argon, 43 for krypton, 29.5 for TTT and 21 for PDT. Unlike radiation therapy, laser-treatment has been commonly associated with retinal traction, hemorrhage, neovascularization and extra-scleral extension. Local control after laser therapy (for similar sized, posteriorly located tumors) was not comparable to conservative radiation therapy techniques.

**Conclusion:** Laser treatment has been used to treat small choroidal melanomas, marginal recurrences, juxtapapillary tumors, radiation retinopathy and neovascular glaucoma. We recommend limiting laser as a primary treatment for small posterior choroidal melanoma only when radiation is not available.

PP-533

**Conjunctival melanoma with scleral or corneal invasion – Local tumor control by adjuvant plaque brachytherapy**

R Bansal<sup>1</sup>, V Reddy<sup>2</sup>, K Mulay<sup>3</sup>, S Honavar<sup>1</sup>.

<sup>1</sup>Ocular oncology and oculoplasty, Centre for Sight, <sup>2</sup>Oncology, Apollo Hospitals, <sup>3</sup>Ophthalmic pathology, Centre For Sight, Hyderabad, India

**Objective:** Considering the high malignant potential and post-surgical local tumor recurrence of conjunctival melanoma, we evaluated the role of adjuvant plaque brachytherapy in these rare cases.

**Methods:** Retrospective case series of 15 consecutive patients.

**Results:** The median age was 33 (range 8-65) years. Majority originated from primary acquired melanosis 7 (47%) or nevi 6 (40%). The mean diameter was  $9.9 \pm 3.2$  (range 4-17) mm and mean height was  $2.9 \pm 1.2$  (range 1.5-6) mm. Corneal and scleral invasion was assessed pre-operatively clinically and by ultrasound biomicroscopy, optical coherence tomography or MRI, intraoperatively, and by histopathology. Ru-106 plaque brachytherapy was performed at primary excision in 8 (54%) or following histopathology confirmation of base invasion in 7 (46%) to 2-3mm depth with 10000 cGy apex dose with a mean duration  $37.4 \pm 18.9$  (range 11.5-74) hours. At a mean final follow-up of 9.3 years, vision salvage (20/40 or better) and local tumor control was achieved in all, with no mortality.

**Conclusion:** Conjunctival melanoma has a high rate of local tumor recurrence. Apart from that, patients with corneal stromal or scleral invasion are typically treated with enucleation. Our data suggests favourable role of adjuvant Ru106 plaque brachytherapy following tumor excision in patients with corneal and/or scleral invasion in preservation of the eye and vision and minimising the risk of local tumor recurrence.

PP-534

## Correlation of Clinical & Histopathological Risk Factors & Role of Adjuvant Therapy in Secondary Enucleation for Retinoblastoma

R Bansal<sup>1</sup>, K Mulay<sup>2</sup>, V Reddy<sup>3</sup>, S Honavar<sup>1</sup>.

<sup>1</sup>Ocular oncology and oculoplasty, <sup>2</sup>Ophthalmic pathology, Centre For Sight, <sup>3</sup>Oncology, Apollo Hospitals, Hyderabad, India

**Objective:** Retinoblastoma has high mortality rates in developing countries owing to delay in diagnosis, advanced disease at presentation, lack of access to advanced medical facilities and lack of awareness. Therefore, it is important to assess a possible correlation of clinical risk factors (CRF) and histopathological risk factors (HRF) to promote early diagnosis, adoption of appropriate management protocols, predicting metastasis and facilitating life salvage. This study was performed to assess a correlation between CRF and HRF in retinoblastoma eyes undergoing secondary enucleation.

**Methods:** Retrospective interventional consecutive case series.

**Results:** : Of 406 eyes that underwent secondary enucleation, 243 (60%) had CRF at baseline and 122 (30%) had HRF. Patients had received a median of 6 cycles of neoadjuvant intravenous chemotherapy (IVC) with Vincristine + Carboplatin + Etoposide. Of those with baseline CRF, HRF was present in 91 (37%). Of the ones with HRF, baseline CRF were present in 91 (76%). CRF included iris neovascularization 40 (33%), secondary glaucoma 39 (32%), sterile orbital inflammation 32 (26%), and infiltrative anterior chamber seeds 22 (18%). HRF were infiltration of iris 19 (16%), ciliary body 26 (21%), choroid ( $\geq 3$  mm) 56 (46%); optic nerve retrolaminar 18 (15%), and resection 8 (7%); scleral lamellar 42 (34%) and extra-scleral 13 (11%). Adjuvant treatment was 6 cycles of IVC in all and radiotherapy in 10 (8%). Presence of CRF correlated with HRF,  $p < 0.001$ . Life salvage was in 401 (99%) overall and 132 (100%) in those with no CRF or HRF at  $120 \pm 79$  months of follow-up. It was 162 (99%) in those with no baseline CRF vs 239 (98%) in those with CRF; 284 (100%) in those with no HRF vs 117 (96%) in those with HRF. Further, life salvage was in 152 (100%) in those with baseline CRF but no HRF, 87 (96%) in those with baseline CRF+HRF, 30 (97%) in those with no baseline CRF but HRF.

**Conclusion:** The presence of CRF is a predictor of HRF, despite neoadjuvant IVC. Life salvage is excellent in patients with baseline CRF following neoadjuvant IVC and enucleation. Discernment of HRF following enucleation and appropriate adjuvant therapy results in excellent life salvage.

PP-536

### Congenital Hypertrophy of the Retinal Pigment Epithelium (CHRPE) as a Screening Marker for Familial Adenomatous Polyposis (FAP)

L Bonnet.

**Objective:** Familial adenomatous polyposis (FAP) has an almost 100% colorectal cancer risk warranting early detection in gene carriers. This study presents congenital hypertrophy of the retinal pigment epithelium (CHRPE) as a highly specific phenotypical marker for FAP that can be used in screening at-risk individuals. Screening recommendations including morphological subclassification were formulated with supporting literature.

**Methods:** A systematic literature review with a comprehensive search strategy was conducted using online databases. Manual searches of bibliographies and reference lists were also performed. Studies meeting inclusion criteria were graded with respect to their hierarchy of evidence and strength of recommendations according to the National Health and Medical Research Council (NHMRC) guidelines of Australia

**Results:** Almost 4500 participants were analysed across 28 included studies. The mean specificity of CHRPE as a phenotypical screening marker of FAP was 89% (standard deviation (SD); 14) with a mean sensitivity of 79% (SD; 8). The mean prevalence of CHRPE amongst FAP participants; at-risk participants were found to be 76% (SD; 24) and 37% (SD; 21) respectively. Bilateralism and multiple lesion number  $\geq 3$  are features highly specific for FAP.

**Conclusion:** CHRPE was found to be a non-invasive, rapid, early phenotypical screening marker of FAP. Clinical recognition further allows increased gene analysis efficiency. The absence of CHRPE alone cannot exclude FAP. Our screening recommendations provide guidance to clinicians on evidence based CHRPE assessment. We would advocate inclusion of ocular examinations as part of a threepronged approach, along with endoscopy and genetic testing, for efficient, timely FAP assessment in at-risk individuals.

PP-537

**Characteristics, treatments, and survival of uveal melanoma: a comparison between Chinese and American cohorts***J Luo<sup>1</sup>, C Zhang<sup>2</sup>, Y Li<sup>1</sup>, W Wei<sup>1</sup>.**<sup>1</sup>Beijing Tongren Hospital, Capital Medical University, <sup>2</sup>Beijing Tiantan Hospital, Capital Medical University, Beijing, People's Republic of China*

**Objective:** To compare the clinical features, treatment modalities, and prognosis of uveal melanoma (UM) patients in China with that of America over a 15-year period.

**Methods:** The study included 4088 American patients with primary UM from the Surveillance, Epidemiology, and End Results (SEER) database and 1508 Chinese patients from Tongren-ophthalmology Research Association of Clinical Evaluation (TRACE). Clinical features, treatment modalities, and overall survival (OS) of Chinese and American cohorts were compared. Univariable and multivariable analyses were performed to determine prognostic factors. Propensity score matching (PSM) and sensitivity analyses were applied to adjust for confounders and to identify independent prognostic factors. Main outcome measures included demographic and clinical characteristics, trend and proportion of different treatment modalities and OS.

**Results:** Mean age at diagnosis of Chinese patients in TRACE was younger than American patients in SEER (mean  $\pm$  SD, 47.3  $\pm$  12.5 years vs 59.7  $\pm$  14.8 years,  $p < 0.001$ ). Tumor size at diagnosis was larger in Chinese than American patients (diameter: 12.0  $\pm$  3.54 mm vs 11.3  $\pm$  8.27 mm; thickness: 7.13  $\pm$  3.28 mm vs 4.91  $\pm$  3.01 mm,  $p < 0.001$ ). Chinese patients were more likely to undergo brachytherapy (BT, 73.2% vs. 50.9%,  $p < 0.001$ ) and less likely to undergo enucleation (EN, 14.8% vs. 17.9%,  $p = 0.007$ ) than those from SEER. Finally, Chinese patients had better OS than American patients. However, after adjusting for age through PSM, there was no longer a significant difference in OS between the two cohorts.

**Conclusion:** Compared with American UM patients, Chinese patients had younger onset age, larger tumors at diagnosis and better prognosis. Younger age of disease onset likely accounted for the better survival in Chinese patients.



**PP-538****National Survey on Retinoblastoma among Nepalese Children in the year 2019****B Limbu.**

**Objective:** To estimate retinoblastoma occurrence, clinical presentation and referral pattern among Nepalese Children during the year 2019.

**Methods:** Multicenteric hospital based, cross sectional prospective study among 27 eye centers across Nepal in the year 2019. All Patients presenting to eye centers with diagnosis of retinoblastoma were included for the study. Data were collected using a special designed online google based performa. Training was conducted to all participating eye centers authorities in regards to obtaining and filling data on google form. All presenting features were noted as per International classification of Retinoblastoma and staging. Affordability to treatment of retinoblastoma was estimated using catastrophic approach. A written consent from parents of children and ethical approval from National Health Research Center, Nepal was obtained. All statistical data was calculated using SPSS ver 17.

**Results:** 34 children with 46 retinoblastoma eyes out of 102 were included, where other children were excluded due to foreign nationals. Average age of children 34.88(4-72, SD 19.9), mean age of unilateral presentation 42.9(11-72, SD19.2) and that of bilateral was 20.1(4-40, SD11). Hospital based estimation on prevalence of Retinoblastoma in Nepal during 2017 was 2.66 per 10000 children aged 0-6 years. Most common presenting symptom was leukocoria(74.4%), with average lag time of 173 days and most common presenting ICRB grouping of Group E(54%) with Stage 0(88%). Main reason for delayed presentation was due to lack of the knowledge about retinoblastoma and its symptoms(46%). Majority of children with retinoblastoma were offered enucleation as treatment option(52.6%) and main reason to refer child from primary eye hospital was for chemotherapy(82.6%). 100% of parents with retinoblastoma children were unable to afford for treatment of retinoblastoma.

**Conclusion:**

Retinoblastoma survival and vision restoration largely depends upon time of presentation, we found most of the children presenting to eye centers were late and major reason for delay was unaware of the disease. Similarly, access to chemotherapy was major challenge in management of retinoblastoma children due to unavailability of chemotherapy centers. We recommend extensive approach via audio visual platform to create awareness on disease which can significantly help for early diagnosis thereby saving child sight and life. Emphasis to establish local or regional chemotherapy unit is crucial and recommended.

PP-543

**Clinical pattern of Retinoblastoma in Yemeni Population**T Aldoais.**Objective:** To document clinical pattern of retinoblastoma in Yemeni population**Methods:** This retrospective study, which was conducted at Oculoplasty Unit, Yemen Magrabi Eye Hospital, Sana'a, reviewed clinical records of patients with retinoblastoma from 2007 to 2017. Staging of disease was done by referring to retinal diagrams, and first CT scan and MRI imaging. Ophthalmic notes, imaging reports and histopathology reports of enucleated eyes established optic nerve involvement. SPSS 21 was used for statistical analysis**Results:** Clinical records of 200 patients with retinoblastoma in 250 eyes were reviewed, and male to female ratio was 1 to 1. Retinoblastoma was bilateral in 50 patients (25%). Mean age at presentation was 2 +/- 3 months, while mean follow-up was 12 ± 3 months. Leucocoria was the most common presenting feature in 220 eyes (85%) followed by squint in 12 eyes (5%). Optic nerve involvement was seen on CT scan or MRI imaging or histopathology in 20 eyes (18%). Distant metastasis was noted in 6 patients (3%) on first presentation. Enucleation and exenteration were performed in 249 (99.9%) and 1 (0.5%) eyes, respectively**Conclusion:** Most common presenting symptom was leucocoria followed by squint. The only treatment offered to our patients is enucleation. It is advisable to consider other modalities for treatment of retinoblastoma that gives good result without removing the eye.

PP-544

**Nutritional Status and Staging in Patients with Retinoblastoma: Is it Related?**

L Yanita, P Utomo, B Dibyasakti, I Darajati, N Darmawan, K Setiawan, A Supartoto.

**Objective:** This study aims to determine whether there is correlation between nutritional status and retinoblastoma stage using hospital medical records.

**Methods:** Records of patients with retinoblastoma from Dr. Sardjito General Hospital, between 2013 and 2020, was obtained for an observational analytic study. Age, gender, laterality, weight for length/height, weight for age, BMI for age, staging of retinoblastoma with Reese-Ellsworth classification were analyzed. The correlation between nutritional status and Reese-Ellsworth classification was analyzed by the Spearman's Rank correlation test and p-value of <0,05 was considered significant.

**Results:** Among 64 cases of retinoblastoma enrolled in this study, there were 34 males and 30 females. Fifteen patients (23.4%) showed bilateral eye involvement while 49 patients (76.5%) reported as unilateral cases. There were 42 patients (65.6 %) of normal weight, 4 patients (6,3%) of severely underweight, 16 patients (25%) of underweight, and 2 patients (3.1%) at risk of being overweight. A Spearman's Rank correlation was run to determine the relationship between weight for age and Reese-Ellsworth classification of retinoblastoma. There was a weak negative correlation between weight for age to Reese- Ellsworth classification of retinoblastoma, which was statistically significant. ( $r_s(8) = -0.294, p = 0.018$ ). On the other hand, there was no correlation between weight for height/length and BMI for age with Reese-Ellsworth classification of retinoblastoma.

**Conclusion:** Weight for age correlates with retinoblastoma staging. There is a weak correlation between weight for age and Reese-Ellsworth classification of retinoblastoma. Thus, the nutritional status might attributable to the cancer development in retinoblastoma.

PP-545

**Multimodal Imaging Findings of a Case of Lung Cancer Complicated with Ocular Metastases**H Yu.

**Objective:** To report the multimodal imaging findings of a case of lung cancer complicated with ocular metastases

**Methods:** An elderly male patient came to our hospital for two months because of blurred vision in the right eye. The patient's medical history was inquired about the diagnosis of lymph node metastasis of lung cancer since October 2019, and he had received 15 in-hospital chemotherapy. Visual acuity, intraocular pressure, anterior segment slit lamp photography, fundus color photography and ultra-wide-angle scanning laser fundus examination, ocular ultrasound biomicroscopy (UBM) examination, ocular B-ultrasound examination, optical coherence tomography (OCT) examination, OCT angiography (OCTA) examination, fundus fluorescein angiography (FFA) examination and ocular magnetic resonance (MRI) examination.

**Results:** Multimodal imaging showed that the patient had lung cancer with iris metastasis in the right eye and choroidal metastasis in both eyes.

**Conclusion:** Lung cancer patients with ocular metastases have great difficulty in both local treatment of ocular metastases and systemic treatment of lung cancer. Lung cancer with ocular metastases is a huge challenge for ophthalmologists and oncologists in terms of diagnosis and treatment. The use of multimodal imaging will help to further improve the understanding of ocular metastases from lung cancer, shorten the diagnosis time, and improve the diagnosis rate, and further develop targeted local treatment strategies and systemic anti-tumor treatment strategies.

PP-547

**Invasive squamous cell carcinoma of the plica semilunaris.**S Souki<sup>1,2</sup>, M Couce Meradi<sup>1,2</sup>.<sup>1</sup>University General Hospital of Catalonia, <sup>2</sup>Sagrat Cor University Hospital, Barcelona, Spain

**Objective:** To describe one case of an invasive squamous cell carcinoma of the plica semilunaris in a 84 year old man, with a four month rapid growth.

**Methods:** A 84-year-old man presented a pedunculated tumour on the nasal ocular surface of his right eye and claimed a rapid growth the last four months. The tumour's base affected longitudinally the plica semilunaris and the diameter displayed was of 12mm with a thickness of 5mm approximately, measured with a light beam in the slit lamp. During the examination, the pedunculated tumour was gently lifted with a non traumatic forceps, so as to confirm no adherence to the bulbar conjunctiva, other than the plica semilunaris and, during that maneuver, fatty/keratinized tissue fell off the superior part of the tumour, giving the impression that it was a possible dermoid cyst. Orbital MRI was performed, previous to surgery, with no evidence of orbital or intraocular invasion.

**Results:** The tumour was treated by surgical resection using the non-touch technique with wide excisional biopsy and adjuvant cryotherapy to the remaining conjunctival margins. Histopathological examination showed a moderately differentiated invasive squamous cell carcinoma (grade II), with a free base but with the other margins involved. The mass size was of 12mm x 5.8mm x 3.4mm. Having in mind it was a pedunculated tumour, Mitomycin C 0.02% eye drops were prescribed at the postoperative period with close follow up.

**Conclusion:** A diagnosis of invasive squamous cell carcinoma must be considered in the presence of an ocular surface pedunculated tumour with a rapid growth. The macroscopic view of fatty/keratinized tissue does not exclude neoplasia. Tumour should be managed with an extensive surgical approach and adjuvant cryotherapy. Postoperative treatment strategy should be adjusted according to the tumour type, staging and risk for recurrence.

PP-549

## Representation of Female Editors-in-Chief in Ophthalmology Journals: A Cross-Sectional Study

J Park<sup>1</sup>, Y Xue<sup>1</sup>, T Felfel<sup>2,3</sup>.

<sup>1</sup>Faculty of Medicine, <sup>2</sup>Department of Ophthalmology and Vision Sciences, <sup>3</sup>Dalla Lana School of Public Health, University of Toronto, Toronto, Canada

**Objective:** This study aims to evaluate the representation of female editors-in-chief (EiCs) in ophthalmology journals globally, and to compare the proportion of female EiCs between journals grouped by geographical regions, impact factor quartiles and subspecialties within ophthalmology.

**Methods:** Ulrich's Periodicals Directory and Scimago Journal & Country Rank were used to comprehensively identify ophthalmology journals. All journals with active websites and EiCs were included. Journals were categorized according to the World Bank's 2021 classification of countries by income and region, and classified into subspecialties based on publication scope. Journal impact factors were obtained from Journal Citation Reports by Clarivate. The gender of each EiC was determined based on institutional profiles. In the absence of profiles, gender was determined using a cut-off of 90% certainty on the name query feature of the gender application programming interface. The chi-square test was used to determine associations between gender and journal categories. Odds ratio (OR) with 95% confidence interval (CI) was reported.

**Results:** A total of 222 EiCs from 193 ophthalmology journals globally were identified. Amongst all EiCs, 17% (37) were female. The proportion of female EiCs in North America (16%) was comparable to that of the rest of the world (17%). Similarly, the proportion of female EiCs in high-income countries was 15% compared to 20% amongst journals originating from lower income countries. Journals classified into the subspecialty category of neuro-ophthalmology and paediatric ophthalmology had 50% (7/14) EiCs that were female compared to 14% (30/208) female EiCs identified in the other journals. In fact, females were nearly 6 times more likely than males to be EiCs in the paediatric/neuro-ophthalmology subspecialty journals (OR = 5.9, 95% CI 1.9-18.1; P = 0.002). The proportions of female EiCs in retina and glaucoma subspecialty journals were 18% (2/11) and 17% (1/6), respectively. There were no associations between the journal impact factor quartiles and the proportion of female EiCs.

**Conclusion:** There is a notable underrepresentation of females in EiC position in ophthalmology journals globally. The gender disparity may vary across different journal subspecialties but not based on journal impact factor. These findings suggest that there is room for improvement regarding representation of women in ophthalmology leadership positions and highlight the need for further research on these disparities.

PP-550

**Oral Eplerenone in Acute Central Serous Chorioretinopathy: New Approach in Management**S Sarkar<sup>1</sup>, A Dey Sarkar<sup>1</sup>, S Thakur<sup>1</sup>, A Dey Sarkar<sup>2</sup>.<sup>1</sup>Ophthalmology, Midnapore Medical College and Hospital, Midnapore, <sup>2</sup>Ophthalmology, NRS Medical College and Hospital, Kolkata, India

**Objective:** Introduction: Central Serous Chorioretinopathy (CSCR) involves serous detachment of neurosensory retina and/or retinal pigment epithelium with accumulation of fluid. Role of increased levels of endogenous or exogenous corticosteroids have been implicated as a probable pathogenesis. This link between corticosteroids and CSCR, combined with observation of an induced CSCR-like model in rats with mineralocorticoid receptor (MR) pathway activation has prompted the evaluation of role of Eplerenone, an MR antagonist in the treatment of CSCR.

Objective: To assess efficiency and safety of Oral Eplerenone in Acute Central Serous Chorioretinopathy (CSCR).

**Methods:** It was a randomised prospective comparative case series designed from a consecutive series of CSCR patients attending Ophthalmology OPD at a tertiary care centre for a duration of 3 years. 162 patients of acute CSCR were enrolled for the study, among which 81 received oral Eplerenone (Group A) and 81 received Placebo therapy (Group B). Each patient underwent assessment of Best Corrected Visual Acuity (BCVA) along with comprehensive ophthalmological examination, multimodal imaging by Fundus Photography, Central macular thickness (CMT) calculation with the help of SD-OCT and serum K<sup>+</sup> levels at baseline and monthly for 3 months.

**Results:** The mean age of presentation in Group A was  $35.33 \pm 9.42$  years whereas that in Group B was  $34.26 \pm 10.57$  years. The study population showed a male preponderance. Change in CMT in Group A and Group B were  $278.8\mu$  and  $206.9\mu$  in 1st month ( $p=0.006$ ),  $328.28\mu$  and  $240.02\mu$  ( $p=0.001$ ) in 2nd month and  $360.7\mu$  and  $278.25\mu$  in 3rd month ( $p=0.002$ ) respectively. Average BCVA improvement in Group A and Group B were 6.05 lines and 4.21 lines at conclusion respectively ( $p=0.021$ ). With regard to SRF resolution, at 1 month, 46% of the patients in the treatment group demonstrated complete SRF reabsorption, compared to only 22% of those in the control group. At the end of 3<sup>rd</sup> month, 3.7% patients in Group A progressed to chronic CSCR compared to 17.3% patients in Group B. Increase in Serum K<sup>+</sup> at conclusion was 0.62mg% in Group A and negligible in Group B ( $p=0.035$ ).

**Conclusion:** Eplerenone is a safe and effective first-line treatment option for acute CSCR conferring higher and faster resolution. This study also indicates that patients undergoing Eplerenone therapy show protection from progression towards Chronic CSCR with permanent RPE changes. Eplerenone may represent an attractive new first-line treatment option for acute CSCR.

## PP-551

**A qualitative study to understand the difficulties faced by clinicians and patients in the management of Uveitis cases**

T Pradeep<sup>1</sup>, A Bhandary<sup>1</sup>, C Pius<sup>1</sup>, D RH<sup>1</sup>.

<sup>1</sup>Ophthalmology, MS Ramaiah Medical College Hospital, Bangalore, India

**Objective:** The study aimed to understand the difficulties faced by patients with uveitis and the challenges faced by clinicians in management of uveitis patients, to recognize and meet those needs through mobile technologies.

**Methods:** A qualitative study was conducted to identify the challenges encountered by patients and clinicians in the management of uveitis and to gain insight so as to overcome these challenges by using technology. This study was executed in phases the first of which involved the assessment of patient's needs. A validated questionnaire was administered pertaining to their understanding of the disease, the use of medication and the requirement of a mobile health technology that may aid in better treatment. In the second phase, health care providers partook in a focussed group discussion that highlighted the challenges they faced in the management of patients with uveitis. Data from this was collected, analysed and used for the development of mobile health application.

**Results:** A semi-structured interview was administered to 10 patients. All patients were in agreement that they did not understand their disease and the need for multiple investigations and systemic medications for an eye disease. Eight out of the 10 patients had no problem in remembering their medication schedule while all ten patients agreed that it would help if they were reminded about the drops. Seven out of the 10 patients recognised that a mobile computer application sending them reminders would be helpful and they would use if such an application was installed on their phone. The individuals who answered in negative about the use of such an application were those who did not using a smart phone. The focus group discussion of clinicians identified gaps in the management strategies such as difficulty in explaining the disease to the patients, explaining the need for multiple investigations and cross referrals. The clinicians unanimously agreed the need for integration of technology to the current management. The use of computer application to educate the patients and monitor the patient's compliance with treatment and referrals would probably help in better management of uveitis patients.

**Conclusion:** The study emphasized the lack of understanding about uveitis among patients and the challenge of educating about the disease by the clinicians. It also provided a direction towards utility of a mobile health application in educating and monitoring uveitis patients for effective management.



PP-552

### Awareness Of Indian Penal Codes To All Global Ophthalmology Journals - Possibility Of All Ophthalmology Societies Grievance Prone

K S V.

**Objective:** Being registered society, AIOS is bound to follow Indian Penal Codes (IPC). AIOS is teaching knowingly evidence based incorrect medical terms to the innocent younger generation without even mentioning misnomer and in turn making them habituated. Hence, AIOS is prone for grievance under article 226 (high court) & article 32 (Supreme Court) in the constitution of India. All global ophthalmology societies having been registered in their respective constitutions are prone for grievance in teaching and publishing incorrect medical terms as per their respective constitutional penal codes too. Historically Ophthalmology is noted for first medical specialty organization in 1864, first board examination in 1917, first antiviral agents, first homo transplants, first time photocoagulation, first time angiography and now trying to remove incorrect terms in literature.

**Methods:** Many incorrect medical terms like Retinoscopy, Retinal detachment, Phaco emulsification, Computer vision syndrome, Syringing etc., have been added to literature. No other options are left for us to request them from whom we have learnt to review literature. I brought to the notice issue of grievance prone to many global societies, editors of many journals by emails. I with my mentor, Dr.Nagpal sir requested to chairman, ethics committee of ICO to discuss in International Federation Ophthalmology Society if possible , as issue is global ethical concern (on the contrary to two representatives from each society).

**Results:** Older generation out of habituation resist and younger generation maintain silence with due respect to elders. Every country will have same laws with different numbers. No attempt was made even with appeal in the past to restore precision. It is unethical to publish incorrect medical terms in journals

**Conclusion:** Further freezing of evidences is to be stopped before questioned by future generations. Papillitis is being changed to Optic neuritis. One side is habituation and other side is precision. Precision is to be preferred in science. General body decision of AIOS is invalid legally. Either AIOS has to prove evidences are being wrong or approach higher authority to take proper steps. Keeping quiet also, AIOS is grievance prone as per the laws mentioned. Bringing to the notice of IFOS(International federation of ophthalmic societies) is only solution to resolve long standing grievance prone issue of all global ophthalmology societies.

PP-553

**Comparison of refractive error using Streak Retinoscope, Hand-Held Autorefractometer and Gimbalscope.**J Oswal<sup>1</sup>, Y Patil<sup>1</sup>, P Chandrakanth<sup>1</sup>, H Gosalia<sup>1</sup>.<sup>1</sup>Aravind Eye Hospital, Coimbatore, Tamil Nadu, Coimbatore, India

**Objective:** To evaluate the accuracy and effectiveness of noncycloplegic & cycloplegic refraction using Gimbalscope (GS) -Frugal smartphone Retinoscope; compared with Streak Retinoscopy (SR) & Autorefractometer (AR) in children and adolescents.

**Methods:** This randomized trial included 224 eyes of children and adolescents. Non cycloplegic and cycloplegic refractive measurements were obtained using Gimbalscope (GS), Streak Retinoscopy (SR) and Autorefractometer (AR). The Spherical(S), Cylindrical(C), Axis of Cylinder(A) & Spherical equivalent(M) were statistically compared. Measurement discrepancies from SR, GS & AR were compared using ANOVA and receiver operating characteristic curve analysis.

**Results:** Compared with Streak Retinoscopy (SR) and Autorefractometer (AR)., measurements obtained before & after cycloplegia with Gimbalscope (GS) showed excellent reliability. No significant statistical difference was found between the 3 methods.

**Conclusion:** This was one of the first studies done which used a smartphone-aided retinoscope to compare results with AR & SR. The results were found to be highly reliable. It was found to be useful for teaching purposes for residents and optometrists alike.

PP-554

**Post-Operative Astigmatism in Small Incision Cataract Surgery done by Final Year Residents**S Thakur<sup>1</sup>, A Dey Sarkar<sup>1</sup>, P Gangopadhyay<sup>1</sup>.<sup>1</sup>Ophthalmology, Midnapore Medical College & Hospital, Midnapore, India

**Objective:** Introduction: In developing countries like India, Small Incision Cataract Surgery (SICS) is economical, effective, safe and non-machine dependent option for cataract surgery. It is important for post graduate trainees in Ophthalmology to be trained in SICS to combat the cataract blindness in the country.

Objective: To assess the post-operative astigmatism in Small incision Cataract Surgery done by final year residents.

**Methods:** Methods: 858 eyes of SICS by done by Final year Ophthalmology residents from August 2019 to March 2022 were studied. Keratometry and Refraction was done preoperatively and 6 weeks post SICS. Surgically Induced Astigmatism (SIA) was calculated using SIA calculator Version 1.1.

**Results:** Results: A total of 858 eyes of 611 patients were performed by final year residents. Overall, 782 eyes (91.14%) had a Post-operative Best Corrected Visual Acuity (BCVA) between 6/6-6/12 on Snellen Chart. Intra-operative complications were seen in 135 eyes (15.73%). Most common complications were extension of capsulorhexis in 31 (3.61%) eyes, Posterior Capsular Rent 28 (3.26%) eyes, Premature Sclero-Corneal Tunnel 22 (2.56%) eyes, iridodialysis 18 (2.09%) eyes and iris prolapse 16 (1.86%) eyes.

39 (4.55%) had no SIA. SIA was between 0.25-1D in 482 (56.18%) eyes while it was 1.25-2D in 210 (24.47%) eyes; 2.25-3D in 99 (11.54%) eyes and 28 (3.26%) eyes had a SIA >3D. The Average SIA was  $1.32 \pm 0.93D$ .

**Conclusion:** Conclusion: Systematic step wise training of residents in the first two years can lead to improved outcomes with standard post-operative astigmatism in final year under proper supervision.

PP-555

### Parameters for Evaluating an Artificial Intelligence Model For Accuracy

S Buragohain, H *Bhattacharjee*<sup>1</sup>, H *Javeri*<sup>2</sup>.

<sup>1</sup>*Comprehensive Ophthalmology, Sri Sankaradeva Nethralaya, Guwahati,* <sup>2</sup>*Vitreo-retina, Sankara Eye Hospital, Bangalore, India*

**Objective:** To perform a literature review on the available methods for the evaluation of an artificial intelligence model in the health care sector

**Methods:** We performed an in-depth literature review using the keywords “Artificial Intelligence”, “Healthcare” and “Evaluation” in Pubmed, Cochrane and Google Scholar. All articles that dealt with methods for the evaluation of artificial intelligence (AI) were included in the review. Additional articles were reviewed by cross-referencing from the key articles from the search.

**Results:** The literature review found a number of articles that dealt with evaluation of an AI model in the health care context. The articles highlighted problems such as “over-fitting” and “under-fitting” that are encountered during the training and testing of an AI model. These problems may give a low test accuracy inspite of the model achieving high training accuracy. The articles also discussed measures to address the above issues and the utilisation of statistical approaches such as receiver-operator curve (ROC) and area under receiver-operator curve (AUROC) in the process. Metric definitions such as accuracy, sensitivity, specificity, precision and negative predictive value have also been discussed.

**Conclusion:** With the increasing utilisation of artificial intelligence in health care it is pertinent for clinicians to be aware of the process of training an AI model as well as its evaluation for clinical application. We have done a literature review to summarise the key parameters which a clinician may take into account when evaluating an AI model for clinical use.

PP-556

**Let's do it: The potential of general ophthalmologist**

H Das<sup>1</sup>.

<sup>1</sup>*Ophthalmology, Nazareth Hospital, Shillong, Shillong, India*

**Objective:** To kindle some interest in oculoplasty & aesthetic procedures among the comprehensive ophthalmologists.

**Methods:** Retrospective analysis of various oculoplastic and aesthetic procedures performed by a general ophthalmologist at a tertiary health care centre in north east India.

**Results:** Lid surgeries (various types of lid reconstruction, ptosis correction, blepharoplasty, orbital surgeries (reduction & fixation of orbital fracture, removal of orbital foreign body, exenteration), conjunctival, lacrimal, squint & glaucoma were found being done

**Conclusion:** A general ophthalmologist also can attain the required minimal skills by good reading, attending lectures, workshops, live demonstrations & practising skills in hands on courses. Good instruction courses of various national & international ophthalmic society & dedicated sessions oculoplastic society in their annual conferences are also very helpful.

PP-557

**An explore of trabeculectomy wet-lab education during the pandemic**C Liu, Y Yang, D Zheng, L Liang, Y Li, Y Zhuo.

**Objective:** Facing the current situation of ophthalmic training with limited participation in clinical surgery but increasing number of students, we hope to improve the training efficiency and help students better master surgical skills by optimizing the wet-Lab course setting of trabeculectomy.

**Methods:** The residents training in Zhongshan Ophthalmic Center (ZOC) were recruited. The training included one pre-training online class, three weeks of practicing freely and six offline classes (one hour each class). Trainees recorded their operational videos after 3, 6, 9, 12 and 15 hours of practicing and these videos were scored by glaucoma specialists. The final assessment was carried out on the last day of the course after practicing at least 15 hours.

**Results:** The training scores gradually increased with the practicing hours. The score was  $64.35 \pm 9.00$  after 3 hours of practicing and  $78.58 \pm 9.24$  after 15 hours ( $P < 0.001$ ) and most steps' scores have been significantly improved. Grouping trainees according to their highest educational diploma, the final scores of the trainees with bachelor degree ( $79.17 \pm 8.90$ ) is lower than that of the others (master:  $89.5 \pm 4.24$ ; doctor:  $89.85 \pm 3.87$ ) ( $P < 0.001$ ). And students with larger variance or range of practicing time have lower final scores (daily practicing time:  $P=0.025$ ; weekly practicing time:  $P=0.007$ ).

**Conclusion:** The three-week course has effectively improved the trainees' trabeculectomy operational ability. According to our results, 12~15 hours of practicing is indispensable for the trainees to master the operation, but the operation needs to be further refined in clinical practice. Centralized practicing is more unfavorable to the improvement of surgical skills of trainees than the equal distribution of practicing time, and standardize the practicing frequency of trainees may be a better choice. Our teaching and evaluation method can be extended online to jointly promote the improvement of ophthalmic practitioners' surgical ability during the pandemic.

PP-558

**EYESI virtual reality simulation and trainee attitudes**C Gin, J Reyna, S Khanwal, R Chakrabarti.

**Objective:** The Eyesi Virtual Reality Simulator (VRS) is a well-established education and microsurgical tool utilised in training cataract surgery. It has been validated for numerous Ophthalmic surgical modules including anterior segment forceps, anti-tremor modules, capsulorhexis, phacoemulsification, navigation, tracking and chopping(1, 2). In education, the impact of a learner's attitude on their learning has been clearly demonstrated (3, 4).

We have reviewed the attitude of trainee Ophthalmologists towards VRS as the first stage of an broader study investigating how attitudes impacts attainment and development of microsurgical skills.

**Methods:** All first-year trainees commencing Royal Australian and New Zealand College of Ophthalmology Ophthalmology training in February 2022 were invited to voluntarily participate in the research prior to commencement of training. They were sent a questionnaire, which included questions on prior experience, certainty-based questions, trainee attitude towards VRS and free-text questions for unstructured comments.

**Results:** The questionnaire was completed by 30 of 32 trainees and it is currently undergoing further analysis.

**Conclusion:** The attitudes of Ophthalmology trainee towards VRS and its implications for attainment of microsurgical skills is a novel topic that has not been explored within academic literature previously. This review is the first step in multistage research project aiming to explore Ophthalmology trainee's attitudes towards VRS and its implications.

1. Mahr MA, Hodge DO. Construct validity of anterior segment anti-tremor and forceps surgical simulator training modules : Attending versus resident surgeon performance. Journal of cataract and refractive surgery. 2008;34(6):980-5.
2. Privett BMD, Greenlee EMD, Rogers GMD, Oetting TAMSMD. Construct validity of a surgical simulator as a valid model for capsulorhexis training. Journal of cataract and refractive surgery. 2010;36(11):1835-8.
3. Kpolovie PJ, Joe AI, Okoto T. Academic achievement prediction: Role of interest in learning and attitude towards school. International Journal of Humanities Social Sciences and Education (IJHSSE). 2014;1(11):73-100.
4. Fakeye DO. Students' Personal Variables as Correlates of Academic Achievement in English as a Second Language in Nigeria. Journal of Social Sciences. 2010;22(3):205-11.

PP-559

**The Gimbalscope – A Novel smartphone - assisted retinoscopy technique.**J Oswal<sup>1</sup>, Y Patil<sup>1</sup>, P Chandrakanth<sup>1</sup>, H Gosalia<sup>1</sup>.<sup>1</sup>Aravind Eye Hospital, Coimbatore, Tamil Nadu, Coimbatore, India

**Objective:** To describe a frugal technique of retinoscopy where we attach the retinoscope to the smartphone camera with the help of adaptors for simultaneous viewing and recording of the subject's retinoscopic reflexes.

**Methods:** Commercially available smartphone holder clamps were attached together using cyanoacrylate super glue. Rubber bands were tied so as to make the holder clamp attachment stronger. A smartphone (IOS operating agent- iPhone 5s; Apple, Los 43 Altos, CA) was attached to one of the clamps. A metal smartphone mount holder (with its clamp removed) was passed through the battery hand piece of the retinoscope (HEINE line retinoscope Beta 200, HEINE Optotechnik, Gilching, Germany). The clamp with the smartphone attached to it was then connected on to the smartphone mount holder which was already secured to the retinoscope battery hand piece. The smartphone camera is then aligned to the eyepiece of the retinoscope and the whole setup is reinforced . The smartphone camera zoom option was used to focus and magnify the retinoscope light beam as well as the reflex. Neutralization was performed at a normal working distance. Retinoscopic reflexes were elucidated and recorded from forty eyes of twenty patients including eight eyes of four paediatric patients.

**Results:** Normal and abnormal retinoscopic reflexes obtained were clear and the smartphone zoom could be used to digitally magnify them at the same working distance.

**Conclusion:** We introduce a novel and relatively inexpensive smartphone assisted retinoscopy apparatus which can clearly record and document the retinoscopy phenomena and provides a convenient, inexpensive tool to assist the teaching of medical students, residents, and for second opinion. This setup is of immense benefit to beginners as they can better understand the retinoscopy phenomena and observe it along with the mentor in real time as well as utilise the recorded videos in identifying the abnormal and subtle retinoscopic reflexes.



## PP-560

**Retinal microvasculature density and geometry in optical coherence tomography angiography predict onset of diabetic retinopathy: a**

Y *Chen*, W *Huang*, W Wang.

**Objective:** To evaluate the associations of optical coherence tomography angiography (OCTA) metrics with the incidence of diabetic retinopathy (DR).

**Methods:** In this prospective cohort study, type 2 diabetes patients without DR at baseline were recruited and followed up at one year. All participants underwent  $3 \times 3$  mm<sup>2</sup> OCTA imaging (DRI-OCT Triton; Topcon Inc., Tokyo, Japan) centred at the fovea of the macula. The foveal avascular zone (FAZ) area, vessel density (VD), vessel length density (VLD), fractal dimension (FD) and blood vessel tortuosity (BVT) in superficial capillary plexus (SCP) and deep capillary plexus (DCP) were measured. DR status was graded from baseline and follow-up fundus photographs using Early Treatment Diabetic Retinopathy Study (ETDRS) protocols.

**Results:** Over a follow-up of one year, 182 of 1,698 participants (10.7%) developed incident DR. After adjusting for age, sex, HbA1c, duration of diabetes, body mass index, systolic blood pressure, diastolic blood pressure, total cholesterol, axial length (AL) and image quality score, the incident DR was significantly associated with the reduced parafoveal VD of SCP (relative risk [RR] 0.81 per 1-*SD* increase; 95% confidential interval [CI]: 0.69, 0.96;  $p = 0.016$ ), reduced parafoveal VLD of SCP (RR 0.73 per 1-*SD* increase; 95% CI: 0.59, 0.90;  $p = 0.003$ ), reduced FD of SCP (RR 0.73 per 1-*SD* increase; 95% CI: 0.61, 0.87;  $p < 0.001$ ), increased BVT of SCP (RR 1.39 per 1-*SD* increase; 95% CI: 1.18, 1.64;  $p < 0.001$ ) and increased BVT of DCP (RR 1.19 per 1-*SD* increase; 95% CI: 1.01, 1.40;  $p = 0.033$ ).

**Conclusion:** Baseline retinal vessel density and geometric distribution were associated with DR onset in patients with type 2 diabetes. This study provided new longitudinal evidence to support macular OCTA metrics as early monitoring indicators of the newly incident DR.

PP-561

**Peripapillary perfusion and rate of eGFR decline in type 2 diabetes: a 3-year prospective study**Y Huang<sup>1</sup>, W Wang.<sup>1</sup>Guangzhou Medical University, Guangzhou, People's Republic of China

**Objective:** To evaluate the associations of peripapillary microcirculation based on non-invasive OCTA technique with the risk of eGFR decline in patients with type 2 diabetes and to clarify their added value.

**Methods:** Type 2 diabetic patients without retinopathy (non-DR) were recruited from the Guangzhou community and underwent standardized ocular and systemic examinations annually during a 3-year follow-up period. The additive value of OCTA parameters for identifying progressive faster eGFR decline was estimated by area under the receiver operating characteristic curves (AUC), net reclassification index (NRI), and integrated discrimination improvement (IDI).

**Results:** A total of 881 patients were included for statistical analysis, with the mean age of  $64.32 \pm 7.32$  years. After adjusting for other confounders, each 1% decrease in baseline whole en face PD in SCP and RPC was associated with accelerated rates of decline in eGFR by  $-0.49$  (95% CI:  $-0.87, -0.12$ ;  $P=0.011$ ) mL/min/1.73/m<sup>2</sup> per year and  $-0.56$  (95% CI:  $-0.89, -0.23$ ) mL/min/1.73/m<sup>2</sup> per year, respectively. Similar relationships were noted between lower cpPD of SCP and cpPD of RPC at baseline and a faster rate of eGFR decline. Adding wiPD in SCP or wiPD in RPC to the conventional model increased the AUC from 0.692 (95% CI: 0.649, 0.734) to 0.717 (95% CI: 0.676, 0.758) ( $P=0.030$ ), from 0.692 (95% CI: 0.649, 0.734) increased to 0.721 (95% CI: 0.681, 0.762) ( $P=0.017$ ), significantly improving the power of identifying patients at the top tertile of eGFR decline rate.

**Conclusion:** Peripapillary perfusion are associated with a faster eGFR decline and have additional predictive value for detecting faster progressor at an early stage. Quantification of retinal microcirculation alterations using OCTA may provide important information for risk assessment of the development of diabetic nephropathy and prediction of the rate of disease progression.

**PP-566****Perceived barriers to low vision rehabilitation services among eye care practitioners in Ethiopia: a cross-sectional study**S Geleta.**Objective:**

To determine the barriers of low vision rehabilitation services in Ethiopia.

**Methods:** A cross sectional descriptive survey was conducted over practicing ophthalmic personnel in Ethiopia during a 2 months period (June 1 to July 30, 2020). The data was entered to Epi data manager version 4.4.1.0 and exported to SPSS version 23 for different analyses. Descriptive statistics like means, proportions and frequency tables was applied for different analysis. Chi-square test was used to test association between independent variable and dependent variables.

**Results:** A total of 150(72.8%) out of 206 responded to the questionnaire and completed it in appropriate way. Out of 150 participants 115(76.7%) were males. Mean and standard deviation of age was  $30.62 \pm 3.89$  years. Among study participant's 54(36.0%) were Ophthalmologists and subspecialists, 6(4.0%) Cataract-Surgeon, 49(32.7%) Ophthalmology-Residents and 27(18%) Optometry-Professionals. The major barriers that ophthalmic personnel face in providing low visions care includes: non-availability and expensiveness of low vision devices 136 (90.67%), lack of training 117(78%), lack of awareness 49 (32.7%), lack of interest/motivation 38(25.3%) and more work load and lack of man power 34(22.67%). The perception that lack of interest/motivation is a major barrier in providing low vision rehabilitation is significantly higher [OR 3.148(1.459, 6.795)] among those who were knowledgeable than not knowledgeable about low vision services and among those trained in Ethiopia [OR 5.062(1.345, 19.050)] than abroad. Lack of training was perceived to be a major constraint for the provision of low vision rehabilitation in a greater proportion of respondents who were from institution giving low vision rehabilitation [OR 4.0125 (1.471, 10.945)] than who didn't provide low vision rehabilitation services.

**Conclusion:** Non-availability of low-vision devices and expensiveness of low vision device within the country is the most common constraint for the provision of low vision rehabilitation. Majority of the participants have good awareness about low vision rehabilitation service but less knowledgeable. Training in low-vision care should be provided for eye care personnel at all levels. It is better if Ethiopian Ministry of Health give concern for ways to provide low vision devices at all government eye care services.

PP-567

**Visual assessment of commercial drivers in the South West Region of Cameroon**E N Nche<sup>1</sup>, B Vofo<sup>2</sup>, D Ayuk<sup>3</sup>, J Pe'er<sup>2</sup>, A Chichom<sup>4</sup>, N Tendongfor<sup>5</sup>.<sup>1</sup>Ophthalmology, Regional Hospital Buea, Buea, Cameroon, <sup>2</sup>Ophthalmology, Hadassah Medical Center, Jerusalem, Israel, <sup>3</sup>Medicine, Ministry of Health, Cameroon, <sup>4</sup>Surgery, <sup>5</sup>Microbiology, University of Buea, Buea, Cameroon

**Objective:** Driving is a visually intensive task. In Cameroon where the burden of road traffic deaths is high, visual assessment is not universally performed before the issuance of driver's licenses. This study assesses the visual status of commercial drivers (CDs) in the Southwest Region of Cameroon.

**Methods:** This work was a cross-sectional community-based study on CDs in Limbe and Buea. Questionnaires were used to assess sociodemographic parameters, the incidence of RTCs, and self-reported visual status. Visual acuity (VA) was measured using a standard Snellen chart at 6 m. Statistical analysis was performed using descriptive methods: frequencies, the paired Student's t-test, and the chi-square test.

**Results:**

Two hundred seven CDs were enrolled in this study, all of which were male, with a mean age of  $41.8 \pm 12.1$  years. A total of 15.0% had undergone an eye exam prior to licensure, and 3.4% had undergone an eye exam within the past 10 years. The VA in the better-seeing eye of participants was less than 6/9 and 6/12 in 14.1 and 10.6% of CDs, respectively. Seventy-five percent of CDs with self-reported poor vision and 95% of CDs with VA  $< 0.5$  had a history of RTCs compared to 55.8% of CDs with self-reported good vision and 55.7% of CDs with VA  $\geq 0.5$  ( $p < 0.05$ ). Injuries from RTCs were more common in CDs with self-reported poor vision (81.1%) and in those with VA  $< 0.5$  (90.5%) compared to CDs who self-reported good vision (55.8%) and those with VA  $\geq 0.5$  (55.7%) ( $p < 0.05$ ).

**Conclusion:** A large proportion of CDs did not undergo a visual assessment before the issuance or renewal of their driver licenses. A substantial number of CDs had poor vision in their better-seeing eye and suffered from RTCs and related injuries, which suggests that the visual status of CDs in Cameroon is related to the gruesome number of road traffic crashes and deaths in the country. Therefore, concerned authorities should consider making vision tests a necessary requirement for the obtention of driver licenses.

PP-568

**Retinal and choroidal microstructures in diabetic retinopathy (DR) by SS-OCTA with or without diabetic nephropathy (DN)**T Liu<sup>1</sup>.<sup>1</sup>Eye Hospital of Shandong First Medical University (Shandong Eye Hospital), Jinan, China, Jinan, Hong Kong, China

**Objective:** To observe the changes in retinal and choroidal microstructures in diabetic retinopathy (DR) with or without diabetic nephropathy (DN) patients and to evaluate the retinal and choroidal vascular perfusion, vessel density (VD) and thickness by the swept-source optical coherence tomography angiography (SS-OCTA).

**Methods:** Subjects were divided into three groups : healthy control group (30 cases, 51 eyes) and DR group (44 cases, 75 eyes), including DR with DN group (16 cases, 29 eyes) and non-diabetic nephropathy(NDN) group (28 cases, 46 eyes). DN patients are divided into with and without DME(14 eyes/15 eyes), as the same as NDN(21 eyes/ 25 eyes). We used the SS-OCTA to measure the deep and choroidal vascular complexes. The deep vascular complexes including the VD, perfusion density(PD) and retinal thickness(RT) within the radius of 3mm, 6mm, 9mm, 12mm, 6-3mm<sup>2</sup>, 9-6mm<sup>2</sup> and 12-9mm<sup>2</sup> around the fovea. The choroidal vascular complexes including the CP, choroidal vascular index(CVI), choroidal vessel volume(CVV) and choroidal thickness(CT).

**Results:** Our results were that VD,PD and CP in DR patients with or without DN were lower than control group. And these in DN patients decreased more than DR patients. However, the RT was thicker than control group. We founded that RT in DME patients was thicker than in non-DME patients. And VD, PD and RT of non-DME patients were statistical differences in 6mm. CVV and CT of DME patients were statistical differences in 6mm, 9mm and 6-3(mm<sup>2</sup>). CVI and CT of DN patients with DME higher than those in DN patients without DME in 3mm, 6mm, 9mm and 12mm. And in all captures, CVV was statistical differences in DN patients with or without DME.

**Conclusion:** DN and DR are consistent. Microvascular lesions in DN are more severe than in DR, expressing in RT, VD, PD and CP. SS-OCTA works as a new alternative to OCTA because of larger examination range and faster scanning speed in DR diagnose.

PP-569

### Exploring Macular Choroidal and Retinal Thickness in Tibetan Children of Different Refractive Status

Y Yao<sup>1</sup>, J Fu<sup>1</sup>.

<sup>1</sup>Ophthalmology, Beijing Tongren Hospital, Beijing, People's Republic of China

**Objective:** To investigate and evaluate the distribution and progressive changes of macular choroidal and retinal thickness of different refractive status in Tibetan children using swept-source OCT(SS-OCT).

**Methods:** OCT assessment was conducted on 1632 students from 7 primary schools in Lhasa, Tibet, following random stratified sampling. Each child underwent comprehensive general and ocular examinations including the SS-OCT scanning to assess the thickness of choroid and retina, including macula, ganglion cell-inner plexiform layer(GCIPL), ganglion cell complex(GCC), and retinal nerve fiber layer(RNFL). Multivariate and correlation analyses were performed to evaluate the association of the demographic and ocular variables.

**Results:** The average age of the 1555 students who finished OCT assessment was  $8.57 \pm 0.50$  years, of which 52.2% were male and 95.1% were Tibetan. The SER of the whole sample was  $0.19 \pm 1.28$ D. The average thickness of macular choroid, full retina, GCC, GCIPL and RNFL was  $233.23 \pm 44.40 \mu\text{m}$ ,  $272.72 \pm 24.32 \mu\text{m}$ ,  $107.91 \pm 11.37 \mu\text{m}$ ,  $70.82 \pm 7.02 \mu\text{m}$  and  $37.21 \pm 6.64 \mu\text{m}$ , respectively. Choroid and retinal thicknesses were significantly thinner in myopic children ( $P < 0.001$ ). The choroid, GCIPL and GCC thickness of girls were significantly thicker than those of boys ( $P < 0.01$ ). The foveal thicknesses of GCC, GCIPL, and RNFL were positively correlated with height and BMI, but negatively with weight ( $P < 0.05$ ). SER was positively correlated with the thickness of most choroidal and retinal regions ( $P < 0.001$ ), except for the central and inner inferior area of full retina. For GCIPL and GCC thickness, only the outer annulus had obvious correlation with SER ( $P < 0.005$ ). The averaged RNFL and nasal region thickness were negatively associated with SER ( $P < 0.05$ ). Every region of the choroid was significantly correlated with the thickness of full retina except central region. Compared to baseline data from 20 months ago, most regions of full retina have decreased significantly ( $P < 0.001$ ). The retinal thickness of the myopic group was thinner than that of the hyperopic group in both thinning and thickening retinal regions. The change in SER was only positively correlated with the change in GCIPL thickness ( $P = 0.002$ ).

**Conclusion:** This study describes the normal distribution of choroid and macular retina thickness in Tibetan children in Lhasa, with the comparison of retinal thickness at baseline. Thinning of choroidal thickness may predict the onset or progression of myopia. It contributes to the establishment of a normative ophthalmology database of Tibetan children.

**PP-572****Peripapillary microvasculature and the risk of the development and progression of diabetic retinopathy**

M Yuan, W Wang.

**Objective:** To examine the associations of peripapillary vessel alterations with diabetic retinopathy (DR) development and progression based on OCT angiography (OCTA).

**Methods:** This observational, prospective cohort study included type 2 diabetes mellitus (T2DM) in community. The 7-field ETDRS fundus photography in baseline and 2-year follow-up was graded. The main outcomes were 2-year incidence of DR, referable DR (RDR), and DR progression of individuals. The peripapillary vessel density (pVD) and vessel length density (pVLD) in optic nerve head were obtained by using a swept-source OCTA (SS-OCTA).

**Results:** A total of 1033 subjects (1033 eyes) were included. The 2-year incidence of DR was 25.1% (n=222) in NDR eyes, 10.2% DR progression (n=15) in DR eyes, and 4.17% RDR eyes (n=43) in all eyes. After adjusting age, sex, HbA1c and DM duration and other risk factors, decreased wi-pVD (RR, 0.81; 95%CI, 0.68-0.96;  $P=0.015$ ), circ-pVD (RR, 0.79; 95%CI, 0.66-0.95;  $P=0.013$ ), wi-pVLD (RR, 0.79; 95%CI, 0.67-0.94;  $P=0.008$ ) and circ-pVLD (RR, 0.76; 95%CI, 0.63-0.91;  $P=0.003$ ) were significantly associated with increased risk of DR incidence; wi-pVD (RR, 0.48; 95%CI, 0.35-0.67;  $P<0.001$ ), circ-pVD (RR, 0.65; 95%CI, 0.45-0.94;  $P=0.023$ ) and wi-pVLD (RR, 0.46; 95%CI, 0.33-0.66;  $P<0.001$ ) were associated with incident risk of RDR. The receiver operator characteristic curve (AUROC) demonstrated that peripapillary vessel metric improve the predictive power, with the AUC for 2-year DR incidence from 0.631 to 0.658 (4.28%;  $P=0.041$ ) by circ-pVLD; the AUROC of 2-year RDR incidence risk prediction model can be elevated from 0.631 to 0.752 by wi-pVD (19.18%;  $P=0.009$ ), to 0.752 by circ-pVD (19.18%;  $P=0.009$ ), and to 0.752 by wi-pVLD (19.18%;  $P=0.009$ ).

**Conclusion:** Lower pVD and pVLD at the ONH region are associated with higher risk for 2-year incident DR and RDR, and capable to optimize prediction models after adjusting established risk factors.

## PP-573

**Longitudinal assessment of peripapillary retinal nerve fibre layer and choroidal thinning in diabetic subjects without clinical re**

S Zhang, W Huang, W Wang.

**Objective:** To evaluate the longitudinal changes in peripapillary retinal nerve fibre (pRNFL) thickness and peripapillary choroidal thickness (pCT) in diabetes patients.

**Methods:** This prospective, observational cohort study was conducted at the Zhong-shan Ophthalmic Centre (ZOC), Sun Yat-sen University, Guangzhou, China. The type 2 diabetes without diabetic retinopathy (DR) at baseline were recruited and followed up for 2 years. The pRNFL thickness and pCT were automatically measured utilising SS-OCT device. The absolute and percent reduction rates of pRNFL thickness and pCT were calculated using linear mixed-effects models.

**Results:** A total of 713 patients (713 eyes) were included in the analysis, and 182 (25.53%) of them developed newly DR after 2 years. Both pRNFL thickness and pCT showed significant thinning over time ( $P < 0.001$ ), with reduction rates varying with quadrants. Absolute and percent average reduction rates of pRNFL thickness were faster for patients with than without incident DR ( $-1.652 \pm 0.137$  vs  $-1.067 \pm 0.182 \mu\text{m}$ ,  $P = 0.001$ ;  $-1.414 \pm 0.107\%$  vs  $-0.790 \pm 0.173\%$ ,  $P = 0.022$ ; respectively); as were the absolute and percent average reduction rates of pCT ( $-9.560 \pm 1.086$  vs  $-4.976 \pm 0.669 \mu\text{m}$ ,  $P = 0.001$ ;  $-7.545 \pm 0.745\%$  vs  $-3.343 \pm 0.715\%$ ,  $P = 0.001$ ; respectively). The multivariate linear mixed model confirmed the faster average percent reduction rate of pRNFL thickness ( $-0.678[-1.304, -0.053]$ ,  $P = 0.033$ ) and faster average absolute and percent reduction rates of pCT ( $-3.347[-5.651, -1.044]$ ,  $P = 0.004$ ;  $-3.341[-5.779, -0.903]$ ,  $P = 0.007$ ; respectively) over time in DR subjects.

**Conclusion:** The rate of pRNFL and pCT thinning was greater in T2DM subjects who would develop DR in future 2 years. Longer follow-up is needed to determine whether monitoring the rate of pRNFL and pCT change has a role in DR management.



PP-574

### Prevalence of Asthenopia in The High School Students Population during e-Learning in Pandemic Covid-19

C Kuswidyati<sup>1</sup>, T Tania, K Etania.

<sup>1</sup>Department of Ophthalmology, School of Medicine and Health Sciences Atma Jaya Catholic University of Indonesia, Jakarta, Indonesia

**Objective:** This study aimed to determine the prevalence and various levels of asthenopia among high school students during e-learning period in the pandemic Covid-19.

**Methods:** The online questionnaire consists of demographic data, total duration of digital use, and asthenopia symptoms filled by the students. The symptoms were described by ten questions related to asthenopia that needed to be responded to using a scale of 0 – 6, with 0 defined as none and 6 as most severe.

**Results:** Five hundred and fifty-four students responded to the questionnaire. This study involved 248 males (44.6%) and 306 females (55.2%) with a mean age was  $15 \pm 0.08$  years. The mean duration of digital use was  $9.9 \pm 0.27$  hours, 428 students (77.2%) use digital devices for 8 or more hours per day. 367 students (66.2%) use eyeglasses. Prevalence of asthenopia is 95.8% (n = 531) and 4.2% (n = 23) with no asthenopia. Of these 66.4% were mild, 27.1% were moderate and 2.3% were severe grades. The highest score for asthenopia symptoms were tired eyes and blurred vision. There was a correlation between the duration of digital use and asthenopia as well as a glasses wearer.

**Conclusion:** There was a high prevalence of asthenopia among students during e-learning period and the common symptoms were tired eyes and blurred vision. Most students use digital devices for 8 or more hours per day. More than half of the participants are glasses wearers. This study revealed that asthenopia correlates with the duration of digital use and the glasses wearer.

PP-576

### Prevalence of dry eye symptoms and risk factors in Saudi Arabia

A Al-Amri<sup>1</sup>, B Asiri<sup>1</sup>, T Alotibi, S Alkorbi, A Alqahtani, A Alahmari.

<sup>1</sup>College of medicine, King Khalid University, Abha, Saudi Arabia

**Objective:** Background: Dry eye is a multifactorial condition of the tears and ocular surface that causes discomfort, visual disruption, and tear film instability, as well as the risk for ocular surface injury. It is accompanied by an increase in the osmolality of the tear film as well as ocular surface inflammation. Dry eye is a prevalent ocular disease that leads to ophthalmologist appointments. The prevalence of the disease varies greatly between epidemiological studies, depending on how the sickness is characterised and diagnosed, as well as depending on the sector of the population surveyed. It is expected to be between 7.4% and 33.7 percent

**Methods:** A descriptive cross-sectional survey was used targeting all groups of population in Aseer region. The study was conducted during 2021. Data was collected using structured questionnaire which included person's socio-demographic data, and the OSDI (ocular surface disease index) combined with questions relevant to the target of our research ((the repetitive habitual/behavioral factors leading to Dry eye disease (DED)), and also using SAS-SV (smartphone addiction scale) in the context of users of smart phones.

**Results:** Out of 2,527 total respondents, 694 (27.5%) have no issues related to eyes, while 1,833 (62.5%) have eye related issues. The mean (SD) of age was 29.4 (8.9) years. 67.0% were females while 33.0% were males. 22.9 % were exposed to air conditioners, 22.9% used contact lenses, 7.36 % used lubricant drops, while 6.3% live in a dry weather area

**Conclusion:** Dry eye illness is a prevalent ophthalmological condition with a number of clinical predictors, including the use of electronic devices and other risk factors. Teachers and health professionals should teach the students and nation about the awareness of dry eye problems.

**PP-577****Quarantine myopic progression in school children after COVID-19 home confinement.**J Jethani, P Dave, A Porwal.

**Objective:** Outdoor activities are known to have protective effect on myopic progression. Due to the lockdown and home confinement after COVID-19 pandemic, the effect of this is unknown on myopic progression in children of school going age.

**Methods: Materials and methods**

All children between the age group of 6-12 years were included in the study. Cycloplegic refraction, axial length, corneal curvature and ocular parameters were measured and compared. These children were reviewed every 6 months and were not on any treatment for prevention of myopic progression.

**Results:** A total of 36 eyes of 36 children were included in the study. Twenty four were male and 12 were females. The mean age was 8.7 +/- 2.2 years. The median progression in myopia per year prior to lockdown (2019-20) was -0.75 D (interquartile range -0.5 D to -0.75D) and post lockdown (2020-21) was -1.25 D (interquartile range -1.0 D to -1.25 D).

The median progression in axial length per year prior to lockdown between 2019-2020 was 0.24 mm (interquartile range 0.15 mm to 0.37 mm) and post lockdown (2020-21) the median was 0.63 mm (interquartile range 0.54 mm to 0.78 mm).

**Conclusion:** The lockdown in COVID-19 pandemic has given a sharp rise in the myopic progression of children in one year.

PP-579

## 25-Year Trends in the Incidence and Epidemiology of Conjunctival Squamous Cell Carcinoma in South Africa (1994–2018)

A Lombard<sup>1</sup>, D Shepherd<sup>2</sup>, R Höllhumer<sup>3</sup>, K Stuart<sup>4</sup>, M Muchengeti<sup>5,6</sup>.

<sup>1</sup>*Division of Ophthalmology, Faculty of Neurosciences, University of the Witwatersrand, Johannesburg, South Africa,*

<sup>2</sup>*Department of Oral and Maxillofacial Surgery, Northwick Park Hospital, London North West University Healthcare NHS Trust, London, United Kingdom,*

<sup>3</sup>*Division of Ophthalmology, Faculty of Neurosciences, University of the Witwatersrand, Johannesburg, South Africa, and,*

*The Cornea Foundation, Johannesburg, South Africa,* <sup>4</sup>*NIHR Biomedical Research Centre, Moorfields Eye Hospital NHS Foundation Trust and UCL Institute of Ophthalmology,*

*London, United Kingdom,* <sup>5</sup>*National Health Laboratory Service, National Cancer Registry,* <sup>6</sup>*School of Public Health, University of the Witwatersrand, Division of Epidemiology and Biostatistics, Johannesburg, South Africa*

**Objective:** To describe the incidence and demographic features of conjunctival squamous cell carcinoma (CSCC) in South Africa (SA) over a 25-year period (1994–2018).

**Methods:** Incident cases of histologically diagnosed CSCC were identified from the South African National Cancer Registry (NCR), a nationwide pathology-based database. Crude and direct age-standardised incidence rates (ASIR) per 100 000 (Segi World Standard Population) were calculated using national population statistics and compared by age, sex and population group. Trends in the incidence and demographic features of CSCC were described and analysed. Incidence rates were compared to national HIV-related statistics for the same time period.

**Results:** Between 1994 and 2018, 9016 cases of CSCC were reported to the NCR, with a mean age at diagnosis of 41.5 years and a predominance of female (n=5 105, 56.6%) and Black (n=7 823, 86.8%) individuals. The overall ASIR was 0.78, with sex-specific rates of 0.82 and 0.75 for females and males, respectively (relative risk, 1.10; 95% confidence interval, 1.06–1.14). Two distinct epidemiological patterns were identified: 1) older White males and 2) younger Black females, with consistently higher rates observed in the latter. Trend analysis revealed significant changes in both the incidence and epidemiology of CSCC over the study period. Before 2000 the mean ASIR was 0.25, with a predominance of the first epidemiological profile. Thereafter, there was an increase to an ASIR of 1.32 in 2010, representing a >5-fold increase in the incidence of CSCC over a single decade, accompanied by a dramatic shift towards the second epidemiological profile. By 2018, the ASIR had declined to 0.56, with a corresponding reversal in the demographic trends. The annual CSCC incidence rate was highly correlated (Pearson correlation coefficient,  $r = 0.98$ ) with the annual AIDS-related mortality rate in SA, with an apparent lag period of 4 years.

**Conclusion:** This study highlights the evolving trends and disease burden of CSCC in SA. There have been significant changes in the incidence and epidemiology of CSCC over the study period, which correlate with similar trends in the HIV/AIDS epidemic. This finding is in keeping with trends for other HIV-related cancers. This has

important implications for future incidence studies and public health policy. The description of CSCC as a disease of older, White males is outdated in SA, with large numbers of Black individuals, especially young Black females, affected by CSCC.

PP-580

## Multinational Patient Experience with Anti-VEGF Therapy in Neovascular Age-Related Macular Degeneration and Diabetic Macular Edema

A García-Layana<sup>1</sup>, A Giocanti-Aurégan<sup>2,3</sup>, N Holekamp<sup>4</sup>, T Jackson<sup>5,6</sup>, P Kertes<sup>7</sup>, F Viola<sup>8,9</sup>, G Chi<sup>10</sup>, M Mirt<sup>11</sup>, V Barbier<sup>12</sup>, H Lewis<sup>13</sup>, A De Palma<sup>14</sup>, B Gentile<sup>10</sup>.

<sup>1</sup>Clínica Universidad de Navarra, University of Navarra, Pamplona, Spain, <sup>2</sup>Ophthalmology Department, Avicenne Hospital, <sup>3</sup>University Sorbonne, Paris Nord Bobigny, France, <sup>4</sup>Pepose Vision Institute, Chesterfield, MO, United States, <sup>5</sup>Faculty of Life Sciences and Medicine, King's College London, <sup>6</sup>King's College Hospital, London, United Kingdom, <sup>7</sup>Department of Ophthalmology and Vision Sciences, Sunnybrook Health Sciences Centre, Toronto, ON, Canada, <sup>8</sup>Ophthalmological Unit, Fondazione IRCCS Ca' Granda Ospedale Maggiore Policlinico, <sup>9</sup>Department of Clinical Sciences and Community Health, University of Milan, Milan, Italy, <sup>10</sup>Genentech, Inc., South San Francisco, CA, United States, <sup>11</sup>F. Hoffmann-La Roche Ltd., Basel, Switzerland, <sup>12</sup>Patient-Centred Outcomes, ICON plc, Lyon, France, <sup>13</sup>Global Health Economics, Outcomes Research and Epidemiology, ICON plc, Reading, United Kingdom, <sup>14</sup>Global Health Economics, Outcomes Research and Epidemiology, ICON plc, Rome, Italy

**Objective:** Anti-vascular endothelial growth factor (VEGF) therapy is efficacious for neovascular age-related macular degeneration (nAMD) and diabetic macular edema (DME), but optimal real-world outcomes require frequent treatment and monitoring that can be burdensome to patients and hinder their ability or willingness to follow a management plan. This study aimed to understand patient treatment experience with anti-VEGF standard of care.

**Methods:** This observational study employed a cross-sectional quantitative survey comprising de novo questions, patient-reported outcome (PRO) measures and medical chart extraction. Adult patients with nAMD or DME, treated with anti-VEGF injections for  $\geq 12$  months, were recruited via 32 clinical sites (6 Canada, 4 Italy, 7 Spain, 6 UK, 9 USA).

**Results:** Surveys were completed by 288 patients with nAMD (67 Canada, 16 Italy, 53 Spain, 54 UK, 98 USA) and 179 patients with DME (48 Canada, 15 Italy, 16 Spain, 33 UK, 67 USA) between January and August 2021. PRO scores indicated that patients across both conditions had relatively high vision-related functioning (National Eye Institute Visual Function Questionnaire-25) and were satisfied with their current treatment (Macular Disease and Retinopathy Treatment Satisfaction Questionnaires). Mean anti-VEGF injections over 12 months ranged from 6.3 (UK) to 9.7 (Canada) for nAMD and 4.3 (Italy) to 8.0 (Canada) for DME. Twelve patients with nAMD (n=12/265; Canada, n=3; Italy, n=0; Spain, n=3; UK, n=3; USA, n=3) and 22 patients with DME (n=22/155; Canada, n=1; Italy, n=2; Spain, n=2; UK, n=9; USA, n=8) missed  $\geq 1$  injection in the past 12 months. Reported barriers were mainly related to treatment (eg, pain, injection fear, lack of understanding) and appointment factors (eg, visit waiting time, ability to book appointments) and the COVID-19 pandemic. Impairment in daily activities due to treatment was reported by 205/467 (44%) patients. After treatment, the majority recovered within  $\leq 1$  day; however, 25% needed  $> 1$  day to

recover (n=116; Canada, n=25; Italy, n=12; Spain, n=17; UK, n=27; USA, n=35). Among the working patients (n=63), 40 (63%; Canada, n=11; Italy, n=4; Spain, n=2; UK, n=8; USA, n=15) reported productivity impairment from absenteeism.

**Conclusion:** Despite high adherence and treatment satisfaction levels, patients reported impairment of daily activities, burden and barriers related to treatment. Longer-acting agents requiring less frequent treatment may be able to mitigate treatment-related burden and barriers.

PP-581

## Visual Health Survey And Early Warning System Development for Myopia Monitoring in School Children: Zhuozhou Childhood Eye Health

M Yusufu<sup>1,2</sup>, Y Liu<sup>3,4</sup>, K Cao<sup>1,2</sup>, Z Yang<sup>4</sup>, M Kang<sup>3</sup>.

<sup>1</sup> University of Melbourne, <sup>2</sup> Centre for Eye Research Australia, Melbourne, Australia, <sup>3</sup> Beijing Tongren Hospital, Beijing, <sup>4</sup> Zhuozhou Liming Eye Hospital, Zhuozhou, People's Republic of China

**Objective:** To report on the myopia prevalence among school students in Zhuozhou City in 2019 and explore the necessity to establish an early warning system for adolescents and children with increased visual health risk so as to provide the needed examination and ensure timely intervention.

**Methods:** Zhuozhou Childhood Eye Health Survey is a cohort study initiated in 2019 among school students in Zhuozhou City, Hebei province, and the survey was designed to be carried out annually. The baseline survey was conducted from June to August 2019 among 72575 students, in which the participants underwent visual acuity test and refraction examination (autorefractometry without cycloplegia). The uncorrected visual acuity (UCVA), spherical power, and cylindrical power were recorded. Myopia was defined as equivalent spherical refraction of less than or equal to -0.75 diopter (D). The early warning system was established to create a visual health record for school children with increased visual health risks (UCVA<0.8) and the risk was classified into 3 grades: grade I ( $20/40 \leq \text{UCVA} < 20/25$ ), grade II ( $20/67 \leq \text{UCVA} < 20/40$ ), and grade III ( $\text{UCVA} < 20/67$ ).

**Results:** A total of 63200 participants with complete visual examination data and aged 6-15 were included in the final analysis, including 32951 males and 30249 females, with a mean age of  $10.29 \pm 2.79$ . The prevalence of myopia in 6 to 15 years old students was 20.61%, 23.77%, 32.57%, 41.99%, 53.84%, 61.92%, 68.53%, 73.07%, 78.20% and 82.89% (49.70% in males vs. 54.71% in females,  $P < 0.001$ ). The prevalence of myopia was 26.06%, 56.60%, and 77.93% in the 6-8, 9-12, and 13-15 years old groups, with a mean UCVA of  $5.00 \pm 0.13$ ,  $4.85 \pm 0.29$ , and  $4.61 \pm 0.41$ . The proportion of school children with grade I risk was 4.51% and 10.98% in the 6-8 and 9-12 years old groups, and the proportion was 1.68% and 10.51% for grade II and 0.85% and 11.53% for grade III. For 13-15 years old group, over 60% had increased visual health risk: 10.94% for grade I with mild myopia and mild hyperopia as main causes, 14.59% for grade II with moderate myopia as the major cause, and 35.83% for grade III with mainly due to high myopia.

**Conclusion:** UCVA among students dropped rapidly with age, with about 80% of secondary school students being myopic. Over 1/3 of secondary school students had a grade III visual health risk, indicating the urgent need of establishing an early warning system and creating visual health records at an earlier stage for eye health monitoring and timely prevention.



PP-583

## SIGHT RESTORATION PROJECT AMONG INTERNALLY DISPLACED PERSONS (IDP) IN DALORI CAMP, BORNO STATE, North East Nigeria JANUARY 2016

A Akinfe.

**Objective:** To restore sight among the IDPs with operable cataracts in Dalori IDPs Camp in Borno state North East Nigeria. To screen and treat cases of allergic/vernal conjunctivitis among the internally displaced children in Dalori IDPs Camp in Borno State.

**Methods:** A descriptive study comprising of IDPs who were mainly from Kanuri, Shua Arabs, Hausa Fulani tribe had since been booked in the Nigeria Airforce Emergency Hospital (fig 1) located in the IDP camp for small incision cataract surgery with posterior chamber intraocular lens implantation. The outcome of the procedure was analyzed. The patients with operable cataracts were counseled about the small incision cataract surgical procedure with posterior chamber intraocular lens implantation (fig 2). All patients had routine pre-operative investigations (Biometry, full blood count, fasting blood sugar, retroviral screening, and urinalysis) and preoperative vital signs (blood pressure/pulse rate) were evaluated.

Informed consent was obtained and all patients were screened for explosives/IUDs by security operatives. They all underwent small incision cataract surgery with posterior chamber intraocular lens implantation and were reviewed on the first day post-operatively. All post-operative medications were instilled as at when due, initially by the nurses for 2 days. Patients were discharged back to their camps after 2 days.

### Results:

A total of 18 patients underwent surgery and all of them were above 49 years of age. There were 15 male patients (83.3%). All patients had preoperative visual acuity  $>6/60$ . On the first day post-op three (16.7%) patients had visual acuity  $\leq 6/60$ , four (22.2%) patients had visual acuity between  $6/60 - 6/18$ , and 11 (61.1%) patients had visual acuity  $> 6/18$ . As at one week post-operatively, the visual acuity of 14 (77.8%) patients had improved to  $6/18$  or better. In all, 17 (94.4%) patients experienced improvement in vision within 1 week after the procedure.

[MOU1]Please confirm if this is correct.

**Conclusion:** Most of the cases done had good vision after small incision cataract surgery<sup>2</sup> with profound excitement and gratitude to the entire team especially the great and gallant soldiers and officers of the Nigerian Air Force.

The phase 1 project is a tremendous success in preparing the internally displaced persons who can now see to return to their various settlements across the insurgency ravaged areas<sup>3</sup>

PP-584

**Sir WILLIAM BOWMAN, a Pioneer in Anatomy, Pathology and Ophthalmic Surgery**

G Balanikas<sup>1</sup>, D Pirounides<sup>1</sup>, G Athanasopoulos<sup>2</sup>, V Athanasiadis<sup>1</sup>, P Ageladarakis<sup>1</sup>, A Koskosas<sup>1</sup>, V Karampatakis<sup>3</sup>, D Christodoulou<sup>4</sup>.

<sup>1</sup>A' Ophthalmologic Clinic, AHEPA Hospital, <sup>2</sup>C'Ophthalmologic Clinic, AHEPA Hospital, <sup>3</sup>Laboratory of Experimental Ophthalmology, Medical School, <sup>4</sup>Laboratory of History of Medicine, Medical School, Aristotle University, THESSALONIKI, Greece

**Objective:** Sir William Bowman (1816-1892) is well known for his discoveries in histology and pathologic anatomy. He was also a competent and inventive surgeon ophthalmologist. In this presentation, we describe his legacy to every field of Ophthalmology.

**Methods:** Sources for this presentation are the published works about every aspect of his engagement with this discipline and more in anatomy and pathology. The reference work, 'The Collected Papers of Sir William Bowman', is a valuable source of his contribution to Medicine. These essays include detailed descriptions of ophthalmic anatomy, pathology, and physiology. Some of his key works are: 'On the Structure and Use of the Malpighian Bodies of the Kidney,' he published the five-volume 'Physiological Anatomy and Physiology of Man (1843–1856) ' (with Robert Todd), and the Cyclopaedia of Anatomy and Physiology (1852).

**Results:** William Bowman had a long career in Medicine, starting very early with surgeon Joseph Hodgson (1788-1869) at Birmingham General Hospital in 1832 and continuing in King's College London with the professor of Physiology Robert Bentley Todd. Too early, at the age of 25, he became famous for his description of the 'nephron's capsule of kidneys, the well-known 'Bowman's capsule' and the corneal layer called later 'Bowman's membrane.' He presented his findings in 1842 in a paper to the Royal Society and was awarded the Royal Medal. He became a Surgeon ophthalmologist at the Royal London Ophthalmic Hospital (later known as Moorefield's Eye Hospital), inventing a number of surgical tools such as irrigation probes, the lid speculum, and more. He supported the wide use of the ophthalmoscope with enthusiasm.

**Conclusion:** Sir William Bowman was an inspired scientist of the 19th century who made significant discoveries in many fields of our science (Anatomy, Pathology, Surgery, and Ophthalmology). He reformed the current mode and thought of Modern Medicine. He taught at King's College and, in 1880, founded the 'Ophthalmological Society', which was named later 'The Royal College of Ophthalmologists.' His scientific integrity and knowledge, management of the patient, and compassion for the weak gave him prestige and universal recognition. He was a distinguished ophthalmic surgeon who made fundamental discoveries, applied innovative surgical techniques, and invented and designed new surgical instruments.

PP-585

**Detection of HIV-1 viral load in tears of HIV/AIDS patients**Y Qian, W Wei.

**Objective:** The tear, as an important bodily secretion, plays a crucial role in preventing infection and maintaining homeostasis of ocular surfaces. Although accumulating studies have reported on the HIV-1 viral load profile among varying bodily fluids and secretions, little was known concerning HIV-1 dynamics in tears. Therefore, the objectives of this study were to investigate the HIV-1 viral load in tears of HIV/AIDS patients and study factors influencing their tear viral load.

**Methods:** A cross-sectional study was conducted. 67 patients with a confirmed HIV-1 infection or AIDS were recruited from the Beijing You'an Hospital, China between April 2018 and September 2018. Socio-demographic information and laboratory test results were collected. At the same time, ophthalmic examinations were carried out and tear samples were tested.

**Results:** Of 30 highly active antiretroviral therapy (HAART)-naïve patients, 53.3% had detectable HIV-1 RNA in tears. Of 37 patients on HAART, HIV-1 RNA was undetectable in their tears, regardless of treatment duration and blood viral load. Tear viral load ranged from TND (target not detected) to 13,096 copies/mL. Viral load was lower in tears than in blood plasma ( $p<0.001$ ), and was significantly correlated with plasma viral load ( $Rho=0.566$ ,  $p<0.001$ ) and AIDS stage ( $Rho=0.312$ ,  $p=0.01$ ), but negatively correlated with CD4+T cell count, CD4+/CD8+T cell count, and duration of HIV infection ( $Rho=-0.450$ ,  $Rho= 0.464$ ,  $Rho= 0.565$ ;  $p<0.001$ ).

**Conclusion:** HIV-1 RNA is present in tears of more than half of the HAART-naïve patients, whereas absent in tears of patients on HAART. Tear viral load is positively associated with plasma viral load while it is negatively correlated with CD4 cell count. This study provides novel insights into the area with limited understanding—HIV-1 viral load in tears.

PP-586

## Sensitivity of the Clinical Strains Isolated from the Patients with Combined Combat Eye Trauma to Antibiotics and Antiseptics

H Nazarchuk<sup>1</sup>, O Nazarchuk<sup>2,3</sup>, V Nahaichuk<sup>4,5</sup>, Y Babina<sup>2</sup>, V Bebyk<sup>2</sup>.

<sup>1</sup>Ophthalmology Department, <sup>2</sup>Microbiology Department, National Pirogov Memorial Medical University, Vinnytsya, <sup>3</sup>Tertiary Clinical Center for Thermal Injury and Plastic Surgery, MNPE "Vinnytsya Regional Clinical Hospital Vinnytsya Regional Council", <sup>4</sup>National Pirogov Memorial Medical University, Vinnytsya, <sup>5</sup>Tertiary Clinical Center for Thermal Injury and Plastic Surgery, MNPE "Vinnytsya Regional Clinical Hospital Vinnytsya Regional Council", Vinnytsya, Ukraine

**Objective:** Combat trauma is characterized by particularly complex including combination of traumatic agents, affection of different anatomical structures and infectious complications that are the results of the complex injury, possible delay of the first aid, long period of hospitalization, which creates an increased risk of medical care associated infections. **The objective** of the study was to investigate the etiologic structure of the eye infectious complications and sensitivity of the clinical strains isolated from the patients with combined combat eye trauma to antibiotics and antiseptics.

**Methods:** In vitro study of the sensitivity of the pathogens, received from the 24 patients with combat wounds and burns of the soft tissues of the face and ocular surface, to antibiotics and anesthetics was performed using the standard method of serial dilutions (Clinical and Laboratory Standards Institute, CLSI).

**Results:** 22 clinical strains (S.aureus 7, S.epidermidis 7, E.faecalis 1, A.baumannii 2, K.pneumonia 2, P.aeruginosa 3) were isolated from the ocular surface of the patients. S.aureus and S.epidermidis were resistant to penicillins and macrolides, sensitive to aminoglycosides. E.faecalis possessed high resistant properties to flouroquinolones, aminoglycosides. A.baumannii were resistant to all antimicrobial agents except polymyxin, cefoperazone-sulbactam. P.aeruginosa were sensitive only to polymyxin, ceftazidim-avibactam. K.pneumonia were sensitive only to tobramycin. All strains were sensitive to local antiseptics (povidone-iodine, chlorhexidine, decametoxin).

**Conclusion:** High resistant to antibiotics clinical strains that caused infections of the eye surface after combat trauma were sensitive to local antiseptics that creates the opportunity to increase effectiveness of treatment and prevention of the infectious complications.

**PP-587****A comparative study of the pre-corneal tear film and conjunctival impression cytology in diabetics and non diabetics**

R Kotian<sup>1</sup>, S Shetty S.B<sup>1</sup>, D Dabir Sundaresh<sup>1</sup>, M Gouri S.R<sup>2</sup>.

<sup>1</sup>Ophthalmology, <sup>2</sup>Pathology, M S Ramaiah Medical College Hospital, Bangalore, India

**Objective:** To compare the precorneal tear film and conjunctival impression cytology in individuals with type 2 Diabetes mellitus and without type 2 Diabetes mellitus.

**Methods:** Seventy two individuals attending the OPD of Dept of Ophthalmology were enrolled in the study . The enrolled individuals are divided in two groups , ( group A) non diabetics and ( group B) diabetics.They underwent complete ophthalmological examination including tear film break up test ( TBUT),schirmer's test,dye tests( fluorescein,lissamine dye test) and conjunctival impression cytology.The results were compared between the two groups.

**Results:** In this study there is a positive correlation noted between ocular surface disease and increasing age.The the mean TBUT values in group A and group B were 21.81 +/- 7.159s and 13.66 +/- 8.02s respectively with a p value of 0.001.Schirmer's test also showed a significant difference (p <0.001) in the two groups,with group A 23.00 +/- 6.43 mm and group B 17.22 +/- 9.002 mm .Ocular surface staining in the two groups showed a significant difference as well.Conjunctival impression cytology showed a marked degree of squamous cell metaplasia and loss in goblet cell density In Group B,with a mean goblet cell density of 83 +/- 19 cells/ mm<sup>2</sup> in group B and 143 +/- 19 cells/mm<sup>2</sup> in group A, which was found to be statistically significant ( p<0.001) .The nelson grade in group A was – 70% grade 0, 25 % grade 1, 5% grade 2, nil in grade 3; Group B nelson score was – 34% grade 0, 12% grade 1, 40 % grade 2, 14 % with grade 3;

**Conclusion:** The study showed a positive correlation between dry eye and diabetes, increasing age, duration of diabetes, and grade of retinopathy as well. Dry eye and its symptoms can progress and lead to visual impairment if adequate measures are not adopted in time. Although rare, it needs special consideration by ophthalmologists since it is preventable if detected early. Screening of all diabetic patients for signs of tear film dysfunction or ocular surface disorders is important to recognize and appropriately manage before progression to permanent ocular surface changes occurs. Thus the tear film function and ocular surface evaluation should be included in the routine examination protocol for all individuals with type 2 Diabetes Mellitus.

PP-588

**Beneficial Actions of Essential Fatty Acids in Streptozotocin-Induced Type 1 Diabetes Mellitus**J Shen, L Zhang<sup>1</sup>, Y Wang<sup>1</sup>, Z Chen<sup>1</sup>, J Ma<sup>1</sup>, X Fang<sup>1</sup>, U Das<sup>1</sup>, K Yao<sup>1</sup>.<sup>1</sup>Eye Center, Second Affiliated Hospital, School of Medicine, Zhejiang University, Hangzhou, People's Republic of China

**Objective:** The essential fatty acids (EFA) n3 alpha-linolenic acid (ALA) and n6 linoleic acid (LA) are of benefit in diabetes mellitus, but their mechanisms of action are unknown.

**Methods:** We therefore examined the effects of EFAs on the metabolism, gut microbiota, and inflammatory and retinal histopathology indices in streptozotocin (STZ)-induced type 1 diabetes mellitus (T1DM) animals, and we assessed the levels of vitreal lipoxin A4 (LXA4)—derived from LA—in subjects with diabetic retinopathy (DR). STZ-induced T1DM rats received LA or ALA 100 µg/day intraperitoneally on alternate days for 21 days, and their blood glucose; lipid profile; plasma, hepatic, and retinal fatty acid profiles (by gas chromatography); retinal histology; activities of hepatic and retinal desaturases; and inflammatory markers (by qRT-PCR) were evaluated. Gut microbiota composition was assayed by 16S rDNA sequencing technology of the fecal samples, and their short-chain fatty acids and bile acids were assayed by gas chromatography, liquid chromatography, coupled with tandem mass spectrometry, respectively. The human vitreal fatty acid profiles of subjects with proliferative DR and LXA4 levels were measured.

**Results:** LA and ALA significantly improved the plasma glucose and lipid levels; increased the abundance of *Ruminococcaceae* (ALA-treated group), *Alloprevotella*, *Prevotellaceae\_Ga6A1\_group*, *Ruminococcaceae\_UCG\_010*, and *Ruminococcus\_1* (LA-treated group) bacteria; enhanced acetate and butyrate levels; and augmented fecal and hepatic concentrations of cholic acid, chenodeoxycholic acid, and tauro ursodeoxycholic acid in ALA- and LA-treated animals. Significant STZ-induced decreases in plasma LA, gamma-linolenic acid, arachidonic acid, and ALA levels reverted to near normal following LA and ALA treatments. Significant changes in the expression of desaturases; COX-2, 5-LOX, and 12-LOX enzymes; and cytokines in T1DM were reverted to near normal by EFAs. DR subjects also had low retinal LXA4 levels.

**Conclusion:** The results of the present study show that ALA and LA are of significant benefit in reversing metabolism, gut microbiota, and inflammatory and retinal index changes seen in T1DM, suggesting that EFAs are of benefit in diabetes mellitus.

PP-590

**Fungal hyphae with IOLSCOPE Recognition Study (FIRST)**P Chandrakanth, H GOSALIA<sup>1</sup>.<sup>1</sup>DNB RESIDENT, ARAVIND EYE HOSPITAL, COIMBATORE, India

**Objective:** To compare Fungal hyphae morphology seen through simple microscope and an Frugal innovative community based point of care device, The IOLSCOPE (Smartphone based intraocular lens microscope)

**Methods:** IOLSCOPE is a do it yourself innovative frugal device made using 4 30D intraocular lens on a chart paper attached to the smartphone camera to take images and videos of microorganisms such as fungus. It can be made in less than 1\$. It can be literally be carried in your pocket and can be used as a point of care diagnostic tool. done in the Microbiology department of a tertiary eye hospital. cross sectional, hospital based, comparative study. Study included samples of corneal scrapping sent for the identification of fungal hyphae. The sample size (*n*) assuming 80% sensitivity, 5% allowable error, prevalence 15% was calculated as 35 patients. Inclusion criteria: Corneal scrapping sent to the microbiology lab for KOH mount and culture over a period of 3 months for identification of fungal hyphae and for culture on SDA medium/ blood agar. KOH mount was first subjected to the gold standard microscope, same sample was then subjected to the IOLSCOPE operated by another microbiologist to check for the presence of fungal hyphae. fungal culture is taken for confirmation.

**Results:** We included a total of 194 samples – 83 were diagnosed as fungal keratitis. male 51(61.49), females 32(38.55). The IOLSCOPE when compared to the simple microscope had 92% sensitivity (95% Confidence Interval (CI) : 89.2 – 100) and 100% specificity in diagnosing KOH mounted and 100% sensitivity and specificity in diagnosing LPCB mounted hyphae identification. Species identification was a challenge.

**Conclusion:** IOLSCOPE is a frugal innovative cost effective instrument which can be used as a screening device for diagnosing fungal keratitis. IOLSCOPE is a good alternative to conventional microscope, as it provides good quality images for diagnostic purposes. It has wide applications for use in peripheral centers, fields and camps and for teleconsultation during COVID times. It can be used as a point of care diagnostic tool anywhere anytime helping each one of us reach those areas of the world where medical assistance could not get in touch. It is a community screening tool which will help to improve the worlds mortality rate by helping early diagnosis and treatment.

PP-592

**m<sup>6</sup>A transferase METTL3 regulates endothelial-mesenchymal transition in diabetic retinopathy via lncRNA SNHG7/KHSRP/MKL1 axis**C Xin.

**Objective:** Diabetic retinopathy (DR) is one of the microvascular complications in diabetic patients and the leading cause of blindness worldwide. The m<sup>6</sup>A transferase METTL3 has been reported to play an important role in DR progression. However, the potential mechanisms of METTL3 in DR remain to be elucidated. Therefore, we investigated the function of METTL3 in endothelial-mesenchymal transition (EndoMT) during DR.

**Methods:** RT-qPCR or western blot assays determined the levels of METTL3, lncRNA SNHG7, KHSRP, MKL1, endothelial and mesenchymal markers in *vitro* and in *vivo*. SNHG7 and MKL1 mRNA stabilities were detected by RT-qPCR. RIP and RNA pull down assays confirmed the interaction between KHSRP and SNHG7 or MKL1. Immunofluorescence measured VE-Cadherin and SM22 expression. Subcellular fractionation and RNA FISH assays tested the expression and location of SNHG7. H&E staining was used to observe the retinal structure in a mouse model of DR.

**Results:** The expression levels of METTL3 and SNHG7 were significantly down-regulated in DR patients, DR mice and high glucose induced-HRMECs cells. Notably, METTL3 installed the m<sup>6</sup>A modification and enhanced the stability of SNHG7. Besides, METTL3 inhibited HRMECs EndoMT by promoting the expression of SNHG7. Additionally, SNHG7 was found to weaken MKL1 mRNA stability by binding to the RNA-binding protein KHSRP. Furthermore, we verified that METTL3 regulated EndoMT in DR through the SNHG7/MKL1 axis.

**Conclusion:** We concluded that METTL3 modulates endothelial-mesenchymal transition in DR via SNHG7/KHSRP/MKL1 axis, which provides new targets for DR treatment.



PP-595

**Traumatic Ocular Adnexal Injuries – Clinical Profile, Management & Functional along with Cosmetic Outcomes**G Damani<sup>1</sup>, N Nyati<sup>2</sup>, K Damani<sup>3</sup>, V Daga<sup>4</sup>.

<sup>1</sup>Department of Ophthalmology, Marble City Hospital, Kishangarh, Ajmer, Rajasthan, Kishangarh, <sup>2</sup>Department of Public Health Dentistry, Darshan Dental College & Hospital, Udaipur, <sup>3</sup>Department of Anesthesiology, Dr. Vithalrao Vikhe Patil Foundation Medical College & Hospital, Vilad Ghat, Ahmednagar, Maharashtra, <sup>4</sup>Department of Periodontics, Shri Sai College of Dental Surgery, Vikarabad, Hyderabad, India

**Objective:** Ocular trauma can result in wide spectrum of injuries with varying levels of severity affecting various ocular adnexal tissues. Ocular adnexal injuries can lead to severe ocular morbidity in terms of a cosmetic blemish, watering, a long healing period, severe complications, or permanent disfigurement. A retrospective study of 11 patients with ocular adnexal injuries involving 13 eyes with respect to their clinical features, management and functional along with cosmetic outcomes is presented here.

**Methods:** Records of all the 56 ophthalmic patients visiting the emergency department from May 2020 to March 2022 were scanned and 11 patients with ocular adnexal injuries involving 13 eyes presenting to the emergency department of Marble City Hospital, Kishangarh, Ajmer, Rajasthan, India were evaluated with respect to demographic details, mode of injury, type and sub-type of ocular injury.

**Results:** Ocular Adnexal trauma can affect all the ages (in our study range from 11 to 55 years). Varied presentations of ocular adnexal tissue injuries ranging from single to multiple adnexal tissue involvement were seen. This Included Eyebrows (23.07%, n=3), Eyelid (84.61%) – upper(n=8), lower(n=6), lateral Canthus (n=5), medial Canthus(n=2); Lacrimal System involvement (15.38%) - canalicular- upper(n=1), lower(n=1); Orbital involvement (15.38%) -Orbital compartment Syndrome (n=1), orbital fracture (n=1)and Intra orbital foreign body(n=1) & Optic Nerve involvement (7.6%) – Avulsion (n=1) were seen. Except for the optic nerve avulsion patient all had good visual outcome. All the patients had good cosmetic outcome except one patient with lower lid laceration involving canaliculus & medial canthus having developed notching of lid margin. But he is functionally fine with no epiphora till last follow up.

**Conclusion:** A complete ophthalmic examination is important to achieve a thorough evaluation and provide optimal management. Also Photographic documentation is a must for patient education, records and medicolegal issues. The ocular adnexa play a significant role in the protection of the globe via various mechanisms. It is observed that early intervention led to better results. It helped to prevent infection, and restoration of the integrity of the ocular adnexal structures led to a cosmetically preferable scar and better functional outcome.

**PP-596****The efficacy of gonioscopy-assisted transluminal trabeculotomy for the treatment of traumatic angle recession glaucoma**H Yujuan.

**Objective:** To evaluate the efficacy of gonioscopy-assisted transluminal trabeculotomy (GATT) with 5-0 polypropylene suture for the treatment of traumatic angle recession glaucoma.

**Methods:** This is a retrospective study. A total of 10 eyes of 10 patients with traumatic angle recession glaucoma underwent GATT from Nov. 2018 to Oct. 2020 in the Second People's Hospital of Foshan were studied. GATT were performed and visual acuity, intraocular pressure (IOP), anterior chamber angle and complications were observed.

**Results:** All patients aged from 32 to 54 years. The preoperative IOP was 28.0-56.2mmHg (1mmHg =0.133kPa) . The follow-up lasted for 7-30 months, and no severe complication happened. Visual acuity improved in 5 cases, decreased in 1 case. There were 7 cases with stable IOP. Three cases with high IOP after drugs controlled received Ahmed glaucoma valve implantation, Ex-PRESS drainage pin implantation, and trabeculectomy, respectively. The IOP of 9 patients was 9.6-18.5 mmHg.

**Conclusion:** GATT with 5-0 polypropylene suture is a safe and effective method for the treatment of traumatic angle recession glaucoma. The efficacy still needs more cases and longer observation time.

**PP-598****Application of CT-DCG-TPR-BTNC in the diagnosis and treatment of traumatic chronic dacryocystitis caused by middle facial fracture**X Zhou.

**Objective:** To explore the application of three-plane reconstruction of CT dacryocystography based on the trend of nasolacrimal canal (CT-DCG-TPR-BTNC) in the diagnosis and treatment of traumatic chronic dacryocystitis caused by mid-facial fracture

**Methods:** Medical data of 22 patients (22 eyes) with traumatic chronic dacryocystitis due to mid-face fracture admitted to the Senior Department of Ophthalmology, the Third medical center of PLA General Hospital from June 2019 to December 2021 were collected and analyzed. Three-plane reconstruction of CT dacryocystography based on the trend of nasolacrimal canal imaging signs of the mid-face fracture were analyzed

**Results:** All 22 patients underwent the CT-DCG-TPR-BTNC. There were 10 males and 12 females, aged between 6 and 53 ( $30.86 \pm 12.02$ ) years-old, diagnosed traumatic chronic dacryocystitis caused by mid-facial fracture. The main cause of injury was car accident (12/22, 54.5%), followed accidental fall (3/22, 13.6%), crashed injury (2/22, 9.1%), boxing injury (2/22, 9.1%), fall injury from high (2/22, 9.1%), steel nail wounded (1/22, 4.5%). All patients had mid-facial fractures and nasolacrimal duct fractures including nasal bone fracture (21/22, 95.5%), orbital fracture (19/22, 86.4%), maxillofacial fracture (12/22, 54.5%), concomitant laceration of medial canthus ligament (18/22, 81.8%), lacrimal sac injured (2/22, 9.1%) and atrophy (2/22, 9.1%), injury of optic nerve (4/22, 18.2%), eyeball rupture (2/22, 9.1%). All patients underwent external modified dacryocystorhinostomy, Cerebrospinal fluid rhinorrhea occurred during operation in 1 (4.5%) patient and was cured after symptomatic treatment. All dacryocystorhinostomies were combined with bicanalicular intubation, and the stent was removed from 3 to 6 months after surgery. No recurrence occurred after 3-6 months of follow-up.

**Conclusion:** Preoperative CT-DCG-TPR-BTNC should be used for evaluation to understand whether there is injury of adjacent tissues, especially bone injury and anatomical deformation, and to evaluate the degree of lacrimal fossa and nasolacrimal duct injury, which is of great significance for guiding the formulation of surgical plan.

PP-599

### Pupilloplasty in different scenarios

S Singh, S *singh*.

**Objective:** To restore the shape of pupil and anatomical structure of iris.

To improve the quality of vision.

To reduce the photic symptoms of patients like glare, diplopia, halos.

**Methods:** 15 different types of cases having iridodialysis, coloboma, traumatic mydriasis, iris defect and leukoma adherence were taken. Pre operatively visual acuity, slit lamp examination, fundus examination, biometry in case of cataract and B-scan ocular ultrasound was done.

Post- operative assessment of visual acuity and other symptoms like glare, diplopia, halos were evaluated

**Results:** 6 out of 15 patients had visual acuity between finger counting close to face to 6/60 preoperatively, 4 had visual acuity between 6/60 to 6/36 and 5 patients had visual acuity better than 6/36. 3 patient had complaint of glare and 2 patients had complaint of diplopia.

Post operative visual acuity in 9 out of 15 cases was between 6/12-6/6. In 3 patients visual acuity was between 6/18 – 6/12 and in rest 3 cases visual acuity was less than 6/18. Patients with glare also showed satisfactory decrease in his symptoms post surgery.

**Conclusion:** Patients reported reduce in the symptoms like glare, halos or diplopia post operatively and also showed significant improvement in the quality of vision.

**PP-601****Optical Coherence Tomographic Features of Retinal Damage caused by Intraocular Foreign Bodies and the Animal Model Study**

X Mai, H *Chen*.

**Objective:** To investigate the retinal optical coherence tomography (OCT) imaging characteristics in IOFB injury from clinical data analysis and verify the retinal phenotype by animal model study.

**Methods:** Clinical and imaging data review of IOFB patients from 2008 to 2020. The characteristics of OCT images as well as their relationships with BCVA and IOFB were analyzed. Pigmented rats (Brown Norway, BN) were used for modeling. The foreign body suspension was injected into eyes of BN rats by vitreous injection at the plana ciliary body. Fundus photography, OCT and fundus fluorescein angiography (FFA) were performed before and after modeling.

**Results:** Totally 231 eyes of 231 patients were included. There were 62 eyes with photoreceptor damage, which manifested as increased reflectivity at the outer nuclear layer (ONL) at the early stage and ellipsoid zone disruption with or without ONL atrophy at the late stage. There were 32 eyes with inner retina damage, which manifested as increased reflectivity of the inner retinal layers at an early stage and retinal inner layer atrophy at a late stage. These damages occurred only in the eyes with metallic IOFB injury, but not in the 16 eyes with non-metallic IOFB injury. In addition, eyes with retina damage had worse final BCVA compared to those without ( $p < 0.05$ ).  $2 \mu\text{mol}$  nano-level foreign body suspension ( $\text{Fe}^0$ :  $56 \mu\text{g}/2 \mu\text{l}$ ,  $\text{SiO}_2$ :  $60 \mu\text{g}/2 \mu\text{l}$ ) was injected into the vitreous cavity. The retinal outer layer was whitened near the iron powder deposit. OCT showed high reflection of the retinal outer layer in the early stage and atrophy of the same part in the late stage. The dispersion of foreign body suspensions was more likely to cause the inner retina damage. Fundus photography showed curvature and thinning of retinal vessels, OCT showed the increased reflectivity of the inner retinal layers, and FFA showed significant delay in retinal vascular perfusion. No similar phenomenon was observed in the eyes injected with the glass powder.

**Conclusion:** IOFBs can cause photoreceptor damage and inner retinal damage, which are associated with worse visual outcomes. These damages are likely caused by metallic toxicity. The IOFB animal model study confirmed the above clinical phenotype.

**PP-602****Magnetized forceps for intraocular foreign body removal: Comparison of different disposable forceps.**

J Werner<sup>1</sup>, A Wolf<sup>1</sup>, M Parlak<sup>1</sup>.

<sup>1</sup>*Department of Ophthalmology, Ulm University Medical School, Ulm, Germany*

**Objective:** Disposable forceps for intraocular surgery can be magnetized and used for the removal of intraocular foreign bodies (IOFB). The advantage is the combination of atraumatic attraction of the foreign body by magnetic force and safe removal of the foreign body from the eye with the forceps. This study investigates how strongly different forceps can be magnetized and which forceps are particularly suitable for magnetic grasping of metallic IOFB.

**Methods:** The different forceps were mounted on a microcontroller-directed linear guide and reproducibly guided and magnetized by an electromagnet for ophthalmic surgery (Oculus, Germany). The magnetic flux density at the tip of the forceps was measured before and after magnetization. Subsequently, the weight that the respective forceps can hold was tested. For this purpose, steel balls with ascending weight were placed in balanced salt solution (BSS) and it was checked whether the balls could be attracted by the forceps and guided through the BSS.

Following forceps were tested: Alcon Grieshaber Revolution DSP ILM Forceps 23G (1) and 25G (2) and Serrated Forceps 20G (3), 23G (4), 25G (5); Synergetics Pinnacle 360° Eckardt 23G (6), DORC Eckardt 23G (7), Vitreq Eckardt 27G forceps (8).

**Results:** Before magnetization, all forceps were practically non-magnetic, the smallest available steel ball with 13.74 mg could not be lifted in BSS. Magnetization increased the magnetic flux density at the tip of the forceps by 7.12, 6.43, 4.39, 3.62, 2.40, 4.35, 5.75, and 2.65 mT of forceps 1-8, respectively. The forceps were able to lift steel balls weighing 87.43, 87.43, 63.78, 13.74, 13.74, 16.37, 32.54 mg in BSS. Forceps 8 was unable to lift any steel ball.

**Conclusion:** The measurement of magnetic flux density and the mass that can be lifted with such magnetized forceps show good agreement and make the results plausible. The strength of the magnetic flux density that can be generated depends on two factors: First, on the strength of the forceps, i.e., the more magnetizable mass is present, the stronger the resulting magnetic flux density. However, the comparison of the Alcon forceps (ILM forceps vs Serrated forceps) shows that there are also other factors that influence the magnetizability. This could be, for example, the alloy, but also the structure of the stainless steel. Consequently, not every forceps can be magnetized equally well. It may be necessary to test in advance whether the available forceps are sufficiently magnetizable to magnetically lift IOFB.

**PP-604****Trauma associated factors with poor visual outcomes in post-surgical removal of posterior segment IOFB in a low-resource setting**

R Jule.

**Objective:** To identify predictive factors for visual outcomes in post-surgical removal of posterior segment intraocular foreign bodies.

**Methods:** Retrospective chart review of 22 eyes were included. Patients underwent surgical removal of intraocular between January 2018 to April 2020 foreign body from at National Unit of Ophthalmology, Guatemala City. Patients with known history of previous ocular injury, optic disc anomalies, signs of any previous retinopathy were excluded. Clinical characteristics included visual acuity, age, sex, and time from trauma to treatment. In addition, trauma associated variables were size of intraocular foreign body (IOFB), entry site, lesions in anterior and posterior segments. We then retrospectively used the ocular trauma score (OTS) as a predictor of visual outcome. Poor visual outcome was defined as best corrected visual acuity less than 20/200 after surgical removal. Analyses were done using SPSS.

**Results:** Mean (SD) age at presentation was 31.7 (14.09) years old and most were male (95%). Mean time to surgery since trauma was 12.21 hours (8.56 SD) and mean follow-up was 21 (2.2) weeks after surgery. Nearly half of injuries (41%) occurred during unprotected work-related activities (metal was the most common IOFB). Most of eyes had a corneoscleral injury as entry site with formation of traumatic cataract and during the first evaluation, Light Perception visual acuity was documented in more than half (57%) the eyes studied. Larger size IOFB bodies were associated with poor prognosis as with low visual acuity on admission. Predictions of visual outcomes using the OTS correlate with statistical significance the visual outcome on post-surgical removed posterior segment IOFB. Larger size IOFB bodies were associated with poor prognosis as with low visual acuity on admission.

**Conclusion:** According to our findings, the OTS could be a useful tool to predict poor outcomes after IOFB trauma in a low-resource setting like Guatemala. Corneoscleral site of entry, large IOFB and retinal tears were all associated with poor outcomes. The OTS should be implemented upon admission of all eye trauma patients in order to predict poor outcomes.

PP-605

**Demographic and Clinical Profile of Ocular Trauma in Major Trauma Cases in Tertiary Care Centre, Kurnool, Andhra Pradesh, India**S Bihani<sup>1</sup>, K Revathy, B Latha.<sup>1</sup>*ophthalmology, kurnool medical college, Kurnool, India*

**Objective:** To evaluate demographic profile and clinical presentations of ocular trauma in major trauma cases presenting to Government General Hospital, Kurnool, India from July 2021 to March 2022. Visual acuity before and after treatment is also evaluated.

**Methods:** The retrospective study was conducted to analyse 330 patients (500 eyes) who presented to Government General Hospital with ocular injuries due to major trauma during July 2021 to March 2022. The data on incidence of ocular injuries, mode of injury, clinical presentations, visual acuity before and after treatment is reviewed. Statistical analysis was carried out using Epiinfo software.

**Results:** 500 affected eyes of 330 patients were reviewed. Incidence of injuries was higher in males (n= 256, 77.5%) compared to females (n=74, 22.42%). Mean age of these patients was 32.2 years. Most common mode of injury in males is Road Traffic Accidents (50.78%), and females is assault (52.70%) (p value = 0.000). Overall RTA is most common mode of injury (44.8%), followed by assault (22.72%), outdoor injuries (13.03%), work related injuries (6.66%) and others (12.7%). Patients presented with Open Globe Injuries, Closed Globe Injuries, and Combined Injuries. 79.4% eyes (n=397) presented with multiple presentations. Most common clinical presentation is periorbital edema (n=312 eyes, 62.4%), followed by SCH (n= 241 eyes, 48.2%), eyelid contusion, eyelid laceration. Globe rupture seen in 18 eyes and traumatic optic neuropathy in 06 eyes. 39.2% eyes had vision better than 6/12 on initial presentation, and 50.4% eyes achieved better than 6/12 vision after treatment (p value= 0.000093). Patients with globe rupture, traumatic optic neuropathy and corneal tear had poor visual improvement.

**Conclusion:** This study shows RTA to be the most common cause of trauma, with more incidence in males compared to females. Most common mode of trauma in females is assault. Initial visual acuity correlated with final visual acuity.

Stringent traffic rules and public health education can help prevent ocular injuries. Immediate and comprehensive medical care is essential for care of trauma patients



PP-607

**Effects of Rigid Gas-Permeable Contact Lenses in Children with Ocular Trauma**

X Zhang<sup>1</sup>, X Yang<sup>2</sup>, Z Zhai<sup>2</sup>, H Wang<sup>2</sup>, B Fang<sup>2</sup>.

<sup>1</sup>Guangzhou Aier Eye Hospital, Jinan University, <sup>2</sup>State Key Laboratory of Ophthalmology, Zhongshan Ophthalmic Center, Sun Yat-sen University, Guangzhou, People's Republic of China

**Objective:** This study aims to investigate the effectiveness, safety and tolerance of rigid gas-permeable contact lenses (RGP CLs) in the visual rehabilitation of children following ocular injuries.

**Methods:** A retrospective study was performed on 17 children (17 eyes) after surgery for ocular trauma between 2019 and 2021. Demographic data, ocular surgery procedure, location of the corneal scar and the status of the lens were documented. Keratometric values, visual outcomes, RGP CLs fitting characteristics, adverse events and drop out reasons were analyzed.

**Results:** The median age was 5.0 years (interquartile range [IQR], 3.0-8.50 years) and 13 patients (76.47%) were males. All eyes had undergone surgery following ocular trauma were fitted with RGP CLs. Of the 17 children, 12 were aphakic (70.59%). The mean best-corrected visual acuity with spectacles (SVA) and RGP CLs (CLVA) was  $0.68 \pm 0.47$  and  $0.46 \pm 0.45$  (logMAR,  $P < 0.001$ ), respectively. The mean base curve (BC) and diameter of RGP CLs was  $7.90 \pm 0.30$  mm and  $9.81 \pm 0.53$  mm. The mean duration of RGP was  $12.27 \pm 9.06$  months. None of the eyes experienced corneal infection. At the end of the follow-up there were 11 eyes (64.71%) still using RGP CLs. The final CLVA of these 11 traumatized eyes was significantly increased ( $0.36 \pm 0.47$ ,  $P = 0.006$ ). The reasons for dropping out RGP were intervening surgical procedures, loss of patient motivation and uncomfortable fit.

**Conclusion:** RGP CLs provide an effective and safe alternative method for visual rehabilitation in children with ocular trauma. The large diameter of RGP CLs and therefore overall stability is well suited for the purpose of preventing lens decentration.

**PP-608****Scleral-Fixated Intraocular Lens with Guidance System Assistance: A Case Report**W Wang.

**Objective:** Intraocular lenses cannot be implanted in the capsular bag due to trauma or congenital or complicated cataract surgery and can be fixated to the sclera. However, the best method to be used for eyes lacking sufficient capsular support still need clarification.

**Methods:** The patient was a 90-year-old woman without a capsular bag of the left eye. The surgical treatment of scleral-fixated intraocular lens (IOL) was performed with guidance system assistance. The crystal position was centered to reduce rotation and tilting during the preparation of limbal incision, insertion of the suspension suture from the sclera opening, and fixation with the suspension suture with the assistance of guidance system incision, guidance system axis, and guidance system ring.

**Results:** After 1 month, the visual acuity of the left eye was 20/32, corrected to 20/26 ( $\cdot 0.25 / \cdot 0.75 \times 135$ ). The IOL was transparent and positive. The optical quality analysis system showed an objective scatter index of 1.8 and modulation transfer function cutoff of 20.032 cycles per degree.

**Conclusion:** Scleral-fixated IOL with guidance system assistance can help achieve more accurate crystal position and improve visual quality.

PP-609

**Accidental Impacted nonmetallic foreign body in the orbit in children: A case series.**A Maitra<sup>1</sup>, S Mandal, O Sarkar<sup>1</sup>.<sup>1</sup>Ophthalmology, Regional Institute of ophthalmology Medical College Calcutta, kolkata, India

**Objective:** Impaction of foreign body in the orbit is a common civilian injury. Longstanding impaction of FB in the orbital wall as well as in the soft tissue of the orbit may cause risk of damage to the eyeball, muscle and cranial nerves which may cause movement disorder, vision loss. FBs can be difficult to detect and, if missed, may have devastating clinical consequences. If an orbital FB is detected, it is critical to determine the type of material, which significantly affects management and potential complications. We have attempted to study the nature of injury, mode of presentation and subsequent post-operative outcome with this case series.

**Methods:** This study shows a series of 8 cases all of which had accidental impacted nonmetallic FB with preserved vision in the affected eye. 4 cases had discharging sinuses and orbital cellulitis with abscess formation. Possibility of metallic FB was excluded by meticulous history taking, and its absence was confirmed by CT scan with thin axial and coronal slices which was the initial imaging modality of choice. Once metallic FBs were ruled out, MRI with T2-weighted and/or contrast and fat suppression protocols of the orbit done for confirmation, better delineation, location, extension of the FB. It provided better visualization and resolution of soft tissues. Minimally invasive orbitotomies through different approaches were undertaken for their removal.

**Results:** FBs were removed from the eyes of all 8 patients, following which all patients had complete resolution of symptoms and eom restriction within one week to 3 months postoperatively

**Conclusion:** Orbital foreign bodies pose difficult diagnostic and therapeutic challenges. Organic foreign bodies can cause significant inflammation and carry a higher risk of subsequent infection compared with inorganic materials. Inorganic nonmetallic foreign bodies are many a times, inert. However, some metallic foreign bodies, particularly iron, copper, and lead, can cause specific complications such as retinopathy, siderosis, chalcosis, or systemic toxicity. Organic FBs are poorly tolerated, hence should be removed

## PP-610

## Severe ocular trauma characteristics 2 years before COVID-19 pandemic and during the pandemic in Riga Stradins university hospital

L Strucinska, A Zemitis, G Laganovska.

**Objective:** The COVID-19 pandemic has been associated with a decline in emergency department presentations for ocular trauma. The purpose of this study was to compare the estimated number and characteristics of eye injuries in 2020, the year of the COVID-19 pandemic, to those before the Covid-19 pandemic in 2018 to 2020 in Riga Stradins university hospital.

**Methods:** In this retrospective, hospital-based, comparative analysis, patients presenting to the emergency department with ocular trauma in the following COVID-19 period (March 12, 2020 to January 6, 2022) were compared with patients in the pre-COVID-19 period (March 12, 2018 to January 12, 2020).

**Results:** Overall, 89 patients (COVID-19 period: 37 and pre-COVID-19 period: 52) presented with ocular trauma. The mean age of the patients in COVID-19 and pre-COVID-19 periods were 44 [IQR 26] and 39 [IQR 29] years.

Home-related injuries were common in the COVID-19 period in 31 patient (83,8%) as compared to pre-COVID-19 period-in 40 patients (76,9%). 17 patients (32,7%) had an intraocular foreign body in pre-COVID-19 period, but 11 patients (29,7%) in COVID-19 period. The most common ocular diagnosis was contusio bulbi oculi gravis in 7 patients (18,9 %) in COVID-19 period and vulnus corneaescleralis perforans in 12 patients (23, 1%) in pre-COVID-19 period. Median visual acuity(VA) shortly after trauma in both groups was pr.lucis incerta. Surgical intervention was required in 59,6% of patients in pre-COVID-19 period and in 48,6% of patients in the COVID-19 period.VA after treatment was 0 (zero) to counting fingers in 46,1 %, 0.01 to 0.5 in 44,2 % and >0.5 in 9,7 % of patients in pre-COVID-19 group but in COVID-19 group it was 0 (zero) to counting fingers in 32,4%, 0.01 to 0.5 in 40.5% and >0.5 was in 27.1% .

In pre-pandemic group median Raw score sum was 37 points [IQR 24], but OTS was 1 [ IQR 1]. In pandemic group median Raw score sum was 46 points [IQR 39], but OTS was 2 [ IQR 2]. There was statistically significant difference in Raw score sum between both groups ( $p < 0,05$ ; Mann Whitney U test- $p$  0.014).

**Conclusion:** During the COVID-19 period, there was a significant decline (41,5%) in the number of patients presenting with ocular trauma. In this period, a majority of patients sustained ocular trauma in home-settings. About half the patients required surgical intervention which was most commonly rendered in the form of primary wound repair- suturing vulnus. The OTS in pandemic group was significantly lower than in pre-pandemic group.

PP-612

**An interesting case of multiple migratory caterpillar hairs in the eye**

H Prasanth, J Prashanth JP<sup>1</sup>.

<sup>1</sup>*Ophthalmology, Pondicherry Institute of Medical Sciences, Pondicherry, India*

**Objective:** To describe an interesting case of multiple migratory caterpillar hairs in the eye

**Methods:** A 40 year old male presented with the history that a caterpillar fell into his right eye a few days prior and he had irritation, pain and redness since then.

**Results:** BCVA was 6/6 and IOP was normal. Multiple caterpillar hairs were found on the palpebral conjunctiva, superficial and deep corneal stroma and in the anterior chamber. There was no AC reaction. Vitreous and retina were normal. Conjunctival hairs were removed with forceps under topical anaesthesia. He was started on topical antibiotics and steroids, with which he improved. On review, caterpillar hair was noted on the cornea and it was removed. No anterior or posterior chamber reaction was noticed, despite the presence of caterpillar hairs in the anterior chamber. On follow-up, two hairs were seen on the surface of the iris. The patient has been followed up for three months.

**Conclusion:** Caterpillar hairs may migrate intraocularly and cause inflammatory reaction, which may occur after the quiescent stage, so follow up of these patients is important.

PP-614

**A monolith in the eye : Temporary Keratoprosthesis for management of giant intraocular foreign body(IOFB) with corneal tear.**

S Makhija, S Jain, N Vyas Joshi.

**Objective:** To demonstrate the multi-stage management of a case of complex ocular trauma(a large central sutured corneal tear, surgical aphakia and an IOFB) with a 17 mm metallic intraocular foreign body enlodged at the macula.

**Methods:** We report a case of a 21 year old factory worker with a corneal tear and posterior segment intraocular foreign body. A multidisciplinary surgical approach was planned.

**Results:** A temporary keratoprosthesis was used to enable visibility during the removal of the posterior segment intraocular foreign body whilst maintaining a watertight chamber. The end result was the successful removal of the intraocular foreign body.

**Conclusion:** A Temporary Keratoprosthesis is an invaluable device in cases where there is an associated corneal opacification hampering visibility for a vitreoretinal surgeon when operating on the posterior segment. These cases require co-ordination between various subspecialties of ophthalmology and is a team effort. Primary prevention, adequate chair time, explanation of the visual prognosis, intimating the police, a well informed consent and precise documentation are of utmost importance.

PP-616

## Management of Penetrating Eye Injury with retained intraocular foreign body in Prince Mutaib Bin Abdulazziz Trauma Centre

A Akinfe.

**Objective:** Management of Penetrating Eye Injury with retained intraocular foreign body in Prince Mutaib Bin Abdulazziz Trauma Centre / Hospital, Saudi Arabia

**Methods:** A 24 year old female patient presented with 2-hour history of ocular injury. She was hit in the left eye by a nail while hammering it into a wall at home. This was associated with instant severe pain, redness, watering and reduction in vision. She was immediately rushed down to the emergency room of the trauma centre.

She experienced left eye severe pain, reduction in vision, lid swelling, redness, foreign body sensation, watering, and orbital fullness.

Evaluation at the emergency room revealed acutely traumatized lady with obvious left hypereamic lid swelling and protruding nail from the globe with subconjunctival heamorrhage (Figure 1). Examination with a bed side portable ER slit lamp device revealed left eye clear cornea, deep anterior chamber, nil hypheama, round and reactive pupil, clear lens, indirect ophthalmoscopy of the left eye also revealed anterior third of the metallic nail in the vitreous extending from the left medial pars plana. No obvious traumatic retina tear nor vitreous heamorrhage seen. The examination of the right eye was essentially normal with good vision. A diagnosis of left penetrating eye injury (with retained protruding nail) was made.

**Results:** Urgent Operating room (OR) request was sent to schedule patient for urgent left eye foreign body (bracket nail) removal and globe repair under general anesthesia. Informed consent was obtained prior to surgery. Left eye conjunctiva exploration, foreign body removal and globe repair was done successfully

The visual acuity assessment of left eye post op revealed counting fingers at 3m at 1<sup>st</sup> day post operation. This however improved to 0.7 Logmar VA by 3 days post operation.

**Conclusion:** Ocular penetrating and perforating injuries (commonly referred to as open globe injuries) can result in severe vision loss or loss of the eye<sup>2</sup>. Penetrating injuries by definition penetrate into the eye but not through and through--there is no exit wound<sup>2</sup> (this particular case has no exit wound). Perforating injuries have both entrance and exit wounds<sup>3,4</sup>. Early presentation, severity of injury, involvement of retina, macular prognosticate the outcome of the prompt review and repair<sup>5</sup>.

PP-617

**Where is the intraocular foreign body?**S Bhattacharya<sup>1</sup>, M Thakar<sup>1</sup>.<sup>1</sup>Guru Nanak Eye Centre, New Delhi, India**Objective:** To illustrate the case of a metal scrap cutter with an occult intraocular foreign body**Methods:** A 22 year old metal scrap cutter presented to the emergency with a diminution of vision after injury to his left eye while working. Examination findings included a self--sealed corneal perforation, a shallow anterior chamber and a post traumatic intumescent cataract with posterior synechiae in 3 quadrants and bunched up iris tissue. An emergency NCCT orbit revealed a hyperdense foci anterior to the lens, suggestive of a foreign body - however, its precise site, whether it was in the lens, iris or in the angles was not clear due to adhesions between all three. An ASOCT was unable to help, but ultrasound biomicroscopy pointed to an intra-lenticular location and the patient was taken for urgent surgery.**Results:** Careful exploration with synechiolysis and iris hooks revealed a 2x2 mm metallic foreign body stuck to the anterior capsule of the lens. Lens aspiration showed a large posterior capsular breach, and an anterior chamber IOL was put, with good gain of vision post operatively.**Conclusion:** Ultrasound biomicroscopy and ultimately surgical exploration is of utmost importance when an anteriorly located intraocular foreign body is suspected.



## PP-618

**Increased serum ferritin is associated with severity of orbital disease in COVID-19 associated Rhino-orbito-cerebral mucormycosis:**

R Singh<sup>1</sup>, S Tanwar, A Kaur<sup>1</sup>.

<sup>1</sup>Ophthalmology, King George's Medical University, Lucknow, India

**Objective:** To study the association between increased serum ferritin and severity of orbital disease in COVID-19 associated Rhino-orbito-cerebral mucormycosis (ROCM) and its role as biochemical determinant for disease progression.

**Methods:** A tertiary care center-based cross-sectional study was conducted. 155 treatment naive patients with concurrent or recent ( $\leq 6$  weeks) history of COVID-19 infection presenting with symptoms and signs of ROCM were evaluated. 100(n) of 155 patients with supportive evidence of ROCM were enrolled in the study. Based on contrast enhanced MRI head, orbit and paranasal sinuses (PNS), the study patients were divided into three groups: Group 1(n=25) - Involvement of nasal mucosa and paranasal sinuses, Group 2(n=37) - Involvement of nasal mucosa, paranasal sinuses and orbit, Group 3(n=38)- Involvement of nasal mucosa, paranasal sinuses, orbit and intracranial structures. Group 2 with orbital involvement was further divided into 4 subgroups: 2a (n=4), 2b (n=15), 2c (n=13), 2d (n=5). Fasting and postprandial blood sugar, inflammatory markers (serum ferritin, IL-6, C-reactive protein, D-dimer) were assessed. Serum level of ferritin was analyzed by using chemiluminescence immunoassay method. Statistical analysis was performed using ANOVA, Pearson correlation analysis and regression analysis. A p value of  $< 0.05$  was considered statistically significant.

**Results:** Mean FBS (mg/dl) was  $176.59 \pm 66.72$  for group 1,  $159.05 \pm 68.60$  group 2,  $158.20 \pm 62.05$  group 3. Mean PPBS (mg/dl) was  $246.14 \pm 119.11$  for group 1,  $257.09 \pm 103.48$  for group 2,  $229.53 \pm 76.81$  for group 3. Mean serum ferritin ( $\mu\text{g/L}$ ) was  $381.92 \pm 205.34$  in group1,  $504.85 \pm 205.99$  in group 2 and  $825.95 \pm 777.30$  in group 3. ANOVA showed a statistically significant increase in serum ferritin levels with severity of disease ( $P = 0.002$ ). Similar trend was observed in group 2 subgroups. Pearson correlation analysis showed a positive correlation between serum ferritin and severity of disease (Pearson correlation coefficient: 0.3379,  $P=0.0006$ ). On multiple regression analysis, serum ferritin was not dependent on blood sugar levels ((Coefficient of determination  $R^2= 0.008000$ ; Multiple correlation coefficient= 0.08944;  $P=0.6774$ ).

**Conclusion:** Serum ferritin levels were statistically significant independently associated with severity of orbital disease in COVID associated ROCM.

PP-619

**Update on Idiopathic Canalicular Inflammatory Disease (ICID): Outcomes with Modified Treatment Protocol**N Bothra<sup>11</sup>, M Javed Ali<sup>12</sup>.<sup>1</sup>Govindram Seksaria Institute of Dacryology, <sup>2</sup>LV Prasad Eye Institute, Hyderabad, India

**Objective:** To present clinical outcomes with addition of topical cyclosporine while managing cases of ICID and to propose a modified treatment protocol.

**Methods:** Prospective case series of 88 canaliculi of 44 eyes of 22 patients diagnosed as ICID at a tertiary care Dacryology service over a period of 2 years. All the patients were diagnosed based on the published major and minor criteria and each of the canaliculus was clinically staged. All patients were treated initially with a combination of topical cyclosporine (0.05%) and rapidly tapering topical steroids followed by punctal dilatation and placement of minimonoka stents after control of inflammation. Monoka stents were extubated at 6 weeks and the cyclosporine was continued for at least up to 3 months beyond the extubation of stents. Patient demographics, investigations, response to cyclosporine, management modalities, recurrence of inflammation, anatomical and functional outcomes were analyzed.

**Results:** Eighty-eight canaliculi were diagnosed to have idiopathic canalicular inflammatory disease during the study period. There was a female preponderance (77%, 17/22) and the mean age at presentation was 51 years. All patients presented with bilateral epiphora (mean duration 4.5 months) without any discharge. Staging revealed 18, 27, 24, and 19 canaliculi were involved with stages 1–4, respectively. The mean duration of cyclosporine use was 5.7 months. All patients except 3 (19/22) underwent monoka dilatation. Complete anatomical and functional resolution were noted in 62% (55/88), of which 12 puncta and canaliculi, all stage 1 (13.6%, 12/88) showed complete resolution with cyclosporine alone. Relentless disease progression to stage 5 was noted in 30% (26/88) of the puncta and canaliculi. All the younger patients (<30 years, 13.6%, 3/22) demonstrated poor outcomes.

**Conclusion:** The addition of topical cyclosporine is beneficial in controlling inflammation and disease downstaging in patients with idiopathic canalicular inflammatory disease. The current modified treatment protocol salvages majority of the canaliculi.

PP-620

**10 /14,French silicone Foley catheter use as expansion device in lid reconstruction and scar revision surgery**S Mandal<sup>1</sup>, O Sarkar<sup>1</sup>, M Gayen<sup>1</sup>, A Maitra<sup>1</sup>, P Ray<sup>1</sup>.<sup>1</sup>*ophthalmology , Regional Institute of ophthalmology Medical College Calcutta, kolkata, India*

**Objective:** To evaluate the efficacy of the 10 /14 French Silicone Foley Catheter use as a soft tissue and skin expander in repair of upper and lower lid defect created after removal of large malignant tumor or trauma. To evaluate the cost and safety of using a 10/14 french silicone Foley catheter rather than conventional silicone tissue expander

**Methods:** Prospective, non-comparative, interventional study conducted over 3 years in 34 patients. With the use of tissue expander Lid Reconstruction surgery was conducted in two stages. In stage 1. The proposed elliptical area was marked which coincide maximum area of tissue expansion. The graded inflation of balloon to stretch soft tissue and skin over period of 5 days. In 2<sup>nd</sup> stage the balloon of catheter was deflated on 5<sup>th</sup> day thus expanded tissue became relaxed. The lid reconstruction was done in 30 cases and scar revision surgery was done in three case to correct the cicatricial ectropion

**Results:** Created defect in the lower and upper eyelid after tumor excision was  $71.125 \pm 7.73$  and  $(56.66 \pm 5.31)$ . The mean PFH value pre operatively was  $3.75 \pm 0.65$  mm, a PFH and post op at 1<sup>st</sup> week  $5.54 \pm 0.58$ , after 6<sup>th</sup> month  $10.41 \pm 0.35$  mm. The mean length of incision in lower lid with use of expander was  $62.27 \pm 1.36$  mm, without the use of expander  $89.33 \pm 13$ . In upper lid with the use of expander is  $60.58 \pm 2.02$  mm and without expander is  $81.08 \pm 1.44$  mm. The ellipsoid surface area calculated by  $S = \pi \times \text{Long axis} \times \text{Short axis}$ . The basal diameter of ellipsoid area for expansion in upper lid mean with SD  $S = \pi \times 42.16 \pm 1.02 \times 32.08 \pm 1.08 = 4250.77 \pm 239.19$  and lower lid mean sd were  $S = \pi \times 42.05 \pm 1.34 \times 32.16 \pm 1.42 = 4251.90 \pm 302.89$

**Conclusion:** The incision length is markedly reduced. Cosmetically scar is less. With the temporary tissue expansion with easy closure of the created defect with Tenzel flap which is difficult with conventional tenzel. Early visual rehabilitation is possible without closing the eyelid. It is safe materials, easily available and cost effective, unlike tissue expander costing (\$150 to \$200). Therefore, 10/14 French Silicon Foleys catheter use as an excellent tissue expander in under developed country where access to other expensive option are limited and more over the successful use of this novel utility are well accepted in well developed countries

**PP-621****Short term outcome analysis of transcutaneous retrobulbar AmphotericinB in COVID-19 associated Rhino-orbital-Cerebral Mucormycosis**

N Mishra, S Mishra, N Fatema Afzal Hussain, A Kaur.

**Objective:** To study the short-term outcome analysis of transcutaneous retrobulbar amphotericin B (TRAMB) in COVID-19 associated Rhino-Orbital-Cerebral Mucormycosis (ROCM)

**Methods:** The study authors confirm adherence to the guidelines of the Declaration of Helsinki. One fifty-seven patients of ROCM fulfilling the institutional criteria for administration of TRAMB and those unfit for undergoing exenteration/local surgical debridement under general anesthesia were included in this prospective interventional tertiary health care center-based study. Risk factor analysis along with detailed ophthalmic evaluation was done for all patients. Sinus debridement, intravenous liposomal amphotericin B and TRAMB was given to patients as per institutional standard protocol. Outcome analysis was done based on the improvement of clinical findings over the period of one month post three doses of TRAMB injection. Survival outcome analysis was done using Cox regression analysis. Data was statistically analysed.

**Results:** Mean age of presentation was 50.38+10.34 years with male preponderance. Main risk factor was Diabetes Mellitus. Lid edema and periocular swelling was the most common presentation. At the end of one month post TRAMB, 85% (n=134) showed arrest of the disease while 20 patients showed improvement in clinical signs. Three patients worsened and were taken up for exenteration. Side effect of TRAMB was noted only in two patients in the form of local tissue necrosis. On Cox regression hazard ratio of 1.2% was noted which was statistically insignificant.

**Conclusion:** TRAMB is a minimally invasive globe sparing treatment for orbital mucormycosis with good survival outcome

**PP-622****Age- related changes in the Lacrimal Punctum Morphology in a normal population**

N Bothra, M *Javed Ali*<sup>1</sup>.

<sup>1</sup>*LV Prasad Eye Institute, Hyderabad, India*

**Objective:** To define the clinical and optical coherence tomography (OCT) morphology of the lacrimal punctum and assess the age-related changes across 8 decades of life in a normal population.

**Methods:** A total of 1310 high-magnification slit-lamp, Fourier-domain OCT (FD-OCT), and optical coherence tomography angiography (OCTA) images were obtained from 320 puncta of normal asymptomatic individuals representing the Indian population. The punctum and peri-punctal area were defined with the help of 2 rims (inner punctal rim and outer punctal rim ) and 3 zones (white zone [Wz], separation zone [Sz], and peri-punctal vascularity). FD-OCT images were used to measure the external punctal diameters and internal lacrimal punctal diameters and the reflectivity patterns of the 3 punctal layers. OCTA was used to assess the branching and extent of vascular networks.

**Results:** The upper puncta were narrower and more circular than the lower puncta across the decades. The elevation of the punctal papilla began in the upper puncta in the fifth decade, involved the lower puncta in the sixth decade, and gradually became exaggerated by the eighth decade. A typical punctal narrowing in previously wide puncta began to appear in the sixth decade of life, peaks in the seventh decade, and reverses gradually and spontaneously by the end of the eighth decade of life. The third and fourth decades saw a narrowing of the Sz with prominent vascularity crossing the Sz to reach the Wz. The Sz became indistinct in the fifth and sixth decades of life. The FD-OCT showed gradual thickening and dominance of the fibrous layer from the fifth to eighth decade of life. The clinical vascularity in the peri-punctal region increases from the third decade onwards, with vascular networks becoming increasingly dense, intricate, and branched as the age progresses.

**Conclusion:** The present study defined and characterized the involitional changes in a normal population's first–eighth decades of life. Significant morphological changes were noticed across the different age groups with several clinical implications.

PP-623

## NOVEL USE OF THE SILICONE CATHETER AS TISSUE-EXPANDER FOR FULL-THICKNESS SKIN GRAFTING IN EYELID RECONSTRUCTION

O Sarkar<sup>1</sup>, S Mandal<sup>1</sup>, A Maitra<sup>1</sup>.

<sup>1</sup>*Ophthalmology, Regional Institute of ophthalmology Medical College Calcutta, kolkata, India*

**Objective:** We use a 10-French Silicone Foleys Catheter as a novel, cheap, and easily-accessible alternative to conventional expensive tissue-expanders. Subsequently, we evaluate its efficacy in providing an adequate graft-area necessary for proper eyelid reconstruction; and positive effects on healing at the donor-site.

**Methods:** In this prospective interventional study, we admitted patients with upper and/or lower eyelid deformities of non-malignant and non-systemic cause (eg: burn contractures, road-traffic accidents, chemical and thermal injuries, etc) – and performed a two-step surgery for eyelid reconstruction. First, we implanted the expander subcutaneously and after a week we released the fibrotic scar tissue while dissecting the eyelid, harvested a full-thickness skin graft from the expander-site and reconstructed the anterior-lamella of the eyelid with it. The intra-operative area of the created skin-defect was noted, alongwith the pre-operative values of eyelid-retraction on either side; and the subsequent areas of the skin-graft on post-operative visits (at 1 week, 1 month, and 6 months) were recorded as well. The data was tabulated in Microsoft Excel spreadsheets and analyzed using standard statistical software

**Results:** During surgery, the mean area of the harvested graft was over-estimated roughly by 30% of the area of the defect. This underwent secondary contraction by 11.18% at 1-month post-operative follow-up; but however, showed an increase of 3.66% after 6 months due to proliferation and recruitment from adjacent tissue- brought about by tissue-expansion of the skin. Thus, it was seen- with respect to the skin-defect area measured under zero-tension intra-operatively, the mean net-gain of tissue at 6 months was 38.93% ( $p < .00$ ).

**Conclusion:** Our study clearly demonstrates that a moderate to high amount of tissue-gain is yielded by tissue-expansion before full-thickness skin-grafting, achieving superior cosmesis; making this a very effective method of eyelid reconstruction for various eyelid deformities. Moreover, the tissue expander is easily available to the patients in our current setup: the humble 10-French Silicone Catheter, costing 50 times less than the conventional silicon tissue-expanders which such poor patients cannot afford. Thus, this novel use of the silicone catheter as a tissue expander is set to be a game-changing innovation in the eyelid-reconstruction scene.

PP-624

**Exploring the globe salvaging treatment options in patients of COVID Associated Mucormycosis (CAM) with orbital involvement**Y Chaurasia<sup>1</sup>, P Khare<sup>1</sup>.<sup>1</sup>Ophthalmology, Bundelkhand Medical College, Sagar, India

**Objective:** To explore the various globe salvaging treatment strategies for patients with COVID Associated Mucormycosis (CAM)

**Methods:** 84 patients of CAM admitted between May 2021 to August 2021 were enrolled for the study. Patients with histologically proven CAM with clinical and/or radiological evidence of orbital involvement were divided into 3 treatment categories based on the site and extent of the lesion. Reassessment was done after 7 days. For patients who worsened with the primary approach, orbital exenteration was considered based on Sion Hospital Scoring System (SHSS). A novel approach to intraorbital antifungal therapy- Site Centered Peribulbar injection of Amphotericin B (SCPeriAmB) was also explored. All the patients were followed up for at least three months.

**Results:** 6 patients had to finally undergo exenteration by the end of the study period. Rest patients were reported to be stable or improved. No mortalities were reported on delaying the exenteration for 7 days. No adverse events were noted in patients who were given SCPeriAmB.

**Conclusion:** Globe salvaging treatment options can be advocated as a primary approach in patients with CAM. Site Centered Peribulbar injections can be considered as an alternative to the retrobulbar route for delivering intraorbital antifungal therapy in selected patients.

PP-625

**Lacrimal organ dysfunction in iodine-131 treatment of thyroid cancer: a systematic review and meta-analysis**C Liang, L Liu<sup>1</sup>.<sup>1</sup>*he First Affiliated Hospital of Jinan University, Guangzhou, People's Republic of China*

**Objective:** There is still controversy about the treatment of thyroid carcinoma with iodine-131(I-131) therapy, mainly because I-131 therapy can cause a series of complications. There is increasing evidence that I-131 therapy can cause ocular complications, however there is a lack of evidence-based medical evidence for the damage of I-131 therapy to the eye. Therefore, the aim of this paper was to investigate the ocular effects of I-131 therapy in patients with thyroid cancer, especially lacrimal apparatus related dysfunction.

**Methods:** In Pubmed, Cochrane, Embase, Web of Science, Medicine, Sinomed, China National Knowledge Infrastructure, Wanfang, and VIP databases were searched for Chinese and English articles published before March 6, 2021 on lacrimal dysfunction caused by I-131 after thyroid cancer surgery.

**Results:** A total of 125 relevant articles were retrieved from the database, including 115 English articles and 10 Chinese articles, and 3 articles were finally included according to the inclusion criteria and exclusion ratio criteria. People who took I-131 after thyroid cancer surgery were included in the test group, and those who did not take I-131 treatment were included in the control group. By comparing the difference of Schirmer test values in the control group, the 95% CI of the effect size shown in the forest plot by STATA 15.0 was -4.19 (-11.40, 3.01) including 0. It can be considered that the difference in the means of the control group is not statistically different, and the means of the outcome measures of the two groups are not equal.

**Conclusion:** This study showed that there was no significant statistical difference in the Schirmer test values of the control group in the I-131 treatment trial. Although there is no significant limitation to the use of I-131 radioiodine therapy at a dose in differentiating thyroid cancer, more extensive studies are needed to obtain more accurate data about lesions such as lacrimal dysfunction that may occur in these cases.



PP-626

## A Study On The Rise Of The Placid Fungus ,Mucormycosis & it's sequelae -A Multidisciplinary Approach To Curb The Diabetic Doom!!

S Ramavath<sup>1</sup>, S Ramavath<sup>2</sup>.

<sup>1</sup>ophthalmology, Regional Eye Hospital, Andhra Pradesh ,Kurnool, <sup>2</sup>ophthalmology, REGIONAL EYE HOSPITAL,KURNOOL, Kurnool, India

**Objective:** Rhino-orbital-cerebral mucormycosis is a rare angio-invasive, life-threatening fungal infection resulting from the zygomycete of the order- Mucorales. The aim was to study the distribution, causative organisms, clinical manifestations, complications of Rhino-orbital-cerebral-mucormycosis.

**Methods:** A study was conducted on 100 patients diagnosed with mucor at Regional eye hospital, kurnool. The mean age was (49.82 ± 11.9). 70% were males. 81% recovered from covid. 93% were diabetics. 91% of species isolated were Mucor.spp followed by 4% Aspergillus.spp & 3% of Rizhopus.spp & 2% of candida.spp Clinical features seen were defective vision, periorbital edema, ptosis, proptosis, ophthalmoplegia etc. All patients underwent RT-PCR, routine blood investigations, MRI & C.T, nasal mucosal endoscopy & histopathological examination. After confirmed with fungal elements Patients were started on systemic Amphotericin-B & Posaconazole without delay. Functional Endoscopic Sinus Surgery(FESS) was done. Exenteration was done for cases with poor prognosis

**Results:** Majority presented with ophthalmoplegia (93%), exposure keratitis(83%) followed by orbital cellulitis(81%) & cerebral involvement(69%). Other complications seen were optic neuritis, retinal detachment, central retinal artery occlusion, visual field defects, cavernous sinus thrombosis, scleral abscess etc. Covid patients who recovered had a high risk of developing meningitis (p = 0.004) due to mucor. Patients with cavernous sinus thrombosis (p=0.008), cerebral abscess(p=0.007) should be treated early as they worsened at later stages & required exenteration. Factors like age, gender, covid, diabetic status do not influence stage of presentation & was statistically proven.

**Conclusion:** The sudden epidemic of ROCM & its variety of presentations led to a curiosity to study, learn about it, & that we can be cautious for the next epidemic waves of ROCM!

A high index of clinical suspicion, early diagnosis by a diagnostic nasal endoscopy and direct microscopy of the high nasal swab or an endoscopically guided nasal swab, supported by contrast-enhanced MRI or CT scan, initiation of full-dose liposomal Amphotericin B & continued step-down oral antifungals may help optimize the outcome of ROCM in the setting of COVID-19. As INDIA is a Diabetic capital & there is a high risk of ROCM in diabetics, prophylactic control of blood sugars along with appropriate multi-disciplinary approach we can curb this diabetic doom!

PP-627

**Clinical observation of the effect of balanced orbital decompression without marginotomy on thyroid-associated ophthalmopathy**W Xu, X Yang.

**Objective:** The increase of orbital contents in patients with thyroid-associated ophthalmopathy (TAO) leads to the change of appearance and the occurrence of exposure keratitis, and some patients have impaired vision due to compressive optic neuropathy. Orbital decompression surgery is required when drugs and other means are ineffective for TAO treatment or when the patients have cosmetic demand. In recent years, orbital decompression surgery has been continuously improved to achieve the personalized treatment purposes. This study aimed to observe the therapeutic effect of balanced orbital decompression without marginotomy on thyroid-associated ophthalmopathy

**Methods:** This is a retrospective case study. The clinical data were collected from patients with TAO and accepted balanced orbital decompression surgery without marginotomy during January 2021 and January 2022 in our department. Main outcome measures included best corrected vision acuity, proptosis, ocular position and ocular movement, diplopia, CT imaging, intraoperative and postoperative complications.

**Results:** There were no significant changes in the best corrected vision acuity after surgery as patients in our study did not have significant compressive optic neuropathy or visual loss. The mean proptosis was  $4.21 \pm 1.05$  mm, ocular movement was improved, diplopia was decreased, and the bone decompression window was clear on the computed tomography slides.

**Conclusion:** The skin incision of our surgery is small and invisible, the surgical method is effect in reducing proptosis and improving ocular movement. There is no need to do marginotomy, and it is suitable for patients with high cosmetic demands, low proptosis and with serious compressive optic neuropathy.

PP-628

**Intraorbital self-inflating Hydrogel Expander Implantation with a Modified Technique in Congenital Microphthalmia**P Wu<sup>1</sup>, D Huang<sup>1</sup>.<sup>1</sup>Oculoplastic Department, Zhongshan Ophthalmic Center Sun Yat-Sen University, Guangzhou, People's Republic of China

**Objective:** To investigate the long-term safety and efficacy of intraorbital self-inflating hydrogel expander implantation with optic nerve transection in children with congenital microphthalmia.

**Methods:** This was a retrospective review of 12 unilaterally blind microphthalmic pediatric patients ( $44.25 \pm 17.5$  months) undergoing hydrogel expander implantation with optic nerve transection. The orbital volume and eye globe volume were measured and analyzed based on computed tomography scans taken preoperatively and 36 months postoperatively. The palpebral length was measured at every follow-up. Surgical complications were also recorded.

**Results:** At 36 months postoperatively, the microphthalmic and contralateral orbital volumes increased by  $3.07 \pm 0.77$  ml and  $2.03 \pm 0.67$  ml, respectively. The mean microphthalmic/contralateral ratio (MCR) of the orbital volume increased significantly from  $76.60\% \pm 5.46\%$  to  $83.81\% \pm 5.41\%$  ( $p < 0.001$ ). The microphthalmic palpebral length increased by  $6.17 \pm 1.85$  mm, while the contralateral palpebral length increased by  $2.67 \pm 1.44$  mm. Significant changes were observed in the palpebral length MCR ( $68.00\% \pm 4.83\%$  vs  $85.07\% \pm 3.87\%$ ;  $p < 0.001$ ). There was no significant change in the microphthalmic eye globe volume at 36 months postoperatively ( $p = 0.215$ ). For the fellow eye, the eye globe volume increased significantly by  $0.53 \pm 0.34$  ml ( $p < 0.001$ ). During the follow-up period, 2 patients required a sunken prosthesis. One patient had difficulty in opening the eye after wearing the conformer. There were no cases of expander rejection or extrusion.

**Conclusion:** Intraorbital self-expanding hydrogel expander implantation with optic nerve transection is a safe and effective treatment for congenital microphthalmia, leading to excellent osseous and eyelid growth throughout the 36-month follow-up period.

PP-629

## Age-related difference in extraocular muscles and its relation to clinical manifestations in Thyroid Associated Ophthalmopathy

Y Su<sup>1,2</sup>, X Liu<sup>1,2</sup>, H Zhou<sup>1,2</sup>, J Sun<sup>1,2</sup>, X Fan<sup>1,2</sup>.

<sup>1</sup>Department of Ophthalmology, Shanghai Ninth People's Hospital, Shanghai Jiao Tong University School of Medicine,

<sup>2</sup>Shanghai Key Laboratory of Orbital Diseases and Ocular Oncology, Shanghai, People's Republic of China

**Objective:** To evaluate the age-related difference in EOMs and its relation to clinical manifestations by computed tomography (CT) measurement of EOMs in thyroid associated ophthalmopathy.

**Methods:** The medical records and CT images review of 40 patients (80 orbits) with moderate-to-severe thyroid associated ophthalmopathy were performed. The patients were divided into two age groups, Group 1 ( $\leq 40$  years) and Group 2 ( $> 40$  years). CT scans of 30 gender- and age-matched normal controls were also obtained. The maximal cross-sectional area (MCA) and its position (pMCA) of each EOM were measured.

**Results:** Group 1 presented with more severe proptosis ( $p < 0.001$ ), while Group 2 had a higher risk of diplopia ( $p < 0.001$ ). Motility restriction in supraduction was more likely to occur in Group 2 ( $p = 0.027$ ) with even higher severity ( $p = 0.047$ ). The pMCA was higher in the inferior ( $p = 0.001$ ), medial ( $p = 0.021$ ), and lateral rectus ( $p = 0.013$ ) in Group 1. Proptosis was positively correlated to pMCA while diplopia was correlated to MCA in both groups. Significant correlation was noted between restrictions levels and MCA (superior,  $r = 0.467$ ,  $p < 0.001$ ; inferior,  $r = 0.358$ ,  $p = 0.007$ ; medial,  $r = 0.314$ ,  $p = 0.018$ ; lateral,  $r = 0.308$ ,  $p = 0.021$ ) or pMCA (inferior,  $r = -0.534$ ,  $p < 0.001$ ) only in Group 2.

**Conclusion:** The muscle enlargement patterns are significantly different between younger and older patients. Older patients tended to have enlarged muscle bellies more posterior in the orbit, which is responsible for more diplopia and motility restriction. Proptosis is more likely to be affected by the most enlarged position than muscle size. So younger patients tended to develop more proptosis and be less bothered by motility restriction even with enlarged muscles.

PP-630

**The Floppy Thyroid Eye Disease (TED)**A Agarwal<sup>1</sup>, M Naik<sup>1</sup>, N Bothra<sup>1</sup>.<sup>1</sup>Ophthalmic Plastic Surgery Services, LV Prasad Eye Institute, Hyderabad, India

**Objective:** To report unique clinical features and management implications of patients with co-existing Thyroid Eye Disease (TED) and Floppy Eyelid Syndrome (FES)

**Methods:** Retrospective observational case review of patients presenting as TED with FES over a period of six years, between 1<sup>st</sup> January 2016 to 1<sup>st</sup> February 2022.

**Results:** Of a total of 100 cases of FES, three patients (six eyes) with co-existing TED and FES were analyzed. Two out of the three cases were males. The average age at presentation was 64 years. Hypothyroidism was noted in 2, and 1 was euthyroid. Average exophthalmometry was 24.6 mm. All cases had bilateral involvement with significant lower lid retraction and scleral show. One patient had repeated episodes of globe luxation. Two cases had corneal exposure and congestion, which mimicked clinically active TED. Upper eyelid retraction was absent in 5 out of 6 eyes.

**Conclusion:** Patients with TED and FES represent a unique subgroup. The lax upper eyelids mask upper eyelid retraction and predispose to lower eyelid retraction as well as globe luxation. Corneal exposure may be more frequent since both etiologies affect ocular surface. A differentiation between papillary congestion in FES and congestion seen in clinically active TED is warranted for appropriate management.

## PP-632

**Treatment of facial depressed scars by the injection of triamcinolone combined with hyaluronic acid**

Y Li, W Lu<sup>1</sup>.

<sup>1</sup>The Second Hospital of Dalian Medical University, Dalian, Taiwan, China

**Objective:** To investigate the clinical outcomes following intralesional injection of triamcinolone with hyaluronic acid for the treatment of depressed facial scars.

**Methods:** Clinical data of 16 patients (26 scar lesions) with depressed facial scars in the Second Hospital of Dalian Medical University between January 2013 and January 2015 were retrospectively analyzed. The patients had undergone intralesional triamcinolone injection every 2 weeks. After each triamcinolone injection the scars' pliability was evaluated. Hyaluronic acid (Restylane No.2) was injected into the dermis under the scar to fill the depression until the score of the scar's pliability decreased less than 1. The scar was evaluated before and after treatment using the Vancouver scar scale (VSS) and the Patient and Observer Scar Assessment Scale (POSAS), patient photographs and scores of the scar's pliability and depth of depression. The follow up was more than 12 months. Complications such as pigmentary changes, telangiectasia, atrophy and ulcer were recorded at the same time. Before and after treatment the comparison of the score of VSS, pliability and depression were analyzed with t-paired test.

**Results:** In all scars, the depression occurred before the treatment. One month after hyaluronic acid injection, 26 scars' depression all were corrected. Only 2 scars were depressed less than 1mm at 1 year's follow-up. At the follow-up visit, the scores of VSS and POSAS demonstrated improvements in skin texture for all scars. The change in the VSS score before and after treatment at one month statistically significant ( $t=17.3, P<0.01$ ). The change in VSS score at six and twelve months after hyaluronic acid injection was statistically significant ( $t=2.74, P<0.05$ ). During the follow up, there were no pigmentary changes, telangiectasias, atrophy or ulceration. Two scars had erythema, three had epidermal thinning following triamcinolone. At one year follow up, the erythema decreased and the epidermis became normal. There were no allergic reactions, vascular embolization or necrosis were recorded during the follow-up.

**Conclusion:** Intralesional injection of triamcinolone combined with hyaluronic acid for the treatment of depressed facial scars is safe and feasible. The treatment could improve the appearance of depressed facial scars.

PP-633

**Surgical Management and Outcome of Lacrimal Canaliculitis**F Afzal, S Sutana<sup>1</sup>, R Rashid<sup>1</sup>, F Afrin<sup>1</sup>.<sup>1</sup>Ispahani Islamia Eye Institute & Hospital, Dhaka, Bangladesh, Dhaka, Bangladesh

**Objective:** This study intends to analyze the clinical profile of lacrimal canaliculitis with its surgical management and outcome.

**Methods:** It is a prospective interventional study that was conducted in Ispahani Islamia Eye Institute and Hospital. All the patients who presented with primary lacrimal canaliculitis in the Oculoplasty and Oncology department within the period of January 2020 to December 2021 were assessed and included in this study. Canaliculitis due to secondary causes like eyelid inflammation or chronic dacryocystitis were excluded. Syringing of lacrimal drainage system on the affected side was proven patent in each case. Canaliculotomy with canalicular curettage was done in all patients. It was followed by irrigation with antibiotic solution (penicillin) on 1<sup>st</sup> day, 7<sup>th</sup> POD and after 1 month. All the patients were followed up upto 3 months.

**Results:** Total 23 patients with lacrimal canaliculitis were analyzed in this study. Mean age of presentation was 50.73 years (range 19 to 70 years) whereas female predominance was observed with male to female ratio 1:1.55. All cases were unilateral and either lower (47.82%) or upper canaliculi (52.17%) were involved. The commonest clinical presentations were pus and concretion (in 82.60% cases), mucous discharge (65.21%), epiphora (95.65%), punctal swelling (73.91%), conjunctival congestion (21.7%) and pain over punctum and canaliculi (39.13%). After surgery, concretion and necrotic epithelium were sent for histopathology. Most common isolated organism was Actinomyces (91.3 %). During follow up, symptoms and signs were resolved completely in 22 (95.65%) patients. Only 1 (4.3%) patient complaints of persistent epiphora possibly due to lacrimal pump failure.

**Conclusion:** Lacrimal canaliculitis is an uncommon canalicular condition and often misdiagnosed with other common ocular disease. It should be appropriately diagnosed and promptly treated to avoid possible complications. Canaliculotomy with curettage followed by irrigation with antibiotic solution is proven to be safe and successful treatment modalities in these cases with minimum post operative complications. This study would unlock further frontiers for the prospective researchers, particularly with the larger number of cases.

PP-634

**Reactive oxygen species activated NLRP3 inflammasomes initiate inflammation in PM2.5-induced dry eye via TRPV1**

Z Guo, J Zhao<sup>1</sup>, L Feng<sup>2</sup>, H Shen<sup>2</sup>, H Niu<sup>3</sup>.

<sup>1</sup>Department of Ophthalmology, <sup>2</sup>Ophthalmology, <sup>3</sup>Ophthalmology, The Fourth Affiliated Hospital of China Medical University, Shenyang, People's Republic of China

**Objective:** As an organ directly exposed to the external environment, eyes are particularly vulnerable to air pollutant PM2.5. It has been reported that PM2.5 is closely related to the pathogenesis of dry eye (DED). However, the molecular mechanism of pathology is not completely clear.

**Methods:** C57BL / 6 mice and corneal epithelial cells were treated by pure PM2.5 to make DED animal model and cell model. The DED model was verified by corneal fluorescence staining, and the expression of TRPV1 was detected by WB, RT-qPCR and other methods. Subsequently, intervention was performed with the TRPV1 inhibitor CPZ. Finally, Reactive oxygen species was detected by DHE staining, ROS staining, WB, IF, RT-qPCR, etc. reactive oxygen species and NLRP3-IL1 $\beta$  in vivo and vitro.

**Results:** The expression of mRNA and Protein of TRPV1, inflammatory factor and NLRP3-IL1 $\beta$  signal axis related protein were increased. The increase of ROS production was observed by DHE and ROS staining. Subsequent intervention with TRPV1 inhibitor CPZ significantly reduced corneal fluorescence staining score, inflammatory factors and NLRP3-IL1 $\beta$  signal axis related proteins and ROS production. Finally, through the inhibition and overexpression of ROS, it was confirmed that TRPV1 promoted the production of ROS and activated NLRP3 inflammasomes

**Conclusion:** TRPV1 inhibitor CPZ can significantly reduce the production of ROS and the activation of NLRP3 inflammasomes. Reactive oxygen species activated NLRP3 inflammasomes initiate inflammation in PM2.5-induced dry eye via TRPV1



PP-636

**Surgical Outcomes of Orbital Evisceration with Primary Orbital Implant placement in patients with Endophthalmitis**K Lai, A Kuk, A Au, S Ko, E Chan, C Ko.

**Objective:** This study reports the surgical outcomes of evisceration with primary orbital implant c in patients with endophthalmitis and analyses the association with implant exposure and extrusion.

**Methods:** A retrospective, multicentre, Chinese cohort study. Review of medical records and orbital images of patients with endophthalmitis who underwent evisceration with primary orbital implant placement between January 2005 and January 2021.

**Results:** Orbital evisceration with primary orbital implant placement was performed in 26 (26 eyes) patients (males=13) with endophthalmitis. The duration from endophthalmitis diagnosis (19=exogenous, 7=endogenous) to evisceration was 9 standard deviation $\pm$ 5 (range: 1-15) days. The follow-up was 70 $\pm$ 46 (24-180) months after operation. The orbital implant size was 17 $\pm$ 3 (14-20) mm, and the material included silicone (18/26), acrylic (5/26), porous polyethylene (2/26) and glass (1/26). The most common post-operative complication was orbital implant exposure (54%, 14/26 of patients), followed by orbital implant extrusion (19% 5/26), ptosis (8%, 2/26), haematoma (4%, 1/26), excessive growth of granulomatous tissue (4%, 1/26), symblepharon (4%, 1/26) and orbital cellulitis (4%, 1/26). Univariate analysis showed single scleral closure technique (100% vs 58%,  $P<0.05$ ) and endogenous endophthalmitis (50% vs 0%,  $P<0.05$ ) were associated with implant exposure or extrusion. Only endogenous endophthalmitis ( $P<0.05$ ) was associated with implant exposure or extrusion with multivariate analysis.

**Conclusion:** Orbital implant exposure or extrusion were experienced in up to 40% of our patients, and they were associated with endogenous endophthalmitis. Double scleral closure technique is a reasonable option to reduce the risk of implant exposure and extrusion in eyes with endophthalmitis.

PP-637

### A Comparison of Silicone Plate vs. Autogenous Auricular Cartilage Graft in Upper Eyelid Reconstruction following Tumor resection

S Mandal<sup>1</sup>, A Maitra<sup>1</sup>, P Ray<sup>1</sup>, M Gayen<sup>1</sup>, O Sarkar<sup>1</sup>.

<sup>1</sup>Ophthalmology, Regional Institute of ophthalmology Medical College Calcutta, kolkata, India

**Objective:** To compare the surgical outcomes, safety, efficacy and cost benefit of using silicone plates (SP) and autogenous auricular cartilage (AAC) grafts for tarsal plate reconstruction of upper eyelid defects following malignant tumor resection.

**Methods:** This is a retrospective, interventional case series of 20 patients over an 18-month period. All patients had malignant tumors of the upper eyelid and underwent repair with a modified Cutler Beard procedure. AAC was used as a tarsal plate substitute in 10 patients and silicone plates in 10 patients. Preoperative margin reflex distance (MRD1), levator function (LF), palpebral fissure height (PFH), central lid thickness (CLD) and lid contour (LC) were compared to 1-month and 6-month postoperative follow-up measurements.

**Results:** Upper eyelid reconstruction was achieved in all patients without complications. The pre-operative MRD1 in the SP and AAC group were  $-2.95 \pm 1.19$  mm and  $-3.05 \pm 1.05$  mm, respectively. The post-operative 1 and 6-month MRD1 measurements were  $2.55 \pm 0.5$  mm and  $3.8 \pm 0.4$  mm in the SP group compared to  $1.65 \pm 0.46$  mm, and  $3.8 \pm 0.41$  mm in the AAC group. The pre-operative LF in the SP and AAC groups were  $1.2 \pm 1.1$  mm and  $1.0 \pm 0.9$  mm, respectively. The post-operative 1 and 6-month LF was  $12.25 \pm 0.9$  mm and  $13.8 \pm 0.4$  mm in the SP group and  $8.25 \pm 0.7$  mm and  $13.7 \pm 0.4$  mm in the AAC group. The pre-operative PFH in the SP and AAC group was  $2.05 \pm 1.19$  mm and  $1.95 \pm 1.05$  mm. The post-operative 1 and 6-month PFH was  $7.55 \pm 0.51$  mm and  $8.8 \pm 0.41$  mm in the SP group, compared to  $6.75 \pm 0.41$  mm and  $8.8 \pm 0.41$  mm in the AAC group. The post-operative CLD for the SP group was  $5.8 \pm 0.66$  mm and  $4.4 \pm 0.17$  mm and  $6.8 \pm 0.34$  mm, and  $4.4 \pm 0.08$  mm in the AAC group. The lid contour was better preserved in patients who received a SP at every follow-up visit.

**Conclusion:** Upper eyelid reconstruction using SP or AAC demonstrated similar MRD1, LPS action, PFH, and CLD but SP offered superior lid contour. Pre-made SP decreases intra-operative time, provides faster recovery, and eliminates risk of disease transmission compared to AAC. SP is also readily available and at a lower cost compared to other tarsal substitutes available. SP offers excellent functional and cosmetic outcomes in upper eyelid reconstruction and may be more advantageous than ACC, especially in resource-poor areas

PP-638

**Frequency and Treatment Outcome of Postoperative Wound Infection after Surgical Procedures on eyelids**M Idris.

**Objective:** To determine the frequency and treatment outcome of postoperative wound infection after surgical Procedures on eyelids.

**Methods:** Operative reports from operation theatre register were used as tool to determine no of eyelid surgeries performed and frequency of reported postoperative wound infection if any were recorded along with final treatment outcome of infection. The author retrospectively reviewed the reported cases of infections after all eyelid surgeries performed between January 1, 2014 and December 31, 2019 at Oculoplastics service of Ophthalmology Department, Lady Reading Hospital, Medical Teaching Institute (MTI), Peshawar. Exclusion criteria include infected cases prior to surgery, diabetic, age more than 80 and any history of systemic or eyelid infection. Patients were followed from day one to a maximum of day 180.

**Results:** A total of 1075 patients underwent eyelid procedures. There were only three reported cases of postoperative infection (0.27%). One dacryocystorhinostomy surgery (redo surgery), a case of levator resection with frost suture which got infected and third case of a frontalis sling patient which got infection. These all cases were treated with systemic antibiotics and underwent an uncomplicated recovery without any complications.

**Conclusion:** The infection rate in clean cases of eyelid surgery is extremely low and follow up is important to advise timely antibiotics if needed in selected cases only.

**PP-639****Reconstruction of Large Medial and Central Lower Lid Defects Using a Pendular Flap of The Residual Lateral Part.**Y Alahmadawy.

**Objective:** to evaluate the functional, cosmetic outcome and the degree of patients' satisfaction, in reconstruction of medial and central lower lid defects using a pendular flap of the remaining lateral part of the lower lid.

**Methods:** A retrospective case series study included 18 patients with isolated medial/ central lower lid defects either posttraumatic or after excision of lid tumors. Patients were included if the defect measured more than 1/3 of lid horizontal length up to 75%. A sliding pendular full thickness composite flap (skin, muscle and tarso-conjunctiva) was created from the lateral part of the remaining lid to cover the defect. Postoperative cosmetic and functional outcome were evaluated.

**Results:** All patients had an acceptable final cosmetic outcome as regard the lid position contour, continuity of the lash line. As regarding patients' satisfaction, all of the patients had positive score which means there was a significant benefit of the procedure and no one regret undergoing the surgery. Three patients developed lid retraction 23.1%, only one patient had minimal lagophthalmous that required re-surgery by medial canthopexy (7.7%). The other two had insignificant retraction.

**Conclusion:** Reconstruction of medial/central lower lid defects by this technique showed an acceptable cosmetic and functional outcome together with high patients' satisfaction

PP-640

**Choroidal thickness in severe congenital ptosis with amblyopia**Z Weiwei, R xiaoxia<sup>1</sup>, W jingjing<sup>1</sup>, C Min<sup>2</sup>.<sup>1</sup>Shanxi Eye Hospital, Taiyuan, People's Republic of China, <sup>2</sup>Shanxi Eye Hospital, Taiyuan, Paraguay

**Objective:** To measure the choroidal thickness (CT) in the macular area of patients with amblyopia in severe congenital ptosis and to compare the CT with that of without amblyopia.

**Methods:** Total of 83 eyes of 60 severe congenital ptosis patients were enrolled from January to October in the year 2019 in the Shanxi Eye Hospital, including 37 eyes with amblyopia and 46 eyes without amblyopia. 37 eyes of 37 normal people were included in the control group. All subjects underwent mydriatic optometry and the spherical equivalent (SE) was calculated. IOL-Master was used to measure the axial length (AL), and EDI-OCT was used to measure the CT in the macular area. The CT was measured at 13 points: directly beneath the fovea (SFCT) and at 1 mm, 2 mm and 3 mm intervals to the nasal, temporal, superior and inferior to the fovea. The points of CT measurements are named according to their positions and distances relative to the fovea, and represented by SFCT, N1, N2, N3, T1, T2, T3, S1, S2, S3, I1, I2, I3 respectively. The SE, astigmatism, AL and CT at each point were compared among the groups. The corrected AL covariance analysis was used to compare the CT at different measurement points among the groups. Spearman rank correlation analysis was used to evaluate the correlation between CT and AL or SE.

**Results:** The SE and absolute astigmatism value was larger, and the AL was shorter in the amblyopia group than that in the non-amblyopia group and control group. Except for I3, the CT of the rest parts in the amblyopia group were greater than that in the non-amblyopia group and the control group. Except for S3 and I3, the CT of the rest parts in the amblyopia group were greater than that in the non-amblyopia group and the control group after adjusting the AL. In three groups, the CT was high in the subfovea and was thin the nasal. The SFCT was negatively correlated with AL (amblyopia group:  $r_s = -0.340$ ,  $P = 0.045$ ; non-amblyopia group:  $r_s = -0.340$ ,  $P = 0.020$ ; control group:  $r_s = -0.463$ ,  $P < 0.001$ ) and positively correlated with SE (amblyopia group:  $r_s = 0.350$ ,  $P = 0.039$ ; non-amblyopia group:  $r_s = 0.412$ ,  $P = 0.004$ ; control group:  $r_s = 0.450$ ,  $P = 0.005$ ) in each group. Age was the influencing factor of AL in the non-amblyopia group and the control group ( $\beta = 0.243, 0.225$ ; both at  $P < 0.001$ ).

**Conclusion:** In comparison with severe congenital ptosis without amblyopia, the SE and absolute astigmatism degree are larger, the AL is shorter, and the CT at most areas are higher in the severe congenital ptosis with amblyopia. CT may be associated with the development of amblyopia in severe congenital ptosis.

**PP-641****Shallow periorbital injection of triamcinolone acetonide in treatment of lower eyelid entropion related to thyroid associated opht**

D Xu.

**Objective:** Entropion and secondary trichiasis can lead to irritative symptoms and essential damage of ocular surface. There are few treatment modalities treating entropion related to TAO. Treatment based on etiology may yield effective and sustained results. We reviewed 15 patients suffering from lower eyelid entropion associated with TAO, who undergo the administration of shallow periorbital

injections of triamcinolone acetonide (TA).

**Methods:** literature review and retrospective analysis of patient documents who received shallow periorbital injections of TA to the affected eye at 3- to 4-week intervals depending on clinical response.

**Results:** of the 15 patients, 10 patients completely recovered with shallow periorbital injection of TA. 1 eye of 1 patient improved, the other eye remained unchanged. 4 patients didn't feel any improvement.

**Conclusion:** Shallow periorbital injection of TA is an effective and simple method treating lower eyelid entropion related to TAO, which is long-lasting. The mechanism is probably related to the immunoinflammatory reaction of the lower eyelid retractors, enhancing the traction of pulling the lower eyelid inferoposteriorly. This hypothesis should be testified with histological pathophysiology of lower eyelid entropion related to TAO.

PP-642

**Application of 3D printing technology combined with absorbable materials in orbital wall fractures**H liao<sup>1</sup>, Y wang<sup>1</sup>, J Yu, C xiong<sup>1</sup>, Q xu<sup>1</sup>.<sup>1</sup>Affiliated Eye Hospital of Nanchang University, Nanchang, Chad

**Objective:** To investigate the clinical effect of 3D printing technology combined with absorbable materials in the treatment of orbital blowout fractures.

**Methods:** The clinical data of patients with orbital blowout fractures who were treated in Nanchang University Affiliated Eye Hospital were prospectively collected. According to different repair materials, they were randomly divided into titanium mesh group, medpro titanium mesh group and absorbable material group, a total of 60 patients. All patients used 3D printing technology to print out the orbital fracture model and implant guide model matching the patient before surgery, and the 3D model was used to assist repair material trimming and shaping during surgery. Preoperative and postoperative diplopia, eye movement disorders, proptosis and postoperative complications were recorded. All data were analyzed using SPSS statistical software.

**Results:** After orbital fracture reconstruction assisted by 3D printing technology in all patients, diplopia (Z values were -2.794, -2.723, -2.901, P values were all less than 0.05), eye movement disorders (Z values were -3.012, -3.236, -3.527, P values were all less than 0.05) and proptosis (Z values were -7.014, -6.983, -6.970, P values were all less than 0.05) and other symptoms were significantly improved. The postoperative complication rate was relatively low in the absorbable material group.

**Conclusion:** The clinical effect of 3D printing technology in the treatment of orbital fractures is good. Complications from absorbable prosthetic materials are likely to be fewer.

PP-643

**CLINICAL TREND ANALYSIS STUDY Of ORBITAL CELLULITIS In NORTH INDIA: A 15 YEARS EXPERIENCE**A Maharana, A Kaur<sup>1</sup>.<sup>1</sup>*ophthalmology, King George's Medical University, Lucknow, India*

**Objective:** The authors present a trend analysis study of orbital cellulitis treated at a medical university hospital over 15 years

**Methods:** Computerised records of 240 consecutive patients of orbital cellulitis treated between February 2006 to February 2020, were analysed for etiology, clinical presentation and blood profile. First consult at this hospital was labelled Primary, initial treatment elsewhere was labelled Secondary. The study period was divided into three consecutive, five-year periods. Failure to aspirate abscess was regarded as 'DRY TAP'. Chi-square tests were used for analysis.

**Results:** Painless residual proptosis displaced the classical painful proptosis in clinical profile, shifting trend towards the secondary presentation. Etiologically decreasing trend in post-sinusitis cases and increasing trend in post dental infection cases was seen. Cases with increased lymphocyte counts matched the trend towards painless residual proptosis. The study also highlights a positive correlation between secondary presentation with 'dry tap'.

**Conclusion:** The study reflects importance of initiation and continuation of adequate therapy of orbital cellulitis, in avoiding a protracted course of the disease and its related sequelae. The study bears further relevance in the establishment of robust primary health care services in developing nations to avoid the socio-economic burden that goes along with incompletely resolved diseases.



PP-644

**Outcome of Revision External Dacryocystorhinostomy with and without Mitomycin C**F Afrin, S Sultana<sup>1</sup>, R Rashid<sup>1</sup>, F Afzal<sup>1</sup>.<sup>1</sup>Ispahani Islamia Eye Institute and Hospital, Dhaka, Bangladesh**Objective:** To compare the outcome of revision external dacryocystorhinostomy with and without mitomycin C**Methods:** This prospective interventional study was conducted over 30 diagnosed patients with failed external dacryocystorhinostomy come to Oculoplasty clinic at Ispahani Islamia Eye Institute and Hospital. Detail history was taken from the selected patients. They were undergo revision external dacryocystorhinostomy surgery with and without mitomycin C. All the patients were followed up to 6 months. Data was checked, cleaned & edited properly before analysis. Ethical approval was taken from ethical committee of Ispahani Islamia Eye Institute and Hospital, Dhaka**Results:** Maximum (40.0%) of the patients were 41–50 age group in Group A (Mitomycin C) and 40.0% in 41-50 age group in Group B (without Mitomycin C). The mean age was  $40.3 \pm 9.3$  and  $41.5 \pm 10.3$  years in Group A and Group B respectively. There were 7(46.7%) males and 8(53.3%) females in Group A. 6(40.0%) males and 9(60.0%) females in Group B. Age and gender matched within groups. Out of 30 patients 18(60%) had left sided and 12(40%) had right sided failed dacryocystorhinostomy. In present study most of the patients had no complications in both groups. Only one patient had resolving corneal epithelia defect in mitomycin C group. Post-operative care and follow up were done identically in both the groups. After six months follow up 93.3% patients had success in revision external DCR with mitomycin C group and 66.7% patients had success in revision external DCR without mitomycin C group.**Conclusion:** Mitomycin C has beneficial effect in preventing reclosure of the dacryocystorhinostomy stoma after revision external dacryocystorhinostomy and no significant complications resulted from its use.

PP-645

**Clinical Analysis of Hyaluronic Acid Injection to Correct Enophthalmos of Orbital Fracture**X Zeng<sup>1</sup>, W Lu<sup>1</sup>.<sup>1</sup>The second hospital of Dalian medical university , Dalian, People's Republic of China**Objective:** To analyze the clinical outcomes of hyaluronic acid injection to correct enophthalmos of orbital fracture.**Methods:** Clinical data of orbital fractures diagnosed at the Second Hospital of Dalian Medical University between September 2014 and September 2016 were retrospectively analyzed. All these 21 cases received hyaluronic acid injection to correct enophthalmos. Efficacy of the treatment was assessed by reviewing CT scans as well as clinical manifestations of enophthalmos, visual acuity with a 6-12 (average 8.9) months follow-up.**Results:** Before injection, the average degree of enophthalmos is 2.67 ( $\pm 0.53$ ) mm, 1 week after injection, 20/21 (95.2%) cases of enophthalmos were precisely corrected, the average degree of enophthalmos is 0.57 ( $\pm 0.48$ ) mm, 6 months after injection, 4/21 (19.1%) cases recurred, in 17/21 (80.9%) cases, the hyaluronic acid was partly absorbed, the average degree of enophthalmos is 1.48 ( $\pm 0.53$ ) mm. There was significant difference in the degree of exophthalmos among three groups ( $F = 31.861$ ,  $P < 0.01$ ), and Pairwise comparisons were statistically significant (preoperative and postoperative 1 week,  $t = -30.817$ ,  $P < 0.05$ ; preoperative and postoperative 6 months  $t = -18.763$ ,  $P < 0.05$ ; postoperative 1 week and postoperative 6 months  $t = 11.708$ ,  $P < 0.05$ ).**Conclusion:** Intra orbital hyaluronic acid injection can correct enophthalmos effectively. This method is convenient, does less damage to the patients, also can avoid the risk of implant exposure or infection. During the injection, visual acuity and the eye globe movement can be evaluated simultaneously, the amount of hyaluronic acid can be decided based on the eyeball position, consequently enophthalmos can be corrected more precisely.

PP-647

**Novel bicanalicular intubation technique for lacrimal canalicular laceration: Kivanç's Loop.**S Kivanç, B Akova<sup>1</sup>.<sup>1</sup>*Uludag University, Bursa, Türkiye*

**Objective:** Monocanalicular intubation is one of the methods frequently used in lacrimal canaliculi injuries. MiniMonoka silicone tube can be used for this purpose. Another method is bicanalicular silicone tube intubation using a pig tail probe. However, in situations that put our world in a difficult situation such as a pandemic or war, there may be difficulties in accessing these equipments, and there are also difficulties and complications caused by the implementation of these procedures. Here we describe a new bicanalicular intubation technique and we believe that we also contribute to sustainability with the new technique we describe.

**Methods:** During the pandemic period and after pandemic, at the time of Ukrainian war that happened north of our country, the prices of health equipment have increased a lot and there has been a limited amount of some equipments available to our clinic. Our department is the tertiary center serving nearly 10 million people in the South Marmara region in terms of Eye Traumas. In our clinic, the pig tail probe is also not used due to the damage it may cause to the lacrimal canaliculi. We needed to develop a novel loop technique which we called Kivanç's Loop.

**Results:** This bicanalicular intubation technique was used 5 times successfully. No complication was observed. Remove of the silicone tube under the biomicroscopy was very easy.

**Conclusion:** This new technique is an alternative, inexpensive and sustainable method that can be used if there is shortage for lacrimal surgery equipments.

PP-648

**Preliminary clinical analysis of high intraocular pressure in extraocular hypertrophic thyroid-associated ophthalmopathy**H Sun, W lu.

**Objective:** To investigate the mechanism of high intraocular pressure (IOP) in extraocular muscle hypertrophic thyroid associated thyroid-associated ophthalmopathy (TAO) patients

**Methods:** Data of TAO patients with extraocular muscular hypertrophy diagnosed in the Second Hospital of Dalian Medical University from September 2017 to September 2018 was retrospectively analyzed. 36 eyes of 25 patients were enrolled whose IOP was higher than 21 mmHg in forward, upward, downward, inward or outward position of single or double eyes. The IOP of 36 eyes at five ocular positions was recorded. The absolute value of the difference between the minimum IOP and the IOP of other ocular positions was calculated and statistically analyzed. Meanwhile, the maximum cross-sectional area of each extraocular muscle was measured to analyze the relationship between IOP and antagonism of extraocular muscle hypertrophy in TAO patients with extraocular muscle hypertrophy at different ocular positions. 5 patients underwent binocular orbital decompression and 4 patients underwent binocular strabismus correction surgery, the IOP of each ocular position was recorded one month after operation. The preoperative IOP and postoperative IOP was statistically analyzed

**Results:** The absolute value of the difference between the minimum IOP in five ocular positions and the IOP in other ocular positions was statistically significant ( $P=0.027 < 0.01$ ). There was also a significant correlation between the IOP in the second ocular position and the maximum cross-sectional area of antagonistic extraocular muscles (correlation coefficient  $r = 0.464$ ). The difference of IOP in different positions before and after orbital decompression surgery has statistical significance ( $t=8.19, P < 0.01$ ). The absolute difference between the minimum IOP in five ocular positions and the IOP in other ocular positions after operation was statistically significant ( $P=0.046 < 0.05$ ). The difference of IOP in different positions before and after strabismus surgery has statistical significance ( $t=5.41, P < 0.01$ ). The absolute difference between the minimum IOP in five ocular positions and the IOP in other ocular positions was not statistically significant ( $P=0.427 > 0.05$ ).

**Conclusion:** The IOP of TAO patients with extraocular muscular hypertrophy is related to ocular position alteration, which is directly related to the antagonistic muscular hypertrophy. Orbital decompression and strabismus surgery can effectively reduce IOP.

PP-649

**Preliminary clinical analysis of high intraocular pressure in extraocular hypertrophic thyroid-associated ophthalmopathy**H Sun, W lu.

**Objective:** To investigate the mechanism of high intraocular pressure (IOP) in extraocular muscle hypertrophic thyroid associated thyroid-associated ophthalmopathy (TAO) patients

**Methods:** Data of TAO patients with extraocular muscular hypertrophy diagnosed in the Second Hospital of Dalian Medical University from September 2017 to September 2018 was retrospectively analyzed. 36 eyes of 25 patients were enrolled whose IOP was higher than 21 mmHg in forward, upward, downward, inward or outward position of single or double eyes. The IOP of 36 eyes at five ocular positions was recorded. The absolute value of the difference between the minimum IOP and the IOP of other ocular positions was calculated and statistically analyzed. Meanwhile, the maximum cross-sectional area of each extraocular muscle was measured to analyze the relationship between IOP and antagonism of extraocular muscle hypertrophy in TAO patients with extraocular muscle hypertrophy at different ocular positions. 5 patients underwent binocular orbital decompression and 4 patients underwent binocular strabismus correction surgery, the IOP of each ocular position was recorded one month after operation. The preoperative IOP and postoperative IOP was statistically analyzed.

**Results:** The absolute value of the difference between the minimum IOP in five ocular positions and the IOP in other ocular positions was statistically significant ( $P=0.027 < 0.01$ ). There was also a significant correlation between the IOP in the second ocular position and the maximum cross-sectional area of antagonistic extraocular muscles (correlation coefficient  $r = 0.464$ ). The difference of IOP in different positions before and after orbital decompression surgery has statistical significance ( $t=8.19, P < 0.01$ ). The absolute difference between the minimum IOP in five ocular positions and the IOP in other ocular positions after operation was statistically significant ( $P=0.046 < 0.05$ ). The difference of IOP in different positions before and after strabismus surgery has statistical significance ( $t=5.41, P < 0.01$ ). The absolute difference between the minimum IOP in five ocular positions and the IOP in other ocular positions was not statistically significant ( $P=0.427 > 0.05$ ).

**Conclusion:** The IOP of TAO patients with extraocular muscular hypertrophy is related to ocular position alteration, which is directly related to the antagonistic muscular hypertrophy. Orbital decompression and strabismus surgery can effectively reduce IOP.

**PP-650****Progranulin (PGRN) inhibited Th1 and Th17 in thyroid associated ophthalmopathy**L Wang, C Wang.

**Objective:** To investigate whether PGRN plays a role in the pathogenesis of TAO and how it affects Th1 and Th17 immune response.

**Methods:** A collection of 27 patients with active TAO without steroids and radiotherapy, 59 healthy individuals cted as controls were included in the study. After cell cultures and human Th17cell polarization, the cell were obtained for intracellular cytokine detection by flow cytometry. Compare the gene and protein expression of PGRN in serum of TAO patients and normal controls. Isolated PBMCs were stimulated with or without PGRN in presence of anti-CD3 and anti-CD28 antibodies for 72h, then the cells were collected for flow cytometry.

**Results:** The protein expression of PGRN was significantly decreased in TAO active patients as compared to normal controls, which is in consistent with the mRNA data.PGRN downregulated TNF  $\gamma$  and IL-17 by PBMCs and CD4+ T cells activated by anti-CD3 and anti-CD28 antibodies in TAO patients and normal controls.

**Conclusion:** PGRN directly inhibited CD4<sup>+</sup>T cells to specifically differentiate into Th1 and Th17 populations in TAO.

**PP-653****Analysis of MYB protein expression and molecular genetic characteristics in lacrimal adenoid cystic carcinoma**

H Liu.

**Objective:** To investigate the expression and molecular genetic characteristics of MYB in adenoid cystic carcinoma (ACC).

**Methods:** 16 cases of lacrimal gland ACC were collected, besides, collecting 20 cases of lacrimal gland non-ACC tumors as controls. Immunohistochemistry of EnVision method and fluorescence in situ hybridization (FISH) were used to detect MYB protein expression and MYB gene translocation in lacrimal gland ACC. At the same time, we analyzed the pathological and genetic characteristics of lacrimal gland ACC and reviewed the literature.

**Results:** The 16 patients with ACC were 19 to 74 years old, with the average age of 49 years. The male to female ratio was 5:11. The tumor's largest diameter was 0.8 to 4.5 cm, with an average of 2.6 cm. The tumor tissue was mainly composed of ductal cells and myoepithelial cells, forming a tube, which was the sieve-like and solid structure with basophilic mucus-like substance and nerve invasion. According to the pathological classification, 5 cases are grade I that they are mainly tubular or cribriform structure, without solid components. 9 cases of grade II have tubular, sieve and solid components, which the solid content is  $\leq 30\%$ . 2 cases of grade III, which have tubular, sieve and solid components and the solid content is  $>30\%$ . The positive expression rate of MYB protein is 100% (16/16) which was detected by immunohistochemistry. It was shown that 5 cases are strong positive and 11 cases are moderately positive. The positive rate of MYB gene translocation detected by FISH was 87.5% (14/16), while 2 cases with negative FISH test show moderate positive expression by immunohistochemistry.

**Conclusion:** Lacrimal ACC is prone to local recurrence or distant metastasis in the eye. MYB protein has a high expression rate in the lacrimal ACC. The detection of MYB by immunohistochemistry and FISH is helpful to make the differential diagnosis between lacrimal ACC and other diseases.

PP-654

## A Riveting Pictorial Case Series On Angio-Invasive Rhino-Orbital-Cerebral-Mucormycosis & It's Sequelae In A Regional eye hospital

S Ramavath<sup>1</sup>, S Ramavath<sup>1</sup>.

<sup>1</sup>ophthalmology, REGIONAL EYE HOSPITAL, KURNOOL, Kurnool, India

**Objective:** Rhino-orbital-cerebral mucormycosis is a rare angio-invasive, life-threatening fungal infection resulting from the zygomycete of the order- Mucorales. The aim was to study the distribution, causative organisms, clinical manifestations & the complications of Rhino-orbital-cerebral mucormycosis.

**Methods:** A study was conducted on 100 patients diagnosed with mucor at a regional eye hospital. The mean age was (49.82 ± 11.9). 70% were males. 81% recovered from covid. 93% were diabetics. 91% of species isolated were Mucor.spp followed by 4% Aspergillus.spp & 3% of Rizhopus.spp & 2% of candida.spp  
Clinical features seen were defective vision, periorbital edema, ptosis, proptosis, ophthalmoplegia etc. All patients underwent RT-PCR, routine blood investigations, MRI & C.T, nasal mucosal endoscopy & histopathological examination. After confirmed with fungal elements Patients were started on systemic Amphotericin-B & Posaconazole without delay. Functional Endoscopic Sinus Surgery (FESS) was done. Exenteration was done for cases with poor prognosis. we present a case series of 8 patients out of a 100 cases that were unique like Rhino-orbital-cerebral-mucormycosis occurring in children, coexisting with plexiform neurofibroma and lacrimal gland tuberculosis, herpes zoster ophthalmicus & the sequelae of the disease.

**Results:** Majority presented with ophthalmoplegia (93%), exposure keratitis (83%) followed by orbital cellulitis (81%) & cerebral involvement (69%). Other complications seen were optic neuritis, retinal detachment, central retinal artery occlusion, visual field defects, cavernous sinus thrombosis, scleral abscess etc. Covid patients who recovered had a high risk of developing meningitis ( $p = 0.004$ ) due to mucor. Patients with cavernous sinus thrombosis ( $p = 0.008$ ), cerebral abscess ( $p = 0.007$ ) should be treated early as they worsened at later stages & required exenteration.

**Conclusion:** A high index of clinical suspicion, early diagnosis by a diagnostic nasal endoscopy and direct microscopy of the high nasal swab or an endoscopically guided nasal swab, supported by contrast-enhanced MRI or CT scan, initiation of full-dose liposomal Amphotericin B & continued step-down oral antifungals may help optimize the outcome of ROCM in the setting of COVID-19. As INDIA is a Diabetic capital & there is a high risk of ROCM in diabetics, prophylactic control of blood sugars along with appropriate multi-disciplinary approach we can curb this diabetic doom!



PP-655

**Effects of total flavonoids of chrysanthemum on NF- $\kappa$ B/HIF-1 $\alpha$  in H<sub>2</sub>O<sub>2</sub>-injured lacrimal gland epithelial cells**J Shi<sup>1,2</sup>, Q Liu<sup>2,3</sup>, X Yao<sup>2,4</sup>.

<sup>1</sup>Hunan University of Chinese Medicine, <sup>2</sup>Hunan Provincial Key Laboratory for Prevention and Treatment of Ophthalmology and Otolaryngology Diseases with Chinese Medicine, <sup>3</sup>Hunan University of Chinese Medicine, <sup>4</sup>The First Hospital of Hunan University of Chinese Medicine, Changsha, People's Republic of China

**Objective:** The effects of chrysanthemum total flavonoids on NF- $\kappa$ B, HIF-1 $\alpha$ , BNIP3 and TRAIL in lacrimal gland epithelial cells of H<sub>2</sub>O<sub>2</sub> were observed.

**Methods:** Rat tear gland epithelial cells were primary isolated and H<sub>2</sub>O<sub>2</sub> was simulated as a model of oxidative damage of tear gland epithelial cells in dry eyes. Chrysanthemum total flavonoids, NF-B blocker (BAY11-7082) and activator (BAY11-7085), HIF-1 blocker (KC7F2) and activator (Molidustat) were added to the intervention. Specific groups are: A. control group; B. model group; C. chrysanthemum flavonoids group; D.NF- $\kappa$ B blocker group; E.NF- $\kappa$ B activator group; F.HIF-1 $\alpha$  blocker group; G. HIF-1 $\alpha$  activator group. Cell proliferation was measured by CCK-8, apoptosis was measured by flow, and apoptosis was measured by TUNEL staining. WB test measured the cellular HIF-1 $\alpha$ , NF- $\kappa$ B, BNIP3, TRAIL protein expression.

**Results:** CCK-8 results showed that H<sub>2</sub>O<sub>2</sub> significantly inhibited cell proliferation, and the suitable dose was 200  $\mu$ M, the action time was 2h, and the serum content of flavonoids containing drug was 5%. The BAY11-7082 dose was selected as 1  $\mu$ M. The BAY11-7085 dose was selected as 1  $\mu$ M and the KC7F2 dose as 5  $\mu$ M. The Molidustat dose was chosen as 10  $\mu$ M; Apoptosis and cycle of each group were detected by flow. The apoptosis rate of group B cells was increased significantly compared with group A (P <0.05). Compared with group B, the apoptosis rate was no significant change in group F, and the apoptosis rate decreased in all relative model groups (P <0.05); WB test showed that the protein expression of HIF-1 $\alpha$ , NF- $\kappa$ B, BNIP3, and TRAIL were all significantly up-regulated in the model group compared with group A (P <0.05). Compared with group B, all the four proteins were downregulated in group C (P <0.05).

**Conclusion:** Chrysanthemum total flavonoids effectively alleviated oxidative damage in rat lacrimal gland epithelial cells caused by H<sub>2</sub>O<sub>2</sub>, and the mechanism of action may be downregulation of NF- $\kappa$ B / HIF-1 $\alpha$  pathway, thus inhibiting the activation of BNIP3 and TRAIL downstream of HIF-1 $\alpha$ .

PP-656

## EXPERIENCE FROM OCULOPLASTIC PRACTICE AT TIMES OF COVID-19 PANDEMIC IN A TERTIARY CARE CENTRE: PRECAUTIONS AND CHALLENGES

M Idris.

**Objective:** To share our experience from oculoplastic practice at times of covid-19 pandemic in a tertiary care centre with precautions and challenges.

**Methods:** short communication

**Results:** Among the specialties with high risk of getting the infection is ophthalmology including orbit and oculoplastics. There is high risk of cross infection in Ophthalmology especially orbit and oculoplastics for their lengthy surgical reconstructive procedures notably tumors and trauma. Our experience in the past two years, dealing with eyelid lacerations, orbital cellulitis, patients with very large and advanced tumors and as well as inflammatory condition like acute cases of thyroid orbitopathy . We share some safe strategies for prevention and safety of both patients and the health care providers in the operation room:

- 1- Use surgical loupe in place of microscope during surgery from a safe distance.
- 2- Try to operate under local anesthesia as General Anesthesia (GA) is associated with aerosol transmission during and after anesthesia induction.
- 3- Awareness of patients regarding the role of Tele medicine should be promoted; this is important in non urgent oculoplastics procedures like chronic dacryocystitis CDC or small eyelid tumors.CDC patients can be instructed to use antibiotic and manual cleaning of blocked duct.
- 4- Oculoplastic procedures are lengthy and dangerous at present scenario examples include exenteration surgery for large tumors or extensive eyelid lacerations. (figure 1a,c and d). Try to finish as quickly as possible with minimum or careful use of cautry as it is also responsible for aerosol transmission containing organisms of COVID-19.

5- Try to reschedule non urgent cases. According to Our experience at Lady Reading Hospital, most of the patients understood for rescheduling their appointment because the problem of being chances of infection to both surgeon and patient.

**Conclusion:** the decision of selecting the right patient at present pandemic is crucial and challenging stressing the need for extra cares especially during long surgical procedures. Although emergency cases are rare but these are the real challenges for an Oculoplastic surgeon.

PP-657

**A Disguised Giant - Orbital Langerhans Cell Histiocytosis**

M Abrar, A Yogeswari<sup>1</sup>, S R<sup>1</sup>.

<sup>1</sup>*Orbit & Oculoplasty, Regional Institute of Ophthalmology, Chennai, Chennai, India*

**Objective:** To highlight the varied presentation of Langerhans Cell Histiocytosis

**Methods:** A 2-year-old male child was referred from a PHC as a case of suspected malignant lesion of the left upper lid. The father gives a history of swelling in left upper lid for the past 2 weeks insidious in onset and gradually progressing in size. History of fever which resolved a week prior to onset of swelling was present. After clinical examination, a CT was done & reported a soft tissue swelling 19.3x13.5mm in left orbit involving & extending into extraconal space. Provisionally diagnosed as Rhabdomyosarcoma, the patient was worked up in coordination with a pediatric oncologist.

**Results:** A left anterior orbitotomy with excision of mass done and sent for biopsy. HPE & Immunohistochemistry with CD1a & S100 stains, confirmed it as a case of Langerhans Cell Histiocytosis-Eosinophilic Granuloma. The child was further managed conservatively & close follow up showed no recurrence

**Conclusion:** A high index of suspicion should be maintained in such cases & should be supplemented with histological analysis & imaging

PP-658

**Rosai Dorfman Disease : Review of a Case Non-responsive to Multiple Chemotherapeutic Regimes**S Iyengar<sup>1</sup>, P Shetty<sup>2</sup>.<sup>1</sup>resident, <sup>2</sup>oculoplasty, Khan Bahadur Haji Bachooali Ophthalmic and ENT charitable hospital, Mumbai, India

**Objective:** Rosai Dorfman disease is a rare benign tumor characterized by an abundance of histiocytes. Typically it manifests as painless lymphadenopathy, but extranodal orbital disease may occur with or without lymph node involvement causing symptoms of exposure, diplopia and optic nerve compression in severe cases. It is commonly found in children and young adults. Typically steroid responsive, chemotherapeutic and immunomodulatory agents may be used in cases of long duration of treatment. Surgical management may be used to relieve ophthalmic symptoms and improve quality of life. This case aims at evaluating treatment modalities including chemotherapy and surgical management.

**Methods:** A case of Rosai Dorfman disease, non-responsive to chemotherapy was reported. Patient came with complaints of B/L lower lid mass. On examination firm-hard, non tender mass was palpable over lower lids approximately measuring (5x5x3 cm). On CECT B/L lower lid and orbital soft tissue mass measuring (5.7x5x2.4 cm) on the right side and (5.7x5x3.2 cm) on the left, extending till the orbital apex and ipsilateral cheeks through infraorbital fissure with extension into the right parasellar area was noted. The patient was treated with multiple chemotherapeutic regimes (vinblastin, etoposide, imantinib, celecoxib, Lenolidomide) along with systemic steroids (prednisolone, dexamethasone) with gradual progression of the disease. The patient was eventually managed surgically with bilateral lower lid and orbital mass debulking through inferior lid crease incision due to progression of the disease over 9 years and failure of response to chemotherapy. On IHC The histiocytes stain with S100 and focally for CD163 while CD1a is negative. The patient was discharged on tablet lenolidomide and tapering dose of steroids. A good cosmetic outcome was achieved.

**Results:** Failure of response to chemotherapy was seen in this case with progression of the disease over the course of 9 years. Surgical excision, though challenging, improved the quality of life.

**Conclusion:** Although chemotherapy still stands as the first line of treatment in Rosai Dorfman Disease, which may help resolve the lesions or slow down progression in a vast number of cases surgical management may be considered to prevent secondary symptoms and to improve the quality of life.

PP-659

**Treatment for an unusual case of ptosis**D Anak Intan<sup>1</sup>, G Yong<sup>2</sup>, C Chua<sup>3</sup>.<sup>1</sup>Ophthalmology, <sup>2</sup>Ophthalmology, Hospital Umum Sarawak, <sup>3</sup>Ophthalmology, ISEC, Kuching, Malaysia

**Objective:** To describe an unusual case of ptosis caused by silent sinus syndrome treated with orbital floor hyaluronic acid and ptosis surgery.

**Methods:** A 37-year-old man was referred because of right ptosis of three years duration. Examination revealed good levator function with a deep upper sulcus. Because the patient complained the right globe felt sunken, Hertel exophthalmometry revealed right enophthalmos with a reading of 17mm for the right eye and 19mm for the left eye. An MRI revealed increased right orbital volume and the presence of right maxillary sinusitis.

2 ml of hyaluronic acid (Neuramis deep) was injected into the orbital floor via the inferotemporal approach using a 25-gauge needle. Subsequently, a posterior approach white line advancement ptosis repair was done.

**Results:** There was a significant improvement of the enophthalmos and a reduction of the deep upper sulcus after hyaluronic acid injection. However, there was an inadequate improvement of the ptosis. Thus, ptosis surgery was performed after that. However, after the surgery the lower lid remains higher than the other side further symmetry was achieved by Botox injection to the lower lid.

**Conclusion:** Silent sinus syndrome should be included in the differential diagnosis of ptosis, especially in patient with enophthalmos. Orbital floor filler is effective to improve enophthalmos and deep upper sulcus secondary to silent sinus syndrome. Ptosis surgery is required to correct residual ptosis.

PP-660

**A Rare Case of Orbital Inflammation in VEXAS Syndrome**H Oo<sup>1</sup>, W Chee<sup>1</sup>, K Lee<sup>1</sup>.<sup>1</sup>*Department of Ophthalmology, National Healthcare Group Eye Institute, Tan Tock Seng Hospital, Singapore, Singapore*

**Objective:** VEXAS syndrome (vacuoles, E1 enzyme, X-linked, autoinflammatory, somatic) is an X-linked autoinflammatory systemic condition in adulthood with dermatologic, rheumatologic and hematologic symptoms, caused by somatic mutations in UBA1 gene in hematopoietic progenitor cells. Ocular manifestations in VEXAS syndrome predominantly present in the form of uveitis, episcleritis, scleritis and iritis. Orbital inflammation is a rare presentation. We describe a case of 71-year-old male patient with VEXAS syndrome presenting with orbital inflammation.

**Methods:** A 71-year-old Chinese male presented to our institution with four days of binocular oblique diplopia and unilateral retrobulbar pain. He was diagnosed with VEXAS syndrome three years ago and was on treatment with oral corticosteroids and immunosuppressants at the time of presentation. Visual acuity was 6/6 bilaterally and he had no clinical signs of intraocular inflammation. Examination showed a painless limitation of abduction and infraduction of right eye. Optic nerve function including colour vision, confrontational visual field, red desaturation, light brightness were intact. There was no relative afferent pupillary defect.

**Results:** Lab tests revealed raised inflammatory markers. Magnetic Resonance Imaging of Brain and Orbits showed mild thickening and enhancement of right superior rectus involving right orbital apex and bilateral inferior recti muscles with orbital fat stranding. His case was co-managed with Rheumatology and his symptoms improved after increasing oral corticosteroids dose. He was given spectacles with bangerter foil for symptomatic relief of diplopia.

**Conclusion:** VEXAS syndrome is a rare inflammatory disease entity. Orbital inflammation should be suspected and treated early in VEXAS syndrome to prevent significant disease morbidity.

PP-661

**Giant Cutaneous Horn of Upper Eyelid: A Rare Case Report**D Rani Mitra.

**Objective:** Cutaneous horn is a hyperkeratotic conical projection of the epidermis that resembles an animal horn, arising from parts of sun exposed area. Etiology is unknown but occurs in association with or as a response to a wide variety of underlying benign, premalignant and malignant cutaneous diseases. Objective of this case presentation is to present a rare case of giant cutaneous horn of upper lid that gave rise to malignancy.

**Methods:** A 65- year- old female presented with a giant wood like structure , 5 cmX 10 cm, over the anterolateral aspect of right upper lid, causing mechanical ptosis for the last 3 months. Visual acuity evaluation was not possible on presentation. In left eye it was 6/12 due to early lental opacity.No regional lymphadenopathy was found. Surgery was planned under local anesthesia.

**Results:** Margin clearance was done by frozen section biopsy. Wound was reconstructed with full thickness skin graft. Histopathology reported squamous cell carcinoma(low Grade)

**Conclusion:** Cutaneous horn is a premalignant condition which is not very rare. But few cases of giant cutaneous horn have been reported in literature presenting as squamous cell carcinoma.



PP-663

**A Fulminant First Presentation, Pediatric Orbital Abscess**

Y Alahmadawy<sup>1</sup>.

<sup>1</sup>*cairo university, cairo, Egypt*

**Objective:** presenting a case with pediatric orbital abscess

**Methods:** A 2 months old girl with periorcular redness followed by rapidly progressive proptosis. full-blown picture in few days. orbital imaging showed a medial space occupying lesion mostly an orbital abscess but without any identifiable cause. no trauma, no sinusitis.

mri with contrast was done meanwhile systemic antibiotics were prescribed

**Results:** marked improvement with starting medial canthal swelling appeared two days after giving the suspicion of acute dacryocystitis and lacrimal abscess.

Back again to imaging the lacrimal sac was seen swollen that was previously missed

**Conclusion:** a very rare condition, congenital nasolacrimal duct obstruction first presenting with the most fulminant complication

PP-664

**Novel gene mutation in Kabuki syndrome with multiple ocular manifestations**

Y Sun, T Zhao<sup>1</sup>, L Yang<sup>1</sup>, Y Xing<sup>2</sup>, J Hong<sup>1</sup>.

<sup>1</sup>Ophthalmology, <sup>2</sup>Pediatric, Peking University Third Hospital, Beijing, People's Republic of China

**Objective:** To describe a case of Kabuki syndrome (KS) with severe ocular manifestations that include Peter's anomaly, complicated cataract after penetrating keratoplasty (PKP), choroidal coloboma, melagopapilla and congenital microphthalmia, which had not been reported in a single case to our knowledge. We also report a novel gene mutation site of Kabuki syndrome in this special case.

**Methods:** This is a case report and review of the literature.

**Results:** A female patient was born with left corneal leukoma, anterior iris synechia and right side coloboma. PKP procedure was postponed twice because of recurrent systemic infections and was performed at the age of 8 months. Complicated cataract was observed and treated 23 months after PKP. Physical examinations and Systemic review revealed typical facial features of KS, bone abnormality, developmental delay, left kidney absence and patent foramen ovale. Gene analysis showed a de novo heterozygous pathogenic variant in KMT2D which confirmed the diagnosis of KS. The mutation site has never been reported to our knowledge.

**Conclusion:** We report a KS case with typical and severe ocular manifestations, though some of which had been reported, but in separated cases. A novel gene mutation site of KS is reported here.

PP-665

### Ocular findings in Two Chinese Children with Loeys-Dietz Syndrome

W Wang.

**Objective:** Loeys-Dietz syndrome (LDS) is a type of connective tissue disease with systemic symptoms similar to Marfan syndrome. Ocular findings are rarely reported especially fundus and extraocular muscles.

**Methods:** Ocular features of LDS were obtained by reviewing the two cases

**Results:** A 6-month old boy with systemic skeletal development delay was found peripheral non-perfusion and neovascularization in the both eyes, and given intravitreal injection of ranibizumab and laser. Fundus examination revealed a mild straightening of the temporal vessel in the both eyes. A 22-month old girl with confirmed connective tissue disorder presented to our hospital for strabismus and showed congenital hypoplasia of extraocular muscles. She also had arteriovenous anastomosis in the retinal. The diagnosis of LDS was supported by the genetic DNA examination.

**Conclusion:** This is the first report of LDS with congenital hypoplasia of extraocular muscles, meanwhile, ocular examination especially fundus should be paid attention to.

PP-666

### Comparison of Reading Speed in Patients with Strabismus versus Controls

D Lamoureux<sup>1</sup>, S Yeo<sup>2</sup>, V Bhambhwani<sup>1,3</sup>.

<sup>1</sup>Northern Ontario School of Medicine, Thunder Bay, <sup>2</sup>Faculty of Medicine, University of Ottawa, Ottawa, <sup>3</sup>Thunder Bay Regional Health Sciences Centre, Thunder Bay, Canada

**Objective:** Reading is an important visual task and affects numerous aspects of daily functioning. Research has indicated reading performance to be a strong predictor of visual ability and vision-related quality of life. Amblyopia has been shown to slow reading speed. However, there is paucity of literature regarding reading speed in individuals with strabismus without amblyopia. The purpose of our study was to compare reading speed in patients with childhood-onset strabismus without amblyopia and normal controls using the International Reading Speed Texts (IReST).

**Methods:** 48 participants were enrolled, including 12 patients with childhood-onset (onset <8 years of age) strabismus without amblyopia and 36 age- and education level-matched controls. Inclusion criteria were age 14-50 years, education level >9 years, primary language English, best corrected vision >20/30 distance and >N8 near in either eye. Exclusion criteria were presence of other eye conditions (other than refractive error), neurological/cognitive conditions including learning disabilities, which may impact reading speed. IReST charts were used to measure reading speed. Each participant was instructed to read two passages (passage 1 and 8) with a break of two minutes between passages, following all IReST chart instructions. Reading time was measured using a stopwatch. Reading speed in words per minute (WPM) was calculated as =  $(60/\text{participant reading time in seconds}) \times (\text{number of words in passage} - \text{skipped words} - \text{incorrect words})$ .

**Results:** Mean age for strabismus group was 28.3 +/- 11.1 and control group was 28.2 +/- 11.0 years (p=0.96). Mean education level for strabismus group was 14.2 +/- 2.4 years and control group was 13.8 +/- 2.5 years (p=0.62). Mean reading speed for passage 1 for strabismus group was 192.0 and for control group was 220.0 WPM (p=0.01). Mean reading speed for passage 8 for strabismus group was 201.3 and for control group was 226.2 WPM (p=0.04). There was some learning effect in both strabismus (p=0.04) and control (p=0.02) groups, with reading speed for passage 8 being faster than for passage 1.

**Conclusion:** In patients with childhood-onset strabismus without amblyopia, average reading speed was slower compared to age- and education-matched controls. This may be due to sub-optimal coordination of eye movements. Further studies with eye tracking may help gain more insight. Strabismus, even without amblyopia, may affect reading performance and consequently vision-related quality of life.

PP-667

**Blood parameters as diagnosis index for the Retinopathy of Prematurity in Chinese population**Y Li<sup>1</sup>, X Tian.

<sup>1</sup>*the Second Xiangya Hospital, Central South University, the Second Xiangya Hospital, Central South University, Chang sha, People's Republic of China*

**Objective:** To determine whether there is an association between blood parameters and retinopathy of prematurity (ROP).

**Methods:** A retrospective case-control study was conducted in a single large tertiary referral hospital in Central South China. The data of 19 neonates were excluded because of the lack of their information. Finally, three hundred and seven hospitalized neonates with gestational age (GA) <32 weeks and birth weight (BW) <2000 g from Oct 2012 to Dec 2021 were divided into three groups: Group 1 (133 premature infants without any evidence of ROP), group 2 (100 infants with Non-treatment-requiring ROPs, NTR-ROPs), Group 3 (74 treatment-requiring ROP infants, TR-ROPs). Demographic features, comorbidity data, laboratory parameters, and ocular examinations were collected. Blood parameters at the initial established diagnosis of ROP (in Group 2 and 3), and the most paired time point in Group 1 were compared, with fluctuation at birth, at 32 weeks, and the first ROP diagnosis were observed. Univariate analysis and multiple logistic regression were used to analyze the associations with ROP in neonates, and than ROC curves were used to access the sensitivity and specificity of these obviously changed parameters and the combined value of the parameters by binary logistic regression analysis.

**Results:** three hundred and seven infants were included in the study. Hemoglobin, Platelet, WBC, Eosinophil granulocytes, procalcitonin (PCT), Bronchopulmonary Dysplasia (BPD), and Necrotizing enterocolitis (NEC), gastrointestinal bleeding and the use of immunoglobulin were statistically significant in TR-ROP compared with NO ROP + NTR ROP groups, the combining of the 9 parameters could prognosticate the occurrence of TR ROP with AUC of 0.845, with the best value of the sensitivity and specificity of 72% and 84%. the trends of the blood parameters are shown during three periods, there are upward trends of Platelet and PCT, and during the period from 32 weeks to the time firstly confirmed with ROP, the data of the severe ROP group shows a steep elevatory. While a significant decline was observed from their birth to 32 weeks in TR ROP group.

**Conclusion:** Our data reveal that the statistical fluctuation of blood parameters and significant variance between early stages of ROP and the condition of infants with no ROP implicates the pathogenesis of ROP. Monitoring the occurrence of ROP through blood tests may be a calculated, widely available, and less suffering way to predict ROP development.

PP-668

**Macular OCT findings in patients with congenital nystagmus syndrome**O Nasser, W wahbi.

**Objective:** To describe the macular optical coherence tomography findings in eyes of patients with congenital nystagmus syndrome compared to healthy subjects.

**Methods:** In this comparative cross-sectional observational study, a spectral-domain optical coherence tomography was conducted on eyes of congenital nystagmus syndrome patients and compared with those of healthy individuals (control group). ETDRS macular map was used in the analysis and average thickness of central 6mm (C6T), average thickness of central 1mm (C1T) and thinnest central thickness (CRT) were obtained and compared between the groups. Prevalence and grading of foveal hypoplasia and albinism were assessed in the patients group.

**Results:** 46 eyes of 23 congenital nystagmus syndrome patients and 46 eyes of 23 healthy individuals were included in the study. 80% of the eyes in nystagmus group had foveal hypoplasia. The mean grade of foveal hypoplasia is  $3.45 \pm 0.9323$  in the above group. 40% of patients with nystagmus had either ocular albinism or oculocutaneous albinism. CRT was  $258.2 \pm 48.31 \mu\text{m}$  in the nystagmus group compared to  $189.3 \pm 24.25 \mu\text{m}$  in the control group with a mean difference of  $68.85 \pm 7.97 \mu\text{m}$  ( $P < 0.001$ ). C1T was  $267.2 \pm 36.01 \mu\text{m}$  in the nystagmus group compared to  $231.0 \pm 26.0 \mu\text{m}$  in the control group with a mean difference of  $36.20 \pm 6.548$  ( $P < 0.001$ ). C6T was  $256.2 \pm 26.15 \mu\text{m}$  in the nystagmus group compared to  $279.1 \pm 9.532 \mu\text{m}$  in the control group with a mean difference of  $-22.90 \pm 4.104 \mu\text{m}$  ( $P < 0.001$ ).

**Conclusion:** The results of this study show that the majority of congenital nystagmus syndrome patients have high grade foveal hypoplasia. There is a structural retinal abnormality with absence of foveal contour and pit. Macular optical coherence tomography can be used to assess the foveal thickness and grading of foveal hypoplasia patients with nystagmus.

PP-669

## Double-edged Roles of Family Dynamics in Chinese Adolescents with High Myopia and Mental Disorders during the COVID-19 Pandemic

Y Shao<sup>1</sup>, M Zhang<sup>2</sup>.

<sup>1</sup>Ophthalmology, Tongji hospital affiliated with Tongji University, <sup>2</sup>Psychiatry, Dongfang Hospital affiliated with Tongji University, Shanghai, People's Republic of China

**Objective:** During the COVID-19 pandemic, home confinement has led to an increase in the incidence of myopia and mental disorders among adolescents. Family dynamics, as an important manifestation of family environment, of which relationships with the occurrence and development of two problems are still unknown. This was the first study to explore the relationship between family dynamics and high myopia, as well as mental disorders including depression and anxiety symptoms.

**Methods:** A cross-sectional survey was conducted with a sample of 709 grade 10 and 11 high school students in Shanghai. Participants underwent routine eye examinations and completed a set of questionnaires that included questions on demographic characteristics, family dynamics (the Self-Rating Scale of Systemic Family Dynamics, SSFD [Chinese version 2]), anxiety (the Youth Anxiety Measure for DSM-5, YAM-5), and depression (the Childhood Depression Inventory, CDI). Univariate analysis was used to compare the differences in variables among myopia students (N=595) between mild-moderate myopia (MM) and high myopia (HM) groups. Binary multivariate regression models among myopia students were used to select independent variables for high myopia. The relationship between family dynamics and mental disorders was analyzed using correlation analysis and general linear regression.

**Results:** Parents' myopia history [odds ratios (OR)= 34.24; 95% confidence interval (CI): 8.24-142.18,  $P < 0.001$ ], native location [OR= 2.15; 95% CI: 1.06-4.34,  $P = 0.034$ ], and personalization in SSFD [OR= 1.11; 95% CI: 1.03-1.20,  $P = 0.009$ ] were independently positively associated with high myopia incidence. Anxiety and depression scores using the YAM-5 and CDI scales showed no significant correlation with high myopia ( $p > 0.05$ ). Family atmosphere and personalization scores in SSFD were negatively related to the YAM-5 ( $r_s = -0.180$ ,  $p < 0.001$ ;  $r_s = -0.154$ ,  $p < 0.001$ ). Family atmosphere, personalization, and disease concept scores in SSFD were negatively related to the CDI scores ( $r_s = -0.329$ ,  $p < 0.001$ ;  $r_s = -0.337$ ,  $p < 0.001$ ;  $r_s = -0.216$ ,  $p < 0.001$ ).

**Conclusion:** High myopia was not associated with anxiety and depression scores using YAM-5 and CDI scale. Family dynamics may play a double-edged role in decreasing the incidence of mental disorders but increasing the prevalence of high myopia. Interventions using family dynamics therapy to improve mental disorders among adolescents should be aware of the existence of the high myopia trap.

PP-670

**CLINICAL COURSE IN BILATERAL PEDIATRIC CYTOMEGALOVIRUS RETINITIS AND EFFICACY OF INTRAVITREAL GANCICLOVIR THERAPY**T Ögreden.

**Objective:** Review of pediatric cytomegalovirus (CMV) retinitis cases diagnosed in a tertiary hospital over an approximately 2-year period.

**Methods:** Retrospective case-control study. CMV positive cases followed in the pediatric clinic and undergoing ophthalmological examination between May 2020 and March 2022 were retrospectively screened.

**Results:** Retinitis was detected in two of 25 patients who underwent ophthalmological screening for cytomegalovirus retinitis (0.08%). Both cases had bilateral involvement. One of the cases was a congenital CMV case who was not diagnosed with any immune deficiency syndrome. The other was a CMV case who had received chemotherapy for leukemia. The congenital CMV case presented with bilateral anterior uveitis, vitritis, acute retinal necrosis (ARN) and bilateral retinal detachment. Localized retinitis was detected in the chemotherapy secondary CMV case.

In addition to systemic antiviral therapy, two doses of intravitreal ganciclovir injection were administered in both cases's four eyes.

The congenital CMV case passed away after 3 months of follow-up. Although there is no ocular complication associated with the injection, no positive effect of intravitreal injection on ophthalmic findings was detected in the three-month follow-up. In the other case, retinitis regressed with a fibrotic sequelae.

**Conclusion:** CMV retinitis is rare in children compared to adults. Limited cases have been reported in a small number of case series. An ophthalmologic examination should be considered in children with positive CMV laboratory results, even in the absence of an identified immunosuppressive disease. Pediatric cytomegalovirus retinitis is usually bilateral and may be a cause of severe vision loss. Evaluation of children at risk and treatment of systemic and ophthalmic disease are important to prevent long-term visual morbidity. However, the prognosis can be poor and the results are not promising in cases resistant to treatment. It should be noted that mortality is high in this patient group.



PP-671

**Safety and Utility of Fundus Fluorescein Angiography in Infants with Retinopathy of Prematurity**M Kvopka<sup>1</sup>.<sup>1</sup>*Ophthalmology, Royal Adelaide Hospital, Adelaide, Australia***Objective:** To determine the safety and utility of fluorescein angiography in infants with retinopathy of prematurity.**Methods:** The literature was searched for studies which utilised fluorescein angiography in infants up to 12 months of age. All relevant English articles were included following screening of abstracts. Non-English articles were included if they had English abstracts available. All years were included in the literature search.**Results:** Intravenous fluorescein appears to be safe for use in infants, with very few adverse events reported in the literature. While it is relatively early to comment on the long-term safety of fluorescein use in infants, immediate adverse events associated with its use remain rare. Nevertheless, as use of fluorescein continues to increase, we can expect genuine allergic responses to be reported in future literature, albeit infrequently.

Fluorescein angiography allows paediatric ophthalmologists to identify several features of retinal vasculature not otherwise visible on traditional binocular indirect ophthalmoscopy and digital wide-field retinal imaging. Addition of fluorescein angiography to indirect ophthalmoscopy and colour fundus photography enables a more objective assessment of retinopathy of prematurity stage and zone through improved visualization of vascular findings. Angiographic findings of leakages, shunts, and hyperfluorescence at the vascular-avascular retinal junction appear to be predictors of future disease progression.

**Conclusion:** Advances in fluorescein angiographic imaging of the infant retina have enabled improved diagnostic accuracy of retinopathy of prematurity and early intervention in treatment-requiring disease. Angiographic monitoring for sequelae of retinopathy of prematurity and response to treatment is an important adjunct to indirect ophthalmoscopy, and will likely become more prevalent as more is learned about the long-term potential for disease recurrence and late-onset vision-threatening complications of treatment. Fluorescein angiography contributes invaluable information towards retinopathy of prematurity diagnosis, and future diagnostic guidelines may incorporate these findings.

PP-673

**Clinical and Echographic Features of Morning Glory Disc Anomaly in Children: A Retrospective Study of 249 Chinese Patients**Y Zou<sup>1</sup>, P Zhao<sup>1</sup>.<sup>1</sup>Xinhua Hospital Affiliated to Shanghai Jiao Tong University School of Medicine, Shanghai, People's Republic of China

**Objective:** To report the clinical and echographic features, the prevalence of retinal detachment (RD), and associated visual acuity in a cohort of pediatric patients with morning glory disc anomaly (MGDA).

**Methods:** This was a retrospective review of 249 pediatric patients with MGDA (271 eyes) seen at the Dept. of Ophthalmology, Xinhua Hospital. Their medical records were reviewed for demographic data and ocular and systemic findings. The maximal depth and width of the cavity were measured using standardized echographic images. The ratios of cavitory depth to axial length, cavitory depth to maximal cavitory width, and the product of cavitory depth and width were calculated and used to indicate the relative size of the excavation. The clinical and echographic findings were correlated with visual acuity and the occurrence of RD of the patient.

**Results:** The relative size of the excavation and the presence of RD were positively associated with increased risk of poor vision ( $p < 0.05$ ). The presence of persistent fetal vasculature was not associated with the risk of RD and poor vision. The ratio of cavitory depth to axial length more than or equal to 0.25 conferred an increased risk of RD (OR, 2.101; 95% CI, 1.469-3.003).

**Conclusion:** Clinical and echographic features of MGDA may be used in predicting the risk of RD. Measuring the relative size of excavation *via* echography may guide the follow-ups and assist in the early diagnosis of RD.

PP-674

### Chemosensitizing Effect of Pentoxifylline on Carboplatin-Treated Retinoblastoma Y79 Cells. Expression of Pro-Apoptotic Proteins

C Cruz Gálvez<sup>1</sup>, R Cano Hidalgo<sup>2</sup>, V Bosch Canto<sup>3</sup>, J Ordaz Favila<sup>3</sup>, V Villar Calvo<sup>4</sup>, M Cancino Marentes<sup>5</sup>, G Hernández Flores<sup>6</sup>, M Espinosa Lagana<sup>7</sup>, P Ortiz Lazareno<sup>6</sup>, A Bravo Cuellar<sup>6</sup>.

<sup>1</sup>Departamento de Fisiología, Universidad de Guadalajara, Guadalajara, <sup>2</sup>Instituto de Oftalmología Conde de Valenciana, <sup>3</sup>Instituto Nacional de Pediatría, Mexico, <sup>4</sup>Private Practice, Guadalajara, <sup>5</sup>Universidad Autónoma de Nayarit, Tepic, <sup>6</sup>Centro de Investigación Biomédica de Occidente (CIBO), Guadalajara, Mexico, <sup>7</sup>Centre for Sight, London, United Kingdom

**Objective:** The goal of this study was to evaluate the effect of Pentoxifylline (PTX) on the expression of pro-apoptotic proteins p53, Poly (ADP-ribose) polymerase 1 (PARP-1), Apoptosis-inducing factor (AIF) and BAX in Carboplatin (CPT)-treated Y79 retinoblastoma cells.

**Methods:** The protocol was approved by the Committee of Research, Ethics, and Biosafety of the Centro de Investigación Biomédica de Occidente (CIBO), Instituto Mexicano del Seguro Social (IMSS), 2016-1305-1. The cell line Y79 (ATCC® HTB-18™ Manassas, VA, USA), derived from human retinoblastoma, was cultured. Y79 cells ( $10 \times 10^6$ ) were treated with CPT (30  $\mu$ g/ml), PTX (4 mM), or PTX (4 mM) + CPT (30  $\mu$ g/ml) for 18, 24, and 48 hours. PTX was added to the culture 1 hour prior to the addition of CPT. We evaluated p53, PARP-1, IAF and BAX protein levels by Western blot analysis. Pro-apoptotic proteins were visualized using the Odyssey™ infrared Imaging System (LI-COR Biotechnology, Nebraska, USA). Protein levels of p53, PARP-1, IAF and Bax in the Western blot were quantified using the ImageJ v1.51 software package (National Institute of Health, Bethesda, MD, USA [www.rsbweb.nih.gov/ij/index.html](http://www.rsbweb.nih.gov/ij/index.html)). Statistical analysis: All experimental procedures were performed in triplicates and were repeated three times. The values represent the mean  $\pm$  standard deviation from the actual values obtained. Statistical analysis was performed using the non-parametric Mann-Whitney U test to compare two groups. Considering values of  $p < 0.05$  as significant. We calculated the  $\Delta\%$ .

**Results:** Western blotting analyses allowed us to assess the effects of CPT, PTX and PTX+CPT on the expression of the p53, PARP-1, IAF and BAX proteins. A statistically significant increase in p53, PARP-1, AIF and BAX proteins was observed in cells treated with PTX + CPT.

**Conclusion:** Retinoblastoma (RB) is the most frequent malignant intraocular tumor in childhood. In a previous study, we found that PTX and CPT significantly affected the viability of the Y79 RB cells in a time- and dose- dependent manner. The PTX+CPT combination exhibited the highest rate of apoptosis, a decrease in cell viability and significant caspase activation, as well as loss of mitochondrial membrane potential and release of cytochrome c. In this study

we found PTX increases the expression of the p53, PARP-1, AIF and BAX proteins in CPT-treated Y79 retinoblastoma cells, increasing the antitumor efficacy of CPT.

PP-676

**Choroidal thickness and vascularity index in school-age children with myopic anisometropia**J Wen<sup>1</sup>, D Zhu<sup>1</sup>, J Zhao<sup>1</sup>.<sup>1</sup>Dept. Pediatric Ophthalmology, Peking University First Hospital, Beijing, People's Republic of China**Objective:** Examine the choroidal characteristics of school-age children who have myopic anisometropia.**Methods:** A retrospective serial case analysis was performed. Twenty-three anisometropic children who underwent measurement of choroidal characteristics using depth-enhanced imaging technology-optical coherence tomography (EDI-OCT) were recruited. To investigate the correlation among the difference in the diopter, axial length, choroidal thickness and vascularity index (CVI) interocular difference in myopic anisometropia.**Results:** There were 12 males and 11 females, with a mean age of  $10.69 \pm 1.54$  years. The normal eyes of the patients were in the emmetropia group (group 1), and the myopic eyes of the patients were in the myopia group (group 2). The spherical equivalent was  $-0.25 \pm 0.47$  D in group 1 and  $-2.25 \pm 0.97$  D in group 2 ( $p < 0.001$ ). The axial length was  $23.64 \pm 0.48$  mm in group 1 and  $24.45 \pm 0.47$  mm in group 2 ( $p < 0.001$ ). The thickness of the subfoveal choroid (SFCT) in group 1 was  $359.76 \pm 41.67$   $\mu\text{m}$  and that in group 2 was  $296.52 \pm 39.58$   $\mu\text{m}$  ( $p < 0.001$ ). The CVI within the foveal (1.5 mm) regions was  $0.715 \pm 0.048$  in group 1 and  $0.724 \pm 0.069$  in group 2 ( $p = 0.632$ ). The difference in the diopter was  $1.99 \pm 0.89$  D, which was positively correlated with the difference in axis length ( $r = 0.893$ ,  $p < 0.001$ ) and choroidal thickness ( $r = 0.509$ ,  $p = 0.013$ ).**Conclusion:** Different axial lengths and SFCT results were obtained in the two eyes of anisometropia patients. The diopter, axial length and SFCT of the two eyes showed statistically significant differences in myopic anisometropia patients. The greater the extent of myopic anisometropia, the stronger the correction of SFCT and diopter.

PP-677

**Agreement of iCare IC200 Tonometry with Perkins Applanation Tonometry in Healthy Children**T Stoddard-Bennett, S Fung<sup>1</sup>.<sup>1</sup>Stein Eye Institute - UCLA, Los Angeles, United States

**Objective:** This study compared interdevice agreement between the iCare IC200 rebound tonometer and Perkins applanation tonometry (gold standard) in a healthy pediatric population.

**Methods:** Forty-two eyes of 42 healthy children were assessed using both tonometers. Data was collected on subject's age, gender, best corrected visual acuity, and central corneal thickness (CCT). Intraclass correlation coefficient (ICC) and Bland-Altman analyses were used to determine agreement between IC200 and Perkins applanation tonometers. Linear regression analyzed the effects of intraocular pressure (IOP) on device difference.

**Results:** The mean age  $\pm$  standard deviation of healthy pediatric subjects was  $10.0 \pm 3.3$  years. The mean difference between IC200 and Perkins tonometers (IC200-Perkins) was 0.72 mmHg with a mean of  $17.1 \pm 3.0$  mmHg and  $16.4 \pm 2.5$  mmHg, respectively. The absolute agreement, or ICC, between tonometers was 0.63 (95% CI: 0.56–0.70). Bland-Altman analysis showed the 95% limits of agreement ranged from -5.2 to +6.6 mmHg. IC200 overestimation positively correlated with IOP levels ( $r = 0.64$ ,  $p = 0.0005$ ). CCT was not correlated with IOP for either the IC200 ( $p = 0.35$ ) or the Perkins tonometer ( $p = 0.052$ ).

**Conclusion:** Compared to applanation tonometry, IC200 overestimated IOP in healthy children, with a tendency of greater overestimation at higher pressures. While there was moderate agreement between the tonometers, CCT does not influence IOP measurement for either tonometer.

PP-678

## CHILDHOOD VISUAL IMPAIRMENT IN MAGRABI ICO CAMEROON INSTITUTE (MICEI) : CAUSES AND PREVALENCE.

G Fossouo Jibia<sup>1</sup>, T Afetane Evina<sup>1</sup>, H Nkumbe<sup>2</sup>, G Helles<sup>2</sup>, M Tchouyo<sup>3</sup>, A Signe Notuom<sup>3</sup>, S Tchuindem<sup>2</sup>, L Bodo<sup>4</sup>.

<sup>1</sup>paediatric ophtalmology, <sup>2</sup>retina unit, <sup>3</sup>glaucoma unit, <sup>4</sup>pharmacy, MAGRABI ICO CAMEROON EYE INSTITUTE, YAOUNDE, Cameroon

**Objective:** Report the prevalence of the main causes and factors associated with visual impairments (VI) found in children aged 0 to 15 who consulted MICEI from January 1, 2017 to August 31, 2021 during a retrospective cross-sectional survey in order to improve the challenging management of childhood blindness in Cameroon.

**Methods:** The sampling was exhaustive. Epidemiological (age, sex, ophthalmological and general history) and clinical (better visual acuity, stage of VI, diagnosis) variables were collected. The ICD-10 classification was used for the definition of blindness and low vision for children of verbal age. For children of preverbal age, an absence of light pursuit or even wandering of gaze were considered to be a sign of poor vision.

**Results:** 394 children (600 eyes) were retained giving a prevalence of 2.57% (394/15,251 children) mostly male (54.30%) (214/180). The age group of [1-6]years was the most affected (34.00%). 52.50% of patients (412 eyes) had bilateral visual impairment (206/188). Blindness was the main type of VI with a frequency of 52.80% (232/394) (317 eyes). The main causes of unilateral VI were retinoblastoma (18.10%) (34/188), cataract (18.10%) (34/188) and trauma (16.10%) (29/188). The main causes of bilateral VI were refractive errors (12.62%) (26/206) and cataract (12.40%) (25/206). 25.38% (100/394) of affected children had nystagmus.

**Conclusion:** Many causes of childhood VI are curable, others lethal. Diagnosed late, they constitute a real handicap for the child whose lifespan is very long. Thus, the necessity to install a better policy for the early detection of those diseases can help reduce their prevalence and social impact among the cameroonian population.

PP-679

**Expression Levels of Aqueous Humor Cytokines in Pediatric Patients with Incontinentia Pigmenti**J Peng, P Zhao<sup>1</sup>.

<sup>1</sup>Ophthalmology, Xinhua hospital affiliated to Shanghai Jiao Tong University School of Medicine, Shanghai, People's Republic of China

**Objective:** To investigate the expression levels of aqueous humor cytokines in pediatric patients with Incontinentia Pigmenti (IP) disease and analyze possible mechanism of the retinal disease.

**Methods:** This study included 6 pediatric patients (8 eyes) with Incontinentia Pigmenti disease and 12 control patients (18 eyes) with congenital cataract. Aqueous humour samples were obtained preoperatively. Concentrations of 22 cytokines were measured with Cytometric Bead Array (CBA) technology. Ophthalmologic findings and expression of the cytokines were recorded.

**Results:** The aqueous humor concentrations of three cytokines (VEGF, IP-10, ICAM-1) were significantly higher and two cytokines (G-CSF, IL-4) significantly lower in IP associated retinopathy (IPR) patients than the control group ( $P < 0.05$ ). VEGF, IL-8, IP-10, ICAM-1 were significantly increasing in parallel with increasing stages of IPR ( $P < 0.05$ ) and IL-4, G-CSF significantly decreasing with increasing stages of IPR ( $P < 0.05$ ).

**Conclusion:** Increasing severity of IPR is associated with the expression levels of VEGF and inflammatory cytokines. T-lymphocyte infiltration and stimulation may play an important role in the pathogenies of IPR. Increased VEGF concentrations in aqueous humor offer theoretical basis for anti-VEGF treatment in IPR patients.



**PP-680****Efficacy and effect of lifting upper eyelid muscle shortening, frontal muscle flap suspension, and combined fascial sheath suspens**

D Xu.

**Objective:** Objective To study the treatment effect and convenience analysis of the modified five-point embedded line method compared with classical lift superior muscle shortening (LMR), frontal muscle flap suspension (FMS) and combined fascial sheath suspension (CFSS) in children with severe ptosis. Design of a prospective case series. The subjects had 100 children (168 eyes) ( $5.21 \pm 13$ ) admitted between March 2019 – August 2021.

**Methods:** Methods, according to the wishes of parents, 100 children had 50 (78 eyes), 23 LMR (32 eyes), 13 FMS (20 eyes) and 14 CFSS (38 eyes). Preoperatively, All the surgical eyes of the children were examined at 7 days, 1 month, 3 months, and 6 months after surgery, Observe the upper eyelid morphology of the children, Measure the size of residual gap (i. e. degree of closure insufficiency), height and position of upper eyelid margin, And according to the upper eyelid margin position of 1,3 and 6 months after the operation of 1,3 and 6 months; Time of tear film rupture (BUT), tear secretion test (SIT), corneal fluorescence staining (FL) examination; Computer optometry instrument diopter check, Record the corneal refraction, corneal astigmatism and astigmatism axis and other indicators; Record the postoperative recovery in the three groups, The overall efficiency of the surgery was judged according to the eyelid closure, eyelid fissure height and the occurrence of complications.

**Results:** The total response rate of line embedding, LMR, FMS and CFSS groups was 91.78%, 79.69%, 86.44% and 92.31%, respectively, The buried line and CFSS groups were significantly higher than the other groups; Three and 6 months ( $0.25 \pm 0.04$ ) mm, ( $0.16 \pm 0.02$ ) mm ( $0.32 \pm 0.04$ ) mm, ( $0.36 \pm 0.03$ ) mm ( $0.35 \pm 0.05$ ) mm, ( $0.38 \pm 0.04$ ) mm ( $P < 0.05$ ) and CFSS; The degree of symmetry and CFSS morphology of the buried group and upper eyelid margin were slightly higher than the other two groups; However, the overall incidence of complications in the buried line group (9.23%) was significantly lower than that in the CFSS group (25.42%), There was no significant difference from the LMR group (17.19%).

**Conclusion:** The four procedures have precise correction effect. The five-point buried line method has the least postoperative response to other methods, and is reproducible and operable, which can be used as a simple and easy surgical plan to improve the eyelid state in patients with early ptosis.

PP-681

**Incidence, Management and Outcome of Pulled-in-two Syndrome Associated with Strabismus Surgery**M Kong<sup>1</sup>, J Li<sup>1</sup>.<sup>1</sup>Strabismus and Pediatric Ophthalmology, Shanxi Eye Hospital, Tai Yuan, People's Republic of China

**Objective:** Pulled-in-two syndrome is a rare and severe complication of strabismus surgery, the objective of this study was to report the incidence and outcomes of Pulled-in-two Syndrome (PITS) during strabismus surgery and investigate the clinical features and management of PITS.

**Methods:** The medical records of patients who had undergone strabismus surgery and developed PITS between July 2013 and October 2020 were reviewed retrospectively. The demographic characteristics, intraoperative details (including surgery type and management to PITS), subsequent and final outcomes were extracted from the records.

**Results:** Of 11824 strabismus surgeries during the study period, 4 cases of PITS were documented, for an overall incidence of 0.034%. The average age of the patients with PITS was  $61.75 \pm 8.99$  years. All 4 patients were female, 2 patients showed abducen nerve palsy and the other 2 patients presented with myopic strabismus fixus. Inferior rectus muscle was involved in one patient and medial rectus muscle were involved in three patients. All of the involved extraocular muscle were lost. The ocular alignment in one patient achieved orthotropia and the others were undercorrected after the surgery.

**Conclusion:** PITS is one of the most rare and serious complication of strabismus surgery, the overall incidence of PITS associated with strabismus surgery was 0.034% in our study cohort. Cranial nerve palsy, advanced age, prior surgery, thyroid associated ophthalmopathy(TAO) and degenerative conditions of the extraocular muscle were risk factors, therefore, more attention should be given to the prevention of PITS in these patients with risk factors.

**PP-682****Effect of twice a day usage of atropine (0.01%) eye drops for myopic progression in nonresponders to once a day usage.**

J Jethani<sup>1</sup>, M *Jethani*.

<sup>1</sup>*Myopia Control Clinic, Baroda Children Eyecare and Squint Clinic, Vadodara, India*

**Objective:** Low concentration atropine (LCA) (0.01%) eye drops once a day are known to slow down the myopia progression in children. Few children who have axial progression may not respond to these drops and may still progress 0.5 D per year and are labelled as nonresponders We did a study to know the effect of increasing the frequency of LCA drops to twice a day and see its effect on non responders.

**Methods:** A total of 30 children known axial myopes nonresponders to once a day usage of LCA drops were included in the study. Thorough Ophthalmic and orthoptic checkup was done. They were asked to start using the drops twice a day. Follow up every 6 months for 2 years.

**Results:** Mean age & spectacle power was 6.4 +/- 3.6 years and -3.18 +/- 2.3 D. Around 10 children (33.3%) responded and the progression reduced to -0.36 D per year from -0.67 D per year. No significant side effects were seen on twice a day usage.

**Conclusion:** We conclude that twice a day usage of LCA (0.01%) eye drops may be effective in managing children who are not responding to once a day usage of low concentration of atropine.

PP-684

**Severe corneal abscesses of bacterial origin in children**

T Elongo, L Kora<sup>1</sup>, C Baqadir<sup>1</sup>, L Bel'hantier<sup>1</sup>, G Daghouj<sup>1</sup>, L Elmaaloum<sup>1</sup>, B Allali<sup>1</sup>, A Elkettani<sup>1</sup>.

<sup>1</sup>*Pediatric ophthalmology, Hôpital 20 août 1953, Casablanca, Morocco*

**Objective:** Corneal abscess is a serious pathology, with a reserved and potentially blinding prognosis. Diagnosis is clinical, requiring appropriate management to avoid any diagnostic and therapeutic delays likely to darken the visual prognosis. The aim of our study is to define the epidemiological, microbiological, clinical, therapeutic and evolutionary aspects of corneal abscesses.

**Methods:** Retrospective study of all cases of corneal abscess of bacterial origin in children hospitalized over a period of 2 years. All the children underwent corneal scraping with microbiological examination. We collected the data from the medical files of the patients and the results of bacteriological examinations.

**Results:** Out of a total of 18 abscesses, the average age of the patients was 3 years with a male predominance. Frequent contributing factors were ocular trauma, the notion of ocular surgery, ocular dryness, ocular rosacea. The germs found were Gram + bacteria (55.5%), Gram - bacteria (33.5%) and multi-microbial (11%). Treatment with eye drops fortified with antibiotics and systemic antibiotic therapy were indicated in all cases. The evolution was favorable in 66.5% of cases with improvement in visual acuity and reduction in corneal opacification.

**Conclusion:** Faced with a serious corneal abscess, only rapid and well-conducted diagnostic and therapeutic management can reduce the risk of an unfavorable outcome. Similarly, prevention requires better management of ocular trauma and other causal factors.

PP-686

**Changes of fixational saccadic eye movements in patients with intermittent exotropia**X Shi<sup>1,2</sup>, J Li<sup>1,2</sup>.

<sup>1</sup>Tianjin Eye Hospital, <sup>2</sup>Clinical College of Ophthalmology, Tianjin Medical University, Tianjin, People's Republic of China

**Objective:** To explore the changes of fixational saccades (FS) in patients with intermittent exotropia (IXT) and its influencing factors.

**Methods:** A total of 50 patients with IXT (100 eyes) and 57 age-matched normal subjects (114 eyes) were recruited. The patients with IXT were further subgrouped into  $\leq 1$  year and  $> 1$  year according to the COD,  $\leq 6$  years old and  $> 6$  years old according to the age of onset,  $\leq 60''$ ,  $80''$ - $3000''$  and stereopsis loss according to the stereoscopic acuity. Fixational saccadic eye movement waveforms were recorded by a high-speed eye tracker. A program written in MATLAB was used to analyze the eye movement data offline.

**Results:** There was significant difference among the FS amplitudes of the dominant eye of IXT patients (Xd), the non-dominant eye of IXT patients (Xn), the dominant eye of the control group (Nd) and the non-dominant eye of the control group ( $F = 4.364$ ,  $P < 0.01$ ). Compared with the Nd group and the Nn group, the FS amplitudes of the Xn group significantly increased. One-way ANOVA was performed to analyze the difference among the FS amplitudes of the dominant eye (Xc1d) and the non-dominant eye (Xc1n) of IXT patients with COD  $\leq 1$  year, the dominant eye (Xc2d) and the non-dominant eye (Xc2n) of IXT patients with COD  $> 1$  year, the dominant eye (N'd) and the non-dominant eye (N'n) of the control group, and showed significant difference ( $F = 3.524$ ,  $P < 0.01$ ). Compared with the N'd group, the FS amplitude of the Xc1n group significantly increased ( $P < 0.05$ ). The FS amplitude was significantly increased in the Xc1n group compared with the Xc1d group ( $P < 0.05$ ). There was no difference between the FS amplitudes of the Xc2d group and the Xc2n ( $P = 0.99$ ), but they are both larger than the normal groups. There was no significant difference of FS amplitudes ( $F = 1.628$ ,  $P > 0.05$ ) or peak velocities ( $F = 1.216$ ,  $P > 0.05$ ) among all the age-of-onset subgroups of IXT patients and age-matched normal subjects. There was also no significant difference of FS amplitudes ( $F = 1.659$ ,  $P = 0.125$ ) or peak velocities ( $F = 1.238$ ,  $P = 0.286$ ) among all the stereoacuity subgroups of IXT patients and age-matched normal subjects.

**Conclusion:** The COD has a significant impact on the changes of FS in patients with IXT and preferentially affects the non-dominant eye. There was no significant influence of age of onset and stereoacuity on the changes of FS in patients with IXT.

PP-687

## The Outcome and Patient Satisfaction of Nasal Transposition of Y Splitting the Lateral Rectus Muscle for Oculomotor Nerve Palsy

M Kong<sup>1</sup>, J Li<sup>1</sup>.

<sup>1</sup>*Strabismus and Pediatric Ophthalmology, Shanxi Eye Hospital, Tai Yuan, People's Republic of China*

**Objective:** To evaluate the outcomes and complications associated with nasal transposition of Y splitting the lateral rectus (LR) muscle procedure, and assess the satisfaction of the patients and/or patients' parents with respect to the surgery outcome in patients with complete oculomotor nerve palsy.

**Methods:** This is a retrospective study. The medical records of 5 consecutive patients with complete oculomotor nerve palsy who underwent nasal transposition of Y splitting the LR muscle between 2016 and 2019 were reviewed. The patient satisfaction were assessed using a 5 point-Likert scale meanwhile.

**Results:** A total of 5 patients were included. Patients had a preoperative horizontal deviation ranged from -90 to -120PD. Of the five patients, one achieved orthotropia, two were slightly overcorrected (+8PD, +15PD) and others were slightly undercorrected (-15PD, -20PD) in the primary position after surgery. Those three patients with orthotropia or overcorrection had a good appearance in the primary position at the last visit, but they were not satisfied with the almost fixed eyeball since they had obviously restriction in abduction and had little improvement in adduction. However, the other two patients with slightly undercorrection in the primary position after the operation were more satisfied since there was no severe restriction of both abduction and adduction.

**Conclusion:** Acceptable comestic results can be achieved in the treatment of complete oculomotor nerve alsy by transporting the split lateral rectus muscle to the medial rectus muscle. In view of patient satisfaction, slightly undercorrection is better than orthotropia and overcorrectionp.

PP-689

**Gender disparities in global burden of refraction disorders in children**W Pan, X Tang<sup>1</sup>.<sup>1</sup>*the Second Affiliated Hospital, College of Medicine, Zhejiang University, Hangzhou, People's Republic of China*

**Objective:** To investigate gender disparities in global burden of refraction disorders in children under 15 years old using disability-adjusted life years (DALYs).

**Methods:** Global, regional, and national gender-specific DALY numbers and rates of refraction disorders in children were obtained by year (from 1990 to 2019) and age group (under 5, 5 to 9, and 10 to 14) from the Global Burden of Disease Study 2019. Inequality-adjusted Human Development Index (IHDI) in 2019 as an indicator of national developmental status was extracted from the Human Development Report. Pearson correlation and linear regression analyses were performed to explore the association between female to male DALY rate ratios and national developmental status.

**Results:** Gender disparities in DALY numbers and rates of refraction disorders in children have persisted from 1990 to 2019, and shown little improvement over the decades. Females had a higher burden than males of the same age, and gender disparities increased with age (1.120 in preschool children, 1.124 in school children, and 1.135 in teenagers). Female-to-male DALY rate ratios were negatively related to IHDI (standardized  $\beta = -0.189$ ,  $P < 0.05$ ).

**Conclusion:** Gender disparities in global refraction disorders burden in children have persisted for decades, with females who are elder, and from more developed countries having a higher burden than males. Gender-specific health policies should be made to manage refraction disorders in children.

**PP-690****The Efficacy of Dose Increments of Botulinum Toxin A in the Treatment of Childhood Esotropia**

K Alotaibi, F *Alshamlan*, M *Alwalmany*, H *Alabdulhadi*.

**Objective:** This study aims to investigate the efficacy of dose increments of botulinum toxin A (BTA) for the treatment of specific ranges of angle deviation.

**Methods:** This was a prospective study that included patients presenting with esotropia to Dhahran Eye Specialist Hospital between 2016 and 2020, who were managed by a single surgeon. Botulinum toxin was given in different dosages (2.5, 5, 7.5, 10 international units (IU)) according to the size of deviation (11–19, 20–29, 30–39, and  $\geq 40$  prism diopters (PD)), respectively. A successful outcome was defined as deviation  $\leq 10$  PD in the last visit (a minimum of 6 months) following a single injection.

**Results:** A total of 56 patients with esotropia were included. The mean pre-treatment angle of deviation was  $38.6 \pm 2.5$  PD. BTA injection in a dose of 2.5 IU for the 11–19 PD angle of deviation showed the highest rate of successful outcomes (75%). According to the type of esotropia, partially accommodative esotropia showed the best response to the use of dose increments (59%). The incidence of ptosis post-BTA injection was the least (37.5%) with the smallest dose (2.5 IU).

**Conclusion:** BTA usage in dose increments is safe, efficient, and might be more cost-effective with less incidence of BTA associated complications. Different esotropia diagnoses have different clinical responses. However, larger studies are necessary to better predict the outcome of using dose increments.



PP-691

**Primary combined polychemotherapy (Intravitreal + Chemoreduction) in bilateral retinoblastoma management**N Bobrova<sup>1</sup>, O Bratishko<sup>1</sup>, T Sorochinskaya<sup>2</sup>, S Tronina<sup>1</sup>, T Romanova<sup>1</sup>, L Sukhodoeva<sup>1</sup>.

<sup>1</sup>department of pediatric ophthalmic pathology, The Filatov Institute of Eye Diseases and Tissue Therapy of the National Academy of Medical Sciences of Ukraine, <sup>2</sup>department of pediatric ophthalmic pathology, *Институт глазных болезней и тканевой терапии имени Филатова Национальной академии медицинских наук Украины, Odesa, Ukraine*

**Objective:** To develop tactics and analyze results of bilateral retinoblastoma (Rb) treatment

**Methods:** Remote results of elaborated tactics of bilateral retinoblastoma (Rb) treatment were analyzed in 37 children (74 eyes) at age 1-105 mo/o (ave  $13.71 \pm 10.76$  mo). Multifocal growth was found in all eyes - from 2 to 7 Rb foci in one. The eyes distribution by stages: T1-21%, T2-29%, T3-50% with T3b predominance (40%). Standard ophthalmology examination under general anesthesia were performed including digital retinal camera PanoCam, anterior and posterior segments B-scan, brain and orbits MRI. Bilateral Rb treatment started from elaborated in 2010 (Bobrova, Sorochynska) primary combined polychemotherapy (PCT) - Intravitreal (IVit) Melphalan + chemoreduction CEV-protocol - in T1-T3b stages; in T3c-T4 - primary chemoreduction to avoid tumor spreading, pinealoblastoma and distant metastasis, than worse eye enucleation using developed methods of biologic tissue welding (Pasechnikova et al., 2014; Bobrova et al., 2018), best eye further treatment using combined PCT. Dosage and terms of Melphalan injections ( $10-30 \mu\text{g}$  every 10-28 days) were administrated depending on the elaborated indications (Bobrova et al., 2021), based on the developed IVit chemotherapy ablaticity (Bobrova et al., 2020). Consolidation therapy by elaborated approaches (Bobrova et al., 2019-2021) was added if necessary - IVit Melphalan + laser-, cryo- or brachytherapy, rarely linear accelerator, on indications. Follow up 8-125 (ave  $56,7 \pm 24,8$ ) mo.

**Results:** Enucleation was performed in 16 eyes with Tc-T4 stages, other 58 eyes received salvage eye therapy using developed tactics. Relapse and complications of developed tactics: retinal detachment (4eyes) haemophthalmos, suspicion of papilla opticus invasion, progressive tumor growth because of break in treatment one by one. That's why enucleation of 7 eyes (12 %) was done. Hystopathology show Rb cells spreading in episclera only in 1 eye with tumor relapse, 5 other hadn't invasion and no vital cells was found in 4 of them. 51 eyes (88 %) were preserved with tumor control.

**Conclusion:** Tactics of bilateral Rb management was developed, using elaborated in Pediatric ophthalmology department new methods of salvage eye therapy based on Primary Combined Polychemotherapy (Intravitreal + Chemoreduction) that allowed to preserve 88 % of treated eyes.

**PP-692****Analysis of pathogenic factors of retinopathy of prematurity in Heilongjiang Province**

Y Gao.

**Objective:** Retinopathy of prematurity is a vascular development disorder in immature retinas of premature infants, which is the leading cause of blindness in children worldwide. In this study, the prevalence and risk factors of ROP in Heilongjiang Province were determined through screening for premature infants in the region, aiming to proceed early prevention of the disease.

**Methods:** Retrospectively analyzed 714 premature infants admitted to the Ophthalmology Clinic of the Second Affiliated Hospital of Harbin Medical University from January 2016 to February 2022. 12 related factors were recorded including patients' gender, gestational age, birth weight, oxygen duration, blood transfusions, anemia, neonatal infections, respiratory distress syndrome, maternal feeding way, childbirth way, pregnancy age and parity. The prevalence of ROP and the differences in related factors between ROP patients and non-ROP patients were found.

**Results:** Among 714 premature infants, 188 had ROP of which the incidence is 26.3%, and 61 patients received treatment. multivariate regression analysis, which showed that gestational age, birth weight, and oxygen duration had remarkable statistical significance ( $P < 0.05$ ) with the occurrence of ROP. Gestational age and birth weight were the protective factors of disease ( $OR = 0.43$  and  $OR = 0.8$ ), while oxygen duration was the risk factor of disease ( $OR = 1.02$ ), and the diagnostic value of the model was high ( $AUC = 0.776$ ). Due to the spread of the COVID-19, 207 children were screened after January 1st in 2020, 50 children were ROP patients, and 25 of whom got treatment (12%), 21 were treated after 8 weeks of birth or more than 37 weeks of corrected gestational age. Four out of five children who received the second treatment happened after the epidemic, and three of them missed treatment due to the epidemic.

**Conclusion:** The gestational age, birth weight and oxygen duration are significantly correlated with the incidence and severity of the disease in premature infants screening of Heilongjiang Province. Premature infants screening and subsequent visit were affected due to the spread of the COVID-19 in the past two years, the proportion of children needed to be cured augmented apparently, therefore, it matters a lot for premature infants to be screened standardly and timely.

PP-693

**Novel case of paediatric acute corneal hydrops in Kabuki Syndrome**R Malik<sup>123</sup>, D Athavale<sup>456</sup>, R Abell<sup>7</sup>, N Verma<sup>5678</sup>.

<sup>1</sup>Port Macquarie Base Hospital, <sup>2</sup>The University of New South Wales, Port Macquarie, <sup>3</sup>The University of Newcastle, Newcastle, <sup>4</sup>Sydney Eye Hospital, Sydney, <sup>5</sup>The University of Tasmania, <sup>6</sup>Royal Hobart Hospital, <sup>7</sup>Hobart Eye Surgeons, Hobart, <sup>8</sup>The University of Sydney, Sydney, Australia

**Objective:** To describe a rare and previously unreported case of acute corneal hydrops in Kabuki Syndrome.

**Methods:** The authors present a clinical case report, followed by a literature review of reported ophthalmic manifestations of Kabuki Syndrome and a further discussion involving the association between corneal hydrops, intellectual disability and eye rubbing.

**Results:** Kabuki syndrome is a rare genetic condition with increasing evidence of a variety of multi-system manifestations. The aetiology of a proportion of acute corneal hydrops is eye rubbing and there is a high documented prevalence of eye rubbing in patients with intellectual disability. This correlation assists in recognising the potential for the ophthalmic manifestation of corneal hydrops in Kabuki syndrome as intellectual disability is one of the five cardinal features of this rare genetic disease.

Primary ocular features of Kabuki Syndrome outlined by National Organization for Rare Disorders include long palpebral fissures, thick sparse eyelashes, ptosis, blue sclerae, broad arched eyebrows, strabismus and eversion of lateral third of lower eyelid. Other ophthalmic signs of Kabuki Syndrome within the literature include cataract, retinal hyper- and hypopigmentation, microphthalmia, amblyopia, nystagmus, coloboma, refractive anomalies and ophthalmoplegia. There are only limited case reports of corneal pathology associated with Kabuki Syndrome, which include megalocornea, microcornea, Peters anomaly, corneal opacities and peripheral corneal nodules.

**Conclusion:** To our knowledge, this is the first report of acute corneal hydrops in Kabuki Syndrome. It is of clinical relevance as it contributes to the existing knowledge of ophthalmic manifestations in Kabuki Syndrome.

PP-694

### Cone Mosaic Characteristics in Unilateral Anisometropic Amblyopia & Changes Following Occlusion Therapy: An Adaptive Optics Study

V Gupta<sup>1</sup>, D Singh<sup>1</sup>, R Dhiman<sup>1</sup>, R Chawla<sup>1</sup>, R Saxena<sup>1</sup>.

<sup>1</sup>AIIMS New Delhi, New Delhi, India

**Objective:** To compare the photoreceptors cone characteristics in children with unilateral anisometropic amblyopic and change in cone mosaic after occlusion therapy using adaptive optics technology.

**Methods:** Ten children with unilateral hyperopic anisometropic amblyopia having uncorrected visual acuity of 20/30 or more in better eye were enrolled. All children were advised to occlude the better eye for 4-6 hours per day. Uncorrected visual acuity (UCVA), best corrected visual acuity (BCVA), axial length (AL) and refraction were recorded. Cone density, spacing, dispersion and regularity of amblyopic eye and fellow eye in nasal, temporal, inferior and superior quadrant at 2° and 4° fixation from fovea were measured by rtx1 adaptive optics retinal camera (using AOdetect Mosaic software) with a 4x4° sampling window size before and after 3 months of occlusion therapy.

**Results:** Mean age of 10 enrolled children were  $11.2 \pm 1.6$  years. Overall at 2° fixation, mean cone density of amblyopic eye and fellow eye is  $32204 \pm 2333$  cells/mm<sup>2</sup> and  $31324 \pm 1998$  cells/mm<sup>2</sup> respectively ( $p$ : 0.23). At 4° fixation, mean cone density of amblyopic eye and fellow eye is  $30809 \pm 2178$  cells/mm<sup>2</sup> and  $30197 \pm 2043$  cells/mm<sup>2</sup> respectively ( $p$ : 0.18). After 3 months of occlusion therapy, visual acuity of amblyopic eye is improved significantly but there is no significant change noted in cone density, spacing, dispersion and regularity of amblyopic and fellow eye in any quadrant (nasal, temporal, superior or inferior) at 2° and 4° foveal fixation.

**Conclusion:** This comparative study shows that cone mosaic characteristics do not differ between amblyopic and fellow eye of unilateral anisometropic children. With occlusion therapy, visual acuity is improved but not related to change in cone characteristics.

PP-695

**Binocular Visual Function in Children with Different Refractive Errors**F Yüksekayla<sup>1</sup>, T Göncü Fırat<sup>1</sup>.<sup>1</sup>Ophthalmology, Harran University School of Medicine, Sanlıurfa, Türkiye

**Objective:** This study aimed to compare the results of Titmus, Randot, TNO and Frisby binocular vision tests in healthy pediatric cases with different refractive errors.

**Methods:** This prospective clinical trial was conducted on a consecutive series of 132 pediatric cases with different refractive errors. All children underwent a detailed ophthalmological examination. Binocular visual functions with best spectacle correction were evaluated with Titmus, Randot, TNO, Frisby, Worth 4 point and Bagolini tests. Presence of fusion and stereopsis values were noted.

**Results:** The mean age of the patients was  $11.1 \pm 3.2$  years. The best stereopsis value was measured with Randot test ( $66.2 \pm 35.6$  sec.arc) which was followed by Titmus ( $82,6 \pm 52,6$  sec.arc), Frisby ( $195,5 \pm 406$  sec.arc) and TNO ( $195,5 \pm 406$  sec.arc). The difference between tests was statistically significant ( $p < 0,001$ ). The cases were grouped with respect to refractive errors. Thirty (22.7%) were emmetropic, 36 (27.3%) were myopic, 34 (25.8%) were hyperopic and 32 (24.2%) were with astigmatism. In emmetropia and myopia groups we did not observe any statistically significant difference between stereopsis tests ( $p=0,137$  and  $p=0,456$  respectively). However there was a significant difference between the results of stereopsis tests in hypermetropia and astigmatism groups ( $p=0,001$  and  $p=0,007$  respectively). In both groups best stereopsis value obtained with Randot test.

**Conclusion:** Stereopsis tests is very valuable tools, especially for children, in the evaluation and follow-up of normal visual development.. In our study, it was observed that which stereopsis test used in examination might affect the obtained stereopsis value. Also refractive errors especially hypermetropia and astigmatism might have impact on stereopsis test results.

PP-696

**Intraocular Pressure Values in Premature Infants and its Correlation with Postconceptional Age**

C M Monteiro, J Almeida<sup>1</sup>, M Ramalho<sup>1</sup>, M Mota<sup>1</sup>, S Teixeira<sup>1</sup>, I Prieto<sup>1</sup>.

<sup>1</sup>Ophthalmology, Hospital Professor Doutor Fernando da Fonseca, Lisboa, Portugal

**Objective:** In order to be able to understand and detect developmental abnormalities and congenital diseases in the eye, it is crucial to have a good understanding of normal IOP values and their progression over time in premature infants. This study aims to determine a normative range of intraocular pressure (IOP) values in premature infants and to evaluate IOP variation over time and its correlation with postconceptional age (PCA).

**Methods:** We conducted a single-center prospective longitudinal study that included premature infants (gestational age  $\leq 32$  weeks) admitted to the neonatal intensive care unit (NICU) in Hospital Professor Doutor Fernando da Fonseca, Portugal. IOP was measured on the occasion of the first retinopathy of prematurity screening requested by the NICU and again with a 2-week interval if postconceptional age was still  $\leq 37$  weeks. IOP measurements were stopped at 37 weeks or if the infant was discharged. The evaluated outcomes were mean IOP values and their correlation with PCA.

**Results:** 34 eyes of 17 preterm infants with a mean gestational age of  $29.4 \pm 2.3$  weeks and a mean birth weight of  $1222.9 \pm 361.9$  g. were evaluated. The mean IOP registered was  $16.1 \pm 6.4$  mmHg, with a median value of 15.3 mmHg. Top 90th percentile was 22.1 mmHg and bottom 10th percentile 9.0 mmHg. Average IOP reduction was  $4.8 \pm 6.7$  mmHg ( $p = 0.0019$ ) within the 2-week interval of PCA.

**Conclusion:** Mean IOP in premature infants was  $16.1 \pm 6.4$  mmHg and this value decreased  $4.8 \pm 6.7$  mmHg ( $p = 0.0019$ ) every 2 weeks of PCA.

PP-697

**Perceptual learning with hand–eye coordination as an effective tool for managing amblyopia: a prospective study**S Shah, M Shah<sup>1</sup>.<sup>1</sup>*Vitreo retina, Drashti Netralaya, Dahod, India*

**Objective:** Amblyopia is a serious condition resulting in monocular impairment of vision. Traditional treatment facilitates improvement in vision; however, we attempted to explore the results of perceptual learning.

**Methods:** This study was designed as a prospective cohort study. All patients with amblyopia were subjected to perceptual learning after documenting the presenting data. We filled the data in a pretested online format, including vision, stereopsis, and contrast sensitivity, and compared the pre- and post-treatment information using descriptive, cross tabulation, and comparative means with SPSS 2.2. We obtained mean values, and p value < 0.05 was considered statistically significant.

**Results:** Our cohort included 47 patients with a mean age of  $14.11 \pm 7.13$  years (range: 6–35 years). In the study cohort, 24 (48.9%) were women, and 24 (51.1%) were men. We found stastically significant improvement in visual acuity after the perceptual learning session, and the median follow-up period was 17 days. We observed significant improvements in stereopsis but did not find a significant difference in the visual outcome among the age groups.

**Conclusion:** Perceptual learning with hand–eye coordination is an effective method for managing amblyopia. This approach can cause improvement in vision in all age groups. However, visual improvement is significantly

PP-698

**Ocular surface changes in operated eye and compare it with non operated eye after squint surgery**J Jethani<sup>1</sup>, S Sharma.<sup>1</sup>*Pediatric Ophthalmology and Strabismus, Baroda Children Eyecare and Squint Clinic, Vadodara, India*

**Objective:** Strabismus surgery changes the ocular surface as the muscle are approached after incising gthe conjunctiva. Patients do complain of irritation and redness even after healing of incisions. We did a study to evaluate ocular surface changes in operated eye and compare it with non operated eye post strabismus surgery.

**Methods:** A total of 50 patients with exotropia underwent unilateral squint correction surgery for exotropia. Dry eye evaluation including TBUT and Schirmer test were done preoperatively and after 1 month postoperatively. The scores were recorded and compared.

**Results:** The mean Schirmer and TBUT in the operated eye and unoperated eye preoperatively was 17.5 +/- 6.4 mm, 19.4 +/- 9.2 seconds and 17.9 +/- 9.6 mm, 20.5 +/- 8.9 seconds respectively. Postoperatively mean Schirmer and TBUT values in the operated and unoperated eye was 13.7 +/- 7.4 mm, 14.5 +/- 8.1 seconds and 18.1 +/- 10.1 mm and 21.2 +/-9.2 seconds respectively. This difference between preoperative and postoperative change in Schirmer and TBUT value was statistical significant.

**Conclusion:** After strabismus surgery, most of the patients do have tear film instability. We should look for it and should treat it separately as a dry eye disease induced secondary to surgery. Also patients should be made aware of this entity post surgery



PP-699

**Study of the Refractive Changes and Ocular Biometrics in Preterm and Term Infants**R Kumar.

**Objective:** Primary objectives to compare refractive changes and ocular biometrics between preterm and term infants in Indian scenario. Secondary objective to find association of gestational age and birth weight to the final refractive status of infants at 1 year of age.

**Methods:** A Cohort study enrolling a total 90 infants with no evidence of any syndromes and co morbidities at birth. 45 preterm and 45 term into two groups. Growth and ocular parameters were measured along with retinoscopy at birth and 3 follow ups after 3 months, 6 months and 1 year following birth. The primary outcome was mean spherical equivalent and axial length measured at 1 year.

**Results:** The ocular parameters at corrected gestational age of 37 weeks of preterm infants and at birth of term infants showed that the mean axial length of preterm infants was  $15.84 \pm 0.84$ mm and among terms was  $16.84 \pm 0.43$ mm. The mean spherical equivalent among preterm and term were -0.6 D and +1.1D respectively.

**Conclusion:** The preterm infants have more tendency to develop myopia which increases for first few months after birth whereas term infants tend to emmetropisation since birth. There is no significant difference in emmetropisation among preterm and term infants at 1 year of age. Among gestational age and birth weight, Birth weight is strongly associated with final refractive status at 1 year age.

## PP-702

**Outcomes of a simplified, fixed surgical dosage calculation for horizontal, uncomplicated, concomitant strabismus in adults**

T Natung<sup>1</sup>, I Pandey<sup>1</sup>, L Lyngdoh<sup>1</sup>.

<sup>1</sup>North Eastern Indira Gandhi Regional Institute of Health & Medical Sciences (NEIGRIHMS), Shillong, India

**Objective:** To evaluate the outcomes of a simplified, fixed surgical dosage calculation for uncomplicated, horizontal, concomitant strabismus in adults. It is always a challenge for novice strabismus surgeons to decide how much to recess or resect in strabismus surgery since the surgical dosages given as guidelines in literature are in ranges. They usually begin their surgeries with uncomplicated, horizontal, concomitant strabismus in adults.

**Methods:** A retrospective, interventional case series study done at a tertiary care centre. Institutional ethics clearance was given. Inclusion criteria: i) Adult patients undergoing strabismus surgery for uncomplicated, horizontal, concomitant strabismus from April 2014 to April 2021, ii) Operated by a single surgeon and iii) a minimum of 3 months follow up. Exclusion criteria: Children (<18 years), incomplete data, incomitant strabismus, patients not completing follow-ups, re-operations, adjustable surgeries, oblique and vertical strabismus, nystagmus, botulinum toxin injection and microphthalmos.

Simplified, fixed surgical dosage calculation was done as follows: 1 mm recession/resection equals 2 Prism Diopters (PD) for Lateral Rectus and 3 PD for Medial Rectus. If deviation  $\leq 40$  PD, Recession-Resection (R-R) was done in the non-dominant eye only; if deviation 40-60 PD, R-R done: non-dominant eye – 02 muscles, dominant eye – 01 muscle, and if deviation  $\geq 60$  PD, R-R done: non-dominant eye- 02 muscles, dominant eye – 02 muscles.

Criteria for successful outcome was defined as: less than 10 PD deviations from straight in primary position.

Meticulous dissections of intemuscular septum and epimuscular fascia were done. R-Rs were limited upto 8 mm only.

Paired t test was used to find the difference between expected correction and correction achieved.

**Results:** Mean age of patients, preoperative deviation, expected correction and correction achieved were  $28.50 \pm 8.43$  years,  $35.16 \pm 9.97$  PD,  $36.26 \pm 9.49$  PD,  $35.92 \pm 10.74$  PD respectively. Thirty five out of 38 patients (92.10%) had successful outcome. No statistically significant difference was found between expected correction and correction achieved ( $P$  value = 0.519).

**Conclusion:** Our method has very high success rate (92.10%). This simplified, fixed, surgical dosage calculation method would help numerous novice strabismus surgeons, ease their calculation of surgical dosages and thereby give them the confidence to do strabismus surgeries. They may modify the dosages later as per their experiences.

**PP-703****The burden, manifestations and willingness to test for paediatric genetic eye diseases in Ibadan, Nigeria - Evidence for planning**

H Monye<sup>1</sup>, T Oluleye<sup>1</sup>, O Olawoye<sup>1</sup>, M Ugalahi<sup>1</sup>.

<sup>1</sup>Ophthalmology, University College Hospital, Ibadan, Nigeria

**Objective:** To determine the proportion, pedigree, clinical profiles and parental willingness to test for paediatric genetic eye diseases at the University College Hospital, Ibadan, Nigeria.

**Methods:** This study was a hospital-based, cross-sectional study carried out at the Eye Clinic, University College Hospital, Ibadan, involving consecutively recruited new and follow-up patients. Patients presumed to have ocular genetic diseases had their pedigrees charted, comprehensive ocular and systemic examinations, and a questionnaire on willingness to test administered to their parents. Data were analysed using Statistical Package for Social Sciences (SPSS) version 20.0. Means and standard deviations were calculated for continuous variables and proportions for categorical variables. Bivariate and multivariate analyses were used to evaluate the determinants of parental willingness to test. A p-value of  $p < 0.05$  was considered significant.

**Results:** Fifty-two (12%) of the 444 children recruited were presumed to have genetic eye diseases and their mean (SD) age was 6.2 (4.1) years. A total of 13 clinical diagnoses were made and the commonest diagnoses were primary congenital glaucoma (13, 25%) and familial non-syndromic cataracts (8, 15%). Thirty (58%) of the conditions were presumed to be sporadic. Overall, all (100%,  $n = 42$ ) parents were willing to have their children undergo genetic testing with varying proportions (>80%) indicating their willingness to test when presented with different scenarios. There was no statistically significant association between willingness to test, and the parental socio-demographic and children's clinical characteristics. All the parents were positively disposed to free testing, while 37 (88%) were willing to pay out of pocket.

**Conclusion:** This study demonstrated a significant burden of a wide range of genetic eye diseases in children and a high rate of parental willingness for testing. This evidence would be invaluable in guiding the establishment of ophthalmic genetics services in this and similar settings.

**PP-704****Macular microvascular findings in familial exudative vitreoretinopathy on optical coherence tomography angiography**W Wang.**Objective:**

To evaluate macular microvessel changes in familial exudative vitreoretinopathy (FEVR) by optical coherence tomography angiography

**Methods:**

Cross-sectional clinical case-control study. From November 2019 to November 2020, 21 FEVR patients (41 eyes) from Weifang Eye Hospital were selected; 17 healthy volunteers (28 eyes) with the same age and gender as FEVR group were selected as normal control group. According to the best corrected visual acuity (BCVA) 1.0 and  $<1.0$ , FEVR group was divided into normal visual acuity group (27 eyes) and visual acuity decreased group (14 eyes). All enrollees received BCVA and OCTA. BCVA was performed with an international standard visual acuity chart, which was converted to logarithm of the minimum angle of resolution (logMAR) vision. The OCTA instrument was used to scan the macular area of all the examined eyes in the range of  $3\text{ mm} \times 3\text{ mm}$ ,  $6\text{ mm} \times 6\text{ mm}$ , and the blood vessel density (VD) and blood perfusion density (PD) within the range of  $3\text{ mm} \times 3\text{ mm}$ ,  $6\text{ mm} \times 6\text{ mm}$  were measured and the area, circumference, and morphological index of the foveal avascular zone (FAZ) within the range of  $6\text{ mm} \times 6\text{ mm}$ . Quantitative data were compared between groups by independent sample t test. Statistical data were compared by  $\chi^2$  test. The area under curve (AUC) of each index was determined according to receiver operating characteristic curve (ROC curve), and the predictive value of each index was evaluated.

**Results:**

In the macular area of  $6\text{ mm} \times 6\text{ mm}$ , VD, PD, FAZ area and FAZ perimeter of FEVR group were all lower than those of normal control group, and the differences were statistically significant ( $t = -3.350, -2.387, -3.519, -3.029; P < 0.05$ ). In macular area of  $3\text{ mm} \times 3\text{ mm}$  and  $6\text{ mm} \times 6\text{ mm}$ , compared with normal vision group and vision loss group, both VD and PD decreased. The differences were statistically significant ( $t = 2.088, 2.114, 2.160, 2.545; P < 0.05$ ). In the macular area of  $6\text{ mm} \times 6\text{ mm}$ , the FAZ morphological index of the two groups was significantly different ( $t = 2.409, P < 0.05$ ). ROC curve analysis showed that all the indicators had low diagnostic value for FEVR ( $\text{AUC} < 0.5$ ).

**Conclusion:**

There are microvascular abnormalities in macular area in FEVR patients, and the decrease of blood vessels and the change of FAZ shape may be related to the loss of visual acuity

## PP-706

**Isolated aniridia caused by a novel PAX6 heterozygous large deletion mediated by multi-exon complex rearrangement**

A Torrefranca, A Santiago<sup>1</sup>, M Lingao<sup>1</sup>.

<sup>1</sup>*Department of Ophthalmology and Visual Sciences, University of the Philippines - Philippine General Hospital, Manila, Philippines*

**Objective:** Mutations in *PAX6* gene (chromosome 11p13) encoding a transcriptional regulator involved in oculogenesis mostly present with aniridia. Aniridia is not uncommon in the Philippines but only limited information is available as yet. The purpose of this study was to present a novel, large deletion mediated by complex rearrangement in *PAX6* gene causing an isolated aniridia in a Filipino female.

**Methods:** The patient is an 8-year-old female who underwent comprehensive ophthalmologic evaluation. Family history reveals presence of the aniridia and cataract with the mother and a sibling. Systemic work-up was performed including whole abdomen, renal ultrasound, blood chemistry and urinalysis. Targeted cataract panel with *WT1* and *PAX6* genes was performed to determine potential pathogenic mutations.

**Results:** The patient consulted due to leukocoria with associated nystagmus and esotropia. Patient presented with subnormal vision, nystagmus, aniridia and cataractous lenses in both eyes. Patient underwent lens extraction without intraocular lens implantation bilaterally, where patient subsequently underwent intraocular lens implantation on her left eye. Repeat evaluation of posterior pole after cataract removal was unremarkable. Systemic evaluation was unremarkable. Molecular analysis revealed a novel, heterozygous *PAX6*-inherited mutation from the mother. This variant is a complex rearrangement in *PAX6* involving partial deletions of exons 3-4 and part of exon 5, including the initiator codon. Deletions of *PAX6* are part of a contiguous gene deletion syndrome: Wilms tumor, aniridia, genitourinary anomalies and intellectual disability (WAGR) syndrome, and therefore evaluation of the *WT1* gene was necessary to rule out this life-threatening syndrome.

**Conclusion:** This rare, complex rearrangement of multiple exons and deletions in *PAX6* causing an isolated aniridia phenotype is probably the first reported *PAX6* gene of this type. Patient was managed by a multi-disciplinary team and the guardians were counseled regarding the prognosis and complications.

PP-707

**The application of median method in the design of intermittent exotropia**D Xu.

**Objective:** To observe the rate of recurrence, the effectiveness and safety of strabismus surgery.

**Methods:** 100 internal and external strabismus patients of 2 to 50 years old in the same year, and 50 patients of control group A and observation group B were selected. The strabismus is divided into three strabismus angles: light, moderate and severe. Preoperative with prism strabismus, group A with traditional prism routine examination, group B with prism set median method, according to their examination results and comprehensive design axis length, preoperative, postoperative first day, the first week, the first month, the third month, the sixth month of corrected vision, strabismus vision, stereo vision function. To evaluate the orthorate, future recurrence rate and recovery of stereoscopic function after strabismus.

**Results:** Preoperative examination: in the severe internal and external groups, the AB groups evaluated the same strabismus angle, and the difference was not significant ( $P > 0.05$ ); in the mild and moderate groups, the difference were significant ( $P < 0.05$ ); the internal and external groups were significant ( $P < 0.05$ ).

Postoperative examination: in the internal and external strabismus, the positive cure rates of AB was 78.83% and 90.01% respectively, 21.84% and 6.74%, 1.33% and 3.25% respectively. There were statistical differences in the diplopia rate, respectively, 13.11% and 23.45%. The stereo function was statistically different, with effective improvement rates of 35.35% and 50.20%, respectively. During the continuous observation of the first week, the first month and the third month of the sixth month, the positive rate of the control group decreased, the undercorrection rate increased, the overcorrection rate increased, and the overvision improved; the observation group increased, the undercorrection rate decreased, and the overcorrection rate improved significantly.

**Conclusion:** three prism routine strabismus examination method, prism double tuning median method can effectively evaluate the strabismus Angle, the probability is larger, but more likely to double vision, correction, need with late training to improve the double vision, but the stability of the two ways in the strabismus check should be complementary, and reference axis length, to reduce the risk of secondary surgery.

PP-708

**Photorefractive keratectomy in treatment of unilateral amblyopia in children with hyperopia**S Agagulyan, I Aznauryan<sup>1</sup>, V Balasanyan<sup>1</sup>, A Salihova<sup>1</sup>.<sup>1</sup>Association of Pediatric Eye Clinics "Yasnyi Vzor", Moscow, Russian Federation

**Objective:** Biomechanical qualities of the eye is a reason why we need differentiated approach to laser correction in children. In this work, we presented data on treatment of amblyopia in children with hyperopia and astigmatism.

**Purpose:** to conduct a dynamic analysis of visual acuity in children with amblyopia after photorefractive keratectomy.

**Materials:**

The study included 17 patients: 9 boys (53%), 8 girls (47%). Inclusion criteria: patients with hyperopic refraction with spherical equivalent from 4 to 7.5 diopters, amblyopia in only one eye, no dynamics in the axial length and in cycloplegic refraction. The exclusion criteria were organic diseases identified by optical coherence tomography and electrophysiological studies, as well as the presence of astigmatism of more than 2.5 diopters. The average age of patients at the time of surgery was  $9.94 \pm 4.21$  (from 5 to 17). The average visual acuity of the amblyopic eye was  $0.38 \pm 0.23$  (from 0.1 to 0.7).

**Methods:** All patients underwent a standard ophthalmological examination, as well as ultrasound biometry, keratotopography, pachymetry, fundus examination lens. All patients underwent photorefractive keratectomy under general anesthesia with a soft contact lens applied for 3 days as a bandage. After 2 months start doing occlusion of the better seeing eye.

**Results:** analysis of visual acuity in patients after 3-, 6- and 12-months after refractive surgery was carried out.

Visual acuity 3 months after surgery  $0.52 \pm 0.26$  (from 0.3 to 0.8)

Visual acuity 6 months after surgery  $0.57 \pm 0.28$  (from 0.3 to 0.9)

Visual acuity 12 months after surgery  $0.72 \pm 0.26$  (from 0.3 to 0.8)

**Conclusion:** Refractive surgery can be considered as a stage in the treatment of unilateral amblyopia with hyperopic refraction in children if anatomical and optical qualities of the eye are stable for 2 years.



PP-709

**Characteristic of Retinopathy of Prematurity Patient in Dr. Kariadi General Hospital Semarang during 2020**S Dimara, A Saubig<sup>1</sup>.

<sup>1</sup>*Pediatric Ophthalmology and Strabismus Departement , Faculty of Medicine, Diponegoro of University, Semarang, Indonesia*

**Objective:** Our aim was to classify the risk factors that contribute to development of ROP.

**Methods:** A retrospective review of medical records, with descriptive approach, was performed of all ROP patients who came to ophthalmology outpatient clinic from January to Desember 2020 in Dr. Kariadi General Hospital, Semarang. Uncomplete data of medical record was excluded.

**Results:** Thirtyeight patients (38 cases), most gender was female (52.63%) with gestational age  $\leq 28$  weeks (16 cases; 42.11%) and birth weight about 1001-1500 kg (20 cases; 52.63%). Most common risk factors were no maternal risk (31 cases; 81.58%) and oxygen used for  $>7$  days or high flow oxygen (35 cases; 79.55%). Stage V was the most common in post conceptional age  $>40$  weeks (11 cases; 68.75%), gestational age  $\leq 28$  weeks, birth weigh about 1000-1500 gr, (9 cases; 56.25%), respectively, and no risk in maternal, oxygen used for  $>7$  days or high flow oxygen (15 cases; 93.75%), respectively. Twelve patients (31.58%) had vision regression due to ROP. A total of 27 cases (56.25%) were performed conservation as the most therapy.

**Conclusion:** With post conceptional age  $>40$  weeks, gestational age  $\leq 28$  weeks, low birth weight less than 1500 gr, long-term oxygen used or high flow oxygen, the more risk to worsening ROP.

**PP-710****Impact of unilateral visual impairment on binocular functions of school children in Saki-East, Oyo State, Nigeria**

F Ibukun<sup>1</sup>, O Ugalahi<sup>1</sup>, C Bekibele<sup>1</sup>.

<sup>1</sup>*Ophthalmology, University College Hospital, Ibadan, Nigeria*

**Objective:** To determine the impact of unilateral visual impairment or blindness on binocular visual functions in school children in Saki East Local Government Area of Oyo State, Nigeria

**Methods:** A school-based, cross-sectional study was conducted in primary and secondary schools in Saki-East Local government Area of Oyo State between May and July 2021. Students aged 6 to 17 years were recruited using a multistage sampling technique. Visual acuity assessment was done with a LogMAR chart to identify students with unilateral visual impairment or blindness using a cut-off visual acuity worse than +0.3 LogMAR in the worse eye. Binocular visual functions of stereopsis, contrast sensitivity and peripheral visual field were assessed with the Titmus stereo test chart, Mars Contrast sensitivity chart and Lister perimeter respectively. Data was descriptively summarised and bivariate analysis was carried out to test the association between the independent variables and the degree of unilateral visual impairment. A p-value of <0.05 was considered significant

**Results:** Fifty-one children had unilateral visual impairment or blindness of which 28 (54.9%) were females. The mean age was  $10.7 \pm 3.6$  years. The mean stereoacuity value was  $651.57 \pm 864.79$  seconds of arc and 38 (74.5%) participants had weak or no stereopsis. The mean contrast sensitivity value was  $1.07 \pm 0.66$  log units and values were impaired in 50 (98%) participants. The peripheral visual field test was assessed in 47 participants, 29 (61.7%) of whom had constricted visual fields. The level of stereopsis of participants worsened with increasing severity of unilateral visual impairment and this was statistically significant ( $p < 0.001$ ).

**Conclusion:** The results of this study showed that children with unilateral visual impairment or blindness had poor binocular functions. Furthermore, unilateral visual impairment had a negative impact on stereopsis which was worse in participants with more severe visual impairment

PP-711

## Surgical Outcome and Characteristics of Large Angle Exotropic Strabismus Patients: A 2-Year Retrospective Study

A Widyarini.

**Objective:** *To evaluate and knowing the characteristics of large-angle intermittent exotropia can help in early to reduce the impact of the exotropia in patients who underwent surgery 2, 3 or 4 muscles.*

**Methods:** *A retrospective cohort study. All data was collected from medical record of 50 intermittent large-angle exotropia patients with large angles ( $\geq 50$  PD). Characteristic data taken in strabismus patients were age, gender, Krimsky test value (PD units), Worth Four Dot Test, stereoscopic, type of strabismus surgery. All data was determine the relationship between nominal variables and statistically significant result in  $p$  value  $< 0.05$  was considered.*

**Results:** *The mean preoperative and postoperative deviations in this study were  $70.44 \pm 6.56$  D and  $10.28 \pm 3.5$ , respectively, with a range of 59–80 and 7–15, respectively. The total number of recessions and resections in this study was  $8.6 \pm 2.23$  mm with a range of 6–12 mm. Residual exotropia and consecutive esotropia were still found in all type of strabismus surgery.*

**Conclusion:** *The most common age group at arrival was in the age group 6 to 11 years. Patients gender with large-angle intermittent exotropia were mostly women. All patients either with vision less than or equal to 20/400, were tested for Krimsky. Correction of 3-muscle strabismus with the bilateral technique of lateral rectus recession-unilateral resection was the most common surgical option in this study.*

PP-712

### Quantitative evaluation of the wide-field fundus photographs in eyes with severe stage 3 and stage 4A premature retinopathy

S Bayramoglu, N Sayin, M Erdogan .

**Objective:** Differential diagnosis can be challenging between severe stage 3 (accompanied by dense fibrous membranes, retinoschisis, vertical tractional bands) and limited stage 4A retinopathy of prematurity (ROP). The aim of the study was to investigate the quantitative differences between severe stage 3 and stage 4A ROP by evaluating the pre-treatment fundus photographs.

**Methods:** Patient charts of 36 infants of 55 eyes that were diagnosed as severe stage 3 ROP and stage 4A ROP between Jul 2018 and Jan 2022 were included. Thirty-three eyes with dense fibrous membranes near the ridge, elevated retinal vessels/retinoschisis, vertical tractional bands extending into the vitreous and without retinal detachment were classified as severe stage 3 ROP. Twenty-two eyes with limited tractional and exudative retinal detachment without foveal involvement were grouped as stage 4A ROP. Optic disc-to-fovea distance (DF), disc area (DA), width and area of the fibrous membranes, the total retinoschisis and detachment areas were quantitatively measured in pixels on 130-degree fundus photographs.

**Results:** In the severe Stage 3 group, dense fibrous membranes, elevated retinal vessel/ retinoschisis, and vertical tractional bands were detected in 18 eyes (55%), in 28 eyes (85%), in 5 eyes (15%), respectively. None of the eyes had dragging of the posterior pole. In the stage 4A group, dense fibrous membranes, elevated retinal vessels/retinoschisis, vertical tractional bands, and dragging were detected in 21 eyes (96%), in 10 eyes (46%), in 22(100%) eyes, and in 17 eyes (77%) respectively. Dragging and vertical tractional bands were higher in the Stage 4A group than in the severe stage 3 group ( $p=0.000$ ). Disc-to-fovea distance, width of the fibrous membranes, total area of the fibrous membranes, total retinoschisis and detachment areas were significantly higher in the Stage 4A group than in the severe stage 3 group (respectively,  $p=0.000$ ,  $p=0.006$ ,  $p=0.024$ ,  $p=0.000$ ).

**Conclusion:** Dense fibrous membranes, elevated retina vessels/retinoschisis, vertical tractional bands can be detected in severe stage 3 ROP, but the width and the total area of the fibrous membranes and total retinoschisis-detachment area were found to be higher in stage 4A eyes. The dragging of the posterior pole can be an important diagnostic indicator for the diagnosis of stage 4A.

**PP-713****Pediatric retinal detachment following penetrating keratoplasty**H Lu.

**Objective:** Pediatric penetrating keratoplasty can usually be multiple procedures. Repeated invasive intraocular operations may cause long-term intraocular changes in both the anterior and posterior segments including retinal detachment. Five cases of retinal detachment following penetrating keratoplasty were studied to evaluate the clinical prognosis

**Methods:** Five cases of retinal detachment following penetrating keratoplasty were included and 4 cases were treated with vitrectomy and silicone oil tamponade

**Results:** Among 5 cases of retinal detachment following penetrating keratoplasty, 1 patient had to give up surgery due to phthisis and other 4 cases were treated with vitrectomy and silicone oil tamponade. All 4 patients had retinal reattachment and vision improvement. The graft continued to be hazy in 6 months after surgery

**Conclusion:** The management of pediatric retinal detachment following penetrating keratoplasty can be more challenging due to small and hazy cornea conditions. Vitrectomy is usually the choice of surgery and the postop prognosis of both retina and graft remain unfavorable.

## PP-714

## Corneal lenticule implantation with a laser-polished stromal bed to correct hyperopia

M Xie, Y Deng, J tang.

**Objective:** To describe the outcomes after surgery combined allogeneic lenticule implant in refractive correction for a high diopter hyperopia with astigmatism, we named the FTRLI. The innovation lies in the implantation of corneal lenticules into the stroma bed polished by PTK

**Methods:** A 30-year-old female complained of vision disturbance due to hyperopia and wanted surgical correction. UDVA was 20/32 for both eyes. Manifest refraction was OD: + 5.0 DS/ - 1.75 DC × 135° and CDVA of 20/20, OS: + 4.5 DS/ - 1.25 DC × 60° and CDVA of 20/20. The flap had a diameter of 8.10 mm, thickness of 110 μm, standard 50° hinges, and 70° side cut angles. After the flap preparation, an excimer laser phototherapeutic keratectomy (PTK) was used for stromal ablation to create an uniform shallow stromal bed with 15 μm depth and 6.5 mm diameter. Immediately followed by the procedure of photorefractive keratectomy (PRK) to eliminate astigmatism with -0.50 DS/ - 1.75DC × 135° for the right eye and -0.25 DS/ - 1.25 DC × 60° for the left eye. Then put the lenticules on the stromal bed and keep edge of lenticule in good alignment with substrate bed. The lenticules from donor's corneal stroma was performed using the VisuMax femtosecond laser in a myopic population who undergone SMILE, OD: -5.25 DS, thickness of 111 μm, optical zone of 6.5 mm, OS: -5.0 DS, thickness of 100 μm, optical zone of 6.5 mm. Finally repositioned the flap, and covered with a silicone hydrogel contact lens to avoid postoperative flap displacement or microdistortion, which was removed the next day

**Results:** The implanted lenticule were stable in the stromal lamellar, and no complications were detected in the reviews. The visual acuity of both eyes was better than 20/25 until 3 month postoperatively. The preoperative refractive error of right eye was +5.00 spherical -1.75-cylinder 135- axis, which was measured to 0.50-spherical 0.25-cylinder 26- axis after three months postoperatively. For left eye, the refractive error was from +4.50 spherical 1.25-cylinder 60- axis before surgery to 0.50 spherical 0.25-cylinder 18- axis. The patient expressed the extremely satisfaction with the vision

**Conclusion:** we report the first case of FTRLI and corneal stroma lenticule implantation to correct high hyperopia in China. FTRLI surgery with lenticules extracted from SMILE surgery is a potentially feasible, predictable, safe, and effective technique for the correction of hyperopia. It is necessary to carry out further research to explore corneal biomechanics and visual quality

PP-715

**ReLex SMILE for mixed astigmatism laser vision correction**O Ziatdinova.

**Objective:** To demonstrate the ability of ReLex SMILE procedure for slight hypermetropia and mixed astigmatism. To present the ReLex SMILE procedure with low energy femtosecond laser parameters

**Methods:** The study included 21 eyes. The range of hypermetropia was from +0.25 until +2.25 diopters. The range of astigmatism was between 1.0 to 5.0 diopters. The ReLex SMILE software allows to plan for laser vision correction only myopia and minus or plus astigmatism.

We should convert hypermetropia and minus astigmatism into myopia and plus astigmatism. It is possible to do with transposition rule where the mixed astigmatism is recalculated from minus to plus with 90 degrees axis changes.

**Results:** For example, the refraction is sphere + 0.5 cylinder - 4.0 axis 10 degree; for ReLex SMILE procedure we can plan with laser software sphere - 3.5 cylinder + 4.0 axis 100 degree

The laser energy parameters were 24 (120 nJ) and point distance 4.5 microns

All eyes in our study after ReLex SMILE procedure achieved preoperative BCVA.

Most of them (16 eyes) had one or two lines more in Snellen chart compared preoperative BCVA.

The refractive data six months after the ReLex SMILE:

The average postoperative sphere was +/-0.25 diopters

The average postoperative cylinder was 1.15 diopters

**Conclusion:** The ReLex SMILE is effective laser vision correction for slight hypermetropia and mixed astigmatism. For the possibility the ReLex SMILE for hypermetropia with mixed astigmatism we should use transposition rule to convert it to myopia and plus cylinder with 90 degrees changes.

The low energy laser parameters allow to perform the ReLex SMILE without any complication and improve the first postoperative day quality of vision and have faster patient satisfaction with surgery.

PP-717

**Nutrient capsules maintain tear film homeostasis for human corneal lenticule transplantation**J Zhao<sup>1</sup>, Z Zhang<sup>2</sup>, X Zhou<sup>1</sup>.<sup>1</sup>Eye and ENT hospital of Fudan University, <sup>2</sup>EENT hospital of Fudan University, Shanghai, People's Republic of China

**Objective:** To construct a novel nutrient capsule which simulates the human tear film homeostasis for the three-dimensional preservation of corneal lenticule and to evaluate its safety and effectiveness.

**Methods:** A nutrient hydrogel capsule that could maintain the homeostasis of tear film was constructed for preserving human corneal lenticules. The nutritional preservation solution containing sodium alginate was coordinated with calcium ions by rapid diffusion to form a stereoscopic buffer capsule, in which chondroitin sulfate interacted with the corneal lenticule surface electrostatically to form a lubricating layer for three-dimensional preservation and nutritional supply. The light transmittance, cell activity, and collagen fiber density of human corneal lenticules after mid-term preservation in nutrient capsules were evaluated. The lenticules preserved in nutrient capsules were used for human allogeneic transplantation for treating corneal diseases and refractive errors.

**Results:** There was no significant difference in the cell survival rates between the nutrient capsules group and the control group at 3 (P=0.59) and 5 days (P=0.08), as well as between the soaking solution and control group at 3 (P=0.45) and 5 days (P=0.94). At 28 days of preservation, there was no significant difference between the nutrition capsule group and the control group, while the live cells in the Optisol (P=0.03), DMEM (P<0.0001), and glycerol (P<0.0001) groups were significantly lower compared to the control group. After 14 days of preservation, there was no significant difference in the light transmittance between the nutrient capsule group and the control group (P=0.12), while the transmittances of the other three groups were significantly lower than that of the control group (P<0.05). Compared with other experimental groups, the corneal collagen fibers in the nutrient capsule preserved human lenticules were more tightly arranged, with fewer cavitation bubbles and clear lenticule edges. The implanted lenticules remained transparent without displacement or graft rejection, and the corrected distance visual acuity increased by two or more lines in 70% of the patients' operated eyes three months after lenticule transplant surgery.

**Conclusion:** This novel nutrient capsule provides a safe and feasible strategy for the preservation and reuse of human corneal lenticules.



## PP-719

**Impact of pupil size upon the quality of vision in patients implanted with an implantable collamer lens (ICL V4c).a**

Q Zhang, E Pazo<sup>1</sup>, W He<sup>1</sup>.

<sup>1</sup>He Eye Specialist Hospital, shenyang, People's Republic of China

**Objective:** The goal of this study was to assess the influence of pupil size on subjective and objective visual quality in subjects who had implanted collamer lenses (ICLs). Furthermore, the ideal pupil size associated with improved visual quality was investigated.

**Methods:** This retrospective study includes 53 patients (53 eyes) who had ICL surgery. At three months after ICL implantation, participants were classified into seven categories according on their pupil size and their uncorrected distance visual acuity (UDVA), higher order aberration (HOA), and quality of vision (QoV) questionnaire score were compared amongst the seven groups.

**Results:** Post-operatively at 3-months the mean QoV score for day and night was  $9.34 \pm 0.76$  and  $8.58 \pm 1.29$  respectively. The mean mesopic pupil size (MPS) and mean photopic pupil size (PPS) was  $4.61 \pm 0.74$  mm and  $6.59 \pm 0.79$  mm respectively. PPS negatively correlated with "QoV day" ( $R_s = -0.413$ ,  $P = 0.001$ ), positively correlated with "haloes" ( $R_s = 0.568^*$ ,  $P < 0.001$ ) and "blurred vision" ( $R_s = 0.243$ ,  $P = 0.04$ ) respectively. MPS negatively correlated with "QoV night" ( $R_s = -0.426$ ,  $P = 0.001$ ), positively correlated with "haloes" ( $R_s = 0.624^*$ ,  $P < 0.001$ ), "starburst" ( $R_s = 0.233$ ,  $P = 0.046$ ) and "difficulty focusing" ( $R_s = 0.27$ ,  $P = 0.025$ ) respectively.

**Conclusion:** The findings of this study suggests that pupil size of the patients who underwent ICL has a negative correlation on their subjective visual quality (QoV) during the day and night. Smaller pupil size during the night had significantly better night QoV score. The optimal pupil diameter for achieving significantly better QoV score during the night was found to range from 4 to 4.99 mm.

**PP-720****Refractive errors and corneal properties in patients with nystagmus**

O Nasser, W Wahbi.

**Objective:** To describe the corneal and refractive properties of patients with congenital nystagmus syndrome compared to healthy subjects.

**Methods:** In this comparative cross-sectional observational study, a scheimpflug imaging tomography was conducted on eyes of congenital nystagmus syndrome patients and compared with those of healthy individuals (control group). Corneal astigmatism prevalence, corneal astigmatic power, maximal keratometry, mean keratometry and pachymetry values were obtained and compared between the groups.

**Results:** 32 eyes of 16 congenital nystagmus syndrome patients and 32 eyes of 16 healthy individuals were included in the study. All nystagmus patients (100%) had astigmatism of at least 1 diopter compared to 11 subjects (34.375%) in the control group ( $P < 0.001$ ). The average astigmatic power in the patient's group was  $3.383 \pm 1.135$  diopters compared to  $0.8281 \pm 0.5854$  diopters in the control group ( $P < 0.001$ ). The maximal keratometric power in the patient's group was  $44.16 \pm 2.444$  diopters compared to  $42.88 \pm 2.052$  diopters in the control group ( $P = 0.027$ ). The mean keratometric power in the patient's group was  $41.98 \pm 2.129$  diopters compared to  $41.40 \pm 5.121$  diopters in the control group ( $P = 0.560$ ). The mean pachymetric value in the patient's group was  $557.1 \pm 47.15$   $\mu\text{m}$  compared to  $544.2 \pm 29.32$   $\mu\text{m}$  in the control group ( $P = 0.1945$ ).

**Conclusion:** All patients with congenital nystagmus syndrome have visually significant astigmatism. This means that there is another major contributor to reduced vision in nystagmus patients, which is the high astigmatism. Corneal tomography can be used to assess and grade the corneal astigmatism in these patients.

## PP-721

**A Prospective Randomized Self-Controlled Study of LASIK Combined with Accelerated Crosslinking for High Myopia: 24-Month Follow-up**

R Dong<sup>1</sup>, Y Zhang<sup>1</sup>, Y Yuan<sup>1</sup>, Y Liu<sup>1</sup>, Y Wang<sup>1</sup>, Y Chen<sup>1</sup>.

<sup>1</sup>Peking University Third Hospital, Beijing, People's Republic of China

**Objective:** To evaluate the clinical effects of femtosecond laser-assisted in situ keratomileusis (FS-LASIK) and FS-LASIK concurrent with accelerated corneal collagen cross-linking (FS-LASIK Xtra) for high myopia in Chinese.

**Methods:** Prospective randomized self-controlled study. 25 patients with high myopia who visited our hospital from May 2019 to January 2020 were randomly treated with FS-LASIK Xtra in one eye and FS-LASIK in the other eye. The patients were followed up at 1 day, 1 week, 1 month, 3 months, 6 months, 12 months and 24 months after operation. The main outcome measures included uncorrected distance visual acuity (UDVA), corrected distance visual acuity (UDVA), manifest refraction spherical equivalent (MRSE), endothelial cell count (ECC) and corneal tomography.

**Results:** The UDVA of FS-LASIK Xtra group on the first day after operation was  $0.09 \pm 0.15$  LogMAR, which was significantly worse than that of FS-LASIK group ( $P = 0.001$ ), but there was no significant difference any more from 1 week postoperatively. At 24 months after surgery, the safety index was  $0.99 \pm 0.16$  in FS-LASIK Xtra group and  $1.08 \pm 0.13$  in FS-LASIK group ( $P = 0.112$ ), while the effective index was  $0.88 \pm 0.18$  and  $0.99 \pm 0.13$ , respectively ( $P = 0.028$ ). 16 eyes (89%) in each group achieved MRSE that was within 0.50D of the target. 14 eyes (78%) in FS-LASIK Xtra group and 12 eyes (67%) in FS-LASIK group had residual astigmatism within 0.25D ( $P = 0.711$ ). During the follow-up, MRSE and keratometry values of both groups showed slight trends of myopic drift, but there was no significant difference between the two groups. In FS-LASIK Xtra group, mild haze and cross-linking lines were observed at early stage after procedure and the corneal density was significantly higher than that in FS-LASIK group throughout 24-month follow-up ( $P < 0.05$ ). There was no significant difference in ECC between preoperative and postoperative results or between the two groups. No serious complication was observed in both groups.

**Conclusion:** FS-LASIK Xtra showed comparable safety and predictability with FS-LASIK for high myopia in Chinese, but lower efficacy and no better stability was observed up to 24-month follow-up.

PP-722

**Plasma rich in growth factor vs mitomycin c in Photorefractive keratectomy****E Uribe**<sup>1,2,3</sup>, **J Merayo**<sup>4</sup>, **R Sanchez**<sup>4</sup>.

<sup>1</sup>Corneal and external disease - Uveitis, Instituto Universitario Fernandez Vega- Universidad de Oviedo, Oviedo, Spain, <sup>2</sup>Corneal and external disease - Uveitis, Clinica Delgado, <sup>3</sup>Corneal and external disease - Uveitis, Universidad San Martin de Porres, Lima, Peru, <sup>4</sup>Ocular Immunology - Uveitis, Instituto Universitario Fernandez Vega- Universidad de Oviedo, Oviedo, Spain

**Objective:** To evaluate the efficacy and safety of Plasma Rich in Growth Factors (PRGF) in prevention of corneal haze in patients undergoing PRK surgery and the comparison with the use of mitomycin c

**Methods:** This retrospective study included patients of the consultation of IUFV (Fernández-Vega University Institute) Corneal Unit between 2013 and 2016 who underwent PRK surgery.

They have spherical correction range from -0.25 to -8.00 D, cylinder correction range from -0.25 to -3.00 and refraction stability at least 1 year. The mitomycin C was used in 0.02% concentration, 10 seconds per Diopter treated with maximum of 40 seconds and PRGF follow the Endoret System protocol, having contact with the surface for a minute in all cases.

Primary endpoint was evaluate and compare the efficacy and safety on both treatments, The adverse events also were reported.

**Results:** Sixty-nine patients of 117 eyes were included in the present study. Forty-four patients (72 eyes) were treated with MMC and twenty-five patients (45 eyes) with PRGF. There were no statistically significant difference in previous CDVA, sphere, cylinder or EE between the groups.

The average corneal ablation was  $29.3 \pm 12.6 \mu\text{m}$ , and the remanent stroma was  $491.4 \pm 44.5 \mu\text{m}$ .

The epithelization time was  $63.7 \pm 12.3$  hours and UDVA (LogMAR) was  $0.029 \pm 0.059$ , there was not statistically significant difference between the treatments.

The corneal endothelial cell density in both groups was very similar ( $p = 0.054$ ), there was no was statistically significant difference between treatments in efficacy ( $p = 0.062$ ) and security ( $p = 0.158$ )

There was no reports of adverse effects in this study

**Conclusion:** The use of PRGF in prevention of corneal opacity is as effective and safe as Mitomycin C, with no recurrence or corneal haze in one year of follow up

**PP-723****A comprehensive investigation of contrast sensitivity and disk halo in high myopia treated with SMILE and EVO ICL**

W Zhao, X Zhou.

**Objective:** To investigate the clinical outcomes in small incision lenticule extraction (SMILE) and EVO implantable collamer lens (ICL)-treated high myopia.

**Methods:** Thirty-three SMILE-treated and 32 EVO ICL-treated patients were included and followed up for 6 months. Subjective refraction, contrast sensitivity, and disk halo size were measured preoperatively and postoperatively. Patient-reported outcomes (PROs) were obtained at the final visit.

**Results:** Significant differences in efficacy and safety indices were observed between the SMILE and EVO ICL groups at 6 months postoperatively ( $P < 0.05$ ). In the SMILE group, the mesopic contrast sensitivity at 2.2 cycles per degree (cpd) and photopic contrast sensitivity at 0.5, 3.4, and 7.1 cpd were significantly improved. In the EVO ICL group, the mesopic contrast sensitivity at 7.1 cpd and photopic contrast sensitivity at 0.5, 7.1, and 14.6 cpd were significantly improved. The halo radii after SMILE were significantly increased at 1 week, showed a decreasing trend at 1 month, returned to baseline at 3 months, and progressed stably at 6 months. However, it was unchanged in the EVO ICL group. Regarding subjective experience, haloes were the most common disturbance with mild and little bothersomeness after EVO ICL in contrast to starbursts after SMILE.

**Conclusion:** EVO ICL implantation yielded better visual outcomes, improved contrast sensitivity particularly at high spatial frequencies, had a stabler disk halo size, and increased incidence of haloes, with less influence than that of SMILE.

PP-724

**Effect of epithelial remodeling after corneal refractive surgery on enhancement surgery**J Bai.

**Objective:** Through the observation and analysis of enhanced corneal refractive surgery with corneal abnormal epithelial remodeling, this paper discusses the correct selection of enhanced surgery, so as to improve the predictability and accuracy of surgery

**Methods:** From 5 M to 18 Y after corneal myopia correction surgery, 16 myopic eyes showed regression or poor visual quality, and enhancement surgery was required. Keratoconus have been excluded , Corneal epithelial thickness, epithelial topography and axial length were examined and analyzed. Enhancement surgery includes: Circle surgery 1 eye, LASIK 2 eyes, LASIK corneal flap uncovering 10 eyes , LASEK 3 eyes ;Conventional surgery was designed in 7 eyes and the corneal topography guided surgery in 9 eyes.

**Results:** Except for LASEK operation, the refractive condition and UCVA of eyes with other operation methods reached the expectation postoperative 1W and the thickness and morphology of corneal epithelium did not change significantly before and after operation;Three eyes with LASEK operation showed overcorrection postoperative 1M , which was compared with the expectation; At the same time, there were significant changes in corneal thickness( $12 \pm 4$  micron) and morphology before and after operation, Until 3 to 6 months after operation, the corneal epithelial thickness returned to the preoperative level, The visual acuity and refractive condition were close to the preoperative expectation ; The refractive condition of other

**Conclusion:** Enhancement surgery after corneal refractive surgery, corneal epithelial morphology and thickness examination should be completed ; Pay attention to the influence of epithelial thickness and morphological abnormalities on the accuracy of enhancement surgery ; If corneal surface surgery is used, the effect of corneal epithelial remodeling after enhancement surgery should be considered

PP-726

### Clinical results of topography-guided FS-LASIK using anterior corneal astigmatism axis and manifest astigmatism axis

C Liu<sup>1</sup>, X Fang<sup>1</sup>, Y Wang<sup>2</sup>.

<sup>1</sup>Refractive Surgery Department, Shenyang Aier Eye Hospital, Shenyang, <sup>2</sup>Refractive Surgery Department, Tianjin Key Lab of Ophthalmology and Visual Science, Tianjin Eye Hospital, Tianjin, People's Republic of China

**Objective:** To evaluate the clinical results of primary topography-guided femtosecond laser-assisted in situ keratomileusis (TG-FS-LASIK) using the Pentacam-measured anterior corneal astigmatism axis (ACA) or manifest refractive astigmatism axis (MRA).

**Methods:** In this prospective cohort study, all eyes were treated with primary TG-FS-LASIK using the manifest cylinder. Thirty-two right eyes were treated using ACA with axis disparity  $>5^\circ$  in the experimental group, and 32 right eyes were treated using MRA with axis disparity  $\leq 5^\circ$  in the control group. Visual, refractive outcomes, and corneal higher-order aberrations were evaluated. Vector analysis of astigmatism was performed using Alpins method with the ASSORT software.

**Results:** The mean logMAR UDVA in the experimental group was  $-0.12 \pm 0.06$ ,  $-0.05 \pm 0.08$  and  $-0.08 \pm 0.08$  at 1-week, 1-month and 3-month follow-up, whereas  $-0.05 \pm 0.06$ ,  $-0.12 \pm 0.06$  and  $-0.14 \pm 0.06$  in the control group ( $p=0.017$ ,  $p<0.001$  and  $p=0.003$ ). At 3-month follow-up, 79% eyes achieved a UDVA of 20/16 or better, 9% gained one line of corrected distance visual acuity, the mean manifest cylinder was  $-0.375 \pm 0.254$  D, 84% showed a manifest cylinder within  $\pm 0.50$  D, the mean magnitude of difference vector was  $0.41 \pm 0.35$  D, the mean absolute angle of error (AE) was  $7.36 \pm 6.21^\circ$ , and 41% exhibited an arithmetic AE within  $\pm 5^\circ$  in the experimental group, whereas 94%, 19%,  $-0.203 \pm 0.148$  D, 100%,  $0.21 \pm 0.15$  D,  $3.39 \pm 3.68^\circ$ , and 69% in the control group (all  $p<0.05$ ). The Pentacam-measured preoperative and 3-month postoperative corneal spherical aberration at central 6-mm optical zone were  $0.231 \pm 0.089 \mu\text{m}$  and  $0.265 \pm 0.118 \mu\text{m}$  in the experimental group, and  $0.230 \pm 0.077 \mu\text{m}$  and  $0.240 \pm 0.088 \mu\text{m}$  in the control group. The comparison within and between groups was of no statistical difference ( $p=0.980$ ,  $p=0.409$ ,  $p=0.305$ ,  $p=0.636$ ).

**Conclusion:** Primary topography-guided FS-LASIK using Pentacam-measured anterior corneal astigmatism axis exhibited slightly inferior clinical results to that using the manifest refractive astigmatism axis. There was almost no changes in corneal spherical aberration 3 months after both treatment methods.

PP-727

**Polarization Sensitive Optical Coherence Tomography (PSOCT) – A New Screening Tool In Refractive Surgery**

R R Ranade<sup>1</sup>, R *Shetty*<sup>1</sup>, A *Sinha Roy*<sup>1</sup>, P *Khamar*<sup>1</sup>, R *Patil*<sup>1</sup>.

<sup>1</sup>NARAYANA NETHRALAYA, BENGALURU, India

**Objective:** To determine preferential alignment of collagen fibres in healthy & keratoconus (KC) corneas, and correlate with early disease-related collagen-fibre changes in suspect corneas.

**Methods:** 50 healthy, 50 KC, 50 suspect, 35 asymmetric fellow corneas of KC patients imaged using ultra-high-resolution polarisation-sensitive(PSOCT). Phase retardation (PR) enface maps generated from corneal posterior surface. Zonal analysis performed on enface maps in annular zones from centre to periphery

**Results:** PR maps of normal eyes showed preferential arrangement of collagen fibrils, with least retardation in apex increasing gradually towards periphery. Suspect corneas showed visibly different alignment. Zonal analysis showed significantly higher PR in suspects compared to normal eyes( $p < 0.05$ ).

**Conclusion:** Changes in PR directly indicate changes in collagen fibre preferential alignment, thus outlining differences between normal and suspicious corneas, which could possibly indicate weaker biomechanics. It can be used in clinical settings for early diagnosis of KC in normal/suspicious topography, and screening for refractive procedures.



PP-728

## Corneal Epithelial Remodeling and its Influence on Postoperative Diopters after Small Incision Lenticule Extraction

L Xia, Y Feng.

**Objective:** To study the distribution and change rules of corneal epithelial thickness following SMILE.

**Methods:** In this prospective cohort study, 85 eyes that underwent SMILE for myopia and myopic astigmatism correction were received ET and corneal thickness measurement by AS-OCT at each corneal region before and after operation. Compare the differences of ET between different regions and observe the distribution and change rule of ET. Analyze the correlation between CET and surgical correction diopter and axial length.

**Results:** The central corneal epithelial thickness (CET) was  $49.38 \pm 3.88 \mu\text{m}$  before operation. At 3 months after SMILE, the central CET was  $55.38 \pm 6.69 \mu\text{m}$ . The thickness of central corneal epithelium at 3 months postoperatively was significantly different from that before operation ( $P < 0.05$ ), and the increases of ET in the area of 0~2, 2~5, and 5~7 mm compared with preoperative value were  $5.99 \pm 5.09 \mu\text{m}$ ,  $5.36 \pm 4.53 \mu\text{m}$ , and  $2.22 \pm 4.08 \mu\text{m}$ , the difference of ET before operation and 3 months postoperatively in each area was statistically significant. The change of CET after surgery was positively correlated with preoperative refractive diopter and axial length ( $P < 0.05$ ). Three months after surgery, the average SE was  $0.10 \pm 0.49 \text{ D}$ . Central corneal epithelial remodeling is negatively correlated with postoperative refractive diopter ( $P < 0.001$ ), that is, more central ET increased, postoperative SE was more prone to myopia.

**Conclusion:** The corneal epithelial remodeling was observed significantly within 3 months after SMILE. Closer to the central area, the more obvious the thickness of the corneal epithelium increased. The more obvious the central corneal epithelial remodeling is, the more the postoperative refractive power drifts to myopia.

PP-729

**Relationship between corneal biomechanical properties and corneal densitometry after small-incision lenticule extraction**Y Huang<sup>1</sup>, T Han<sup>1</sup>, X Zhang<sup>1</sup>, P Yao<sup>1</sup>, X Zhou<sup>1</sup>.<sup>1</sup>*ophthalmology, Eye & ENT Hospital of Fudan University, Shanghai, People's Republic of China*

**Objective:** To investigate corneal biomechanical properties and corneal densitometry changes after small-incision lenticule extraction (SMILE) and their relationship.

**Methods:** This prospective study included 20 patients (40 eyes) undergoing SMILE from April 2020 to March 2021. Routine ophthalmic examinations were conducted preoperatively, 1 month postoperatively, and 3 months postoperatively. Corneal biomechanical properties were evaluated with Corvis ST and the densitometry of different areas of the cornea was obtained Pentacam.

**Results:** There were significant changes in corneal biomechanical parameters including AT1, DA Ratio, IR, SP-A1, and SSI after SMILE ( $P < 0.05$ ). Regarding densitometry, significant changes were observed mainly in the anterior and middle parts of the cornea ( $P < 0.05$ ). Postoperatively 3 months, the total corneal densitometry was positively correlated with AT1 ( $r = 0.610$ ,  $P < 0.01$ ), DA Ratio ( $r = 0.419$ ,  $P < 0.01$ ), and SP-A1 ( $r = 0.542$ ,  $P < 0.01$ ). The correlations among other parameters were not significantly observed.

**Conclusion:** After the SMILE surgery, corneal densitometry was associated with corneal biomechanical parameters, indicating that densitometry might represent changes in corneal biomechanics to some extent.

PP-731

## Artificial-intelligence-based Prediction Of Refractive Error and EVO-ICL Lens Power Calculation For Myopia Correction

Y Jiang<sup>1</sup>, C Wang<sup>2</sup>, Y Shen<sup>1</sup>, X Wang<sup>1</sup>, X Zhou<sup>1</sup>.

<sup>1</sup>Department of Ophthalmology and Optometry, Eye and ENT Hospital, Fudan University, <sup>2</sup>Research and Development Department, Shanghai MediWorks Precision Instruments Company Limited, Shanghai, People's Republic of China

**Objective:** To predict the postoperative refractive error and the EVO-Implantable Collamer Lens(ICL) power by artificial intelligence(AI).

**Methods:** We included 2725 eyes of 1565 patients undergoing ICL surgery from 2014 to 2021. The manifest refraction was measured between 1 week and 1 month postoperatively. Permutation importance and impurity-based feature importance were used to assess the impact of input features on the postoperative spherical equivalent(SE). Machine learning models (SVR, Lasso, Random Forest and XGBoost) were trained to predict the postoperative SE and sphere. Subgroup analysis was performed based on the preoperative SE( $\geq 10.0D$  and  $< 10.0D$ ) and preoperative sphere( $\geq 10.0D$  and  $< 10.0D$ ), respectively. The ensembled models combined the models performing best in each subgroup. Then, ICL SE and ICL sphere were set as the prediction target, and the postoperative SE, sphere and the other input features were set as the new inputs. Refraction prediction error of each model was calculated for each eye. The accuracy of the trained models was compared with the existing formula by mean absolute error(MAE), median absolute error(MedAE), and the percentage of eyes within  $\pm 0.25D$ ,  $\pm 0.50D$  and  $\pm 0.75D$ .

**Results:** All the machine learning models had numerically lower MAE and higher percentage of eyes within  $\pm 0.25$ ,  $\pm 0.50$ , and  $\pm 0.75D$  than the existing formula. The Random Forest and XGBoost had the lowest MAE In predicting SE(0.349) and sphere(0.353), respectively. In the subset of SE $< 10.0D$  and SE $\geq 10.0D$ , the Random Forest and SVR had the best results (MAE=0.302 and 0.385). The ensembled model for predicting SE had a lower MAE(0.339) and a higher percentage of eyes within  $\pm 0.25D$ (46.9%),  $\pm 0.50D$ (77.1%) and  $\pm 0.75D$ (91.8%). In the subset of sphere $< 10.0D$  and sphere $\geq 10.0D$ , the SVR and the Random Forest performed best(MAE=0.329 and 0.398). The ensembled model for predicting sphere decreased the MAE(0.353) and improved the percentage of eyes within  $\pm 0.25D$  (47.0%),  $\pm 0.50D$  (75.9%), and  $\pm 0.75 D$  (91.3%). Using the ensembled models, the MAE of predicting ICL SE and ICL sphere were 0.255 and 0.300, respectively. The percentage of eyes within  $\pm 0.25D$ ,  $\pm 0.50D$ , and  $\pm 0.75 D$  achieved 54.6%, 84.0%, and 94.6% for ICL SE, and corresponding values were 54.9%, 84.0%, and 94.3% for ICL sphere.

**Conclusion:** AI-based models predict the refractive error accurately and may assist to design surgical strategies. Random forest and SVR models have great potential to be optimized and improve ICL surgery predictability.

PP-732

**Identify Affecting Factors for the Outcome of SMILE Surgery Using Artificial Intelligence**Y Wang, S Liang, S Ji, X Liu, M Chen, Y Lei, J Hou, M Li, H Zou, Y Peng, Z Ma, V Jhanji.

**Objective:** To identify the key factors influencing postoperative refraction after small-incision lenticule extraction (SMILE) applying information gain by AI.

**Methods:** The study comprised 2350 eyes of 1200 patients who underwent SMILE in three ophthalmic centers. Anterior segment features, including corneal curvature and central corneal thickness (CCT), were obtained from Pentacam HR (Oculus, Wetzlar, Germany). Information gain was calculated to analyze the importance of features affecting postoperative refraction.

**Results:** Preoperative and postoperative mean spherical equivalent (SE) refraction were -5.00 (-6.13, -3.88) D and 0.00 (-0.25, 0.13) D, respectively. None of the patients lost more than two lines of corrected distance visual acuity. The safety index was  $1.32 \pm 0.24$ ,  $1.03 \pm 0.08$ , and  $1.13 \pm 0.16$  in centers A, B, and C, respectively. The efficacy index was  $1.31 \pm 0.25$ ,  $1.02 \pm 0.08$ , and  $1.13 \pm 0.17$  in centers A, B, and C, respectively. At least 95% of the eyes were within  $\pm 1.00$  D of the attempted correction. Postoperative refraction was related to preoperative spherical diopter refraction ( $r=0.369$ ,  $p<0.001$ ), preoperative SE ( $r=0.364$ ,  $p<0.001$ ), maximum lenticule thickness ( $r=-0.311$ ,  $p<0.001$ ), preoperative uncorrected distance visual acuity ( $r=0.164$ ,  $p<0.001$ ), residual stromal thickness ( $r=0.139$ ,  $p<0.001$ ), preoperative mean anterior corneal curvature ( $r=-0.127$ ,  $p<0.001$ ), preoperative flattest anterior corneal curvature ( $r=-0.122$ ,  $p<0.001$ ), nomogram ( $r=-0.100$ ,  $p<0.001$ ) and preoperative CCT ( $r=-0.058$ ,  $p=0.005$ ).

**Conclusion:** The factors affecting the surgical outcome in order of importance were preoperative spherical diopter refraction, preoperative SE, maximum lenticule thickness, preoperative uncorrected distance visual acuity, residual stromal thickness, preoperative mean anterior corneal curvature, preoperative flattest anterior corneal curvature, nomogram and preoperative CCT. Postoperative refraction was influenced by preoperative mean anterior corneal curvature, CCT, refraction, and residual stromal thickness according to information gain by AI.

PP-734

**Prediction of vault size after Implantable Collamer Lens implantation based on deep learning**Y Di<sup>1</sup>, Y Li<sup>1</sup>, Y Luo<sup>1</sup>, Y Xu<sup>2</sup>, H Fang<sup>2</sup>, Y Yang<sup>3</sup>.<sup>1</sup>Ophthalmology, Peking Union Medical College Hospital, <sup>2</sup>Intelligent Healthcare Unit, Baidu, <sup>3</sup>South China University of Technology, Beijing, People's Republic of China**Objective:** To investigate the practicalities of deep learning in predicting vault size after Implantable Collamer Lens (ICL) V4c implantation, and to propose the best performance deep learning model.**Methods:** This study included AS-OCT images of 707 patients (707 eyes) one week after ICL V4c implantation. ResNet50, MobileNet and Swin Transformer-B were used to construct models to predict the vault size one week after ICL V4c implantation. Mean absolute error (MAE), median absolute error (MedAE), root mean square error (RMSE) and symmetric mean absolute percentage error (SMAPE) were used to compare the prediction performance of each model. In addition, paired t-test and Pearson correlation test were analysis differences and correlations between the predicted vault and actual vault of each deep learning model.**Results:** The data set was divided into a training set of 180 patients (180 eyes) and a test set of 527 patients (527 eyes). ResNet50 and Swin Transformer-B had similar prediction errors, which were less than prediction error of MobileNet. For ResNet50, the MAE, MedAE, RMSE, and SMAPE were 127.02  $\mu\text{m}$ , 107.53  $\mu\text{m}$ , 156.54  $\mu\text{m}$ , and 20.01%, respectively. For Swin Transformer-B, the MAE, MedAE, RMSE, and SMAPE were 126.97  $\mu\text{m}$ , 108.30  $\mu\text{m}$ , 156.61  $\mu\text{m}$ , and 20.00%, respectively. There was no significant difference between the predicted vault and the actual vault of the above three deep learning models ( $P = 0.656$ ,  $0.829$ , and  $0.378$ , respectively). And the predicted vault had positive correlated with the actual vault of ResNet50 and Swin Transformer-B ( $P < 0.001$ ), but there was no significant correlation between them in MobileNet ( $P = 0.829$ ). Swin Transformer-B was selected based on MAE value and compared with the multiple linear regression analysis prediction formula and XGBoost model proposed in this project. The MAE value: XGBoost model (121.70  $\mu\text{m}$ ) < Swin Transformer B model (126.97  $\mu\text{m}$ ) < multiple linear regression formula (135.09  $\mu\text{m}$ )**Conclusion:** ResNet50 and Swin Transformer-B can be used to predict the vault after ICL V4c implantation, and the model performance can be further improved by expanding the sample size in the future.

PP-735

**Effective Optical Zone and Refractive Outcomes of two Excimer Ablation Profiles in treatment of myopia**F An<sup>1,1</sup>, W Zhao<sup>1</sup>, L Sun<sup>1</sup>, J Zhou<sup>1</sup>.<sup>1</sup>Ophthalmology, Xijing Hospital, Xi'an, People's Republic of China

**Objective:** To compare the asymmetric and symmetric ablation profiles in myopia femtosecond laser-assisted laser in situ keratomileusis (FS-LASIK).

**Methods:** Retrospective case series. All cases were randomized to receive asymmetric (A group) and symmetric (S group) ablation mode with the SCHWIND Amaris 750S excimer laser platform (SCHWIND eye-tech-solutions, Kleinostheim, Germany) with the same planned optical zone on the contralateral eyes based on a coin toss method, LASIK flaps were created using the 150-kHz IntraLase iFS (Abbott Medical Optics, Santa Ana, CA) with same diameter. Refractive outcomes were measured at 1 week, 1 month, and 3 months postoperatively; corneal wavefront aberration, effective optical zone (EOZ) and ablating centers were evaluated 3 months after the operation. The EOZ were analyzed the tangential curvature difference map of the Scheimpflug tomography system with a modified strategy and OS. data were flipped to calculate. The EOZ were stimulated with an ellipse to determine the size and centroid.

**Results:** The study included 43 patients (86 eyes). The frequency with which the A group and S group achieved postoperative UDVA of  $\geq 20/20$ , lost lines or maintained their preoperative CDVA, refractive error within  $\pm 0.25$  diopters of emmetropia were not statistically different from each other (all  $P > 0.05$ ). There were no statistically significant differences in coma, trefoil, spherical aberration or higher-order root mean square error (HOAs) between the groups (all  $P > 0.05$ ), and postoperative trefoil were less and coma, spherical aberration, HOAs were larger (all  $P < 0.05$ ) with ANOVA test. The mean EOZ sizes were  $22.43 \pm 3.30 \text{ mm}^2$  (A) and  $22.86 \pm 3.08 \text{ mm}^2$  (S) ( $P = 0.202$ ), the centroid offsets were  $0.29 \pm 0.17 \text{ mm}$  (A) and  $0.18 \pm 0.13 \text{ mm}$  (S) ( $P < 0.001$ ), divided offset to X-axis (A  $0.03 \pm 0.23$  vs. S  $0.03 \pm 0.14$ ,  $P = 0.93$ ) and Y-axis (A  $0.14 \pm 0.21$  vs. S  $0.06 \pm 0.16$ ,  $P = 0.04$ ), the EOZ/FOZ ratio (A  $0.63 \pm 0.07$  vs. S  $0.64 \pm 0.07$ ,  $P = 0.175$ ). The preoperative kappa offset was positively correlated with OZ centroid offset in A group ( $r = 0.438$ ,  $P < 0.01$ ), the slope of linear regression is  $y = 0.95x + 0.09$  ( $R^2 = 0.19$ ,  $P < 0.001$ ); however, no correlation was found in the S group ( $r = 0.072$ ,  $P = 0.65$ ). The origin point was located outside the 95% confidence ellipse of OZ centroid in both groups.

**Conclusion:** The SCHWIND Amaris asymmetric and symmetric profile customized FS-LASIK provide similar results in myopia patients; however, the asymmetric mode emerges a stronger tendency in optical zone decentration with a large kappa angle.

PP-736

### Changes in Corneal Biomechanical Properties After Small-Incision Lenticule Extraction and Photorefractive Keratectomy

S Zarei-Ghanavati, S *Hasanzadeh*.

**Objective:** The aim of this study was to evaluate and compare early corneal biomechanical changes after small-incision lenticule extraction (SMILE) and photorefractive keratectomy (PRK).

**Methods:** The study comprised 74 patients eligible for refractive surgery, equally allocated to PRK (37 patients) and SMILE (37 patients). Corneal biomechanical properties were recorded and compared between the 2 groups at preoperatively and 3 months after surgery using a dynamic ultra-high-speed Scheimpflug camera equipped with a noncontact tonometer.

**Results:** Both procedures significantly affected corneal biomechanical properties at 3 months after surgery. Patients in the PRK group showed significantly better results for deformation amplitude ratio (DA ratio) ( $P = 0.03$ ), maximum inverse radius (InvRadMax) ( $P = 0.02$ ), and A2 time ( $P = 0.03$ ). The mean changes in DA ratio, HC radius, InvRadMax, and Ambrosio relational thickness were significantly higher in the SMILE group in comparison with those of the PRK group (all,  $P < 0.05$ ). In both groups, change in CCT was significantly correlated with changes in DA ratio and InvRadMax ( $P < 0.05$ ).

**Conclusion:** Both SMILE and PRK refractive surgeries significantly altered corneal biomechanical properties but the changes were more prominent after SMILE.

PP-738

### The influence of different corneal diameters on Pentacam system combined with Corvis ST

Q Lin.

**Objective:** To explore the effect of different corneal diameter on Belin/Ambrósio enhanced ectasia display (BAD) and Corvis ST.

**Methods:** This study recruited 132 eyes (72 males and 60 females)

, who had completed preoperative examination before corneal refractive surgery at our center from Jan 2021 to June 2021. Age was  $(25.41 \pm 6.12)$  years old and No patients had keratoconus. All the patients recruited were divided into two groups according to the corneal diameter measured by the Pentacam system (WTW). Group A included 66 eyes with corneal diameter  $\leq 11.5$  mm; group B also included 66 eyes whose corneal diameter is  $\geq 11.6$  mm. Central corneal thickness (CCT), the deviation of front elevation difference map (Df), deviation of back elevation difference map (Db), deviation of average pachymetric progression index (Dp), deviation of minimum thickness (Dt), deviation of Ambrósio's relational thickness maximum (Da) and overall deviation value (Do) of BAD parameters were measured by Pentacam. The Corvis ST parameters included Integr. Radius, corneal thickness thinnest/pachymetric progression (ARTH), the ratio of deformation amplitude (DA ratio), resultant pressure divided by deflection amplitude at the first applanation (SPA1), the Corvis Biomechanical Index (CBI) and tomographic and biomechanical index (TBI). The preoperative BAD parameters and Corvis ST parameters between these two groups were analyzed with Independent sample T test.

**Results:** In groups A and B, CCT was  $533.38 \pm 31.16$  and  $552.66 \pm 31.55$ ; Df was  $1.02 \pm 0.99$  and  $0.92 \pm 1.46$ ; Db was  $1.74 \pm 1.97$  and  $0.61 \pm 1.15$ ; Dp was  $1.67 \pm 0.75$  and  $1.27 \pm 1.34$ ; Dt was  $-0.37 \pm 0.86$  and  $0.18 \pm 0.89$ ; Da was  $0.63 \pm 0.62$  and  $0.78 \pm 0.76$ ; Do was  $1.70 \pm 0.51$  and  $1.32 \pm 0.85$ . DA Ratio was  $4.14 \pm 0.40$  and  $4.14 \pm 0.46$ ; ARTH was  $437.04 \pm 76.60$  and  $470.46 \pm 103.36$ ; SPA1 was  $99.80 \pm 17.27$  and  $96.31 \pm 17.36$ ; CBI was  $0.36 \pm 0.18$  and  $0.30 \pm 0.21$ ; TBI was  $0.42 \pm 0.21$  and  $0.44 \pm 0.28$ , respectively. The BAD parameters of Dt, Db, Dp, CCT and Do were all significantly different between these two groups ( $P < 0.05$ ). The Corvis parameters of ARTH were also significantly different between these two groups ( $P < 0.05$ ).

**Conclusion:** Different corneal diameter had a crucial influence on BAD and Corvis ST.



PP-741

**Small Incision Lenticule Extraction versus Laser In Situ Keratomileusis for astigmatism correction:A Meta-analysis**J Song, H Cao, G Wu, Y Wang.

**Objective:** To compare small incision lenticule extraction (SMILE) and laser assisted stromal in situ keratomileusis (LASIK) in astigmatism correction by the meta-analysis.

**Methods:** We reviewed published outcomes after LASIK and SMILE for astigmatism correction. The database included PubMed, EMBASE, Cochrane, and Web of science, retrieved until Dec.27th,2021. Astigmatism correction outcomes were evaluated using vector analysis. The changes of visual acuity, refraction, and high-order aberrations were compared between different surgeries.

**Results:** There were 16 publications including 1891 eyes. For all eyes, no significant difference in CI (MD = -0.02, 95% CI: -0.04 to 0.00, P=0.06), IOS (MD=0.00, 95% CI: -0.03 to 0.03, P = 0.96), AE (MD=0.08, 95% CI: -0.57 to 0.72 P = 0.82), and DV (MD=0.06, 95% CI: -0.01 to 0.14, P =0.08) was shown between SMILE and LASIK. There was no significant difference between different procedures in visual acuity and refraction (UDVA: MD=0.00, 95% CI: -0.01 to 0.02, P=0.58; CDVA: MD=0.00, 95% CI: -0.01 to 0.01, P =0.68 SE MD=-0.05, 95% CI: -0.09 to 0.00, P =0.05), or high-order aberration (MD=-0.01, 95% CI: -0.07 to 0.04, P = 0.67), other than spherical aberration (MD -0.12, 95% CI: -0.23 to -0.01, P =0.04).

**Conclusion:** For the treatment of astigmatism, both SMILE and LASIK are effective and predictable and have a generally equivalent outcome.

PP-743

**The use of two 90 degree arc intracorneal ring segments in management of crab claw topographic pattern**H El-Nashar.

**Objective:** To assess the visual and refractive outcome of using two 90 degree arc intracorneal ring segments (ICRS) in cases with crab claw topographic pattern which indicate the patients have corneal ectasia which may be pellucid marginal degeneration (PMD) or pellucid like keratoconus (PLK)

**Methods:** A case series of 7 eyes ( 4 patients) underwent two 90 degree ICRS in each eye using femtolasers to create intrastromal tunnels for management of crab claw topographic pattern with at least 6 months follow up .full examination was performed pre and post operative including uncorrected visual acuity (UCVA),best corrected visual acuity ( BCVA) , manifest refraction of patient and keratometric readings

**Results:** The follow up period range from 6 months to 2 years . Only one intraoperative complication occurred in which small perforation into anterior chamber occurred and after 2 weeks reimplantation of 90 degree ICRS in new tunnel which was little superficial and central than the old perforated one . All eyes showed improvement in UCVA, BCVA, manifest refraction and k-reading .the UCVA preoperative range from (0.05-0.2)and post operative range from (0.8-1.00)and BCVA preoperative range from (0.1-0.5) and postoperative (0.9-1.0) and manifest sphere preoperative range from (+0.5 to +3.50) with no significant change in post operative and manifest cylinder preoperative range from (-10.0 to - 6.0) and post operative range from (-3.0 to - 0.75) .

**Conclusion:** The implantation of two 90 degree arc ICRS using femtolasers in crab claw pattern either diagnosed as PMD or PLK in early or advanced cases give good refractive and visual results

PP-744

**Impact of teleconsultation on visual and refractive outcomes in patients undergoing laser refractive surgery during Covid-19**V Singh, P Vaddavalli .

**Objective:** To assess the role of remote teleconsultation follow-up care following a successful and uneventful laser vision correction

**Methods:** The study is a retrospective, comparative analysis of patients undergoing laser vision correction at L V Prasad Eye Institute, India. The patients were divided into two groups. The first group included patients operated on before the Covid-19 pandemic and were followed up with physical consultations during their follow-up visit (Group 1). The second group comprised patients operated on during the pandemic and had at least one remote teleconsultation during their post-operative follow up (Group 2).

**Results:** A total of 1088 eyes of 564 patients and 717 eyes of 372 patients were included in Group 1 and 2, respectively. The mean number of visits for the patients from Group 2 during the Covid period (2.56 +/- 0.74 days) was significantly lesser ( $p < 0.0001$ ) than Group 1 in the pre-Covid period (3.53 +/- 1.07 days). Close to 90% of eyes achieved a UDVA of 20/20 in both groups ( $p = 0.925$ ). 96.50% of the eyes in Group 1 and 98.18% of eyes in Group 2 achieved UCVA 20/25 or better ( $p = 0.049$ ). Eight eyes (0.73%) in Group 1 and one eye (0.14%) in Group 2 reported a loss of 2 or more lines. However, the results were not statistically significant ( $P = 0.156$ ). None of the groups had any patients who had a sight-threatening complication.

**Conclusion:** Remote teleconsultation following refractive surgery is safe and can be effectively integrated into routine refractive practice to reduce travel to the hospital for a physical consult

PP-745

## Reasons for Long-Term Loss of Follow-up in Myopia Patients after Posterior Chamber Intraocular Lens Implantation Surgery in China

Y Chen<sup>1</sup>, J Zhou<sup>1</sup>, Q Zhou<sup>2</sup>.

<sup>1</sup>Refractive surgery department, Chengdu Aier EYE Hospital, Chengdu, <sup>2</sup>Refractive surgery department, ChongQing Ophthalmic optometry Hospital, ChongQing, People's Republic of China

**Objective:** To investigate the reasons for long-term loss of follow-up in myopia patients after implantable collamer lens (ICL) surgery in China. Then to further understand the long-term safety after this operation.

**Methods:** A multicenter cross-sectional study. Patients from 3 sites (Chongqing, Wuhan and Changsha Aier Eye Hospitals) with complete 5-year or more follow up were selected which underwent ICL surgery from December 2009 to December 2014. By dialing the telephone number to contact the patient to back to the hospital for reexamination, ask the patient's visual symptoms, and understand the patient's willingness for follow-up, and collect complications after surgery.

**Results:** A total of 1156 cases (2292 eyes) were operated on in the three hospitals five years ago, of which 387 (33.5%) were invalid phone numbers, 287 (24.8%) were unable to connect, and 482 (41.7%) were able to connected to. Among all patients, 43 (3.7%) insisted on regular follow up; 116(23.8%) said they had not know about the regular follow-up; 98 patients (20%) felt good eyesight and were unwilling to follow up, 47(9.7%) said they were too busy to come, 14 patients in remote places were inconvenient, and 6 were worried about the high cost. The follow-up rate of the two hospitals with special preoperative instruction and education for patients was higher than the other. About 32 eyes (1.4%) appeared complications.

**Conclusion:** Most patients felt good visual quality was the main reason for long-term loss of follow-up. The surgeon's education on regular follow-up was helpful to improve the return visit rate. Since there were few complications, it could be inferred that the ICL demonstrated high safety.

PP-748

**Early assessment of circumferential anterior segment structures following Implantable Collamer Lens V4c implantation via SS-OCT**F Liu, F xia, L niu, J zhao, X wang, X zhou.

**Objective:** To explore early changes in circumferential anterior segment structures following the implantable Collamer lens (ICL) V4c implantation via swept-source optical coherence tomography (SS-OCT)

**Methods:** In 103 eyes of 56 myopic patients undergoing ICL V4c surgery, anterior segment were measured via SS-OCT (CASIA2, Tomey) to compute local anterior chamber angle (ACA) parameters on nasal-temporal ( $0^{\circ}$  - $180^{\circ}$  ), superior-inferior ( $90^{\circ}$  - $260^{\circ}$  ), superior nasal-inferior temporal ( $80^{\circ}$  - $270^{\circ}$  ) meridian, including angle opening distance (AOD), trabecular iris space area500 (TISA500), trabecular iris angle500 (TIA500), and circumferential ACA parameters, including AOD volume500 (AODV500), trabecular-iris circumference volume500 (TICV500), the index and area of iris-trabecular contact (ITC). ACA parameters were compared preoperatively and at 1 week, 1 month, 3 months postoperatively and compared among quadrants. Mixed-effects model was used to predict the post-ITC parameters.

**Results:** The mean AOD500, TISA500, TIA500, AODV500 and TICV500 were decreased by 65.4-71%, 64.1-69.3%, 53.8-61.5%, 69.9% and 69.2% respectively at 1 week postoperatively , the index and area of ITC rose from  $1.436 \pm 4.427\%$  and  $0.070 \pm 0.254 \text{ mm}^2$  to  $12.343 \pm 13.216\%$  and  $0.903 \pm 1.304 \text{ mm}^2$  (all  $p < 0.05$ ). No further decreases in ACA parameters beyond 1 week postoperatively (all  $p > 0.05$ ). Significant differences were observed among quadrants, with the narrowest in superior-nasal quadrant, followed by superior quadrant. 3 months vault was identified as a predictor of ITC index and area at 3 months postoperatively.

**Conclusion:** Anterior segment structures were significantly shallow at 1 week but no further decreases thereafter. In light of anatomical variability, we recommend circumferential meridian scan to assess angle status, with special attention to the superior-nasal and superior quadrants.

PP-749

**Hemorrhagic retinal arterial macroaneurysm combined with BRVO treated with intravitreal conbercept injection:  
A case report**P *xie*, W Feng.

**Objective:** Retinal arterial macroaneurysm (RAM) is a common condition in females aged 60– 80, with a global prevalence of 1/4500 and a domestic prevalence of 1/9000 in China. Most patients with RAM are asymptomatic and do not require special treatment. However, some patients may develop retinal exudates, macular edema, and other complications that can cause severe visual loss. Branch retinal artery occlusion (BRAO) is a rare complication of RAM. To the best of our knowledge, there has been no previous report of treatment of such a case. Herein, we report a case of RAM combined with BRAO treated with intravitreal conbercept injection.

**Methods:** A 75-year-old female presented to our outpatient clinic with sudden onset of blurred vision in her left eye lasting for 4 days. Her best corrected visual acuity (BCVA) was 20/30 in the right eye and counting fingers in the left eye. Fundoscopic examination revealed a large RAM in the inferior-temporal branch artery, with peripheral subretinal and preretinal hemorrhage involving the macular center. Spectral-domain optical coherence tomography (SD-OCT) revealed intraretinal and subretinal fluid in the macula of the left eye. After Fluorescence angiography and indocyanine green angiography, were diagnosed as RAM in the left eye, inferior-temporal BRAO. At follow-up 3 months after the second injection, the RAM had subsided with approximately complete absorption of the subretinal and preretinal hemorrhage.

**Results:** The RAM had subsided with approximately complete absorption of the subretinal and preretinal hemorrhage. Furthermore, BCVA of the left eye had improved to 20/200. SD-OCT showed partial retinal atrophy and the formation of an epiretinal membrane.

**Conclusion:** BRAO is a rare complication of RAM but can be effectively treated with intravitreal injection of conbercept.

PP-750

**Post-operative visual outcomes based on morphological staging of idiopathic epiretinal membranes on OCT**H Tayyab, S Momin<sup>1</sup>.<sup>1</sup>*Ophthalmology, the Aga Khan University Hospital, Karachi, Pakistan*

**Objective:** To evaluate the recently described optical coherence tomography (OCT) based classification of epiretinal membrane (ERM) and its usefulness in predicting the functional outcome.

**Methods:** A retrospective observational review of OCT scans of patients with the diagnosis of ERM was carried out from January 2016 to June 2021. All consecutive images diagnosed with any stage of idiopathic ERM and fulfilled the eligibility criteria were included in the analysis. ERM was identified on OCT scans as a thin hyperreflective layer over the inner layers of retina. OCT scans of patients with ERM who underwent vitrectomy, were independently staged as per the new classification by two independent retinal surgeons (non authors) to form a consensus on stage. Best Corrected visual acuity (BCVA) in LogMAR scale and central subfield thickness (CST) on pre- and post-operative spectral domain OCT scans were the variables noted for all patients at the time of diagnosis and at 6 and 12 months follow up visit after undergoing intervention. Partial correlation coefficient was computed between BCVA (LogMAR) and CST by ERM stage adjusting by baseline measures. Non-parametric Friedman repeated measure ANOVA was applied to assess change in variables over time. A p value of 0.05 was considered as significant.

**Results:** Clinical charts of 74 patients with idiopathic ERM were assessed. Clinically significant improvement in BCVA overtime was observed with significant difference in median visual acuity of patients with Stage II-IV with P-Values on Friedman Chi-square of <0.001 that remained consistent on post hoc Dunn's test. The median CST of all patients with Stage II-IV that showed similar consistent improvement with P-value on Friedman Chi-square (p-value <0.001) from baseline to 12th month. Our results showed not only gain in visual acuity but also shift from baseline to anatomical normalization of CST in stage II. We found a decrease in CST with difference of 166µm and 151µm in stage III and Stage IV respectively. Our results remained consistent with the hypothesis of improved visual outcomes with all stages of ERM with adjusted moderate linear correlation between visual acuity and CST in stage II-IV ( $r > 0.3$ ).

**Conclusion:** Our results showed equally significant visual outcomes of patients with ERM staged II-IV and therefore can be counselled for improved visual acuity after surgical removal of ERM with improvement up to 5 lines on Snellen's chart from the baseline.

## PP-751

**The Effectiveness of Different Gas Tamponade in the Treatment of Idiopathic Macular Holes.**

Z Rozanova, N *Umanets*.

**Objective:** Currently, it is actively introduced into the practice the foveasparing methodic of surgical treatment of idiopathic macular holes (MH), when during the intervention of the internal limiting membrane (ILM) is not removed directly from the edge of the macular hole.

**Methods:** 20 patients (5 male, 15 female, mean age 65,2 SD 5,9) years old) 22 eyes with MH stage IV were operated from May 2020 to December 2021. During vitrectomy the formation of a flap of ILM much more peripheral than the temporal edge of the MH was performed, so that ILM was not removed from the edge of the MH. Then the ILM flap was inverted to the MH with further gas tamponade. Patients were asked to follow “face down” position for at least 2 week (the methodic by Fajzrahmanov R.R., et al., 2019). 2 types of gas mixture were used: 20% SF<sub>6</sub> and 15% C<sub>3</sub>F<sub>8</sub>.

**Results:** 14 patients (16 eyes), the size of the MH ranged from 198 to 769 microns, mean – 443,5 (SD 165,3) μm, the duration of MH was from 1 month to 3 years, mean – 7,7 (SD 9.8) months, initial visual acuity from 0,02 to 0,25, mean – 0,13 (SD 0,09). A month after the vitrectomy on the 5 eyes (31,25%), the MH did not close. 2 eyes due to the rapid absorption of gas (less than 2 weeks), to these patients was performed an additional gas tamponade of 15% C<sub>3</sub>F<sub>8</sub> and “face down” position was prolonged for another 3 weeks. In 3 eyes, where patients did not follow “face down” position, reoperation was made with the removal of the ILM according to the classical methodology. As a result, MH closed in all 14 eyes. Visual acuity increased in all 14 eyes to 0,45 (SD 0,16).

It should be noted that the eyes with failed MH closure had no difference from all the group in the size of MH – 415,2 (SD 180,2) μm, nor in the MH duration. So we decided that MH closure failure is associated with short gas tamponade and began to use a longer tamponade of 15% C<sub>3</sub>F<sub>8</sub>. 6 patients were operated on with such a tamponade (2 male, 4 female, the mean age 68,3 (SD 4,14) years) 6 eyes, the size of MR 420 (SD 177,2) μm, MH duration 8,1 (SD 6,3) months, initial visual acuity – 0,18 (SD 0,12). In this group, the MR closed in all eyes after the first intervention, visual acuity increased to 0,5 (SD 0,15).

**Conclusion:** It is known that after vitrectomy with a classic removal of the ILM to an idiopathic MH, it closes in 3-5 days after surgery, however, with this modification of the fovea-saving methodology, a longer tamponade is needed to close the macular hole.



PP-752

**Evaluation of minimally invasive vitrectomy for the treatment of severe proliferative diabetic retinopathy with Advanced Ultravit**X Li<sup>1</sup>, Y Shao<sup>1</sup>, J Liu<sup>2</sup>.<sup>1</sup>Tianjin Medical University Eye Hospital, <sup>2</sup>Tianjin Medical University Eye Hospital, Tianjin, People's Republic of China

**Objective:** To describe a novel minimally invasive vitrectomy for complicated proliferative diabetic retinopathy by using Advanced ULTRAVIT<sup>®</sup> 27-gauge probe, and determine the short-term efficacy and safety.

**Methods:** A prospective observational descriptive case series study was designed. Patients who had proliferative diabetic retinopathy with traction retinal detachment were enrolled in the study. All of them underwent minimally invasive vitrectomy and proliferative membrane peeling with advanced ULTRAVIT<sup>®</sup> 27-gauge beveled probe was performed. The primary outcome measures included the number of ancillary instruments used, the rate of peeling membrane, and intraoperative complications. Secondary outcomes included postoperative visual acuity, intraocular pressure, and postoperative complications.

**Results:** 12 eyes were enrolled, and follow-up was 1 month. The average rate of peeling membrane was  $4.03 \pm 2.17$  times optic disc area per minute. There were four cases replaced probes with ancillary instruments (33.3%) and five cases formed iatrogenic retinal hole (41.7%) in surgery. The mean preoperative best corrected visual acuity was  $1.42 \pm 0.56$  logMAR. And the mean postoperative best corrected visual acuity at 1 week and 1 month was  $1.48 \pm 0.47$  logMAR ( $P=0.818$ ) and  $0.90 \pm 0.48$  logMAR ( $p=0.039$ ) respectively. The mean postoperative intraocular pressure at 1 week and 1 month was  $16.0 \pm 3.6$  mmHg and  $16.3 \pm 2.2$  mmHg respectively. One had high ocular pressure in the first week, which was normalized after a month. A case had postoperative vitreous hemorrhage (8.3%), and received vitreous lavage.

**Conclusion:** The Advanced ULTRAVIT<sup>®</sup> 27-gauge probe offers an efficient and safe treatment for patients with severe proliferative diabetic retinopathy. However, the number of cases and follow-up time are limited, so we will continue to observe these patients in clinic.

PP-754

**Long-term functional outcomes after epiretinal membrane surgery****B Bajén Espuña<sup>1</sup>, R Maroto Cejudo<sup>1</sup>, C Blanco Marchite<sup>1</sup>, S Copete Piqueras<sup>1</sup>.**<sup>1</sup>*Complejo Hospitalario Universitario de Albacete, Albacete, Spain*

**Objective:** To evaluate the preoperative predictive factors and functional development after epiretinal membrane (ERM) surgery in a long-term follow-up.

**Methods:** This retrospective study included consecutive case-series of patients diagnosed with ERM that underwent surgical procedures in Albacete University Hospital (Albacete, Spain). 23 or 25 G vitrectomy and ERM peeling was performed, complementing the surgical intervention with cataract surgery when considered by the surgeon. Only patients with idiopathic ERM were included. Those who did not complete at least one year of follow-up, or with secondary ERM, and any other retinopathies were excluded. Also, baseline OCTs were reviewed and the variables analysed were: central macular thickness and volume, outer nuclear layer thickness, the presence of cysts, inner retina wrinkling and hyperreflective dots as well as the aspect of the fovea, plexiform, external limiting membrane and ellipsoid zones.

**Results:** Forty-five eyes of forty-five patients were included, of which forty-four reached 1 year follow-up and thirty reached up to four years of tracking. The mean age was  $72,3 \pm 6,8$  years. Twenty-three phakic eyes were studied, of which 14 received combined surgery and 3 underwent delayed cataract surgery in the postoperative follow-up. The mean best-corrected visual acuity (BCVA) at baseline was 0,29, meanwhile the evolution observed 1, 6, 12, 24, 36 and 48 months postoperatively was  $0,05 \pm 0,18$ ,  $0,16 \pm 0,22$ ,  $0,17 \pm 0,32$ ,  $0,28 \pm 0,26$ ,  $0,34 \pm 0,27$ ,  $0,26 \pm 0,25$ , respectively. There was a significant difference in BCVA showed after the 6 month postoperative assessment. Age was inversely related to the final BCVA ( $p < 0,05$ ) and directly correlated to the initial BCVA ( $p < 0,05$ ). The external retinal pattern was also correlated with the BCVA ( $p < 0,05$ ) but no relationship was found with central macular thickness or volume, cysts, hyperreflective dots or neurosensorial detachment. Patients that received combined surgery showed improved vision ( $p < 0,05$ ) but after delayed cataract surgery the evolution was similar ( $p < 0,05$ ).

**Conclusion:** BCVA post ERM surgery improves progressively even after only one year and this advancement can be maintained for at least four years. Combined phacoemulsification-vitrectomy surgery was as effective as delayed cataract surgery, so the surgical intervention should be planned according to factors such as lens transparency. Baseline external retinal appearance is the most valuable tomographic variable.

PP-755

**Temperature monitoring in vitreoretinal surgery**

O Zadorozhnyy<sup>1</sup>, L Anatyчук<sup>2</sup>, R Kobylianskyi<sup>2</sup>, R Nazaretian<sup>1</sup>, A Korol<sup>1</sup>, V Naumenko<sup>1</sup>, N Pasychnikova<sup>1</sup>.

<sup>1</sup>State Institution "The Filatov Institute of Eye Diseases and Tissue Therapy of NAMS of Ukraine", Odesa, <sup>2</sup>Institute of Thermoelectricity, Chernivtsi, Ukraine

**Objective:** To study the dynamics of epibulbar and intraocular temperature during vitreoretinal surgery.

**Methods:** This pilot study included 20 patients with rhegmatogenous retinal detachment (10 eyes) and proliferative diabetic retinopathy (10 eyes). All patients underwent vitreoretinal surgery with irrigation solution with room temperature. In all cases, the ambient temperature, the patient's body temperature, the temperature of the irrigating solution, and temperature in the anterior vitreous, midvitreous and posterior vitreous were recorded during surgery. Pre and post-operative thermometry were also performed on the outer ocular surface.

**Results:** During vitreoretinal surgery with irrigation solution with room temperature ( $24.2 \pm 0.52^\circ \text{C}$ ) a decrease in temperature ( $p < 0,001$ ) versus the initial one was found in all segments of the vitreous cavity. In the absence of continuous irrigation, a rapid rewarming of the vitreous cavity was noted (an average of  $0.2^\circ \text{C}$  per minute). Our study also demonstrated the presence of local epibulbar hyperthermia of the operated eye in a number of patients (25 %) in the post-operative period.

**Conclusion:** Current study shows that vitreoretinal surgery is performed under conditions of uncontrolled local ocular hypothermia, which is characterized by a rapid uncontrolled rewarming of the vitreous cavity after cessation of cooling, and in the post-operative period local epibulbar hyperthermia of the operated eye is observed in a number of patients.

PP-756

**Comparable postoperative myopic shift in retinal vascular diseases and vitreomacular interface diseases after phacovitrectomy**T Lin.

**Objective:** To compare the predictive refractive error (PRE) of intraocular lens (IOL) power between retinal vascular and vitreomacular interface diseases after phacovitrectomy.

**Methods:** We retrospectively reviewed patients who underwent phacovitrectomy for various retinal diseases. Patients with retinal vascular diseases and vitreomacular interface diseases were included in group A and group B, respectively. Age- and gender- matched senile cataract patients with phacoemulsification were set as controls. The mean PRE and absolute value of refractive error (ARE) among different groups were compared. The associated risk factors with ARE were also analyzed in the univariate and multivariate analyses.

**Results:** In total, 106 patients (Group A), 108 patients (Group B) and 110 patients as controls were included. The PRE in Group A ( $-0.35 \pm 0.83D$ ) and Group B ( $-0.53 \pm 0.74D$ ) were more myopic compared to the control group ( $-0.11 \pm 0.58D$ ) ( $p < 0.05$ ). The ARE in Group A ( $0.70 \pm 0.57D$ ) and Group B ( $0.75 \pm 0.51D$ ) were significantly higher compared to the control group ( $0.47 \pm 0.35D$ ) ( $p < 0.05$ ). There were no significant differences in the PRE and ARE values between the two study groups ( $p = 0.267$  and  $0.861$ , respectively). There were no significant differences of the PRE and ARE in the eyes with silicone oil tamponade ( $-0.63 \pm 0.75D$ ,  $0.81 \pm 0.54D$ ) and gas tamponade ( $-0.42 \pm 0.83D$ ,  $0.74 \pm 0.56D$ ) ( $p = 0.693$  and  $0.988$ , respectively). In the multivariate model, preoperative LogMAR visual acuity ( $\beta = 0.162$ , 95%CI=0.113-0.211,  $p < 0.001$ ), mean corneal curvature ( $\beta = 0.105$ , 95% CI=0.074-0.135,  $p < 0.001$ ) and age ( $\beta = 0.012$ , 95% CI=0.005-0.019,  $p = 0.001$ ) were all positively correlated with the ARE.

**Conclusion:** Postoperative myopic shift after phacovitrectomy may be comparable in retinal vascular diseases and vitreomacular interface diseases, no matter the gas or silicone oil tamponade. Older age, steeper corneal curvature, and worse preoperative visual acuity could produce more prediction errors.

PP-757

**Applications of artificial intelligence in the analysis fluid markers involved in retinal occlusive diseases: A systematic review**

D Pur<sup>1</sup>, S Krance<sup>1</sup>, A Pucchio<sup>2</sup>, A Bassi, R Miranda<sup>3</sup>, T Felfel<sup>4</sup>.

<sup>1</sup>Schulich School of Medicine and Dentistry, Western University, London, <sup>2</sup>School of Medicine, Queen's University, Kingston, <sup>3</sup>Toronto Health Economics and Technology Assessment Collaborative, <sup>4</sup>Department of Ophthalmology and Visual Sciences, University of Toronto, Toronto, Canada

**Objective:** To review the literature on applications of artificial intelligence (AI) and bioinformatics-based analyses using biofluids as biomarkers in retinal vein occlusion (RVO) etiology, diagnosis, and management, with a focus on evaluating novel clinical implementations of these technologies.

**Methods:** We systematically searched MEDLINE, EMBASE, Cochrane Central Register of Controlled Trials, Cochrane Database of Systematic Reviews, and Web of Science for articles reporting on AI or bioinformatic applications in RVO involving biofluid biomarkers from inception up to August 2021.

**Results:** Amongst 10,264 studies screened, 14 eligible articles, including 7 prospective (50%), 3 retrospective (21%), and 4 cross-sectional (24%) studies were identified. A total of 578 RVO patients and 201 controls were included. Forty-three percent of studies reported on branch RVO (BRVO) with macular edema (ME), and 47% on central RVO (CRVO). The number of biofluids reported varied between proteomic studies from 94 in RVO including CRVO and BRVO (Clusterin, Complement C3, Ig lambda-like polypeptide 5, Opticin and Vitronectin, etc.) to 56 proteins, mainly implicated in angiogenesis, oxidative stress and collagen synthesis (fibroblast growth factor-4, alpha crystallin A chain, etc.) in BRVO. Overall, several studies implicated vitreous levels of interleukin-6 (IL-6), vascular endothelial growth factor (VEGF), and aqueous levels of intercellular adhesion molecule-1, IL-6, IL-8, monocyte chemo-attractant protein-1 as important biomarkers for pathogenesis and predictive of intravitreal injection treatment outcomes in BRVO with ME. In CRVO, baseline renal parameters such as blood urea and serum creatine were found to predict visual outcome after treatment for ME. A metabolomics and Kyoto Encyclopedia of Genes and Genomes enrichment analysis study identified the metabolic signature of CRVO to be related to lower aqueous concentration of carbohydrates and amino acids, but a relatively higher concentration of carnitine-associated energetic substances compared to the control group.

**Conclusion:** Overall, several studies to date have combined proteomics and metabolomics with AI analyses of biofluids in RVO for clinical decision making. Several biofluids such as IL-6 and VEGF can be used to predict visual acuity outcomes after intravitreal injections or vitrectomy, respectively. Applications of AI and bioinformatics with biofluids may advance the future of precision medicine and help elucidate the pathophysiology of RVO.

PP-759

**YAG LASER VITREOLYSIS OR OBSERVATION FOR SYMPTOMATIC WEISS RING FLOATERS**T Lin.

**Objective:** To compare the significant and complete resolution of symptoms of Weiss ring floaters between YAG laser vitreolysis and observation during long-term follow-up.

**Methods:** We retrospectively reviewed patients with symptomatic Weiss ring floaters. Patients undergoing YAG laser vitreolysis were included in group A, and the patients who refused any treatment were set as controls. The significant or complete improvement of floater symptoms in two groups was compared.

**Results:** In total, 230 patients were included in group A and 179 patients in group B. The mean age of all patients was  $60.54 \pm 8.91$  years old, and the mean duration of follow-up was  $22.49 \pm 6.22$  months. More patients were found to have significant and complete improvement in their symptoms in group A than in group B (50.43% vs. 32.96%,  $P < 0.001$ ). Age (OR=1.036, 95% CI=1.004-1.069,  $P = 0.029$ ) and the number of floaters (OR=0.522, 95% CI=0.292-0.934,  $P = 0.028$ ) were significantly correlated with the success of YAG laser vitreolysis in the multiple binary logistic regression analysis.

**Conclusion:** YAG laser vitreolysis is an effective and safe therapy, even though approximately one-third of patients with Weiss ring floaters may experience significant or complete spontaneous remission during long-term observation. Older age and fewer floaters have the tendency to obtain better efficacy.

**PP-761****Aerosol monitoring during pars plana vitrectomy and the role of microscope drapes**

M Butt<sup>1</sup>, M Dogramaci<sup>1</sup>, N Akter<sup>1</sup>, S Erdur<sup>2</sup>, F Senturk<sup>2</sup>, C Aras<sup>2</sup>.

<sup>1</sup>The Princess Alexandra Hospital, Harlow, United Kingdom, <sup>2</sup>Medipol University Hospital, Istanbul, Türkiye

**Objective:** A pilot study was performed to measure the level of aerosol particles PM 2.5 generated during pars plana vitrectomy and to further establish the role of secondary adhesive microscope drapes as an extra protection measure against aerosol particles.

**Methods:** A purpose-built particle detector equipped with an aerosol sensor was used to count the number of aerosol particles PM 2.5 trapped within a closed circuit under a secondary surgical drape, typically attached to the lower edge of the microscope and tenting over the surgical field. The measurements were taken during a case of pars plana vitrectomy for a dislocated intraocular lens implantation and iris fixated artisan lens without phacoemulsification.

**Results:** The mean aerosol particles recorded throughout the procedure within the closed system under the secondary drape was 506.37 Particles/0.01L3 compared to 491.47 Particles/0.01L3 recorded in the open space within the theatre but outside of the secondary drape. The mean aerosol particles recorded in the open space in the theatre but outside of the secondary drape during the initial half of the procedure was 490.12 Particles/0.01L3 compared to 492.83Particles/0.01L3 recorded during the second half of the procedure. It was found that all of the measured differences were statistically significant ( $p < 0.05$ ).

**Conclusion:** The particle sensor can be used to monitor aerosol particles generated during ophthalmic procedures. A clinically minor but statistically significant increase in aerosol particles is detected in close vicinity to pars plana vitrectomy procedure, moreover, the increase in aerosol particles is mostly within the closed environment under the secondary drape and during the second half of the procedure.

PP-762

## Surgical Techniques of Rhegmatogenous Retinal Detachment Secondary to Posterior Capsule Rupture during Cataract Surgery

X Meng, H Han<sup>1</sup>, Y Liu<sup>1</sup>, J Yu<sup>1</sup>, W Zhang<sup>2</sup>, B Huang<sup>3</sup>, M Du<sup>4</sup>, X Wang<sup>4</sup>, H Yan<sup>1</sup>.

<sup>1</sup>Tianjin Medical University General Hospital, <sup>2</sup>Tianjin Eye Hospital, Tianjin, People's Republic of China,

<sup>3</sup>Ophthalmology, University of Mississippi Medical Center, Jackson, United States, <sup>4</sup>Tianjin Medical University, Tianjin, People's Republic of China

**Objective:** The onset of rhegmatogenous retinal detachment (RRD) secondary to posterior capsule rupture (PCR) during phacoemulsification combined with intraocular lens implantation is insidious. In this study, we aimed to describe the characteristics of this kind of RRD, and to discuss the surgical techniques and efficacy of 23G pars plana vitrectomy (PPV) treatment for it.

**Methods:** Clinical data of 19 eyes with RRD after received a cataract surgery with PCR who underwent 23G PPV in Tianjin Medical University General Hospital from 2012 to 2017 were analyzed. The mean follow-up was 6.2 months ranged from 3 to 18 months.

**Results:** All the retinal holes are located in peripheral retina, and in the same region with the position of PCR. The retinal holes are all <1/2PD. Retinal reattachment was achieved in 17 eyes (89.47%) after the primary PPV, and the reattachment rate was 100.00% after the second procedure. Transient rise of IOP happened in 5 eyes (26.32%) after surgery.

**Conclusion:** Post-cataract surgery RRD is associated with PCR. Retinal holes are usually small and located in the peripheral retina. Key to a successful surgery is to find the retinal holes, release the PVR between the retinal holes and the ruptured posterior capsule, and completely excise the vitreous around the retinal holes. Patients can be treated with 23G PPV safely and effectively.



**PP-764****Treatment of recurrent diabetic macular edema by ILM peeling after multiple injections of anti-VEGF**H Yan.

**Objective:** To evaluate the efficacy and safety of the treatment of recurrent DME by ILM peeling after multiple injections of anti-VEGF for one year, and to analyze the relative factors.

**Methods:** The involved eyes have received multiple injections of anti-VEGF for recurrent DME for one year. All eyes were divided into two groups which included ILM peeling group and non-ILM peeling group. In ILM peeling group, ILM was peeled during vitrectomy without further injections of anti-VEGF, and eyes received further injections of anti-VEGF again in non-ILM peeling group when recurred. Visual acuity and central retinal thickness were compared between two groups.

**Results:** The postoperative visual acuity increased and the central retinal thickness decreased in all eyes in ILM peeling group. All eyes in ILM peeling group did not receive further injections of anti-VEGF. The postoperative visual acuity increased and the central retinal thickness decreased in all eyes in non-ILM peeling group. All eyes in non-ILM peeling group received further two or three injections of anti-VEGF. The main postoperative complications included nuclear sclerosis in ILM peeling group and temporary IOP elevation in 2 eyes in non-ILM peeling group.

**Conclusion:** There is no recurrent DME after ILM peeling, and the visual acuity increased significantly. There is no severe postoperative complications in eyes with ILM peeling. Therefore, the treatment of recurrent DME by ILM peeling is a safe and effective method in patients with multiple injections of anti-VEGF for one year.

PP-766

**In Vitro Comparison of Various High-Speed Vitrectomy Machines Using Dual Blade Cutters**H Tayyab, S *jamil*<sup>1</sup>, S *hashmi*<sup>2</sup>.<sup>1</sup>*ophthalmology*, <sup>2</sup>*surgery*, The Aga Khan University Hospital, karachi, Pakistan

**Objective:** The objective of this study is to compare various dual blade vitrectomy cutters for their efficiency in an in vitro setting.

**Methods:** Methods In this in vitro experimental study, we compared various vitrectomy systems including EVA (Dutch Ophthalmic Research Center, Zuidland, The Netherlands), REVOLUTION (Optikon 2000, Inc., Rome, Italy), and OS4 (Oertli Instrumente AG, Berneck, Switzerland) in terms of efficiency in vitreous cutting and aspiration for various vitreous substitutes. These substitutes included water, chicken egg albumin, and goat vitreous. We only used 23-gauge dual blade cutters across all platforms to maintain uniformity. The cutting and aspiration efficiency was measured across various cut and vacuum settings of vitrectomy machines and measured as mass aspirated in a given time. Data analysis included comparing the amount of mass aspirated by these machines at preset cut and vacuum settings.

**Results:** Scatter plots showed a comparable mass of water aspirated by the EVA and REVOLUTION at 1000 to 5000 cuts per minute at a constant vacuum of 500 mm Hg whereas OS4 aspirated lesser mass at similar settings. Same trends were noted for goat vitreous for EVA and REVOLUTION but aspirated mass of albumin fluctuated widely across various platforms. At peak machine settings, REVOLUTION showed superiority across all three vitreous models due to its higher peak settings. The area under curve (AUC) analysis showed no significant differences among machines for water and goat vitreous at comparable settings but results were fluctuating for egg albumin.

**Conclusion:** Employing higher cut rates for dual blade cutters results in better efficiency of vitrectomy machines.

PP-767

**Vitreoretinal Amyloidosis:****Clinical Features, OCTA Appearances, Gene Mutations, and Treatment Outcomes of PPV Surgery**N Zhou, W Wei.

**Objective:** To report the clinical characteristics and surgical outcomes of vitrectomy encountered in eyes with vitreous amyloidosis. The novel term named vitreoretinal amyloidosis, systemic evaluation and visual outcome after vitrectomy are discussed. Transthyretin gene (TTR) mutations in Asian patients with familial amyloidosis are described.

**Methods: Design:** Retrospective, observational case series.

**Participants and Methods:** Nineteen eyes of 10 Asian patients with a diagnosis of vitreoretinal amyloidosis from January, 2008, to September, 2021. Detailed history, genetic analysis, systemic and ocular examination of 19 eyes of 10 patients were carried out. Vitreous biopsy, followed by 23- to 25-gauge vitrectomy was performed in all patients. Patients were followed up on days 1, 7, and 30 and then every 3 months. The main outcome measures were best-corrected visual acuity (BCVA), intraocular pressure, SD/SS-OCT/OCTA insights, pathology, TTR mutations, treatment and disease course on follow-up outcomes were investigated.

**Results:** Mean age at presentation was 51 years, with a 1:1 male-to-female distribution. Family history was positive in 4 patients. Eighteen eyes had pseudopodia lentis, whereas all 19 eyes had glass wool-like vitreous. Waxy or cotton-wool vitreous with firm vitreous adhesions beyond major arcades and along retinal vessels was noted during surgery in all eyes. Congo red staining and polarized microscopy demonstrated vitreous amyloidosis. Most of preoperative BCVA was < 20/200, whereas the postoperative BCVA improved to 20/100 to 20/25.

We identified the OCTA features of vertical hyperreflective lesions that appeared as punctate with moderate or high reflectivity affecting all layers of the neuroretina in 18 eyes of 9 patients (18 eyes of 19 eyes [94.7%]), and the subtle needle-shaped patterns in 17 of 19 eyes (89.5%). Gene sequencing revealed the heterozygous Val30 Met TTR mutation in 2 patients of 1 pedigree, a heterozygous mutation G, p.R54G TTR (late-onset) in another 2 patients of 1 pedigree, confirming the diagnosis of familial amyloidosis. No patients subsequently were found to have systemic amyloidosis during the follow-up.

**Conclusion:** We firstly described and named the novel terms of "vitreoretinal amyloidosis" mainly based on OCT/OCTA features corresponding to the tissue structures. In addition, the heterozygous mutations of TTR in four patients of familial amyloidosis with vitreoretinal amyloidosis from Chinese are reported.

PP-768

## The relationship between renal function and prognosis of Chinese PDR patients undergoing the first vitrectomy

C Lei<sup>1</sup>, M Zhang<sup>1</sup>.<sup>1</sup>Ophthalmology, West China Hospital, Chengdu, People's Republic of China

**Objective:** To investigate whether the renal function has an association to the prognosis of visual function in proliferative diabetic retinopathy (PDR) patients undergoing pars plana vitrectomy (PPV)

**Methods:** The present study was a prospective cohort study of PDR patients with definite indications for surgery and meeting the criteria of admission who were hospitalized in the Ophthalmology department of West China Hospital of Sichuan University from May 2020 to December 2021. Examination data including BCVA was collected at baseline and postoperative follow-ups. The follow-up time included preoperative, intraoperative, postoperative 1 day, postoperative 1 week, postoperative 5 weeks, postoperative 13 weeks, postoperative 6 months, then followed up as needed. The primary outcome was best-corrected visual acuity (BCVA)(logMAR). Estimated glomerular filtration rate (eGFR) was used as a stratification factor of renal function, which was divided into two groups (eGFR $\geq$ 60 mL/min  $\times$  1.73 m<sup>2</sup> and eGFR $<$ 60 mL/min  $\times$  1.73 m<sup>2</sup>). A generalized additive mixed model (GAMM) was used to analyze the relationship between the eGFR $\geq$ 60 group and eGFR $<$ 60 group and BCVA.

**Results:** A total of 106 PDR patients (106 eyes) were included in this study, including 65 males and 41 females, with an average age of  $56.38 \pm 9.63$  years. The mean eGFR of all PDR patients was  $62.79 \pm 30.18$  mL/min  $\times$  1.73 m<sup>2</sup>. During the follow-up period, the postoperative BCVA (logMAR) of PDR patients decreased first and then increased with time, with a trough value appearing at about 150 days. The postoperative BCVA (logMAR) of PDR patients with different renal functions also decreased first and then increased with time. After adjusting for confounding factors, the changing trends of postoperative BCVA (logMAR) over time in PDR patients with different renal functions were relatively low. The increased rate of postoperative BCVA (logMAR) in PDR patients with eGFR $\geq$ 60 mL/min  $\times$  1.73 m<sup>2</sup> was 0.0001 logMAR/day. Compared with the eGFR $\geq$ 60 group, the increased rate of postoperative BCVA (logMAR) in PDR patients with eGFR $<$ 60 mL/min  $\times$  1.73 m<sup>2</sup> was 0.0004 logMAR/day lower. However, there was no statistical difference in the change rate of postoperative BCVA (logMAR) over time between the two groups.

**Conclusion:** It has not been found that visual acuity is related to renal function, indicating that renal function might not be used as a surgical contraindication for PDR patients or an indicator for predicting visual prognosis of PDR patients.

## PP-772

**Effect of Vitrectomy with or without encircling band on choroidal thickness & mean ocular perfusion pressure in retinal detachment**G Gujral.

**Objective:** To evaluate the effect of Vitrectomy v/s Vitrectomy with encircling band on subfoveal choroidal thickness (SCT) and mean ocular perfusion pressure (MOPP) in macula off rhegmatogenous retinal detachment (RRD).

**Methods:** Prospective interventional single centre study conducted at a tertiary eye hospital in North India. Twenty one patients of vitrectomy with encircling band (group 1) and nineteen patients of pars plana vitrectomy (PPV) (group 2) were studied for changes in SCT and MOPP over a period of time. All the patients underwent surgery with silicone oil tamponade. Enhanced Depth Spectral Domain Optical Coherence Tomography (EDI-OCT) was done to image the choroid and Goldmann applanation tonometer (GAT) was used to measure the intraocular pressure (IOP). Blood pressure (BP) was monitored on all visits. SCT and MOPP were measured at 1 week (T1), 1 month (T2) after vitrectomy with or without encircling band and 1 day (T3) and 3 months (T4) after silicone oil removal (SOR), and the non-operative eye was used as an internal control.

**Results:** The SCT increased temporarily at T1 in the operated eye in group 1 compared to group 2 ( $P < 0.001$ ). Subsequently, no statistically significant difference in SCT was noted between the two groups. There was a statistically significant difference noted in the mean IOP at T1 ( $P < 0.01$ ) with a higher mean IOP noted in group 1 {12.04 ( $\pm$  0.93) mm Hg} as compared to group 2 {11 ( $\pm$  1.34) mm Hg}. IOP was comparable between the two groups subsequently at T2 ( $P = 0.11$ ), T3 ( $P = 0.2$ ) and T4 ( $P = 0.12$ ). There was a statistically significant difference noted in the MOPP between the two groups at all points of time {T1 to T4 ( $P < 0.01$ )} with group 2 exhibiting higher MOPP than group 1. The final MOPP noted at T4 was 54.25 ( $\pm$  1.29) mm Hg and 59.05 ( $\pm$  1.39) mm Hg in group 1 and 2 respectively. Both the groups showed statistically significant improvement in BCVA post-operatively. There was a statistically significant difference in the distance VA and near VA between the two groups with group 2 showing better VA at T1 and T2 ( $P < 0.001$ ). However no statistically significant difference was noted in distance VA between the 2 groups at T3 ( $P = 0.25$ ) and T4 ( $P = 0.67$ ).

**Conclusion:** Obstruction of venous drainage induced by compression force of encircling band leads to increased SCT in the acute postoperative phase and overall decrease in MOPP. With the development of vitreous surgery techniques, the possible deleterious effect of encircling band on visual function might be alleviated

PP-774

**Ocular Syphilis Masquerading as Antiphospholipid Syndrome: A Case Report**

B Ramos Aguilar, P Kawakami Campos, M Fuentes Cataño, D Rodríguez Juárez, E Mundo Fernández.

**Objective:** To describe the clinical characteristics, diagnosis and management of a rare and aggressive case of ocular syphilis.

**Methods:** We present a bilateral occlusive retinal vasculitis, central retinal vein occlusion and panuveitis in an otherwise healthy 36-year-old woman. At initial examination she showed bilateral corneal subepithelial edema with anterior chamber cellularity (SUN grade 1+), iris rubeosis and 360 degree angle closure. Best corrected visual acuity went from counting fingers to 20/400 and 20/150 respectively. Under pharmacological dilatation, both eyes showed grade 1 vitreous haemorrhage and cellularity, optic disc neovascularization (NVD), perivascular sheathing and intraretinal haemorrhages in all quadrants. Topical treatment was prescribed for both eyes with prednisolone acetate 1%, brimonidine/dorzolamide/timolol and tropicamide/phenylephrine; oral acetazolamide and indometacine. Macular OCT showed right sub foveal fluid and fluorescein angiography corroborated bilateral peripheral occlusive vasculitis with NVD and left grade 3 vitreous haemorrhage. These findings urged us to start pan retinal photocoagulation immediately. Ahmed valve implant was scheduled for both eyes. Among preoperative tests, a COVID19 test came positive for which a two week quarantine was mandatory. After quarantine, she was treated with 14 day course of IV penicillin G, 3 pulses of intravenous methylprednisolone, Ahmed valve implant on both eyes and bilateral intravitreal Aflibercept.

**Results:** Both non-treponemal and treponemal tests as well as anti-cardiolipin and anti-beta 2 glycoprotein IgM were positive on initial workup, however follow up four months later showed negativity in all antiphospholipid markers discarding primary antiphospholipid syndrome and a probable syphilis related false positive initial result.

**Conclusion:** Syphilitic uveitis remains one of the biggest masquerade syndromes in ocular inflammation. When approaching a young woman with bilateral occlusive retinal vasculitis one must always rule out latent infections before steroid pulse therapy or immunosuppressive treatment under the impression of an autoimmune disease. To our knowledge this would be the first case of a syphilitic bilateral ischemic central retinal vein occlusion in an HIV negative individual.

PP-775

**Clinical manifestations and treatment of ocular toxoplasmosis: report of two cases**J Liu, L Niu.

**Objective:** Although *Toxoplasma gondii* infects nearly one third of the world population, the serum level in mainland China is low, about 6.26%. *Toxoplasma gondii* is also relatively rare. Although it is described in some journals as "diagnosed at a glance", like "headlights in fog", its clinical manifestations are diverse, and clinicians are prone to misdiagnosis and missed diagnosis. The detailed diagnosis and treatment of two cases of toxoplasmosis has positive clinical significance for the diagnosis and treatment of toxoplasmosis.

**Methods:** Based on the clinical manifestations, symptoms and signs of two cases of toxoplasmosis, the fundus examination (attached), FFA (attached), OCT (attached), intraocular fluid examination (attached), the changes of fundus during treatment (attached) and treatment methods were described in detail. The present diagnostic criteria of toxoplasmosis were reviewed in order to further understand toxoplasmosis.

**Results:** The correct and timely diagnosis and treatment of toxoplasmosis can help the recovery of visual acuity, and the later follow-up can make the disease recover as soon as possible and maintain good visual acuity.

**Conclusion:** Toxoplasmosis is not common clinically in mainland China, and is easily confused with other infectious uveitis and other diseases, resulting in misdiagnosis and missed diagnosis. To be familiar with the fundus manifestations and clinical symptoms and signs is the key to diagnosis and timely treatment. In the area with low incidence, it has important guiding significance for ophthalmologist clinical diagnosis and treatment.



## PP-776

**Application of artificial intelligence in analyzing biomarkers for diagnosis and management of uveal diseases: a systematic review**

A Bassi<sup>1</sup>, S Krance<sup>1</sup>, A Pucchio<sup>2</sup>, D Pur<sup>1</sup>, R Miranda<sup>3</sup>, T Felfel<sup>4</sup>.

<sup>1</sup>Schulich School of Medicine and Dentistry, London, <sup>2</sup>Queen's University Medical School, Kingston, <sup>3</sup>The Institute of Health Policy, Management and Evaluation, <sup>4</sup>Ophthalmology and Visual Sciences, University of Toronto, Toronto, Canada

**Objective:** By using AI methods, patterns in complex interactions can be uncovered to give high-yield clinical information in uveal diseases. This study aims to systematically identify the available literatures describing the utilization of AI and bioinformatics as a clinical tool in uveal disease diagnosis, profile, progression, differentiation and treatment outcome.

**Methods:** A comprehensive literature search was conducted in the following electronic databases, Medline, EMBASE, Web of Science, Cochrane Central Register of Controlled Trials, and Cochrane Database of Systematic Reviews, to find all available studies relating to AI or bioinformatics and uveal diseases. A risk of bias assessment was performed using the Joanna Briggs Institute Critical Appraisal tools and followed the Preferred Reporting Items for a Systemic Review and Meta-analysis (PRISMA) guidelines (protocol registration CRD42020196749).

**Results:** In total, 10,258 studies were screened, and 18 studies met inclusion criteria and moved into the data extraction phase. After analysis, uveal melanoma (44%) and uveitis (56%) were the two main uveal diseases of interest. Nine studies examined disease prognosis, 4 differentiated between diseases, 5 explored treatment outcomes, 4 characterized the disease profile, and 1 determined disease progression. Ten studies (56%) used complex machine learning methods while 13 studies (72%) used regression methods. The most common complex AI method used was principal component analysis (33%) whereas logistic regression (38%) was the most common regression tool. The articles showed a large amount of heterogeneity in the biomarkers examined, ranging from 1 to 4396 biomarkers in a single study. The only biomarker that showed overlap between the studies is lactate dehydrogenase (LDH), found in 50% of studies concerning uveal melanoma. However, almost all studies (94%) highlighted that the biomarkers of interest were significant.

**Conclusion:** This study highlights the value of using complex and simple AI tools as a clinical tool in uveal disease prognosis, differentiation, diagnosis, progression and treatment outcome. Particularly, complex AI methods can be used to weigh the merit of significant biomarkers, such as LDH, in order to create staging tools and predict treatment outcome. The limited overlap in the type of biomarkers used, indicates future research should be conducted to confirm the application of significant biomarkers in a clinical setting.

PP-777

**Widefield swept-source optical coherence tomography angiography assessment of choroidal changes in Vogt-Koyanagi-Harada disease**Y Qian, M Zhang.

**Objective:** To investigate choroidal changes in patients with Vogt-Koyanagi-Harada disease (VKH) using widefield swept-source optical coherence tomography angiography (SS-OCTA).

**Methods:** In this cross-sectional study, 133 eyes of 69 patients with VKH (52 eyes of 28 active VKH patients and 81 eyes of 41 inactive VKH patients) and 104 eyes of 52 age and sex matched healthy volunteers were imaged using a widefield SS-OCTA instrument. On 12 mm × 12 mm OCTA scans, mean choroidal thickness (MCT), choroidal vascularity index (CVI), choriocapillaris (CC) flow area, and mean retinal thickness (MRT) were separately calculated in the fovea (diameter of 1 mm) and in concentric rings with different diameters (1–3, 3–6, 6–9, and 9–12 mm).

**Results:** Eyes with active VKH showed significant increases in MCT, CVI, and MRT, and decreased CC flow area in all central and peripheral regions (0–1, 1–3, 3–6, 6–9, and 9–12 mm) than in the healthy eyes ( $p \leq 0.01$ ) and inactive VKH eyes ( $p < 0.05$ ). Inactive VKH eyes only showed marked decrease in CC flow area in all regions compared with controls ( $p < 0.05$ ). Flow voids were observed in 51 of 52 (98.1%) active VKH eyes and 50 of 81 (61.7%) inactive VKH eyes on 12 mm × 12 mm OCTA. The MCT of all regions was significantly correlated with age, disease duration, and disease activity, whereas CVI was associated with age and disease activity. The CC flow void was related to visual acuity in all regions ( $p < 0.05$ ).

**Conclusion:** Widefield SS-OCTA enables a more comprehensive evaluation of chorioretinal changes in patients with VKH disease. Structural and vascular abnormalities are observed in both the central and peripheral choroid and are closely correlated with disease activity.

PP-778

**Ocular Ischemic pathologies as presenting signs of Anti-Phospholipid Antibody Syndrome in a young Filipino male**J Lacanilao<sup>1</sup>, B *Mesina*<sup>1</sup>.<sup>1</sup>*Department of Ophthalmology and Visual Sciences, University of the Philippines - Philippine General Hospital, Manila, Philippines*

**Objective:** To present a rare case of Anti-Phospholipid Syndrome (APS) initially presenting as central retinal vein occlusion and ischemic optic neuropathy.

**Methods:** A 38 year-old hypertensive Filipino male presented with sudden blurring of vision of the right eye associated with an undiagnosed and untreated sudden blurring of vision on the left eye, that occurred when the patient was 15 years old. A comprehensive ophthalmologic and systemic examination was performed.

**Results:** He had poor visual acuity and pale optic discs on both eyes, and multiple flame-shaped hemorrhages and cotton wool spots following the orientation of the major vessel arcades on the right eye. Fluorescein angiography showed patchy delayed choroidal filling, focal areas of perivascular sheathing, tortuous vessels, and leakage of dye consistent with small to medium-sized vasculitis. Systemic examination revealed optic nerve atrophy and multiple chronic small vessel ischemic white matter changes on cranial MRI, and positive Lupus anticoagulant exemplified by prolonged Dilute Russell Venom Viper Time and aPTT Mixing Studies that persisted upon confirmatory testing after 12 weeks. The patient was diagnosed with APS and was started on anti-coagulant therapy.

**Conclusion:** Vasculitides such as APS are important risk factors for the development of ocular vaso-occlusive events, which at times can be the initial or only clinical manifestation in such patients. Vasculitic & thrombophilic work-up should be strongly considered in a young patient with unexplained ocular manifestations in order to promptly diagnose and reduce the risk of visual loss, systemic morbidity or even mortality.

PP-779

**Risk Factors for Ocular Toxoplasmosis among Uveitis Patients in Kinshasa, DR Congo**N N Nsiangani Lusambo<sup>1</sup>, D Kaimbo Wa Kaimbo<sup>1</sup>, P Akilimali<sup>2</sup>.<sup>1</sup>Ophthalmology Department, <sup>2</sup>School of Public Health, University of Kinshasa, Kinshasa, Congo, The Democratic Republic of the

**Objective:** This study aimed to identify the factors associated with ocular toxoplasmosis (OT) among uveitis patients seen in two ophthalmic clinics in Kinshasa, DR Congo

**Methods:** A cross-sectional analysis was conducted in two ophthalmic clinics in Kinshasa between March 2020 and July 2021. Patients with diagnostic of uveitis were enrolled in the study. Each patient underwent an interview and a complete ophthalmic examination. The serology testing was performed by an enzyme-linked fluorescent assay. A logistic regression model was used to identify the factors associated with OT. Variance-inflation factors were calculated to test for multicollinearity, with the highest found to be 2.04.

**Results:** Of 212 patients included, 53% of patients were male. The mean age was  $42 \pm 15.9$  years. The IgG antibodies were positive for 87% of patients and OT affected 45% of patients (IC95%: 38.7-52.1). Old Uveitis patients (>60 years old) (AOR 8.48; 95% CI 2.33-3.52;  $p < 0.001$ ), consumption of cat meat (AOR 2.48; 95% CI 1.14 -5.40;  $p=0.022$ ), eating undercooked meat (AOR 2.34; 95% CI 1.05 -5.21;  $p=0.037$ ) were significantly associated with ocular toxoplasmosis among uveitis patients.

**Conclusion:** Screening for OT should be routine in patients, especially the elderly. Consumption of undercooked meat, especially cat meat, should be discouraged to reduce the risk of OT. A more elaborate study to confirm or refute the results of the present study is highly recommended.

PP-780

## Beyond Conjunctivitis - Uncommon Ophthalmic Complications of SARS CoV 2 Infection by Diverse Mechanisms

A Ines<sup>1</sup>, A Sriram<sup>1</sup>, J Mbekeani<sup>2</sup>, P Kim<sup>3</sup>, L Paliaodimos<sup>4</sup>.

<sup>1</sup>Department of Ophthalmology and Visual Sciences, Montefiore Medical Center, <sup>2</sup>Department of Ophthalmology,

<sup>3</sup>Department of Surgery, <sup>4</sup>Department of Medicine, Jacobi Medical Center, Bronx, United States

**Objective:** Conjunctivitis is the most frequently reported ophthalmic manifestation of SARS-CoV-2. Recent reports of other findings have suggested associated systemic infection, inflammation, and coagulopathy.

**Methods:** Three unvaccinated patients, admitted with SARS-CoV-2 infection, had associated ophthalmic manifestations. We describe their diverse ophthalmic presentations.

### Results: Case 1

An 18-year-old male with recent SARS-CoV-2 infection presented with fever, conjunctival injection, blurry vision, peripheral edema, maculopapular rash, and fluid refractory shock. He was diagnosed with multisystem inflammatory syndrome in children (MIS-C). Ophthalmic exam revealed 20/25 vision, 2+ anterior chamber cells, and grade 2 optic disc edema OU. Infectious and inflammatory workup revealed elevated CRP, fibrinogen, D-dimer, and von Willebrand factor (vWF). MRI brain was normal and lumbar puncture, unsuccessful. Topical and systemic steroids were begun. Ocular inflammation resolved within a week and disc edema after 2 months.

Diagnosis: MIS-C related uveitis and disc edema.

### Case 2

A 64-year-old male admitted for SARS-CoV-2 ARDS, developed severe right eye pain and blurry vision. Ophthalmic exam revealed counting fingers vision, a mid-dilated, fixed pupil, 56mmHg ocular pressure, and corneal edema. A few days later he had similar symptoms in the left eye. Exam revealed 20/400 vision, a mid-dilated, fixed pupil, 40mmHg intraocular pressure, and corneal edema. Bedside B-scan revealed bilateral choroidal thickening. Sequential topical anti-hypertensives and IV acetazolamide therapy resulted in resolution of symptoms and normal IOP.

Diagnosis: Choroidal thickening with anterior rotation of lens-iris diaphragm and acute angle closure.

**Case 3**

A 50-year-old male with asthma and morbid obesity, admitted for SARS-CoV-2 ARDS, developed hypovolemic shock after massive internal bleeding following DVT anticoagulation therapy. Once extubated, he reported decreased vision. Ophthalmic exam revealed NLP visions, non-reactive pupils, and pale, swollen optic nerves with flame hemorrhages. Labs revealed elevated D-dimer, fibrinogen, vWF (factor, activity, and antigen), ESR, and CRP. MRI/MRA brain, stroke and further hypercoagulability workup were negative. There was no evidence disseminated intravascular coagulopathy.

Diagnosis: NAION secondary to COVID coagulopathy and bleeding diathesis.

**Conclusion:** SARS CoV-2 infection is associated with diverse ophthalmic manifestations with various pathogenesis.

PP-781

**Multimodal imaging in diagnosis and monitoring of ocular Sarcoidosis**A Vyas, A Subramanyam<sup>1</sup>, S Phatak, S tiwari<sup>2</sup>.<sup>1</sup>Vitreo-retina , KBHB charitable eye and ear institute, Parel, <sup>2</sup>Vitreo-retina, KBHB eye and ear charitable institute, Parel, Mumbai, India**Objective:** To understand the role of various imaging modalities used to aid the diagnosis and response to treatment in ocular Sarcoidosis.**Methods:** A 48 year old female, complained of redness in both eyes. Visual acuity was 20/40. Anterior segment examination of both eyes showed features of both granulomatous and non granulomatous uveitis. Vitreous cavity showed snowballs. Fundus evaluation showed a hyperaemic optic disc and multiple, dsmall, greyish-whitish lesions scattered over the posterior pole. Optical coherence tomography enhanced depth imaging (OCT-EDI) showed hyper reflective dots on the vitreoretinal interface and normal reflectivity of retinal layers. Choroid showed homogenous hypo reflective elevated lesions with choriocapillaries thinning and areas of healthy choroid adjacent to it. Fundus autofluorescence was unremarkable. Fundus fluorescence angiography revealed areas of early hypo fluorescence to late hyper fluorescence at the posterior pole corroborating with the clinical picture. Optic disc staining with late leakage and peripheral vascular leak were noted. Systemic investigations was positive for Quantiferon TB Gold test and chest X Ray showed lymph node calcification. Serum angiotensin converting enzyme (sr.ace) was borderline (59.6). A provisional diagnosis of latent tuberculosis in an endemic area was made and the patient was started on anti-tubercular therapy for 6 months along with posterior sub tenon injection of triamcinolone acetonide. Subsequent follow ups did not reveal any change in the clinical picture. The radiological finding, a borderline sr.ace and a strong OCT-EDI finding of intact retinal layers and large choroidal granulomas was highly suspicious of ocular sarcoidosis. Patient was started on 1mg/kg body weight of oral prednisolone. however due to steroid intolerance, she was started on mycofenoalte mofetil. Serial monitoring of the lesions using OCT-EDI showed a reduction in the size of the choroidal granulomas with homogenous hyporefectivity and subsequent reduction in choroidal thickness. Patient is stable and is on concurrent anti-tubercular therapy and immunomodutor therapy.**Results:** OCT-EDI is a non invasive tool to monitor the progression of disease**Conclusion:** Fundus fluorescein angiography and OCT-EDI plays an important role in supporting a clinical diagnosis of ocular sarcoidosis especially in tuberculosis endemic areas. OCT-EDI can be used as an efficient tool in monitoring the progress and response to treatment.

PP-783

**Efficacy and Safety of Suprachoroidal CLS-TA/ARVN001 for NIU-ME in Asian Groups: Post-hoc Analysis**M Zhang<sup>1</sup>, T Ciulla<sup>2</sup>, J Qi<sup>3</sup>, T Bai<sup>3</sup>, Q Liu<sup>3</sup>.<sup>1</sup>*Peking Union Medical College Hospital, Beijing, People's Republic of China*, <sup>2</sup>*Clearside Biomedical, Inc., Alpharetta, United States*, <sup>3</sup>*Arctic Vision Biotechnology Limited, Shanghai, People's Republic of China*

**Objective:** PEACHTREE study is a phase 3, multi-center, masked, controlled clinical trial evaluating the safety and efficacy suprachoroidally injected triamcinolone acetonide (CLS-TA/ARVN001) in patients with macular edema (ME) associated with non-infectious uveitis (NIU). In this analysis, a subpopulation of patients in both the CLS-TA/ARVN001 and control groups were evaluated based on Asian ethnicity.

**Methods:** Patients in PEACHTREE were randomized 3:2 to receive either CLS-TA/ARVN001 4mg administered suprachoroidally via the SCS Microinjector® or a control (a sham procedure utilizing a syringe with a needle-less hub). Study treatments were administered on Day 0 and Week 12. Starting at Week 4, patients could receive rescue therapy if pre-defined criteria were met, with the choice of therapy left to the Investigator's discretion. Patients were followed for a total of 24 weeks. Results for PEACHTREE have been previously published by Yeh [PMID: 32173113].

**Results:** This post hoc subpopulation analysis showed that n=44 Asians were treated with CLS-TA/ARVN001 and n=28 Asian patients were randomized to the control group. At 24 weeks, approximately 54.5% of Asian patients who were treated with CLS-TA/ARVN001 experienced a gain of 15 or more letters in best corrected visual acuity, versus 28.6% of Asian patients in the control (p=0.34). Asian CLS-TA/ARVN001 patients gained a mean of 16 letters, versus 8.3 letters in the control. Similarly, Asian patients experienced a reduction in retinal thickness by a mean of 182.0 microns in the CLS-TA/ARVN001 group versus a reduction by 28.2 microns in the control (p<.001). The procedure was well tolerated among this subpopulation. A total at 11.4% of patients in the CLS-TA/ARVN001 group subpopulation experienced a TEAE of "Intraocular pressure increased" (include intraocular pressure increase and ocular hypertension) versus 10.7% in the control. TEAE of cataract (including cataract, cataract cortical, cataract subcapsular) were reported in 7.3% of CLS-TA/ARVN001 patients and 6.3% of control patients.

**Conclusion:** In conclusion, these results are consistent with those published by Yeh et al. While there are numerical differences in the results between the Asian subpopulation and the overall PEACHTREE findings, the results of this post hoc subgroup analysis do not show any findings indicating a lack in efficacy, or safety and tolerability signals in patients self-identifying as Asian.



PP-784

## CASE SERIES OF NON-INFECTIOUS UVEITIC EYES WITH MACULAR EDEMA TREATED WITH FLUOCINOLONE ACETONIDE IMPLANT (FAc, 0.19 mg, ILUVIEN®)

M Lima Fontes<sup>1</sup>, M Leuzinger Dias<sup>1</sup>, C Oliveira Ferreira<sup>1</sup>, J Araújo<sup>1</sup>, M Silva<sup>1</sup>, L Figueira<sup>1,2,3</sup>.

<sup>1</sup>Ophthalmology Department, Centro Hospitalar Universitário de São João, <sup>2</sup>Department of Pharmacology and Therapeutics, Faculty of Medicine, University of Porto, <sup>3</sup>Centre for Drug Discovery and Innovative Medicines (MedInUP), University of Porto, Porto, Portugal

**Objective:** The aim of this case report series was to evaluate the effectiveness and safety of fluocinolone acetonide implant in the treatment of non-infectious uveitic macular edema.

**Methods:** Retrospective case series that encompasses 6 eyes from 5 patients with recurrent non-infectious uveitic macular edema treated with a single fluocinolone acetonide implant. Mean follow up after FAc implant was  $19.8 \pm 11.3$  months. Demographics, form of uveitis, previous treatments, best-corrected visual acuity (BCVA, ETDRS letters), central macular thickness (CMT,  $\mu\text{m}$ ), intraocular pressure (IOP, mmHg) and IOP lowering medication needed before FAc implant were recorded at baseline. Highest BCVA and IOP values and lowest CMT values registered throughout the study were recorded as well as time to edema recurrence and the need of hypotensive drops. Significant macular edema reduction was defined as  $\text{CMT} < 300 \mu\text{m}$  or a decrease in CMT  $> 20\%$ .

**Results:** Six eyes from 5 patients with mean age of  $55.2 \pm 9.9$  years were included. Four patients were female, and all were pseudophakic at baseline. Four of the eyes had been diagnosed with anterior uveitis, 1 eye with posterior uveitis and 1 eye with panuveitis. All cases of uveitis were idiopathic/undifferentiated. Prior to FAc implant, all eyes were under systemic therapy with oral corticosteroids and/or immunosuppressive agents, and performed intravitreal short-action corticosteroids that conduced to macular edema reduction but with quick relapse after 1 to 6 months. At baseline, BCVA was  $45.0 \pm 23.2$  ETDRS letters, CMT was  $474.7 \pm 127.0 \mu\text{m}$  and IOP was  $14.0 \pm 4.8$  mmHg. After FAc implant, all eyes achieved criteria for macular edema reduction with a peak functional gain of 16.7 ETDRS letters and a maximum anatomical reduction of  $205.7 \mu\text{m}$ . Throughout this study, 80% showed no recurrence of edema and 1 eye saw its edema relapsing after 28 months. Maximum value of IOP registered was  $15.2 \pm 4.4$  mmHg, at a mean follow-up period of  $10.7 \pm 7.0$  months. No IOP lowering drugs were needed for any eye during follow-up.

**Conclusion:** In this case series report, the treatment of non-infectious uveitic macular edema with FAc implant was associated with visual acuity gains and significant reductions of CMT, as well as improved control of inflammatory activity and prevention of edema recurrence. No additional safety concerns were observed after FAc implant. These results were consistent to those described in the pivotal study PSV-FAI-001.

PP-785

### High Cure Rate can be Achieved for Acute Vogt-Koyanagi-Harada Disease with Appropriate Immunosuppression Regimen

X Zhang.

**Objective:** To report the clinical profile and outcomes of acute Vogt Koyanagi Harada (VKH) disease with strict corticosteroids tapering regimen, and to investigate the independent risk factors for prolonged disease course.

**Methods:** A total of 101 acute VKH patients (202 eyes) with more than 18 months follow-up were recruited from January 2011 to June 2020. All the patients were divided into 2 groups according to the interval between the onset of VKH and the obtainment of treatment. group 1 was within 2 weeks, and group 2 was within 2 weeks to 2 months. The first-line therapy was oral prednisone, which was gradually and slowly tapered off by a diminished dose. Immunomodulatory agents were added only as clinically indicated. Patient's responses to the treatment regime at the deadline for study inclusion were classified as two outcomes: restitution ad integrum and chronic-recurrent. Independent risk factors for longer disease course were analyzed.

**Results:** Of the 101 patients, there were 59 patients (118 eyes) in group 1, 42 patients (84 eyes) in group 2. Ninety-six patients (95.0%) (56 in group 1 and 40 in group 2) achieved restitution ad integrum and none of them had a recurrence of ocular inflammation after the termination of therapy, the other 5 patients (5.0%) developed into chronic-recurrent uveitis. Among patients who ultimately were tapered all medications off, the median time-frame of taking prednisone and immunosuppressants was 11.0 months. BCVA in 96.5% of patients reached at least 20/40 at last visit, and the percentage of BCVA equal to or better than 20/25 was 90.6%. Multivariate logistic regression analysis demonstrated that the time of visit, ocular complications and cigarette smoking were independent risk factors for longer disease course. Meanwhile, cigarette smoking has a significant impact on ocular inflammation activity.

**Conclusion:** Appropriate immunosuppression regimen can successfully prevent acute VKH from developing into chronic recurrent uveitis and cure the disease. The time of visit, ocular complications and cigarette smoking are independent risk factors for prolonged disease duration.

PP-788

### The Clinical Results of Heparin-Coated Intraocular Lens Implantation in Fuchs Uveitis Syndrome

P Kaya, Y Özdamar Erol<sup>1</sup>, K Özdemir Yalçınsoy<sup>1</sup>, E Köylü<sup>1</sup>, P Çakar Özdal<sup>1</sup>.

<sup>1</sup>Ophthalmology, Health Sciences University Ulucanlar Eye Training and Research Hospital, Ankara, Türkiye

**Objective:** To evaluate the clinical results in eyes undergoing phacoemulsification and hydrophobic heparin-coated foldable intraocular lens (IOL) implantation in Fuchs uveitis syndrome (FUS) related complicated cataract.

**Methods:** This prospective, randomized single-center study included 22 eyes of 22 Fuchs uveitis patients. The visual and clinical outcomes were evaluated after phacoemulsification and hydrophobic heparin-coated foldable IOL implantation.

**Results:** 10 (45.5%) patients were female of 22 patients with a mean age of  $36.59 \pm 12.4$  years. The mean follow-up time was 12 months. Best-corrected visual acuity was  $0.17 \pm 0.15$  preoperative and  $0.71 \pm 0.21$  postoperative with a statistical significance ( $p < 0.001$ ). Intraocular pressure was  $14.95 \pm 3.4$  mmHg preoperative and  $16.73 \pm 8.32$  mmHg postoperative ( $p: 0.758$ ). Posterior subcapsular cataract was observed in 20 eyes (90.9%), nuclear cataract in 1 eye (4.5%), and mature cataract in 1 eye (4.5%). Intraoperative complications (such as posterior capsule rupture/anterior vitrectomy) were not developed in any patient. Posterior capsule opacification (PCO) developed in 6 eyes (27.3%), and the mean PCO development time was  $3 \pm 2.4$  months. Giant cell (GC) deposits on the IOL were detected in 3 eyes (13.6%). The mean time for the development of these deposits was  $4.3 \pm 2.8$  months. Postoperative  $\geq +2$  anterior chamber reaction, uveitis reactivation, anterior capsule fibrosis, and IOL opacification were not observed in any patient.

**Conclusion:** The GC deposits and PCO are the most important problems that reduce the quality of vision after cataract surgery in FUS patients. Heparin surface coating reduces inflammatory cell adhesion and heparin-coated IOL is a way to improve visual acuity, reduce the deposit accumulation and PCO in FUS patients.

**Keywords:** Cataract; Fuchs' uveitis syndrome; heparin-coated intraocular lens; phacoemulsification; uveitis

PP-790

**Sankara Nethralaya Tuberculous Uveitis (SANTU) – Report of a prospective study**J Biswas, J Ramdoss<sup>1</sup>, N Lathiff<sup>1</sup>.<sup>1</sup>Uvea, Sankara Nethralaya, Chennai, India

**Objective:** To assess the clinical profile and response to standardized antitubercular therapy in patients with presumed tubercular uveitis in a tertiary eye care center in south India.

**Methods:** This prospective study was conducted between 2018 to 2022. Complete ophthalmic evaluation and systemic examination by a pulmonologist with appropriate laboratory investigations were done in all patients

**Results:** 295 patients were included in our study. Mean age was  $36.9 \pm 12.46$  years. Male (65%) were more commonly affected than female (35%). Bilateral (56%) presentation was more common than unilateral (44%). Past history of TB was noted in 60 patients (20%). Uveitis was anterior (N= 19, 4%), intermediate (N= 78, 16.2%), posterior (N= 178, 38.5%) and panuveitis (N=12, 2.5%) were seen. Posterior segment findings include retinal vasculitis in 79 eyes (17%), multifocal choroiditis in 36 eyes (7.7%), serpiginous like choroiditis in 28 eyes (6%), choroidal tuberculoma in 7 eyes (1.5%). Mantoux positivity was seen in 184 (62.3%), QuantiFERON TB gold test showed positivity of 41 patients (13.8%) and HRCT showed mediastinal lymphadenopathy in 102 patients (34.5%). PCR for M.TB were done in 53 patients, showed positive for nested PCR in 46 patients (86%) and in real time PCR in 23 patients (7.7%). Complications like cystoid macular edema (N=42, 14.2%), glaucoma (N=32, 6.9%), cataract (N=65, 22%), epiretinal membrane (N=24, 8.1%), CNVM (N=9, 3%) were seen. All were treated with standardized ATT regimen. 108 patients finished 9 months treatment of ATT. 94.2% (N=278) patients were treated with addition of oral steroids. Visual acuity improvement in 112 (50%) patients, maintained in 46 (20.9%) and decreased in vision noted in 32 (14.5%) patients.

**Conclusion:** Retinal Vasculitis was the most common ocular lesion in intraocular TB followed by serpiginous like choroiditis. ATT with steroid helped in preserving vision.

PP-791

**Novel Findings Utilizing Optical Coherence Tomography Angiography Analysis in Autoimmune Posterior Uveitis**J Shen, J Kong<sup>1</sup>, S Chen<sup>1</sup>, L Feng<sup>1</sup>.<sup>1</sup>Eye Center, Second Affiliated Hospital, School of Medicine, Zhejiang University, Hangzhou, People's Republic of China

**Objective:** To analyze the quantitative parameters acquired by optical coherence tomography angiography (OCTA) in patients with autoimmune posterior uveitis.

**Methods:** OCTA images of 65 eyes affected with uveitis and 65 normal control (NC) eyes were obtained. The central macular thickness (CMT), retinal thicknesses, foveal avascular zone (FAZ) area, foveal density 300  $\mu$ m (FD300), and vascular density (VD) were compared among acute uveitic eyes, chronic uveitic eyes, and NC eyes. VDs were evaluated in the choriocapillaris, outer retina, optic disk, whole and parafovea superficial capillary plexus (SCP), and whole and parafovea deep capillary plexus (DCP). Correlation analysis was used to analyze the relationship between LogMAR best-corrected visual acuity (BCVA) and quantitative parameters from OCTA.

**Results:** Compared with NC eyes, the CMT and retinal thicknesses were increased significantly in eyes with uveitis ( $p < 0.05$ , respectively). No significant difference was observed in the FAZ area. FD300, VDs in the optic disk, SCP, and DCP both in whole image and parafovea, choriocapillaris were significantly decreased in uveitis eyes ( $p < 0.05$ , respectively) compared with NC eyes, only the acute group had decreased VD of the outer retina and choriocapillaris compared with the NC group ( $p < 0.05$ ). Moreover, quantitative parameters of OCTA showed a significant correlation with LogMAR BCVA in the patients with uveitis. Whole VD DCP was the best predictive factor for BCVA in the patients with uveitis.

**Conclusion:** Quantitative measurement by OCTA is a promising strategy for objective assessment of autoimmune posterior uveitis.

**PP-793****Visual Rehabilitation In Children With Cortical Visual Impairment- An Interim Analysis With Phase-Wise Strategies.****S K.S.<sup>1</sup>, S Veenish<sup>1</sup>.**<sup>1</sup>*Jawaharlal Nehru Medical College, Belagavi, India*

**Objective:** Primary objective: To study the outcome after structured visual interventional strategies in children with Cortical Visual Impairment(CVI).

Secondary objective: To evaluate the aetiology and radiological correlation with the severity of CVI.

**Methods:** This is an ongoing prospective interventional study. Children attending the Child Development Centre (CDC) of a tertiary care hospital in South India and diagnosed with CVI in the age group of six months to 12 years and meeting the sampling criteria were screened and enrolled consecutively after obtaining parental consent.

A CVI Kit encompassing all the interventional activities are indigenously developed to ensure better compliance. Smartphone based messenger apps are utilized for monitoring and guiding. Follow up is done every three months.

**Results:** During the study period, a total of 43 children referred by CDC with a diagnosis of CVI were enrolled. Follow up is going on. Based on MRI findings, most common cause of CVI in our group was hypoxic–ischemic encephalopathy (HIE) seen in 20 subjects (50%). In a significant number of children (27.5%) with CVI, the MRI findings were normal.

Most children were grouped in CVI phase 1(56%). In the age group less than one year, all children were diagnosed with CVI phase I.

Among the 24 subjects grouped in Phase I CVI, 17 had perinatal insult. 39.5% of children had an uneventful perinatal period.

In this pandemic era, 16 children have followed up for the three monthly follow up and all have shown significant improvement either in phase or in their rating scores within the phase.

**Conclusion:** A child with CVI has difficulty in processing more than one sensory input at a time. Hence an early and less complex intervention program tailored according to child's specific needs should be encouraged. Early ophthalmic screening of pre term and high-risk babies with significant perinatal insult should be incorporated in routine practice.

PP-794

## Low Vision Rehabilitation With And Without Training Of The Preferred Retinal Locus In Patients With Central Scotoma

A Saleh<sup>1</sup>, S Sharafeldeen<sup>1</sup>, R Mahdy<sup>1</sup>, A Atalah<sup>2</sup>, K Solaiman<sup>1</sup>.

<sup>1</sup>Ophthalmology, Zagazig University Hospital, <sup>2</sup>Computer science, Zagazig Faculty of Engineering, Zagazig, Egypt

**Objective:** To compare the percentage of patients among both groups who gained at least two lines improvement of lea distance eye chart, those who gained at least 10 P improvement of the font size of come closer reading acuity test and to compare the improvement in reading speed and in performing various daily activities

**Methods:** Randomized controlled clinical trial included sixty patients with age group ranging from 7 – 70 years with bltateral irreversible maculopathy causing central scotoma. Thirty patients (group 1) received rehabilitation using low vision magnifying devices and the other thirty patients (group 2) received low vision rehabilitation with magnifying devices and training of the Preferred Retinal Locus (eccentric viewing traning). After full ophthalmological assessment we compared the results of the two interventions on far visual acuity, reading size, reading speed and performance of various daily activities.

**Results:** large pecent of patients were Age Related Macular Degeneration and Stargardts. There is statistically significant improvement in far vision, reading size and reading speed in both groups but there is no significant difference in between the two groups except in the reading speed with range (8 to 55), (10 to 80) word/ minute in group 1 and 2 respectively. Regarding the daily activities (reading, writing, face recognition, watching TV and household activities). There is statistically significant improvement in both groups with non-statistically significant difference in between studied groups except ability to do household work (46.7% within first group versus 83.3% within the second group)

**Conclusion:** In patients with bilateral irreversible maculopathy, low vision rehabilitation with eccentric viewing training would have better effect on the quality of their vision than that without eccentric viewing training. Eccentric viewing can be done only to this patients if the low vision devices are not available and it could lead to significant improvement in various daily activities.

PP-795

### A Survey of Resources for Vision Rehabilitation in Schools for the Blind, South-east Nigeria: Any Implication for Eye Care Policy?

S Onwubiko, C Anyalebechi<sup>1</sup>, N Nwachukwu<sup>1</sup>, C Mamah<sup>1</sup>, F Maduka-Okafor<sup>1</sup>, E Onwasigwe<sup>1</sup>, R Umeh<sup>1,2</sup>.

<sup>1</sup>Ophthalmology, University of Nigeria Teaching hospital Ituku-Ozalla Enugu Nigeria, Enugu, Nigeria

**Objective:** Documented evidence showed that the blind and visually impaired can acquire useful compensatory skills in special schools. Rehabilitation enhances vision, improves quality of life and facilitates development. This survey assessed the resources available for vision rehabilitation in schools for the blind, their impact on the students and factors influencing their availability in rural south-east Nigeria.

**Methods:** A descriptive, cross-sectional study design using both quantitative and qualitative approaches was adopted for this survey in April, 2019. Ethical approval was obtained from the Health Research and Ethics Committee (Institutional Review Board) of the University of Nigeria Teaching Hospital, Ituku-Ozalla, Enugu according to the tenets of the Helsinki Declaration. A checklist was used to assess the resources available for rehabilitation in the three south-eastern schools located at Oji River, Enugu State, Isulo, Anambra State and Afaraukwu, Abia State. An in-depth interview was held with the head-teachers to investigate the factors influencing their availability. Focus group discussions with a convenient sample of students from each school were conducted to ascertain if the available resources were accessible and their impact on them. Descriptive statistics were used to summarize the data.

**Results:** There was a total of 215 students, 75 in Oji River, 62 in Isulo, and 78 in Afaraukwu. The schools comprised of boarding primary and vocational sections. The resources for rehabilitation in these schools were inadequate. Braille was the predominant material resources. Computerized assistive devices were non-existent. The number of teachers were insufficient, with limited offers in Nigerian Universities on special education. However, available educational devices, daily living devices and personnel were accessible to the students and had impacted positively on them. Funding was the main factor affecting availability of the resources.

**Conclusion:** In rural south-east Nigerian schools for the blind, resources for rehabilitation were deficient. The reported deterrent is amenable to even resource allocation by governmental, non-governmental donor agencies and philanthropy. These data serve to guide policy makers on measures to improve the blind students' quality of life.



PP-796

**Functional vision and clinical Management of Patients with Retinitis Pigmentosa**S Asal<sup>1</sup>, D Dala<sup>2</sup>.<sup>1</sup>optometry, Nagar school of optometry, Ahmedabad, <sup>2</sup>Paramedical and Health Sciences, Faculty of Medicine, Parul University, vadodara, India**Objective:** 1) To explore Functional vision and of Patients with Retinitis Pigmentosa.

2) To rule out the clinical Management of Patients with Retinitis Pigmentosa.

**Methods:** All the subjects visiting Low vision Rehabilitation centre during January to December 2021 were included. Oral Consent of Subjects were Obtained. Comprehensive Ocular examination was done followed by Low vision trial and management. Data was analysed with Microsoft Excel 2016.**Results:** 30 subjects with Retinitis pigmentosa were included in the study. 30% were female and 70% were male. Mean age of subjects was  $32.73 \pm 18.42$ . On an average subjects were found to have Retinitis pigmentosa since  $12.23 \text{ years} \pm 8.50 \text{ years}$ . Mean refractive error among subjects was  $-2.73 \pm 4.52\text{D}$  spherical power and  $-1.24 \pm 1.52\text{D}$  cylindrical. An average Best corrected visual acuity of right eye 1.005 logmar standard deviation 0.41 and left eye mean 1.01 standard deviation 0.35. In all subjects visual field defects were present. Out of total population 93.33% had normal color vision and 6.66% had abnormal color vision. In all subjects Contrast Sensitivity improved after optical correction. Out of total population screened 60% had moderate visual impairment. According to WHO Categories 20% has had severe visual impairment and another 20% were diagnosed with blindness.**Conclusion:** Higher population of RP was found among male as compared to female. Subjects with moderate visual impairment are benefited with low vision devices. Earlier diagnosis could benefit subjects for low vision management and Rehabilitation services.

PP-798

**Treatment of Subretinal Hemorrhage with Recombinant Human TNK tissue-type Plasminogen Activator: a case report**

W Wang.

**Objective:** Treatment of Subretinal Hemorrhage with Recombinant Human TNK tissue-type Plasminogen Activator: a case report

**Methods:** A 69-year-old female patient showed a round subretinal bleeding area of 8PD size in the posterior pole of the right eye on fundus examination. The diagnosis was subretinal hemorrhage of the right eye, and was treated by vitrectomy through the posterior approach of the right eye and subretinal injection with 38G needle and 50ug of TNK.

**Results:** On the 5th day after the operation, the subretinal hemorrhage spread to the periphery and absorbed most of it. On the 15th day after the operation, the subretinal hemorrhage was basically absorbed. This case is the first reported case in China that TNK is used in the treatment of subretinal hemorrhage.

**Conclusion:** The results showed that the treatment of subretinal injection of TNK is safe and effective, which could make subretinal hemorrhage migrate earlier, reduce retinal damage and facilitate the recovery of retinal function.

PP-799

**Effects of Hypoxia on Collagen Metabolism in Human Fetal Scleral Fibroblasts and its Mechanism**X Tang, S Song, H Li.

**Objective:** To observe the effects of hypoxia on collagen expression in human fetal scleral fibroblasts (HFSFs) and to investigate whether hypoxia participates in scleral remodeling through endoplasmic reticulum stress(ERS).

**Methods:** HFSFs were cultured in a three-gas incubator with an oxygen concentration of 2% for 0 h or 48 h. Western blot was used to detect the protein levels of IRE1  $\alpha$ , P-IRE1  $\alpha$ , COL1A1, MMP2,  $\alpha$ -SMA, and apoptosis-related proteins BAX and BCL-2. The content of  $\alpha$ -SMA was detected by immunofluorescence; Cell apoptosis rate and proliferation were detected by flow cytometry and CCK-8 respectively.

**Results:** Western blot showed that the protein levels of IRE1  $\alpha$ , P-IRE1  $\alpha$ , COL1A1, MMP-2,  $\alpha$ -SMA, BAX, and BCL-2 were all higher in the hypoxic 48 h group than in the hypoxic 0 h group (all  $P < 0.05$ ). Immunofluorescence results showed that  $\alpha$ -SMA protein fluorescence intensity was higher in the hypoxic 48 h group than in the hypoxic 0 h group. Flow cytometry showed that the apoptosis rate in the hypoxic 48 h group was higher than in the hypoxic 0 h group ( $P < 0.05$ ). CCK-8 showed that OD values were lower in the hypoxic 48 h groups than in the hypoxic 0 h group ( $P < 0.05$ ).

**Conclusion:** Hypoxia may participate in scleral remodeling by activating endoplasmic reticulum stress to down-regulate the expression of COL1A1.

## PP-801

**Gene-independent therapies for inherited retinal dystrophies**

R Rodrigo<sup>1</sup>, L Olivares González<sup>1</sup>, S Velasco<sup>1</sup>, D Salom<sup>2</sup>, E González García<sup>3</sup>.

<sup>1</sup>Pathophysiology and Therapies for Vision Disorders, Research Center Principe Felipe, Valencia, <sup>2</sup>Ophthalmology,

<sup>3</sup>Neuroscience, Manises Hospital, Manises, Valencia, Spain

**Objective:** Inherited retinal dystrophies (IRDs) constitute a heterogeneous group of retinal diseases that cause the progressive loss of vision. RP is the most common IRD that cause the progressive loss of vision, mainly associated with photoreceptor (rods and cones) dysfunction and their loss. RP has a high genetic (more than 120 genes) and clinical heterogeneity which makes difficult to find a correct treatment. Currently, there is only one treatment for RPE65 gene. Evidence suggest that inflammation and oxidative stress play a key role in their progression. The objective was to evaluate different antioxidant or/and anti-inflammatory approaches on preclinical models of RP and RP patients.

**Methods:** Firstly, several markers of redox status and inflammation were analysed in ocular samples of a model of RP, rd10 mice and RP patients by enzyme immunoassay (ELISA), real-time PCR (qPCR), or enzymatic assays. Then we assessed two different approaches: 1) oral administration of a mixture of nutraceuticals with antioxidant properties in RP patients and rd10 mice; 2) intravitreal administration of an antibody (Adalimumab) against the cytokine tumour necrosis factor alpha (TNF  $\alpha$ ) in rd10 mice and in RP patients (ongoing clinical trial ADARET). Retinal degeneration by histology (mice), inflammation by histology, ELISA, qPCR, redox status by enzymatic assays, visual function by ERG, OCT, visual field, etc. were assayed in rd10 retinas and aqueous humour/blood of RP patients.

**Results:** Oral administration of the mixture of nutraceuticals ameliorated retinal degeneration in rd10 mice along with the inflammatory process and oxidative damage. Besides, 24-month oral supplementation slowed down retinal dysfunction (multifocal ERG recordings) and some markers of redox status in RP patients compared to RP patients who received placebo. A single intravitreal injection of Adalimumab reduced retinal degeneration, inflammation, and improved redox status in rd10 mice. Currently, we are performing the clinical trial in RP patients.

**Conclusion:** Oxidative damage and inflammation contribute to retinal degeneration in RP progression. Both cellular processes are highly interconnected. They are key players during RP regardless of the disease-causing mutation. Therapies aimed at improving ocular redox status and reducing inflammation seem to be promising approaches to slow down retinal degeneration in this rare disease.

PP-802

## Consistency Of The Performance Of Fundus Images Taken By Different Camera Modes In Multiple Eye Disease Models

S He, D shi, M He.

**Objective:** The purpose of this study is to verify the consistency of the performance of fundus images taken by different camera styles in multiple eye disease models.

**Methods:** We collected fundus photographs of the same patient taken by both Topcon and mediwork cameras and input them into the four previously trained disease classification DL models, respectively. Additionally, we calculated the consistency of the two eyes of the same patient as well. We calculated the agreement between the results of the fundus photos between each DL model using Cohen's linearly weighted kappa.

**Results:** In the 5-class DR model, the topcon and mediwork camera both show substantial consistency on the left and right eyes (Cohen's Kappa was 0.64 and 0.66, respectively). The topcon camera showed a substantial consistency, while the mediwork camera showed a moderate consistency (Cohen's Kappa was 0.77 and 0.59, respectively) when it comes to the consistency of the left and right eyes. In the binary classification model of referable DR, the right eye has achieved substantial consistency, and the left eye has achieved almost perfect agreement (Cohen's Kappa was 0.75 and 0.83, respectively). The consistency in AMD and glaucoma model is way less impressive compared to the above ones (Cohen's Kappa was 0.47 and 0.34 in AMD, 0.38 and 0.29 in glaucoma).

**Conclusion:** We found that on the five-class DR model, the two cameras had substantial agreement, moreover, their agreement improved on the two-category referable DR model. Therefore, the two-category referable DR model is better at adapting to diverse data than the five-category DR model. The topcon and mediworks camera did not achieve satisfactory agreement in the AMD and glaucoma classification models further indicates that the performance of DL models need to be re-evaluated and adapted when using new camera modes.

PP-804

**Mfn2 Is Essential for Retinal Organization And Neurogenesis during Mouse Retinal Development**H Shen<sup>1</sup>, L Feng<sup>1</sup>, H Niu<sup>1</sup>, Z Guo<sup>1</sup>, J Zhao<sup>1</sup>.<sup>1</sup>The 4th Affiliated Hospital of China Medical University, Eye Hospital of China Medical University, Provincial Key Laboratory of Lens Research, Shenyang, People's Republic of China**Objective:** We used a mouse model to explore the role of Mitofusin 2(Mfn2) in mammalian retinal development.**Methods:** The normal expressing pattern of Mfn2 in C57BL/6 mice was analyzed by immunofluorescence staining. To investigate the effects of Mfn2 absence on retinal development, the Cre-loxP system was used to generate retina-specific Mfn2 in knockout mice (Mfn2<sup>flox/flox</sup>; Six3cre<sup>+</sup>; CKO). Morphological changes in the retina of E13.5, E17.5, P0.5, P7, P14 and P21 mice were observed via hematoxylin and eosin staining. Immunofluorescence staining was used to assess protein distribution and terminal deoxynucleotidyl transferase dUTP nick end labeling (TUNEL) staining to assess apoptosis changes. Proteins were identified and quantified by Western blotting. Fundus color photography, fundus fluorescence angiography and optical coherence tomography were performed on 3-week-old to 8-week-old mice to evaluate function and structure of retina and its blood vessels.**Results:** The Mfn2 protein was widely distributed in the whole retina during development, especially concentrated in retinal ganglion cells (RGC) layer, inner plexiform layer and inner segment of photoreceptors. Loss of retinal Mfn2 led to RGC loss and decreased inner plexiform layer thickness. TUNEL apoptosis signals were present in developing RGC layer and inner plexiform layers. There were some changes in visual function and angiogenesis of 3-week-old mice to 8-week-old mice, accompanied by some retinal morphological degeneration.**Conclusion:** Mfn2 regulates retinal structure, especially the development and apoptosis of retinal ganglion cells.

**PP-805****Laboratory evaluation of halos and through-focus performance of three different multifocal intraocular lenses**

X Liu, Y Huang<sup>1</sup>.

<sup>1</sup>Eye Institute of Shandong First Medical University, Qingdao, Hong Kong, China

**Objective:** To compare the halo features and through-focus performance of three different multifocal intraocular lenses (MIOLs) that provide distance, intermediate, and near vision in clinical trial.

**Methods:** A diffractive MIOL (AT LISA tri 839MP, Carl Zeiss Meditec, Jena, Germany), an extended depth-of-focus MIOL (TECNIS Symphony ZXR00, Abbott Laboratories, Abbott Park, IL), and a rotational asymmetric MIOL (SBL-3, Lenstec, Inc., Christ Church, Barbados) were assessed in a modified International Organization for Standardization eye model. The modulation transfer function (MTF) at the IOLs' foci was obtained using aperture sizes of 3.0 and 4.5 mm. Through-focus MTF curves were compared among all IOLs. Images of the slit pattern were used to assess halo formation and characteristics.

**Results:** AT LISA tri and Symphony showed symmetric halos. The halos of AT LISA tri were larger but weaker in distance and near foci, while the halos of Symphony were smaller and fainter in intermediate focus. The halos of SBL-3 were asymmetric and appeared as tangentially downward weaker halos. The optical performance of diffractive MIOLs gradually deteriorated as the aperture increased. The distance foci of AT LISA tri and SBL-3 were of similar superior optical quality, the intermediate focus of Symphony showed the best optical quality, and the near focus of SBL-3 outperformed the near foci of the remaining IOLs.

**Conclusion:** The differences in the design of the MIOLs translate to differences in optical performance at their foci, through-focus expressions, and halo features, which can provide further information to surgeons when selecting what IOL to implant.

PP-806

## Comparison of the Influence of Different Equipment or Different Screen Brightness Conditions on AI Acuity Test

L Cheng<sup>1</sup>, S Peng<sup>1</sup>, J Huang<sup>1</sup>.

<sup>1</sup>State Key Laboratory of Ophthalmology, Zhongshan Ophthalmic Center, Sun Yat-sen University, Guangdong Provincial Key Laboratory of Ophthalmology and Visual Science, Guangdong Provincial Clinical Research Center for Ocular Diseases, Guangzhou, People's Republic of China

**Objective:** To compare an online VA tests- Stanford Acuity Test (StAT) test results under different electronic equipment or different screen brightness conditions on the basis of real-human VA measurements, and to assess the agreement of StAT with ETDRS eye chart measurement under the different conditions.

**Methods:** Healthy subjects with Best Corrected Visual Acuity (BCVA) of 0.0LogMAR or higher were recruited in the study. The EDTRS eye chart test was performed first, followed by the StAT test was performed on iPad Air2 (IPAD) and Microsoft Surface pro4 (MS) under two different screen brightness levels (50% and 100%). The time spent measuring each eye in each method was also recorded. The consistency of the visual acuity test results of different equipment or different screen brightness conditions were assessed using the EDTRS eye chart test results as the gold standard.

**Results:** A total of 51 eyes of 51 people were recruited in this study. The average BCVA of IPAD and MS groups at 50% screen brightness was -0.05LogMAR and -0.07LogMAR, respectively. When the brightness was set to 100%, the IPAD and MS groups were both -0.09LogMAR. The visual acuity test results for IPAD (at 50% brightness) group had the highest correlation with the EDTRS group (the correlation coefficient was 0.62). The average time spent for EDTRS group was 58.51 seconds. According to statistics, except for the MS (at 50% brightness) group (58.97 seconds), the time spent of the IPAD (50%, 100% brightness) group (51.56 seconds, 50.16 seconds) and MS (100% brightness) group (53.53 seconds) were significantly shorter than the EDTRS group.

**Conclusion:** For people with BCVA of 0.0LogMAR or higher, different equipment and screen brightness did have an effect on the accuracy of StAT system, which was lower than EDTRS results, but StAT was more convenient and faster than EDTRS eye chart test, which can play an auxiliary medical role.



## PP-807

**Short-Wavelength (Violet) Light Affects Axon Terminus and Neurotransmitter Function during Mice Visual Pathway Development**

X Zhang, X Wang, Y Wen, C Xie, J Tong, Y Shen.

**Objective:** Light wavelengths influence refractive development; however, their effects on disturbances in early visual pathway development and mechanism are poorly understood. Using an experimental model of visual development, we tested the hypothesis that light wavelengths affected early visual pathway development then led to myopia susceptibility.

**Methods:** C57BL/6 mice were placed in three spectrum environments beginning at eye opening: violet (Group V), green (Group G) and full-spectrum white light (Group W). After one, two and three weeks, eyes were collected for immunofluorescence to assess the changes of retinal components. Vitreous cavity injection of cholera toxin subunit B (CTB) fluorescent tracer was used to observe the retina ganglion cell (RGC) axon terminal morphology in lateral geniculate nucleus (LGN). Visual acuity (VA) and the ocular structure were measured. Retinal mRNA-seq and qRT-PCR were used to explore the molecular mechanism after two weeks. All data were described in mean  $\pm$  SEM. Mann-Whitney or t-test, one-way or two-way ANOVA were adapted for data analysis dependently. At least four mice were used for each group at each time point.

**Results:** After two weeks in Group V, the ocular axis length (AL) (Mann-Whitney test,  $p=0.0043$ ), anterior chamber depth (ACD) (unpaired t-test,  $p=0.014$ ) and vitreous chamber depth (VCD) (unpaired t-test,  $p=0.02$ ) were shorter, the VA decreased (one-way ANOVA,  $p<0.0001$ ). The number of S-cones in the dorsal retina decreased (one-way ANOVA,  $p=0.01$ ), while the diversity in length distribution of outer segment increased in the ventral retina (Kolmogorov-Smirnov test,  $p<0.05$  at L-1w,  $p<0.0001$  at L-2w and L-3w). Amacrine cells (ACs) were activated at a delayed phase. The axonal terminals in the LGN were less clustered and sparse (two-way ANOVA with Tukey's test,  $p<0.0001$ ). The results from Group G were very similar to those obtained from Group W. The KEGG and GO enrichment analysis showed that the violet light influenced the neural circuitry, synaptic formation and neurotransmitter function.

**Conclusion:** Exposure to violet light in the early stage of vision-dependent development in mice delayed the development of visual pathway. The axon terminus structure and neurotransmitter function may be the major suffering.

PP-809

**Generation of Patient-specific Congenital Cataract Model from Induced Pluripotent Stem Cells**Q Fu, K Yao.

**Objective:** Congenital cataract is the leading cause of childhood blindness. Surgical removal of the cataractous lens is the only established treatment currently. Considering the inevitable complications and heavy financial burden brought by cataract surgery, it is urgent to establish new strategies of cataract prevention and management. Up till now, appropriate disease models in vitro are lacking for the mechanism research and drug screening of congenital cataract. The present study aims to establish a congenital cataract model in vitro through generation of patient-specific lentoid bodies from induced pluripotent stem cells (iPSCs).

**Methods:** Two families affected by congenital cataracts were identified with c. 70C>A (p. P24T) of the  $\gamma$  D-crystallin gene (CRYGD) and c. 463C>T (p. Q155X) of the  $\beta$  B2- crystallin gene (CRYBB2), respectively, and were enrolled in the present study. The urinary cells from the proband as well as two healthy controls from each family were collected and reprogrammed into iPSCs using the four Yamanaka factors. Lentoid bodies (LBs) with highly similarity to human lens were developed from iPSCs using our “fried egg” method. The morphology of LBs was observed via light microscope and compared with the patient’s phenotype and disease course. Immunofluorescence staining of  $\alpha$  A-crystallin was performed to examine the formation of protein aggregates in the LBs.

**Results:** The LBs derived from the CRYGD- and CRYBB2-mutated iPSCs (CRYGD- and CRYBB2-mutated LBs) displayed opacification compared to normal LBs. The CRYGD-mutated LBs exhibited more severe opacification compared to the CRYBB2-mutated LBs, which was similar to the patients’ phenotypes. Both the CRYGD- and CRYBB2-mutated LBs expressed mature lens specific markers, though the expression of  $\gamma$  -crystallin was lower compared to normal LBs. The CRYGD- and CRYBB2-mutated LBs showed significantly more protein aggregates and decreased protein solubility than the normal LBs.

**Conclusion:** The present study provides a novel disease model of congenital cataracts, which may be applied to the research into pathological mechanisms and anti-cataract drug screening.

## PP-810

**Is there any relationship between accommodative amplitude and anterior chamber depth?**

D Kilic<sup>1</sup>, A Inceyol<sup>1</sup>, I Toprak<sup>2</sup>.

<sup>1</sup>Kayseri City Training and Research Hospital, Kayseri, <sup>2</sup>Pamukkale University School of Medicine, Denizli, Türkiye

**Objective:** The aim of this study was to determine the relationship between the accommodative amplitude and the change in anterior chamber depth after cycloplegia.

**Methods:** The study included 28 eyes of 28 healthy volunteers under the age of 40 years. After comprehensive ophthalmological examination accommodative amplitudes (AA) of the individuals were assessed by minus lens test. To determine the changes in anterior chamber depth (ACDc) objectively, two Pentacam tomography measurements were performed: before (ACD1) and after (ACD2) applying topical cyclopentolate hydrochloride 1 %.

**Results:** There were 16 (57.1%) male and 12 (42.9%) female participants in this study. The mean age was  $28.43 \pm 5.38$  years and the mean spherical equivalent (SE) was  $-1.89 \pm 0.74$  Diopters (D). The mean AA was  $10.12 \pm 3.1$  D, the mean ACD1 was  $3.14 \pm 0.12$  millimeters (mm), the mean ACD2 was  $3.28 \pm 0.11$  mm and the mean ACDc was  $0.13 \pm 0.06$ . Significant differences were detected in mean ACD1 and ACD2 ( $p < 0.001$ ). There was a significant positive correlation between ACDc and AA ( $r=0.418$ ,  $p=0.027$ ). Besides there were negative correlations between AA and SE and between age and ACD1 and ACD2 ( $r=-0.579$ ,  $p=0.001$ ,  $r=-0.573$ ,  $p=0.001$  and  $r=-0.653$ ,  $p<0.001$ ; respectively).

**Conclusion:** The study showed the positive correlation between ACDc and AA. It should be kept in mind that in those patients who have high AA, the optimal ACD measurements especially before performing intraocular surgeries should be taken after cycloplegia is achieved.

## PP-812

**Emphasis on heat strain to ocular surface: a functional and clinical study of a modified medical goggle**

Y Shao<sup>1</sup>, Y Bi<sup>1</sup>.

<sup>1</sup>Ophthalmology, Tongji Hospital affiliated with Tongji University, Shanghai, People's Republic of China

**Objective:** We aimed to build a modified medical goggle (MG) with better physical performance, and use a temperature humidity index (THI) as an indicator to investigate the impact of goggle-related heat strain on the ocular surface.

**Methods:** We evaluated the basic function of anti-fog, anti-ultraviolet and blue light radiation capability and the clinical impact on median noninvasive keratography tear film break-up time (m-NIKBUT), intraocular pressure (IOP), central corneal thickness (CCT), Schirmer test I, THI, and the Dry Eye-related Quality of life Score (DEQS) in twenty-four healthcare workers by comparing MG with standard goggles (SG, AF1621, 3M). THI inside the goggle and DEQS were recorded each 30min. The correlation between DEQS and THI was evaluated.

**Results:** MG had a significantly longer anti-fog time than SG ( $218.87 \pm 21.52$  vs.  $139.17 \pm 6.09$  min.,  $p < 0.05$ ), stronger anti-ultraviolet ability at 400 nm (99.9% vs. 45.55%), and optimal anti-blue light performance at 440 nm (33.32% vs. 13.31%). Both goggles achieved moderate to strong heat strain with a temperature humidity index (THI) over 80 at all time points. THI was significantly correlated with DEQS ( $r_s = 0.864$ ,  $p < 0.05$ ). Tear film stability and tear secretion were significantly different from those before wearing the goggle (both  $p < 0.05$ ). The MG group showed lower THI and dry eye-related quality of life score (DEQS) and higher tear film break-up time than the SG group (both  $p < 0.05$ ).

**Conclusion:** Wearing goggles for a long time may cause heat strain to the eyes, leading to eye discomfort and changes in the microenvironment of the ocular surface. Our MG has better anti-fog, anti-ultraviolet, and optimal anti-blue light performance, and lower heat strain on the ocular surface than SG.

PP-814

**Illumination for patients with retinal diseases**K Or<sup>1</sup>.<sup>1</sup>Private Office, Hamburg, Germany

**Objective:** Due to the development of new illumination devices in the last decades with different characteristics (color temperature, wavelength spectrum, reduced non-useable radiation, color e.t.c.) people have a wider choice for illumination than before. Knowledge of the luminous bodies and their targeted use in various retinal diseases can u.a. lead to improved visual perception.

**Methods:** In market available luminaires and their properties are mostly explored for normal and healthy people. The effects on retinal diseases are discussed theoretically in changes from physiology to pathology in retinal diseases. New and available luminaires (different LEDs, compact fluorescent luminaires, different street lighting luminaires e.t.c.) are compared in terms of their properties. In some eye diseases, changes in visual perception of patients have been explored by different lighting fixtures. In many diseases, however, their effect has not yet been investigated. Their potential use in retinal diseases is discussed.

**Results:** With the illumination devices available on the market, ophthalmically healthy people can usually see well enough, even though those with visual perception changes such as color shifts has to be accepted. In many retinal diseases, the visual perception changes, so that the visual perception is different and / or worse. Due to the different properties of the new lighting luminaires, ophthalmologists may provide recommendations for lighting in certain retinal diseases, which may lead to subjective (and possibly also measurable and / or objective) improvement in visual acuity of the retinal patient.

**Conclusion:** With the development of new, on the market available luminaires and constant improvement of their properties, the ophthalmologist have in some retinal diseases new possibilities for improved visual perception of the retinal patients. It is appropriate that more ophthalmological research should be done on the visual perception of ophthalmically healthy persons and retina patients under illumination with the new luminaires and their various properties.

PP-815

**Illumination and colour use to enhance the visual perception for ophthalmological patients in the private offices and clinics**

K Or.

**Objective:** Beyond clinically normal patients, ophthalmology clinics and private offices have a lot of patients with different ophthalmological diseases which may cause a decrease and / or change in vision. In addition there are many ophthalmological patients by whom the vision is changed temporarily due to dilation of the pupils or due to exposure flashes and /or light or lasers. The illumination and colour around the patients should be good enough to enable the best visual perception.

**Methods:** The combined knowledge of vision in various ophthalmological diseases, changes in visual perception during and after diagnostic and therapeutical procedures, illumination needs and possibilities of illumination with new luminaires, avoiding glare and using colour specifications of environment (walls and furniture) for better perception of the patients is needed to have an interdisciplinary solution.

**Results:** Inner architects use mostly monocoloured walls and multicoloured furnitures. For the changed/lowered vision patients the seeing of sitting places can be made with monocoloured furniture which are in contrast to the walls and other furnitures. For the patients with dilated pupils glare is a big problem. The use of non-direct light sources like LED panels or using reflected light from ceiling is important. There are many new luminaries fulfilling this requirements. The waiting room illumination levels should not exceed the minimum required levels.

**Conclusion:** Ophthalmological patients may have a better visual perception in the private offices and clinics with the use of certain illumination and colour properties in the environment.

# ***E-POSTERS***

**P-001****A Rasch Validated, Filipino, Cross Cultural Adaptation of the Cataract Questionnaire-9 Short Form (Catquest-9SF)**

J Pascaran<sup>1</sup>, L Pe<sup>1</sup>.

<sup>1</sup>*Ophthalmology, Quirino Memorial Medical Center, Quezon City, Philippines*

**Objective:** To produce a Rasch validated, Filipino version of the Catquest-9SF that accounts for linguistic and cultural disparities while maintaining the psychometric properties of the source questionnaire and establish a demographic profile of cataract patients seen in the outpatient department of Quirino Memorial Medical Center Department of Ophthalmology from April 2021 to November 2021.

**Methods:** A cross-cultural adaptation of the English version of the Catquest-9SF is made via a forward-backward-final forward translation protocol. A participating pre-test was then conducted. All adult patients diagnosed with a cataract were asked to answer the questionnaire. Conversely, patients with previous history of non-cataract related ocular surgery, severe to profound hearing loss, or cognitive impairment were excluded from participation. Demographic and clinical data were also gathered. The answers are subjected to Rasch analysis and Pearson correlation.

**Results:** A total of 43 patients were included in the study. The mean age was 63 years old with 58% of the participants being male. 95% of patients preferred Filipino as their primary language. Most patients had no visually significant ocular comorbidities (74%), nor did they have any systemic comorbidity that interferes with daily activities (95%). Bilateral cataracts were present in 54% of patients, while 19% of patients are already for second eye surgery. Many of the patients had a visual acuity of logMAR 0.48 and above in their better eye (70%).

Rasch analysis yielded well ordered categories with threshold values that ranged from -3.13 to 2.94. The person separation index and reliability were 2.89 and 0.89 respectively, indicating about 3 strata of visual disability. The infit mean square range was 0.51 to 1.73, with almost all questions within limits for good fit. Significant differential item functioning in one item was present among patients with differing educational backgrounds. Significant mistargeting was noted, with a floor effect being present. Person measures were significant and moderately correlated with visual acuity.

**Conclusion:** The cross-adapted Filipino version of the Catquest-9SF was unidimensional, with well-ordered categories, and person separation. It was mostly free from differential item functioning but had significant mistargeting. The results of the analysis can support clinical use albeit with some reservations with regards to the target population.



P-002

## Incidence of cystoid macular edema in pseudophakic patients with or without glaucoma receiving prostaglandin analogue

D Grew.

### Objective:

- 1- determine if the occurrence of CMO after cataract surgery is affected by the use of PGA drops by patients with glaucoma
- 2-determine if the use of prostaglandin analogue after cataract surgery to decrease intraocular pressure in non-glaucomatous patient can cause CMO
- 3- does there a real correlation between use prostaglandin analogue and CMO after cataract surgery

1- determine if the occurrence of CMO after cataract surgery is affected by the use of PGA drops by patients with glaucoma  
 2-determine if the use of prostaglandin analogue after cataract surgery to decrease intraocular pressure in non-glaucomatous patient can cause CMO  
 3- does there a real correlation between use prostaglandin analogue and CMO after cataract surgery

**Methods:** -Study Design:- observational longitudinal prospective cohort study- Inclusion and Exclusion Criteria:- Study Population MALE AND FEMALE AGE FROM 18 TO 70 YEARS patients with and without glaucoma undergoing cataract surgery recorded by a healthcare professional within 90 days of surgery, glaucomatous patient or non-glaucomatous patient taking prostaglandin analogs as Prophylaxis Eyes receiving prophylactic nonsteroidal anti-inflammatory drugs were excluded. - Sample size calculation(Expected incidence in unexposed 0.01, Assumed relative risk 3, Confidence level 0.95, Power 0.8, Sample size per group 766 Total sample size (both groups): 1532

**Results:** the doctor could face two dilemmas first one is the fear of the development of cystoid macular edema after cataract and the second is the increase of intraocular pressure or after surgery The incidence of postoperative day 1 IOP elevation after phacoemulsification performed by resident surgeons was 2 to 5 times that of experienced cataract surgeons. because of that prostaglandin analog has been used in the patient who had probably glaucoma or used after surgery to decrease intraocular pressure by increasing drainage of the uveoscleral tract

**Conclusion:** the prediction of the incidence of cystoid macular edema after mature cataract surgery is challengeable because decreased visual acuity after cataract surgery leads to dissatisfaction either to the patient or to the doctor.

P-003

### Surgical Outcome At Six Weeks After Cataract Surgery in Patients with Ocular Comorbidities

V Mangiraj<sup>1</sup>, S Kulkarni<sup>1</sup>, S Pissurlencar<sup>1</sup>, M Deshpande<sup>1</sup>.

<sup>1</sup>H.V.DESAI EYE HOSPITAL, PUNE, India

**Objective:** There is high incidence of cataract associated with ocular comorbidities but no study has been carried out in India regarding visual outcome in such patients. The aim of this study was to assess and compare visual outcomes and complications at 6 weeks after cataract surgery in patients with and without ocular comorbidities

**Methods:** This was a retrospective observational case control study. All the EMR records of patients operated for cataract from JAN 2018 to MAY 2021 were checked. Sample size was 106. Cases were defined as cataractous eyes with coexisting ocular comorbidities and controls were as without ocular comorbidities. Mild comorbidities were defined as those with minimal risk of intra operative / post-operative complications and no anticipated impact on visual outcome. Severe comorbidities were defined as those likely to negatively affect visual outcome or those with high risk of intraoperative/ postoperative complications. Ocular comorbidities were stratified by their anatomical site. Systemic association was also checked. Data on preoperative vision, diagnostic details of comorbidity, grades of cataract were collected. All surgeries were performed by senior surgeon. Primary outcome assessed were the preoperative and BCVA at 6 week and intra/postoperative complications. The complications were divided into minor and major complications. Major being as those likely to have direct negative impact on visual outcome or conditions where secondary surgical intervention was required.

**Results:** 98% of patients were above 40 years of age. In cases we found 56% of patients were male. In 63% of patients there were mild comorbidities. Retina (55%) was most common site for ocular comorbidities. In both cases and controls the most common grade of cataract was medium. In 54% of patients' ocular comorbidities were associated with systemic comorbidities. In patients with hard cataract only 9% were having good vision preoperatively which was improved to 64% after surgery. In cases the improvement in BCVA was statistically significant. 4% cases were associated with major complications while in 13% of cases there were minor complications. When compared to control this difference was statistically significant

**Conclusion:** The patients having ocular comorbidity should be counselled preoperatively regarding fair to poor visual outcome and occurrence of complications. Despite of having ocular comorbidity these patients may have good visual outcome when surgery performed by skilled surgeon.

**P-004****The Mystery of PPC**

A *Kulkarni*, *A Anusha*, *S Ramani*.

**Objective:** To evaluate the outcomes of small incision cataract surgery in cases of posterior polar cataract.

**Methods:** A retrospective study conducted in the department of ophthalmology a tertiary care centre in South of India. All patient diagnosed with Posterior Polar Cataract were included in the study. The preoperative vision, Symptoms and signs were noted. A detailed history regarding the duration of symptoms, history of drug intake and any other comorbidities was noted. All patients underwent manual small incision cataract surgery with hydro delineation and postoperative outcomes were evaluated.

**Results:** A total of 40 patients were evaluated. The mean age group was 55+/- 15 years. 82.5% of the patients of patients had no history of any drug intake, 90% of patients had no known co morbidities.

Intraoperatively there were no complications noted.

Post operatively 75 % of the patient had a vision of 6/12 or better on Snellen's chart, 12.5% had a vision between 6/18-6/24, 5% of patients had postoperative vision 6/36 – counting fingers 2 mts. Finally 2.5% of patients were found to have a vision of less than counting fingers at 1 meter.

On post op day 1, 72% of the patients had a clear cornea, 10 % of the patients had a few folds in the decemets membrane 5% had microcystic oedema and 10 % of the patients had central stromal oedema.

**Conclusion:** Posterior polar cataract is infamous for the abnormal attachment of the posterior capsule to the polar opacity. This abnormal attachment could be the cause for the increased number of posterior capsular rent during cataract surgery. However, with accurate preoperative assessment and intraoperative planning these untoward complications can be avoided and patients can have an excellent visual outcome.

P-005

### Changes of the central retinal thickness among patients with diabetic retinopathy after uneventful phacoemulsification

N Bachuk, D Zubkova<sup>1</sup>, B Olesia<sup>2</sup>.

<sup>1</sup>Ophthalmological, V.N. Karazin Kharkiv National University, <sup>2</sup>Medical Center «OKO», Kharkiv, Ukraine

**Objective:** Advances in modern technology, experienced surgeons, and high-quality intraocular lenses have made cataract phacoemulsification a highly effective, safe and routine surgical intervention that allows to restore vision immediately after surgery. However, in certain categories of patients, we are talking about patients with initial pathology of the retina, phacoemulsification can lead to some negative consequences in the posterior segment of the eye.

**Methods:** In this retrospective study medical records of 53 patients (aged  $64.7 \pm 6.3$ ) with cataract and diabetic retinopathy were analyzed. After preoperative optical coherent tomography (OCT) patients were divided into two groups: 28 persons with clinically significant diabetic macular edema (DME) and 25 patients without DME. The difference between preoperative and postoperative central retinal thickness (CRT) in 1 week, 1, 3 months after the operation was estimated by OCT.

Patients with preoperative clinically significant DME were treated with intravitreal Aflibercept injector 28 days prior of the surgery and 28 days after the phacoemulsification.

**Results:** In DME group with preoperative anti-VEGF treatment the average difference between preoperative and postoperative CRT was not statistically evident 1 week after phacoemulsification. CRT increased by  $45.2 \pm 8.6 \mu\text{m}$  (15 %) 1 month after surgery when we returned to the previous anti-VEGF treatment protocols and 3 months after cataract extraction, the difference in CRT was not statistically evident as compare with preoperative data.

In non- DME group the average difference between preoperative and postoperative CRT increased by  $31.1 \pm 8.6 \mu\text{m}$  (11 %) 1 week after phacoemulsification. 1 and 3 months after cataract extraction, the difference in CRT was  $65.0 \pm 9.1 \mu\text{m}$  (23 %),  $53.8 \pm 7.6 \mu\text{m}$  (19 %) respectively. In two cases of the 25 in preoperatively non-DME group, macular edema became clinically significant that required further anti-VEGF treatment.

**Conclusion:** Uneventful phacoemulsification among patients with diabetic retinopathy can potentially lead to diabetic macular edema in some cases.

P-006

### Comparison between VLink System and Conventional Image-Guided System for Patients with Significant Lens Opacity

M Chou, C Lee<sup>1</sup>, H Lin<sup>2</sup>, S Yang<sup>3</sup>, Y Chen<sup>2</sup>.

<sup>1</sup>Show-Chwan Memorial Hospital, Changhua City, Taiwan, China, <sup>2</sup>Ophthalmology, Show-Chwan Memorial Hospital, Changhua City, <sup>3</sup>Medical Research, Chung Shan Medical University, Taichung, Taiwan, China

**Objective:** To evaluate the astigmatism after cataract surgery between the use of intraoperative aberrometer plus image-guided system (VLink) and image-guided system (Verion) alone in patients with significant lens opacity.

**Methods:** A retrospective cohort study was conducted. A total of 73 patients with optical-disturbance cataract and received VLink system management were enrolled in the study group, while another 76 individuals with Verion system approach constituted the control group. The main outcomes included the best-corrected visual acuity (BCVA), astigmatism, spherical equivalent (SE) status and the predicting factor for less astigmatism in the two groups. Generalized estimated equation (GEE) was used to produce the adjusted odds ratio (aOR) and corresponded 95% confidence interval (CI).

**Results:** The preoperative and postoperative BCVA between the VLink and Verion groups were similar (all  $P > 0.05$ ). The preoperative cylinder power, preoperative SE and estimated SE were statistically insignificant between both groups (all  $P > 0.05$ ). Postoperative cylinder power ( $-0.28 \pm 0.15$  vs  $-0.96 \pm 0.88$ ), the postoperative SE ( $-0.18 \pm 0.41$  vs  $-0.57 \pm 0.74$ ) and difference between real SE and estimated SE ( $-0.03 \pm 0.21$  vs  $-0.41 \pm 0.58$ ) were significantly lower in the VLink group. Implantation of toric IOL was significantly associated with lesser astigmatism in both groups (both  $P < 0.05$ ). Longer axial length ( $P = 0.013$ ) and higher central corneal power ( $P = 0.023$ ) were correlated with higher astigmatism in the Verion group.

**Conclusion:** The application of VLink system is correlated to better postoperative astigmatism control and predictability compared to the use of Verion system in patients with significant lens opacity.

**P-007****Refractive accuracy of different methods of intraocular lens power calculation in phacoemulsification after radial keratotomy**J C Reddy.

**Objective:** To compare methods of calculating the required intraocular lens (IOL) power for patients undergoing cataract surgery after radial keratotomy (RK)

**Methods:** Retrospective evaluation of medical records of 69 eyes of 50 patients who had sequential RK and uneventful cataract surgery. Biometry was obtained with the IOLMaster 700. Nine IOL calculation formulae were evaluated. The achieved spherical equivalent outcome was compared with the target outcome to calculate the absolute error for each eye with each formula. Median and mean absolute error (MedAE and MAE), and percentage of patients within  $\pm 0.50$ ,  $\pm 0.75$  and  $\pm 1.00$ D of refractive target. The prediction error was compared between eyes that had  $\leq 1.4$ D inferior superior asymmetry (ISA) in the central 3.0mm to those that had  $>1.4$  D ISA.

**Results:** In the overall sample best results were seen with total keratometry (TK) Holladay 2 (using IOLMaster 700) formula with least MedAE of 0.45 and 58.8% eyes were within  $\pm 0.50$ . In eyes with  $\leq 1.4$ D ISA double-K modified Holladay 1 using IOLMaster keratometry showed least MedAE of 0.25 and 72.7% eyes within  $\pm 0.50$ . Whereas in patients with  $>1.4$  D TK Holladay 2 formula showed least MedAE of 0.45 and 63.6% eyes were within  $\pm 0.50$ .

**Conclusion:** This study has shown a difference in the performance of the IOL calculation formulae in eyes with prior RK. Anterior corneal asymmetry may be considered while calculation IOL power in eyes with prior RK to improve the accuracy of different IOL formulae.

**P-008****Congenital Cataract-causing Mutation G18D Affects The Stabilities Of  $\gamma$ S-crystallin Against Thermal And Chemical Stress**S Zhu, Y Xi, J Xu, X Chen, K Yao.

**Objective:** To study the effect of G18D mutation on the structure and stability of  $\gamma$  S-crystallin, so as to gain a deeper understanding of the molecular mechanism of  $\gamma$  S-crystallin-related congenital cataracts.

**Methods:** We constructed the recombinant plasmid pET-28a of  $\gamma$  S-crystallin wild-type and G18D mutant by polymerase chain reaction technology and site-directed mutagenesis, and transformed the plasmids into *E. coli* Rosetta (DE3) to overexpress the proteins. We used biochemical, biophysical methods, such as circular dichroism spectroscopy, fluorescence spectroscopy, to study the effects of the mutation on protein structure and stability. And molecular dynamic simulation technology was applied to further study the structural basis of mutant protein aggregation.

**Results:** Our results showed that there were tertiary structural differences between the wild-type protein and the G18D variant, and we found that the mutation significantly impaired  $\gamma$  S-crystallin stability against environmental stresses and promoted aggregation. Furthermore, the G18D mutation altered the surface electrostatic potential.

**Conclusion:** The G18D mutation significantly impaired  $\gamma$  S-crystallin stability against environmental stresses and promoted aggregation, which may result from the altered H-bonding formation and surface electrostatic potential.

**P-009****A Novel Single-Base Deletional Mutation in Major Intrinsic Protein (MIP) in Autosomal Dominant Cataract Of a Chinese Pedigree**Y Yu<sup>1</sup>, K Yao<sup>1</sup>.<sup>1</sup>Eye Center, Second Affiliated Hospital of Zhejiang University School of Medicine, Hangzhou, People's Republic of China

**Objective:** To identify the underlying genetic defect and the molecular phenotype in a Chinese family affected with autosomal dominant congenital punctate cataract.

**Methods:** Detailed clinical and ophthalmological examinations were performed on the affected and unaffected family members in this pedigree. The blood samples were collected for DNA extraction. All reported congenital cataract-related candidate genes were screened for causative mutations by direct DNA sequencing. Effects of amino acid changes on the structure and function of protein were predicted by bioinformatics analysis.

**Results:** All affected individuals in this family showed punctate cataracts. Sequencing of the candidate genes revealed a novel single deletion of nucleotide (nt) 301 (within codon 101) in exon one of the major intrinsic protein (MIP). This mutation was identified in all affected individuals but is not found in any of the 100 normal controls. Bioinformatics analysis showed that the mutation was predicted to affect the function and secondary structure of the MIP protein.

**Conclusion:** Our results identify that the novel single base pair deletion c.301delG mutation in MIP gene is responsible for congenital cataract in the Chinese pedigree. The mutation found in our study broadens the spectrum of MIP mutations causing congenital cataract.



P-011

### Late Intraocular Lens - Capsular Bag - Capsular Tension Ring Complex Subluxation or Dislocation

X Ma.

**Objective:** To describe clinical findings from cases of in-the-bag capsular tension ring (CTR) and intraocular lens (IOL) (IOL-CB-CTR complex) subluxation or dislocation.

**Methods: Design:** Retrospective case series study

**Methods:** Patients with IOL-CB-CTR complex subluxation or dislocation who had undergone cataract surgery with zonula weakness, and had complete medical history record in Eye Institute of Shandong First Medical University during from January 1,1994 to March 31, 2022 were selected. The detailed characteristics of cases were analysed.

**Results: Results:** A total of 31 cases were included. Patients were aged  $65.17 \pm 7.19$  years at subluxation or dislocation, which was performed  $41.23 \pm 14.63$  months after implantation. The incidence of IOL-CB-CTR complex subluxation or dislocation was 1.22%. The mean duration of IOL-CB-CTR complex with zonules weakness  $< 4$  o'clock hours was significantly longer than  $\geq 4$  o'clock hours. Ocular blunt trauma is a commonly associated condition. The main surgical methods for IOL-CB-CTR complex subluxation or dislocation were IOL repositioning and IOL exchange. The intraocular pressure was significantly decreased, and the uncorrected visual acuity and best-corrected visual acuity were significantly increased after surgery. No case occurred with retinal detachment, corneal endothelial decompensation, endophthalmitis or redislocation.

**Conclusion:** The incidence of late IOL-CB-CTR complex subluxation or dislocation was 1.22%. When zonula weakness was  $\geq 4$  o'clock hours, late IOL-CB-CTR complex dislocation was prone to occur and modified CTR was recommended to fix on the sclera with suture during cataract surgery, which may would contribute to prevent the dislocation of late IOL-CB-CTR complex.

P-012

**Three-dimensional Heads-up Cataract Surgery Using Femtosecond Laser: A Randomized Clinical Trial**K Wang<sup>1</sup>, K Yao<sup>1</sup>.

<sup>1</sup>Eye Center of the Second Affiliated Hospital, School of Medicine, Zhejiang University, Hangzhou, People's Republic of China

**Objective:** To compare the efficiency, efficacy and safety, as well as the educational value of heads-up (three-dimensional visualization system-assisted) and traditional microscopic cataract surgery.

**Methods:** This randomized non-inferiority trial enrolled 242 eyes of 201 patients who received femtosecond laser-assisted cataract surgery. The questionnaire study enrolled 26 medical interns and 39 medical students. Patients received surgery under either a three-dimensional visualization system (3D group, 117 eyes) or traditional microscope (TM group, 125 eyes) after random allocation. The primary outcome was surgical time. The non-inferiority margin of surgical time was 60 seconds. Secondary outcomes included ultrasound power, phacoemulsification time, visual acuity, intraocular pressure, endothelial cell density, central corneal thickness, complications, and observer satisfaction scores for surgical procedures.

**Results:** Surgical time was  $462.03 \pm 80.36$  seconds in the 3D group and  $452.13 \pm 76.63$  seconds in the TM group (difference 9.90 seconds, 95% CI, -9.98 to 29.78,  $p = 0.365$ ). Visual acuity and other perioperative parameters were comparable between the 3D group and the TM group (all  $p > 0.05$ ). Incidences of both intraoperative and postoperative complications were low and not statistically different between groups (all  $p > 0.05$ ). Across all observers, 3D surgery was superior to TM surgery for improving the degree of satisfaction (all  $p < 0.001$ ).

**Conclusion:** The surgical efficiency of heads-up cataract surgery is not inferior to traditional microscopic surgery. Both methods achieved similar efficacy and safety outcomes. Moreover, heads-up cataract surgery showed a significant advantage in medical education.

**P-013****The effect of pupillary dilation on IOL calculation in 70 phakic eyes measured by partial coherence interferometry**

K Cheng.

**Objective:** To determine the difference of IOL power calculation before and after pupil dilation in patients diagnosed with cataract measuring by partial coherence interferometry

**Methods:** This is a retrospective study of 70 phakic eyes diagnosed with cataract from 1<sup>st</sup> November 2020 to 1<sup>st</sup> March 2021 at Khmer-Soviet Friendship Hospital. Axial length (AL), Anterior Chamber Depth (ACD), Keratometry (K), Central Corneal Thickness (CCT), White to White distance (WTW) were measured by AL-Scan NIDEX prior to dilation the eyes. After the Pupil size (PS) > 6mm a second set of measurement was set to measure. The IOL power calculation formula: SRK/T and Barrett Universal II were set to calculate in the study before and after dilation.

**Results:** The ACD and CCT significantly changed from pre to post pupil dilation. In contrast, others parameters such as AL, K, WTW did not show to change in our study. Using SRK/T formula, IOL power did not change ( $p= 0.219$ ). However, using Barrett Universal II formula a significant change into high IOL power  $0.19 \pm 0.70$  D in post dilation measurement.

**Conclusion:** ACD and CCT significantly changed from pre to post dilation. This change result did not changed IOL power prediction using SRK/T a third generation formula. However, this result changed IOL power prediction based on Barrett Universal II, which calculates the effective lens position taking into account the ACD.

P-015

### Changes of corneal parameters in different areas after cataract surgery

L Mingming.

**Objective:** To compare the characteristics and differences in the Sagittal front power, True net power, Total corneal refractive power and Back-front corneal radius ratio after cataract surgery.

**Methods:** Prospective randomized clinical trial study. A total of 162 patients (162 eyes) in Weifang Eye Hospital from December 2020 to May 2021 were collected, including 86 males and 76 females (76 eyes) (age  $56.8 \pm 10.3$  years). The patients were underwent 2.2mm microincision cataract surgery. Anterior-posterior ratio of corneal curvature (B/F ratio), Sagittal front power (ASF), true net corneal refractive power (TNP), and total corneal refractive power (TCRP) on the corneal apex and pupil-centered 2mm, 4mm, and 6mm rings and regions were measured preoperatively and up to 3mo after surgery. The vectors were measured using Pentacam analyzer. The differences were compared using paired t-test and Kruskal-Wallis rank sum test for statistical analysis.

**Results:** Postoperative, there was no statistical difference in ASF values on and in the region of the 2mm radius ring centered on the corneal apex and centered on the pupil ( $P > 0.05$ ), whereas there was a statistical difference in ASF values on and in the region of the 4mm and 6mm radius rings compared with the preoperative period ( $P < 0.05$ ); The postoperative values on and in the region of the 2mm, 4mm, and 6mm radius rings centered on the corneal apex and centered on the pupil were statistically different ( $P < 0.05$ ). TNP and TCRP values on and within the 4mm and 6mm radius rings were statistically different compared to preoperatively ( $P < 0.05$ ). Preoperative, TCRP values were different between 2mm, 4mm, and 6mm on both corneal vertex and pupil-centered rings ( $p < 0.05$ ), while TCRP values were only different between 2mm and 6mm radius on corneal vertex-centered and pupil-centered regions ( $p < 0.05$ ). Postoperatively, TCRP values were different on corneal vertex-centered and pupil-centered rings between between 2mm and 6mm and between 4mm and 6mm ( $p < 0.05$ ). TCRP values within the corneal vertex-centered and pupil-centered regions differed only within a 2mm versus 6mm radius ( $p < 0.05$ ). Postoperative B/F ratio values were statistically different compared to preoperative values ( $p < 0.05$ ).

**Conclusion:** Corneal parameters such as corneal curvature values of different diameters of rings and areas centered on the pupil after cataract surgery may change and differ, which should be taken into account when selecting the K value for IOL calculation and individualizing the selection of IOLs based on corneal characteristics.

**P-016****Effect of blue light-filtering intraocular lenses on survival and risk of fall: A nationwide cohort study with 10-year follow-up**

J Lee<sup>1</sup>, P Li<sup>2</sup>, Y Hu<sup>3</sup>, L See<sup>2,4,5</sup>.

<sup>1</sup>Department of Ophthalmology, Chang Gung Memorial Hospital at Linkou, <sup>2</sup>Department of Public Health, School of Medicine, <sup>3</sup>Department of Occupational Therapy, School of Medicine, Chang Gung University, <sup>4</sup>Division of Rheumatology, Allergy, and Immunology, Chang Gung Memorial Hospital at Linkou, <sup>5</sup>Biostatistics Core Laboratory, Molecular Medicine Research Center, Chang Gung University, Taoyuan City, Taiwan, China

**Objective:** To compare the relative incidence of mortality and risk of fall in pseudophakes with blue light-filtering intraocular lenses (BF-IOLs) and non-BF-IOLs after cataract surgery.

**Methods:** This nationwide cohort study was conducted using data from the Taiwan National Health Insurance Research Database. We enrolled 49,481 patients who underwent cataract surgery in both eyes between 2008 and 2013 and followed them from the date of first cataract surgery until death, loss to follow-up, or December 31, 2018, whichever occurred first. Propensity score matching (PSM) was used to balance the baseline characteristics between the BF-IOL and non-BF-IOL groups.

**Results:** Overall, 25,656 (51.9%) and 23,825 (48.1%) patients had BF-IOL and non-BF-IOL implants, respectively; and after PSM, 21,874 patients in each group were compared. Within a mean follow-up period of 6.2 years (range: 1–10 years), 3,066 (19.87%) and 3,181 (20.65%) patients in the BF-IOL and non-BF-IOL groups died, respectively; and 188 (1.22%) and 212 (1.38%) patients in the BF-IOL and non-BF-IOL groups had events of fall, respectively. There were no significant differences in mortality and fall incidence rates (per 100 person-years) between the BF-IOL and non-BF-IOL groups.

**Conclusion:** In Taiwan, the use of a BF-IOL for up to 10 years had no apparent disadvantage over non-BF-IOLs with respect to fall and survival.

P-017

### m<sup>6</sup>A-induced lncRNA regulatory networks via downregulation of GPX4 triggers LECs ferroptosis in age-related cataract

P Li, S Bao, C Wang, S Wang, H Guan.

**Objective:** To explore the relationship between N<sup>6</sup>-methyladenosine (m<sup>6</sup>A) modification of long non-coding RNAs (lncRNAs) and ferroptosis in the lesion of lens epithelium cells (LECs) under the circumstances of age-related cataract (ARC).

**Methods:** LECs were collected from normal subjects and patients with cortical type of ARC (ARCC). M<sup>6</sup>A-tagged lncRNAs and lncRNAs expression were analyzed by m<sup>6</sup>A-modified RNA immunoprecipitation sequencing (m<sup>6</sup>A-RIP-seq) and RNA sequencing (RNA-seq). Gene Ontology (GO) annotation, Kyoto Encyclopedia of Genes and Genomes (KEGG) pathway enrichment analyses were used to predict possible functions of the m<sup>6</sup>A-lncRNAs. Then, we investigated the *cis* regulation mechanism of lncRNA to find corresponding target genes, which genes located within 10 kbp upstream or downstream of the lncRNAs were considered *cis*-regulated. Expression of m<sup>6</sup>A-lncRNA and glutathione peroxidase 4 (GPX4) was measured by quantitative RT-PCR. Expression of GPX4, a key component of ferroptosis, were determined by Western blot. Transmission electron microscopy (TEM) was used to assess the ultrastructure of ferroptosis in lens anterior capsule tissues.

**Results:** All 11193 m<sup>6</sup>A peaks within lncRNAs had different abundances with 7043 enriched and 4150 subdued. The level of m<sup>6</sup>A abundance in total lncRNAs was increased in the LECs from ARCCs in comparison with the controls. We also found that the expression of highly m<sup>6</sup>A-tagged lncRNAs was mostly decreased in comparison with non-m<sup>6</sup>A-tagged lncRNAs and the expressions of divergent m<sup>6</sup>A-lncRNA were different. The bioinformatics analysis predicted the potential functions of m<sup>6</sup>A modified lncRNAs and the relevant pathways that may be associated with m<sup>6</sup>A modified lncRNAs. Among this, lncRNA ENST00000586817 was significantly upregulated in LECs of ARCCs. The lncRNA is located 8561 bp upstream of the GPX4 gene. The *cis*-acting lncRNA ENST00000586817 may augment the expression of GPX4, akin to the function of enhancers. We also found that up-regulated m<sup>6</sup>A-lncRNAs (ENST00000586817) can regulate GPX4 expression in ferroptosis networks. In addition, TEM results indicated that mitochondrial changes increased in ARCC.

**Conclusion:** Our data provided novel evidence regarding the involvement of lncRNAs m<sup>6</sup>A modifications in ARC. The altered expression of m<sup>6</sup>A-lncRNA in LECs might induce the formation of ARC through down-regulating GPX4 that triggers ferroptosis. The results might provide a new insight in the molecular target of ARC pathogenesis.

P-018

**Chaperone-mediated autophagy regulates apoptosis in oxidative damaged lens epithelium cells**J Luo<sup>1</sup>, H Guan<sup>1</sup>.<sup>1</sup>Eye Institute, Affiliated Hospital of Nantong University, Nantong, People's Republic of China

**Objective:** Oxidative damage of lens epithelium cells (LECs) is a common accepted pathogenesis of age-related cataract (ARC). This research aimed to investigate the roles of chaperone mediated autophagy (CMA) in regulating lens epithelium cells (LECs) oxidative damage response.

**Methods:** We established a LECs oxidative damage model by 10min UVB irradiation on SRA01/04 (human lens epithelium cell line). The irradiated cells were analyzed 24 hours after irradiation. Expression level of LAMP2A and HSC70 (the key proteins in CMA process) were detected by western blot. The marks of apoptosis, including BAX and BCL-2, were also detected by western blot. We used *LAMP2A*-siRNA transfection to knock-down the LAMP2A expression, which resulted in inhabitation of CMA process. The knockdown efficiency was verified by qRT-PCR. And apoptosis of *LAMP2A*-knockdown SRA01/04 cells was analyzed by western blot and TUNEL assay. We also used CMA agonist (AR7), to activate CMA process in SRA01/04. The drug toxicity of different dosages (0  $\mu$  M, 20  $\mu$  M, 40  $\mu$  M, 80  $\mu$  M) was tested by CCK-8. And apoptosis of AR7-treated SRA01/04 cells was analyzed by western blot and TUNEL assay.

**Results:** The expression of LAMP2A and HSC70 was significantly decreased in UVB irradiated SRA01/04. The BAX/BCL-2 ratio was increased in UVB irradiated SRA01/04. The BAX/BCL-2 ratio was up-regulated in *LAMP2A*-siRNA group vs. NC-siRNA group. In addition, The BAX/BCL-2 ratio was also higher in *LAMP2A*-siRNA+UVB group vs. NC-siRNA+UVB group. The TUNEL assay showed more positive fluorescent signals in *LAMP2A*-siRNA+UVB group than NC-siRNA+UVB group. CCK-8 assay showed that cell viabilities were up-regulated with the increase of AR7 dose. Expression of LAMP2A and HSC70 was significantly up-regulated in AR7-treated LECs. The BAX/BCL-2 ratio was lower in AR7+UVB group vs. DMSO+UVB group. The TUNEL assay showed less positive fluorescent signals in AR7 +UVB group than DMSO+UVB group.

**Conclusion:** CMA was suppressed in oxidative damaged LECs. CMA could inhibit cell apoptosis of LECs in oxidative damage response. The results provided new insights into prevention and treatment of ARC.

P-019

### Performance of toric intraocular lens (IOL) in femtosecond laser-assisted cataract surgery

K Ma<sup>1</sup>, N Hung<sup>2</sup>, A Altansukh<sup>3</sup>, D Adiyabazar<sup>4</sup>, E Kang<sup>2</sup>, D Ma<sup>2</sup>.

<sup>1</sup>Department of Medicine, Catholic University of the Sacred Heart, Rome, Italy, <sup>2</sup>Department of Ophthalmology, Chang Gung Memorial Hospital, Linkou, Taoyuan, Taiwan, China, <sup>3</sup>Department of Ophthalmology, Health Center of Bayangol District, <sup>4</sup>Department of Ophthalmology, Gegeen Melmii Eye Hospital, Ulaanbaatar, Mongolia

**Objective:** With the accurate position and shape of capsulotomy created by femtosecond laser, femtosecond laser assisted cataract surgery (FLACS) has been proposed to achieve precise implantation of toric IOL. However, to date only few articles have reported the surgical outcome of toric IOL implantation in FLACS. Therefore, we aim to compare the accuracy and visual outcome following toric IOL implantation in FLACS and conventional phacoemulsification (phaco).

**Methods:** This is a single center, retrospective study. Patients who received FLACS (Alcon LenSx System) or phaco (Alcon Infiniti) and implantation of Alcon toric IOL (IQ Toric SN6ATx and IQ PanOptix Toric TFNTx0) from 2018 and 2021 were enrolled. The electronic medical records were reviewed, and following data were retrieved: 1. Pre-OP cylinder power as measured by IOLMaster 500 biometer on the same day of operation. 2. Proposed IOL axis calculated by Alcon online toric IOL calculator. 3. Measured IOL axis after pupil dilatation at post-OP 6 months (ranging from 3 to 12 months). 4. Cylinder value measured by autorefractometer. 5. Uncorrected distant VA (excluding eyes with vitreoretinal disorders or targeted refraction more than -1.0 D). Independent two-sample t-test was used for data comparison.

**Results:** 21 eyes from 19 patients receiving LenSx, and 36 eyes from 29 patients receiving phaco were recruited. The mean age was  $65.6 \pm 11.3$  vs  $61.0 \pm 15.6$  y/o ( $p=0.330$ ). The pre-OP cylinder value was  $2.04 \pm 0.99$  D in the LenSx group, and  $2.22 \pm 1.16$  D in the phaco group ( $p=0.737$ ). At post-OP 6 M, the mean IOL axis deviation was  $2.9 \pm 2.8$  degrees in the LenSx group, and  $4.3 \pm 4.5$  degrees in the phaco group ( $p=0.197$ ). The residual astigmatism at post-OP 6 M detected by autorefractometer was  $0.47 \pm 0.26$  D in the LenSx group, and  $0.66 \pm 0.36$  D in the phaco group ( $p=0.053$ ). Finally, the uncorrected distant logMAR vision was  $0.19 \pm 0.14$  in the LenSx group, and  $0.18 \pm 0.16$  in the phaco group ( $p=0.650$ ).

**Conclusion:** Although toric IOL implanted after LenSx showed tendency for less IOL deviation and less residual astigmatism, statistical significance was not reached due to limited case number and variation in the data. Furthermore, unaided distant vision in the two groups was essentially the same, suggesting that FLACS does not further promote visual performance in toric IOL implantation.



**P-020****changes of astigmatism of posterior corneal surface in different areas centered on corneal apex and pupil after cataract surgery**L Mingming.

**Objective:** To compare the differences in posterior surface astigmatism (PA) in different regional ranges centered on the corneal apex and pupil after cataract surgery.

**Methods:** Prospective randomized clinical trial study. A total of 162 patients (162 eyes) in Weifang Eye Hospital from December 2020 to May 2021 were collected. The patients were underwent 2.2mm microincision cataract surgery. Pentacam anterior segment biometry was performed during the follow-up time, and posterior surface astigmatism (flat, steep, and mean values) was collected before and after surgery with the corneal apex and with the pupil as the center of 2 mm, 4 mm, and 6 mm rings and areas, respectively. The data were divided into corneal vertex group and pupil center group by corneal vertex or pupil center. The astigmatism was decomposed into XY radii using the vector analysis method, and SIA was calculated. paired t-test was used to analyze the differences in PA on and in the area of different radii in the corneal vertex group and pupil center group before and after surgery and the changes in the axial position of posterior corneal surface astigmatism after surgery.

**Results:** There were differences in the posterior corneal surface astigmatism vector center of mass at different radii in the corneal vertex group before and after surgery measured in the circular and regional modes. The differences were statistically significant ( $P < 0.05$ ) between the preoperative corneal apex group and the pupil center group in the circular mode for 4 mmk1 values, 2 mm and 6 mmk2 values, and 2 mmkm and 6 mmkm values; and in the circular zone mode for 2 mm, 4 mm, and 6 mmkm values, and the differences were statistically significant ( $P < 0.05$ ) between the two groups; and in the postoperative corneal apex group and the pupil center group in the circular mode for 4 mmk1 values, and 2mm, 6mmk2 values, and 4mmkm values in both groups were statistically significant ( $P < 0.05$ ); 4mm, 6mmk1 values, 2mm, 4mm, 6mmk2 values, and 4mm, 6mmkm values in the circular zone mode in both groups were statistically significant.

**Conclusion:** The astigmatism of the posterior corneal surface after cataract surgery has some differences in different areas centered on the cornea tip and pupil, which has clinical value for evaluating the overall and regional changes of refraction of the posterior corneal surface after cataract surgery and for the selection of personalized intraocular lens.

**P-021****Evaluation of refractive and visual outcome in post myopic corneal laser refractive surgery patients with Trifocal IOL implantation**

X chen, J zhang.

**Objective:** To evaluate the refractive and visual outcome of cataract extraction surgery with Trifocal IOL implantation in Chinese patient eyes with previous myopic corneal laser vision correction

**Methods:** This retrospective case series included patients with previous myopic corneal laser vision correction who underwent phacoemulsification and trifocal IOL (AcrySof IQ PanOptix) implantation. Follow-up was done at 1-week, 1-month and 3-month to assess the visual outcomes. Outcome measures were uncorrected distance, intermediate and near visual acuity (UDVA, UIVA, UNVA), manifest refraction spherical equivalent (MRSE), predicted refractive error (PRE), Binocular defocus curve, and subjective quality of vision.

**Results:** Twenty-nine Eyes from seventeen patients were included, Mean age was  $54.68 \pm 5.47$  years, range 46 to 66 years, Mean Axial Length was  $26.95 \pm 2.69$  mm, range 23.09 to 34.65 mm, Mean Flat K was  $38.03 \pm 1.81$  D, Steep K was  $38.85 \pm 1.99$  D. Mean monocular UDVA, UIVA and UNVA (logMAR) at last visit were  $0.05 \pm 0.16$ ,  $0.02 \pm 0.10$ , and  $0.03 \pm 0.09$  respectively. 86.21%, 93.10% and 89.66% patients achieved 0.1 LogMAR (Snellen 20/25) for UDVA, UIVA and UNVA. Mean postoperative manifest refraction spherical equivalent (MRSE) at 3-month was  $0.34 \text{D} \pm 0.61 \text{D}$ , wherein, 19 eyes (65.52%) were within  $\pm 0.50 \text{D}$  of the desired emmetropia. The median absolute refractive predicted error at 3-month was 0.4D. Binocular defocus curve at 3-month showed best visual acuity ( $-0.02$  logMAR and  $0.20$  logMAR) with defocus of 0.00 D and  $-2.50$  D, simulating distances of 4 m and 33 cm. In the range between the peaks, the curve transited smoothly and reached the bottom as 0.15 logMAR at  $-1.50 \text{D}$ , sixteen patients (94%) did not need spectacles at all distances, while the other 1 patient (6%) used spectacles for near-distance related visual activity.

**Conclusion:** Trifocal IOL implantation after myopic corneal laser vision correction could restore good full range of vision and provide relatively accurate refractive outcomes as well as high spectacles independence rate.

**P-022****A Comparative Study on Endothelial Corneal Cell After Cataract Surgery Using Torsional vs Longitudinal Phacoemulsification**P Faranita.

**Objective:** Endothelial cells losses remain as undesirable side effect of cataract surgery. Torsional phacoemulsification offer less repulsion and heat energy than Longitudinal phacoemulsification. The purpose of this study was to compare endothelial corneal cell changes after cataract surgery performed with Torsional and Longitudinal phacoemulsification in patient with senile cataract.

**Methods:** In this prospective study, the patients were divided into two groups, 24 eyes had underwent cataract surgery using Torsional (OZil Infiniti Vision System, Alcon) and 23 eyes using Longitudinal phacoemulsification (Stellaris, Bausch & Lomb).

Preoperative, 1 day, and 1 week post-operative examinations on endothelial corneal cells were performed using specular microscopy. Cataracts were subdivided according to the LOCS III grading of nucleus. Intraoperative parameters using phacoemulsification time were evaluated.

**Results:** On the results of CCT at 1 day and 1 week post-operative, there were significant changes in group Torsional and Longitudinal  $601 \pm 68.67$ ;  $562.22 \pm 45.48$  ( $p=0.033$ ) and  $561,71 \pm 36,37$ ;  $519.52 \pm 79.93$  ( $p = 0.015$ ). However, there were no significant changes of CD, CV, HEX 1 day and 1 week post operatively between two groups. The phacoemulsification time was lower in group Torsional  $17.11 \pm 15.86$  seconds than group Longitudinal  $18.53 \pm 15.46$  seconds ( $p=0.595$ ) but not significantly different.

**Conclusion:** Torsional phacoemulsification outperforms the Longitudinal with a lower phacoemulsification time on soft and medium cataracts, but the differences were not significant. Torsional caused more corneal edema at 1 day and 1 week postoperative significantly and more endothelial cell losses but insignificantly.

**P-024****Femtosecond laser-assisted cataract surgery versus conventional phacoemulsification: comparison of internal aberrations and visual**Y Zhong.

**Objective:** To compare the internal aberrations and optical quality after femtosecond laser-assisted cataract surgery (FLACS) and conventional phacoemulsification cataract surgery (CPCS).

**Methods:** This study included patients who received FLACS or CPCS from January 2016 to July 2019. Postoperative examinations included wavefront measurements under pupil diameters of 3.0 mm and 5.0 mm, intraocular lens (IOL) decentration, visual acuity (VA), and refractive outcomes. Visual quality was measured with Strehl ratio and modulation transfer function (MTF). Subgroup analyses were conducted based on monofocal or multifocal-extended depth of focus (EDOF) IOL.

**Results:** The study consisted of 221 eyes (105 eyes in FLACS and 116 eyes in CPCS). With a pupil diameter of 5.0 mm, FLACS demonstrated a significantly lower root mean square of total internal aberration ( $P=0.004$ ), higher order aberrations (HOAs) ( $P = 0.034$ ), tilt ( $P = 0.049$ ), coma ( $P = 0.004$ ), and spherical aberration ( $P = 0.014$ ). IOL tilt was found to be positively correlated with total internal aberration ( $P < 0.001$ ), HOAs ( $P < 0.001$ ), and coma ( $P < 0.001$ ). The FLACS group presented significantly smaller IOL decentration than the CPCS group ( $P < 0.001$ ), but there were no significant differences in terms of VA and refractive outcomes between groups. In the multifocal-EDOF subgroup, Strehl ratio and MTF values were significantly higher in the femtosecond group with a 3.0-mm pupil.

**Conclusion:**

FLACS induced significantly lower values of IOL tilt, decentration, and internal aberrations compared with the CPCS group with a pupil diameter of 5.0 mm, while no significant differences were found in the VA or optical quality over long-term observation.

**P-025****Application value of optional parameters in Barrett Universal II IOL calculation formula**

Y Zhang<sup>1</sup>, J Liu<sup>1</sup>.

<sup>1</sup>cataract, Shanxi eye hospital, Taiyuan, People's Republic of China

**Objective:** To investigate the application value of Lens Thickness (LT) and White-to-White (WTW) when using the Barrett Universal II (BUII) formula.

**Methods:** Eligible 279 eyes (from 196 patients) who underwent cataract phacoemulsification in the Shanxi Eye Hospital from May to December 2020 were included, and OA-2000 optical biometric data were collected to help patients select MX60 IOLs. Using the BUII web formula, combinations of parameters were substituted into four groups: 1 omit LT+WTW(OWL), 2 omit WTW(OW), 3 omit LT(OL), 4 no omit(NO). Further stratification was done according to the eye axis length.

I. Theoretically: the predicted diopter of group NO was taken as the refractive outcome, and the predicted absolute prediction error (PAE) of other groups that ignored the parameters was calculated and compared.

II. Practically: the absolute prediction error (AE) was calculated when substituting some or all of the optional parameters based on the actual SE. The median absolute prediction error (MedAE), AE distribution, and AE optimum acquisition rate (cumulative accuracy & stability) were calculated and compared.

All statistical results were analyzed using SPSS software 25.0.  $P < 0.05$  was considered statistically different.

**Results:** I. Theoretically: PMedAE deviated 0.04-0.08D overall ( $P < 0.001$ ). In any combination, PMedAE deviated the least in the long AL subgroup (0.02D,  $P < 0.001$ ). PMedAE deviated the most in total or medium AL subgroup when both WTW and LT were ignored (0.08D, 0.09D,  $P < 0.001$ ).

II. Practically: the overall predictive accuracy of the BUII formula was high (80%  $AE \leq 0.50D$ ,  $P > 0.05$ ). MedAE did not differ statistically between the four combinations of parameters when overall or stratified (overall 0.23D). Within the error range of 0.25D- $>1D$  levels, there were no statistically significant differences in the distribution of cumulative AE frequencies between groups and within eye axis subgroups. The minimum value acquisition rate was the lowest in the total population OW group at 24.73% (69/279), and the rate was higher in the OL group than in the NO group, in the total population, medium and long eye axis subgroups (35.48%, 31.05%, 60.00%). The maximum value acquisition rate of OWL group and medium AL subgroup was the highest (40.50%, 39.27%).

**Conclusion:** The prediction level of the BUII formula with or without substitution of optional parameters was generally good, and the Omitting-LT calculation method can be used preferentially for eyes with  $AL \geq 22mm$ .

P-026

## Challenging Management for Spontaneous Single Piece Intraocular Lens In the bag Disinsertion – Unusual Cataract Surgery Complicati

C Valentina<sup>1</sup>, I Jayanegara<sup>2</sup>.

<sup>1</sup>Ophthalmology Residency, <sup>2</sup>Cataract and Refractive Surgery, Udayana University, Denpasar, Indonesia

**Objective:** to report management of a challenging case of spontaneous in the bag single piece IOL haptic dislocation.

**Methods:** We report a case of 60-years-old male who presented with chief complaints of double and decrease of vision in the RE with VA of 6/12. We examined dislocation of intraocular lens to anterior chamber after 3 years following uncomplicated phacoemulsification with foldable acrylate intraocular implantation and one week after ND Yag capsulotomy. Neither vitreous showed on anterior chamber, zonule weakness and nor posterior capsular rupture were noted. It was managed with intraocular lens reposition using polypropylene 10-0 suture to the iris.

**Results:** Intraocular lens haptics disinsertion to anterior was succesfully managed with effective and efficient method, which was in this case using iris suture technique. The patient complaints were improved with final VA of 6/6 in the RE.

**Conclusion:** In-the-bag intraocular lens disinsertion is a rare and surgeons have performed different techniques. Dislocation of intraocular lens to anterior can be managed effectively using iris suture technique and have good prognosis after reinsertion.

**Precise :** The technique that was used in this case does not require large corneal incisions, low postoperative cylindrical error, and lower complications rate compare to other methods in this case, and also doesn't require changing the intraocular lens, thereby it was chosen because of its effectiveness and efficient in managing such a complicated case.

**Background:** Intraocular lens disinsertion is a rare but potential as a late cataract surgery complication after 1.5 years of uneventful surgery. There are only few cases reporting spontaneous IOL disinsertion to anterior where its surgical treatment methods are still controversial.

**P-027****Clinical Observation of transscleral Suture Fixation of PCIOL Implantation Through Scleral Pockets with Intact Conjunctiva**S Ni.

**Objective:** To present the follow-up outcomes of a modified technique of transscleral suture fixation of posterior chamber intraocular lens (PCIOL) in eyes with inadequate capsule support.

**Methods:** A retrospective chart review of 21 patients underwent transscleral suture fixation of a foldable 3-looped haptics one-piece PCIOL implantation through scleral pockets was conducted. Preoperative data and follow-up data for at least 3 months were collected for all patients.

**Results:** The mean operative duration was  $36.62 \pm 10.70$  min. The mean pre- and post-operative LogMAR uncorrected distance visual acuity was ( $1.25 \pm 0.50$  vs.  $0.41 \pm 0.22$ ,  $P < 0.01$ ). The mean pre- and post-operative LogMAR best corrected visual acuity was ( $0.48 \pm 0.25$  vs.  $0.33 \pm 0.24$ ,  $P < 0.01$ ). The mean proportion of postoperative endothelial cell loss was  $11.46 \pm 4.78\%$ . The mean postoperative anterior chamber depth was  $3.05 \pm 0.44$  mm. The mean postoperative IOL tilt degree was  $2.81 \pm 1.41^\circ$ , and the mean postoperative IOL decentration degree was  $0.31 \pm 0.13$  mm. Four patients with transient corneal edema (19.0%) and three patients with transiently elevated IOP (14.3%) were observed after operation, and such complications were resolved within 1 week. No severe complications were observed.

**Conclusion:** The modified technique was a feasible method of PCIOL implantation.

P-028

**Outcomes of cataract surgery in 90-year-old or older patients.**O Bello<sup>1</sup>, E Ansari<sup>2</sup>.<sup>1</sup>Maidstone Hospital, Kent, United Kingdom, <sup>2</sup>Ophthalmology, Maidstone Hospital, Kent, United Kingdom

**Objective:** Advances in surgical techniques and increased life expectancy have made cataract surgery more common among very old patients. However, surgical outcomes in the over 90s in the literature are limited.

**Methods:** Single-centre, retrospective case-note study. 531 cases of cataract surgery performed in nonagenarians between 1/04/2015 and 19/12/2018, were included. Primary outcome measure was proportion of eyes achieving  $\geq 6/12$  best visual acuity (BVA); secondary outcome measures included intraoperative and postoperative complications and serious incidents. Demographic data including ocular and systemic comorbidities, surgeon rank and anaesthetic type are also described.

**Results:** The mean age (range) was 92 (90-100) years. Male to female ratio was 1:1.5. All Caucasian. Most common ocular comorbidities: AMD (17.1%), glaucoma (29.3%). Most frequent systemic comorbidities: arterial hypertension (12.8%) and diabetes mellitus (8.5%). Mean preoperative VA was  $0.32 \pm 0.17^*$  (n=368) and mean postoperative VA was  $0.5 \pm 0.25$  (n=299). 71% had improvement in visual acuity. 56% achieved best visual acuity (BVA) of  $\leq 6/12$ . In 4% (11/266) vision declined by two or more lines of Snellen acuity. Intraoperative complications: 1.33% (n=7), posterior capsule tear being the most common (n=2). Postoperative complications 3.2% with cystoid macular oedema (n=4) and transient diplopia (n=3) being the commonest. All surgeries performed under LA except for one case performed under GA. All cases of phacoemulsification. Consultants, registrars, junior trainees, and clinical fellows/SAS doctors conducted 67%, 6.5%, 6.5%, and 20% of cases, respectively.

**Conclusion:** Cataract surgery is generally safe and successful in very elderly patients and improves the BVA in the majority of cases. AMD and glaucoma limit the VA improvement in these patients.



P-031

### Visual Outcomes of Cataract Surgery at a Public Hospital in Guyana

N Ezinne<sup>1</sup>, C Ngwumezie<sup>2</sup>, K Ekemiri<sup>1</sup>, S Sugrim<sup>3</sup>.

<sup>1</sup>Optometry Unit, Department of Clinical Surgical Sciences, University of the West Indies, Saint Augustine Campus, Saint Augustine, Trinidad and Tobago, <sup>2</sup>Department of Optometry, University of Guyana, <sup>3</sup>Eye Department, , Georgetown Public Hospital Corporation, Georgetown, Guyana

**Objective:** To determine the visual outcome of patients who did cataract surgery at Georgetown Public Hospital Corporation (GPHC) Guyana

**Methods:** Medical records of patients  $\geq 40$  years who did cataract surgery at GPHC from January 2019 to December 2019 by a single surgeon were reviewed. Information about their demography, medical history, surgical history, ocular findings, post-operative complications, pre and post visual acuity (VA) were retrieved. Post operation visual acuity measured four weeks after surgery was used as the major outcome variable. Postoperative visual acuity of 6/18 or better was regarded as good visual acuity, 6/24 to 6/60 as borderline and less than 6/60 as poor visual acuity.

**Results:** Of the 100 patients with a mean age of 65.69 years that did cataract surgery, 66% were males and 34% were females. The major type of nucleus removal performed were Vectis (61%) and phacoemulsification (31%). Most (79%) of the operated eyes had good visual outcome ( $\geq 6/18$ ) after surgery, while 13% (13) and 8% (8) had borderline (6/24 to 6/60) and poor visual outcome ( $< 6/60$ ) respectively. Age was found to be significantly associated with post-surgery visual outcome ( $p = 0.001$ ). No significant association was found between gender, type of nucleus removal, complications, pre-existing ocular conditions and visual outcome ( $p = 0.46$ ).

**Conclusion:** Visual outcome of cataract surgery at GPHC was good and comparable to World Health Organization recommendation. Age was the major factor that influenced their visual outcome. Awareness of the importance of early screening for cataract in this community is highly recommended.

P-032

### Changes in intraocular pressure after cataract surgery depending on the Indicator of the Individual Norm

A Rafaelyan, N Yousef, E Kazaryan, N Shkolyarenko.

**Objective:** Literature data confirm the existence of different opinions about the nature of changes in intraocular pressure after cataract extraction. However, assessment of the risk factors significance for complications and prediction their occurrence in the postoperative period are still unresolved issues. Average statistical norm can still entail a persistent increase in IOP after cataract surgery. **Purpose:** to study the frequency of persistent increase in IOP after cataract surgery with a statistically normal level of IOP depending on the ratio of the preoperative level of IOP with its individual norm.

**Methods:** The clinical study was based on the analysis of 69 phacoemulsifications and posterior chamber intraocular lens implantations with a preoperative IOP level within the average statistical norm (IOP <22 mm Hg). The determination of individual norm of IOP was carried out using flowmetry according to the original method developed at the Research Institution of Eye Diseases. All patients were divided into 3 group. Group 1 — 25 patients with IOP less than individual norm of IOP. Group 2 — 18 patients (21 eyes) with medically compensated IOP (less than individual norm of IOP ). Group 3 — 20 patients (22 eyes) with IOP more than individual norm of IOP.

**Results:** GROUP 1. The initial IOP value before surgery in group 1 averaged  $15.7 \pm 3.6$ , after a year a decrease in IOP was recorded in 15 eyes (57.7 %). In 11 eyes (42.3 %) IOP remained unchanged. However, IOP changes in this group were statistically insignificant ( $p > 0.5$ ). GROUP 2. After a year decrease in IOP was recorded in 11 eyes (52.4 %). In 10 eyes (47.6 %) IOP remained unchanged. GROUP 3 The initial IOP level before surgery was on average  $17.9 \pm 1.4$ . One year later, a decrease in IOP was recorded in 6 eyes (40.9 %). In 8 eyes (22.7 %) IOP remained unchanged.

**Conclusion:** When planning cataract surgery the indicator of real compensation is the level of ophthalmotonus, which does not exceed the individual norm. IOP exceeding the individual norm indicates a high probability of a persistent increase in IOP after cataract surgery.

P-034

### Modified Technique for Retropupillary Iris Supported IOL in child with bilateral lens dislocation in the anterior chamber

H El-Nashar.

**Objective:** to show a rare type of ectopia lentis and how to manage it and to show a change in the original technique of retropupillary iris fixation iol that may be more safe especially in children

**Methods:** a child 4 years old referred to me because of poor vision . examination showed bil. anterior dislocation of crystalline lens into anterior chamber that causes bil. pupillary block with very high IOP and central faint corneal opacity due to corneal touch by the lens.no history of trauma. not associated with any systemic disease. ultrasound was free. i decided to lensectomy , anterior vitrectomy and iol implantation in both eyes in the same setting due to very high IOP. i had 3 options for iol implantation , yamane technique and iris claw iol either anterior or posterior approach and i decided to use retropupillary iris claw iol with the standered technique in one eye and modified technique in the other eye that while i fixate the haptics i perforate iris with one haptic so, the lens has one haptic on each side above iris (i think this be more safe in children especially with trauma as we have 2 haptics above iris prevent iol from dropping in vitreous)

**Results:** after 1 year , iol in place , rounded pupil with no iris atrophy ,the cornea get clear , iop normal and refraction of patient about -2.50 cylinder , both eyes are quiet

**Conclusion:** spontaneous bil anterior dislocation is a rare type of ectopia lentis. in some situations we are forced to do surgery in both eyes in the same setting as in this case due to high iop but we must take all precautions. i think the use of retropupillary iris fixation iol is the best choice to correct aphakia in children and the change i did in the technique will make the use of this iol more safe

**P-035****Unilateral Cataract and Retinitis Pigmentosa in a patient with the PHARC syndrome: a Case Report.**

M Hernandez, N Izquierdo, A Emanuelli.

**Objective:** Patients with mutations in *ABHD12* gene develop ocular complications including cataracts and RP, as part of the PHARC syndrome.

**Methods:** A chart review on a patient with a heterozygous mutation on the *ABHD12* gene, underwent comprehensive ophthalmic evaluation.

**Results:** Visual acuity was 20/20 and 20/400 on the OD and OS respectively. There was pseudophakia in the OS. Fundus examination in OD was normal. Left eye had pale optic nerve, attenuated vessels, cystoid macular edema, and mid-peripheral bony spicules. Visual field test showed a ring scotoma of the OS. Macular OCT and autofluorescence showed cystoid macular edema of the OS. ERG of left eye was flat. Patient's systemic findings included: polyneuropathy, and hearing loss.

**Conclusion:** Unilateral presentation of cataract and RP in a patient with a heterozygous pathogenic mutation on the *ABHD12* gene is rare. This could be due to mosaicism. Retinal follow up is warranted in these patients since manifestations may occur later in the contralateral eye.

A heterozygous pathogenic mutation on the *ABHD12* gene may lead to partial ocular and systemic manifestations of the PHARC syndrome.

**P-036****Applications of smart contact lenses in tear metabolite and intraocular pressure measurement and ocular drug delivery**J Zhang.

**Objective:** Human tears have a similar chemical composition to blood, containing proteins, lipids, electrolytes, urea, ascorbic acid, L-lactic acid, cholesterol, and other key metabolites. Corneal metabolomics has the potential to monitor systemic and ocular physiological changes and disease progression. This systematic review aims to examine research findings on the applications of smart contact lenses in the measurement of key tear metabolites and intraocular pressure and therapeutic drug delivery.

**Methods:** Comprehensive PubMed literature search, abstract screening, article review, and data extraction.

**Results:** Smart contact lenses show rapid detection of tear glucose changes associated with systemic glucose fluctuations with an appropriate calibration range (0.03–5.0 mM). Periodic monitoring, improved accuracy, and enhanced patient comfort are achieved. Lactic acid can be measured with embedded amperometric L-lactic acid sensors or lactate test strips with integrated tear sampling apparatus comprising Schirmer test papers. Sensors are resistant to interference by other acidic metabolites, such as uric acid and ascorbic acid. Two principal intraocular pressure measurement methodologies involve measuring corneal curvature changes and the deformation of the meridional angle of juncture between the cornea and sclera, leading to accurate and reliable intraocular pressure readings.

Embedded drug delivery systems can enhance treatment efficacy by overcoming non-compliance, increasing bioavailability, maintaining constant therapeutic ocular drug levels, and reducing systemic absorption. Smart contact lenses loaded with epidermal growth factors facilitate corneal epithelial wound healing. To achieve optimal drug loading, drug release behaviour and drug residence time, therapeutic contact lenses are mainly made by immersion and molecular imprinting. Drug release profiles can be assessed by self-reported colourimetric assays by combining molecularly imprinting with inverse opal structures. Silver nanoparticles and HTCC can enhance the antifungal and antimicrobial abilities of contact lenses. Antifungal contact lenses with embedded econazole-loaded PLGA film showed extended antifungal activity against *Candida albicans* and enhanced bioavailability.

**Conclusion:** Smart contact lenses can be employed to continuously monitor tear metabolite levels and intraocular pressure to reflect ocular and systemic physiological changes and provide sustained ocular drug delivery in ophthalmic diseases.

P-038

**Small-incision lenticule extraction and femtosecond-assisted laser in situ keratomileusis in patients with deep corneal opacity**Z Fang<sup>1</sup>, X He, W Han.<sup>1</sup>Eye Center, the Second Affiliated Hospital, Zhejiang University School of Medicine, Hangzhou, People's Republic of China

**Objective:** To report the safety, efficacy and accuracy of small-incision lenticule extraction (SMILE) or femtosecond-assisted laser in situ keratomileusis (FS-LASIK) for the correction of myopia or myopic astigmatism in patients with deep corneal opacity denoted by anterior segment optical coherence tomography(AS-OCT).

**Methods:** Four patients with single eye corneal opacity (3 due to mechanical injury, 1 due to firecracker wound) were recruited and treated with refractive surgery (3 for SMILE, 1 for FS-LASIK combined with limbal relaxing incision (LRI). Preoperative ocular manifestations, surgical details, postoperative visual outcomes, corneal opacity parameters, and corneal topography were analyzed.

**Results:** Preoperatively, spherical diopter ranged from -3.0D to -4.75D with cylinder ranging from -0.75 to -5.0D, and corrected distance visual acuity (CDVA) ranging from 20/25 to 20/20. One eye's corneal opacity was located in central zone and three were in mid-peripheral optical zone. Three patients underwent uneventful SMILE in both eyes, whilst one patient underwent FS-LASIK for high astigmatism in both eyes and LRI in the right eye. CDVA of eye with corneal opacity ranged from 20/22 to 20/20 one to six weeks postoperatively. Two patients achieved better CDVA and no patients lost Snellen lines. The postoperative diopter was within  $\pm 0.75$  D for all eyes. Significant flap edema existed above the corneal opacity in one eye and dissipated soon. No eccentric corneal topography or morphological anomaly of corneal cap was observed.

**Conclusion:** Our cases demonstrated that SMILE or FS-LASIK was safe and effective to treat myopic astigmatism combined with deep corneal opacity lesions after comprehensive preoperative evaluation and appropriate candidate selection. FS-LASIK combined with LRI was also sufficient for correcting high astigmatism due to corneal scarring.

P-039

**Magnification, Spectacles and Yellow Filter Lens in Low Vision with Steroid Induced Glaucoma: A Case Report**M Cicilia<sup>1</sup>, A Ismail<sup>1</sup>.<sup>1</sup>*Ophthalmology, Sriwijaya University, Dr. Mohammad Hoesin General Hospital, Kota Palembang, Indonesia*

**Objective:** To evaluate the efficacy of a low-vision aid that combines magnification, spectacles, and yellow filter lens in a case report of steroid induced glaucoma.

**Methods:** A 10 years old boy with history of using steroid eye drops due to vernal keratoconjunctivitis complained about blurred vision after using self prescription drugs for 13 months. In the ophthalmology clinic the doctor diagnosed the boy with steroid induced glaucoma and perform trabeculectomy on both of his eyes. We consider to add low-vision aids to improve his visual function even after medical treatment and surgery, because from standard refractive correction, patient who has a VA less than 6/18 to light perception or a visual field of less than 10 degrees from the point of fixation is considered to be people with low vision impairment.

**Results:** Refraction status before rehabilitation on this patient was identified as 4/60 on the right eye and 3/60 on the left eye. Best corrected visual acuity after spectacle prescription for the right eye was 6/15 using S -1.50 C -1.00  $\alpha$  120° and for the left eye was 5/60 using S -1.50 C -1.00  $\alpha$  60°. Near vision acuity in this patient was 20/150 (8D) using spectacles. To achieve better near vision acuity to 20/40 (4D) we need to add 2X Magnification. The contrast sensitivity using Pelly Robson chart were 1.35 for the right eye and 1.20 for the left eye, and from the both eyes was 1.35. The intraocular pressure on the both eyes with 2 glaucoma medications was 35.7 mmHg on the right eye and 26.3 mmHg on the left eye. Patient was diagnosed with low vision et causa steroid induced glaucoma with compound myopia astigmat on the both eyes. Patient was treated with adding Magnification, Spectacle, and Yellow Lens filter to improve the condition.

**Conclusion:** Low-vision aids using magnification, spectacles can allow patients to continue their daily living tasks. Yellow filter lens can increase contrast sensitivity in this patient. The accomplishment shows that the patient can do his daily tasks once more. Low-vision rehabilitation allows patients to increase their VA to read, write and perform other near detailed vision tasks. This is also a significance sign of improvement from his Low Vision Quality of Life (LVQOL) measurement during follow-up.

P-041

### The Contribution of Posterior Capsular Opacification to Ocular Residual Astigmatism: A Case Report

D Nindita<sup>1</sup>, A Ismail<sup>1</sup>, A Tribowo<sup>1</sup>, E Kumalasar<sup>2</sup>.

<sup>1</sup>Department Ophthalmology, Sriwijaya University, Mohammad Husein General Hospital, <sup>2</sup>Department Ophthalmology, Sriwijaya University, Kota Palembang, Indonesia

**Objective:** To report a patient posterior capsular opacification who evolved with less astigmatism after laser capsulotomy, emphasizing the importance of complementary therapy beside refractive correction.

**Methods:** a 39 years old male with posterior capsular opacification on the left eye was presented to the clinic with myopia astigmatism. The patient was identified for his refraction status before and after laser capsulotomy. Astigmatism was accounted separately for anterior cornea astigmatism and refractive astigmatism. Thibos vector analysis was used to calculate the distribution of ocular residual astigmatism (ORA) before and after laser capsulotomy.

**Results:** Refraction status before and after laser capsulotomy was obtained and being analysed using Thibos vector analysis to determine the contribution of posterior capsular opacity. Before laser capsulotomy, the refractive astigmatism was identified as C -2.50  $\alpha$  125° along with corneal astigmatism -2.00  $\alpha$  36° and after laser capsulotomy, the refractive astigmatism was identified S -2.25 C -0.50  $\alpha$  60° along with corneal astigmatism -2.00  $\alpha$  34°. The ORA before laser capsulotomy was 4.482 D axis 118,07° and after laser capsulotomy was 2.304 D axis 25,93°.

**Conclusion:** This report represent a patient with diminishing ocular residual astigmatism after laser capsulotomy. These finding suggest posterior capsular opacification contributed to ocular residual astigmatism as intraocular lens also become refractive media of eye. Refractive correction of astigmatism is not only limited to spectacles but also another treatment which can diminish astigmatism aberration. Knowledge about ocular residual astigmatism may help an ophthalmologist to make a better judgement of astigmatism therapy.



**P-042****Comparison of two artificial tear formulations for overnight orthokeratology contact lenses wearing**

Y Hsieh<sup>1</sup>, H Lin<sup>1</sup>, Y Tsai<sup>1</sup>, C Lin<sup>1</sup>.

<sup>1</sup>Eye Center, China Medical University Hospital, Taichung, Taiwan, China

**Objective:** To compare the differences between the use of low viscous solution and a higher viscous artificial tear to fill the lens during orthokeratology wear.

**Methods:** Preservative-free artificial tears with 0.9% NaCl (AIM Artificial Tears, Aimecine, Taiwan) and higher viscous preservative-free artificial tears with 0.4% polyethyleneglycol (Systane Ultra UD, Alcon, France) were used in the prospective randomized crossover study. Visual acuity (VA), Ocular Surface Disease Index (OSDI), corneal staining (NEI) score, tear film break-up time (TBUT) and topography for centration of orthokeratology lens were measured at baseline and after each of two 1-month treatment periods.

**Results:** There were 4 subjects (2 males and 2 females) with a mean age of  $9.75 \pm 0.96$  years (range 9-11) in the preliminary study. The average spherical equivalent (SE) was  $-2.86 \pm 1.03$ D (range -1.50 to -4.50D). Corneal staining was increased with 1-month using of low viscous artificial tears (NEI score  $1 \pm 2.14$  versus 0 with higher viscous artificial tears). A greater decreased OSDI score ( $6.77 \pm 6.88$  in higher viscous versus  $3.13 \pm 4.96$  in low viscous) and higher TBUT ( $3 \pm 4.34$  sec in higher viscous versus  $0.16 \pm 5.19$  sec in low viscous) were observed in higher viscous artificial tears group. Topography decentration distance from center was better with high viscous artificial tears ( $0.13 \pm 0.51$  mm in higher viscous group versus  $0.22 \pm 0.26$  mm in low viscous group). There was no obvious difference in VA with contact lenses wearing while using low and higher viscous artificial tears

**Conclusion:** Higher viscous artificial tears may show more benefits for overnight orthokeratology lenses wear, including better subjects comfort, better contact lenses centration, increasing TBUT and reducing corneal staining. Further study with larger group size is conducting.

P-043

**Diagnosis and Management of Pseudomyopia in Mohammad Hoesin Hospital Palembang: A Case Series**R Yunanda<sup>1</sup>, A Ismail<sup>1</sup>.<sup>1</sup>Ophthalmology, Sriwijaya University, Dr. Mohammad Hoesin General Hospital, Palembang, Indonesia

**Objective:** To Report the Diagnosis and Management of Pseudomyopia in Mohammad Hoesin Hospital that increased during the COVID-19 pandemic.

**Methods:** We report 3 cases of patients who came with blurred vision on both eyes. Ophthalmologic examination revealed that uncorrected visual acuity in case 1 was 6/21 for right eye and on left eye is 6/15, case 2 4/60 for right eye and 3/60 for the left eye, and case 3 was 6/40 for the right eye and 5/60 for the left eye. We do the Autorefractometry in both eyes with and without cycloplegic (cyclopentolate eye drops and, if required, atropine eye drops). Outcome measures were refractive error reduction or spherical equivalent refractive (SER) error  $\leq -0.50$  D before cycloplegia and  $> -0.50$  D after cycloplegia.

**Results:** Three patients, presented with complaints of sudden onset blurring of vision and asthenopic symptoms in two patients with history of aggravation of symptoms with prolonged near work (online school) because of pandemic conditions. Refraction was initially showing myopic refractive error. After cycloplegia, there was hypermetropic shift and VA was 6/9 for distance in one patient with his hyperopic correction. In two patients there was myopic shift from high myopia into moderate myopia. The diagnosis of pseudomyopia was made. Glasses were prescribed with avoidance of aggravating factors was started. Patients were observed for a months in which none had recurrence. Post cycloplegia, the condition resolved and asthenopic symptoms were improved.

**Conclusion:** Pseudomyopia refers to a phenomenon due to accommodation, especially in young children. It is causing apparent myopic error and disappear after cycloplegia, that is why cycloplegic refraction is important in examination especially in young children. Treatment of pseudomyopia depends on the underlying etiology.

P-077

**Awareness toward keratoconus and its relation with eye rubbing: A cross-sectional study in Madina**E Kordi<sup>1</sup>, E Alshareef<sup>2</sup>, A Almokhtar<sup>2</sup>, A Alkayyal<sup>2</sup>, J Alharbi<sup>2</sup>, A Alharbi<sup>3</sup>.<sup>1</sup>Ophthalmology , Ohud hospital , <sup>2</sup>Medicine and Surgery, Taibah University , Medina, <sup>3</sup>Vision college of medicine , Vision colleges , Riyadh , Saudi Arabia**Objective:** This study aims to assess the awareness of the population in Madina toward Keratoconus and its relation to eye rubbing.**Methods:** A cross-sectional study enrolled 767 participants via an online pre-designed questionnaire from November 2021 to January 2022, in Medina, Saudi Arabia.**Results:** Among the study participants, 94.1% have a lack of awareness. On the other hand, having visual problems and positive family history of keratoconus was significantly associated with good awareness levels. 39.8% of the participants had heard about keratoconus, and having a relative with keratoconus was the most common source of their information. 34.9% of the participants report having an allergic reaction, and 7.7% have a family history of keratoconus. Only 27.8% believe in the relationship between keratoconus and allergy, and 61.9% have no idea about the treatment. For eye rubbing, 28.9% of participants believe it can lead to keratoconus, and 80.4% reported rubbing their eyes with itching being the most common cause.**Conclusion:** The majority of the participants have a lack of awareness about keratoconus and its relation to eye rubbing. Moreover, itching sensation could be considered as a risk factor for keratoconus. Health education programs for the population should be conducted to enhance the public awareness about keratoconus.

**P-044****YOU GOT BURNED!**A Desai.

**Objective:** Reporting a case of acute alkali injury to bring attention to the need of immediate intervention.

**Methods:** A 26-year-old male presented to the emergency department with a history of exposure to ammonia in both eyes while working in a chemical laboratory. Patient had burning sensation in both eyes and throat with diffuse bilateral periocular edema, superficial burns on lid margins of both eyes and difficulty breathing. Ocular examination showed eyelid chemosis, conjunctival chemosis and near total corneal epithelial defect in both eyes. Initial treatment with topical therapy was initiated. In view of persistent corneal epithelial defects, bilateral amniotic membrane transplant was done. In the post-operative period, bilateral acute ischemia was observed so we went ahead with a bilateral tenonplasty procedure.

**Results:** Postoperative follow up was uneventful and sequential opening of tarsorrhaphy was done. At 3 months follow-up, right eye has a persistent epithelial defect of 2\*2 mm in size, while left eye cornea has healed completely. Both eye endothelium has pigment dispersion and lens is showing signs of cataractous changes. Subsequent surgeries will be needed for visual recovery.

**Conclusion:** Because chemical burns from alkali agents can cause liquefaction necrosis with deep tissue injury, it becomes essential to develop a rapid treatment plan.

**P-045****Indication, graft viability, visual acuity and complications in patients undergoing penetrating keratoplasty (PKP)**

S Lotfi Sadigh<sup>1</sup>, O Dikmetas<sup>1</sup>, M Algedik<sup>1</sup>, A Çankaya<sup>1</sup>, S Kocabeyoğlu<sup>1</sup>.

<sup>1</sup>Ophthalmology, Hacettepe university, Ankara, Türkiye

**Objective:** To compare indication, graft viability, visual acuity and complications in patients undergoing penetrating keratoplasty (PKP)

**Methods:** The medical records of patients who underwent PKP between 2016-2021 were evaluated retrospectively. Patients with less than 6 months of follow-up were excluded. Surgical indication, allograft reaction, graft transparency, post-operative visual acuity and long-term complications were assessed.

**Results:** PKP was applied to 65 eyes of 65 patients (33 males, 32 females). The mean follow-up period was  $30.67 \pm 12.16$  (12-60) months. The mean age was 56.62 years. Indications are included: keratoconus (36.92%), trauma (20%), aphakic and pseudo-phakic bullous keratopathy (18.46%), viral keratitis (10.76%), corneal dystrophy and degeneration (% 10.76), vascularized leukoma (3.07%). Long term complications were as mentioned below: graft failure (29.16%), graft rejection (16.66%), cataract (16.66%), glaucoma (16.66%), suture complications (12.5%), graft keratitis (8.33%). Visual acuity of 0.2 and above was obtained in 26 (40%) eyes.

**Conclusion:** Visual acuity increased in most of the cases. In our clinic, the leading indication in a 5-year period is keratoconus. Penetrating keratoplasty is an effective and safe treatment method in selected corneal diseases.

P-048

### Minimally Invasive Corneal Neurotization for Neurotrophic Keratopathy: Clinical Outcomes at Stein Eye Institute from 2018 to 2021

T Chen<sup>1</sup>, K Roelofs<sup>2</sup>, D Rootman<sup>2</sup>, S Fung<sup>3</sup>.

<sup>1</sup>UCLA, Los Angeles, United States, <sup>2</sup>Orbital and Ophthalmic Plastic Surgery, <sup>3</sup>Cornea and External Diseases, UCLA, Los Angeles, United States

**Objective:** To report clinical outcomes in patients with neurotrophic keratopathy (NK) treated with minimally invasive corneal neurotization (MICN) performed by the oculoplastics team, who harvests the sural nerve graft and creates the brow tunnel with donor nerves on the face, and the cornea team, who performs the neurotization.

**Methods:** Patients who underwent MICN at Jules Stein Eye Institute from 2018 to 2021 were retrospectively included. Data on best-corrected visual acuity (BCVA), central corneal sensation and peripheral corneal sensation (CCS and PCS, measured with Cochet-Bonnet esthesiometer), and corneal epithelial integrity (presence of staining and epithelial defects) were collected. Parametric data was assessed with t-test and non-parametric data was assessed with Wilcoxon signed-rank test.

**Results:** Between August 2018 and June 2021, 8 eyes of 8 patients underwent MICN. The mean age of the patients was  $50.1 \pm 19.3$  years old and half of the patients were male. Causes of the NK included radiation, stroke/intracranial hemorrhage, and trigeminal nerve trauma. Mean duration of NK until surgery was  $5.1 \pm 8.7$  years and the majority of patients (7/8, 87.5%) had concurrent facial nerve palsy. Mean follow-up was  $16.5 \pm 10.9$  months (range 6-36 months). Two patients died (one from a brain tumor after post-op month 6 and one from heart failure after post-op month 18). One patient was lost to follow up after 6 months. Mean CCS significantly improved from 0 (range 0-0mm) to  $20.7 \pm 27.1$  (range 0-60mm) at the latest follow-up visit ( $p = 0.011$ ). Mean BCVA (logMAR) remained stable (pre op  $1.86 \pm 1.01$  versus post-op at latest visit  $1.46 \pm 0.79$ ;  $p = 0.517$ ). The number of patients with epithelial defects decreased from 6/8 (75%) to 2/8 (25%) and the number of corneal epithelial defects after MICN was reduced from  $2.13 \pm 3.27$  to  $0.63 \pm 1.41$  ( $p = 0.0894$ ). There were few expected side effects from surgery: two patients experienced numbness on the contralateral forehead and one experienced numbness around the right lateral dorsal foot that improved within one month.

**Conclusion:** MICN improves corneal sensation and stabilizes corneal epithelium. It is useful even years later after diagnosis of NK and in presence of concurrent facial nerve palsy.

P-049

**A Bacteriostatic Peptide for the treatment of Pseudomonas Keratitis by Host Defence**Y Qiao<sup>1</sup>, M Zhou<sup>1</sup>, K Yao<sup>1</sup>.<sup>1</sup>Eye Center, Second Affiliated Hospital of Zhejiang University School of Medicine, Hangzhou, People's Republic of China

**Objective:** Keratitis caused by the opportunistic pathogen *Pseudomonas aeruginosa* is a usual clinical type of microbial keratitis, and antibiotics are difficult to cure. This bacterial community can cause by biofilm formation, and it exhibits resistance to antibiotics.

**Methods:** Host defence peptide which was mimetic antimicrobial poly- $\beta$ -peptides was prepared, tested, and appraised for the treatment of *Pseudomonas aeruginosa* infectious keratitis. The structure of molecular, release curve and storage stability was evaluated. In vitro, the antimicrobial consequence of *P. aeruginosa* was evaluated by opacity, unit counting, fluorescent staining, scanning electron microscope, and transmission electron microscope. Biofilm disruption was assessed by fluorescence confocal microscope and in vitro scanning electron microscopy. The therapeutic result of the mice *Pseudomonas* keratitis model was evaluated by clinical scoring. The potential mechanisms were distinguished by histologic paraffin sections, IHC and WB. In vivo toxicity was observed by tissue sections of major organs and hematological tests.

**Results:** Owing to the membrane-active antibacterial mechanism, this poly- $\beta$ -peptide in this study exhibits strong and broad-spectrum antimicrobial activity versus MDR bacteria with inconspicuous toxicity to mammalian cells. In addition, the poly- $\beta$ -peptides have bactericidal properties and are highly effective in bactericidal consequences. In addition, these host defence peptide can prohibit biofilms proliferation and floating bacteria multiplication. By *Pseudomonas aeruginosa*-infected mouse keratitis model, topical administration of host defence peptide eradicated this ocular surface infection compared with levofloxacin and tobramycin.

**Conclusion:** In conclusion, host defence peptide is a novel antimicrobial for *Pseudomonas aeruginosa* infectious keratitis with biosafety biosafety.

**P-050****Transient Alteration of Retinal Microvasculature after Laser assisted in situ keratomileusis**M Tsai<sup>1</sup>.<sup>1</sup>*Ophthalmology, Show-Chwan Memorial Hospital, Changhua, Taiwan, China*

**Objective:** Laser assisted in situ keratomileusis (LASIK) is one of the most commonly performed refractive surgery worldwide. In our study, we used optical coherence tomography angiography (OCTA) to analyze the retinal microvasculature and quantified the change of vascular density of retina after operation.

**Methods:** Twenty eyes of 10 patients who undertook LASIK were investigated by using OCTA three times respectively (preoperation, 3 post-operation-days, 14 post-operation-days). OCTA was performed by AngioVue OCTA, Optovue, CA, USA, and LASIK was performed by Visx CustomVue Star S4 excimer laser system. Cornea flap was done with sterile blade. Suction pressure and suction time was also analyzed respectively. Vessel density (VD) and foveal avascular zone (FAZ) were analyzed each time. Qualified data was processed with Python 3.8.5, mainly using sklearn 0.23.2. All data were normal distributed confirmed by a Kolmogorov-Smirnoff test. Measurements before and after surgery were compared by using the Mann-Whitney U test.  $P < 0.05$  was considered statistically significant.

**Results:** 10 subjects, who were undertaken LASIK with both eyes, were included in the present study. The suction time were ranged from 22 seconds to 25 seconds, and the suction pressure were ranged from 171mmhg to 175mmhg. The pre-operation spherical equivalent of the participants were  $-6.44 \pm 2.12$  D. We found the VD of whole macular image in the superficial capillary plexuses (SCP) decreased significantly on the 14 post-operation-days ( $P=0.005$ ), and VD of disc also decreased significantly both in the capillary and whole vessel on the 14-post-operation-days ( $P=0.035$  in capillary,  $P=0.03$  in whole vessel). On the contrary, the VD of the deep capillary plexuses (DCP) increased slightly after operation ( $P=0.103$ ). The VD of foveal region decreased slightly both in the superficial and deep layers. The foveal avascular zone (FAZ) slightly enlarged after operation ( $P=0.382$ ).

**Conclusion:** In conclusion, retinal microvascular density at the SCP and the disc region decreased significantly after 14 post-operation-days. However, the long-term impact on vessel density after operation still need further evaluation.



P-051

**Antimicrobial effect of PACK-CVX in models of fungal keratitis caused by *Candida albicans* and *Fusarium* spp.**L Troichenko, G Drozhzhyna<sup>1</sup>.<sup>1</sup>cornea, The Filatov Institute of eye diseases and tissue therapy, Odessa, Odessa, Ukraine

**Objective:** Fungal keratitis (FK) remains a severe cause of visual impairment and blindness, and case management is difficult due to ocular intrinsic barriers and drug shortages. The novel methods of treatment FK should be designed to allow for fast and comprehensive microbicidal and microbostatic response on their target with minimum toxic effect to the body. The purpose of our study was to evaluate the antimicrobial effect of PACK-CVX using a photosensitizer 0,1% riboflavin in the models of FK caused by *Candida albicans* (CA) and *Fusarium* spp.(FS)

**Methods:** The experimental study was performed on 20 eyes of 10 chincilla rabbits. We used the model of FK of Zborovska(2012). Yeast culture of CA was used on 10 eyes and culture of FS - on 10 eyes. In the control groups (5 paired each eyes) anti-fungal treatment was used. The 4 times/day instillations of fluconazole in the model of CA and voriconazole in the model of FS were performed in all eyes according to sensitivity of microflora. The PACK-CVX using a photosensitizer 0,1% riboflavin was additionally performed in the main groups of 5 eyes.

**Results:** Moderate keratitis was 70% in the CA model and 50% in the FS model, severe keratitis - in 30% in the CA keratitis and 50% in FS model for 10-13 days. Epithelialization achieved on a model of CA moderate keratitis main group on day  $7 \pm 1,22SD$ ; control - 4,4 days later ( $11,4 \pm 1,14SD$ )  $p=0,005$ . Epithelialization of severe model CA keratitis main group - on day  $21,8 \pm 4,9SD$ ; control - 1,6 days later ( $23,4 \pm 5,27SD$ )  $p=0,002$ . The epithelialization on the FS model moderate keratitis main group was achieved on day  $12,2 \pm 2,28$ ; control group - 4 days later ( $16,2 \pm 1,64$ )  $p=0,04$ . Time of epithelialization in FS severe model had no difference between main ( $18,8 \pm 1,64SD$ ) and control ( $19,2 \pm 11,12SD$ ) groups. In all cases the fungal flora was not detected in microbiological studies after the treatment (except for 1 case FS severe control group when the epithelialization was not achieved)

**Conclusion:** Fungal keratitis is caused by FS was more severe (50%) than keratitis caused by CA (30%). In models of FK using CA and FS showed a positive antimicrobial effect of PACK-CVX using a photosensitizer of 0.1% riboflavin, which is confirmed by absence of fungal flora in microbiological studies and achievement of corneal epithelialization 4.4 days earlier CA moderate keratitis main group; 1,6 days earlier CA severe keratitis main group; 4 days earlier FS moderate main group, and had no difference between main and control groups in FS severe model.

P-052

**Comparative Evaluation of Autologous Serum and Artificial Tears in Persistent Epithelial Defects**G Singh<sup>1</sup>, P Golhait<sup>1</sup>, J Goyal.<sup>1</sup>Maulana Azad Medical College, New Delhi, India

**Objective:** To compare the outcomes of autologous serum 50% eyedrops and artificial tears in persistent corneal epithelial defects (PEDs) more than two weeks duration.

**Methods:** Prospective comparative study was conducted wherein 32 eyes with PEDs were randomly divided into two equal groups. Group A received autologous serum 50% eyedrops and group B received artificial tears for minimum 4 weeks. Patients were evaluated for change in BCVA, size of defect, depth of defect on AS-OCT, corneal sensations, number of days required for complete healing, improvement in subjective symptoms. Success was defined as complete epithelialization of the defect while failure was defined as no objective improvement or worsening of lesion or need for surgical intervention.

**Results:** The success rate of group A by the end of 4 weeks was 81.25% and group B 37.5%. The days required in complete healing were significantly lesser in group A compared to group B (p-value=0.015) with significant improvement in BCVA (p-value=0.029) and earlier resolution of subjective symptoms.

**Conclusion:** Though the eventual outcome was comparable, artificial tears had a significantly longer and static course of recovery compared to autologous serum. Thus autologous serum should be considered as an adjuvant in the treatment of PEDs with earlier initiation of therapy for early recovery and resolution.

P-053

**A Case report of 3 Corneal Dystrophies in Same Eye**S Koya<sup>1</sup>, S Potti<sup>1</sup>, K Shah<sup>1</sup>.<sup>1</sup>Cornea ,Anterior segment, & Phacorefractive, Sankara eye hospital, Guntur, India

**Objective:** To report a rare case with bilateral presentation of three corneal dystrophies in same eye of a middle aged female.

**Methods:** Here we are reporting a case of 46 year old female presented with decreased vision in both eyes since 2 years. There was no history of trauma and no systemic illness.

On examination her best corrected visual acuity was 6/18 in OD, 6/36 in OS.

ON SLIT LAMP EXAMINATION : OU-Multiple bread crumbs like opacities at anterior stromal level were found, with intervening stroma showing multiple translucent lines in lacy pattern and at endothelial level multiple guttae were found, lens OU was NS grade1-2.

On AS-OCT: OU-homogenous hyper-reflective deposition at stromal level and hyper reflective descement's membrane with endothelial bleb was found suggestive of early guttae formation.

Specular microscopy didn't give clear images because of stromal opacities.

**Results:** The case was diagnosed as **Avellino's dystrophy(Granular+ Lattice) with Fuch's endothelial corneal dystrophy** based on clinical findings and supportive investigations. Patient was advised Triple procedure (Penetrating keratoplasty+ cataract surgery) in left eye.Patient was counselled about further deterioration of vision in right eye due to progressive nature of disease, and about need for optical penetrating keratoplasty, as lamellar keratoplasty couldn't be performed due to involvement of both stromal and endothelial layers.

**Conclusion:** We are reporting this case, as Avellino's dystrophy is a rare dystrophy with incidence of 8/10,000 individuals , and only Two families with familial inheritance were reported from India. Further presence of Fuch's dystrophy with Avellino's dystrophy is not reported in literature in our literature search from major peer reviewed journals.

P-054

### Tear Function in Patients with Diabetes Mellitus: A Systematic Review and Meta-analysis

Y Kuo<sup>1</sup>, S Shao<sup>2</sup>, E Lin<sup>3</sup>, L Pan<sup>4</sup>, L Yeung<sup>1</sup>, C Sun.

<sup>1</sup>Ophthalmology, <sup>2</sup>Pharmacy, Chang Gung Memorial Hospital, Keelung, Keelung, <sup>3</sup>College of Medicine, Chang Gung University, <sup>4</sup>Ophthalmology, Chang Gung Memorial Hospital, Linkou, Linkou, Taiwan, China

**Objective:** To systematically examine tear function in patients with diabetes mellitus (DM).

**Methods:** We searched Embase and PubMed from database inception to March 16, 2022. We included observational studies that compared tear function between patients with and without DM. Tear function was measured using invasive tear breakup time (ITBUT) and Schirmer's 1 test. Pooled results are presented as standard mean difference (SMD) with 95% confidence interval (CI), based on random-effects models.

**Results:** We included 59 studies (7,234 eyes) from 19 countries comparing the tear function between patients with and without DM. This meta-analysis indicated that patients with DM had worse tear function than those without DM (ITBUT: SMD -0.98, 95% CI -1.27 to -0.69; Schirmer's 1 test: SMD -0.45, 95% CI -0.64 to -0.26), and the results remained consistent in patients with different types of DM (e.g., type 1 DM and type 2 DM) and from different ethnic backgrounds (e.g., Asian vs. non-Asian). Patients with DM with poor glycemic control had worse tear function than those of the non-DM group (ITBUT: SMD -1.26, 95% CI -1.86--0.66; Schirmer's 1 test: SMD -0.25, 95% CI -0.48 to -0.02), while there were no significant differences in tear function between patients with DM with optimal glycemic control and non-DM groups.

**Conclusion:** We found that patients with type 1 or type 2 DM had significantly reduced tear function. The level of tear function could be determined by glycemic control, and therefore our findings suggest that glycemic control in patients with DM is critical for maintaining tear function.

P-055

**Ferrostatin-1-loaded Liposome for Treatment of Corneal Alkali Burn via Targeting Ferroptosis**K Wang<sup>1</sup>, K Yao<sup>1</sup>.

<sup>1</sup>Eye Center of the Second Affiliated Hospital, School of Medicine, Zhejiang University, Hangzhou, People's Republic of China

**Objective:** To determine whether lipid peroxidation-dependent ferroptosis occurs in the pathogenesis of alkali burn-induced corneal injury and to compare therapeutic effects of free ferrostatin-1 (Fer-1) and Fer-1-loaded liposome (Fer-1-NPs).

**Methods:** The therapeutic effects were determined in the alkali-burned mice by slit-lamp observation of corneal opacity and neovascularization, as well as the histological examination. In addition, the expression of the factors associated with ferroptosis, inflammation, and neovascularization were assessed by RT-PCR and immunofluorescent staining.

**Results:** Fer-1 attenuated the alkali burn-induced injury and rescued the dysregulation expression of Ptgs2 and 4-HNE, suggesting that ferroptosis mediated alkali burn-induced corneal injury. Moreover, Fer-1-NPs exerted remarkable curative effects regarding corneal opacity and neovascularization in vivo. The efficacy was comparable to that of dexamethasone, but without appreciable side effects. The significant suppression of ferroptosis (induced by lipid peroxidation and mitochondria disruption), inhibition of inflammation, and neovascularization might be the mechanisms underlying the therapeutic effect of Fer-1-NPs.

**Conclusion:** Fer-1-NPs provide a new prospect for safe and effective therapy for corneal alkali burn.

P-056

**Arc Of Plasma Used As A Booster In Corneal Collagen Crosslinking**

L Garduño Vieyra<sup>1</sup>, O Hernández Zepeda<sup>2</sup>, C López Camacho<sup>3</sup>, J Vázquez Solís<sup>3</sup>.

<sup>1</sup>Oftalmología Garduño. Escuela de Medicina Universidad Quetzalcóatl, Irapuato, Guanajuato., <sup>2</sup>CINVESTAV Escuela de Medicina Universidad Quetzalcóatl, Irapuato, Guanajuato, <sup>3</sup>Escuela de Medicina Universidad Quetzalcóatl, Irapuato, Guanajuato., Mexico

**Objective:** To evaluate the efficacy of the combined treatment of Crosslinking and plasma for the reinforcement of corneal collagen fibers.

**Methods:** A comparative study was done on 20 pigs' eyes (Large white). The rules of the Helsinki protocol on animal studies were respected. They were divided into 3 groups. At the beginning of the study, all eyes had a corneal tomography to measure corneal thickness. The cornea of each eye was marked by the middle to treat only 50 % and the other 50% acted as a control. In the first group was applied crosslinking, in the second group with plasma, and a combination of plasma plus crosslinking in the third group. After treatments, all eyes had a new tomography and was measured the corneal thickness and the depth of treatment. Afterward, the pieces (eyes) were immediately fixed in 10% formaldehyde and the histopathological study of the samples of each group was carried out by a pathologist who interpreted the changes and differences that occurred.

**Results:** The mean depth of treatment in group 1 (crosslinking) was 328.90  $\mu$  m, in group 2 (arc of plasma) of 537.64  $\mu$  m, and group 3 (arc of plasma plus crosslinking) of 741.27  $\mu$  m. In the comparison of the combined treatment versus Crosslinking, a  $p=0.00456$  was obtained. Combined treatment versus controls of  $p=0.00588$ .

**Conclusion:** The efficacy of the combined treatment of plasma and Crosslinking was demonstrated. It was possible to obtain better penetration of the treatment without endothelial damage. This constitutes a step forward in the treatment of corneal ectasias.

P-057

**Znf469 deficiency leads to abnormalities of ECM component in cornea stroma: A zebrafish model of keratoconus**

J Bao, X Yu<sup>1</sup>, X Shentu<sup>1</sup>, J Zou<sup>2</sup>.

<sup>1</sup>Ophthalmology, The Second Affiliated Hospital, Zhejiang University School of Medicine, <sup>2</sup>The Institute of Translational Medicine, Hangzhou, People's Republic of China

**Objective:** In recent years, the mutation of *ZNF469* is considered to be one of the pathogenesis of keratoconus. We establish a *znf469* mutant zebrafish line to elucidate the possible molecular mechanism of *znf469*.

**Methods:** We generated the *znf469* mutant zebrafish by using the CRISPR/Cas9 system. TEM is applied to examine the phenotype of the cornea in different development stage. RNA sequencing and quantitative RT-PCR are used to reveal the molecular mechanism.

**Results:** Macroscopically, the homozygous *znf469-4del* zebrafish larva exhibited a curved body from 72 hpf similar to kyphoscoliosis and a noninflated swimbladder at 7 dpf. TEM reveals the extreme reduction of corneal stroma in homozygous *znf469-4del* zebrafish in both central and peripheral cornea. RNA-seq analysis demonstrates that the *znf469* mutation leads to the decreased synthesis of various ECM component like collagens and proteoglycans but increased synthesis of 26S proteasome families.

**Conclusion:** Our work indicates that *znf469* is an critical gene that encoding a transcription factor, regulating the synthesis and degradation of a large number of ECM components which is also the pathologic basis of the ocular and extraocular phenotypes in the *znf469* mutant zebrafish model.

P-058

**Overexpression of PAX6 gene inhibits cell migration in corneal epithelial cells**H Chien<sup>1</sup>, Y Shen<sup>1</sup>.<sup>1</sup>*Ophthalmology, Taichung Veterans General Hospital, Taichung, Taiwan, China*

**Objective:** PAX6 gene is called the master regulator of eye development. Aniridia, Axenfeld-Rieger syndrome and limbal stem cell deficiency are associated with PAX6 mutation. Animal studies showed similar phenotypes in overexpression and haploinsufficiency of PAX6 gene. It expresses in adult cornea and upregulates in corneal epithelial defects. The purpose of this study was to report the role of PAX6 gene in maintaining homeostasis of corneal epithelium.

**Methods:** We transfected two plasmid complementary DNA, including pBI-EGFP-PAX6 and tetracycline inducible Tet-On system into statens seruminstitut rabbit cornea (SIRC) cells, a cell line of rabbit corneal epithelium. PAX6 was overexpressed by 1ug/ml doxycycline addition (PAX6+dox and PAX6-dox group). Tet-On-transfected SIRC cells were cultured in the medium with doxycycline addition (Tet-On+dox group) for 3 days and served as a control group for doxycycline effect. PAX6 was expressed ectopically in corneal epithelial cell line by tetracycline inducible system and the phenotypes were assayed. Cell migration was tested by culture wound and transwell method. SIRC cells with PAX6 stable transfection grew in 35 mm cultured dishes until confluence with or without doxycycline for 3 days. After cells cultured with or without doxycycline to complete confluence, a wound was introduced by using a 200 µl pipette tip and wound healing was observed for 24 hours. At the same time, hydroxyurea at a final concentration of 5 mM (Sigma, St Louis, MO) was added to the medium and incubated for a further 24 hours. Cells migration assays were also performed using transwell Boyden chambers containing polycarbonate membrane inserts with 8.0 µm pores.

**Results:** PAX6 inducible SIRC cells, when cultured without doxycycline, were able to move to the center of wound and nearly healed it. In contrast, SIRC cells expressing PAX6 did not move to the center of the wound by 24 hours. Cell migration was inhibited by overexpression of PAX6 compared with PAX6 inducible SIRC cells without doxycycline induction and Tet-On transfected SIRC cells with doxycycline addition. The average numbers of cells migrating assayed with Boyden transwell were 54, 93 and 97 in the PAX6+dox, PAX6-dox and Tet-On+dox group, respectively.

**Conclusion:** PAX6 overexpression inhibited cell movement in SIRC cells. The finding provided a clue that PAX6 may function in corneal wound healing.



P-059

### Epidemiology of Infectious Keratitis in Taiwan: A 15-Year Population-Based Study

P Wu<sup>1</sup>, J Wang<sup>1</sup>, C Lai<sup>1,2,3,4</sup>.

<sup>1</sup>Ophthalmology, Chang Gung Memorial Hospital, Chiayi, Puzi City, Chiayi County, <sup>2</sup>Ophthalmology, <sup>3</sup>School of Traditional Chinese Medicine, College of Medicine, Chang Gung University, Taoyuan City, <sup>4</sup>Nursing, Chang Gung University of Science and Technology, Puzi City, Chiayi County, Taiwan, China

**Objective:** To investigate the demographics, risk factors, microbiological characteristics of infectious keratitis (IK) in Taiwan over the past 15 years.

**Methods:** A retrospective population-based study was conducted using the Chang Gung Research Database. Patients with IK were identified by diagnostic codes for corneal ulcer and corneal scraping cultures during the period from 1 January 2009 to 31 December 2019. Demographics, predisposing factors, microbiological profiles and antibiotic susceptibility were compared between 2004 to 2007, 2008 to 2011, 2012 to 2015 and 2016 to 2019. The Cochran-Armitage test was used to detect the trends.

**Results:** A total of 7807 subjects with cultured IK were included in the analysis, of which 3532 (45.2%) corneal scrapings were culture positive. Overall, bacterial keratitis accounted for 2761 (78.2%) of all isolates, including 15 nontuberculous mycobacteria, followed by fungal keratitis for 761 (21.5%) isolates. Of the 3532 microorganisms isolated, the most common were *Pseudomonas aeruginosa* (N=1002, 28.3%) and coagulase-negative *Staphylococcus* (N=631, 17.9%). The percentage of gram-positive isolates increased over time, however the number of gram-negative isolates decreased in the current years. Among the analyzable risk factors, the percentage of contact lens-related IK declined (P<0.05). The trend for the susceptibility profiles of both gram-positive and gram-negative bacteria did not change during the study period. The antibiotic resistance remained more common in gram-positive isolates and 5% MRSA showed resistance to vancomycin. The need for surgery to treat IK decreased over time (P<0.05).

**Conclusion:** We documented contact lens-related IK was on the wane along with a decreasing trend in the percentage of gram-negative bacteria, especially *Pseudomonas* species. Increased resistance to vancomycin raise some concern about the empirical use of fortified vancomycin in the initial management of gram-positive bacterial keratitis.

P-061

**Different compression sutures combined with intracameral air injection for acute corneal hydrops**X Liu<sup>1,2</sup>, Y Bi<sup>1,3</sup>.

<sup>1</sup>Ophthalmology, Tongji Hospital, School of Medicine, Tongji University, Shanghai, <sup>2</sup>Ophthalmology, Guizhou Provincial People's Hospital, Guiyang, <sup>3</sup>Tongji Eye Institute, Tongji University School of Medicine, Shanghai, People's Republic of China

**Objective:** To evaluate the efficacy and safety of full-thickness sutures combined with intracameral air injection (FTS-AI) versus pre-Descemet's membrane sutures combined with intracameral air injection (PDS-AI) in the management of acute corneal hydrops in keratoconus.

**Methods:** The research included 8 patients (8 eyes) suffering from acute corneal hydrops caused by keratoconus. Four patients were randomly assigned to FTS-AI. And the other four were randomly assigned to PDS-AI. Corneal oedema, visual acuity, corneal thickness were assessed during follow-up.

**Results:** The demographics, preoperative duration of symptoms and severity of corneal hydrops between the two groups were not significantly different. The mean corneal oedema resolution time after FTS-AI and PDS-AI were  $11 \pm 1.15$  and  $15 \pm 1.41$  days, respectively ( $p < 0.05$ ). The maximum corneal thickness of the scarred region decreased in both groups at one week postoperatively ( $p < 0.05$ ). No obvious difference was found in the mean maximal corneal thickness between the two groups postoperatively. The BCVA improved significantly after FTS-AI and PDS-AI at three months postoperatively. No obvious difference was found in the BCVA after FTS-AI and PDS-AI at three months postoperatively.

**Conclusion:** FTS-AI and PDS-AI are safe and effective therapies to accelerate the resolution of corneal oedema in acute corneal hydrops secondary to keratoconus. Despite faster resolution of corneal oedema in the FTS-AI group, we recommend PDS-AI to avoid potential endothelium cell damage.

**P-062****Long-term visual outcome in surgical management of cataract coexistent with corneal opacity in one-eyed patients**

R Kusumesh<sup>1</sup>, V Parasar<sup>1</sup>, D Kumari<sup>1</sup>.

<sup>1</sup>Ophthalmology, Indira Gandhi Institute of Medical Sciences, Patna, India

**Objective:** To determine the long-term visual outcome of surgical management in one-eyed patients with cataract coexistent with corneal opacity

**Methods:** Retrospective case-control study reviewed 44 one-eyed patients with cataract coexistent with corneal opacity. The patients who underwent cataract surgery alone (group A, n=25) were compared with matched group of patients managed with triple procedure (group B, n=19). Outcome measures were the improvement of best corrected visual acuity (BCVA) and period of maintained ambulatory vision. Surgical success was defined as attaining postoperative visual gain  $\geq 20/200$ .

**Results:** The most common etiology of corneal opacity was fungal and the commonest cause of permanent visual loss in other eye was phthisis bulbi. Mean age was  $61.2 \pm 8.1$  years and  $62.5 \pm 6.9$  years in group A and B respectively. In both the groups, at each follow-up the mean BCVA was found significantly better than the preoperative vision ( $P < 0.001$ ). Although, post operative vision significantly improved in both groups, at the end of 3 years of follow-up, mean BCVA of group A was significantly better than group B ( $p = .012$ ). Mean period of maintained ambulatory vision in group A ( $33.36 \pm 1.97$  months) was longer than group B ( $26.5 \pm 13.5$  months) ( $P = 0.048$ ). Limited visual outcome was due to continuing presence of corneal opacity in group A whereas graft infection followed by graft rejection in group B.

**Conclusion:** Cataract surgery with IOL implantation alone can be considered as an alternative or temporary option to provide at least stable ambulatory vision in one-eyed patients.

P-063

### A Comparative Study of AMP Combined With AMT and PKP in the Treatment of Corneal Microperforation

C Lv, Y CHEN.

**Objective:** To compare the clinical efficacy of amniotic membrane plugging(AMP) combined with amniotic membrane transplantation(AMT) and penetrating keratoplasty (PKP) in the treatment of corneal micro-perforation.

**Methods:** A retrospective analysis was made of patients diagnosed with corneal microperforation in our hospital who failed conservative treatment. A total of 40 patients (41 eyes) with corneal microperforation were included in this study. According to the surgical method, they were divided into AMP combined with AMT group (AMP group) and penetrating keratoplasty group (PKP group). The best corrected visual acuity(BCVA) at 1 month, 3 months, 6 months and 12 months after operation, anterior chamber formation time, corneal thickness changes before and 6 months after operation, primary disease control, anterior chamber maintenance time, transparent graft growth and survival time and complications were analyzed and evaluated between the two groups.

**Results:** 1. The BCVA of AMP at 1 and 3 months after operation was not significantly different from that before operation, while the BCVA at 6 and 12 months after operation was not different from that before operation. There were statistical differences between the previous comparisons, and both were improved; There were significant differences in the PKP group at 1, 3, 6, and 12 months after the operation and before the operation, and the BCVA was significantly improved compared with that before the operation. 2. The anterior chamber of the two groups could be formed within 3 days after the operation, and there was a significant difference in the formation time of the anterior chamber between the two groups. 3. The thickness of the corneal perforation area increased in the AMP 6 months after the operation, which was statistically different from that before the operation. There was a statistically difference between the two groups before operation; there was no statistical difference in the thickness of the corneal perforation area between the two groups before operation. 4. There was no statistical difference in overall survival time between the two groups. 5. There was no statistical difference in the incidence of postoperative complications between the two groups.

**Conclusion:** In the absence of fresh corneal grafts, AMP combined with AMT can be used as an effective method for the treatment of corneal microperforation, and has achieved good results in postoperative visual acuity and primary disease control.

P-067

### The Diagnosis and Treatment of Contact Lens-related Limbal Stem Cell Deficiency

Y Shen<sup>1</sup>, Q Le<sup>2</sup>.

<sup>1</sup>Department of Ophthalmology, Eye, Ear, Nose & Throat Hospital of Fudan University, <sup>2</sup>Department of Ophthalmology, Eye, Ear, Nose & Throat Hospital of Fudan University, Research Center, Eye, Ear, Nose & Throat Hospital of Fudan University, Shanghai, People's Republic of China

**Objective:** To analyze the clinical features and outcomes of eyes with contact lens-induced limbal stem cell deficiency (CL-iLSCD) so as to provide supportive evidence for its diagnosis and treatment.

**Methods:** This cross-sectional study included the patients who were diagnosed as CL-iLSCD in Eye, Ear, Nose & Throat Hospital of Fudan University from October 2018 to March 2022, and collected their demographic data, clinical examinations for the diagnosis and therapeutic regimens. The clinical features of CL-iLSCD, their outcomes and related risk factors were analyzed.

**Results:** A total of 15 patients (22 eyes) with the mean age of  $35.1 \pm 1.5$  years old were included in this study, among whom 13 were females (86.7%). Soft contact lenses were used by all patients with an average daily wearing time of  $10.4 \pm 0.6$  hours and an average wearing duration of  $11.3 \pm 1.2$  years. Nineteen eyes (86.4%) had ocular symptoms including decreased vision, ocular discomfort or pain, redness and photophobia. Comb- or whorl-pattern late fluorescein staining under cobalt blue light is the most characteristic clinical sign of CL-iLSCD, which was the most commonly seen at the superior limbus (22/22, 100%), along with the reduction of basal cell density, central corneal epithelial thickness and corneal nerve fiber length. A comprehensive score was assigned to each eye with the combination of clinical findings and in vivo imaging biomarkers. Four, 11 and 6 eyes were classified as mild, moderate and severe stage of LSCD, respectively. Twenty eyes (90.9%) had a history of misdiagnosis. After stopping use of contact lens and medical treatment, all eyes achieved significant improvement, among which twelve eyes were fully recovered.

**Conclusion:** The symptoms and clinical signs of CL-iLSCD are subtle at the early stage. The ophthalmologists are supposed to have more awareness and recognition of CL-iLSCD. Early diagnosis and treatment significantly improve its prognosis.

P-068

## The survival and characteristics of cryopreserved human iPSC-derived corneal epithelial cells generated by SSM-CI method

R ABDALKADER<sup>1</sup>, T FUJITA<sup>1,2</sup>.

<sup>1</sup>Ritsumeikan Global-Innovation Research Organization (R-GIRO), <sup>2</sup>College of Pharmaceutical Sciences Department of Pharmacy, Ritsumeikan University, Shiga, Japan

**Objective:** The evaluation of the function and survival of cryopreserved human iPSC-derived corneal epithelial cells (hiPSC-CEpCs) generated by the simplified small molecule-based corneal induction method (SSM-CI) in the post-thawing process.

**Methods:** Cell differentiation: The hiPSC 585A1 was used in this study. Cells were resuspended in mTeSR™ Plus basal medium supplemented with 10 μM Y27632 and plated on a matrigel-coated culture dish. The culture medium was replaced with the basal medium daily. To initiate cell differentiation, mTeSR™ Plus was replaced with a chemical induction medium, comprising fresh E6 medium supplemented with a Wnt pathway inhibitor (IWP-2), TGF-β kinase/activin receptor-like kinase inhibitor (SB505124), and human bFGF. These conditions were applied for four days. Cells were cultured in a maintenance medium comprising E6 medium alone for 20 days and then harvested and cryopreserved in liquid nitrogen. Cells thawing: cells were thawed in E6 basal medium with or without 10 μM Y27632 and plated on culture dishes coated with matrigel, collagen IV, or laminin 511. Immunofluorescence: cells were fixed and then permeabilized. Subsequently, cells were incubated with the primary antibody and secondary antibody (paired box protein; PAX6, cytokeratin; CK12, and zonula occludens; ZO-1) in blocking buffer.

**Results:** The differentiated cells expressed relevant maturation markers, including PAX6 and CK12 at day 20-25. The presence of 10 μM Y27632 significantly improved cells survival as compared to cells without Y27632 treatment. Moreover, cells could adhere to matrigel, collagen IV, as well as laminin 511 ECM coated dishes. While cell proliferation was superior on collagen IV, and laminin 511, the expansion of hiPSC-CEpCs on these ECM could not be sustained and soon cells detached. In contrast, in matrigel coated transwell inserts, cells could sustain their adherence post-thawing. Finally, the addition of EGF in the post-thawing process has significantly improved the formation of the corneal epithelial barrier characterized by a high expression of the tight junction protein ZO-1 and the maturation marker CK12.

**Conclusion:** In this research, we emphasize the importance of three factors for the survival and functionality of hiPSC-derived CEpCs: 1. The addition of ROCK inhibitor Y27632 for enhancing the cell's survival 2. The impact of the extracellular matrix (ECM) on the cell's adherence and function. 3. The addition of human EGF growth factor for enhancing cell maturation.

P-069

**Acute corneal transplant graft rejection after mRNA-1273 vaccine**C Wu, Y Ting<sup>1</sup>, C Huang<sup>1</sup>.<sup>1</sup>Ophthalmology, Wan Fang Hospital, Taipei Medical University, Taipei, Taiwan, China

**Objective:** We report a case of acute corneal allograft rejection that occurred 3 days after the injection of the mRNA-1273 vaccine (Moderna) for severe acute respiratory syndrome coronavirus 2 (SARS-CoV-2)

**Methods:** A case report

**Results:** We report the case of a 77-year-old female patient with a past ophthalmic history of cataract surgery and PK of her right eye that occurred 10 years ago. She received regular follow-up at our outpatient department for the past 10 years and exhibited a moderately clear and stable corneal graft condition and an average BCVA of 20/40 in the right eye. She complained of acute blurred vision in her right eye 3 days after receiving her first dose of mRNA-1273 vaccine for COVID-19. The patient's best corrected visual acuity (BCVA) was 20/400 and 20/50 in the right and left eyes, respectively. Slit lamp examination revealed diffuse corneal edema, fine keratic precipitates, and posterior chamber intraocular lens in place in her right eye (figure 1A, 1B, and 1C). Anterior optical coherence tomography revealed edematous corneal graft with keratic precipitates in the right eye (figure 2). Anterior chamber paracentesis with samples sent for virus polymerase chain reaction revealed negative results for cytomegalovirus, herpes simplex virus, and herpes zoster virus. We prescribed oral prednisolone (0.5 mg/kg/day), topical prednisolone acetate 1% (administered every hour), and cyclosporine ophthalmic emulsion 0.05% (administered 4 times per day for her right eye). A 7-day follow up revealed resolved corneal edema and return of BCVA to baseline.

**Conclusion:** Although the relationship between corneal transplant graft rejection and COVID-19 vaccination requires further verification, the time sequence of the two events suggests a possible association. The activation or flaring up of immune-mediated diseases can occur after vaccination, thereby causing the acute inflammation of a PK graft that was stable for 10 years. For the patient, a thorough evaluation of risks and benefits should be conducted if she intends to take the second dose of the COVID-19 vaccine. Although such occurrences are rare, ophthalmologists should pay attention to patients who complain of acute blurred vision after receiving COVID-19 vaccination, particularly those with an ophthalmic history of corneal transplantation.

**P-070****A complicated case of Acanthamoeba keratitis**I Gardeli<sup>1</sup>, K Mouriki<sup>1</sup>.<sup>1</sup>Cornea Department, State Ophthalmology Clinic, General Hospital of Athens G. Gennimatas, Athens, Greece

**Objective:** The purpose of this paper is the presentation of the clinical course and management of a case complicated with Acanthamoeba and fungal keratitis. This patient was contact lens wearer and presented to the outpatient clinic with a corneal ulcer with epithelial defect and Wesseley immune ring.

**Methods:** The superficial corneal swab was used for cultures and Polymerase Chain Reaction (PCR). PCR results were found to be positive for Acanthamoeba and fungi. In this case cultures of Acanthamoeba were grown.

**Results:** In this case we used coll desomedine and polyhexamethylene biguanide (PHMB) 0.02% for the treatment of Acanthamoeba keratitis, whereas for the fungal keratitis we used tab and coll voriconazole. The clinical course of the patient was good in follow up although she had received treatment for herpes simplex virus before she presented to our clinic.

**Conclusion:** Prompt diagnosis and treatment of a case complicated with Acanthamoeba and fungal keratitis are essential for a good visual outcome.



**P-071****Subconjunctival injection of Bevacizumab as an adjuvant treatment of peripheral ulcerative keratitis**H *Chien*, Y Shen.

**Objective:** To report subconjunctival injection of Bevacizumab as an effectively adjuvant treatment in two cases of progressive peripheral ulcerative keratitis (PUK).

**Methods:** 2 cases of newly diagnosed PUK were successfully treated with adjuvant subconjunctival injection of Bevacizumab. Case 1, a 54-year-old woman without medical history of autoimmune diseases, presented with a one-week history of right eye redness and stabbing pain. There was an area of PUK extending 160 degree temporally and spanning 2 mm at its greatest width, with 50% stromal thinning and de-epithelialization. Corneal ulceration and epithelial defect persisted after 1 week treatment consisted of topical antibiotics, corticosteroids and lubricants. Case 2, A 89-year-old woman was referred for corneal ulceration with persistent pain of both eyes for one month duration. There were deep peripheral ulceration with stromal thinning extending from 11 to 6 o'clock and impending perforation in the right eye and ulceration along limbus from 10 to 1 o'clock in left eye. Rheumatoid arthritis was diagnosed at rheumatology department thereafter. Despite the treatment consisted of oral tetracycline, vitamin C and prednisolone 20 mg daily, topical corticosteroids and lubricants, impending corneal perforation was observed.

**Results:** In case 1, 2 consecutive subconjunctival injections of Bevacizumab (0.25mg/0.1 ml) on the right eye at weekly intervals were initiated. Regression of corneal stromal vessels, healing epithelial defect were observed 2 weeks after the first injection. In case 2, amniotic membrane transplantation to the right eye and 2 consecutive subconjunctival injections of Bevacizumab (0.25mg/0.1 ml) to both eyes were administered. Marked reduction of the limbal and adjacent conjunctival vessels of both eyes were observed within one week after injections. Cases 1 and 2 both experienced healing of corneal ulceration and relieved symptoms.

**Conclusion:** Subconjunctival injection of Bevacizumab may play a role in the treatment of PUK, as an adjuvant therapy. Further studies are needed to determine the long-term efficacy and safety.

**P-072****Necrotizing Anterior Scleritis Associated With Extrapulmonary Tuberculosis: A Case Report**P Bayu Putra.

**Objective:** Necrotizing anterior scleritis is the most severe form of scleritis, characterized by severe pain and extreme scleral tenderness. It is a serious ocular condition that can lead to vision loss and therefore requires early diagnosis and treatment. The etiology is commonly autoimmune, idiopathic, or infection but some cases are associated with systemic infection such as tuberculosis

**Methods:** This case report was aimed to present necrotizing anterior scleritis associated with extrapulmonary tuberculosis.

**Results:** The case reported is a 20-year old girl presented with sudden redness and swollen left eye after having had a fever for 5 days. Visual acuity was 20/60 in the left eye and 20/20 in the right eye. Ophthalmologic examination showed ocular movement pain, swollen eyelid, purulent discharge with subconjunctival bleeding, and a 8x8mm necrotic scleral tissue at 2mm from limbus. The patient had undergone autoimmune and infection serology tests, scleral scrapping culture, and sacroiliac joint x-ray, but all results were negative. Only Mantoux test revealed positive with 16mm induration with normal chest x-ray and negative tuberculosis sputum smear. Anti-tuberculosis treatments were started 1 week later, and 1 month later the patient reported visual acuity improvement to 20/20 in both eyes and inflammation on the left eye was subsided. Anti-tuberculosis treatments were continued until 9 months.

**Conclusion:** Although systemic tuberculosis is reported as a possible cause of scleritis and other ocular inflammatory manifestations, assessment of the diagnosis of tuberculosis-related ocular inflammation is challenging especially in latent forms. The treatment is largely presumptive. However, a favorable response to antitubercular therapy without relapse is taken as evidence of the disease.

**P-073****Corneal burn injury in picosecond laser treatment: A potential hazard in cosmetic therapy**P Lee<sup>1</sup>.<sup>1</sup>*ophthalmology, Kaohsiung medical university hospital, kaohsiung City, Taiwan, China*

**Objective:** To describe a case of picosecond laser-related corneal burn injury. Case presentation of a patient under[1]went picosecond laser cosmetic treatment, complicated with severe corneal burn injury.

**Methods:** We evaluate patient's visual acuity, corneal edema condition under slit lamp and corneal OCT (Optical coherence tomography), corneal shape with topography, and intraocular pressure. Picosecond laser emits optical pulses with duration between one to tens of picoseconds. The original purpose was to remove tattoos, but has now extended to a wide range of skin diseases and even cosmetic use.

**Results:** When applying cutaneous laser therapy, several ocular adverse events have been reported, mostly due to no appropriate ocular protection during treatment. We report a case of corneal burn injury after receiving picolaser therapy for a pigmented lesion over the upper lid. Severe cornea edema and vision impairment improved gradually after appropriate treatment.

**Conclusion:** Even picosecond laser produce less thermal burns than other lasers, it is essential to use ocular protection during the entire treatment. According to our database search, this is the first picolaser-related ocular adverse event reported.

P-074

**Long-Term Follow-Up Of 7 Years After Corneal Crosslinking In Patients With Keratoconus.**

C Enders<sup>1,2</sup>, D Vogel<sup>1</sup>, J Dreyhaupt<sup>3</sup>, A Garip-Kuebler<sup>1</sup>, L Neuhann<sup>1</sup>, J Hall<sup>1</sup>.

<sup>1</sup>MVZ Prof. Neuhann GmbH, Munich, <sup>2</sup>Medical Faculty, <sup>3</sup>Institute of Epidemiology and Medical Biometry, Ulm University, Ulm, Germany

**Objective:** To analyse safety and efficacy of corneal collagen crosslinking in patients with keratoconus 7 years postoperatively.

**Methods:** In this retrospective study we included all consecutive patients who underwent CXL in our cornea center from 01/01/2007 to 12/30/2011 of whom a full keratometric dataset was available preoperatively and 7 years postoperatively and met our inclusion criteria. CXL was performed in all patients according to the Dresden-protocol. We analyzed best corrected visual acuity (BCVA) and topographic keratometry by Scheimpflug corneal tomography.

**Results:** 7 years postoperatively a complete topographic dataset was available for 126 eyes. logMAR BCVA improved by  $0.09 \pm 0.16$  after 7 years ( $n=73$ ) ( $p<0.0001$ ). Mean decrease of Kmax was  $-2.18$  Diopters (dpt)  $\pm 3.64$  dpt., K1 showed a decrease of  $-1.01$  dpt  $\pm 2.66$  dpt, K2 showed a decrease of  $1.71$  dpt  $\pm 2.42$  dpt, anterior astigmatism showed a decrease of  $-0.72$  dpt  $\pm 1.47$  dpt. Also thinnest corneal thickness decreased  $-35.49$   $\mu\text{m}$   $\pm 42.13$   $\mu\text{m}$ . All of these changes were all statistically significant ( $p<0.0001$ ). No relevant infections occurred, no patient received penetrating keratoplasty.

**Conclusion:** We were able to demonstrate the positive long-term effect of CXL on patients with keratoconus even 7 years postoperatively while maintaining outstanding safety of this procedure.

P-075

## Management of Left Oculi Central Corneal Ulcer Using Periosteal Graft Technique Followed by Keratoplasty: A Case Report

P Purwanita<sup>1</sup>, A Tribowo<sup>1</sup>, F Amrina<sup>1</sup>.

<sup>1</sup>Ophthalmology, Dr. Mohammad Hoesin General Hospital, Sriwijaya University, Palembang, Indonesia

**Objective:** To report a management of left eye central corneal ulcer case caused by bacteria using periosteal graft surgery followed by keratoplasty.

**Methods:** A 40-year-old man presented with white spot in left eye since 7 months ago. Patient complained redness, watery and discharge in his left eye. He also admitted his left eye was exposed to wood dust, then washed his eye with betel leaves water. Ophthalmic examination of the left eye showed the visual acuity of 1/~, conjunctiva and ciliary injection, accompanied with corneal central defect 8x7 mm with >2/3 stromal depth, infiltrates and fluorescent staining at defect margin, and desmetocele. Gram examination: positive-coccus bacteria. Corneal discharge culture: Staphylococcus lugdunensis. Patient was diagnosed with central corneal ulcer with impending corneal perforation as complication. We considered a periosteal graft surgery covering the corneal surface, then followed by keratoplasty 6 months after the periosteal graft.

**Results:** This patient experienced impending corneal perforation caused by a central corneal ulcer. In consequence, the periosteal graft technique was chosen to maintain the eyeball integrity and help corneal ulcer healing. After evaluating for 6 months post periosteal graft, we decided to perform a keratoplasty, a surgery procedure of replacing all layers of the cornea. This procedure is indicated for corneal abnormalities with a high degree of severity, in accordance with this case which performed a large ulcer defect and desmetocele. After keratoplasty, a comprehensive follow-up was carried out to assess the success of the procedure. From the follow-up results, it was found that there was an improvement in visual acuity from 1/~ to 1/300. An increase in visual acuity which was only up to 1/300 was suspected from complicated cataract in this patient. It is expected that after managing the cataract by extraction, the patient's visual acuity will result a better improvement. There were no signs of complications in this patient. In corneal examination, it was found that the cornea was clear. This indicated the occurrence of fusion between the recipient and donor cornea.

**Conclusion:** The use of periosteal graft technique can maintain the eyeball integrity and help corneal ulcer healing. The use of keratoplasty can improve the patient's visual acuity and aesthetics outcomes. Keratoplasty procedure on patients with periosteal grafts can also still be performed as long as there is still a portion of the cornea remaining.

P-076

**Corneal Crosslinking In Patients With Keratoconus: a 3-Year Follow-Up**

J Hall<sup>1</sup>, D Vogel<sup>1</sup>, J Dreyhaupt<sup>2</sup>, A Garip-Kuebler<sup>1</sup>, L Neuhann<sup>1</sup>, C Enders<sup>1,3</sup>.

<sup>1</sup>MVZ Prof. Neuhann GmbH, Munich, <sup>2</sup>Institute of Epidemiology and Medical Biometry, <sup>3</sup>Medical Faculty, Ulm University, Ulm, Germany

**Objective:** To evaluate safety and efficacy of corneal collagen crosslinking (CXL) in patients with keratoconus 3 years after CXL.

**Methods:** In this mono-centre exploratory study we included all consecutive patients who underwent CXL in our cornea center from 01/01/2007 to 12/30/2011 and met the inclusion criteria. CXL was performed in all patients according to the Dresden-protocol. Evaluation included best corrected visual acuity (BCVA), topographic keratometry by Scheimpflug corneal tomography and adverse events.

**Results:** The study enrolled 107 eyes of which a complete keratometric dataset existed preoperatively and 3 years postoperatively. BCVA increased statistically significant after 3 years (mean: -0.10 logMAR, std: 0.24 logMAR;  $p=0.0023$ ). We were able to demonstrate statistically significant decreases of the keratometric parameters Kmax, K1, K2, anterior astigmatism and thinnest corneal thickness. None of the eyes received penetrating keratoplasty, no relevant infections occurred in this cohort.

**Conclusion:** CXL can slow down or even stop the progression of keratoconus in the majority of cases while providing excellent safety.

P-078

**Toxicity of amantadine hydrochloride on cultured bovine cornea endothelial cells**P Lee.

**Objective:** Amantadine hydrochloride (HCl) is commonly prescribed for treating influenza A virus infection and Parkinson's disease. Recently, several studies have indicated that the use of amantadine HCl is associated with corneal edema; however, the cytotoxic effect of amantadine HCl has not been investigated.

**Methods:** In the present study, the effects of amantadine HCl on cell growth, proliferation, and apoptosis in bovine cornea endothelial cells, and in vitro endothelial permeability were examined.

**Results:** Results showed that lower doses of amantadine HCl do not affect cell growth ( $\leq 20 \mu\text{M}$ ), whereas higher doses of amantadine HCl inhibits cell growth ( $\geq 50 \mu\text{M}$ ), induces apoptosis ( $2000 \mu\text{M}$ ), increases sub - G1 phase growth arrest ( $2000 \mu\text{M}$ ), causes DNA damage ( $\geq 1000 \mu\text{M}$ ), and induces endothelial hyperpermeability ( $\geq 1000 \mu\text{M}$ ) in bovine cornea endothelial cells; additionally, we also found that amantadine HCl attenuates the proliferation ( $\geq 200 \mu\text{M}$ ) and arrests cell cycle at G1 phase ( $\geq 200 \mu\text{M}$ ) in bovine cornea endothelial cells.

**Conclusion:** In the present study, we measured the cytotoxic doses of amantadine HCl on cornea endothelial cells, which might be applied in evaluating the association of corneal edema.

P-079

**THE EFFECT OF HYDROXYPROPYL-GUAR NANOEMULSION ON SIGNS AND SYMPTOMS OF DRY EYE**

T Jia<sup>1</sup>, M Markoulli<sup>1</sup>, K Wong<sup>1</sup>, J Siddireddy<sup>1</sup>, N Briggs<sup>1</sup>, J Tan<sup>1</sup>.

<sup>1</sup>UNSW Sydney, UNSW Sydney, Australia

**Objective:** To examine the effect of hydroxypropyl-guar nanoemulsion versus saline on comfort and tear film properties of people with dry eye disease both in the short-term (up to 2 hours post-drop instillation) and longer-term (after 4 weeks of 4-times daily use), and to examine the effect on tear inflammatory markers after 4 weeks.

**Methods:** This was a prospective, investigator-masked, randomised, cross-over dispensing study. Twenty participants with dry eye were randomised to HP-Guar nanoemulsion or saline. Ocular symptoms, lipid layer thickness (LLT), tear evaporation, tear osmolarity and non-invasive break-up time were measured pre-drop instillation, 1 hour, 2 hours post- instillation, and after 4-weeks of 4-times daily drop use. Tear inflammatory mediators were measured pre-instillation and after 4-weeks. Participants were crossed over to the alternate eye drop after a 4-week washout.

**Results:** With HP-Guar nanoemulsion, participants reported less grittiness/burning/stinging 1 hour ( $79.5 \pm 23.3$  vs.  $66.8 \pm 27.7$ ,  $p = 0.02$ ); less dryness 1 hour and 2 hours ( $77.8 \pm 23.0$  and  $76.2 \pm 23.7$  vs.  $61.0 \pm 27.1$  respectively,  $p < 0.01$ ); and greater overall satisfaction 1 hour post-instillation and after 4 weeks compared to baseline ( $80.4 \pm 21.6$  and  $83.4 \pm 16.6$  vs.  $68.6 \pm 26.0$  respectively,  $p \leq 0.011$ ). With saline, participants reported less dryness after 4 weeks compared to baseline ( $74.2 \pm 23.8$  vs.  $60.2 \pm 24.0$ ,  $p < 0.01$ ). For HP-Guar nanoemulsion, average LLT was significantly thicker 2 hours post-instillation ( $79.5 \pm 21.7$  nm) compared to baseline ( $63.7 \pm 18.9$  nm) and 4 weeks ( $62.4 \pm 23.1$  nm,  $p < 0.01$ ). For saline, average LLT was significantly thicker at 1 hour and 2 hours post-instillation ( $76.0 \pm 23.8$  nm and  $80.4 \pm 24.8$  nm) compared to baseline ( $61.0 \pm 15.6$  nm,  $p < 0.01$ ). There was no difference in inflammatory mediators or other tear variables.

**Conclusion:** HP-Guar nanoemulsion was more effective for improving subjective dry eye symptoms compared to saline. Both HP-Guar nanoemulsion and saline transiently increased lipid layer thickness.



**P-080****Endothelial cell loss between Anterior and Retropupillary implantation of Iris-Claw Intraocular Lens**C Wu, C Huang, Y Ting.

**Objective:** To evaluate the endothelial cell loss and outcomes of iris-claw intraocular lens implantation between anterior and retropupillary locations.

**Methods:** We retrospectively examined the outcomes of patients with iris-claw intraocular lens implantation (IOL) during the period of January 2016 to January 2022. The exclusion criteria consisted of patients with insufficient preoperative or postoperative data. The patients were categorized by location of implantation. The outcome was compared by preoperative and postoperative best-corrected visual acuity (BCVA), intraocular pressure (IOP), target refraction, central endothelial cell density (CECD), and postoperative complications.

**Results:** In this study, 56 eyes of 42 patients were included. Iris-claw IOL was implanted posteriorly in 29 (51.7%) eyes. The most common indication for iris-claw IOL was complicated cataract surgery, followed by trauma and by refractive error. Patients with either anterior or retropupillary position obtained a significant improvement in BCVA ( $P < 0.05$ ) whatever the causative indication. Anterior iris-claw IOL patients had significantly lower endothelial cell density (cells/mm<sup>2</sup>). There was no statistically significant difference in the risk of IOP elevation events and the central cornea thickness between the two groups.

**Conclusion:** Retropupillary iris-claw IOL may achieve lower endothelial cell loss without significant postoperative complications. Further comprehensive and detailed complication analyses with larger sample sizes and longer follow-ups are needed.

P-081

## Psychological Distress in Patients with Ocular Graft-versus-Host Disease after Hematopoietic Stem Cell Transplantation

Q Chen<sup>1</sup>, Y Liao<sup>1</sup>, L Liang<sup>1</sup>.

<sup>1</sup>State Key Laboratory of Ophthalmology, Zhongshan Ophthalmic Center, Sun Yat-sen University, Guangzhou, People's Republic of China

**Objective:** To investigate the association between ocular graft-versus-host disease (oGVHD) and psychological distress in patients after allogeneic hematopoietic stem cell transplantation (HSCT).

**Methods:** This Cross-sectional observational study included 142 patients after HSCT between November 1, 2019 to January 31, 2021. oGVHD was diagnosed according to International Chronic Ocular GVHD Consensus Group (ICOGCG) criteria. Self-reported psychological assessment by Depression, Anxiety and Stress Scale (DASS-21). Potential risk factors of psychological distress were evaluated by linear regression.

**Results:** Higher total distress score (24 [IQR 8.5-38] vs. 12 [IQR 5-30],  $P=0.018$ ) including depression (8 [IQR 2-14] vs. 4 [IQR 2-10],  $P=0.004$ ), anxiety (8 [IQR 4-15.5] vs. 6 [IQR 2-10],  $P=0.064$ ) and stress (6 [IQR 2-14] vs. 2 [IQR 0-10],  $P=0.019$ ) scores were presented in the oGVHD group than those in non-oGVHD group. oGVHD group experienced an increasing tendency in the prevalence of depression (39% vs. 26%,  $P=0.106$ ), anxiety (51% vs. 39%,  $P=0.137$ ) and stress (21% vs. 12%,  $P=0.191$ ) on the DASS-21 scales. The psychological distress was significantly correlated with ICOGCG score ( $\beta = 2.224$ , 95%CI: 0.749 to 3.699,  $P=0.003$ ) and post-HSCT medical expense ( $\beta = 0.763$ , 95%CI: 0.280 to 1.246,  $P=0.002$ ) in patients after HSCT.

**Conclusion:** Patients after HSCT experienced evident psychological distress, particularly in those with oGVHD. Detailed assessment of psychological distress and oGVHD should be included in HSCT survivorship for a better chronic disease management.

P-082

**Penetrating keratoplasty for silicone oil keratopathy with retained silicone oil tamponade**C Wu<sup>1</sup>, Y Ting<sup>1</sup>, C Huang<sup>1</sup>.<sup>1</sup>Ophthalmology, Wan Fang Hospital, Taipei Medical University, Taipei City, Taiwan, China

**Objective:** Long term silicone oil tamponades are associated with silicone oil keratopathy and many other ocular complications. While penetrating keratoplasty for silicone oil keratopathy was associated with poor prognosis, it may be one of the very few ways to improve vision, especially in patients whose eye is the only eye with visual potential. We report the outcomes and managements of silicone oil associated complications.

**Methods:** We conduct a retrospective case series of patients who underwent penetrating keratoplasty for silicone oil keratopathy at a single medical center in Taiwan from 2012 to 2021.

**Results:** A total of 18 penetrating keratoplasties were performed for 12 patients under the diagnosis of silicone oil keratopathy. Mean age was 59.2 years (ranging from 23 to 80 years). The eye that underwent surgery was the only eye with visual potential accounted for 50% of our patients. All of the selected patients' silicone oil were not removed during the procedure and additional silicone oil was injected intraoperatively to balance for those that were loss. 2 out of 18 penetrating keratoplasties resulted in primary graft failure (11.1%). Average corneal graft survival was 19.2 months (ranging from 2 to 108 months, standard deviation=24.8 months, median= 12 months). 2-year graft survival rate was 27.8%. Four corneal grafts that remained clear with ongoing follow up by the time of analysis survived for 4, 16, 24, 108 months, respectively. Complications include postoperative hypotony that required additional injection of silicone oil that accounted for 2 eyes (11.1%).

**Conclusion:** Silicone oil was generally removed by the vitreoretinal surgeons as soon as 3 months to prevent long term complications of silicone oil tamponade. However, extended duration of silicone oil tamponade may be unavoidable in patients with high risks of retinal re-detachment, and especially when the eye is the only eye with visual potential. Although the 2-year graft survival rate was relatively poor, which was similar to those reported by previous studies, it is to note that there is still possibility of long term graft survival. Further studies should investigate the factors that would benefit the long-term graft survivability in silicone oil keratopathy.

P-084

**Efficacy of ProKera in the Management of Symblepharon post Stevens-Johnson Syndrome**P Wu<sup>1</sup>, J Wang<sup>1</sup>, C Lai<sup>1234</sup>.

<sup>1</sup>Ophthalmology, Chang Gung Memorial Hospital, Chiayi, Puzi City, Chiayi County, <sup>2</sup>Ophthalmology, <sup>3</sup>School of Traditional Chinese Medicine, College of Medicine, Chang Gung University, Taoyuan City, <sup>4</sup>Nursing, Chang Gung University of Science and Technology, Puzi City, Chiayi County, Taiwan, China

**Objective:** To report the efficacy of sutureless amniotic membrane device (ProKera, Bio-Tissue, Inc. Miami, FL) in the management of symblepharon.

**Methods:** Case report and review of the literature.

**Results:** A 54-year-old woman, previous victim of Steven-Johnson syndrome, presented with bilateral nasal symblepharon, which impeded lateral gaze and smooth eyelid opening. The slit-lamp examination revealed corneal persistent epithelial defect in both eyes. After initial management with topical steroids and lubricants, the cornea achieved partial epithelization with little improvement in her vision and eye movement. Symblepharon release was performed under topical anesthesia in both eyes, while ProKera was placed only in the right eye because of financial pressure. One month after the surgery, slit-lamp examination showed complete reepithelization of both corneas and conjunctivae. She was able to open her eyelids and move her eyes fully in all directions. At six-month follow-up, there were no signs of recurrence and her visual acuity remained stable in both eyes.

**Conclusion:** ProKera placement may be effective in the treatment of symblepharon. The presence of a rigid conformer ring provides a support to reconstruct proper forniceal anatomy and prevent recurrence.

P-085

### The Economic Burden of Dry Eye Disease in Asia-Pacific Countries

R Kara<sup>1</sup>, M Ainslie-Garcia<sup>2</sup>, W Wang<sup>2</sup>, E Persaud<sup>2</sup>, J Bench<sup>1</sup>, K Mills<sup>1</sup>.

<sup>1</sup>Alcon Laboratories, Inc., Fort Worth, United States, <sup>2</sup>EVERSANA, Burlington, Canada

**Objective:** Despite the increasing prevalence of dry eye disease (DED), the economic impact is largely underrecognized. A literature review was conducted to understand available evidence on the economic burden of DED in countries within the Asia-Pacific region.

**Methods:** MEDLINE was searched from Jan-01-2012 to Jan-14-2022 using the terms DED, economic burden, cost, and productivity loss. Reviews, economic analyses, and observational studies reporting on direct or indirect burden were retained. Reference lists from relevant articles were also scanned. Language restrictions were not applied. Costs were inflated to 2021 in reported currency.

**Results:** Of 160 titles screened, 12 studies were identified across China (n=4), Japan (n=4), Australia (n=1), Singapore (n=1) or the overall Asia-Pacific region (n=2 reviews). Sources of direct medical burden characterized by studies included examination, pharmacological therapy (including ocular lubricants), and nonpharmacological therapy fees (eg, punctal plugs). Mean direct medical costs ranged from USD\$504 in China to AUD\$1,420 in Australia. Severity of DED, mixed DED subtype, and presence of anxiety were each associated with higher direct medical costs. One study reported patients 30–39 years of age incurred the highest direct costs in China. In Japan, annual indirect costs from productivity loss were significantly greater for patients with DED versus controls ( $p < 0.05$ ), with estimated losses of USD\$8,084 per patient with DED, or USD\$20.2 billion country-wide. In Australia, indirect costs associated with DED (in patients with glaucoma) was AUD\$442 million annually.

**Conclusion:** These studies demonstrate that DED causes substantial economic burden in Asia-Pacific countries. Raising awareness and improving effective management of DED symptoms among the working age population should be a priority.

P-086

**Clinical characteristics and treatment in patients with herpes simplex keratitis after cataract surgery**M Tsai<sup>1</sup>, Y Wan<sup>1</sup>, C Sun<sup>2</sup>.<sup>1</sup>Ophthalmology, Show-Chwan Memorial Hospital, Changhua, <sup>2</sup>Ophthalmology, Chang Gung Memorial Hospital, Keelung, Taiwan, China

**Objective:** To investigate the demographics, treatment strategies, and outcomes between non-cataract surgery-related herpes simplex keratitis (ncsHSK) and post-cataract surgery herpes simplex keratitis (pcsHSK).

**Methods:** This is a retrospective case-control study that enrolled patients with pcsHSK (study group) and ncsHSK (control group).

The demographics, underlying systemic diseases, ocular diseases, clinical course, and treatment outcomes in both groups were obtained. The different covariates mentioned above were compared and analyzed.

**Results:** The patients in the study group had significantly more underlying systemic diseases than the patients in the control group (P=0.019). Treatment duration was also longer in the pcsHSK group than in the ncsHSK group (P<0.001). Treatment with oral famciclovir and topical acyclovir was positively correlated to better post-treatment BCVA and negatively correlated with longer treatment duration in the pcsHSK group (P=0.021 and 0.003, respectively). Old age was a risk factor for poor post-treatment best-corrected visual acuity (BCVA) and longer treatment duration in both groups (all P<0.05). Better pre-treatment BCVA was significantly correlated with better post-treatment BCVA in the control group (P =0.002) but not in the study group (P=0.299).

**Conclusion:** The reason for different clinical characteristics between pcsHSK and ncsHSK may be systemic diseases. Taking a complete medical history included systemic disease before the cataract surgery is necessary. Early diagnosis and aggressive antiviral treatment with oral famciclovir and topical acyclovir for pcsHSK may be beneficial to avoid longer treatment duration and poor visual outcomes.

**P-087****The Use of Contact Lenses Among Keratoconus Patients in Saudi Arabia: Prevalence, Habits and Complications**S Alanazi.

**Objective:** To determine the prevalence of contact lens use as well as the attitudes toward contact lens usage and its complications among keratoconus patients.

**Methods:** his cross-sectional study included 112 keratoconus patients who were treated with contact lenses; subjects were from different areas of Saudi Arabia. A voluntary self-administered questionnaire was used to collect data regarding prevalence, habits and outcomes of contact lens use among keratoconus patients.

**Results:** Of 112 respondents, 84.8% were treated with hard lenses, while 23.2% used soft lenses. Complications were reported among 57.1%, the most common being dry eyes. Regarding hygiene habits, 66.3% reported washing their hands before wearing their lenses, while 33.7% did not. Moreover, 69% of the participants made sure that there were no scratches or breaks in the edges of the contact lenses before wearing them. The majority of participants reported that they had never slept with lenses on (68.4%), while 13.7% kept their lenses on during naps.

**Conclusion:** The results of this study highlight negative habits of contact lens use and complications experienced by users. Although the study shows good practice among keratoconus patients, health education on contact lens hygiene is recommended to improve patient behaviour and prevent severe complications. In addition, further research must be undertaken to evaluate the awareness of contact lens related complications among KC patients.

P-088

**Extensive scleromalacia pre-perforans complicating granulomatosis with polyangiitis**S Ben Aoun<sup>1</sup>, R Maamouri<sup>1</sup>, W Nabi<sup>1</sup>, A Chebbi<sup>2</sup>, Z Aydi<sup>3</sup>, M Cheour<sup>1</sup>.<sup>1</sup>Ophthalmology department, Habib Thameur Hosiptal, <sup>2</sup>Department C, Hedi Raies Institut of Tunis, <sup>3</sup>Department of internal medicine, Habib Thameur Hospital, Tunis, Tunisia

**Objective:** Scleromalacia pre-perforans is a rare and severe ocular manifestation of systemic inflammatory diseases. Our purpose is to report a case of granulomatosis polyangiitis with severe sight-threatening involvement.

**Methods:** A single case report documented with multimodal imaging.

**Results:** A 61-year-old African male was referred for more than six month's history of progressive painful blurred vision of the right eye (OD). His best corrected visual acuity was limited to light perception in OD and 20/20 in the left eye (OS). Anterior segment examination revealed in OD severe scleromalacia with extensive superior prolapses of the choroid and dense white cataract. OS examination was unremarkable except the presence of local scleromalacia in the temporal part. Intraocular pressure was 10 mmHg in the OD and 12 mmHg in the OS. B-scan ultrasonography in OD showed choroidal elevation of 11 mm regarding the scleromalacia, without spontaneous vascular pulsations or retinal detachment. He underwent an exhaustive work-up that came back normal. Due to the poor visual acuity an enucleation was proposed but the patient refused and was lost to follow-up. He came back one year later when examination showed stable lesion without extension. After internal medicine examination and considering the presence of bilateral necrotizing anterior scleritis, the diagnosis of granulomatosis with polyangiitis was made and the patient was treated with corticosteroids with immunosuppressive drugs.

**Conclusion:** The presence of granulomatosis with polyangiitis require close monitoring with regular follow-up since it could be a sight and a life-threatening condition.



P-089

### Transepithelial Corneal Collagen Cross-linking in the Treatment of Keratoconus Stages I-III

S Bekirova, I *Saliev*.

**Objective:** Keratoconus is a non-inflammatory progressing primary ectasia of the cornea clinically manifesting itself as conic corneal ectasia with cornea-thinning and decreased visual acuity due to development of irregular astigmatism. Corneal collagen cross linking (CCC) is currently one of the most effective methods of keratoconus treatment in its initial and advanced stages.

**Methods:** 70 patients (114 eyes) with diagnosed advanced stages I, II and III of keratoconus were treated with corneal collagen transepithelial cross-linking. The patients included 17 women and 53 men with an average age of  $22.5 \pm 2.5$  years. Keratoconus stage I was diagnosed in 21 eyes (18.4%), stage II-44 eyes (38.5%), and stage III-49 eyes (43.0%). All the patients underwent visometry (LogMAR) without correction and with maximum spectacle correction; corneal keratopography was performed with an Oculyzer II, CASIA2;

**Results:** The patients with keratoconus stage I had UCVA from  $0.3 \pm 0.9$  to  $0.2 \pm 0.8$  D; CVA from  $0.1 \pm 1.5$  to  $0.0 \pm 0.9$  D; the cylindrical refraction component from  $-3.52 \pm 0.14$  to  $-3.21 \pm 0.13$  D, respectively; K max from  $52.04 \pm 2.25$  D to  $50.39 \pm 2.5$  D; Kavg from  $46.3 \pm 2.48$  to  $44.4 \pm 2.61$ ; the CV in the keratectasia area increased by  $12.3 \mu\text{m}$  and was  $508.2 \pm 9.25 \mu\text{m}$ .

In the patients with keratoconus stage II, UCVA from  $0.7 \pm 0.9$  to  $0.5 \pm 0.9$  D. CVA from  $0.3 \pm 1.5$  to  $0.1 \pm 0.9$  D and decrease the spherical and cylindrical component of refraction, respectively, from  $-5.25 \pm 0.15$  D to  $-3.75 \pm 0.18$  D and from  $-4.25 \pm 0.17$  D to  $3.93 \pm 0.13$  D. Kmax  $57.4 \pm 4.3$  D to  $54.4 \pm 3.35$  D; and Kavg  $49.11 \pm 2.77$  to  $46.8 \pm 3.21$  while CCV was  $458.5 \pm 7.25 \mu\text{m}$ .

The patients with of keratoconus stage III UCVA from  $1.1 \pm 0.9$  to  $0.7 \pm 0.9$ ; CVA from  $0.7 \pm 0.9$  to  $0.3 \pm 1.0$  D. Spherical and cylindrical refraction component from  $-8.75 \pm 0.31$  to  $-7.75 \pm 0.18$  D and from  $-7.5 \pm 0.19$  D to  $-7.2 \pm 0.15$  D, respectively. Kmax from  $62.5 \pm 3.75$  to  $61.3 \pm 2.25$  D; K avg from  $52.37 \pm 2.38$  to  $51.4 \pm 1.36$  D; while the CV in the keratectasia from  $415.4 \pm 9.25 \mu\text{m}$  to  $412.4 \pm 5.35 \mu\text{m}$ .

#### Conclusion:

1. After transepithelial cross-linking showed stabilization of keratoconus against the background of CVA and UCVA, decrease in corneal astigmatism and corneal refractive power.
2. The undoubted advantage of this method is that it excludes the traumatic and rather dangerous step of epithelium removal thus reducing the risk of infection and essentially excluding corneal syndrome.
3. The transepithelial cross-linking technique in keratoconus treatment improves optometric indices and stabilizes the course of the disease.

P-090

**GOOD EVOLUTION OF AN INFECTIOUS KERATITIS ON DYSTHYROID ORBITOPATHY**T Elongo, L Kora<sup>1</sup>.<sup>1</sup>*Pediatric ophthalmology, Hôpital 20 août 1953, Casablanca, Morocco*

**Objective:** Dysthyroid orbitopathy is an autoimmune disease that is the most common extra-thyroid manifestation. It is the result of a cross auto-reactivity between thyroid antigens and orbital tissue. It can be seen in a context of hyperthyroidism most frequently (basedow's disease). Severe forms threaten the visual prognosis in the very short term by optic neuropathy or corneal damage

**Methods:** We report the clinical observation of a patient who presented infectious keratitis on dysthyroid orbitopathy

**Results:** 39-year-old woman who has had a painful right red eye with decreased visual acuity for two (2) days. She has the following pathological history: hyperthyroidism on disease basedow's orbitopathy for 15 years on corticosteroid treatment and betablockers, pulmonary embolism 1 year ago on anticoagulant, type 2 diabetes for 6 months on insulin. She has been hospitalized in the endocrinology department since 1 week for diabetic ketosis following an acute thyrotoxic crisis. On ophthalmologic examination of the right eye we found: 20/200 of visual acuity Inflammatory exophthalmos with lagophthalmos. A central corneal ulcer with epithelial infiltrate, corneal edema, keratic precipitates, hypopion lamina, anterior chamber cells and posterior synechiae, pupillary myosis ,the fundus was not accessible Intraocular pressure was high. A corneal sample and an ocular ultrasound were performed. Management was carried out in collaboration with endocrinologists. The clinical course under treatment is good

**Conclusion:** Infectious keratitis occurring in active dysthyroid orbitopathy is a sign of seriousness. Such a case requires urgent multidisciplinary management in collaboration with endocrinologists for a better visual prognosis.

**P-091****WHEN CROSSLINKING GETS COMPLICATED**T Elongo.

**Objective:** Corneal collagen crosslinking is a non-invasive technique that changes the biomechanical properties of the corneal stroma. It helps stop the progression of keratoconus. This commonly performed surgery is not without risk and can lead to secondary corneal infection. Corneal collagen crosslinking is a non-invasive technique that changes the biomechanical properties of the corneal stroma. It helps stop the progression of keratoconus. This commonly performed surgery is not without risk and can lead to secondary corneal infection.

**Methods:** We report the clinical observation of a 32-year-old female patient who presented with a painful right red eye following corneal collagen crosslinking.

**Results:** 32-year-old woman with Down's syndrome, followed for 6 months in our department for progressive bilateral keratoconus as well as allergic conjunctivitis. She benefited from an epi-off corneal collagen crosslinking in her right eye, which went without incident. On the 2nd postoperative day, she presented with a painful right red eye with purulent secretions. On ophthalmologic examination we find three (3) epitheliostromal abscesses each measuring 1.6mm by 1.2mm. A corneal sample was taken, showing a coagulase negative staphylococcus. The infectious risk factor found is the notion of eye rubbing in a patient who is not very complacent in the follow-up of hygiene rules. The patient received treatment consisting of antibiotic therapy by injection, eye drops fortified with antibiotics, cycloplegia and then corticosteroid therapy. The clinical course, two (2) weeks later, is marked by an almost total thinning of the cornea.

**Conclusion:** Patients who are candidates for crosslinking must benefit from close postoperative medical monitoring in order to be able to detect complications in time and manage them effectively.

P-094

### Effects of Phacoemulsification Cataract Surgery on Corneal Endothelium and Central Corneal Thickness, Cambodian Population

D Chanthan<sup>1</sup>, M Ngy<sup>2</sup>, P Kong<sup>3</sup>, A Mar<sup>4</sup>, P Ith<sup>5</sup>.

<sup>1</sup>Ophthalmology Department, <sup>2</sup>Khmer-Soviet Friendship Hospital, <sup>3</sup>Cambodian Ophthalmological Society,

<sup>4</sup>Ophthalmology, Preah Angduong Hospital, <sup>5</sup>Faculty of Medicine, University of Health Sciences, Phnom Penh, Cambodia

**Objective:** The aim of this study is to examine the effect of phacoemulsification cataract surgery on corneal endothelial cell density and central corneal thickness on adult Cambodian population.

**Methods:** This study is designed as a retrospective study and conducted for two months period, from June 1 st to August 1 st 2020 at Khmer-Soviet Friendship Hospital, Cambodia. Populations aged over 40 with senile cataract underwent phacoemulsification. The change in the corneal endothelial cell count or density and central corneal thickness measured by specular microscope, number will be compared preoperatively, one week, and three weeks post-operatively. Participants' demographic data, related ocular information, corneal endothelial cells density and corneal thickness were recorded and analyzed by SPSS version 25.0 for Mac.

**Results:** Among 110 patients included in the study, there were 79 women (71.80%) and 31 men (28.20%). Ranging from 40 to 80 years old. The changes in average corneal thickness pre and postoperatively was 1.99% ( $p < 0.05$ ). Endothelial cell density was also significantly decreased postoperatively of 5.488% ( $p < 0.05$ ). In addition, coefficient of variation also changed in 9.301% increased ( $p < 0.05$ ), corresponding with the declined in percentage of hexagonal cells of 5.35% ( $p < 0.05$ ).

**Conclusion:** Phacoemulsification could result in significant corneal endothelial damage, despite healthy cornea and without previous surgical history and no corneal abnormalities before surgery. This is particularly important in patients with a borderline reservoir of endothelial cell, and harder nucleus density.

**P-095****Case report of Thygeson's superficial punctate keratitis**

A *Kambulyan*, D *Gogoryan*, L *Kambulyan*.

**Objective:** To present a case report of Thygeson's superficial punctate keratitis

**Methods:** Thygeson's superficial punctate keratitis is a rare chronic disorder with episodes of exacerbations and remissions. The disease is usually bilateral, onset is commonly adulthood but can affect patients of any age. Typical features of the disease include multiple, grayish white, intraepithelial corneal lesions.

**Results:** Case presentation: A 24-year-old female was admitted to "Doctor Visus" eye clinic, Vanadzor, Armenia. She was complaining of photophobia and tearing of both eyes. The past ocular history was unremarkable. She denied contact with anyone with influenza or a cold. Visual acuity was 20/30 with correction cyl (-1.0) ax60= 20/20 right eye and 20/25 with correction cyl(-0.5) ax80= 20/20. Slit lamp examination revealed multiple, grayish white intraepithelial corneal lesions in both eyes. IOP was within normal limits. The patient was diagnosed with Thygeson's superficial punctate keratitis and prescribed artificial tears QID and topical fluorometholone eye drops QID. After 1 week the symptoms and the corneal lesions disappeared. FML eye drops were tapered for one month. There was no recurrence after the withdrawal of FML eye drops. IOPs were normal in both eyes at the 3 months follow up.

**Conclusion:** Topical fluorometholone seems to be effective and safe treatment of Thygeson's superficial punctate keratitis and should be considered when there is a high risk of long term steroid treatment.

P-096

**Case report of Thygeson's superficial punctate keratitis**

A *Kambulyan*, L *Kambulyan*, D *Gogoryan*.

**Objective:** To present a case report of Thygeson's superficial punctate keratitis

**Methods:** Thygeson's superficial punctate keratitis is a rare chronic disorder with episodes of exacerbations and remissions. The disease is usually bilateral, onset is commonly adulthood but can affect patients of any age. Typical features of the disease include multiple, grayish white, intraepithelial corneal lesions.

**Results:** Case presentation: A 24-year-old female was admitted to "Doctor Visus" eye clinic, Vanadzor, Armenia. She was complaining of photophobia and tearing of both eyes. The past ocular history was unremarkable. She denied contact with anyone with influenza or a cold. Visual acuity was 20/30 with correction cyl (-1.0) ax60= 20/20 right eye and 20/25 with correction cyl(-0.5) ax80= 20/20. Slit lamp examination revealed multiple, grayish white intraepithelial corneal lesions in both eyes. IOP was within normal limits. The patient was diagnosed with Thygeson's superficial punctate keratitis and prescribed artificial tears QID and topical fluorometholone eye drops QID. After 1 week the symptoms and the corneal lesions disappeared. FML eye drops were tapered for one month. There was no recurrence after the withdrawal of FML eye drops. IOPs were normal in both eyes at the 3 months follow up.

**Conclusion:** Topical fluorometholone seems to be effective and safe treatment of Thygeson's superficial punctate keratitis and should be considered when there is a high risk of long term steroid treatment.

P-097

### Femtosecond intrastromal keratoplasty with corneal segment implantation in keratoconus

S Bekirova, I Saliev<sup>1</sup>.

<sup>1</sup>Saif-Optima, Tashkent, Uzbekistan

**Objective:** Keratoconus (KC) is the most common form of corneal ectasia with progressive thinning, protruding, clouding and scarring of the cornea, resulting in increased myopia and astigmatism. Currently, various treatment options are available. A smoother and more leveled corneal surface is achieved moving the ectased area toward the center. When IRSs are to be used, the central corneal area must be transparent.

**Methods:** IRS implantation was performed in 51 patients (61 eyes) aged 20 - 42 years with keratoconus stage II and III according to the Amsler classification. The patients were divided into 2 groups. Group 1 included 30 patients (35 eyes) to whom intrastromal corneal tunnel was formed using a femtosecond laser. Group 2 included 21 patients (26 eyes) whose tunnel was formed by the conventional method. Visual acuity of the patients was assessed before and after the operation both without correction and with maximum correction (Log MAR); refractometry, biomicroscopy were made to all of them. Topographic keratometry and pachymetry were performed using WaveLight Oculyzer II anterior segment analyzer, CASIA 2. In all cases of IRS implantation, the calculation was performed according to the Keraring nomogram (Calculation Guidelines).

**Results:** In the both groups of patients, postoperative corneal refraction changed from  $54,39 \pm 1,50$  to  $53,18 \pm 1,25$  in 1 group and  $51,14 \pm 1,26$  to  $47,9 \pm 0,9$  in 2 group the central zone according to the Kmax topographic study. The astigmatism degree decreased with a mean change of 2.62 D in group 1 and 1.62 D in group 2; the spherical equivalent decreased by 2.17 and 2.08, respectively. Uncorrected visual acuity increased with a mean change from  $1.1D \pm 1.4$  to  $0.5 D \pm 1.3$  in-group 1 and from  $1.2 D \pm 1.4$  to  $0.6 D \pm 1.5$  in-group 2, while with maximum spectacle correction it improved by from  $1.0D \pm 1.3$  to  $0.2D \pm 0,8$  and from  $1.1D \pm 1.4$  to  $0.3D \pm 1.3 D$ , respectively.

#### Conclusion:

1. IRS implantation reduces the spherical and astigmatic components of refraction which in turn leads to an increase in both uncorrected and corrected with spectacle lenses visual acuity.
2. The surgery should be considered as an alternative option in the correction of refractive errors when rigid contact lenses cannot be prescribed.
3. Refraction results depend on the surgical technique. The main advantage of femtosecond laser application is a technical simplification of intraoperative intrastromal tunnel creation and absence of complications.

P-100

**Catarrh with no Epidemiological Bar- A rare Case of Vernal Keratoconjunctivitis in a young female**

T Kumar, A Onkar<sup>1</sup>, M Kumar<sup>2</sup>.

<sup>1</sup>OPHTHALMOLOGY, <sup>2</sup>student, All India Institute of Medical Sciences Deoghar, Deoghar, India

**Objective:** To report a rare case of vernal keratoconjunctivitis in a 21 year old female, diagnosed by undergraduate trainee during clinical posting

**Methods:** A 21 year female reported to Ophthalmology outpatient department with complaints of severe itching with ropy discharge for past 4 years. She has had repeated episodes, which worsen during summers. Personal and past family history was insignificant for any systemic or chronic disease. She had been on treatment for allergic conjunctivitis for past 2 years with inconsistent relief of symptoms. On examination, bilateral circumferential limbal coalescent gelatinous nodules were observed along with conjunctival pigmentation and cobblestone papillae in superior tarsal conjunctiva

**Results:** Mixed limbal and tarsal vernal keratoconjunctivitis (VKC) was diagnosed and tacrolimus ointment was started with excellent clinical and symptomatic improvement

**Conclusion:** This case reports a rare occurrence of all features of vernal keratoconjunctivitis in a patient nonconforming to the epidemiological domain of the disease (female patient in third decade of her life), diagnosed by an undergraduate medical trainee during ophthalmic clinical postings, leading to prompt institution of appropriate therapy and resolution of symptoms



**P-101****A case of endophthalmitis after penetrating keratoplasty**

X Wu, H Dong<sup>1</sup>.

<sup>1</sup>*Ophthalmology, The Third People's Hospital of Dalian, Dalian, People's Republic of China*

**Objective:** The patient had undergone intraocular lens(IOL) implantation 20 years ago, resulting in keratoleukoma. Now he underwent penetrating keratoplasty, and developed postoperative endophthalmitis.

**Methods:** Symptoms and signs: The patient's left eye visual acuity was photosensitive before surgery. The second day after penetrating keratoplasty, the patient's left visual acuity decreased rapidly, with ache, severe conjunctival congestion, slight edema of the corneal graft, Tyndall(+), floccular exudation observed in the anterior and temporal lower part of the IOL, and white turbidities observed behind the IOL. Color doppler ultrasonography showed dense punctured weak echo suspension in the left eye vitreous cavity.

Diagnosis method: The patient was diagnosed as endophthalmitis by medical history, clinical symptoms and signs, auxiliary examination, intraoperative observation and microbial detection, and the disease was suspected to be caused by enterococcus faecalis, a latent opportunistic pathogen triggered by surgery.

**Results:** After timely and adequate drug and surgical treatment, the patient successfully preserved the eyeball and part of the visual function, and the follow-up situation was stable 4 months after surgery.

**Conclusion:** The endophthalmitis of Enterococcus faecalis should be controlled by enough vancomycin, and be treated by vitrectomy with removing IOL and bag as soon as possible. This case reflects the importance of the patient's past medical history, surgical history and case data.

P-102

### Corneal Haze After Fireworks-inflicted Ocular Injury in an Eye with Previous Laser In Situ Keratomileusis

B Wu, Q wang, L wang.

**Objective:** To report a case of corneal haze after fireworks-inflicted ocular injury in an eye with previous laser in situ keratomileusis(LASIK).

**Methods:** case report.

**Results:** A 30-year-old man underwent an uneventful LASIK in 2013. his postoperative uncorrected distance visual acuity (UDVA) was 20/20 in both eyes.He then underwent left eye fireworks-inflicted ocular injury by in January 2022.Amniotic membrane graft transplantation was performed immediately at the outside hospital.The patient complained decreased vision after surgery.He presented to our clinic in February 2022.His UDVA at presentation was 10/400.The corrected intraocular pressure(IOP) was 18mmHg and 32mmHg in the right and left eyes.Slit lamp examination of left eye revealed diffuse corneal edema.And anterior stromal haze was observed in his central cornea.Anterior chamber was normal and the pupil measured 8 mm and was nonreactive to light.Confocal microscopy showed corneal edema of the epithelial layer.At anterior stroma layer(about 200  $\mu$  m) there were activated corneal keratocytes.We did not observe inflammatory cell infiltration at haze zone of anterior stroma layer. Gonioscopy showed 360 degree angle recession in his left eye.The central corneal thickness (CCT) measured by Pentacam was 495 mm in the right eye and 395 mm in the left eye.The patient was treated with tobramycin/dexamethasone qid,carbetolol hydrochloride bid,brinzolamide tid,latanoprost qn,pilocarpine tid.One week later, the patient's left eye showed both improvement in visual acuity and decrease in stromal haze.The pupil measured 4 mm.UDVA was 20/50.Corrected IOP was 17mmHg.

**Conclusion:** Ocular trauma and hypertension of post-LASIK eye may damage corneal epithelial basement membrane and induce haze.The image of confocal microscopy is useful to distinguish post-LASIK haze from pressure-induced stromal keratitis(PISK).

P-103

**Infectious keratitis after laser-assisted subepithelial keratectomy originating from an undetected nasal furuncle**X Pan<sup>1</sup>, Q Wang<sup>1</sup>, J Xiao<sup>1</sup>.<sup>1</sup>Ophthalmology, Affiliated Hospital of Qingdao University, Qingdao, People's Republic of China**Objective:** To describe a 19-year-old Chinese man developed infectious keratitis on the second day after LASEK**Methods:** case report.**Results:** The patient had a furuncle on the right nasal ala that was neglected before surgery because of a face mask. Infection of the cornea due to accidental contact with germs in the skin through the hands was suspected, and *Staphylococcus aureus* was identified as the infective agent based on bacterial culture and drug susceptibility tests. Systemic and topical medication was used to control the infection, and a low dose of corticosteroids was added to the treatment when the infection was under control. The dosage of corticosteroids was increased once the infection had resolved to minimize scarring. The corneal ulcer healed completely in approximately 1 month. The patient got a vision of logMAR 0.097 eventually**Conclusion:** Facial skin especially the area covered by the mask should be checked before surgery. Timely and adequate doses of sensitive antibiotics is essential for the treatment. Appropriate use of corticosteroids can promote healing and reduce scarring.

**P-104****Two cases of acute corneal edema in diabetic patients**

M Xu<sup>1</sup>, S Wu<sup>1</sup>, L Yang<sup>1</sup>, Y Han<sup>1</sup>, Y He<sup>1</sup>, F Zhao<sup>1</sup>, X Niu<sup>1</sup>.

<sup>1</sup>Aier eye hospital of Wuhan university, Wuhan, People's Republic of China

**Objective:** To report two cases of acute corneal edema in diabetic patients with poor glyceemic control.

**Methods:** Case 1 was a 60-year-old male patient who had a history of diabetes, hypertension and heart disease, and had not been treated. Patient underwent slit-lamp examination, Anterior segment OCT, UBM, B ultrasound, Keratoendoscope, random blood glucose and other examinations. Case 2 was a 28-year-old male patient who had a history of diabetes and was treated with oral medication. However, due to his love of sugary drinks, the blood glucose control was poor. He repeatedly had symptoms of blurred vision in both eyes and the symptoms could be relieved without treatment. Patient also underwent the examination above.

**Results:** In case 1, the slit-lamp examination found that uniform edema of the whole cornea and uniform white opacity in the deep stroma layer in the patient's left eye. Anterior segment OCT showed the cornea of the left eye was uniformly thickened, with a central thickness of 653  $\mu$  m, uniform high reflectance can be seen behind. The UBM in the left eye showed a small amount of flocculent exudation in the lower iris and surface of the lens. Patient's random blood glucose was up to 26mmol/L. In case2, the slit-lamp examination found that uniform edema of the whole cornea and uniform white opacity in the deep stroma layer of the lower cornea in the patient's right eye. Corneal endothelial folds. Flocculent exudation was observed on the anterior surface of the lens. Anterior segment OCT showed the cornea of the right eye was uniformly thickened, with a central thickness of 700  $\mu$  m, uniform high reflectance can be seen behind; Patient's fasting plasma glucose was up to 15mmol/L. The two patients' keratoendoscope showed, the density of corneal endothelial cells was normal, the cells were vary in size in both eyes. Both patients were given topical glucocorticoid and dilated eye drops. The corneas of the two patients were completely transparent within 3 days, and the flocculent exudation in anterior chamber disappeared.

**Conclusion:** While we cannot prove that these symptoms are caused by or directly related to Higher blood glucose, we did not find any other plausible cause that could explain these ophthalmic signs. Both the patients had poorly controlled hyperglycemia, therefore, we considered that the acute corneal edema was related to hyperglycemia in the two patients.

P-105

**Blood Urine Skin and the eye**G Budhiraja.

**Objective:** To investigate and approach the diagnosis of a case of a 31 year old female with history of redness and pain from her left eye since one week noted in both eyes.

She had a history of being treated elsewhere for anterior scleritis one month back.

She had pigmentary changes in skin over face, head, hands & feet. Her fingers were distorted in both hands.

**Methods:** On slit lamp examination, stromal edema with adjacent scleral thinning of around 80% was noted in both eyes.

There was a similar family history in her brothers.

A provisional diagnosis of bilateral sclerokeratitis with a differential diagnosis of porphyria was made.

She was investigated for porphyrins in her urine, which was positive and skin biopsy confirmed porphyria.

**Results:** She was treated with short course of topical steroids for her eyes & she responded to treatment and her management by done with a joint collaboration of dermatologist and ophthalmologist.

She was also instructed to avoid sunlight and this helped in her treatment.

**Conclusion:** Porphyrias are group of disorders which are easier to be missed and can delay the treatment if not diagnosed properly, which can be irreversible for many patients.

**Delay in management may lead to corneo-scleral perforation** in many patients, sometimes just leading to tectonic management and rehabilitation of many cases.

Early diagnosis and proper management in our case, has been beneficial for our patient , with very simple management like avoidance of sunlight exposure.

The management of such cases requires joint collaboration with various modalities , like dermatotologists, gastroenterologists , ophthalmologists.

Proper diagnosis and management in such patients gives gratifying results and can lead to longevity of such patients.

P-107

### A Rare Case of an Asymptomatic Extensive Corneal Descemet's Membrane Detachment

B Wu, L wang.

**Objective:** To report a rare case of an asymptomatic extensive corneal descemet's membrane detachment.

**Methods:** case report

**Results:** A 80-year-old woman presented to the hospital in April 2020, with a 3-month history of right eye visual acuity decreased, redness and swelling that had acutely worsened in the last 10 days. She denied any symptom in her left eye. Her right eye was diagnosed with glaucoma. Initiation of antiglaucomatous treatment and trabeculectomy obtained normalized IOP and anterior chamber depth. Surprisingly, patient's left ophthalmic examination showed evident membrane-like transparent flap at the central of the corneal endothelial layer. The upper portion of the flap was seen attached tightly at the endothelium, and the lower portion of the flap scrolling in anterior chamber. Linear zone of white scar was obvious on the nasal part of the flap. Past ocular history included uneventful bilateral phacoemulsification in December 2012. On detailed questioning, the patient recalled that there was steady improvement of visual acuity at the same-day and 1-month postoperative in 2012. And she denied any change or decrease in the visual acuity of her left eye after then. Confocal microscopy showed endothelial count was 602 cells/mm<sup>2</sup> in the left eyes. Confocal images of the left eye showed cells with normal appearance in the epithelial and stroma layer. The posterior interface between deep stroma and descemet membrane in flap area showed activated corneal keratocytes, scarring and inflammatory cell infiltration. Descemet's folds were noted at the margin of membrane-like lesion. Endothelial polymegathism and pleomorphism was observed outside the lesion. None of the endothelial cells were found in the membrane-like lesion except thickening descemet membrane.

**Conclusion:** We reported a extensive corneal descemet's membrane detachment without any symptoms. The possible hypothesis was timely secretion of newborn descemet's membrane would take protective effect during the slow process of the detaching of descemet's membrane, which proved by patient's unchanged visual acuity after surgery

**P-108****Double trouble- case of concurrent hordeolum with phlyctenular kerato-conjunctivitis**

S Sinha<sup>1</sup>, A Onkar<sup>2</sup>, A Agarwal<sup>1</sup>, R Bairagi<sup>1</sup>, H Dixit<sup>1</sup>.

<sup>1</sup>Student, <sup>2</sup>Ophthalmology, AllMS-Deoghar, Deoghar, India

**Objective:** To report a case of hordeolum with phlyctenular kerato-conjunctivitis, diagnosed by an undergraduate medical trainee during clinical postings.

**Methods:** A 20 year old female presented to Ophthalmology outpatient department with complaints of swelling of left lower lid with pain and photophobia. She has had repeated such episodes for past 2 years. Personal and past family history was insignificant for any systemic or chronic disease. There was no history of stickiness of eyelids, any febrile episodes or ocular trauma. On examination, an external eyelid swelling with pus point peaking at left lateral lower eyelid was noted. Dandruff like deposits were noted over eyelashes. Multiple grayish nodules were observed over inferior part of cornea. Hemogram and chest x-ray were normal and no induration was evident on tuberculin test.

**Results:** A clinical diagnosis of hordeolum with phlyctenular kerato-conjunctivitis was made and the patient started on topical steroids and systemic antibiotics with excellent resolution of lesions over a week.

**Conclusion:** This case report highlights a rare concurrent hordeolum with phlyctenular kerato-conjunctivitis diagnosed by an undergraduate medical trainee during ophthalmic clinical postings, leading to prompt institution of therapy and resolution of lesions

**P-109****Fingerprint-like Acquired Sessile Conjunctival Hemangioma**L Qu, Y Zhao, W Liu.**Objective:** Acquired sessile conjunctival hemangioma is reported.**Methods:** An case report.

**Results:** A 41-year-old man presented to an ophthalmologist with complaints of congestion in and increased secretion from the right eye. He was diagnosed with acute bacterial conjunctivitis. His visual acuity in both eyes was 20/20. Slit-lamp microscope revealed a conjunctival hemangioma on the nasal side of the left eye, which was difficult to find when viewed directly. This hemangioma had a shape of a chaotic fingerprint surrounded by sporadic pigmentation. His left eye had once been scratched by iron sand and removed decades ago. However, hemangioma was neglected. Acquired sessile conjunctival hemangioma is extremely rare and has never been reported in xanthoderm until now. There is no special treatment for this disease other than a follow-up as the disease is mostly benign, and the patient encounters no discomfort and/or disease progression latter. The patient in the present case received treatment for conjunctivitis and reassurance regarding this incidental finding.

**Conclusion:** Acquired sessile conjunctival hemangioma is reported firstly in xanthoderm.



P-121

## Comparison of the Efficacy and Safety Between Phacotrabeculectomy and Trabeculectomy in Advanced Primary Glaucoma

I Soebijantoro<sup>1</sup>, P Agaristi<sup>1</sup>, R Sulastiwaty<sup>1</sup>, A Safira<sup>1</sup>, W Wiyogo<sup>1</sup>.

<sup>1</sup>JEC Eye Hospital and Clinics, Jakarta, Indonesia

**Objective:** To evaluate the efficacy and safety, after trabeculectomy compared with combined trabeculectomy-phacoemulsification in Indonesia eyes with late-advanced stage primary glaucoma.

**Methods:** A retrospective study was performed by reviewing existing medical records. Data collection included IOP, visual acuity, visual field, optic disc ratio, retinal nerve fiber layer thickness, and the use of IOP lowering medication preoperatively and up to 6 months post operatively. Complications, if any, were also noted

**Results:** Data from 55 eyes of 47 subjects which underwent trabeculectomy (group 1) were analyzed and compared to 47 eyes of 40 subjects which underwent combined trabeculectomy-phacoemulsification (group 2). Majority of the subjects were male in both groups (65.9% in group 1 and 52.5% in group 2) with higher mean age of  $62.60 \pm 9.95$  years in group 2.

Mean IOP (mmHg) in group 1 was  $35.64 \pm 12.35$  at baseline and  $13.18 \pm 5.20$  after mean follow up of 6 months, while in group 2 was  $29.08 \pm 11.39$  at base line and  $13.89 \pm 4.17$  at last follow up. IOP reductions of  $\geq 20\%$  were achieved in 53/55 eyes (96.3%) in group 1 and 40/47 eyes (85.1%) in group 2. There was a significant difference in the mean IOP reduction in group 2 (54%) compared to group 1 (42%) ( $p < 0.05$ ). Mean medication used in group 1 declined from  $3.35 \pm 1.25$  medications per eye at baseline to  $0.76 \pm 1.12$  at last follow-up ( $p < 0.0001$ ) while in group 2 declined from  $3.91 \pm 1.25$  medications per eye at baseline to  $1.17 \pm 1.19$  at last follow-up ( $p < 0.0001$ ). Mean IOP lowering medication reduction were 34% and 23% for group 2 and group 1, respectively, but there was no significant difference between them ( $p = 0.110$ ). No vision-threatening complications were observed in both groups

**Conclusion:** Combined procedure of trabeculectomy-phacoemulsification provides better results in terms of IOP reduction and no wipe-out complication has been reported during follow-up.

P-110

## Clinical Characteristics and Surgical Outcomes of Turkish Pediatric Glaucoma Patients Who Underwent Glaucoma Surgery

H Haidar<sup>1</sup>, E Biberoglu<sup>2</sup>, M Eraslan<sup>3</sup>.

<sup>1</sup>School of Medicine, Marmara University, <sup>2</sup>Department of Ophthalmology, Marmara University Pendik Educational and Research Hospital, <sup>3</sup>Department of Ophthalmology, School of Medicine, Marmara University, Istanbul, Türkiye

**Objective:** To describe the clinical characteristics and outcomes of a pediatric cohort, surgically treated for primary or secondary pediatric glaucoma (PPG/SPG).

**Methods:** A retrospective chart review was conducted of all pediatric glaucoma patients who were operated between 2013 and 2021. Relevant demographic and clinical data were cumulated and analyzed.

**Results:** Forty-two eyes of 29 patients (18 female) were included divided into 22(52.4%) Primary Congenital Glaucoma (PCG), 7(16.7%) Juvenile Open Angle Glaucoma and 13(30.9%) SPG eyes. Mean ages at presentation were  $2.57 \pm 2.87$ ,  $131.96 \pm 27.71$  and  $62.09 \pm 65.12$  months, respectively. In this study, PCG eyes presented the earliest, with the highest Intraocular-Pressure (IOP) and thickest Central Corneal Thickness (CCT).

The mean number of glaucoma-surgeries was  $1.48 \pm 0.71$ , with 38.1% of the eyes necessitating  $\geq 2$  glaucoma-surgeries, trabeculectomy was the most frequent glaucoma-surgery in this cohort. After surgical intervention, the overall mean IOP dropped from  $32.25 \pm 12.97$  to  $18.10 \pm 9.23$  mmHg ( $p < .001$ ). Moreover, the percentage of antiglaucoma-medication users decreased from 100% to 35.7% at final visit, as did the number of medications prescribed per eye ( $2.69 \pm 0.92$  vs  $1.05 \pm 1.46$ ,  $p < .001$ ). Mean Best Corrected Visual Acuity (BCVA), in patients who could have their BCVA measured, improved from  $0.61 \pm 0.61$  to  $0.53 \pm 0.51$  (LogMAR) at final follow-up.

**Conclusion:** Surgical intervention was shown to provide a well-controlled IOP, decrease dependence on glaucoma-medication and improve BCVA in both PPG and SPG. Multiple surgical interventions may be necessary in the management of some pediatric glaucoma patients. Prognostically, thicker CCT was significantly associated with worse IOP control, more glaucoma-surgeries, and more antiglaucoma-medication at final visit. Initial BCVA correlated significantly with BCVA at final visit.

**P-111****Efficacy and Tolerance of Netarsudil Latanoprost Fixed dose combination (NLFC) in a switch study with other Glaucoma Medications**

S Sonty<sup>1,2</sup>, P Nukala<sup>1</sup>, M Erramilli<sup>1</sup>.

<sup>1</sup>*Glaucoma, Midwest Eye Centers, Calumet City,* <sup>2</sup>*Glaucoma, University of Illinois@Chicago, Chicago, United States*

**Objective:** To study the Efficacy and Tolerance of Netarsudil-Latanoprost Fixed Dose Combination(NLFC) in a switch study in Glaucomatous Eyes with inadequate IOP control in 24 Patients ( 24 OD & 24 OS ) on Glaucoma Medications ( 24 /34 Initiated)

**Methods:** 24 of 34 Glaucoma Patients (POAG 20 PACG 1 (S/P LPIS) SOAG 3 ) 17 Black 6 White & 1 Hispanic; 16M: 8F; Ages < 50 (1) 50-69 ( 12) 70-89( 11) with 24 OD & 24 OS ( 2 OD & 2 OS Only) with inadequate IOP Control on Current Anti Glaucoma medications & Switched to NLFC 23 Pts ( 20 OU, 2 OD & 1 OS ) that completed 48 wks ( 44-52 Wks) mean 12 mths were studied. 6 pts who completed 3 - 9 mths were excluded 5/34 pts discontinued due to side effects - Corneal Edema (3) Intolerance - Redness-Irritation( 1) & Body aches (3) Pre switch Glaucoma Medications switched to NLFC included Netarsudil (4) PGAs ( 7) Netarsudil & PGAs ( 8) Other Medications (4) IOPs in mm Hg were measured at Visit 0 ( Initial) Visit 1 @ 2wks ( 1-3 wks) Visit 2 @ 4 wks ( 3 -5 Wks) Visit 3 @ 12 wks ( 10-14 wks) Visit 4 @ 24 wks ( 22- 26 wks) & Visit 5 @ 48 wks ( 44 - 52 wks) after switch

**Results:** IOPs in mm Hg Visit 0 : 24.6 (12-40) OD;21.9 (10-46) OS  
 Visit 1 : 20.9 (14-34) OD ( P : 0.004) ; 19,8 (12-45 ) OS ( P:0.002)  
 Visit 2 : 21 ( 12-31 ) OD ( P: 001) ; 19.6( 12-40) OS ( P:0. 002)  
 Visit 3 : 20.5 ( 11-31) OD ( P : 0.001) ; 19.1 ( 12-40) OS ( P:0.003)  
 Visti 4 : 20.5 ( 11-31) OD ( P: 0.001) ; 20.1 ( 12-40) OS ( P : 0.002)  
 Visit 5 : 18.4 ( 11-26 ) OD ( P : 0.001) ; 16.95 ( 10-24 ) OS ( P : 0.02)  
 Preswitch Hyperemia : 0 (11) +0.5-1 ( 9) +2 ( 3) +3 ( 1)  
 Post Switch Hyperemia : 0 ( 12) +0.5-1 (6) + 2 ( 4) + 3 ( 2 )  
 Reduction in No. of Bottles : 3.2 Pre vs 2.7 Post Switch. No.Meds : 2.8 Pre vs 2.4 Post Switch

**Conclusion:**

- 1 Netarsudil Latanoprost Combination (NLFC) is better than most Single & Combination Glaucoma Medications and equal to Netarsudil and Latanoprost used separately together.
2. The Safety profile is comparable to the other Glaucoma Medications except for Corneal Edema in few patients with few exceptions where Hyperemia increased.

P-112

### 3-month retrospective analysis of goniotomy/viscodilation with novel Streamline device in primary open angle glaucoma

I Wagner<sup>1</sup>, A Ahuja<sup>2</sup>, S Dorairaj<sup>1</sup>, R Ten Hulzen<sup>1</sup>, L Checo<sup>3</sup>, P Lentz<sup>4</sup>, A Stockard<sup>4</sup>, A Patel<sup>5</sup>.

<sup>1</sup>Ophthalmology, Mayo Clinic, Jacksonville, <sup>2</sup>Florida Atlantic University- Charles E. Schmidt College of Medicine, Boca Raton, <sup>3</sup>Ophthalmology, Mayo Clinic- Research Collaborator, Jacksonville, <sup>4</sup>Mayo Clinic Alix School of Medicine, Phoenix, <sup>5</sup>Stanton College Preparatory High School, Jacksonville, United States

**Objective:** To evaluate the safety and efficacy of Streamline, a novel device capable of incising the trabecular meshwork and injecting viscoelastic into Schlemm's canal, in the treatment of primary open angle glaucoma (POAG).

**Methods:** Retrospectively reviewed POAG eyes presenting with a mild/moderate (n=29), severe (n=14), or indeterminate (n=2) diagnosis treated with standalone Streamline (SL; n=19) or combined Streamline and phacoemulsification cataract extraction (SL+CE; n=26) between December 2021 and March 2022. Intraocular pressure (IOP) and number of glaucoma medications were compared to (no washout) baseline for up to 3 months follow-up using paired sample t-tests. Groups were compared with Pearson's chi-squared tests.

**Results:** Baseline IOP (SL:  $25.3 \pm 4.9$  mmHg; SL+CE:  $18.7 \pm 4.3$  mmHg) and number of medications (SL:  $1.9 \pm 1.0$ ; SL+CE:  $0.9 \pm 0.4$ ) were established. At last follow-up (mean 1.5 months), IOP was reduced (SL: -11.3 mmHg, 45% reduction,  $p=2.2E-6$ ; SL+CE: -6.2 mmHg, 33% reduction,  $p=5.5E-6$ ) and medications were reduced (SL: -0.5 meds, 27% reduction,  $p=4.0E-3$ ; SL+CE: -0.6 meds, 70% reduction;  $p=1.3E-6$ ). Both groups achieved an IOP  $\leq 14$  mmHg (SL: 68%, SL+CE: 77%;  $p=0.52$ ), an IOP reduction of  $\geq 20\%$  (SL: 89%, SL+CE: 85%;  $p=0.64$ ), and reduction by  $\geq 1$  medication (SL: 42%, SL+CE: 62%;  $p=0.20$ ). No vision-threatening complications were observed.

**Conclusion:** With up to 3-months follow-up, goniotomy and viscodilation of Schlemm's canal with Streamline appears safe and efficacious at reducing both IOP and medication burdens in POAG patients of all severity types, regardless of phacoemulsification status.

P-116

## Network Meta-Analysis of Surgery for Neovascular Glaucoma

P Lin.

**Objective:** To compare the effectiveness and safety of the six interventions for neovascular glaucoma.

**Methods:** Randomized controlled trials and cohort studies which compared the six interventions in neovascular glaucoma were identified using the following databases searched up to 1 September 2020: PubMed, Cochrane Library, Embase, Web of Science. The quality assessment was conducted by using the Cochrane risk of bias tool and the Newcastle-Ottawa scale. The primary outcome measure was the weighted mean differences (WMDs) for intraocular pressure reduction. Secondary one was odds ratios (ORs) for success rate. Outcome measures were reported with a 95% confidence interval (CI) and  $P < 0.05$  was considered statistically significant. Network meta-analysis was performed using STATA version 15.0.

**Results:** Twenty-three studies involving a total of 1303 patients were included. The types of surgical treatments included ahmed glaucoma valve implant surgery (AGV), AGV combined with intravitreal anti-vascular endothelial growth factor (AGV+IVAV), cyclophotocoagulation (CPC), cyclocryotherapy (CCT), trabeculectomy with mitomycin (Trab(MMC)) and Trab(MMC) combined with IVAV (Trab(MMC)+IVAV). Network meta-analysis showed that in comparison with AGV, AGV+IVAV (MD=4.74, 95%CI 1.04 to 8.45) and Trab(MMC)+IVAV (MD=6.19, 95%CI 0.99 to 11.40) showed a favorable effect in intraocular pressure reduction (IOPR) 6 months after surgery. Compared with CCT, AGV (OR=-0.17, 95%CI -0.53 to -0.05), AGV+IVAV (OR=-0.10, 95%CI -3.48 to -1.19), CPC (OR=-0.12, 95%CI -0.53 to -0.05), Trab(MMC) (OR=3.54, 95%CI 1.15 to 10.91), Trab(MMC)+IVAV (OR=5.78, 95%CI 2.29 to 14.61) showed a superior impact in success rate. The order of efficacy as best intervention ranked as follows: Trab(MMC)+IVAV (IOPR 6 months after surgery, SUCRA=88.1), CPC (IOPR 12 months after surgery, SUCRA=81.9), AGV+IVAV (IOPR 12 months after surgery, SUCRA=79.9), AGV+IVAV (success rate, SUCRA=92.7). Adverse events were also summarized in detail.

**Conclusion:** In the treatment of neovascular glaucoma, AGV+IVAV and CPC were more effective in IOPR and success rate than the other four interventions. Additionally, AGV+IVAV is superior to CPC concerning the success rate in the long-term treatment. However, considering the limitations of this review, more high-quality trials, especially those surgical interventions not mentioned in this review, should be carried out in the future to further confirm the current findings.

P-117

**Pharmacotherapeutic Effect of Original Liposomal Latanoprost Composition in Experimental Glaucoma**

I Mikheyseva<sup>1</sup>, G Grigorieva<sup>2</sup>, N Pasechnikova<sup>1</sup>, S Kolomiichuk<sup>1</sup>, N Konakhovich<sup>2</sup>.

<sup>1</sup>Filatov Institute of Eye Diseases, Odessa, <sup>2</sup>Institute of Pharmacology and Toxicology, Kyiv, Ukraine

**Objective:** **Objective** - to establish the dynamics of intraocular pressure (IOP) with time and the duration of the hypotensive effect of the original latanoprost (LP) composition on a liposomal phospholipid's platform applied by eye drops instillations into the conjunctiva sac and subconjunctival injection for the experimental glaucoma (EG).

**Methods:** Ophthalmic experiments were carried out on Chinchilla rabbits (1 year old, weighing 2.5 - 3 kg). It was performed in compliance with European Convention for the Protection of Vertebrate Animals Used for Experimental and Other Scientific Purposes from the European Treaty Series (Strasbourg, 1986). The rabbits were divided into four groups: Group I - EG was simulated and treated with eye drops of liposomal form of LP; Group II - EG was modeled and treated with subconjunctival administration of liposomal form of LP; Group III - EG was modeled without treatment; Group IV - intact control. EG was induced by two injections of 0.1 ml of 0.3% carbomer in isotonic solution into the anterior chamber of the eyes at 10 days interval. Subconjunctival administration of the liposomal form of LP was applied by a 0.1 ml single injection immediately after the formation of the EG. Treatment of animals with eye drops of liposomal form of LP was carried out daily in the evening, one drop in both eyes. Follow-up duration was 10 weeks. IOP monitoring was carried out at key stages of the experiment for each group of animals.

**Results:** A study of the pharmacological efficacy and duration of action of the original liposomal form of LP was carried out on the EG model in rabbits administered by different routes. After EG modeling was performed (Group III), there was a persistent increase in IOP, with the IOP values being 51-65% higher than at control Group IV ( $p < 0.001$ ). The IOP in animals with EG treated daily with LP instillations (Group I) was 31% lower than in untreated EG (Group III) ( $p < 0.001$ ). A single subconjunctival injection of LP resulted in a 37% reduction of IOP in Group I compared to untreated animals in EG ( $p < 0.001$ ), with the effect being as long as 10 weeks.

**Conclusion:** The results obtained in the experiment on the EG model indicated a significant hypotensive effect of long-term eye drops instillations and a single subconjunctival injection of the original latanoprost composition on a liposomal phospholipid's platform with an emphasis on the effect of a single subconjunctival injection of the medicine, which is clearly prolonged up to 10 weeks.

P-118

### Comparison of the effects between a selective EP2 agonist, Omidenepag, with PGF2 $\alpha$ , on TGF $\beta$ 2-treated human trabecular meshwork cell

S Suzuki<sup>1</sup>, M Watanabe<sup>1</sup>, M Furuhashi<sup>2</sup>, Y Ida<sup>1</sup>, A Umetsu<sup>1</sup>, Y Tsugeno<sup>1</sup>, F Hikage<sup>1</sup>, H Ohguro<sup>1</sup>.

<sup>1</sup>Department of Ophthalmology, School of Medicine, Sapporo Medical University, <sup>2</sup> Departments of Cardiovascular, Renal and Metabolic Medicine, Sapporo Medical University, Sapporo, Japan

**Objective:** Two and three-dimensional (2D and 3D) cultures of TGF- $\beta$  2-treated human trabecular meshwork (HTM) cells were used to study the drug effects of the EP2 agonist omidenepag (OMD) and prostaglandin F2  $\alpha$  (PGF2  $\alpha$ ) on glaucomatous HTM.

**Methods:** We performed following analyses;1) transendothelial electrical resistance (TEER) and FITC dextran permeability measurements (2D), 2) the size and stiffness of the 3D spheroids, and 3) the expression (both 2D and 3D) by several extracellular matrix (ECM) molecules including collagen (COL) 1, 4 and 6, and fibronectin (FN), and  $\alpha$  smooth muscle actin ( $\alpha$  SMA), tight junction (TJ) related molecules, claudin11 (Cldn11) and ZO1, the tissue inhibitor of metalloproteinase (TIMP) 1-4, matrix metalloproteinase (MMP) 2, 9 and 14, connective tissue growth factor (CTGF), and several endoplasmic reticulum (ER) stress-related factors.

**Results:** TGF- $\beta$  2 significantly 1) increased TEER values of 2D HTM monolayers, 2) decreased FITC dextran permeability, and 3) induced smaller and stiffer 3D HTM spheroids. Such TGF- $\beta$  2-induced changes in TEER levels and FITC-dextran permeability were remarkably inhibited by PGF2  $\alpha$  but not by OMD. In addition, PGF2  $\alpha$  increased the size and stiffness of TGF- $\beta$  2-treated 3D spheroids, while OMD increased only spheroid size. Exposure to TGF- $\beta$  2 significantly increased the expression of most of the molecules evaluated, except for some of the ER stress-related factors, which were downregulated. TJ-related molecules or ER stress-related factors were significantly upregulated (2D) or downregulated (3D) by PGF2  $\alpha$  and OMD, and both drugs differentially altered the expression of several other genes in the 3D spheroids.

**Conclusion:** The results suggest that PGF2  $\alpha$  and OMD regulate the permeability of TGF  $\beta$  2-modified 2D monolayers and the physical properties of 3D HTM spheroids in different ways.

P-119

**Human Trabecular Meshwork Model for Primary open angle glaucoma and steroid glaucoma in 3D cell culture**

M Watanabe<sup>1</sup>, Y Ida<sup>1</sup>, Y Tsugeno<sup>1</sup>, S Suzuki<sup>1</sup>, A Umetsu<sup>1</sup>, F Hikage<sup>1</sup>, H Ohguro<sup>1</sup>.

<sup>1</sup>Ophthalmology, Sapporo Medical University, Sapporo, Japan

**Objective:** To establish a reliable *in vitro* cell culture model of primary open angle glaucoma (POAG) and steroid glaucoma (SG) using human trabecular meshwork (HTM) cells.

**Methods:** 2D and 3D cultured HTM cells were exposed to 5 ng/mL transforming growth factor (TGF)  $\beta$  2 or 250 nM dexamethasone (DEX) for six days. Then, those are characterized as follows; 1) barrier functions of the 2D HTM monolayers by transendothelial electrical resistance (TEER) measurements and FITC dextran permeability, 2) scanning electron microscopy (SEM) of the 2D and 3D cultured HTM cells, 3) physical properties, size and stiffness of the 3D HTM spheroids, and 4) the expression of the extracellular matrix (ECM) including collagen (COL) 1, 4, 6, and fibronectin (FN),  $\alpha$  - smooth muscle actin ( $\alpha$  -SMA) by quantitative PCR (qPCR) and immunostaining.

**Results:** Upon administering DEX or TGF  $\beta$  2, a significant or mild increase in the TEER values and a decrease in the FITC dextran permeability, respectively, 2) a mild or significant increase of the ECM deposit of the 2D and 3D HTM cells, respectively, and 3) a mild and significant downsizing and an increase in stiffness, respectively. Furthermore, mRNA expressions indicated that DEX induced a significant up-regulation of FN (3D), and TGF  $\beta$  2 induced a significant up-regulation of COL1 and 4, FN,  $\alpha$  -SMA (2D), and COL1, 6 (3D). While in contrast, immunostaining of the 3D spheroids indicated that only FN expression was significantly increased by TGF  $\beta$  2.

**Conclusion:** The findings presented herein indicate that our DEX-treated or TGF  $\beta$  2-treated 2D and 3D HTM cells caused different biological aspects and therefore, these may serve as a possible models replicating SG or POAG HTM



## P-120

**Efficacy of microcatheter-assisted trabeculotomy on secondary glaucoma after congenital cataract surgery**

W Zhang, Y Qi<sup>1</sup>.

<sup>1</sup>Ophthalmology, the First Affiliated Hospital of Zhengzhou University, Henan Province, People's Republic of China

**Objective:** To evaluate efficacy of microcatheter-assisted trabeculotomy (MAT) in eyes with secondary glaucoma after congenital cataract surgery and explore its correlation with the different degree of trabeculotomy.

**Methods:** A retrospective analysis was conducted on patients who underwent the said procedure between December 2019 and December 2020. The patients were classified into two groups according to the degree of trabeculotomy (group 1:  $\leq 240$ -degree; group 2: 240–360-degree). The intraocular pressure and anti-glaucoma drugs before and after operation was collected during the 12-month follow-up.

**Results:** We reviewed 27 eyes of 25 patients: 11 (40.7%) eyes in group 1 and 16 (59.3%) eyes in group 2. The mean preoperative IOP of all patients was  $34.67 \pm 9.18$  mmHg with that at 1 day, 1 week, 1, 3, 6 and 12 months after surgery were  $8.74 \pm 4.32$ ,  $9.95 \pm 5.65$ ,  $14.39 \pm 5.30$ ,  $16.02 \pm 4.37$ ,  $15.82 \pm 3.28$  and  $16.19 \pm 3.56$  mm Hg respectively. In all patients, there were significant differences in intraocular pressure at each time point ( $F = 65.614$ ,  $P < 0.01$ ). The intraocular pressure at each follow-up point was lower than that before surgery (all  $P < 0.01$ ). In each group, intraocular pressure after surgery was also lower than that before surgery (all  $P < 0.01$ ), but there was no difference in the rate of intraocular pressure reduction between the two groups ( $P = 0.246$ ). Furthermore, the amount of anti-glaucoma medications reduced to  $0.30 \pm 0.67$  (0–2) at 12 months from  $2.63 \pm 0.49$  (2–3) preoperatively ( $P < 0.01$ ), and there was no difference between the two groups ( $P > 0.05$ ). At the end of follow-up, the partial success rate was 81.8% in group 1 versus 93.75% in group 2 ( $P = 0.549$ ). All patients developed different degrees of intraoperative and postoperative hyphema, which could be spontaneously absorbed or cleaned through paracentesis and irrigation for hyphema. No other serious complications was observed.

**Conclusion:** MAT can effectively reduce IOP in patients with secondary glaucoma after congenital cataract surgery with providing a high success rate and safety. And it can be used as the first choice for the treatment of secondary glaucoma after surgery for congenital cataracts.

P-123

### Evaluation of the Effect of the Phaco-iStent vs Phacocanaloplasty on Corneal Endothelial Cell Loss - early outcomes.

K Gołaszewska<sup>1</sup>, I Obuchowska<sup>1</sup>, E Saeed<sup>1</sup>, J Konopińska<sup>1</sup>.

<sup>1</sup>Ophthalmology, Medical University of Białystok, Białystok, Poland

**Objective:** The aim of the study was to compare early surgical outcomes of the effect of the iStent bypass implantation combined with phacoemulsification versus phacocanaloplasty on corneal endothelial cell loss (CECL) and changes in anterior chamber depth (ACD) in patients with open-angle glaucoma (OAG).

**Methods:** A retrospective chart review were conducted including consecutive adult patients with OAG that underwent iStent bypass implantation combined with phacoemulsification or phacocanaloplasty between January 2015 and November 2021. The study took place in Department of Ophthalmology Medical University of Białystok, Poland. Primary outcomes measures included intraocular pressure (IOP) reduction and number of glaucoma medication. Secondary outcome measures were best-corrected visual acuity (BCVA), endothelial cell density (ECD) and changes of anterior chamber depth (ACD) and complications rate. A total of 108 eyes (108 patients) with primary and pseudoexfoliative OAG were included in the study; of these, 63 eyes were implanted with the iStent device and 45 eyes were treated with phacocanaloplasty.

**Results:** The preoperative IOPs were  $18.30 \pm 4.39$  (mean  $\pm$  standard deviation) mmHg and  $15.14 \pm 4.73$  mmHg in the iStent and canaloplasty groups, respectively ( $p=0.002$ ). At the end of follow up IOP decreased to  $15.50 \pm 4.31$  mmHg and  $15.00 \pm 4.2$  mmHg in the iStent and canaloplasty groups, respectively ( $p=0.498$ ). All patients' eyes in both groups became medication-free by 6 months follow-up. Preoperatively, ECD was  $2\ 185.48 \pm 430.06$  and  $2\ 253.56 \pm 370.89$  in iStent and canaloplasty groups, respectively ( $p=0.524$ ). After 6 months of observation, ECD in the iStent and canaloplasty groups was  $1\ 498.50 \pm 481.95$  and  $1\ 888.47 \pm 620.17$  ( $p=0.222$ ), respectively. Mean baseline ACD was  $2.99 \pm 0.50$  and  $3.32 \pm 0.49$  in the iStent and canaloplasty groups, respectively ( $p=0.116$ ). At the end of 3 months follow up ACD increased to  $4.94 \pm 0.66$  and  $4.30 \pm 1.00$  in the groups I and II, respectively ( $p=0.194$ ). All eyes in both groups maintained or showed improved BCVA versus baseline. Safety outcomes were comparable between groups.

**Conclusion:** iStent bypass implantation combined with phacoemulsification offers better results in IOP reduction at 6 months and more significant anterior chamber deepening at 3 months than phacocanaloplasty. Phacocanaloplasty offers better results of ECD at 6 months after operation. Both types of treatments are effective in lowering medication with a favorable and comparable safety profile over a 6-months follow-up in OAG.

P-124

### Analysis of the Interleukin-1 $\alpha$ (-889) Locus Polymorphism and Serum IL-1 $\alpha$ Levels with the Severity of Normal Tension Glaucoma

Y Wu<sup>1</sup>, C Wang<sup>1</sup>.

<sup>1</sup>Ophthalmology, Taichung Veterans General Hospital, Taichung, Taiwan, China

**Objective:** Factors other than elevated intraocular pressure are likely to have a role in the pathogenesis of glaucomatous optic neuropathy, particularly in individuals with normal tension glaucoma (NTG). Interleukin-1(IL-1), has been linked to the pathogenesis of glaucoma and may regulate RGC survival or death. The IL-1 $\alpha$  (-889) T allele has also been shown to increase the IL-1 $\alpha$  protein. We hypothesized that the IL-1 $\alpha$  (-889) polymorphism may be a genetic factor predisposing affected the severity of glaucoma. The aim of the present study is to evaluate IL-1 $\alpha$  polymorphism and serum IL-1 $\alpha$  levels as a potential risk factor related to the severity of NTG.

**Methods:** 367 people with NTG in the Taiwanese population were enrolled. Patients were genotyped for the IL-1 $\alpha$  (-889) C/T polymorphism. Genomic DNA was amplified by a polymerase chain reaction, followed by the enzymatic restriction fragment length polymorphism technique. Serum IL-1 $\alpha$  levels was measured by ELISA. The associations between genotypes of IL-1 $\alpha$  (-889) C/T and the clinical parameters were calculated using a logistic regression.

**Results:** IL-1 $\alpha$  (-889) TT genotype in NTG patients was a significant association with larger C/D ratio , smaller RA and thinner RNFL (p=0.04) than IL-1 $\alpha$  (-889) CC patients. Serum IL-1 $\alpha$  levels were higher in advanced stages than in early-moderate stages. ( $6.76 \pm 3.42$  pg/ml v.s.  $3.12 \pm 2.53$  pg/ml).

**Conclusion:** The IL-1 $\alpha$  (-889) TT genotype is associated with larger C/D ratio, smaller RA, and thinner RNFL than IL-1 $\alpha$  (-889) CC in NTG patients. IL-1 $\alpha$  (-889) C/T polymorphism and serum IL-1 $\alpha$

P-127

**Switching orders of Prostaglandin F2 and EP2 agonists exert different effects on 3D 3T3-L1 spheroids**

Y Ida, A *Umetsu*, M *Watanabe*, F *Hikage*, H *Ohguro*.

**Objective:** To elucidate the effects of switching a PGF2  $\alpha$  agonist, bimatoprost acid (BIM-A), to an EP2 agonist (Omidenepag; OMD, butaprost; Buta) or reversing the switching on adipose tissue, two-dimensional (2D) and three-dimensional (3D) cultures of 3T3-L1 cells were analyzed.

**Methods:** Two-dimensional (2D) and three-dimensional (3D) cultures of 3T3-L1 cells were analyzed by lipid staining and according to the mRNA expression of adipogenesis-related genes (*Ppar  $\gamma$* , *Ap 2*, and *Leptin*), components of the extracellular matrix (ECM; *collagen 1 (Col 1)*, *Col 4*, *Col 6*, and *fibronectin (Fn)*), and the sizes and stiffness of the 3D spheroids.

**Results:** Switching from BIM-A to EP2 agonists caused (1) suppression of lipid staining and downregulation of most adipogenesis-related genes, (2) smaller and stiffer 3D spheroids, and (3) upregulation of Col1 and Fn, downregulation of *Col 4* (2D), or up-regulation of all ECM genes (3D, BIM-A to OMD), as well as downregulation of *Col 6* (3D, BIM-A to Buta). In contrast, reversing the switching resulted in (1) an enhancement in lipid staining (2D) and a significant upregulation of adipogenesis-related genes (2D, 3D Buta to BIM-A), (2) larger and slightly stiffer 3D spheroids, and (3) upregulation of Col1 and Fn (2D).

**Conclusion:** These collective findings indicate that the switching orders of BIM-A and EP2 agonists significantly affect lipid metabolism, ECM expression, and the physical stiffness of 3T3-L1 cells.

P-128

**ROCK inhibitors induce larger and lipid-enriched 3D 3T3-L1 cells spheroids**A Umetsu, Y Ida<sup>1</sup>, M Watanabe<sup>1</sup>, F Hikage<sup>1</sup>, H Ohguro<sup>1</sup>.<sup>1</sup>Ophthalmology, Sapporo Medical University, Chuoku, Sapporo City, Hokkaido, Japan

**Objective:** After the recent discovery of prostaglandin-associated peri-orbitopathy, a great interest has been paid concerning the adverse effects of anti-glaucoma medications on orbital fatty tissue, especially their adipogenesis. In the present study, among several anti-glaucoma medications, in order to study the Rho-associated coiled-coil-containing protein kinase inhibitor (ROCK-i) including Ripasudil and Y27632 on the adipogenesis of the fatty tissue, two- or three-dimension (2D or 3D) cultures of the 3T3-L1 cells were employed.

**Methods:** 1) 2D cultures of 3T3-L1 cells were prepared with or without adipogenic differentiation for seven days. The effects of ROCK-i were studied by lipid staining, and quantitative Polymerase Chain Reaction (qPCR) of extracellular matrix (ECM) – related genes (*Col1*, *Col4*, *Col6*, and *fibronectin*) and adipogenesis-related genes (*Ppar γ*, *Ap2*, *Cebpa*, and *Leptin*). 2) 3D cultures of 3T3-L1 cells were prepared with or without adipogenic differentiation for seven days, during which their ultrastructure and physical stiffness were analyzed by electron microscopy and a micro-squeezer, respectively. The effects of ROCK-i on 3D spheroid sizes, lipid staining, physical stiffness, and the mRNA expression of the several related genes were analyzed as above.

**Results:** Ultrastructure by electron microscopy and physical stiffness measurements by a micro-squeezer demonstrated that the 3D spheroids had essentially matured during the 7-day culture. The effects of ROCK-i on 3D spheroid sizes, lipid staining, the mRNA expression of adipogenesis related genes, *Pparg*, *Cebpa* and *Leptin*, and extracellular matrix (ECM) including collagen (COL) 1, 4 and 6, and fibronectin, and physical stiffness were then conducted. Upon adipogenesis, the sizes, lipid staining and mRNA expressions of adipogenesis related genes, *Col 4* and *Col 6* were dramatically increased, and were further enhanced by ROCK-i. Micro-squeezer analysis demonstrated that adipogenesis resulted in a markedly less stiffed 3D spheroid and this was further enhanced by ROCK-i.

**Conclusion:** Our present study indicates that ROCK-i significantly enhanced the production of large lipid-enriched 3T3-L1 3D spheroids.

P-129

### Real-World Surgical Outcomes of Ahmed Glaucoma Valve Implantation in Asian Eyes

B C Ang<sup>1</sup>, V Lee<sup>1</sup>, R Sim<sup>2</sup>, A Lim<sup>3</sup>, M Tien<sup>1</sup>, O Hee<sup>1</sup>, B Lim<sup>1</sup>, V Yong<sup>1</sup>, H Wong<sup>1</sup>, L Yip<sup>1</sup>.

<sup>1</sup>Department of Ophthalmology, National Healthcare Group Eye Institute, Tan Tock Seng Hospital, <sup>2</sup>Department of Ophthalmology, Singapore National Eye Centre, <sup>3</sup>Woodlands Health Campus, Singapore, Singapore

**Objective:** To evaluate surgical outcomes, efficacy and safety, as well as factors associated with surgical failure after Ahmed Glaucoma Valve (AGV) implantation in Asian eyes.

**Methods:** A retrospective, single-institution, multi-surgeon review of eyes which underwent AGV implantation from January 2001 to October 2017. Outcomes included intraocular pressure (IOP), number of IOP-lowering medications and complications. Multivariate regression analyses were performed adjusting for age, gender, ethnicity, glaucoma type, history of trabeculectomy surgery, intraoperative mitomycin-C (MMC) use, pre-operative IOP and number of pre-operative glaucoma medications.

**Results:** 150 eyes were included for analysis. Mean follow-up period was  $67.5 \pm 47.6$  months. By the 10-year post-operative timepoint, the median IOP reduced from 25.0mmHg pre-operatively to 15.0 mmHg ( $p < 0.001$ ); and number of medications decreased from 4.0 pre-operatively to 1.0 ( $p < 0.001$ ). Using the IOP threshold of 18mmHg as criteria for surgical success, the cumulative probability of success was 46.5% at Year 5 and 38.1% at Year 10. Increased age was associated with less failure at Year 2 (HR 0.98,  $p = 0.046$ ) and Year 5 (HR 0.98,  $p = 0.032$ ). Higher pre-operative medicated IOP was associated with less failure at Year 5 (HR 0.97,  $p = 0.022$ ) and Year 10 (HR 0.97,  $p = 0.023$ ). Upon removal of the 20% IOP reduction criteria from surgical failure definition, previous trabeculectomy was associated with less failure at all timepoints (Year 2: HR 0.42,  $p = 0.046$ ; Year 5: HR 0.39,  $p = 0.023$ ; Year 10: HR 0.35,  $p = 0.009$ ) and intra-operative MMC use was associated with greater success at Year 5 (HR =2.27,  $p = 0.034$ ) and Year 10 (HR =2.75,  $p = 0.012$ ).

**Conclusion:** AGV implantation is effective for long-term sustained IOP control in Asian eyes. Previous trabeculectomy, older age, MMC-use and higher pre-operative medicated IOP may be associated with a lower risk of surgical failure.

P-132

### Transcriptome Analysis for the Regulatory Mechanism of BMSC-Sca-1<sup>+</sup> Exosomes in Retinal Inflammatory Response

Y Wang<sup>1,2</sup>, W Qin<sup>1,2</sup>, Y Bai<sup>1</sup>, X Ye<sup>1,2</sup>, X Li<sup>1,2</sup>, Y Zhang<sup>1,2</sup>, Z Shao<sup>\*1,2</sup>.

<sup>1</sup>Department of Ophthalmology, The Second Affiliated Hospital of Harbin Medical University, <sup>2</sup>Future Medical Laboratory, The Second Affiliated Hospital of Harbin Medical University, Harbin, People's Republic of China

**Objective:** To evaluate the possible alleviation of retinal inflammation by antigen 1 positive bone marrow stem cell (BMSC-Sca-1<sup>+</sup>) derived exosomes, explore the differential expression signatures of microRNAs(miRNA) related to the BMSC-Sca-1<sup>+</sup> and BMSC-Sca-1<sup>-</sup> derived exosomes, find out the therapeutic potential of BMSC-Sca-1<sup>+</sup> exosomes for the treatment of retinal inflammation.

**Methods:** BMSC-Sca-1<sup>+</sup> and BMSC-Sca-1<sup>-</sup> cells from C57BL/6 mice (2-3 months) were isolated by immunomagnetic cell sorting and the cell culture supernatant was collected to enrich exosomes. Old mice (over 12 months) were subjected to high intraocular pressure to induce retinal ischemia-reperfusion(I/R) injury, retinal Inflammation was evaluated by examining iNOS expression by immunofluorescence staining. Inflammatory cytokines inside and NO released from BV2 cell constructed by lipopolysaccharide(LPS) were detected to evaluate the anti-inflammatory efficacy of BMSC-Sca-1<sup>+</sup> and BMSC-Sca-1<sup>-</sup> exosomes. Total RNA from exosomes was performed transcriptome analysis by Illumina HiSeq high-throughput sequencing. miRanda, PITA and RNAhybrid softwares were used to predict the target genes of differentially expressed miRNAs in BMSC-Sca-1<sup>+</sup> and BMSC-Sca-1<sup>-</sup> secreted exosomes ( $P < 0.05$ ). GO and KEGG enrichment were analyzed by David database for biological processes and cell signaling pathways.

**Results:** Immunofluorescence staining of retina shows increased expression of iNOS in retinal I/R injury mice, microglia were activated and migrated to ganglion cell layer, inner plexiform layer and outer plexiform layer. The diameter range of exosomes was 30-150 nm and the biomarker Alix was positive. The level of Cox-2, IL-6, IL-1 $\beta$  and NO was reduced significantly in the LPS-induced BV2 cells treated by BMSC-Sca-1<sup>+</sup> exosomes than BMSC-Sca-1<sup>-</sup> group ( $P < 0.05$ ). 1038 miRNAs were detected by bioinformatic analysis, of which 46 were variant. 4138 target genes were significantly enriched in KEGG pathways. 17 inflammation-related genes were downregulated in MAPK, Ras and Rap1 pathway.

**Conclusion:** Retinal I/R injury is associated with retinal inflammatory response. BMSC-Sca-1<sup>+</sup> exosomes prevented microglia inflammatory response, and the MAPK, Ras and Rap1 pathway might play an important role in BMSC-Sca-1<sup>+</sup> exosomes-mediated retinal anti-inflammatory efficacy.

P-133

**Safety and efficacy of resident-performed GATT (gonioscopy-assisted transluminal trabeculotomy)**I Patterson<sup>1</sup>, E Avdagic, M Qiu<sup>1</sup>.<sup>1</sup>University of Chicago Department of Ophthalmology, Chicago, United States

**Objective:** Report outcomes of gonioscopy-assisted transluminal trabeculotomy (GATT) performed by PGY-3 and PGY-4 residents.

**Methods:** Eyes either underwent resident-performed GATT-alone (n = 10) or GATT + cataract extraction with intraocular lens implantation (CEIOL) (n = 41). Best corrected visual acuity (BCVA), intraocular pressure (IOP), number of IOP-lowering medications, complications, and subsequent IOP-lowering procedures, were collected preoperatively, at postoperative day 1 (POD1), week 1 (POW1), month 1 (POM1), month 3 (POM3), month 6 (POM6), month 12 (POM12), and the most recent clinic visit if greater than 12 months. Mean procedure times were also recorded.

**Results:** The primary aim was to assess whether resident-performed GATTs demonstrated success rates comparable to the GATT literature. Surgical success was defined in this study as IOP < 21 mmHg, an IOP reduction of 20% from baseline, and no subsequent IOP lowering surgery. The secondary and tertiary aims were to describe complication rates and to report the operating times for resident-performed GATTs, respectively.

Surgical success was 75% for GATT-alone and 42% for GATT + CEIOL at 6 months. Three eyes required subsequent IOP-lowering surgery. Hyphema was 16% at POW1 and 6% at POM1. IOP spike rate > 30mmHg (all etiologies) was 18%. A single choroidal effusion was attributed to complicated cataract surgery rather than the GATT itself. Mean surgical time for GATT-alone was 27 minutes for PGY3 and 40 minutes for PGY4. PGY3s may have required more assistance from the attending than PGY4s. Mean surgical time for GATT + CEIOL was 59 minutes for PGY3 and 76.5 minutes for PGY4. The cataract portion of GATT + CEIOL cases was performed less frequently by the PGY3 (35%) than the PGY4 (85%); attending performed cataracts are faster.

**Conclusion:** With a standardized approach, GATT can be performed efficaciously and safely by PGY-3 and PGY-4 residents, with clinical outcomes and complication rates that mirror those of attending-performed GATT cohorts from the literature.



P-134

### The role of artificial intelligence in analysis of fluid biomarkers for diagnosis and management of glaucoma: a systematic review

A Pucchio<sup>1</sup>, S Krance<sup>2</sup>, D Pur<sup>2</sup>, A Bassi<sup>2</sup>, R Miranda<sup>3,4</sup>, T Felfel<sup>4,5</sup>.

<sup>1</sup>School of Medicine, Queen's University, Kingston, <sup>2</sup>Schulich School of Medicine & Dentistry, Western University, London, <sup>3</sup>Toronto Health Economics and Technology Assessment Collaborative, <sup>4</sup>Institute of Health Policy, Management and Evaluation, <sup>5</sup>Department of Ophthalmology and Visual Sciences, University of Toronto, Toronto, Canada

**Objective:** Given the complexity of relationships between biofluid biomarkers and clinical characteristics, advanced strategies are required to uncover meaningful trends for paradigm shift in research and personalized glaucoma management strategies. This study aims to detail the accuracy and validity of AI in the exploration of biomarkers to provide insight into glaucoma pathogenesis.

**Methods:** This systematic review was conducted in accordance with the Preferred Reporting Items for a Systemic Review and Meta-analysis guidelines (protocol registration CRD42020196749). A comprehensive search was conducted across 5 electronic databases including EMBASE, Medline, Cochrane Central Register of Controlled Trials, Cochrane Database of Systematic Reviews, and Web of Science from inception to August 1, 2021. Studies pertaining to biofluid marker analysis using AI or bioinformatics in glaucoma were included. Identified studies were critically appraised and assessed for risk of bias using the Joanna Briggs Institute Critical Appraisal tools.

**Results:** A total of 10258 studies were screened and 39 studies met the inclusion criteria, including 23 cross-sectional studies (589%), nine prospective cohort studies (23%), six retrospective cohort studies (15%), and one case-control study (3%). Primary open angle glaucoma (POAG) was the most commonly studied subtype (55% of included studies). Twenty-four studies examined disease characteristics, 10 explored treatment decisions, and 5 provided diagnostic clarification. While studies examined the entire metabolomic or proteomic profiles to determine changes in POAG, there was heterogeneity in the data with over 175 unique, differentially expressed biomarkers reported. Discriminant analysis and artificial neural network predictive models displayed strong differentiating ability between glaucoma patients and controls, with average sensitivity and specificity of over 85%, although these tools were untested in a clinical context.

**Conclusion:** The use of models such as discriminant analysis and artificial neural network can inform clinical decision making with high sensitivity and specificity. While insight into differentially expressed biomarkers is valuable in pathogenic exploration, no clear pathogenic mechanism in glaucoma has emerged.

P-135

### 18-month retrospective analysis of phacoemulsification with ab-interno canaloplasty in well-controlled primary open angle glaucoma

A Stockard<sup>1</sup>, C Lentz<sup>1</sup>, I Wagner<sup>2</sup>, R Ten Hulzen<sup>2</sup>, P Bai<sup>1</sup>, J Lopez-Dominguez<sup>1</sup>.

<sup>1</sup>Mayo Clinic Alix School of Medicine, Scottsdale, <sup>2</sup>Ophthalmology, Mayo Clinic, Jacksonville, United States

**Objective:** To examine the 18-month efficacy of phacoemulsification with ab-interno canaloplasty (IOL+ABiC) in well-controlled mild and moderate primary open angle glaucoma (POAG).

**Methods:** Retrospectively reviewed mild (n=31) and moderate (n=11) POAG eyes that underwent IOL+ABiC between April 2019-February 2022. Intraocular pressure (IOP) and glaucoma medications were compared to (no washout) baseline at 18-months. Statistical analysis used paired sample t-tests and Pearson's chi-squared tests.

**Results:** For all patients analyzed together, the mean baseline IOP was  $15.0 \pm 4.6$  mmHg, reduced to  $13.6 \pm 3.8$  mmHg ( $p=0.015$ ) at 18 months. When separated into mild and moderate cohorts, the mild POAG cohort had a mean baseline IOP of  $15.5 \pm 5.0$  mmHg, reduced to a mean of  $14.4 \pm 3.7$  mmHg ( $p=0.12$ ) at 18 months. The moderate cohort had a mean baseline IOP of  $13.4 \pm 2.8$  mmHg, reduced to  $11.3 \pm 3.2$  mmHg ( $p=0.002$ ) at 18 months. When both groups were analyzed together, the mean number of glaucoma medications at baseline was  $1.5 \pm 1.0$ , reduced to  $0.57 \pm 0.55$  ( $p<0.001$ ) at 18 months. Mean number of glaucoma medications for the mild cohort at baseline was  $1.32 \pm 0.91$ , reduced to  $0.45 \pm 0.51$  ( $p<0.001$ ) at 18 months. The mean medications for the moderate cohort was  $2.0 \pm 1.2$ , reduced to  $0.91 \pm 0.54$  ( $p=0.020$ ) at 18 months. A meaningful percentage of patients achieved an IOP  $\leq 14$  mmHg (mild: 58%; moderate: 82%;  $p=0.16$ ). A high percentage also reduced medication burden by  $\geq 1$  meds (mild: 61%; moderate: 55%;  $p=0.69$ ).

**Conclusion:** In mild and moderate POAG, IOL+ABiC shows long-term safety and effectiveness at reducing both IOP and medication burdens for patients.

P-136

### Netarsudil 0.02% for treatment of glaucoma with elevated episcleral venous pressure: pilot investigation in Sturge-Weber syndrome

A Kaufman<sup>1</sup>, A Elhousseiny<sup>1,2</sup>, D Edward<sup>1</sup>, T Vajaranant<sup>1</sup>, A Aref<sup>1</sup>, J Abbasian<sup>1</sup>.

<sup>1</sup>Department of Ophthalmology and Visual Sciences, Illinois Eye and Ear Infirmary, University of Illinois at Chicago, Chicago, <sup>2</sup>Department of Ophthalmology, Harvey and Bernice Jones Eye Institute, University of Arkansas for Medical Sciences, Little Rock, United States

**Objective:** Topical netarsudil 0.02% may reduce intraocular pressure (IOP) by decreasing episcleral venous pressure (EVP), which carries theoretical utility for glaucoma associated with elevated EVP. A role for netarsudil in patients with elevated EVP is evaluated in a pilot investigation using a cohort of individuals with Sturge-Weber syndrome (SWS).

**Methods:** Retrospective study of patients with SWS and glaucoma who were treated with netarsudil. Five patients (six eyes) were identified. Data collected included demographics, visual acuity, IOP, glaucoma medical and surgical treatments, and adverse effects of netarsudil.

**Results:** Mean age was  $13.6 \pm 8.5$  years. EVP elevation was presumed based on clinical stigmata and/or historical features. Mean number of baseline glaucoma medications was  $3.3 \pm 1.2$ . There was a significant reduction in the IOP at netarsudil initiation (mean  $26.2 \pm 4.5$  mmHg) to 1 month of netarsudil therapy (mean  $20.2 \pm 3.8$  mmHg,  $p=0.0283$ ) and latest IOP on netarsudil (mean  $17.6 \pm 1.4$  mmHg,  $p=0.0034$ ). Mean duration of netarsudil therapy was  $18.7 \pm 11.8$  months. Three patients required additional glaucoma procedures; one patient required an additional glaucoma medication. Three eyes (50%) developed conjunctival hyperemia. One patient discontinued netarsudil at 29 months, to reduce drop burden.

**Conclusion:** Netarsudil can effectively reduce IOP in patients with SWS, even when used as a fourth or fifth glaucoma medication. A possible role for netarsudil in the management of patients with elevated EVP is suggested pending further future investigations.

P-137

**The association between obstructive sleep apnea and the severity of subsequent glaucoma: a population-based cohort study**C Lee, C Chang<sup>1</sup>, S Yang<sup>2</sup>.<sup>1</sup>Nobel Eye Institute, Taipei, <sup>2</sup>Institute of Medicine, Chung Shan Medical University, Taichung, Taiwan, China

**Objective:** To evaluate the impact of pre-existing obstructive sleep apnea (OSA) on the severity of following glaucoma using the national health insurance research database (NHIRD) in Taiwan.

**Methods:** A retrospective cohort study was conducted and patients with the glaucoma diagnosis were enrolled. Then the study population was divided into 11,778 cases with pre-existing OSA and another propensity-score matched 11,778 cases without such condition. The primary outcome was defined as the numbers of anti-glaucomatous drugs, the incidence of laser trabeculoplasty, trabeculectomy and cyclodestructive procedure. Cox proportional hazard regression was applied to estimate the adjusted hazard ratio (aHR) and corresponding confidence interval (CI) of OSA on the outcomes.

**Results:** There were 67, 782 and 60 cases received laser trabeculoplasty, trabeculectomy and cyclodestructive procedure in the OSA group, while another 69, 239 and 64 events of same procedures occurred in the control group. After adjusting for multiple co-variables, the incidence of trabeculectomy was lower in the OSA group (aHR: 0.757, 95% CI: 0.624-0.919) while the incidence of laser trabeculoplasty (aHR: 0.978, 95% CI: 0.698-1.371) and cyclodestructive procedure (aHR: 0.927, 95% CI: 0.651-1.320) were similar between the two groups. Besides, the numbers of anti-glaucomatous medication did not differ between the two groups ( $P>0.05$ ). In the subgroup analyses, age older than 60 years, male sex and the types of glaucoma did not influence the severity of glaucoma in OSA patients (all CI included 1).

**Conclusion:** The pre-existing OSA did not increase the severity of subsequent glaucoma, regarding the numbers of medications and frequencies of surgeries.

P-138

**No Causal Effects between Glaucoma and Stroke: A Bidirectional Mendelian Randomization Study**K Wang<sup>1</sup>, K Yao<sup>1</sup>.<sup>1</sup>Eye Center of the Second Affiliated Hospital, School of Medicine, Zhejiang University, Hangzhou, People's Republic of China

**Objective:** Observational studies have reported positive associations between glaucoma and stroke; however, controversial results exist. Importantly, the nature of the relationship remains unknown since previous studies were not designed to test causality. Therefore, we aimed to investigate the possible causal relationships between glaucoma and stroke.

**Methods:** Our two-sample Mendelian randomization (MR) encompassed multi-ethnic large-scale genome-wide association studies with more than 20,000 cases and 260,000 controls for glaucoma, and more than 80,000 cases and 630,000 controls for stroke. Individual effect estimates for each SNP were combined using the inverse-variance weighted (IVW) method. To avoid potential pleiotropic effects, we adjusted the main results by omitting metabolic factors-associated genetic variants. The weighted median and MR-Egger methods were also used for the sensitivity analysis.

**Results:** Our MR analysis showed that glaucoma and its subtypes, including primary open-angle glaucoma and primary angle-closure glaucoma, had no causal role on any stroke (AS), any ischemic stroke (AIS), large-artery atherosclerotic stroke (LAS), small-vessel stroke (SVS), or cardioembolic stroke (CES) across MR analyses (all  $P > 0.05$ ). The null associations remained robust after metabolic-related traits adjustment and were consistent in both the European and Asian populations. Reverse MR analyses also did not indicate any significant causal effects of AS, AIS, LAS, or CES on glaucoma risk.

**Conclusion:** Evidence from our series of causal inference approaches using large-scale population-based MR analyses did not support causal effects between glaucoma and stroke. Strategies to prevent either of the disease progression may not simply reduce the risk of the other.

P-139

## PERIPAPILLARY FLUX INDEX AND PERIPAPILLARY PERFUSION DENSITY IN OPEN ANGLE GLAUCOMA AND OCULAR HYPERTENSION: A LONGITUDINAL STUDY

M Schilt-Catafal<sup>1,2</sup>, V Pérez-Torregrosa<sup>3</sup>, A Duch-Samper<sup>3,4</sup>.

<sup>1</sup>*Glaucoma Department, Innova Ocular ICO Barcelona, Barcelona,* <sup>2</sup>*Ophthalmology Department, Hospital Sant Jaume de Calella, Calella,* <sup>3</sup>*Ophthalmology Department, Hospital Clínic Universitari de València,* <sup>4</sup>*Associated Professor, Universitat de València, València, Spain*

**Objective:** To investigate prospectively peripapillary vascular changes in patients with glaucoma and ocular hypertension, and to correlate these vascular changes with structural and functional outcomes.

**Methods:** A 12-month prospective longitudinal study was performed with 124 open-angle-glaucoma-eyes (GE), 111 ocular-hypertension-eyes (OHE) and 98 gender and age matched control-eyes (CE). Glaucomatous progression was defined as a decrease of greater than or equal to  $5\ \mu\text{m}$  in average or  $7\ \mu\text{m}$  in a sector of RNFL thickness. Humphrey Field Analyzer3 and OMAG OCT microangiography (Angioplex, HD OCT, Cirrus 5000, Zeiss) were used. The statistical analysis was performed using the Mann-Whitney-Test and Spearman-Rank-Correlation.

**Results:** In OHE and GE groups, 21,7% of eyes showed progression, being the decrease of **Peripapillary Flux Index (PFI)** greater (-0,0067) compared to non-progressive eyes (+0,0038) [ $p=0,015$ ]. Furthermore, **Peripapillary Perfusion Density (PPD)** showed non-significant greater decrease (-0,347) compared to non-progressive eyes (-0,324) [ $p=0,775$ ].

Characteristics as increased vertical cup to disc ratio (CDV) (0,64 vs 0,57), elevated intraocular pressure (IOP) (18,25 vs 15,40 mmHg), thinner central corneal thickness (CCT) (520,18 vs 541,67  $\mu\text{m}$ ) and lower ocular perfusion pressure (OPP) (47,81 vs 48,95 mmHg) were significantly different in those progressive OHE and GE [ $p<0,05$  for all]. Nevertheless, minimum ganglion cell layer thickness (GCLM) was only significantly lower in progressive GE (58,51 vs 73,98  $\mu\text{m}$ ) [ $p=0,036$ ].

Regression analysis showed that PFI change was positively correlated with changes of Retinal Nerve Fiber Layer thickness (RNFL) ( $r=+0,371$ ), Ganglion Cell Layer thickness (GCL) ( $r=+0,151$ ) and Visual Field Mean Deviation (VFMD) ( $r=+0,234$ ) [ $p<0,001$  for all]. Visual Field Index change (VFI) ( $r=+0,199$ ) was not significantly correlated ( $p=0,089$ ) with PFI change. PPD change was not significantly correlated with any parameter.

**Conclusion:** Data showed that when glaucomatous progression took place, stronger vascular changes occurred in the peripapillary area, as greater decrease of PFI and PPD. These changes seemed to be correlated with some of traditional glaucoma parameters such RNFL, GCL and VFMD. Furthermore, common characteristics as increased CDV and IOP, lower OPP and GCLM, and thinner CCT seemed to be risk factors for those eyes that eventually showed progression. Nevertheless, further research with larger population and larger follow-up is needed to obtain stronger results.

P-140

## Evaluation of Central Glaucomatous Visual Field Defects Using Standard Automated Perimetry and Amsler Grid Test.

T Gbadegesin<sup>1</sup>, O Olawoye<sup>2</sup>, T Sarimiye<sup>2</sup>, B Ajayi<sup>1</sup>, O Idowu<sup>3</sup>.

<sup>1</sup>Eleta Eye Institute, <sup>2</sup>ophthalmology, college of medicine, university of ibadan, Ibadan, Nigeria, <sup>3</sup>Genentech Inc, south san francisco, south california, United States

**Objective:** To determine the validity of the Amsler grid in detecting central glaucomatous visual field defects in primary open angle glaucoma (POAG) in low resource settings.

**Methods:** This was a cross sectional study of follow up glaucoma patients at a secondary eye care hospital in Nigeria. All patients had detailed standard ophthalmic examination in addition to 24-2, 10-2 central visual field (CVF) tests and Amsler grid test (AGT). The different severities of POAG were classified using the Hodapp-Parrish-Anderson criteria (HPA) into mild, moderate and severe on 24-2 CVF. An abnormal 10-2 CVF was defined as 3 or more adjacent points with a P value of 1%, with at least one point with a P value of 0.5% on the pattern deviation plot. An abnormal AGT was defined by the presence of missing or blurry lines on the Amsler grid. The area of the blurry or missing lines on the AGT was referred to Amsler grid scotoma area and was measured with Image J software. The diagnostic validity of the Amsler grid as a screening tool was calculated using the 10-2 CVF as a reference standard. Regression analyses were performed between the Amsler grid scotoma area and 10-2 mean deviation (MD), number of depressed points with P<1% on the total deviation plot (scotoma extent) as well as the average sensitivity of the depressed points with P<1% on total deviation plot (scotoma mean depth).

**Results:** A total of 150 eyes of 150 patients were enrolled. A total of 150 eyes (150 patients) were recruited with an age range of 40 – 85 years, the mean  $\pm$  standard deviation (SD) age was  $59.3 \pm 11.0$  years. The average mean deviation  $\pm$ SD in all severity groups was  $-8.7 \pm 8.6$ dB (range -32.8 to -0.2dB) on 10-2 VFT. The sensitivity, specificity, positive and negative predictive values of the Amsler grid when compared with the 10-2 CVF was 49.5%, 95.9%, 96.2% and 47.9% respectively with an area under curve of 0.7 across the different severities of POAG. The sensitivity increased with increasing severity of POAG ( $p<0.001$ ) from 20.0%, 31.0% and 76.6% in mild, moderate and severe POAG respectively. The Amsler grid scotoma area had the strongest relationship with the 10-2 MD, followed by the 10-2 scotoma extent and the least 10-2 scotoma mean depth with a quadratic R<sup>2</sup> of 0.579, 0.370 and 0.307 respectively.

**Conclusion:** The Amsler grid has a low sensitivity in mild to moderate POAG. However, it may serve as an adjunctive cost-effective tool in resource scarce settings for detection of severe POAG in the community by primary eye care providers.

P-141

### Gonioscopy-assisted transluminal trabeculotomy following failed glaucoma surgery in primary congenital glaucoma; One-year results

A Elhusseiny, R Aboulhassan<sup>1</sup>, Y El Sayed<sup>1</sup>.

<sup>1</sup>Ophthalmology, Cairo University, Cairo, Egypt

**Objective:** Gonioscopy-assisted transluminal trabeculotomy is a minimally invasive glaucoma surgery that allows the cannulation of the inner wall of Schlemm's canal using either suture or microcatheter through a corneal incision. Few studies have evaluated its efficacy in primary congenital glaucoma (PCG). The purpose of the current series is to evaluate the one-year outcomes of GATT in PCG with a history of prior glaucoma surgery.

**Methods:** A retrospective chart review was performed to identify all PCG patients  $\leq 16$  years who had GATT surgery at Cairo University Children's Hospital from January 2016 to March 2022. Excluded patients included those with childhood glaucoma other than PCG, PCG patients who had not undergone glaucoma procedure before GATT, and those with  $<12$  months' follow-up.

**Results:** Seven PCG eyes (6 patients) underwent GATT surgery with at least 12 months of follow-up. Four patients were males. There was no statistically significant difference in the mean preoperative cup to disc ratio ( $0.61 \pm 0.22$ ) compared to the last follow-up visit ( $0.64 \pm 0.25$ ) ( $P = 0.71$ ).

The mean age at the time of GATT surgery was  $62.8 \pm 29.7$  months (median; 60 months). The median follow-up was 13.5 months (mean:  $15.7 \pm 4$  months, range; 12-24.1 months). The mean IOP was statistically significantly reduced from  $25.7 \pm 5.9$  mmHg preoperatively to a mean of  $12 \pm 1.5$  mmHg (median; 12 mmHg) ( $P = 0.001$ ) at 12-months.

The mean number of glaucoma medications was statistically significantly reduced from  $1.5 \pm 1.1$  (median; 2) preoperatively to a mean of  $0.14 \pm 0.34$  mmHg (median; 0) ( $P = 0.03$ ) at 12-months

No patients required further glaucoma procedures. No serious intra- or postoperative complications were identified. Mild hyphema developed in 3 eyes (42.8%) which resolved on the first seven days postoperatively on conservative treatment.

**Conclusion:** We present the first and largest to date case series evaluating GATT after failed glaucoma surgeries in PCG. GATT was effective in our cohort over a 12-months follow-up. We believe our early experience is important as it highlights that GATT can be performed as an alternative before considering conjunctival or scleral glaucoma surgeries.



P-142

**iStent versus XEN gel stent in primary open angle glaucoma during the COVID-19 pandemic**J Cheng, Y Ting<sup>1</sup>.<sup>1</sup>*Ophthalmology, Wan Fang Hospital, Taipei Medical University, Taipei City, Taiwan, China*

**Objective:** To compare the iStent (Glaukos) and the XEN gel stent (Allergan Inc.) in postoperative outcomes, postoperative visits, hospitalization, and reoperation rates. This would help surgeons and glaucoma patients alike to decide which surgical procedure to choose during a pandemic. Frequent postoperative visits, hospitalization, and reoperation would be a severe burden for patients during a pandemic.

**Methods:** All patients underwent either iStent or XEN gel stent implantation for primary open angle glaucoma (POAG) from January 2020 to January 2021. All patients have at least 12 months of postoperative follow-ups. IOP was measured on all visits, including preoperative, postoperative 1 day, 1, 3, 6, 12 months, and any additional visits. Postoperative complications, hospitalization days, reduction of IOP lowering eye drops and reoperation (needling) were based on medical records. Mann-Whitney U test was used to compare the difference between the two groups.

**Results:** We included a total of 21 eyes from 18 patients diagnosed with POAG. There was no statistical difference of the baseline, 1, 3, 6, and 12 months between the two groups. Reduction of IOP showed no significant difference between the two groups ( $p > 0.05$ ). Reduction of IOP lowering eye drops was 1.17 (SD=1.60) in the iStent group, and 2.5 (SD=1.18), with no significant difference between the two groups ( $p > 0.05$ ).

Postoperative clinic visits showed significant less frequent visits of the iStent group ( $p < 0.05$ ), with an average was 9.7 visits per year in the iStent group, and 16.0 visits per year in the XEN group.

iStent resulted in less postoperative complications (1 vs 6,  $p < 0.05$ ) that required to return to the operation room. Postoperative complication for iStent was hyphema ( $n=1$ , 11.1%). Postoperative complications for XEN was mainly due to bleb failures that requires additional surgery for bleb needling ( $n=6$ , 50%).

**Conclusion:** In conclusion, the iStent trabecular microbypass stent and the XEN gel stent were both efficient in IOP-lowering. Moreover, the iStent trabecular microbypass stent has less postoperative visits required and less risks of additional surgeries comparing to the frequent bleb needling revisions following the XEN gel stent. This would make iStent less of a burden for both surgeon and patient during a pandemic.

P-143

**The Effect of OPTN(E50K) Mutation on Mitochondrial Function in R28 Cells**

M Du<sup>1</sup>, Q Wang<sup>1</sup>, S Zhang<sup>1</sup>, X Liu<sup>1</sup>, H Yuan<sup>1</sup>.

<sup>1</sup>The Second Affiliated Hospital of Harbin Medical University, Harbin, People's Republic of China

**Objective:** OPTN(E50K) is one of the main mutations caused normal tension glaucoma, which can trigger age-related loss of retinal ganglion cells (RGCs). The accumulation of damaged mitochondria and mitochondrial dysfunction may contribute to death of RGCs, and plays a synergistic role with environmental factors such as aging and oxidative stress, eventually leads to axonal degeneration and visual function impairment. This study explored the effect of OPTN(E50K) mutation on mitochondrial function in R28 cells.

**Methods:** GFP-R28, GFP-OPTN(WT)-R28 and GFP-OPTN(E50K)-R28 cell models were constructed by adenovirus transfection into R28 cells, verified by fluorescence microscope; The levels of ATP, SOD, MDA and the changes of total antioxidant capacity were detected.

**Results:** The ATP level and SOD activity of GFP-OPTN(E50K) group were significantly lower than other three groups. At the same time, the content of MDA was higher in GFP-OPTN(E50K) group. Besides, the total antioxidant capacity of GFP-OPTN(E50K) group was significantly lower than that of other three groups as well. There was no significant difference in ATP, MDA and SOD levels among control group, GFP group and GFP-OPTN(WT) group.

**Conclusion:** OPTN (E50K) mutation can cause the disorder of energy synthesis, lead to oxidative stress and reduce the antioxidant capacity of R28 cells.

P-144

### PGF2 $\alpha$ and omidenepag differently stimulate the fibrogenetic changes in TGF- $\beta$ 2 treated human conjunctival fibroblasts

Y Tsugeno<sup>1</sup>, M Watanabe<sup>1</sup>, Y Ida<sup>1</sup>, F Hikage<sup>1</sup>, A Umetsu<sup>1</sup>, S Suzuki<sup>1</sup>, M Furuhashi<sup>2</sup>, H Ohguro<sup>1</sup>.

<sup>1</sup>Ophthalmology, <sup>2</sup>Cardiovascular, Renal and Metabolic Medicine, Sapporo Medical University, sapporo, Japan

**Objective:** To investigate the effects of prostaglandin F2 $\alpha$  (PGF2 $\alpha$ ) and an EP2 agonist, omidenepag (OMD), both of which are frequently used as anti-glaucoma medications, on transforming growth factor- $\beta$  2 (TGF- $\beta$  2)-induced conjunctival fibrogenesis, two-dimension (2D) and three-dimension (3D) cultured human conjunctival fibroblasts (HconF) were used.

**Methods:** 2D and 3D cultured HconF cells were analyzed by transendothelial electrical resistance (TEER, 2D), size and stiffness (3D), and qPCR of the extracellular matrix (ECM) proteins including collagen1 (COL1), COL4 and COL6, fibronectin (FN), and  $\alpha$ -smooth muscle actin ( $\alpha$  SMA) (2D, 3D) in the absence or presence of PGF2 $\alpha$  or OMD.

**Results:** The significant increase in the TEER values by TGF- $\beta$  2 were greatly reduced or enhanced by PGF2 $\alpha$  or OMD, respectively. PGF2 $\alpha$  induced a substantial down-sizing of the 3D HconF spheroids in the presence or absence of TGF- $\beta$  2. Both PGF2 $\alpha$  or OMD increased the stiffness of the 3D HconF spheroids, and PGF2 $\alpha$  was also enhanced the TGF- $\beta$  2-induced increase in the stiffness. Among 5 ECMs, TGF- $\beta$  2 induced a significant up-regulation of SMA, although PGF2 $\alpha$  and OMD caused a substantial up-regulation of all ECMs. PGF2 $\alpha$  and OMD caused a marked down-regulation in TIMP1, 2 and 4, and MMP2, 9 and 14 of the 3D HconF spheroids in the absence of TGF- $\beta$  2, and those effects were diminished in the presence of TGF- $\beta$  2.

**Conclusion:** The findings reported herein indicate that the TGF- $\beta$  2-induced increase in fibrogenetic changes on the plane or in the spatial space were significantly and differently enhanced by both OMD and PGF2 $\alpha$ , respectively.

P-145

### Prompt Primary Cyclophotocoagulation with Subsequent Aqueous Shunt as Needed for Neovascular Glaucoma with Synechial Angle Closure

J Wang, M Qiu<sup>1</sup>.

<sup>1</sup>*Ophthalmology and Visual Science, Uchicago Medicine, Chicago, United States*

**Objective:** In acute NVG, implanting an aqueous shunt into eyes with active anterior segment neovascularization (NV) increases bleeding-related complications. Prompt administration of anti-VEGF rapidly regresses NV but is ineffective at lowering IOP when the angle is already synechially closed. CPC has historically been reserved for eyes with poor visual potential. The purpose of this case series is to describe a single surgeon's experience utilizing prompt CPC with prior or concurrent anti-VEGF and subsequent aqueous shunt as needed in NVG eyes with total synechial angle closure, regardless of visual potential.

**Methods:** A retrospective chart review was performed for NVG patients with uncontrolled IOP, active anterior segment NV, total synechial angle closure, no contraindications to prompt anti-VEGF, CPC within 3 days of presentation, and at least 6 months of follow-up.

**Results:** Seven patients (3 male, 4 female, all African American) with mean age 63.9 years were included. Underlying etiologies were PDR (N=3), CRVO (N=3), and chronic RD (N=1). All patients underwent CPC and anti-VEGF injections within 3 days of presentation, with ongoing anti-VEGF and PRP at the discretion of the retina service. Five patients did not require subsequent aqueous shunts through a mean follow-up of 17.4 months; most recent visual acuities ranged from 20/40 to LP, and IOPs ranged from 4 to 19 mmHg on 0 to 3 IOP-lowering medications. Two patients who required subsequent tubes (1 Ahmed 5 weeks later, 1 Baerveldt-350 11 weeks later) had resolution of active anterior segment NV by the time of surgery, and phacoemulsification could be performed to facilitate sulcus tube placement. Upon follow-up examination of the eyes that underwent Ahmed and Baerveldt-350 placement, visual acuities were 20/30 and 20/125 at 28 and 9 months, respectively, with normal IOP. No eyes developed uncontrolled anterior segment inflammation, sympathetic ophthalmia, or phthisis.

**Conclusion:** Prompt primary CPC within 3 days of presentation, with prior or concurrent anti-VEGF, may be an effective strategy to immediately lower IOP in acute NVG eyes with active anterior segment NV and total synechial angle closure, regardless of visual potential. If IOP becomes uncontrolled later, an aqueous shunt can be implanted in a controlled setting after active anterior segment NV has regressed. Further research is needed to compare outcomes of prompt CPC versus aqueous shunt in NVG eyes with acutely high IOP and total synechial angle closure.

P-146

**The Long-term Visual Outcomes of Primary Congenital Glaucoma.**C Liang<sup>1</sup>.<sup>1</sup>*Ophthalmology, Taichung Veterans General Hospital, Taichung, Taiwan, China*

**Objective:** To evaluate the long-term visual outcomes of trabeculotomy for primary congenital glaucoma (PCG) at a single tertiary medical center.

**Methods:** In this retrospective case series, data from 70 eyes of 41 patients who received trabeculotomy between July 2008 and June 2020 were reviewed. Data of the best corrected visual acuity (BCVA), stereopsis, ocular alignment and surgical success were analyzed. Surgical success was defined as intraocular pressure (IOP) less than 21 mmHg and 20% below baseline without additional glaucoma surgery.

**Results:** Mean age of operation is  $26 \pm 9.6$  months. BCVA at the time of diagnosis was  $0.41 \pm 0.40$  logMAR, which changed to  $0.54 \pm 0.58$  logMAR at the final follow-up ( $P = 0.04$ ). 23% of patients had BCVA  $\geq 20/40$  at the final visit. The mean refraction at baseline was  $-3.56 \pm 4.28$  diopters, with myopic progression to be  $-5.8 \pm 4.83$  diopters at the final visit. The ocular alignment was considered orthoptic in 68% of patient. 23% of patients present manifest nystagmus. The average final stereopsis was 430.33 sec of arc. There are significant associations between the surgical success and final BCVA ( $P = 0.02$ ). Mean baseline IOP was  $31.3 \pm 8.56$  mmHg, and significantly decreased to  $15.24 \pm 6.72$  mmHg at final follow-up ( $P = 0.001$ ). 36 eyes (51%) received additional glaucoma surgery due to elevated IOP. The survival period of trabeculotomy was  $96.2 \pm 11.35$  months.

**Conclusion:** Long term IOP control can be achieved in patients with PCG. Although half of the patients need additional glaucoma surgeries in 8 years, 23% of the patients gained fair visual function.

P-147

### Effect of tafluprostaglandin on intraocular pressure fluctuation and intraocular perfusion pressure

J Sun<sup>1</sup>, H yuan<sup>2</sup>, L li<sup>2</sup>.

<sup>1</sup>ophthalmology, 2nd affiliated hospital of haerbin medical university, harebin, <sup>2</sup>ophthalmology, 2nd affiliated hospital of haerbin medical university, haerbin, People's Republic of China

**Objective:** To investigate the effects of 0.0015% tafluprostaglandin ophthalmic solution in controlling intraocular pressure (IOP) in patients with primary open-angle glaucoma or ocular hypertension and its effect on 24-hour IOP fluctuation and intraocular perfusion pressure.

**Methods:** All of the patients were enrolled from the clinic of the 2nd affiliated hospital of Haerbin Medical University. The patients who were using topical drugs for control of IOP before initiation of the trial were required to complete a drug washout period. The patients took the first (baseline) measurement of 24-hour habitual postural IOP and blood pressure (BP) at 2:00, 6:00, 8:00, 10:00, 14:00, 18:00, 22:00. 4 times in sitting position over 16 h during daytime and 3 times in supine position over 8 h at night. Then 0.0015% tafluprostaglandin ophthalmic solution was given once a day at 20:00 for 4 weeks. The 2nd 24-hour IOP and BP measurement was performed 4 weeks after nighttime drug therapy following enrollment. The drug was withdrawn for 60 to 84 hours, and then the third 24-hour IO pressure was recorded. Mean perfusion pressure (MOPP) was calculated. Goldmann applanation tonometer and Perkin supine tonometer will be used for measuring IOP.

**Results:** A total of 9 patients and 18 eyes were enrolled in this study, including 7 males and 2 females, with an average age of 38 years, 2 POAG and 7 OHT, with baseline IOP of 21.1mmHg-32.3mmHg. After 28 days of medication, the mean 24-hour IOP decreased by 2.6mmHg (9.5%) from baseline, 2.8mmHg in daytime and 2.0mmHg in night. The 24-hour IOP fluctuation decreased by 2.1mmHg on average (27.7%) from baseline; MOPP increased by 3.4mmHg (9.5%) on average from baseline. 60-84h after drug withdrawal, the mean 24-hour IOP decreased by 1.3mmHg from baseline ; The average fluctuation of intraocular pressure in 24 hours decreased by 2.0mmHg.; MOPP increased by 3.1mmHg on average.

**Conclusion:** In patients with POAG or OHT, 0.0015% tafluprostaglandin ophthalmic solution can significantly reduce the fluctuation of intraocular pressure within 24 hours and increase the intraocular perfusion pressure under different body positions. Partial effect was maintained 60 to 84 hours after medication withdrawal.

**P-148****Optic disc drusen masking primary angle closure glaucoma in virtual glaucoma clinics****B Griffin, A Daas<sup>1</sup>, C Panos<sup>1</sup>, R Petrarca<sup>1</sup>.**<sup>1</sup>*Department of Ophthalmology, Epsom and St Helier University Hospitals NHS Trust, London, United Kingdom*

**Objective:** To describe the case of a phakic moderate hypermetropic man in his late 70s presenting during the Covid-19 pandemic with primary angle closure glaucoma masked during virtual consultations by optic disc drusen.

**Methods:** Case report describing a patient presenting to a teaching hospital within London, UK.

**Results:** This patient was referred by his optician with elevated intraocular pressure and unexplained visual field loss. During initial clinic visit, the angles were narrow but felt to be open, intraocular pressure elevated at 31 and 27 mmHg (RE and LE respectively) and superior arcuate visual field defects were identified bilaterally. Optic disc appearance on undilated retinal photography showed normal cup-disc ratio agreeing with OCT optic disc scans (CDR 0.4 bilaterally). Prostaglandin analogue was started as a treatment for ocular hypertension whilst awaiting repeat visual field testing. Follow-up two months later showed a modest improvement in IOP bilaterally (25 and 22 mmHg) however further narrowing of the angles was evident on anterior segment OCT, leading to the laser peripheral iridotomy being performed. At the post laser face to face follow-up appointment, IOP improved to 18 mmHg bilaterally and angles were wide open on gonioscopy allowing dilated fundal assessment to be performed. This examination demonstrated bilateral optic disc drusen which were masking glaucomatous optic disc disease. The diagnosis was altered to primary angle closure glaucoma.

**Conclusion:** Optic disc drusen are known to cause visual field defects, including arcuate scotomata and peripheral defects, however these also may mask glaucomatous optic disc changes. During Covid-19 pandemic, many glaucoma clinics functioned as virtual clinics and undilated scans were predominantly performed. These images may not show cupping of the optic disc and scans may report an erroneous cup-disc ratio. In our case, dilated fundoscopic examination following peripheral YAG laser iridotomy allowed the identification of optic disc drusen and highlighted the importance of dilated disc assessment in cases of unclear diagnosis and the assessment of new patients.

P-149

### The importance of glaucoma screening in a population of Lubumbashi, Democratic Republic of the Congo

G KINTADI LUYINGILA<sup>1</sup>, F MBAMBU SENGE<sup>1</sup>, J KABUYAYA BWAMBALE<sup>1</sup>, A ASSANI MORISHO<sup>1</sup>, F NGOIE KAYAMB<sup>1</sup>, J KANKU MBUYI<sup>1</sup>, F MPIA EPOMBE<sup>1</sup>, M KANGAKOLO BINTILUMAMI<sup>1</sup>, F TWITE BADYE<sup>1</sup>, J MAKUMYAVIRI MBUIRO<sup>1</sup>, F SENDA IBUTSHI<sup>1</sup>, J LUKINGA WITANENE<sup>1</sup>, L TABU YEKOLI<sup>1</sup>, D LUEMBE KASONGO<sup>1</sup>, S IYE ABIAL<sup>1</sup>, G CHENGE BORASISI<sup>1</sup>.

<sup>1</sup>Ophthalmology, Université de Lubumbashi, Lubumbashi, Congo, The Democratic Republic of the

**Objective:** Glaucoma is an anterior optic neuropathy characterized by the destruction of the optic nerve caused by some risk factors, mainly an increase in intraocular pressure. It is a disease which sets in without any symptoms in its early stages and slowly evolve through a progressive loss of the visual field leading up to blindness, thus representing one of the causes of irreversible blindness in developing countries.

**Methods:** It is a descriptive study following a free glaucoma screening campaign, organized by the Ophthalmology service of the Clinic of the university of Lubumbashi, DR Congo, on the occasion of World Glaucoma Week from 07th to 12th March 2022

**Results:** Out of a total number of 729 patients consulted, it was found that 188 or 25.79% had glaucoma (43.09% open-angle glaucoma; 5.85% hypertonia; 9.57% normal pressure glaucoma and 41.49% suspect glaucoma).

**Conclusion:** The black race is a significant factor in chronic open-angle glaucoma. The permanent awareness of the population should therefore be done in all the ophthalmological care structures of the city of Lubumbashi, for an early diagnosis and adequate care.



**P-150****Correlation Between Glaucoma Severity and RNFL Thickness in Primary Angle Closure Glaucoma Patients at Kariadi Hospital**

P Faranita.

**Objective:** Primary Angle Closure Glaucoma (PACG) is the most common primary glaucoma in Kariadi Hospital and has a rapidly deteriorating progression. This study aims to analyze the correlation between glaucoma severity and Retinal Nerve Fiber Layer (RNFL) thickness in PACG patients.

**Methods:** In this retrospective cross-sectional study, data were collected from patient electronic medical records since January 2020 to March 2022 including Best Corrected Visual Acuity (BCVA), Intraocular Pressure (IOP), Cup to Disc Ratio (CDR) and RNFL thickness. The CDR and RNFL Thickness were examined using *ZEISS CIRRUS HD-OCT 5000*. The glaucoma severity was graded according to Canadian Guidelines. Data were analyzed using Spearman correlation.

**Results:** In this study, 254 eyes of 180 PACG patients were included. Mean of IOP was 26.66 mmHg. Mean of early, moderate, and advanced CDR were 0.57, 0.77 and 0.90. Mean of RNFL thickness at early, moderate, and advanced stage of glaucoma were 91.18 $\mu$ m, 72.60 $\mu$ m and 60.28 $\mu$ m. There was a significant negative correlation between moderate stage of glaucoma with RNFL thickness ( $p=0.002$ ). The same thing was found in the correlation of overall CDR with RNFL thickness ( $p<0.001$ ).

**Conclusion:** In PACG patients, RNFL thickness decrease as glaucoma severity increase. These results can be used as information on OCT-based screening and management in PACG patients.

**P-151****Roberts syndrome with negative cytogenetic analysis presenting with bilateral congenital glaucoma.**A Almulhim.

**Objective:** We are presenting a rare case of one week old baby with Roberts syndrome associated with bilateral congenital glaucoma, general body system examination within normal limits except left-hand rudimentary digits and right ectopic kidney. Bilateral non-penetrating glaucoma surgery done with good control of intraocular pressure for more than six months.

**Methods:** Case report.

**Results:** Non penetrating Deep Sclerectomy plus Mitomycin C was performed for both eyes and intraocular pressure was stable for more than 6 months. Molecular analysis showed no abnormality. To the best of our knowledge, this is the first case reported with phocomelia, bilateral congenital glaucoma, and unilateral ectopic kidney without any detected genetic abnormality.

**Conclusion:** We recommend full ophthalmic evaluation for any suspected case of Roberts syndrome to rule out any ocular involvement including congenital glaucoma to stave off any potential damage for the eye.

**P-152****Treatment of refractory angle closure glaucoma with MicroPulse transscleral cyclophotocoagulation**C Hsu.

**Objective:** To report a 75-year-old refractory angle closure glaucoma patient successfully treated with MicroPulse transscleral cyclophotocoagulation (TSCPC).

**Methods:** A retrospective case report

**Results:** A 75-year-old female patient had left eye pain and redness for 2 weeks, and very high intraocular pressure (IOP) around 60 mmHg was measured during the first visit. Obvious angle closure glaucoma attack was diagnosed, and the general ophthalmologist tried to do laser iridotomy (LI) but failed.

During the patient's initial consultation, her IOP was 47 mmHg (under Travoprost, brimonidine, timolol, brinzolamide and oral acetazolamide) with grade 1 nuclear sclerotic cataract. After LI was done successfully, her IOP decreased to 24. However, one week later, her IOP elevated to 37 though LI was patent. After LI was performed at two other sites, her IOP decreased to 29 mmHg but best corrected visual acuity was only hand motion level. 3 weeks later, the IOP was measured up to 52 though the 3 LI sites were all patent. Lens extraction was indicated but her optic nerve head showed total cupping already by slit-lamp biomicroscopy.

After informed her the poor prognosis of her vision even after the cataract surgery, the patient refused to have the invasive operation. Therefore, I tried MicroPulse TSCPC for her. The 810 nm laser (G6, Iridex) was used with the MicroPulse P3 handpiece. The setting was 2500 mW, 360° for 200 secs, 50 secs each quadrant. Post-MicroPulse day 1, IOP decreased to 18; post-operative (post-op) 1 week, 14.5 mmHg; post-op 2 weeks, 14 mmHg; and post-op 1 month, 14.5 mmHg.

After a post-operative period of two months, her IOP was 15 mmHg during her latest clinic visit, and under 3 anti-glaucoma eye drops only. Tapering of her anti-glaucoma medicines may be the next treatment planning.

**Conclusion:** For refractory angle closure glaucoma, MicroPulse TSCPC seems to be an alternative viable non-invasive treatment strategy to control IOP.

**P-154**

**Bilateral multiple ciliary body cysts with angle-closure glaucoma in 18-year-old patient: A case report.**

A Almulhim.

**Objective:** To present a rare case of bilateral multiple ciliary body cysts with angle-closure glaucoma in 18-year-old patient

**Methods:** Case report

**Results:** Based on the clinical and UBM findings, a diagnosis of pseudoplateau iris was established. Nd: YAG Laser Peripheral Iridotomy (LPI) was done for both eyes and neither opened the angle nor controlled the IOP. Maximum topical medications were started and IOP became controlled. Given the age of the patient and disc cupping status, Trabeculectomy plus Mitomycin C was performed for the left and then the right eye. Over the next 4 months, IOP was controlled without any medication bilaterally. To the best of our knowledge, this is the youngest reported case of isolated bilateral pseudoplateau iris.

**Conclusion:** This case highlights the importance of a comprehensive eye exam for all preschool age groups for early diagnosis and treatment of any subclinical ophthalmic conditions.

P-155

## Micropulse Transscleral Cyclophotocoagulation In Neovascular Glaucoma Aggravated By Silicone Oil Tamponade

L Houda, R Lazreg, Y Walha, W Hmaied.

**Objective:** We aimed to discuss the effectiveness of Micropulse transscleral cyclophotocoagulation (MP-TCP) in treating a monophthalmic diabetic patient with neovascular glaucoma (NVG) aggravated by silicone oil tamponade.

**Methods:** a case report

**Results:** A 51-year-old man presented in 2015 to our department with an NVG of the right eye. He had proliferative diabetic retinopathy complicated with NVG. He was monophthalmic, he lost the left eye after an ancient cranial traumatism. He was put on maximal anti-glaucomatous medications and underwent urgent pan-retinal photocoagulation (PRP) and then an intravitreal injection. Six months later he developed a vitreous hemorrhage that required pars plana vitrectomy and silicone oil implantation that decompensated the intraocular pressure (IOP). He had silicone oil removal with an endolaser and an intravitreal injection of Bevacizumab that failed to control IOP. Since this was a case of a young monophthalmic patient with refractory NVG, we chose a safe alternative using MP-TCP.

After the procedure, Visual acuity was 3/10, and the IOP had decreased to 12 mmHg. The IOP remained stable without medication for six months. Then it started to increase gradually under topical anti-glaucomatous medication. The MPTCP was repeated twice in three years until the patient died from leukemia. It allowed maintaining a visual acuity of 3/10 and a stable visual field.

**Conclusion:** micropulse delivery is set with specific on-off times. "Off" periods, allow the adjacent structures to dissipate the heat, protecting them from the thermal effect. This technique should be considered in eyes at higher risk of postoperative complications because of its more favorable safety profile. MP-TCP has been used in many cases of refractory glaucomas, such as neovascular glaucoma (NVG) with good results and fewer complications. It offers the opportunity for re-treatment.

**P-156****Neovascular Glaucoma Complicating Chronic Rhegmatogenous Retinal Detachment: Presentation And Management**L Houda, A Sirine, S Sioud, W Hmaied.**Objective:** We aimed to describe the pathophysiological mechanisms and management of NGV complicating CRD.**Methods:** a case report**Results:** A 70-year-old man underwent a three-way pars plana vitrectomy with silicone oil tamponade in 2015 for a total rhegmatogenous retinal detachment of the left eye. A residual retinal detachment of the inferior retina persisted postoperatively. Thus, the patient had cataract surgery (phacoemulsification), inferior scleral indentation, a complement of peripheral vitrectomy, and vitreoretinal proliferation (VRP) peeling with silicone oil re-injection. Persistence of a small inferior detachment with a flat macula was noted. We chose to reinforce the laser in the inferior retina and supervise the patient. After eight months after the second surgery, the patient developed neovascular glaucoma with an intraocular pressure of 30 mmHg. Fundus examination showed a persistent retinal detachment in the extreme retinal periphery from four o'clock to 9 o'clock.

The patient had a topical monotherapy to lower the (IOP), subconjunctival injections of anti-VEGF before the surgery. We performed silicone removal, dissection of the VPR nodes, and a retinectomy of the ischemic retina. The active neovascularization disappeared after three months following surgery, and IOP decreased to 14 mmHg under a monotherapy. We had no improvement in visual acuity.

**Conclusion:** The retinal ischemia related to the persistence of a chronic retinal detachment is probably the cause of neovascular glaucoma. The removal of the ischemic retina with retinectomy combined with intraocular injection of anti-VEGF allowed the regression of the new vessels and the IOP control.

P-157

**Seven-year follow-up of spontaneously resolved primary congenital glaucoma: a case report**

Q Ye, Y Wang<sup>1</sup>, J Xu, M Yu, Y Yang.

<sup>1</sup>State Key Laboratory of Ophthalmology, Zhongshan Ophthalmic Center, Sun Yat-sen University, Guangzhou, People's Republic of China

**Objective:** To describe a case of unilateral spontaneously resolved primary congenital glaucoma at seven-year follow-up visit and the differential development of axial length between affected eye and healthy eye.

**Methods:** A six-year-old boy firstly presented at our hospital with expanded corneas and ruptures in Descemet's membranes (Haab's striae) and apparently thin retinal nerve fiber layer (RNFL) in the left eye, but normal intraocular pressure (IOP) of both eyes without anti-glaucoma medications or surgeries.

**Results:** At seven-year follow-up, the intraocular pressures of bilateral eyes were stable ranging from 8 to 11mmHg. A cup to disc ratio and the retinal nerve fiber layer (RNFL) was stable in the left eye at the following visit. The axial length (AL) increased almost 3mm in the right eye but 1.5mm in the left eye. Without anti-glaucoma medications or surgeries, the primary congenital glaucoma was spontaneously resolved.

**Conclusion:** Spontaneously resolved primary congenital glaucoma is rare and the mechanism remains unknown. It may figure out the development and influence of the affected eye of the patient, including axial length and refraction state with regular ophthalmic examination at periodically follow-up.

P-158

**Choroidal Detachment after Secondary Glaucoma in S-W Syndrome: A Case Report**Y Chen, F Wang<sup>1</sup>, Y Su<sup>2</sup>.<sup>1</sup>Ophthalmology, Fourth Affiliated Hospital of Harbin Medical University, <sup>2</sup>Ophthalmology, First Affiliated Hospital of Harbin Medical University, Harbin, People's Republic of China

**Objective:** Sturge-Weber syndrome (S-W syndrome, SWS), also known as cerebral facial hemangiomas, is a rare neurocutaneous syndrome, belonging to congenital neurocutaneous vascular dysplasia. The main manifestation is the hemangioma involving the pia meningeal, facial trigeminal innervation area and choroid. SWS can lead to severe complications of anterior segment of eyes involving conjunctiva and eyelids, whereas posterior segment may also be affected by diffuse choroidal hemorrhages. In this abstract, we reported a case of choroidal detachment after secondary glaucoma in S-W syndrome to elucidate the ocular manifestations, diagnosis, treatment and surgical complications of this syndrome.

**Methods:** An 25-year-old male patient was admitted due to "blurred vision for one week after glaucoma surgery of right eye". The right eye trabeculectomy was performed in another hospital one week ago for "right vision loss with eye pain for more than two years". The patient was diagnosed as secondary glaucoma of the right eye and Sturge-Weber syndrome. The current treatment was conservative, using drugs to reduce IOP, stop bleeding and promote blood absorption. According to the recovery, suprachoroidal drainage was further considered.

**Results:** S-W syndrome is a developmental disease of vascular malformation of the head and face. It is usually unilateral and often associated with intracranial hemangioma or eye invasion. Preoperative indirect ophthalmoscopy, ultrasound and fundus imaging should be performed in patients with S-W syndrome to prevent missed diagnosis of choroidal hemangioma. Choroidal hemangioma is not contraindicated in surgery, but will increase the risk of intraoperative suprachoroidal hemorrhage. As the most common ocular complication, the treatment of SWS secondary glaucoma should be individually assessed and designed for each case, based on intraocular pressure, disease stage and glaucoma type.

**Conclusion:** Treatment of S-W syndrome secondary glaucoma and prevention of its complications remain to be challenging tasks. Surgery is often required when medication cannot prevent persistent IOP elevation and the loss of visual function. Goniotomy and trabeculectomy have been successful in controlling IOP. The control of complications through various appropriate modifications of surgical approaches is currently being explored, and these experiences will provide new support for addressing the problems of secondary glaucoma to S-W syndrome and the risks of surgical treatment.



P-159

## Neovascular Glaucoma from Ocular Ischemic Syndrome Treated with Monthly Intravitreal Bevacizumab and Panretinal Photocoagulation

H Asif<sup>1</sup>, Z Si<sup>1</sup>, S Quan<sup>1</sup>, P Amin<sup>1</sup>, D Dao<sup>1</sup>, L Shaw<sup>1</sup>, D Skondra<sup>1</sup>, M Qiu<sup>1</sup>.

<sup>1</sup>University of Chicago Medicine, Chicago, United States

**Objective:** To describe a case of open-angle neovascular glaucoma (NVG) secondary to ocular ischemic syndrome (OIS) treated with a planned series of 6 monthly anti-VEGF injections with interspersed panretinal photocoagulation (PRP) sessions. We term this treatment protocol the Salvaging Conventional Outflow Pathway in Neovascular Glaucoma (SCOPING) Protocol, and this is our (MQ and DS) standard of care for all NVG patients presenting with partially or completely open angles.

**Methods:** Case report of a patient with NVG secondary to OIS treated with monthly anti-VEGF injections and PRP sessions interspersed.

**Results:** A 66-year-old man presented to our clinic asymptotically and his right eye was found to have a visual acuity of 20/50, intraocular pressure (IOP) of 42 mmHg on 0 IOP-lowering medications, and neovascularization of the iris (NVI) and angle (NVA) with no peripheral anterior synechiae (PAS). Fundus exam revealed mid-peripheral dot-blot-hemorrhages with no diabetic retinopathy or vein occlusion. Fluorescein angiography revealed profound peripheral retinal non-perfusion in both eyes without leakage. The patient was diagnosed with open-angle NVG secondary to OIS and treated with a course of 6 serial monthly anti-VEGF injections interspersed with 4 PRP sessions over 22 weeks, during which time his anterior segment neovascularization regressed and his IOP normalized on zero IOP-lowering medications. Ten weeks after the last injection, the anterior segment neovascularization and elevated IOP recurred, so he underwent 4 more monthly anti-VEGF injections and 4 PRP sessions over 16 weeks, during which time his anterior segment neovascularization regressed and his IOP normalized on zero IOP-lowering medications. However, 6 weeks after the last anti-VEGF injection, the anterior segment neovascularization and elevated IOP again recurred, so he was resumed on a third course of serial monthly anti-VEGF injections, which may be continued in perpetuity. Despite a total of over 4,000 spots of PRP, this eye had 2 recurrences of anterior segment neovascularization and elevated IOP when more than 1 month elapsed between anti-VEGF injections.

**Conclusion:** The patient's NVG was quiescent while under the protection of anti-VEGF injections, however, the disease recurred each time injections were stopped. Therefore, in patients with NVG secondary to OIS, monthly anti-VEGF injections may be necessary in combination with PRP to regress anterior segment neovascularization and maintain physiologic IOP.

**P-161****Study on relevance between lens zonule status and angle closure glaucoma**G Dang, Y xie, J Ma.

**Objective:** To explore the relationship between lens zonule and angle closure glaucoma(ACG) as well as their physiopathologic mechanism

**Methods:** The patients with clinically diagnosed angle-closed glaucoma(ACG) except secondary ACG from September 2020 to February 2022 were collected continuously, and the relevant data were analyzed. Measurements of beeline between equator of the lens and ciliary processes on 3,6,9,12 o'clock in UBM, and the length and laxity of lens zonule were evaluated. Lens arch high(LAH), the peak to angle-to-angle line vertical distance, were also measured. The lens thickness, anterior chamber depth, axial length and white to white were recorded by Master 700. Another 50 eyes of senile cataract without abnormalities were collected as contrast group.

**Results:** 455 eyes of 235 patients (male 68, female167) were enrolled with average age 67.3ys. Of all, including 226 right eyes and 229 left eyes, the average IOP was 24.07mmHg. The lens zonule length distribution on 3,6,9,12o'clock was 1.034mm, 1.088mm, 1.049mm, 0.908mm respectively; longer than contrast group's correspondent sites 0.728mm, 0.843mm, 0.578mm, 0.644mm (P<0.05) . LAH is also more protrude in study group than contrast group, 1.03mm vs 0.57mm. In some cases, the zonular shape like "wave type", indicating paralysis. This condition may lead to the lens more forward and thicker, so that shallower ACD as well as higher IOP.

**Conclusion:** To investigating the lens zonule status in angle closure glaucoma, finding its loosen facilitating to lens forward following shallow ACD and elevating IOP. Therefore, the lens zonule could play an important role in the pathogenesis of ACG. The theoretical basis maybe optimization of the treatments of these disorders.

P-162

**Case reports: Probable Association of an Attack of Bilateral Secondary Acute Angle-Closure With Immunosuppressant**

J Huang<sup>1</sup>, L Ye<sup>1</sup>, J Huang<sup>1</sup>.

<sup>1</sup>State Key Laboratory of Ophthalmology, Zhongshan Ophthalmic Center, Sun Yat-sen University, Guangdong Provincial Key Laboratory of Ophthalmology and Visual Science, Guangdong Provincial Clinical Research Center for Ocular Diseases, Guangzhou, People's Republic of China

**Objective:** To investigate the association between acute angle-closure secondary to lens zonular relaxation and systemic history of immunosuppressant therapy.

**Methods:** We report two cases of bilateral acute angle-closure due to lens zonular relaxation who were treated with immunosuppressants for systemic disease. Their etiology, diagnosis and treatment process were analyzed.

**Results:** Both cases were admitted to our hospital twice due to acute angle-closure of both eyes. At the first visit, the anterior chamber depth of affected eye and unaffected eye was asymmetrical (1.27mm and 1.79mm in case 1, and 1.48mm and 1.77mm in case 2). At the second visit (two years later in case 1, and four months later in case 2), the anterior chamber depth of the unaffected eye was significantly shallower (1.18mm in case 1, and 1.26mm in case 2). Case 1 was treated with long-term leflunomide for rheumatoid and case 2 was treated with long-term lenalidomide for multiple myeloma (MM) . Both patients denied a history of other systemic diseases, eye trauma and family genetic diseases. After completing preoperative preparation, two patients underwent phacoemulsification and intraocular lens implantation in both eyes, during which radial folds of the lens capsule were seen. Both leflunomide and lenalidomide are immunosuppressants. It is speculated that the use of immunosuppressants leads to gradual relaxation of the lens zonule, progressive shallow anterior chamber, and eventually to acute angle-closure glaucoma.

**Conclusion:** This is the first report to describe the clinical association between immunosuppressant and secondary acute angle-closure. For patients with acute angle-closure, especially those with a history of immunosuppressant therapy, we should identify primary or secondary factors to determine appropriate treatment options.

P-163

**Hydrochlorothiazide-induced hyponatremia – a bilateral acute angle closure glaucoma case report**S Teixeira<sup>1</sup>, R Rothwell<sup>1</sup>, D Meira<sup>1</sup>.<sup>1</sup>Centro Hospitalar Vila Nova de Gaia/Espinho, Vila Nova de Gaia, Portugal**Objective:** To report a case of bilateral acute glaucoma associated with hydrochlorothiazide- induced hyponatremia.**Methods:** Observational Case Report**Results:** An 83-year-old female patient presented at the emergency department with severe ocular pain and decreased visual acuity in both eyes, associated with headache, nausea and vomiting. She had history of arterial hypertension, dyslipidaemia, multinodular goiter and bronchiectasis. Her chronic medication was amlodipine, candesartan, hydrochlorothiazide, atorvastatin, euthyrox and cetirizine, and she denied recent changes in her medical prescription.

On ophthalmologic examination, visual acuity (VA) was counting fingers at 30 cm in both eyes. Biomicroscopy showed diffuse ciliary hyperemia, chemosis, marked corneal edema, shallow anterior chamber and nuclear cataracts in both eyes. Gonioscopy revealed bilateral angle closure. Intraocular pressure (IOP) was 59/68 mmHg. UBM showed bilateral ciliary body effusion with anterior rotation of the ciliar body. Topical hypotensive drugs, atropine and dexamethasone, intravenous mannitol and paracetamol were started. Blood tests revealed severe electrolyte imbalance with profound hyponatremia and hypochloraemia. After electrolyte stability, laser iridoplasty was performed in both eyes. The patient was discharged with topical dexamethasone, atropine, timolol and dorzolamide. Hydrochlorothiazide was suspended.

In subsequent reassessments, progressive clinic improvement and pain resolution, with normalization of IOP, allowed gradual tapering of medication. VA returned to its baseline values, as biomicroscopy.

**Conclusion:** Bilateral acute angle closure has been associated with sulfonamide derivative medications including topiramate, acetazolamide and hydrochlorothiazide. The development of bilateral ciliary effusions and angle closure potentially due to hydrochlorothiazide-induced-hyponatremia, had been reported only once in literature. Our case reinforces Chen S.H. (2014) findings.

**P-165**

**Angle closure Glaucoma in Patient with Nanophthalmos Eye. Does clear lens extraction matters? A case report.**

R Bhandari.

**Objective:** To determine the reduction of intra ocular pressure, after clear lens extraction in patient with Nanophthalmos.

**Methods:** In this case report, we treated two eyes of one patient with nanophthalmos with Glaucoma, with clear lens extraction and posterior intraocular lens (IOL) implantation.

**Results:** Clear lens extraction with IOL implantation helps in deepening the anterior chamber which results in opening of the angle due to which there is an increased outflow of fluid from anterior chamber and thereby reducing IOP

**Conclusion:** It is difficult to perform glaucoma surgery (trabeculectomy or a combined surgery involving Trabeculectomy with phacoemulsification and IOL implantation), as well post-operative period is difficult to manage. We need to perform sclerotomy before performing Trabeculectomy or a combined procedure. As well IOP reduction is important before surgery.

Clear lens extraction with IOL implantation helps in deepening the anterior chamber which results in opening of the angle due to which there is an increased outflow of fluid from anterior chamber and thereby reducing IOP and saving sight of the patient with less complication.

**P-166****Improving Eye Care Quality Using Adverse Event Reporting System in a Chinese Eye Hospital Group**H Lan.

**Objective:** The quality of medical care is important for the whole medical industry. For a large private eye hospital group with over 500 hospitals, it's always essential but difficult to manage eye care quality for hospitals of different scales. Adverse event has been given a high priority in medical care, as well as in eye care. In order to deliver better eye care, Aier Eye Hospital Group released an adverse event reporting system for all hospitals over the group.

**Methods:** The adverse event reporting system was established on the e-data reporting system of Aier Eye Hospital Group. Once an adverse event happens, the hospital is obliged to report the event online in details by filling out an e-form in 3 days. Information such as disease group, adverse event category, patient's eyesight and IOP, the process of diagnosis and treatment are required. We provided 12 eye disease groups and 17 adverse event categories for hospitals to choose, including surgical complication, communication and education disadvantages, hospital infection events, etc. Although most contents are provided by the doctor, the medical administration division of each hospital is authorized to audit and submit the form. With the real-time system, the medical management center of the group is able to review all adverse events on a daily basis. Meanwhile, the medical management team of each provincial district is required to review all adverse events in the district per month. We encourage hospitals to report adverse events by establishing incentives, while the permission of reviewing the events is only given to the person in charge of the corresponding level.

**Results:** As for the reporting of adverse events, the compliance of the hospitals has improved over the years, showing by the increasing amount of reported events. Up till 2022, all provincial districts with medical management groups are able to review monthly all adverse events happen in the area. Also, the medical management center is categorizing and reviewing the events on a daily and monthly basis. The main disadvantages in each district are analyzed, while specific measures are taken to improve eye care quality in certain district.

**Conclusion:** While adverse events may sound like disadvantages of the hospitals, the medical management team should be aware of them, and consider them as a way of delivering better eye care. We are still improving the system to make it more user-friendly, hoping it would become a better eye care quality control tool in the future.

P-167

**Knowledge, Attitudes, and Practices Toward Self-Medicating Eye Symptoms in Saudi Arabia**

A Khalaf<sup>1</sup>, D Alessa<sup>2</sup>, R AlHuthail<sup>2</sup>, S Almahfud<sup>1</sup>, A Alshngeetee<sup>1</sup>, S Alruwaili<sup>1</sup>, M Almutlq<sup>1</sup>.

<sup>1</sup>Al-Imam Mohammed Ibn Saud Islamic University, Riyadh, Saudi Arabia, <sup>2</sup>Ophthalmology Department, Al-Imam Mohammed Ibn Saud Islamic University, Riyadh, Saudi Arabia

**Objective:** Self-medication is the selection and use of drugs by individuals to treat self-diagnosed diseases or symptoms. While some patients regard self-medicating as harmless, it is far from being a safe practice. The aim of this study was to evaluate the knowledge, attitudes, and practices toward self-medicating eye symptoms in Saudi Arabia.

**Methods:** A cross-sectional study was conducted through an online questionnaire on a study population that consisted of Saudi nationals aged 18 and older who were using or had previously used ophthalmic medications.

**Results:** Among the 524 responses obtained, 79.4% were female, and more than half were less than 40 years old. Participants admitting to practicing ophthalmic self-medication measured 62.4%. The most commonly self-prescribed ophthalmic medications were artificial tears (n=276), followed by antiallergic (n=57) and antibiotic medications (n=33). Many participants reported that the reason for self-treatment was for repeated and simple symptoms that did not require professional care. While approximately 51% showed high levels of knowledge about ophthalmic medications, no significant relationship was seen with their choice to self-medicate (P=0.153).

**Conclusion:** Despite detecting a high level of knowledge and acceptable practices and attitudes among participants, a high incidence of self-medication was observed. This effect was mostly attributed to long hospital waiting times and patient self-diagnosis. Increasing the number of healthcare units and properly educating patients on ophthalmic medications may help decrease the incidence of self-medication.

P-168

**What are the challenges to managing refugee eye health?**

M Kurian, L *Jiang* .

**Objective:** Refugees are a diverse and vulnerable subgroup of the population, subject to a variety of communicable and non-communicable diseases. These include ocular health issues. This review will provide a brief overview of the challenges facing refugees regarding their ocular health.

**Methods:** The PRISMA-P 2015 protocol was used to conduct a literature review. Studies from 2010 onwards were considered. Literature search was conducted using key terms such as refugee, asylum seeker, displaced person, ophthalmology, eye, ocular and ophthalmic health. Search engines employed included PubMed, Medline and EMBASE. Of the 163 search results, 41 papers fitted the inclusion criteria and were reviewed.

**Results:** Refugees and asylum-seekers, including children, suffer from a range of treatable ocular pathologies including infection (e.g. trachoma), cataract, uncorrected refractive errors, and chronic conditions such as diabetic eye disease (1–5). Reduced vision has a direct impact on their physical and mental health. Challenges to managing ocular health include access to diagnostics, screening, follow-ups and specialist services (6–8).

**Conclusion:** Further emphasis must be provided for refugee eye health, in order to ensure that the ophthalmic needs of this population are met. Further research and provision of services for screening as well as management of ocular health conditions can be beneficial to this population.



**P-169****What are the challenges to managing refugee eye health?**M Kurian, L *Jiang* .

**Objective:** Refugees are a diverse and vulnerable subgroup of the population, subject to a variety of communicable and non-communicable diseases. These include ocular health issues. This review will provide a brief overview of the challenges facing refugees regarding their ocular health.

**Methods:** The PRISMA-P 2015 protocol was used to conduct a literature review. Studies from 2010 onwards were considered. Literature search was conducted using key terms such as refugee, asylum seeker, displaced person, ophthalmology, eye, ocular and ophthalmic health. Search engines employed included PubMed, Medline and EMBASE. Of the 163 search results, 41 papers fitted the inclusion criteria and were reviewed.

**Results:** Refugees and asylum seekers, including children, suffer from a range of treatable ocular pathologies including infection (e.g. trachoma), cataract, uncorrected refractive errors, and chronic conditions such as diabetic eye disease. Reduced vision has a direct impact on their physical and mental health. Challenges to managing ocular health includes access to diagnostics, screening, follow-ups and specialist services.

**Conclusion:** Further emphasis must be provided for refugee eye health, in order to ensure that the ophthalmic needs of this population are met. Further research and provision of services for screening as well as management of ocular health conditions can be beneficial to this population.

P-171

### An unusual case of submacular exudation in an elderly patient with no clinically evident choroidal neovascularisation

S P V.

**Objective:** Pachychoroid disease spectrum (PDS) refers to a group of clinical entities that have common choroidal findings which includes : 1) focal or diffuse choroidal thickening, 2) reduced fundus tessellation, 3) dilated Haller layer vessels ( pachyvessels) along with thinning of overlying inner choroid and 4) choroidal hyper permeability on indocyanine green angiography. Peripapillary pachy choroid syndrome is a new variant of PDS. To report a case of PPCS which responded to combination of intravitreal anti VEGF and photodynamic therapy.

**Methods:** 82 year old male presented with defective vision in left eye. BCVA was 6/6 in right eye and counting finger at 1 meter in left eye. Fundus showed choroidal t folds and few drusens in both eyes. Left eye showed large PED. OCT showed PED in left eye and thickening of retina nasal to fovea along with subretinal fluid. FFA showed peripapillary pigmentary changes and hyperfluorescence. ICGA revealed hypercyanescence in peripapillary area of both eyes and suspicious polyp in left eye. Since the lesion didn't respond to anti VEGF injection, choroidal imaging was done which showed thickened choroid in peripapillary area. Patient underwent half fluence PDT in area of peripapillary hypercyanescence in both eyes. Polyp received full fluence PDT. Both eyes also received anti VEGF injections.

**Results:** Fluid resolved in right eye. Left eye PED persisted

**Conclusion:** Pachychoroid disease constitute a spectrum which includes: 1) Pachychoroid pigment epitheliopathy, 2) Central serous retinopathy, 3) Pachychoroid neovascularopathy and 4) Polypoidal choroidal vasculopathy, PPCS is a new entity. No treatment guideline is described for this condition. Half fluence PDT to areas of hyperfluorescence and dilated capillaries along with Anti VEGF injection seem to be a treatment option in these patients.

**P-172**

**New perspectives in the re-evaluation of the AOFVD after long-term follow-up: a very rare case report.**

G Bellizzi.

**Objective:** Description of an atypical case of AOVFD with evaluation of its long-term evolution, reconsidering the role of RPE-choroid complex permeability and of photoreceptors dystrophy related to the alterations of BEST1 and PRPH2 genes.

**Methods:** Male patient with familial positivity for maculopathy, first diagnosis of epitheliopathy in 1982 at 25 years of age.

In 1993 moderate decrease in visual acuity with variable values in both eyes, metamorphopsias and first angiographic examination.

In 1997 angiographic diagnosis of Best's late dystrophy, with progressive decrease in visual acuity.

In 2010 tomographic and electrofunctional investigations confirmed an atypical AOFVD and low vision condition. Surgery was performed for relapsed exudative retinal detachments in the last advanced stage.

**Results:** The first angiographic examination described the clinical condition as a non-inflammatory but probably dystrophic exudative maculopathy, however the EOG and ERG flicker values were not initially altered as occurs in the Best.

Subsequent tomographic evaluations confirmed the initial sudden functional involution, both central and peripheral, however difficult to correlate with the apparently steady morphological condition.

Autofluorescence showed typical lesions in the advanced stage, therefore a genetic investigation with a larger panel was recommended.

Genetic investigation confirmed an AD-dystrophy with mutations of the genes BEST1 and PRPH2.

**Conclusion:** The evolution of retinal dystrophy observed in this long and rare 40-year follow-up allowed us to better understand the pathology, initially described as a late Best and after better defined as an atypical AOFVD, showing us the relevant role of the genetic component in permeability alterations of the RPE-choroid complex and photoreceptors atrophy.

P-173

**The unexpected role of pigment epithelium of retina in ARMD**

A Solis-Herrera, P Solis Arias<sup>1</sup>.

<sup>1</sup>*Clinical Researcher, Human Photosynthesis(r) Study Center, Aguascalientes, Mexico*

**Objective:** Macular degeneration remains among the top three causes of blindness worldwide. Available treatments have not changed their incidence and prevalence. Our discovery that melanin from the retinal pigment epithelium can dissociate water represents a disruptive finding.

**Methods:** Patients with ARMD of our ophthalmological center.

**Results:** In average, the patients improve their central vision significantly.

**Conclusion:** Melanin's hitherto unknown ability to dissociate the water molecule opens a new era in ophthalmology.

P-175

**Is abnormal choroidal vasculature the underlying cause for Torpedo Retinopathy?**S Rajasekaran<sup>1</sup>, F Ghanchi<sup>1</sup>.<sup>1</sup>*Ophthalmology, Bradford Teaching Hospitals NHS trust, Bradford, United Kingdom*

**Objective:** Torpedo Retinopathy is a rare clinical condition in which smooth, oval, solitary torpedo (bullet) shaped lesions occur in the retina. The etiology remains speculative, with the most accepted hypothesis being 'persistent defect in development of retinal pigment epithelium (RPE) in the fetal temporal bulge'. Observation of multimodal imaging in our cases reveal the varied morphology of the lesions, denoting different stages of progression. Hence an abnormal choroidal vasculature as a possible cause of etiology can be determined.

**Methods:** This is a retrospective observational case series. We reviewed the electronic medical records of three patients for the clinical details. All patients had multimodal imaging including colour fundus photography, fundus autofluorescence and optical coherence tomography (OCT). One patient had OCT-Angiography (OCT-A) in addition to the above investigations.

**Results:** Three patients with torpedo shaped lesions in the macula were studied. Two patients were in the paediatric age group (nine and ten years old) and one young adult. They were all asymptomatic with good visual acuity. OCT image of the nine year old patient showed Type 1 lesion with attenuation of interdigitation and ellipsoid zones without outer retinal cavitation, and that of the ten year old patient showed Type 2 lesion with outer retinal cavitation. OCT of the adult patient revealed excavated inner retinal layers, retinal thinning, photoreceptor loss, inner choroidal excavation representing a Type 3 lesion. OCT-A of the adult patient showed diffuse attenuation of choriocapillaries. The superficial retinal vascular plexus was normal hinting that the primary site of pathology is at the RPE/choriocapillaries.

**Conclusion:** Based on our observations from the three cases, we believe that progression of lesions from Type 1 to Type 2 or Type 3 can occur quickly, as opposed to the previous published reports that this could take decades to evolve from one type to the other. From our study of the OCT images, we support 'abnormal choroidal vasculature' hypothesis as the possible cause for Torpedo retinopathy. Therefore we strongly recommend periodic monitoring of these patients, as there is a possibility of developing a choroidal vascular membrane, which may require treatment.

P-176

**Advanced Eales' Disease With Neovascular Glaucoma at First Presentation**

H Alabdulhadi, M *Alfayyadh*, M *Almubarak*.

**Objective:** Eales' disease is an idiopathic vasculitis that affects the peripheral retina. It is characterized by recurrent vitreous hemorrhage as a complication of retinal neovascularization. It is more prevalent in India and affects young males. Here, we present a patient with neovascular glaucoma as a rare first presentation of Eales' disease.

**Methods:** This is a 24-year-old Indian male, who complained of a sudden decrease in vision in the left eye over less than 24 hours, along with frontal headache and eye pain for the last three weeks. Ocular examination revealed peripheral retinal ischemia in the right eye, very high intraocular pressure, rubeosis iridis, vitreous hemorrhage and extensive retinal ischemia in the left eye, vascular sheathing and neovascularization in both eyes. The purified protein derivative skin test was positive.

**Results:** The patient was managed with anti-glaucoma, intravitreal anti-vascular endothelial growth factor and laser photocoagulation. Systemic steroids and anti-tuberculous therapy were also initiated.

**Conclusion:** Neovascular glaucoma is an infrequent complication of Eales' disease. However, the lack of early detection of the disease in the early stages might lead to such serious complications.

P-177

**Bilateral blindness in a young male of rhino-orbital-cerebral mucormycosis: A case report**R Kaur, B Khan.

**Objective:** To report a rare finding of Bilateral blindness in a young male of rhino-orbital-cerebral mucormycosis.

**Methods:** The storm of COVID-19-associated mucormycosis (CAM) has not yet settled, and it has proven itself a disfiguring and potentially life-threatening disease, complicating the course of COVID-19 infection. Mucormycosis is a rare but devastating fungal infection caused by filamentous fungi of the family Mucoraceae. We report a rare case of a 37-year-old diabetic male with bilateral rhino-orbital-cerebral mucormycosis (ROCM) where it leads to bilateral central retinal artery occlusion (CRAO) as manifestation of the disease.

**Results:** Brain CT complemented with contrast-enhanced CEMRI of brain, PNS, and orbits showed bilateral maxillary and ethmoid sinusitis, bilateral medial and inferior turbinate hypertrophy, left premaxillary and left preseptal orbital cellulitis, acute infarct in left medial basifrontal lobe with bilateral cavernous sinus thrombosis (left > right). Mild narrowing of left internal carotid artery was also noted. KOH report of nasalswab revealed broad aseptate hyphae. The patient was put on posaconazole, and on seeing his kidney status, amphotericin B was withheld. Patient gave history of fever 2 months back. The patient was COVID-19 RT-PCR negative. Fundus examination was repeated after 24 hours which revealed bilateral CRAO. The patient underwent emergency left maxillectomy with left exenteration with right modified Denker approach under general anesthesia. Postoperatively, the patient was put on mechanical ventilation. Histopathological examination of sections from resected margin of optic nerve showed area of necrosis along with the presence of numerous broad aseptate, obtuse-angled branching hyphae invading the nerve bundles, thus confirming the diagnosis of mucormycosis. On 5th postoperative day, patient developed sudden bradycardia. All resuscitation measures were started immediately but unfortunately the patient could not be revived and was declared dead.

**Conclusion:** A strong suspicion of COVID-19 associated mucormycosis in uncontrolled diabetics can result in early diagnosis and management.

P-178

**PDLIM1 inhibits cell migration and invasion in diabetic retinopathy via negatively regulating Wnt3a**P Xie<sup>1</sup>, X Gao<sup>2</sup>.

<sup>1</sup>Ophthalmology, Beijing Anzhen Hospital, Capital Medical University, Beijing Institute of Heart, Lung and Blood Vessel Diseases, <sup>2</sup>Ophthalmology, Beijing Anzhen Hospital, Capital Medical University, Beijing, People's Republic of China

**Objective:** This study aimed to elucidate the role of PDLIM1 on retinal endothelial cells in DR.

**Methods:** Immunofluorescence staining was used to localize the expression of PDLIM1 in the mouse retina. Retinal capillary endothelial cells (RCECs) were treated with high-glucose, high-lipid (HG/HL), and siRNA transfection to investigate the role of PDLIM1 in DR. PDLIM1 and Wnt3a expression was confirmed by qRT-PCR and western blotting. Flow cytometry, Transwell assay, and scratch assay were used to detect cell apoptosis, migration, and invasion.

**Results:** PDLIM1 was mainly expressed in the retinal pigment epithelium (RPE) and photoreceptor layers (PRL). HG/HL increased Wnt3a levels and promoted cell apoptosis, migration, and invasion, which were reversed by the knockdown of PDLIM1.

**Conclusion:** PDLIM1 ameliorates cell apoptosis, migration, and invasion by negatively regulating Wnt3a in RCECs of DR, which suggests that PDLIM1 might be a promising therapeutic target for DR treatment.



P-179

### Engineering exosomes derived from Treg cells for management of choroidal neovascularization

Y Tao, Y Tian<sup>1</sup>.

<sup>1</sup>Ophthalmology, Beijing Chaoyang Hospital, Capital Medical University, Beijing, People's Republic of China

**Objective:** Choroidal neovascularization (CNV) induced by age-related macular degeneration and pathological myopia etc is one of the major causes of blindness. A single therapy with anti-VEGF (aV, vascular endothelial growth factor) was found incomplete in about half patients. In addition, a strong association between inflammation and high VEGF production is also reported in patients with CNV, while intraocular use of steroid aiming to control inflammation may induce cataract and glaucoma. Therefore, we propose a combined therapeutic strategy with engineering exosome to target both pathogenic pathways.

**Methods:** We engineered exosomes derived from regulatory T cells (rEXS) and conjugated them with aV antibodies using a peptide linker (cL), which is subject to cleavage by matrix metalloproteinases (MMPs) in inflammatory lesions. We rationalized that the nanodrug rEXS-cL-aV exploits the ability of rEXS to localize in lesions of neovascularization and, upon MMP-mediated cleavage, releases rEXS and aV to suppress inflammation and VEGF activity, respectively. We confirmed this activity using both murine and non-human primate models of CNV to develop a treatment with enhanced therapeutic efficacy.

**Results:** Transmission electron microscopy (TEM) revealed typical cup-like exosome morphology for rEXS-cL-aV with an average diameter of ~120 nm. After the induction of CNV, a mixture of rEXS and aV (rEXS+aV), rEXS-fL-aV, or rEXS-cL-aV was intravitreally injected. In the rEXS+aV-treated mice, the aV fluorescent signal in the vitreous chamber reduced by more than half within 24 h and almost disappeared within 96 h, while those of rEXS-fL-aV and rEXS-cL-aV were retained for longer periods, that is, > 50% for 96 h and ~1/4 at 7 days post-injection. Imaging revealed that rEXS-cL-aV-treated cynomolgus monkeys showed minimum pigment epithelial detachment (PED) and higher resolution of CNV lesions than other groups. Similar to the results in the CNV mouse model, high efficacy of rEXS-cL-aV was accompanied by the most pronounced reduction in both VEGF and proinflammatory cytokines.

**Conclusion:** The resulting nanodrug rEXS-cL-aV was tested in both murine and non-human primate models with CNV and demonstrated selective accumulation in diseased lesions and a high efficacy in suppressing neovascularization as compared to that exhibited by individual components or a simple mixture. Therefore, rEXS-cL-aV exhibits spatiotemporal delivery for combinatorial therapy, thus achieving enhanced efficacy for CNV.

P-182

## Retinal Vascular Profile in Predicting Incident Cardiometabolic Diseases among Individuals with Diabetes

B Betzler<sup>1</sup>, C Sabanayagam<sup>23</sup>, Y Tham<sup>23</sup>, C Cheung<sup>24</sup>, C Cheng<sup>235</sup>, T Wong<sup>235</sup>, S Nusinovic<sup>23</sup>.

<sup>1</sup>Yong Loo Lin School of Medicine, National University of Singapore, <sup>2</sup>Singapore Eye Research Institute,

<sup>3</sup>Ophthalmology and Visual Sciences Academic Clinical Programme, Duke-NUS Medical School, Singapore,

Singapore, <sup>4</sup>Department of Ophthalmology and Visual Sciences, The Chinese University of Hong Kong, Hong Kong,

People's Republic of China, <sup>5</sup>Department of Ophthalmology, Yong Loo Lin School of Medicine, National University of Singapore, Singapore, Singapore

**Objective:** Changes in retinal vascular profile (RVP) are known to be associated with cardiometabolic diseases. However, little is known about their performance to predict risk of cardiometabolic events. This study aimed to 1) determine the longitudinal associations between RVP and four major cardiometabolic diseases; and 2) quantify performance improvements in predicting these diseases when adding RVP beyond traditional risk factors (RF) in individuals with diabetes.

**Methods:** Subjects were enrolled from the Singapore Epidemiology of Eye Disease (SEED) study, a multi-ethnic Asian population-based prospective cohort study. 4 cardiometabolic diseases were considered: cardiovascular disease (CVD), hypertension (HTN), diabetic kidney disease (DKD) and hyperlipidaemia (HLD). Their incidences were calculated between baseline and follow-up visits ~6 years later. The RVP was characterized at baseline by 5 parameters – vessel tortuosity, branching angle, branching coefficient, fractal dimension, and vessel calibre – for both retinal arterioles and venules; and the DR status. Traditional RFs included age, sex, ethnicity, body mass index (BMI), smoking, blood pressure (BP), education level, estimated glomerular filtration rate (eGFR), HbA1c, and total or LDL cholesterol. We compared the performance of two different models: (1) with 'RF only' and (2) with 'RF plus RVP'. Comparison was done using area under the receiver operating characteristics curve (AUC), Integrated Discrimination Index (IDI), Nagelkerke's R-square ( $R^2$ ), and Net Reclassification Improvement (NRI).

**Results:** The study population comprised 1,770 individuals with diabetes. Incidences were 6.3% (n=79/1259) for CVD, 48.7% (n=166/341) for HTN, 14.6% (n=175/1199) for DKD, and 59.4% (n=336/566) for HLD. DR and narrower arteriolar branching angle were associated with increased CVD risk. Narrower arteriolar calibre, and wider arteriolar branching angle were associated with increased risk of HTN. Finally, DR was associated with increased risk of DKD. Regarding the predictive performance of RVP beyond RF, the largest improvement was found for HTN with AUC increment of 0.034,  $R^2$  increment of 0.058, and IDI of 0.048. Furthermore, adding RVP allowed better reclassification of 11.4% of cases and 4.6% of controls.

**Conclusion:** We found in our large, multi-ethnic, population-based cohort that RVPs substantially improved the prediction of HTN in individuals with diabetes, but add limited information for CVD, DKD and HLD predictions.

P-183

### The effect of subretinal fluid reduction on macular function in age-related macular degeneration treated with anti-VEGF therapy

T Nishimura<sup>1</sup>, S Machida<sup>1</sup>.

<sup>1</sup>Ophthalmology, Dokkyo Medical University Saitama Medical Center, Koshigaya, Japan

**Objective:** A small amount of subretinal fluid (SRF) remaining after anti-VEGF therapy for age-related macular degeneration (AMD) has been reported to have no adverse effect on the visual prognosis evaluated by the best corrected visual acuity (BCVA). The aim is to determine the SRF amount which would not influence the macular function from an electrophysiological point of view.

**Methods:** Intravitreal aflibercept injections (IVA) were made monthly for 3 months in 47 eyes of 47 AMD patients without previous treatment. The focal macular electroretinogram (fmERG) and spectral-domain optical coherence tomography (OCT) were recorded before and after the treatment. In OCT images, the SRF thickness was measured from the ellipsoid zone to the retinal pigment epithelium. The fmERG b-wave amplitude was recorded by using a 15 ° circular stimulus spot. The correlation coefficients between the SRF thickness reduction (SRF reduction) and the b-wave amplitude improvement (b-wave recovery) after the treatments were determined.

**Results:** The SRF disappeared in all cases after the consecutive three IVAs. The BCVA improvement did not correlate with the SRF reduction. The median values of the SRF reduction and b-wave recovery were 76.5 (5-180)  $\mu\text{m}$  and 0.4 (0.1-1.4)  $\mu\text{V}$ , respectively. These factors were non-linearly and significantly correlated ( $R = 0.67$ ,  $P < 0.001$ ), which was expressed by an equation of  $Y = 252.6 * X / X + 0.754$  in which X and Y represent the b-wave recovery and SRF reduction, respectively. According to the equation, when the SRF reduction was less than 29.6  $\mu\text{m}$ , the b-wave recovery was less than 0.1  $\mu\text{V}$  which is the minimum measurable unit of the fmERG.

**Conclusion:** When the AMD eyes with the SRF less than 30  $\mu\text{m}$  in thickness were treated with IVAs, significant improvement of the fmERG b-wave was not obtained. Therefore, the macular function may not be expected to improve by anti-VEGF therapy within the initial 3 months in case that the SRF thickness is less than 30  $\mu\text{m}$ .

P-184

## Efficacy, Safety and Immunogenicity of SUN Ranibizumab Biosimilar compared with Reference Ranibizumab in nAMD

A Ghosh<sup>1</sup>, N Subhash<sup>2</sup>, C Shukla<sup>3</sup>, R Lau<sup>4</sup>, A Dixit<sup>5</sup>, S Mahapatra<sup>6</sup>, S Nayak<sup>7</sup>, U Shah<sup>8</sup>, S Parwal<sup>9</sup>, N Venkatapathy<sup>10</sup>, N Radhakrishnan<sup>11</sup>, A Kelgaonkar<sup>12</sup>, S Saxena<sup>13</sup>, D Mishra<sup>14</sup>, V Dave<sup>15</sup>, P Khan<sup>16</sup>, M Saswade<sup>17</sup>, S Malli<sup>18</sup>, K Ramasamy<sup>10</sup>, S K. S.<sup>19</sup>, P Patel<sup>20</sup>, S Behera<sup>20</sup>, M Rajurkar<sup>20</sup>, M Vakharia<sup>20</sup>, P Rohira<sup>20</sup>, L Lakhwani<sup>20</sup>, S Joglekar<sup>20</sup>.

<sup>1</sup>Regional Institute of Ophthalmology, Medical College, Kolkata, <sup>2</sup>Department of Ophthalmology, B. J. Govt. Medical College And Sassoon General Hospital, Pune, <sup>3</sup>Lotus Multispeciality Hospital, Ahmedabad, <sup>4</sup>Chopda Medicare & Research Centre Pvt. Ltd, Nashik, <sup>5</sup>Sankat Mochan Nethralaya and dental care, Varanasi, <sup>6</sup>JPM Rotary Club of Cuttack Eye Hospital & Research Institute, Cuttack, <sup>7</sup>L V Prasad Eye Institute, Vijayawada, <sup>8</sup>Pagarav Hospital, Gandhinagar, <sup>9</sup>SMS Hospital, Jaipur, <sup>10</sup>Aravind Eye Hospital & Postgraduate Institute of Ophthalmology, Coimbatore, <sup>11</sup>Amrita Institute of Medical Sciences and Research Centre, Kochi, <sup>12</sup>L V Prasad Eye Institute, Bhubaneswar, <sup>13</sup>King George's Medical University, Lucknow, <sup>14</sup>Sankara Eye Hospital, Bangalore, <sup>15</sup>L V Prasad Eye Institute, Hyderabad, <sup>16</sup>Department of Ophthalmology, GSVM Medical College, Kanpur, <sup>17</sup>Saswade Netra Rugnalay & Omkar Lasik Laser Centre, Aurangabad, <sup>18</sup>Diva Eye Institute, Ahmedabad, <sup>19</sup>KLEs Dr Prabhakar Kore Hospital & MRC, Belagavi, <sup>20</sup>Sun Pharmaceuticals Laboratories Ltd., Mumbai, India

**Objective:** This study was planned to demonstrate comparability in terms of efficacy, safety and immunogenicity of SUN ranibizumab biosimilar with reference ranibizumab (Accentrix®) in patients with neovascular age related macular degeneration (nAMD).

**Methods:** This randomized, double-blind, parallel-group, phase 3 equivalence study of 16 weeks was conducted at 20 centers across India in 161 nAMD patients aged ≥50 years. Patients received 0.5 mg intravitreal injection of SUN ranibizumab or reference ranibizumab (2:1) in the study eye every 4 weeks. Primary endpoint was proportion of patients losing <15 letters from the baseline best corrected visual acuity (BCVA) in the study eye at week 16.

**Results:** Baseline demographic and disease characteristics were comparable between both the groups. At 16 weeks, 99% in SUN ranibizumab group and 100% in reference ranibizumab group lost fewer than 15 letters (p>0.99); with proportion difference (90% CI) at -1% (-2.51, +0.61). Visual acuity improved by 15 or more letters in 43% of SUN ranibizumab group and 37% of reference ranibizumab group (p=0.43). Mean increase in visual acuity was 15.7 letters in SUN ranibizumab group and 14.6 letters in reference ranibizumab group (p=0.53). Mean change in central macular thickness was comparable in both the groups (p= 0.79). Five ocular treatment emergent adverse events were reported in this study. Of these, 2 (1.8%) were in SUN ranibizumab group (conjunctivitis) and 3 (5.6%) were in reference ranibizumab group (conjunctivitis, eye irritation and retinal hemorrhage). Anti-ranibizumab antibodies were

found in one study patient only (in reference ranibizumab group). Neutralizing antibodies were not found in the study patients.

**Conclusion:** SUN ranibizumab biosimilar is found to be therapeutically equivalent to reference ranibizumab (Accentrix®) in nAMD and there were no additional safety or immunogenicity concerns.

P-185

### Flow Dynamic comparison of single and dual cutting action 27G vitrectomy probes

S Tambat<sup>1</sup>, A Irannejad<sup>1</sup>, V Wuyyuru<sup>1</sup>, D Steel.

<sup>1</sup>Alcon, lake forest, United States

**Objective:** To compare the SOI (sphere of influence) and pulsatile motion around 27g dual and single cutting action vitrectomy probes.

**Methods:** The micro-PIV experiments and CFD simulation models of 27+<sup>®</sup> Advanced UltraVit (Single action dual pneumatically activated beveled tip) 10,000 cuts per minute (cpm) and 27+<sup>®</sup> HyperVit (Dual action cutting) 20,000 cpm with a beveled tip were used to compare flow motion around the probe tip. Vitrectomy system parameters such as applied vacuum settings of 650 mmHg, with a 50/50 duty cycle setting on the CONSTELLATION<sup>®</sup> Vision System were applied for both micro-PIV and CFD simulations in a BSS filled beaker.

**Results:** A large number of cycles were used for the PIV analysis. The average of these cycles was used to represent the ensemble averaged cycle to minimize the effect of PIV error. The micro-PIV results indicating the transient evolution of the pointwise velocity in the nearfield of the probe tip showed that the mean velocity of HyperVit was higher compared to that of AdvUltraVit probes at matched vacuums. The Advanced UltraVit showed a higher fluctuation magnitude compared to HyperVit Probes. The mean velocity of HyperVit probe approached that of AdvUltraVit under matched flow conditions while its velocity fluctuation intensity was further lowered.

Reynolds number and Intensity of Velocity Root Mean Square (RMS) were used in the CFD simulations to compare the mean velocity and intensity of pulsatile motion, respectively. They were measured on spheres of increasing radius from the probe tip and maximum values were recorded. In agreement to the micro-PIV results, the quantification of velocity fluctuation intensity in CFD simulations showed that it was significantly reduced for the HyperVit compared to Advanced UltraVit probes. A pointwise transient evolution comparison between CFD and PIV is also presented for both probes.

**Conclusion:** Micro-PIV experiments and CFD simulations were used to compare flow dynamics in the nearfield of the Vitrectomy probe tip. Flow performance of the 27 gauge HYPERVIT probes had more stable aspiration, which was shown by a reduction in the pulse intensity of velocity during fluid aspiration, whilst having an enhanced overall flow rate over the cycle. Reduced pulsatile motion may enhance safety of the vitreoretinal surgery. Simulations may help surgeons better understand differences in probe performance and optimize instrument selection and settings.

**P-186****Control in Myopia Progression and Change in subfoveal Choroidal Thickness under Low-intensity Red-light and Orthokeratology Therapy**

X Wang.

**Objective:** To investigate the efficacy of ameliorating myopia progression and change of subfoveal choroidal thickness after low-intensity red light and orthokeratology therapy

**Methods:** This was a prospective, randomized, controlled clinical study. Totally 153 children aged 6-13 years with myopia ranging from -0.75 to -6.00D in both eyes were recruited and randomly assigned to undergo the treatment of LRL, or orthokeratology (OK), or single-focus spectacles (control group, SFS) for 1 year. Outcome measures were axial length (AL), cycloplegic spherical equivalent refraction (SE), subfoveal choroidal thickness (SFCT) and best corrected visual acuity (BCVA), which were measured at baseline, 1-, 3-, 6- and 12-month.

**Results:** Of 153 subjects, 134 (87.6%) children completed the 12-month follow-up and included in the final analysis (n=46 in LRL, n=48 in OK and n=40 in SFS group). The mean 12-month axial elongation was  $0.01 \pm 0.003$  mm and  $0.12 \pm 0.01$  mm in the LRL group and OK group, compared with  $0.39 \pm 0.03$  mm in the control group, representing a 97.4 % and 69.2 % slowing axial elongation in the LRL group and OK group, respectively. The mean 12-month SER progression was  $0.05 \pm 0.07$  D and  $-0.64 \pm 0.07$  D in the LRL group and control group, with a relative reduction of 100 % in myopia progression. Changes in SFCT observed at 12-month were  $21.56 \pm 4.75 \mu\text{m}$ ,  $12.75 \pm 2.28 \mu\text{m}$ , and  $-11.30 \pm 3.00 \mu\text{m}$  for the LRL, OK and control group, respectively.

**Conclusion:** LRL therapy is an effective and relatively safe clinical measurement to control myopia progression among Chinese children in low and moderate myopia, showing an greater effect than OK treatment. Additionally, both LRL and OK therapy can increase SFCT significantly, where the former shows a lasting and stable increase of SFCT and a closer negative correlation between the changes of SFCT and AL.

P-187

**PM 2.5 Induces Migration and Epithelial Mesenchymal Transition via Mediating the PI3K/AKT/mTOR Pathway in ARPE-19 Cells**Y Hung, H Lin, M Hsu, Y Chang.

**Objective:** Exposure to PM2.5 (particulate matter with a diameter less than 2.5  $\mu\text{m}$ ) has been linked to ocular surface diseases, yet knowledge of the molecular mechanism impacted on retina is limited. Therefore, the purpose of this study was to assess the effects and involved cellular mechanisms in APRE-19 cells with PM2.5 exposure.

**Methods:** The wound healing capabilities of the cells treated with PM2.5 was assessed by cell migration study on ARPE-19 cells. ARPE-19 cells were exposed to different concentrations of PM2.5 (12.5, 25, and 50  $\mu\text{g/ml}$ ) for 48 h. The Bio-Rad protein assay kit was used to measure the protein concentrations of the samples. Protein levels were then analyzed using enhanced chemiluminescence method. MMP-9 and MMP-2 proteolytic activity assay were performed by gelatin zymography. The supernatants of cells treated with PM2.5 were collected. IL-6 and IL-8 levels were measured using IL-6 and IL-8 ELISA kits (R&D systems) following the standard protocols. The protein concentrations of each samples were calculated according to the standard curve.

**Results:** Our data revealed that decreased cell viability as well as increased migratory ability were observed in APRE-19 cells after PM2.5 exposure for 48 h in a dose-dependent manner. Furthermore, a fibroblast-like shape in APRE-19 cells treated with PM2.5 was found. Both MMP-2 and MMP-9 protein levels and gelatinase activities of MMP-2 were markedly increased, but TIMP1 and TIMP-2 were significantly reduced in APRE-19 cells exposed to PM2.5. Additionally, PM2.5 promoted the activation of AKT and mTOR, which were linked with expression EMT, such as E-cadherin were elevated. Most importantly, inflammatory cytokines IL-6 and IL-8 were also remarkably increased in the cells treated with PM2.5 in a dose-dependent manner.

**Conclusion:** Taken together, the current study demonstrated the possible mechanisms of APRE-19 cells exposed to PM2.5 and provide a potential value for treatment of PM-induced retinal disease.



P-188

## Intravitreal anti-VEGF agents compared to intravitreal steroid treatments for ME secondary to RVO: a meta-analysis

A Hatamnejad<sup>1</sup>, N Patil<sup>1</sup>, A Mihalache<sup>2</sup>, M Popovic<sup>3</sup>, P Kertes<sup>4</sup>, R Muni<sup>5</sup>.

<sup>1</sup>Michael DeGroot School of Medicine, McMaster University, Hamilton, <sup>2</sup>Faculty of Science, University of Western Ontario, London, <sup>3</sup>Department of Ophthalmology and Vision Sciences, University of Toronto, <sup>4</sup>John and Liz Tory Eye Centre, Sunnybrook Health Sciences Centre, <sup>5</sup>Department of Ophthalmology, St. Michael's Hospital/Unity Health Toronto, Toronto, Canada

**Objective:** The role of intravitreal steroids in macular edema (ME) secondary to retinal vein occlusion (RVO) is not entirely well understood. This meta-analysis aims to compare the efficacy and safety of intravitreal anti-vascular endothelial growth factor (anti-VEGF) agents and intravitreal steroids for the treatment of ME secondary to RVO.

**Methods:** A systematic literature search was conducted on Ovid MEDLINE, EMBASE, and the Cochrane Controlled Register of Trials for studies published between January 2005 and November 2021. Randomized clinical trials (RCTs) reporting on patients with ME secondary to RVO who were treated with intravitreal steroids or anti-VEGF agents were included in our analysis. We excluded non-English studies, observational studies, and studies that included combination treatments. The risk of bias was assessed using Cochrane's risk of bias tool 2 and GRADE recommendations were used to assess the certainty of evidence. A random-effects meta-analysis was performed.

**Results:** 11 RCTs of 867 eyes at baseline were included in this meta-analysis. At final follow-up, intravitreal anti-VEGF agents were associated with a significantly better BCVA (intravitreal steroids: ~20/60, intravitreal anti-VEGF agents: ~20/41, WMD=-0.13 logMAR, 95% CI=[-0.17,-0.08], p<0.00001) and significantly lower retinal thickness (WMD=-37.66 µm, 95% CI=[-55.60,-19.73], p<0.0001) relative to intravitreal steroids. There were similar findings at 3-, 6-, 9-, and 12-month timepoints. Intravitreal anti-VEGF agents were associated with a significantly lower incidence of IOP-related adverse events (RR=0.26, 95% CI=[0.14,0.48], p<0.0001), cataract development/progression (RR=0.24, 95% CI=[0.11,0.55], p=0.0007) and conjunctival hemorrhage (RR=0.52, 95% CI=[0.32,0.86], p=0.01).

**Conclusion:** Overall, this meta-analysis of 11 RCTs found a superiority of anti-VEGF treatment in comparison to steroid treatment for ME secondary to RVO with regards to BCVA, OCT outcomes, and adverse events. These conclusions were consistent across different timepoints. This updated analysis provides an important context for the treatment of ME secondary to RVO and provides further evidence of the superiority of anti-VEGF agents relative to steroid treatment in this setting.

P-189

**FABP-5 in the vitreous fluid is a possible clinical parameter of retinal vascular diseases**

M Higashide<sup>1</sup>, M Furuhashi<sup>2</sup>, A Umetsu<sup>1</sup>, Y Tsugeno<sup>1</sup>, S Suzuki<sup>1</sup>, Y Ida<sup>1</sup>, M Watanabe<sup>1</sup>, F Hikage<sup>1</sup>, H Ohguro<sup>1</sup>.

<sup>1</sup>Ophthalmology, <sup>2</sup>Cardiovascular, Renal and Metabolic Medicine, Sapporo Medical University, School of Medicine, Sapporo, Japan

**Objective:** Fatty acid-binding proteins (FABPs), a family of molecules, are involved in the intracellular lipid transportation to specific cellular compartments to stimulate several lipid-associated responses. The aim of this study was to report significant elevations of the vitreous levels of FABP4 (Vt-FABP4) and FABP5 (Vt-FABP5), and vascular endothelial growth factor A (VEGFA) (Vt-VEGFA) in patients with proliferative diabetic retinopathy (PDR) or retinal vein occlusion (RVO) compared to controls.

**Methods:** Total forty eight patients (mean age 66 years  $\pm$  10years, 19 males and 29 females) with PDR (n=20), RVO (n=10, CRVO; n=3, BRVO; n=7) or controls (epiretinal membrane, n=18) who underwent vitrectomies were enrolled in the present study. The concentrations of Vt-FABP4, Vt-FABP-5 and Vt-VEGFA were determined by enzyme-linked immunosorbent assays (ELISA). To assess the correlation analyses of their Vt-FABP4, Vt-FABP5 and V-VEGFA with several systemic and ocular indices, the ocular blood flow by laser speckle flow-graphy (LSFG), height and weight, systemic blood pressures and several blood biochemistry (FBS, HbA1c, Cr, BUN, AST, ALT,  $\gamma$ -GTP, total cholesterol, triglycerides, hsCRP, eGFR) were analyzed.

**Results:** The levels of Vt-FABP5 were significantly ( $P < 0.05$ ) elevated in patients with PDR or RVO as compared to control patients. Such elevation was more evident in patients with RVO than with PDR. Log Vt-FABP5 was significantly correlated negatively or positively with all the LSFG ocular circulation indices or Log triglycerides ( $r = 0.31$ ,  $p = 0.031$ ), respectively. However in contrast, the Vt-FABP4 and Vt-VEGFA levels were elevated more evidently in the PDR group ( $p < 0.05$ ) and those were correlated positively with Log fasting glucose and negatively with some of the LSFG indices. Multivariable regression analyses indicated that the LSFG of the optic disc at baseline was an independent factor with Log Vt-FABP5 other than several possible factors including age, gender, Log triglycerides, Log Vt-FABP4 and Log Vt-VEGFA.

**Conclusion:** These current findings suggest that Vt-FABP5 is involved in the pathogenesis of PDR or RVO in a manner that is different from that for Vt-FABP4 and Vt-VEGFA, presumably by regulating retinal circulation.

P-190

## Causal Effects of N-6 Polyunsaturated Fatty Acids on Age-related Macular Degeneration: A Mendelian Randomization Study

K Wang<sup>1</sup>, K Yao<sup>1</sup>.

<sup>1</sup>Eye Center of the Second Affiliated Hospital, School of Medicine, Zhejiang University, Hangzhou, People's Republic of China

**Objective:** Although the role of n-6 polyunsaturated fatty acids (PUFAs) in age-related macular degeneration (AMD) has been studied in previous observational studies, the precise manner in which one or more n-6 PUFAs account for this relationship remains unclear. Using genetic instruments for n-6 PUFAs traits implemented through mendelian randomization (MR), we aimed to study possible causal associations between n-6 PUFAs and AMD.

**Methods:** The two-sample MR method was used to obtain unconfounded causal estimates. We selected genetic variants strongly associated ( $P < 5 \times 10^{-8}$ ) with circulating linoleic acid (LA) and arachidonic acid (AA) from a study involving 8,631 individuals and applied to an AMD case-control study (33,526 participants and 16,144 cases). The weighted median and MR Egger methods were used for the sensitivity analysis.

**Results:** Our MR analysis suggested that circulating LA was a causal protective factor for AMD, with an odds ratio (OR) estimate of 0.967 (95% confidence interval [CI] 0.945 to 0.990;  $P = 0.005$ ) per percentage in total fatty acid increase in LA. In contrast, higher genetically predicted circulating AA causally increased the AMD risk (OR = 1.034; 95% CI 1.012 to 1.056;  $P = 0.002$ ). Sensitivity analysis provided no indication of unknown pleiotropy. The findings from different single-nucleotide polymorphism selections and analytic methods were consistent, suggesting the robustness of the causal associations.

**Conclusion:** Our study provided genetic evidence that circulating LA accounted for protective effects of n-6 PUFAs against the risk of AMD, whereas AA was responsible for deleterious effects on higher AMD risk.

P-191

### Real-world Treatment Patterns of Retinal Vein Occlusion in China: Results of OPERA Study

X Zhao<sup>1</sup>, Y Chen<sup>2</sup>, X Chen<sup>3</sup>, H Guan<sup>4</sup>, C Zhang<sup>5</sup>, X Pu<sup>5</sup>, S Zhang<sup>5</sup>, X Zhu<sup>5</sup>, H Dai<sup>6</sup>, L Lu<sup>1</sup>.

<sup>1</sup>State Key Laboratory of Ophthalmology, Zhongshan Ophthalmic Center, Sun Yat-sen University, Guangzhou, <sup>2</sup>Peking Union Medical College Hospital, Beijing, <sup>3</sup>The First Affiliated Hospital of Xinjiang Medical University, Xinjiang, <sup>4</sup>Affiliated Hospital of Nantong University, Nantong, <sup>5</sup>Novartis Pharmaceuticals, Shanghai, <sup>6</sup>Beijing Hospital, Beijing, People's Republic of China

**Objective:** To describe ranibizumab's treatment patterns of patients with macular edema secondary to retinal vein occlusion (RVO-ME) in "real-world" clinical settings in China.

**Methods:** OPERA, the Chinese largest real-world study in retina to date, is a multicenter, prospective, non-interventional observational study of ocular treatment with intravitreal injections of ranibizumab of patients (treatment-naïve or prior ranibizumab-treated) with wet age-related macular degeneration (wAMD), diabetic macular edema (DME), or RVO-ME. The duration of the study was 18 months for recruiting, with a 12-month follow-up period per patient.

**Results:** The OPERA study enrolled 2223 patients from 51 hospitals. A total of 219 patients with RVO-ME (136 BRVO patients and 83 CRVO patients) were observed. Overall, patients received an average 2.4 injections (SD 1.6) of ranibizumab and were followed in 2.4 visits (SD 1.7) during the 12-month treatment period. The median interval time between injections was 43 days, with the prior-treatment group having significantly longer median interval time between injections (58.5 days) than the treatment naive group (40.4 days) ( $p < 0.001$ ). In general, at baseline, the mean BCVA was 52.0 letters (SD 23.8); 50.9% of patients demonstrated a  $\geq 10$ -letter increase within the first 3 months (59.4% BRVO, 40% CRVO), and the mean BCVA change was 7.2 letters (SD 22.6) at year 1 ( $p = 0.128$ ).

Forty-three patients (19.6%) had records of ischemic status at baseline. The number of intraocular procedures among the ischemic patients was significantly higher than non-ischemic patients (1.3 vs 0.2,  $p = 0.006$ ). Non-ischemic patients received more loading injections than ischemic patients (1.7 vs 1.2 injections;  $p = 0.004$ ). The mean interval time between injections among the ischemic patients was significantly longer than in non-ischemic patients (72 vs 48 days,  $p = 0.041$ ).

**Conclusion:** The findings of the study showed that patients with RVO in routine practice in China received fewer injections and attended fewer visits compared to clinical trials or other real-world studies. Meanwhile, it is also noteworthy that ischemic patients received less treatments and had longer treatment interval than non-ischemic patients, which imply that ischemia status should be paid more attention during treatment. These real-world data may help to improve routine clinical practice for RVO patients.

P-192

### Secretogranin III as a disease-selective ligand to alleviate choroidal neovascularization

L Ji<sup>1,2,3</sup>, P Waduge<sup>1</sup>, J Zhao<sup>2,3</sup>, J Zhang<sup>2,4</sup>, H Tian, W Li<sup>1</sup>.

<sup>1</sup>Baylor College of Medicine, Houston, United States, <sup>2</sup>Ophthalmology, The Fourth Affiliated Hospital of China Medical University, Eye Hospital of China Medical University, <sup>3</sup>The Key Lens Research Laboratory of Liaoning Province, <sup>4</sup>Aier Excellence Eye Hospital, Shenyang, People's Republic of China

**Objective:** Wet age-related macular degeneration is characterized with choroidal neovascularization (CNV), which affects the central vision. This study aims to discover disease-selective target to alleviate CNV with optimal efficacy and safety.

**Methods:** CNV was induced by laser photocoagulation in mice. Comparative ligandomics profiling was conducted to screen CNV-restricted endothelial ligands. An innovative in vivo ligand binding assay was developed to independently quantify binding activity and selectivity of identified endothelial ligands to CNV vessels. A unique technique of functional immunohistochemistry (FIHC) was created to visualize ligand binding sites on healthy and CNV vessels. A ligand-neutralizing humanized antibody Fab fragment (hFab) was developed and characterized using OCTET and ELISA. The neutralizing activity of the hFab was analyzed in HUVEC cells, and its therapeutic activity was determined in CNV mice. CNV severity and ligand-dependent therapeutic activity were characterized in ligand-knockout (KO) mice.

**Results:** Comparative ligandomics identified secretogranin III (Scg3) as a CNV-selective binding ligand with 65,455:70 binding activity ratio for CNV:healthy choriocapillaris. The disease binding selectivity of Scg3 was independently confirmed in CNV mice using by in vivo ligand binding assay and visualized by FIHC. Anti-Scg3 hFab specifically bound to Scg3 protein with a high affinity ( $K_D=8.7$  nM). The hAb was confirmed for its neutralizing activity in HUVECs and conferred with high efficacy to alleviate CNV in mice. No ocular abnormality was found in Scg3-KO mice, but CNV severity was markedly reduced in Scg3<sup>-/-</sup> mice. Anti-Scg3 hFab, but not the anti-VEGF drug aflibercept, alleviated CNV in an Scg3-dependent manner.

**Conclusion:** Scg3 is a CNV-selective angiogenic factor, and anti-Scg3 hFab is a promising disease-targeted VEGF-independent anti-angiogenic therapy for CNV with wide therapeutic window and optimal safety.

P-193

**Protection of Retina by Lemon Extract On Sodium Iodate Induced Age-Related Macular Degeneration Model**Y Hung, H Lin, M Hsu, Y Chang.

**Objective:** Age-related macular degeneration (AMD), a disease of aging, which could lead to gradual vision loss with unclear mechanism and ineffective treatment. Sodium iodate ( $\text{NaIO}_3$ ), a natural oxidant, has been reported with ability to induce AMD-liked retinal pigment epithelial (RPE) cells and retinal degeneration on human and mice, and widely applied in AMD research. Lemon was known for rich flavonoids and antioxidants, but the effects on AMD remain unclear. So, the aim of this study was to evaluate the potential of lemon on  $\text{NaIO}_3$ -induced AMD model *in vitro* and *in vivo*.

**Methods:** In this study, we evaluated the effectiveness of lemon extract under different extraction conditions by TEAC, DPPH, flavonoids and polyphenol content assay. Then, we screen the influence of lemon extract pretreatment on  $\text{NaIO}_3$ -induced ARPE-19 (human RPE) cells oxidative damage by MTT and anti-oxidative enzymes assay kits, as well as  $\text{H}_2\text{DCF-DA}$ , JC-1 and Western blotting. Contemporary, H&E staining and pupil constriction testing were adopted to investigate the protection of lemon extract on  $\text{NaIO}_3$ -treated mice.

**Results:** Our data indicated that lemon extract significantly regulation  $\text{NaIO}_3$ -induced ARPE-19 cells mitochondrial dysfunction and apoptosis though reduced the level of ROS via reduced Catalase, GSH activity and p-Nrf-2 and SOD-1/2 expression. *In vivo*, lemon extract can restored the anti-oxidant enzymes activity, and also reduced the retinal thinning and pupil dysfunction induced by  $\text{NaIO}_3$ .

**Conclusion:** This research supports Lemon extract has potential on preventing AMD or other retinal diseases involving in RPE oxidative stress and apoptosis.

P-195

### Idiopathic Retinal Vasculitis, Aneurysms, and Neuroretinitis syndrome (IRVAN): A Case Report with Literature Review.

D Sinnayya<sup>1</sup>, P Lott<sup>2</sup>, T Mohamed Iqbal<sup>2</sup>.

<sup>1</sup>Ophthalmology, University Malaya, <sup>2</sup>Ophthalmology, University of Malaya, Kuala Lumpur, Malaysia

**Objective:** To report the challenges in diagnosing a case of idiopathic retinal vasculitis, aneurysms, and neuroretinitis syndrome (IRVAN) syndrome in a middle-aged female with multiple co-morbidities.

**Methods:** Case report

**Results:** A 60-year-old Malay female with underlying seropositive rheumatoid arthritis, diabetes mellitus, hypertension, atrial fibrillation, and dyslipidaemia presented with 2 weeks history of floaters associated with flashes over the right eye (OD). On examination, best-corrected visual acuity was 6/6 in both eyes. Right eye anterior segment examination was normal. However, fundus examination revealed 3 macroaneurysms at the superotemporal quadrant along the arcade, dot and blot haemorrhages at the posterior pole, splinter haemorrhage superiorly and gliosis of the inferior optic disc. There were also epiretinal membrane and grade 3 hypertensive retinopathy changes. The patient's left eye (OS) examination findings were normal. A provisional diagnosis of right retinal vasculitis secondary to rheumatoid arthritis with macroaneurysms and grade 3 hypertensive retinopathy was made which was later revised to IRVAN syndrome. Our patient demonstrated 2 out of the 3 major criteria of IRVAN syndrome: retinal vasculitis and aneurysmal dilatations. She differs from a typical patient with IRVAN reported in literature which is usually a young individual in their third decade with bilateral involvement.

IRVAN has not reported any consistent disease association. To our knowledge, this is the first reported case of patient with both rheumatoid arthritis and IRVAN. The presence of both rheumatoid arthritis and IRVAN in our patient could have occurred by chance alone. However, an association is plausible as both conditions affect the vasculature. Retinal arterial aneurysms are a key feature in IRVAN and unlike in hypertension, aneurysms in IRVAN show extensive dynamics in location, shape and size. A detailed fundus examination along with multimodal imaging aids in the diagnosis of this rare condition.

Patients can progress to severe vision threatening sequelae as evident in our patient despite good response initially. A close follow up is hence advisable for patients with IRVAN syndrome.

**Conclusion:** IRVAN syndrome continues to present with atypical features as reported by many other authors. However, in the presence of multiple co-morbidities, a thorough evaluation of the findings is required. Management of IRVAN is still challenging and a late diagnosis can result in severe vision loss.

P-196

## Retinal Microvascular Development in the First Six Years: A Novel Measurement with Artificial Intelligence

G Liu<sup>1</sup>, A Jiang<sup>1</sup>, F Lu<sup>1</sup>.

<sup>1</sup>Department of Ophthalmology, West China Hospital, Sichuan University, Chengdu, People's Republic of China

**Objective:** Retinal microvasculature pathology plays an important role in many fundus lesions in children and even some chronic illness in their later life. However, little was known on the normal retinal microvasculature, due to limited sample size and difficulty in measuring. The purpose of the study was to determine the normal retinal microvascular development in the first six years by month and provide base parameters of retinal microvasculature for future studies.

**Methods:** Young children, aged from birth to six years old, with only one abnormal eye undergoing fundus fluorescein angiography from January 1st, 2019 to October 31st, 2021 in West China Hospital, Sichuan University were selected. Fundus images were taken with RetCam 3 system and a 130-degree wide-angle lens was used to film the images centering optic disc. An automatic computer-based image analysis system was developed to measure fractal dimension, diameter, tortuosity and density of retinal microvasculature.

**Results:** 146 normal eyes of 146 children were included. 64 (43.84%) were females, 125 (85.62%) were full-term, 124 (84.93%) were weighed normally and 120 (82.19%) had no history of oxygen during birth. A decline of 0.001 was showed in fractal dimension with growth ( $y=-0.001x+1.548$ ,  $R=0.273$ ,  $P=0.001$ ). For vessel diameter, an obvious decline was found in those under 3 years old ( $y=-0.023x+7.228$ ,  $R=0.438$ ,  $P<0.001$ ), but a slight increase happened from 4 years old without statistical significance ( $y=0.007x+6.199$ ,  $R=0.163$ ,  $P=0.245$ ). The change of vessel tortuosity showed the similar trend with diameter. Vessel tortuosity decreased in the first 3 years ( $y=-0.00005x+0.009$ ,  $R=0.251$ ,  $P=0.015$ ), but vessel tortuosity did not change in the next 3 years with a mean of  $0.010 \pm 0.002$ . Age had little impact on the density of retinal microvasculature with a coefficient approaching 0 and a  $P=0.541$ .

**Conclusion:** Children under 3 years old seemed to remodel retinal microvasculature, which was reflexed by vessel diameter and tortuosity. During the first 3 years of life, retinal microvascular diameter and tortuosity were more likely to decrease, and then slightly increase in next 3 years. The fractal dimension and density of vessels had a decline trend in the first 6 years, but the coefficients were approximately 0, which had little impact on the structure and distribution of retinal microvasculature. Findings from this study could help future investigators better understand early microvasculature development, especially in the first 3 years of life.



P-197

## PREVALENCE OF MICROALBUMINURIA IN PATIENTS WITH TYPE 2 DIABETES MELLITUS HAVING DIABETIC RETINOPATHY IN A TERTIARY CARE HOSPITAL

S Dutta, P Sarkar<sup>1</sup>.

<sup>1</sup>Calcutta National Medical College and hospital, Kolkata, KOLKATA, India

**Objective:** To find out the prevalence of microalbuminuria in diabetic retinopathy patients with type 2 diabetes attending the outpatient department of a tertiary care hospital in eastern India and to find out the association if any between microalbuminuria and severity of diabetic retinopathy

**Methods:** This cross sectional study included 200 type 2 diabetic patients of age 30 years and above diagnosed with diabetic retinopathy. Patients with known other organic eye disease, pregnancy, renal or cardiac disorder, liver disorder, urinary tract infection and those who did not give consent were excluded from the study. Preliminary tests included laboratory blood tests and ophthalmologic examination. Urine for albumin estimation and albumin creatinine ratio(A:C) were done using Konelab 20 Autoanalyzer by immunoturbidimetry method in early morning urine sample. Microalbuminuria was considered when A:C ratio of 30-299mg/g or urine albumin excretion of 30 - 299mg was found. Diabetic retinopathy severity classification was done as per International Diabetic Retinopathy Severity Scales into mild, moderate, severe non proliferative diabetic retinopathy (NPDR) and proliferative diabetic retinopathy(PDR). SPSS 20 software used for statistical analysis

**Results:** The prevalence of microalbuminuria was found to be 36% (72 patients) of which 11.67% had mild NPDR, 19.28% had moderate NPDR, 88.24% had severe NPDR and 82.61% had PDR. 93.06% patients with microalbuminuria had clinically significant macular edema. Statistically significant correlation ( $P < 0.001$ ) was found between severity of diabetic retinopathy with urine microalbumin excretion in mild, moderate and severe NPDR patients.

**Conclusion:** The present study demonstrated statistically significant correlation between severity of diabetic retinopathy and urine microalbumin excretion in type 2 diabetic patients with mild, moderate and severe NPDR and almost similar prevalence of microalbuminuria in patients with severe NPDR and PDR with slight preponderance in severe NPDR category. A larger community based study is required for external validity of the results.

P-198

## Intravitreal dexamethasone and triamcinolone acetonide compared to anti-VEGF treatment for DME: a meta-analysis

A Hatamnejad<sup>1</sup>, N Patil<sup>1</sup>, A Mihalache<sup>2</sup>, M Popovic<sup>3</sup>, P Kertes<sup>4</sup>, R Muni<sup>5</sup>.

<sup>1</sup>Michael DeGroot School of Medicine, McMaster University, Hamilton, <sup>2</sup>Faculty of Science, University of Western Ontario, London, <sup>3</sup>Department of Ophthalmology and Vision Sciences, University of Toronto, <sup>4</sup>John and Liz Tory Eye Centre, Sunnybrook Health Sciences Centre, <sup>5</sup>Department of Ophthalmology, St. Michael's Hospital/Unity Health Toronto, Toronto, Canada

**Objective:** Diabetic macular edema (DME) can be treated with intravitreal anti-vascular endothelial growth factor (VEGF) injections or intravitreal corticosteroid injections. We provide an updated comprehensive meta-analysis of the comparative efficacy and safety of intravitreal steroids and anti-VEGF agents for DME.

**Methods:** A systematic search was performed on Ovid MEDLINE, EMBASE, and Cochrane Controlled Register of Trials from January 2005 to November 2021. Study screening and selection was conducted by two independent reviewers with conflicts resolved by consultation with a third reviewer. Inclusion criteria included published randomized clinical trial (RCT) data comparing the efficacy and safety of intravitreal steroids versus anti-VEGF agents for DME. Non-randomized, non-comparative, and non-English studies were excluded. Data extraction and synthesis was conducted by two independent reviewers. Cochrane's risk of bias tool 2 and ROBINS-I were used to assess risk of bias and GRADE evaluation was conducted to assess certainty of evidence. Random-effects meta-analysis was conducted.

**Results:** Fourteen RCTs reporting on 827 eyes were included. Between these two modalities, our analysis revealed no significant difference in BCVA outcomes at 3 months ( $p=0.11$ ), 6 months ( $p=0.21$ ), 12 months ( $p=0.24$ ), and final follow-up ( $p=0.93$ ). Retinal thickness was significantly lower with steroid treatment at 3 months ( $p=0.04$ ), 6 months ( $p<0.00001$ ), and final follow-up (WMD=39.99 microns, 95% CI=[14.58,65.41],  $p=0.002$ ), however there was no significant difference at 12 months ( $p=0.18$ ). Intravitreal steroids were associated with a higher incidence of IOP-related adverse events (RR=0.15, 95% CI=[0.07,0.32],  $p<0.00001$ ). There was no significant difference between comparators for other adverse events, including cataract development or progression ( $p=0.22$ ).

**Conclusion:** Overall, intravitreal steroid treatment for DME was associated with no significant differences in BCVA, a significantly lower retinal thickness, and a higher risk of IOP-related events at last study observation. Our meta-analysis of RCTs found no significant difference between treatment modalities for most adverse events, including cataract-related adverse events. Our results reinforce the importance of a continual reevaluation of the role of intravitreal steroids in DME management.

**P-199****Perifoveal Exudative Vascular Anomalous (PEVAC) In Our Center**H Tapia Quijada, N Betancor Caro.

**Objective:** To investigate the clinical characteristics of Perifoveal Exudative Vascular Anomalous Complex (PEVAC) patients diagnosed in the University Hospital of Canarias .Tenerife-Spain

**Methods:** This retrospective study included 7 eyes (of 7 patients) diagnosed with PEVAC. We reviewed the demographic characteristics. All of our patients had undergone a complete ophtalmological examination including color retinography, Optical Coherence Tomography (OCT), fluorescein angiography (FA) and OCT-Angiography (OCTA). We also reviewed the follow-up information.

**Results:** Of our 7 patients, 3 were women and 4 were men. The average age and standard deviation was 71.0 +/- 12.8 years. Average visual acuity was 0.54 +/- 0.24. Of our 7 patients, 4 had no remarkable comorbidities, 2 had age related macular degeneration (AMD) and 1 patient myopic degeneration. PEVAC presented as a big isolated perifoveal aneurysm. On OCT PEVAC appeared as a round hyperreflective lesion, typically surrounded by intraretinal cystic spaces. FA showed a well-defined hyperfluorescent lesion with variable leakage. OCTA revealed that the isolated aneurysmatic lesion was located in the superficial capillary plexus in 2 cases; in the deep capillary plexus in 4 cases and in 1 case it seemed to be in the intermediate plexus. In 5 cases there was only subtle exudation that did not require treatment, remaining stable during follow up. In two cases exudation was greater, so we treated them with anti-VEGF, with partial response.

**Conclusion:** PEVAC is an aneurysmatic isolated perifoveal abnormality that can occur in patients with or without retinal disease such as AMD or myopic degeneration. PEVAC does not appear to respond to anti-VEGF therapy.

P-200

**Efficacy of Bevacizumab in the treatment of macular edema secondary to retinal vein occlusion : real life study**K Fekih<sup>1</sup>, M Ouederni<sup>1</sup>, I Ouederni<sup>1</sup>, R Maamouri<sup>1</sup>, M Cheour<sup>1</sup>.<sup>1</sup>ophthalmology, Hbib Thameur university Hospital, Tunis, Tunisia

**Objective:** Macular edema (ME) is the most common cause of vision loss during retinal vein occlusion (RVO). The aim of the present study was to evaluate the efficacy of intravitreal (IV) Bevacizumab injections in the treatment of ME related to RVO “in real life”.

**Methods:** A retrospective descriptive study ,from January 2018 to December 2020, was performed in 30 eyes of 30 patients with ME secondary to RVO and treated with IV Bevacizumab injections, with more than 6 months follow-up. We collected data from medical history, standardized ophthalmic evaluation and swept-source optical coherence tomography (SS-OCT) at baseline and after treatment.

The following parameters were assessed: duration of symptoms before injection, number of IV Bevacizumab injections, side effects, evolution of visual acuity (VA) and foveal status evaluated on SS-OCT.

We studied the prognostic factors for visual and anatomical outcome.

**Results:** Thirty eyes of 30 patients with a mean age of 62,77 years and a sex ratio of 1. 67% of patients were hypertensive, 27% diabetic, 27% dyslipidemic and 43% glaucomatous. The mean number of injections was 5,17 and the mean duration of follow-up was 15,07 months.

The mean baseline VA changed from 1,17 to 0,55 logMAR ( $p=0,000$ ) with a gain of 2 lines or more in 40% of patients, while the mean macular central thickness (MCT) went from 598,53 to 283,33  $\mu\text{m}$  ( $p=0,000$ ).

The final foveolar profile was favorable in 73% and unfavorable in 27% of patients. We noted microcystic degeneration in 6 eyes, epimacular membrane in 5 eyes, macular atrophy in 2 eyes and lamellar macular hole in one eye.

Final VA was correlated with short duration of symptoms before injection ( $p=0,011$ ), better baseline VA ( $p=0,000$ ) and the absence of baseline ellipsoid line alteration ( $p=0,006$ ).

Good anatomical outcome was correlated with a short duration of symptoms before injection ( $p=0,001$ ), associated laser photocoagulation treatment ( $p=0,019$ ), increased number of injections ( $p=0,022$ ) and absence of baseline ellipsoid line alteration ( $p=0,018$ ).

**Conclusion:** Intravitreal Bevacizumab injections proved to be an effective and well-tolerated treatment for ME due to RVO. Duration of symptoms before treatment, baseline VA and baseline ellipsoid line alteration are the most predictive factors of a good visual outcome.

## P-201

**The impact of residual retinal fluid following intravitreal anti-VEGF therapy for DME and ME secondary to RVO: a systematic review**

A Mihalache<sup>1</sup>, N Patil<sup>2</sup>, A Dhoot<sup>3</sup>, M Popovic<sup>4</sup>, R Muni<sup>4,5</sup>, P Kertes<sup>4,6</sup>.

<sup>1</sup>Faculty of Science, University of Western Ontario, London, <sup>2</sup>Michael DeGroot School of Medicine, McMaster University, Hamilton, <sup>3</sup>Faculty of Medicine, <sup>4</sup>Department of Ophthalmology and Vision Sciences, University of Toronto, <sup>5</sup>Department of Ophthalmology, St. Michael's Hospital/Unity Health Toronto, <sup>6</sup>John and Liz Tory Eye Centre, Sunnybrook Health Sciences Centre, Toronto, Canada

**Objective:** Traditionally, anti-vascular endothelial growth factor (VEGF) treatment regimens aim for complete fluid resolution, however recent findings in neovascular age-related macular degeneration (nAMD) have suggested that residual subretinal fluid may not negatively impact visual acuity. The roles of residual subretinal fluid (SRF) and intraretinal fluid (IRF) on visual acuity for DME and ME secondary to RVO are not well established. In this systematic review, we summarize the existing literature in this domain.

**Methods:** A systematic literature review was performed for studies published between January 2005 – January 2022 on Ovid MEDLINE, EMBASE, and Cochrane CENTRAL. Study screening and selection was conducted by two independent reviewers with conflicts resolved by consultation with a third reviewer. Peer-reviewed observational studies or RCTs reporting on visual acuity outcomes stratified by SRF, IRF, or any retinal fluid at final follow-up after intravitreal anti-VEGF injection for the treatment of DME or ME secondary to RVO were included. Cochrane's risk of bias tool 2 and ROBINS-I were used to assess risk of bias.

**Results:** Overall, five studies of 613 eyes were included. Two observational studies found no significant differences between eyes with residual retinal fluid and no residual retinal fluid for final BCVA, while one study found a greater visual gain in eyes with no residual retinal fluid. One analysis of RCT data found that eyes with retinal fluid at final follow-up had a significantly worse BCVA than eyes without retinal fluid, whereas another RCT found no significant difference for change in BCVA from baseline. No studies reported on outcomes stratified by the presence of SRF or IRF.

**Conclusion:** There is a paucity of evidence examining the impact of residual retinal fluid on visual acuity outcomes in DME and ME secondary to RVO. The limited evidence may suggest that aggressive fluid resolution is worthwhile in patients with these conditions, however, further investigation in this setting is warranted.

P-202

**Induction of cGMP–PKG signaling in monkey retina explant culture for RD research**

W Xu<sup>1</sup>, Y dong<sup>1</sup>, Y li<sup>1</sup>, Z hu<sup>1</sup>, F Paquet-Durand<sup>2</sup>, K jiao<sup>1</sup>.

<sup>1</sup>Yunnan Eye Institute & Key Laboratory of Yunnan Province, Affiliated Hospital of Yunnan University, Kunming, China., Kunming, People's Republic of China, <sup>2</sup>Institute for Ophthalmic Research, Eberhard-Karls-Universität Tübingen, Germany., Tuebingen, Germany

**Objective:** To establish an in vitro monkey model of retinal degeneration (RD) of making most appropriate for RD research.

**Methods:** Developed for establishing a monkey retinal explant culture. Treated it with different concentrations of the PDE6b inhibitor *zaprinast* to induce the cGMP–PKG signaling pathway, similar to that observed in RD pathogenesis.

**Results:** We noted that the treatment of the in vitro retinal model with 400  $\mu$ M *zaprinast* exhibited the largest number of TUNEL-positive cells, a significant cGMP signal, and low toxicity.

**Conclusion:** The successful induction of the cGMP–PKG signaling pathway makes this model appropriate for use in the comprehensive investigation of RD pathogenesis and research for the development of optimal therapies for RD

P-203

**An overview of the efficacy and safety of Qiming granule for diabetic retinopathy in type 2 diabetes patients**

M Shi<sup>1</sup>, X Leng<sup>1</sup>, X Liu<sup>1</sup>, G Li<sup>1</sup>, X Lu<sup>1</sup>.

<sup>1</sup>Chengdu University of Traditional Chinese Medicine, Chengdu, People's Republic of China

**Objective:** To evaluate the efficacy and safety of Qiming granule in the treatment of diabetic retinopathy.

**Methods:** English databases including PubMed, Ovid database, the Cochrane library, WOS, Embase, and Chinese databases including CBM, CNKI, VIP, Wan fang Database were searched for the meta-analyses of comparing Qiming granule with other treatments. The odds ratio and standardized mean differences were used to calculate the overall efficacy, visual acuity, and central macular thickness, respectively.

**Results:** The overall efficacy in the treatment group was greater than that in the control group (OR=3.33, 95% CI [2.86, 3.88], I<sup>2</sup>=0.0%). The visual acuity in the treatment group was lower than that in the control group (SMD=-0.20, 95% CI [-0.34, -0.07], I<sup>2</sup>=0.0%). The central macular thickness in the treatment group was lower than that in the control group (SMD=-1.01, 95% CI -0.7 [-1.34, -0.68], I<sup>2</sup>= 85.8%).

**Conclusion:** The pooled result indicated that Qiming granule was effective and safe in the treatment of diabetic retinopathy, and it is a more effective and economical choice for patients with relatively poorer vision. Pan retinal photocoagulation combined with Qiming granule is more recommended for patients with severe macular edema.

P-204

**Diabetic Retinopathy as an Independent Prognostic Factor: An Inpatient COVID-19 Cohort Study**

M Jaffry, H Choudhry, O Kothari, K Mandava , K Jaffry, M Ahmed, M Ors, A Ahmed, R Trivedi, N Souayah.

**Objective:** Diabetic retinopathy (DR) as a factor in the prognosis of COVID-19 has previously been suggested to be associated with poorer outcomes. We aim to investigate the effect of DR as a factor in selected outcomes of COVID-19 patients.

**Methods:** An analysis of 920 patients who were hospitalized with COVID-19 was conducted between March 2020 and March 2021. Of these patients 724 did not have diabetes (COVID-19N), 177 patients had diabetes without retinopathy (COVID-19DM) and 20 patients had diabetic retinopathy (COVID-19DMR). The length of stay (LOS), discharge disposition and mortality were compared. Multivariable binary logistic regression was performed adjusting for variables such as age and race to discern if LOS and diabetic retinopathy status were significant predictors of mortality.

**Results:** Average LOS in days was not significantly different between COVID-19N, COVID-19DM and COVID-19DMR (11, 10 and 10  $p>0.05$ ). For COVID-19N patients 80% of patients were discharged routinely, 20% were discharged to a skilled nursing facility (SNF), long term care facility (LTC), or home health service (HHS) and 9% expired. In COVID-19DM patients, 68% were discharged routinely, 25% were discharged to SNF, LTC or with HHA and 6% expired. In COVID-19DMR patients, 60% were discharged routinely, 20% were discharged to SNF, LTC or with HHS and 20% expired. Multivariable regression revealed that increased LOS was a significant predictor of mortality (OR= 1.019, 95% CI 1.006-1.032,  $p=.003$ ). In COVID-19DMR patients, although there was increased incidence of mortality compared to COVID-19N patients, the increased risk did not reach levels of significance.

**Conclusion:** These preliminary results suggest that DR was associated with increased mortality, with an increased LOS. Work is currently being done to utilize a larger sample size, characterization of type of DR, whether proliferative or non-proliferative, stratification by age and comorbidities as well as use of other established markers of poorer COVID-19 prognosis. LOS should be marginalized in COVID-19 patients to reduce the risk of mortality.



P-205

**Ranibizumab Treatment of Symptomatic Exudative Retinal Arterial Macroaneurysm**H Tapia Quijada.

**Objective:** To assess the anatomical and functional results in symptomatic exudative retinal arterial macroaneurysms (RAM) treated with ranibizumab.

**Methods:** Observational retrospective study including 10 patients with 10 eyes with diagnosis of exudative symptomatic retinal arterial macroaneurysm. Given that the RAMs were located within the superior and inferior temporal arcades, they were treated with intravitreal ranibizumab (Lucentis®). Patients received a loading dose of 3 monthly injections of ranibizumab (0.5mg/0.05ml) followed by an additional injection if necessary. Best corrected visual acuity (BCVA) and central macular thickness (CMT) was assessed both prior to the treatment as well as posteriorly in the follow up visits.

**Results:** 10 patients were included, of whom 5 were men and 5 were women. The average age was 72.9 years. The average follow-up period was  $7.9 \pm 2$  months, during which there was a remarkable visual and anatomical recovery (all patients improved their BCVA 3 or more Snellen lines). BCVA improved significantly compared to baseline BCVA from  $0.21 \pm 0.2$  to  $0.6 \pm 0.28$ .

The average decrease after treatment in CMT measured with OCT was also significant, decreasing from  $590.2 \pm 163.8 \mu\text{m}$  previous to treatment to  $291,6 \pm 61.4 \mu\text{m}$  after treatment. No complications were observed with the intravitreal injection of ranibizumab.

**Conclusion:** Injections of anti-vascular endothelial growth factor may be a therapeutic option in cases of symptomatic exudative RAM. Other types of studies are needed to recommend this treatment in this entity.

**P-206****Effect of  $\alpha$ -tocopherol in the prevention of retinal cells apoptosis in diabetic rats model**

A Ichsan<sup>1</sup>, A Bukhari<sup>2</sup>, S Lallo<sup>3</sup>, U Miskad<sup>4</sup>, A Dzuhry<sup>1</sup>, I Islam<sup>1</sup>, H Muhiddin<sup>1</sup>.

<sup>1</sup>Ophthalmology, <sup>2</sup>Clinical Nutrition, <sup>3</sup>Pharmaceutical Science, <sup>4</sup>Pathology, Hasanuddin University, Makassar, Indonesia

**Objective:** This study aims to examine the effect of  $\alpha$ -tocopherol compound to prevent apoptosis of the retinal layers of the diabetic rat model.

**Methods:** Diabetic induction using alloxan 150mg/kgBW in a single dose intraperitoneally. Administration of 15mg/kgBW  $\alpha$ -tocopherol were given to each animal model for 7 days post induction and 14 days (7 days pre and post induction). Evaluation of apoptosis examined by caspase-3 and caspase-7 expression in retinal ganglion cells (RGCs) and retinal photoreceptor cells using immunohistochemistry methods, then the cell densities were analyzed by Hematoxylin and Eosin staining.

**Results:** Statistical analysis on the caspase-3 showed that wild type group has IHC expression of  $16.80 \pm 3.70$ , diabetic control group was  $76.20 \pm 14.97$ ,  $\alpha$ -tocopherol group for 7 days was  $32.80 \pm 2.28$ , then  $\alpha$ -tocopherol group for 14 days was  $38.60 \pm 7.79$  ( $p=0.010$ ). The caspase-7 expression revealed that the IHC expression on the wild type group was  $18.60 \pm 1.94$ , in diabetic control group was  $77.20 \pm 10.82$ ,  $\alpha$ -tocopherol group for 7 days was  $27.20 \pm 3.27$ , then  $\alpha$ -tocopherol group for 14 days was  $32.40 \pm 4.50$  ( $p=0.010$ ).

**Conclusion:** In diabetic rats,  $\alpha$ -tocopherol plays a role in preventing the death of retinal cells and become a potential adjuvant therapy for diabetic retinopathy cases.

P-207

**PREVALENCE OF DIABETIC RETINOPATHY AND ITS ASSOCIATED RISK FACTORS AMONG DIABETIC PATIENTS AT SÃO GERALDO HOSPITAL - MINAS GERAIS**

H Porfírio<sup>1</sup>, P Barbosa<sup>1</sup>, N Dias<sup>1</sup>, G Provenzano<sup>1</sup>, D Almeida<sup>1</sup>, M Nehemy<sup>1</sup>, M Frasson<sup>1</sup>.

<sup>1</sup>Universidade Federal de Minas Gerais, Belo Horizonte, Brazil

**Objective:** To describe the epidemiological profile of diabetic patients assisted at São Geraldo Hospital (Minas Gerais Federal University, Brazil), the risk factors for the development of diabetic retinopathy and its prevalence.

**Methods:** This cross-sectional study was conducted among 369 diabetic patients screened for diabetic retinopathy, between January 2016 and December 2018. Epidemiological data were collected from medical records, including risk factors for diabetic retinopathy, comorbidities and clinical characteristics of each patient. Data was entered in EpiData 3.1 and exported to SPSS 20 for analysis. Binary logistic regression with 95% confidence interval was used. Simple binary logistic regression followed by multiple binary logistic regression analysis was conducted to identify associated factors. Odds Ratio and 95% CI were calculated.  $p < 0,05$  was considered significant.

**Results:** Diabetic retinopathy was detected in 176 patients. The risk factors involved on the onset of diabetic retinopathy identified by univariate regression analysis were diabetes duration greater than 15 years (OR=4.9, 95% CI=2.8-8.5), insulin use (OR=1.6, 95% CI=1.01-2.5), systemic arterial hypertension (OR=2.0, 95% CI=1.3-3.1), nephropathy (OR=2.2, 95% CI=1.3-3.8) and obesity (OR=1.9, 95% CI=1.2-3.0). The multiple logistic regression analysis selected obesity (OR=2.08, 95% CI=1.19-3.64) and diabetes duration greater than 15 years (OR=5.87, 95% CI=3.14-10.97).

**Conclusion:** Obesity and diabetes duration greater than 15 years were highly associated with the development of diabetic retinopathy in the sample analyzed.

P-208

## Evaluation of Choroidal & Macular thickness by SD-OCT in the Natural Progression of Myopia in Indian patients

D Desai.

**Objective:** To measure choroidal and macular thickness via SD- OCT in myopic eyes of Indian subjects and correlate them with the refractive error and myopia progression.

**Methods:** This is a prospective observational analytical study in 148 eyes of 74 myopic subjects who were between the ages of 15 years to 40 years. Spectral Domain Optical Coherence Tomography with enhanced depth imaging was performed on all subjects using HD 5- line Raster centered around the fovea. The measurements of both the choroidal and retinal thickness at the macula were taken vertically as well as horizontally in 5 different quadrants as specified by the ETDRS. Baseline scans were taken when the participant entered the study and then repeated after a temporal interval of 6 months. Participants were then grouped into three – low, moderate and high myopia - based on the degree of refraction and subjected for statistical analysis. The two sets of data which were recorded 6 months apart were coded and recorded in MS Excel spreadsheet program and compared. SPSS v23 (IBM Corp.) was used for data analysis.

**Results:** At baseline, the mean retinal thickness decreased by 2.17microns with every 1D increase in myopia ( $\rho = -0.47$ ,  $p = <0.001$ ). At follow up, the mean retinal thickness decreased by 1.87 microns with every 1D increase in myopia ( $\rho = -0.34$ ,  $p = <0.001$ ). Strongest correlation was seen in moderate and High myopia subgroups where 1D increase showed a decline in the mean retinal thickness by 3.22 and 4.54 microns respectively.

At baseline , the mean choroidal thickness decreased with the increase in myopia ( $\rho = -0.1$ ,  $p = 0.301$ ). At follow up , the mean choroidal thickness decreased by 5.48 microns with every 1D increase in myopia( $\rho = -0.39$ ,  $p = <0.001$ ).

At follow up, for every increase in the dioptric difference, the mean retinal thickness difference reduced by 8.70 microns ( $\rho = -0.26$ ,  $p = 0.005$ ). The overall change in mean choroidal thickness was not statistically significant with myopia.

**Conclusion:** There is a significant difference between the 4 groups of myopia Indian subjects in terms of mean retinal thickness with the maximum thinning in Myopia group of S.E  $>-9D$ . There was no significant difference in terms of mean choroidal thickness amongst various myopic groups.

There was a significant difference in mean retinal thickness between males and females, with the values being more in Males. There was no significant difference in the mean choroidal thickness in males and females in the Indian population.

**P-209****Struggle with ocular vascular pathologies in a patient with Factor 5 Leiden mutation**B Taskiran Kandeger.**Objective:** Evaluation of retinal vascular pathologies in a young patient with a factor 5 Leiden mutation.**Methods:** Case report

**Results:** A 42-year-old male patient was admitted with decreased vision in his left eye. Visual acuity was:0.7 (Snellen), anterior segment examination on slit-lamp biomicroscopy was unremarkable, and dilated fundus examination revealed superior retinal vascular occlusion (RVO) in the left eye. Fundus fluorescein angiography revealed superior RVO; ischemia was observed near the superior arcuate. Laser photocoagulation and anti-vascular endothelial growth factor (anti-VEGF) injection therapy were planned, and the patient was consulted to the hematology and cardiology departments for systemic investigation. After the hematology examinations, Factor 5 Leiden mutation was detected. The hematology department started systemic anticoagulant therapy. During the 2-year follow-up, the patient underwent four sessions of laser photocoagulation and 13 intravitreal bevacizumab injections. Then he was presented with sudden vision loss, visual acuity was hand movement, and fundus examination revealed vitreous hemorrhage. His orbital USG revealed vitreous hemorrhage, and his retina was not detached. Anti-VEGF treatment was planned. One month later, vitreous hemorrhage was regressed, and his vision was 0.9 (Snellen). Laser photocoagulation was adopted in all visible areas in the superior quadrant, and the patient was followed up monthly.

**Conclusion:** Factor 5 Leiden mutation should be kept in mind in the etiology of retinal vascular occlusion in young patients, and these patients should be systematically investigated. During follow-up, vitreous hemorrhage may develop due to ocular neovascularization and systemic anticoagulant therapy, worsening the disease.

P-210

## Effect Of Half-Dose Photodynamic Therapy In Chronic Central Serous Chorioretinopathy- Increased Viability And Cost-effectiveness

S Sadanandan<sup>1</sup>, S Bhansali, S Bhansali, S Natha<sup>2</sup>.

<sup>1</sup>ophthalmology, <sup>2</sup>Wrightington Wigan and Leigh Teaching Hospital NHS foundation Trust, Wigan, United Kingdom

**Objective:** To assess the anatomical and functional outcomes of half dose photodynamic therapy(PDT) in patients with chronic central serous chorioretinopathy(CSCR) and to note its financial benefits.

**Methods:** A retrospective analysis of patients who underwent half dose PDT with verteporfin (3mg/m<sup>2</sup>) for chronic CSCR in our eye department at Wrightington, Wigan and Leigh Teaching Hospitals NHS Foundation Trust, UK, from the year 2010 to 2020 was performed. The data was extracted from Medisoft – electronic patient record system.

30 eyes of 29 patients with CSCR persisting over 6 months were included and analysed for changes in visual acuity and central retinal thickness(CRT) at 3, 6, 9 and 12 months post therapy.

**Results:** The mean age of the participants was 58.2 +/-10.5 years. Males constituted 53.3% and females 46.7 % of the study population. The mean baseline best corrected visual acuity (BCVA) in ETDRS letters was 66 ± 10.6. Improvements in BCVA were seen at the 3 month review of 69.4 ± 12.8 ETDRS letters(p=0.0051), and at the 9 month review of 68.8 ± 13.1 letters (p=0.3404). BCVA dropped to 66.3 ± 16 (p=0.3745) at the 12 month review. Pre procedure, the average CRT was 360.3 ± 92.7mm, which reduced to 265.8 ± 85.1mm at 3 months (p <0.001) and 243 ± 106.9um at 12 months (p=0.0027).

80% of the patients achieved anatomical resolution, with 66.67% of the participants achieving it with a single session of PDT. Only 20% of the participants needed further PDT or intravitreal therapy.

**Conclusion:** Half dose PDT is beneficial in achieving anatomical resolution in chronic CSCR. However, anatomical resolution may not correlate well with functional outcome, as in our study, likely due to pre-existing atrophic retinal pigment epithelial changes.

This study also highlights a reduction of treatment burden in 80% of patients by using PDT instead of loading doses of anti-VEGF, thus reducing the frequency of the visits and financial burden to the NHS. Hence, HD- PDT is still the safest and most effective treatment modality available for chronic CSCR.

P-211

**Brolucizumab monotherapy for wet age-related macular degeneration: a systematic review and meta-analysis**X Xin<sup>1</sup>, M Shi<sup>1</sup>, X Leng<sup>1</sup>, X Lu<sup>2</sup>.<sup>1</sup>Chengdu University of Traditional Chinese Medicine, <sup>2</sup>Chengdu University of Traditional Chinese Medicine, Chengdu, People's Republic of China

**Objective:** Brolucizumab is a novel anti-vascular endothelial growth factor (VEGF) agent. This study aimed to evaluate the therapeutic effects of brolucizumab on wet age-related macular degeneration by meta-analysis.

**Methods:** A systematic search was performed in the PubMed, Embase, Google Scholar, Clinical Trails, Web of Science, and the Cochrane Library databases through July 13, 2021. Two reviewers independently screened citations and full-text articles to identify randomized controlled trials (RCTs), extracted data and appraised the risk of bias. All included randomized controlled trials should include central subfield thickness (CSFT) and best-corrected visual acuity (BCVA). The methodological quality of the references was evaluated according to the Cochrane quality assessment. RevMan 5.4 software was used to perform the data analysis.

**Results:** A total of 5 randomized controlled trials, including 1762 eyes, were included, and the results showed that the effect of brolucizumab on CSFT was significantly different from that of traditional anti-VEGF drugs (Mean difference [MD] = -26.26, 95% Confidence interval [CI] [-39.17~-13.34], P=0.001, I<sup>2</sup>=0%), also the CSFT at 8 weeks (MD = -18.78, 95% CI [-31.66~-5.89], P=0.004, I<sup>2</sup>=0%) and 56 weeks (MD=-24.57, 95% CI [-39.45~-9.70], P=0.001, I<sup>2</sup>=0%) after the application of Brolucizumab 6mg was statistically significant. However, short-term (4 weeks) treatment of Brolucizumab 3mg (MD = -6.95, 95% CI [-23.97~10.07], P=0.42, I<sup>2</sup>=0%) and 6mg (MD=-13.44, 95% CI [-29.80~-2.92], P =0.11, I<sup>2</sup>=0%) showed no statistical significance. The effect of brolucizumab on BCVA was not significantly different from that of traditional anti-VEGF drugs (MD=-0.50, 95% CI [-1.83~-0.84], P=0.47, I<sup>2</sup>=0%).

**Conclusion:** Current evidence suggests that brolucizumab has a definite therapeutic effect on wAMD. Compared with traditional anti-VEGF drugs, Brolucizumab improved CSFT more significantly, and long-term use of Brolucizumab may be better than short-term treatment, but there was no significant difference in BCVA improvement. Therefore, brolucizumab had a more significant effect on the regression of macular edema. Due to the small number of literature included in this study, the safety analysis and the optimal period and dose of Brolucizumab were still incomplete, so more randomized controlled trials were expected to confirm the safety and clinical application of Brolucizumab.

P-212

### Phenotype Variation of an RDS/Peripherin Mutation in Seven Family Members

A Elhusseiny, A Sharabura<sup>1</sup>, J Dehnel<sup>1</sup>, M Williams<sup>2</sup>, R Sanders<sup>1</sup>, S Uwaydat<sup>1</sup>.

<sup>1</sup>Ophthalmology, <sup>2</sup>University of Arkansas for Medical Sciences, Little Rock, United States

**Objective:** The PRPH2 (RDS/Peripherin, OMIM:179605) gene product is an integral transmembrane glycoprotein that forms and stabilizes photoreceptor disks in rods and cones. Mutations in the PRPH2 gene are largely autosomal dominant and can cause a broad spectrum of hereditary retinal dystrophies including retinitis pigmentosa, various forms of pattern dystrophies, and cone-rod dystrophy.

We herein present this series of 7 family members with the c.828+3A>T PRPH2 mutation to understand the natural history and the intrafamilial phenotypic variation across seven individuals in the same family.

**Methods:** We performed a retrospective chart review of 7 patients from the same family with the c.828+3A>T PRPH2 mutation characterizing the natural history and intrafamilial phenotypic variation.

Data collected included age at the time of presentation, gender, best-corrected visual acuity (BCVA) at the initial visit and last follow-up, slit-lamp findings, fundus examination findings, electrophysiological, and genetic testing results. BCVA was recorded using standard Snellen visual acuity charts. We worked with genetics counselors and an ocular geneticist to determine the presence of a PRPH2 mutation.

**Results:** The current study included seven patients with a mean age of  $62.8 \pm 11$  years (median: 58 years, range: 49-79 years) at the time of presentation to our clinic. Four patients (57.1%) were females. Of seven patients, three were lost to follow-up and one patient subsequently passed away. The remaining three patients (patients #1, #3, and #7) were followed up for 9, 6, and 5 years, respectively. Initial BCVA ranged from 20/25 (57%) to hand motion. At the final follow-up visit, BCVA deteriorated in patients #1 and #7, however, it was stable in patient #3. Patients were referred to our clinic with a variety of diagnoses including retinal dystrophy (2 patients), rod-cone dystrophy (1 patient), macular degeneration (3 patients), and rod dysfunction (1 patient). Five patients completed genetic testing. The index patient (patient #1) and her mother (patient #6) developed choroidal neovascular membranes (CNVMs).

**Conclusion:** : In the current case series, We described the various phenotypes associated with PRPH2 mutation in related individuals of the same family. We tracked the changes in visual acuity and phenotype in three related patients over a period of 5 to 9 years.



P-213

**A Rare Anomalous Macular Arterial Blood Supply in a Patient with CSR : Case Report**C Munasinghe, P Sriharanadan .

**Objective:** Congenital anomalous retinal arterial blood supply is a rare phenomenon of minute clinical significance. Though It is reported to cause vascular occlusions and leaking macro aneurysms with aberrant retinal arteries, an associated central serous chorioretinopathy(CSR) is not documented in literature.

**Methods:** Ocular imaging was done to confirm the diagnosis and to document the findings.

**Results:** A 44 years old male presented to us with left eye blurred vision for 1 month. His corrected vision was 6/6 Plano right and 6/6 +0.50 sphere left. Left eye fundus had a CSR at macula involving the fovea. The macular supply by an anomalous retinal artery stemming from inferotemporal arcade in its third division was incidentally noted which also crossed the horizontal raphe rendering this the cardinal vessel supplying the central macular inner retina. Rest of the retina was normal with a healthy nerve fiber layer arrangement. There was no optic pit. The other eye was normal. A well demarcated neurosensory detachment involving the fovea was noted in red free images with a characteristic mottled Retinal Pigment Epithelial(RPE) changes on fundal auto fluorescence. OCT macula detected subneurosensory clear fluid with a small RPE disruption, characteristic string of pearl appearance and a pachychoroid of 471mm. Ink blot pattern leakage was noted in fundal fluorescence angiogram. The fovea avascular zone was normal.

**Conclusion:** The outer and the inner retina is supplied mainly by the choriocapillaris and branches of the central retinal artery respectively. Furthermore, the macula is supplied by the temporal retinal arterial arcades and its ramifications which is not the case always as in 15%-20% of cases cilioretinal artery exists. The concept of watershed areas is important in pathological point of view in cases where the ischemia induced cessation of retinal function ensues. The embryological development of this two major sources of blood supply of the retina seems to be independent and the same is true for the neuronal components which might explain why most individuals with congenital anomalous retinal arterial blood supply have normal retinal function. The proposed mechanism of CSR lies there in the dysfunctional retinal pigment epithelium and choroid, being an entity of pachychoroid spectrum of diseases. The relationship between the Anomalous retinal artery of the index case and CSR may be causal or incidental which is yet to be determined.

P-214

**Auto-segmentation of Choroid Layer on Spectral Domain Optical Coherence Tomography with Deep Learning**W Hsia.

**Objective:** Changes in choroidal thickness are noted in chorioretinal diseases. This study attempts to develop an automatic method for measuring choroidal thickness on OCT with greater convenience and accessibility.

**Methods:** The OCT image database used in this study is composed of data from 30 healthy subjects. History of ocular diseases or intraocular intervention were excluded. SD-OCT scan (Heidelberg) with EDI methods rather than conventional SD-OCT were used for all 30 subjects. Every OCT image composed a  $6 \times 6$  mm area and 25 scans, separated by 24  $\mu$ m between each scan. One pixel equals to 4  $\mu$ m in this study. Initial image processing includes cropping images and manual labeling of the inner border of choroid (CiB) and the choroid-scleral interface (CSI) was performed by two ophthalmologists. The Mask R-CNN model using the ResNet combined with the FPN backbone with standard convolution and fully connected heads for mask and box prediction were used in this study. Two different numbers of ResNet layers were proposed. The ResNet 101 layers (R101) have deeper features that could provide better representation of boundary information, and the ResNet 50 layers (R50) with shallow features could provide a pixel relationship. We also provides an intersection version (AND model) and a union version (OR model) of the sketching results from the R50 and R101 layers. The choroidal thickness was defined as thicknesses between the CiB and the CoB by using the Euclidean distance.

**Results:** The average error were 4.86 pixels and 5.04 pixels for the OR model and the AND model respectively. The average execution time were 5.3 seconds and 4.6 seconds for the OR model and the AND model respectively. These results showed good accuracy of choroidal thickness measurement, which was an average accuracy rate of 87.5%. Three cases with relative lower accuracy rate (70.3%, 66.6% and 54.2%, respectively) were noted and possibly because of the interference of the large vessels passing through the choroid-scleral interface in these cases on identifying the inferior border of choroid layer. The average accuracy rate of choroidal thickness measurement improved to 90.2% after excluding these three extreme values.

**Conclusion:** This study provides an alternative choroid segmentation method which ameliorates the disadvantages of previous models and provides faster and more precise outcomes. It has the ability to be used as an alternative automatic sketching scheme to measure the choroidal thickness on OCT with better efficacy.

P-215

**A Case of Occult Macular Dystrophy with Detected *RP1L1* Variant**D Zhang<sup>1</sup>, X Chen<sup>1</sup>, L Suo<sup>1</sup>, C Zhang<sup>1</sup>.<sup>1</sup>Ophthalmology, Peking University Third Hospital, Beijing, People's Republic of China

**Objective:** Occult macular dystrophy (OMD) is an inherited macular dystrophy characterized by progressive bilateral decrease in the visual acuity associated with normal fundus and normal fluorescence angiograms. Besides, the full-field electroretinogram (ERG) shows normal results. However, the focal ERGs are abnormal. Characteristic microstructural changes of photoreceptor cells can be observed in spectral-domain optical coherence tomography (SD-OCT). Since causative mutations in the retinitis pigmentosa 1-like 1 (*RP1L1*) gene have been reported in patients with OMD, the exome sequencing has helped the diagnosis of OMD. Here, we reported a typical OMD case with detected *RP1L1* variant p.G1200V.

**Methods:** A 24-year-old man came to our clinic, complaining of decreased visual acuity (VA) in both eyes. Detailed medical history and family history were obtained, including onset and duration of disease. Comprehensive ophthalmologic examinations were performed, including measurements of the best-corrected decimal visual acuity (BCVA), ophthalmoscopy, fundus autofluorescence (AF) imaging, fundus fluorescence angiogram (FFA), SD-OCT, visual field testing and electrophysiologic assessments. To clarify the cause of disease, exome sequencing was also performed.

**Results:** This patient had a progressive decrease of VA in both eyes from 19 years old, but no similar symptoms had happened to his parents and sister. The BCVA was 0.25 in both eyes. The anterior and posterior segments showed normal appearance. No abnormality had been found in AF imaging and FFA. Both eyes had central scotoma in visual field testing. In SD-OCT, the blurring of ellipsoid zone and absence of the interdigitation zone of the photoreceptors were found. Multifocal ERG recordings showed localized macular dysfunction in both eyes, while the recordings of visual evoked potentials and flashed ERG had no significant abnormality. Notably, exome sequencing and targeted analysis for retinal disease-causing genes reported *RP1L1* variant p.G1200A, which was a pathogenic missense variant reported in patients with OMD in previous studies. The genotype was consistent with the photoreceptor microstructural phenotype. Thus, this patient was diagnosed with hereditary OMD.

**Conclusion:** Our results demonstrated that the association between the genotype and the phenotype in the case of OMD. Besides, exome sequencing and targeted analysis may assist the diagnosis of unexplained decreased VA, especially retinal diseases that are difficult to diagnose clinically.

P-216

**Idiopathic Choroidal Neovascularization in a Pediatric Patient. Case Report**

E Muñoz Anaya<sup>1</sup>, G Aguilar Montes<sup>2</sup>.

<sup>1</sup>*Ophthalmology, Private Clinic, Jalisco,* <sup>2</sup>*Ophthalmology, Hospital General Dr. Manuel Gea González , Mexico City, Mexico*

**Objective:** To report the case of a children with idiopathic choroidal neovascularization.

**Methods:** Case report of a 14 years old girl, who presented with visual impairment in the left eye. The fundoscopic examination showed macular elevation in a bulls eye configuration and subretinal hemorrhage.

**Results:** Fundus fluorescein angiography of the left eye showed a net of increasing hyperfluorescence at the macula, consistent with a choroidal neovascularization, optical coherence tomography showing subfoveal choroidal neovascularization and surrounding subretinal fluid, Electrophysiological tests, electrooculogram with normal Arden index, electroretinogram with decrease in the amplitude of waves a – b.

**Conclusion:** It is a rare eye disease causing severe impairment of the central vision if of lesions located subfoveal. There are 5 categories of CNV: inflammatory, infectious, degenerative, traumatic, neoplastic and idiopathic. In children, hereditary retinal dystrophies must also be taken into account, idiopathic are more frequently unilateral, and diagnosis is made by ruling out the etiologies mentioned. CNV in children and adolescents are known to be type 2 membrane, having features of “classic” CNV on FFA, CNV in children is more likely to have a solitary in-growth site.

P-217

**Structural and Functional correlation of the natural course of Berlin's edema.**I Sharma<sup>1</sup>, G Das<sup>1</sup>.<sup>1</sup>*Ophthalmology, University College of Medical Sciences & GTB Hospital, Delhi, India*

**Objective:** This poster highlights the role of the fundus examination and imaging along with posterior segment OCT in diagnosis and follow up of a patient with Berlin's edema. It also demonstrates the use of OCT to assess the natural course of resolution of Berlin's edema over time and correlate the structural and functional outcomes.

**Methods:** A 21-year-old male presented to the emergency with diminution of vision in the left eye following blunt trauma. He was subjected to detailed ophthalmological examination and was diagnosed with Berlin's edema based on the fundus examination and OCT features. The fundus examination revealed a pseudo-cherry red spot appearance of the fundus suggestive of retinal edema and the OCT was suggestive of a sub-foveal neurosensory detachment with surrounding intra-retinal edema along with distortion of the ellipsoid and myoid zone. The patient was advised to be under close follow up in the outpatient department weekly until 1 month to document the course of the pathology to assess the progression or regression of the disease. Photographic documentation of the fundus and the OCT features of each weekly visit will be provided in the E-Poster.

**Results:** At presentation, the patient had a visual acuity of 6/6 OD and 2/60 OS.

On the first follow up visit (1<sup>st</sup> week), the patient had a vision of 3/60 OS and fundus examination revealed a hypopigmented linear lesion along with resolution of the retinal edema. The OCT Macula after the first week revealed resolution of the neurosensory detachment and appearance of a hyper-reflective linear lesion crossing the inner and outer retinal layers along with a focal area of distortion of the outer retinal layers at the outer end of the lesion.

Eventually, at the subsequent weekly follow up visits, the patient's best corrected visual acuity improved from 2/60 to 6/60 to 6/18 and 6/9 respectively. The OCT Macula showed progressive decrease in the size of the edema and organisation and contraction of the linear hyperreflective lesion and near resolution of the pathology.

**Conclusion:** Berlin's edema also known as commotio retinae is a known complication following blunt trauma. Sometimes, in certain cases with post-traumatic diminution of vision, the edema may not be clinically appreciable. In such cases, posterior segment OCT can aid in the diagnosis. Posterior segment fundus imaging and OCT can also be used to assess the course of the disease during the follow up visits to correlate the structural and functional course of the pathology.

P-219

### The influence of intravitreal anti-VEGF afibercept injections on retinal vein diameters in branch retinal vein occlusion BRVO

H Arzoalxhiu.

**Objective:** To assess changes in affected trunk vein diameter and macular thickness after intravitreal afibercept injection in eyes with branch retinal vein occlusion (BRVO).

**Methods:** We examined 18 eyes of 18 patients who have been treated with intravitreal afibercept injection more than once because of recurrent macular edema secondary to BRVO. Best corrected visual acuity (BCVA), foveal thickness measured by optical coherence tomography, and trunk vein diameter were evaluated 1 week after the first and second intravitreal afibercept injections. BCVA was converted to the logarithm of the minimum angle of resolution and averaged. The mean diameter of three segments of the affected trunk vein located in an area of 1-3 disc diameters from optic disc border was calculated using digital fundus photography and computer software. We calculated the ratio of trunk vein diameter after the first injection, before and after the second injection. The mean interval between the first and second afibercept injection was 74 days.

**Results:** The mean BCVA before and after 1 week after the first injection, and 1 week before and after second injection were 0.63, 0.30, 0.26 and 0.16 respectively. Mean foveal thickness before and 1 week after the first injection, and before and 1 week after second injection were 613 nm, 240 nm, and 467 nm, 202 nm respectively. The ratios of the mean trunk vein diameters before and 1 week after the first injection, and before and 1 week after the second injection were 1; 09,0;78, 0;95, 0;76, respectively.

**Conclusion:** Affected trunk vein diameter decreased after the first afibercept injection. Increased again before the second injection, and then decreased after the second injection. These results demonstrate that intravitreal afibercept injections reduce not only macular thickness but also the diameter of the affected retinal vein in eyes with BRVO.

P-220

**Pachychoroid neovascularopathy in a young female: A case report**Y Yao<sup>1</sup>.<sup>1</sup>*Ophthalmology, Show-Chwan Memorial Hospital, Changhua, Taiwan, China*

**Objective:** To report a young female of pachychoroid neovascularopathy, a form of Type 1 (sub-retinal pigment epithelium) neovascularization, occurring over areas of increased choroidal thickness and dilated choroidal vessels.

**Methods:** Case report and literature review

**Results:** A 26-year-old healthy female with visual loss came to our clinic for help. There was Type 1 neovascularization overlying a localized area of choroidal thickening and dilated choroidal vessels seen with optical coherence tomography. With Fluorescein angiography, there were large choroidal veins and choroidal hyperpermeability seen beneath the area of the neovascular tissue in the right eye. There was no submacular exudative detachment or autofluorescence changes to suggest antecedent acute or chronic central serous chorioretinopathy. The right eye had no drusen or degenerative changes to suggest age-related macular degeneration or other degenerative diseases. The patient's visual acuity improved from 0.2 to 0.5 after an intravitreal injection with aflibercept.

**Conclusion:** Pachychoroid neovascularopathy may occur as a focal abnormality within the macula, even in a young female without any medical history. Aflibercept may be helpful in pachychoroid neovascularopathy.

P-221

### Management of Diabetic Macular Edema using Intravitreal Bevacizumab versus Intravitreal Triamcinolone

M Almuafa<sup>1</sup>, E Aljarabah<sup>2</sup>.

<sup>1</sup>ophthalmology, King Fahad Hospital, Albaha, Saudi Arabia, Albaha, <sup>2</sup>ophthalmology, Security forces hospital, Dammam, Saudi Arabia

**Objective:** determine the efficacy and safety of Intravitreal Bevacizumab (IVB), versus Intravitreal Triamcinolone (IVT) in Diabetic Macular Edema (DME) patients.

**Methods:** A systematic search was performed over different medical databases to identify ophthalmology studies, which studied the outcome of the IVB group versus the IVT group of DME patients. We conducted a meta-analysis process on Best-Corrected Visual Acuity (BCVA) and Central Macular Thickness (CMT), as primary outcomes, and on Intraocular Pressure (IOP) as a secondary outcome. Eight studies were identified involving 564 eyes, 285 in the IVB group, and 279 in the IVT group.

**Results:** Our meta-analysis process showed a highly significant decrease in mean CMT in the IVB group compared to the IVT group ( $p=0.043$ ). But, there was a non-significant difference in mean BCVA and IOP between groups ( $p>0.05$ ) respectively.

**Conclusion:** This study compares the efficacy and safety of Intravitreal Bevacizumab (IVB), versus Intravitreal Triamcinolone (IVT) in Diabetic Macular Edema, according to our results IVB was more effective than IVT in CRT reduction but no difference between both in best-corrected visual acuity and on Intraocular Pressure (IOP) parameters.



P-222

**Treatment of primary vasoproliferative tumor of retina using laser photocoagulation and intravitreal injection of Ranibizumab.**

M Ahmad Musthafa<sup>1</sup>, W Wan Muda<sup>2</sup>, N Ramli<sup>3</sup>.

<sup>1</sup>Department of Ophthalmology, Hospital Sultanah Nur Zahirah, Kuala Terengganu, <sup>2</sup>Department of Ophthalmology, Hospital Tengku Ampuan Afzan, Kuantan, <sup>3</sup>Department of Ophthalmology, University Malaya Medical Centre, Kuala Lumpur, Malaysia

**Objective:** We present a case of vasoproliferative tumour of the retina that successfully responded to laser photocoagulation and intravitreal injection of ranibizumab.

**Methods:** Case report

**Results:** A 40-year-old female presented with a painless blurring of vision in her right eye. The right eye's visual acuity was 6/30 and the left eye was 6/6. Right fundus examination revealed epiretinal membrane at the macula and subretinal exudation at the temporal arcade, as well as a yellowish-red tumour at the temporal peripheral retina suggestive of VPT. The patient received combination of selective laser photocoagulation of the tumour and serial intravitreal injections of ranibizumab. The vasoproliferative tumour regressed after 6 months. At a one-year follow-up, her right eye's visual acuity was 6/6 with a dry macula.

**Conclusion:** Laser photocoagulation treatment should be considered for treating primary vasoproliferative retinal tumours as it is the most available treatment modality. Combination therapy laser photocoagulation treatment with anti-VEGF provides long-term tumour regression, which is effective for the macula oedema associated with this condition.

P-223

### The first Chinese case of CDH3-related Congenital Hypotrichosis with Juvenile Macular Dystrophy caused by Disrupted mRNA splicing

Y Lin<sup>1</sup>, P Yu<sup>2</sup>, K Yao<sup>1</sup>, J Lin<sup>1</sup>.

<sup>1</sup>Eye Center, Second Affiliated Hospital, School of Medicine, Zhejiang University, <sup>2</sup>Department of Cell Biology and Medical Genetics, School of Medicine, Zhejiang University, Hangzhou, People's Republic of China

**Objective:** *CDH3*-related hypotrichosis with juvenile macular dystrophy (HJMD) is a rare autosomal-recessive disease characterized by early-onset macular degeneration and sparse scalp hair. Only less than 40 HJMD patients with molecular confirmation have been reported in the literature. Here, we report the first Chinese patient with HJMD, and predict the function of a novel intron mutation of *CDH3*.

**Methods:** A 16-year-old male patient with poor visual acuity since childhood underwent comprehensive ophthalmic examinations, including visual acuity, fundus imaging, spectral-domain optical coherence tomography (SD-OCT), optical coherence tomography angiography (OCT-A), short-wavelength fundus autofluorescence (SW-AF). Whole exome sequencing (WES) and Sanger sequencing were used to detect and verify mutations. Human Splicing Finder and Berkeley Drosophila Genome Project Software were used to predict the function of mRNA splicing mutation.

**Results:** The WES analysis and Sanger sequencing revealed novel compound heterozygous *CDH3* variants, c.1625A>G and c.391-3C>G. The c.391-3C>G mutation may destroy the original mRNA splicing receptor and form a new splicing receptor, thus affecting the splicing of *CDH3* exons. Ophthalmologically, the patient exhibited loss of visual acuity with BCVA of 0.8 (OD) and 0.2 (OS). Fundus examination revealed chorioretinal atrophy in the posterior pole. SD-OCT imaging showed disappeared ellipsoid zone in the central area, and outer retinal atrophy with outer retinal tubulations. Choriocapillaris defects were exhibited on OCT-A, and SW-AF showed hypoautofluorescent area in the macula; Dermatological examination revealed thinning of the scalp hair.

**Conclusion:** This is the first description of a Chinese case with HJMD associated with *CDH3* mutations, and its particular genetic alteration. Substitution of c.391-3C>G in *CDH3* likely disrupts the original splicing receptor and form a new splicing receptor. Whether c.391-3C>G mutation affects *CDH3* gene exon splicing remains to be further studied. Our findings can expand the knowledge and understanding of *CDH3*-related HJMD, which could be helpful to ophthalmologists.

P-224

**Special coats-like retinopathy with semi-facial atrophy: three case report**J Duan, M zhang.

**Objective:** Parry-Romberg syndrome (PRS) is a rare pathogenesis unknown hemi-facial atrophy disorder. It involved multi-system changes and 10-35% patients presented ophthalmologic disease. In this article, we described three case with PRS. They all came to our clinic with same ophthalmologic chief complain of VA decrease in one eye, and we underwent ophthalmic examination, fundus photographs, optical coherence tomography and fluorescein fundus angiography in three patients. They all presented with coats-like fundus, exudative retinal detachment and semi-facial atrophy without involving other systems. The facial hemi-atrophy and ocular disorder occurred at the same time. The contralateral eye was all healthy in three patients. With symptomatic treatments including laser treatment, injection of anti-VEGF and surgery of vitrectomy or scleral cryotherapy, the fundus lesions in three patients tend to be stable.

**Methods:** case report.

**Results:** Clinical features, fundus photographs, optical coherence tomography and fluorescein fundus angiography are reported.

**Conclusion:** Ocular changes in PRS patient were rare with a great variety of different manifestations including coats-like fundus. When progressive atrophy of unilateral face was found and disease started in childhood or young adult, especially in female, doctors should consider the diagnose of PRS with exclusion of other causes, then treat in the basis of the symptom to halt the disease progressing.

P-225

**A case of peripheral retinal myelinated nerve fibers with decreased retinal vascular density**L Wei, W shuai<sup>1</sup>.<sup>1</sup>*The First Affiliated Hospital of Zhengzhou University, zhengzhou, zhengzhou, People's Republic of China*

**Objective:** A 50-year-old man presented for a routine eye checkup. His best-corrected visual acuity was 20/20 OU. A Widefield pseudocolor image revealed central serous chorioretinopathy in the right eye and the left eye showed myelinated nerve fibers in the temporal raphe. The Swept source optical coherence tomography angiography (SS-OCT) angio scan images showed that the density of retinal vascular in this area was lower than the fellow eye.

**Methods:** SPSS 19.0 software was used for statistical processing. In the thickest area of MRNF, independent samples T test was performed on the nerve fiber layer thickness and retinal blood vessel density in both eyes.  $P < 0.05$  means the difference is statistically significant.

**Results:** The analysis results showed that the analyzed area: the nerve fiber layer thickness and retinal blood vessel density in both eyes were significantly different, with statistical significance ( $P = 0.000$ ,  $P = 0.042$ ), but there was no significant correlation between the two data differences ( $P = 0.605$ ).

**Conclusion:** Retinal blood vessel density is reduced at retinal myelinated nerve fibers

P-227

**Progressive Mitochondrial Retinal Dystrophy: A Case Report**

V Miranda<sup>1</sup>, M Matias<sup>1</sup>, C Aguiar<sup>1</sup>, J Ambrósio<sup>1</sup>, J Chibante<sup>1</sup>, M Ruão<sup>1</sup>.

<sup>1</sup>Ophthalmology Department, Centro Hospitalar de Entre o Douro e Vouga, Santa Maria da Feira, Portugal

**Objective:** To report on the retinal phenotype and associated systemic findings in a patient with the m.3243A>G mutation in the MTTL1 gene.

**Methods:** Case report analysis.

**Results:** A 39-years-old Caucasian women was referred to our department due to bilateral vision loss. She had a history of dyslipidaemia, arterial hypertension, fatigue and sensorineural hearing loss (SNHL) diagnosed 3 years prior and wore hearing prosthetics. Her best corrected visual acuity (BCVA) was 20/30 and 20/25 Snellen in the right eye (RE) and left eye (LE) respectively. Anterior segment exam was unremarkable. Fundus exam showed macular and peripapillary areas of chorioretinal atrophy which corresponded to areas of sharply demarcated outer retina atrophy and outer retina tubulations in optical coherence tomography. Fundus autofluorescence showed the same well demarcated areas with virtually absent autofluorescence and with hyperautofluorescent speckled margins. Genetic study detected the mitochondrial DNA m. 3243A>G heteroplasmic variant in the MTTL1 gene. There are no known ophthalmologic manifestations in the patient's maternal ancestry or in the patient's offspring (a 13-years-old boy) and it is still unknown at this stage if they are carriers of the mutation or if it is a *de novo* mutation. The patient, now 42-years-old, maintains regular follow-up in our department and throughout this period we observed sustained centripetal progression of the areas of chorioretinal atrophy, with almost half a disc-diameter of progression in some directions. Her BCVA has deteriorated to 20/50 in her RE due to partial foveal involvement and is preserved in her LE so far.

**Conclusion:** The m.3243A>G variant is one of the most common mitochondrial DNA point mutations and has been shown to cause a variety of mitochondrial diseases, including retinal abnormalities and other systemic manifestations. This retinal dystrophy typically affects the macula and the area surrounding the optic disc. Retinal and systemic phenotype can be variable according to the heteroplasmy levels. We hereby present a new case of mitochondrial retinal dystrophy associated with the m.3243A>G mutation with progressive chorioretinal atrophy and SNHL.

P-229

**Central retinal artery occlusion after vaccination with inactivated SARS-CoV-2 vaccine**S Bhattacharya<sup>1</sup>, M Thakar<sup>1</sup>.<sup>1</sup>*Guru Nanak Eye Centre, New Delhi, India*

**Objective:** To date, however, there have been no reports of central retinal artery occlusion (CRAO) after the indigenously developed Covaxin, and worldwide, only one case report of CRAO post vaccination with AstraZeneca. We report a case of a patient who developed an isolated CRAO 10 days following the administration of the Covaxin COVID-19 vaccine.

**Methods:** A 44 year old man presented to a tertiary care hospital in India complaining of sudden onset painless vision loss in his left eye 10 days after receiving the second dose of Covaxin COVID-19 vaccine. His best-corrected visual acuity in the left eye was only minimal perception of light without projection. Left eye ophthalmologic examination showed a relative afferent pupillary defect, along with arterial attenuation and a cherry red spot at the macula on dilated fundus examination, suggesting a central retinal artery occlusion.

**Results:** Optical coherence tomography of the same eye showed macular swelling and disorganisation of the inner retinal layers, likely ischemic sequelae. Blood work was within normal limits, apart from a mildly raised ESR. The cardiovascular examination was unremarkable, and the patient was kept on follow up.

**Conclusion:** To our knowledge, this is the first case of an isolated CRAO following the administration of the Covaxin COVID-19 vaccine, and the second case with COVID-19 vaccines overall. Further studies are needed to evaluate this potential association between COVID-19 vaccinations and CRAO.

P-230

**Case report: Rapid regression of optic disc neovascularization in Behcet's uveoretinitis after aflibercept therapy**Y Xiao, Q Wang<sup>1</sup>.<sup>1</sup>*Department of Ophthalmology, Shandong Provincial Hospital Affiliated to Shandong First Medical University, Jinan, Shandong, People's Republic of China*

**Objective:** Optic disc neovascularization is an uncommon but serious complication of Behcet's disease. Effectiveness of intensive anti-inflammatory and conventional immunosuppressive treatments in the early stage of optic disc neovascularization are not satisfactory. Here we present the first reported case of rapid regression of optic disc neo-vessels after aflibercept injection in BD, which was well controlled after concurrent administration of other treatments.

**Methods:** A 36-year-old woman, diagnosed with Behcet's disease 5 months ago, was referred for further evaluation of blurred vision in both eyes. Oral prednisolone had already been administered before referral. Optic disc neovascularization and uveitis associated cystoid macular edema were demonstrated by fluorescein angiography and OCT. Intravitreal injection of Aflibercept was performed followed by conventional combination of corticosteroids, immunomodulatory and biologic agents.

**Results:** Both optic disc neovascularization and macular edema were rapidly regressed within a few days after aflibercept injection. To reduce the risk of recurrent uveitis attack in this patient, she was at a tapering dose of oral prednisone combined with adalimumab and cyclosporine A. Optic disc neovascularization resolved almost completely. There were no signs of neo-vessels recurrence during 2 years of follow-up.

**Conclusion:** Optic disc neovascularization is rare but sight-threatening in Behcet's patients. There are still certain thorny issues during treatment. This is the first study reporting fast regression of optic disc neovascularization in response to aflibercept in a young Behcet's patient. Combination of corticosteroids, immunomodulatory and biologic agents would eventually prevent the recurrence of uveitis attacks and disc neovascularization. Anti-VEGF therapy is considered as an attractive modality in conjunction with other therapies to achieve fast acting and long-lasting control of refractory uveitic optic disc neovascularization.

P-231

**Photopic Retinopathy Secondary to Smartphone Flash Exposure: A Case Report**

A Parra-Morales, B *Framiñán Aparicio*, R *Pineda Oliveros*, I *Gómez Ledesma*.

**Objective:**

The appearance of photic retinopathy has been associated with direct exposure to sun gaze in the literature. However, there are emerging reports suggesting that not only sun rays can contribute to retinal damage, but also other sources of bright light such as camera flashes, ophthalmic instruments and lasers. We report a case of photic retinopathy in association with smartphone flash light exposure.

**Methods:** Case report.

**Results:** A 20-year-old male presented to the ophthalmology unit with left eye central scotoma after being exposed to the flash light of a smartphone camera for a few minutes at a short distance. Corrected visual acuity was of 20/20 in the right eye and 20/80 in the left eye. Examination with slit-lamp did not give away any abnormalities, but, funduscopy of the left eye revealed an abnormal yellowish swelling of the fovea. Optical coherence tomography (OCT) revealed a hyperreflective lesion above the foveal retinal pigment epithelium (RPE). Photopic retinopathy was diagnosed and a daily dose of 0.3% nepafenac was prescribed. At the fourth month follow-up the patient showed a complete remission of the affection.

**Conclusion:** To our knowledge, this is the first case of photic maculopathy in association with smartphone flash light exposure. Since these devices are widely used, even at very premature ages, our findings justify an increasing concern about their safety and the need for further studies that could reveal the potential damage that camera flashes might induce in retinal cells.



**P-233****Unilateral acute posterior multifocal placoid pigment epitheliopathy after COVID-19 vaccination**Q Mi.

**Objective:** To report a case of unilateral acute posterior multifocal placoid pigment epitheliopathy after COVID-19 vaccination in a Chinese young male patient.

**Methods:** A 26-year-old Chinese male patient completed with two dose of COVID-19 vaccine was evaluated due to unilateral visual loss. A complete ophthalmological exam was performed. Best-corrected visual acuity (BCVA) was 20/400 in the right eye and 20/50 in the left eye which has been diagnosed with choroiditis four years ago. At fundus examination, multiple yellow-white placoid lesions were evident at the posterior pole in the right eye.

**Results:** Complete blood test to identify infectious disease, such as tuberculosis, syphilis and toxoplasmosis, the results obtained were negative. According to the ophthalmic examination including FFA, the definite diagnosis is APMPE.

**Conclusion:** APMPE has been reported as an inflammatory disease which may related to a viral prodromic period. We should pay attention to the patient presenting low vision after COVID-19 vaccination.

P-235

**Acquired Nystagmus – Clue to The Neuro-Ophthalmologist**U Syabaniyah, S Jinat<sup>1</sup>, M Sibgatullah<sup>1</sup>, N Nahar<sup>1</sup>.<sup>1</sup>*Neuro-Ophthalmology, Ispahani Islamia Eye Institute and Hospital, Dhaka, Bangladesh***Objective:** To report four cases of acquired nystagmus.**Methods:** Descriptive case series.**Results:** Four types of acquired nystagmus were illustrated in this series. Case number one was a 45 years male presented with downbeat nystagmus. MRI of brain suggestive of infarction in medulla oblongata. Case number two was a 21 years female presented with upbeat nystagmus and MRI of brain suggestive of tumour in posterior fossa. Case number three was a 30 years male with Bruns' nystagmus and MRI of brain suggestive of tumour in left cerebellopontine angle. Case number four was a 42 years male with seven-and-a-half syndrome and MRI of brain suggestive of acute infarction in left pontine area.**Conclusion:** Nystagmus is a clinical sign, not a disease entity. Neuroimaging is necessary in every patients presenting with acquired nystagmus along with systemic manifestations. By understanding nystagmus, we can localize the lesion and take appropriate measurement.

P-237

**Bilateral Optic Disc Edema in Syphilis: A Case Report**F Almeda.

**Objective:** Ocular syphilis can present in many ways involving any portion of the eye. Manifestations include conjunctivitis, chorioretinitis, vasculitis, and optic; however, optic nerve involvement is considered to be a rare manifestation of ocular syphilis. Noticeably, with the increase in syphilis cases reported in various countries, there has also been an increase in the number of patients manifesting with ocular syphilis. The primary objective is to present a case of ocular syphilis manifesting with optic disc edema.

**Methods:** This is a case report focusing on a young, immunocompetent Filipino male presenting with 5 day history of blurring of vision and eye pain of both eyes, initially starting with the left eye. A complete Neuro-ophthalmologic examination. Ophthalmologic diagnostics such as visual field perimetry, optical coherence tomography were done, along with magnetic resonance imaging of the brain and orbits. Other diagnostics to work-up for various infectious and auto-immune diseases were also included.

**Results:** The patient presented with sudden visual acuity of both eyes, initially on the left and an RAPD on the left. On fundoscopy, using the modified Frisen scale, he had grade 5 and grade 4 disc edema on the right and left eye, respectively. Visual field testing revealed generalized depressions of both eyes. Magnetic resonance imaging of the optic nerves revealed hyperintensity and enhancement of the left optic nerve. He tested positive for both RPR and FTA-ABS and was diagnosed to have syphilitic optic neuritis. He underwent desensitization to penicillin and completed 10 days of penicillin treatment with noted improvement in visual acuity and optic disc edema.

**Conclusion:** Timely treatment of syphilis normally has a good prognosis, though delayed diagnosis and administration of antibiotics may have permanent visual consequences for patients. This case emphasizes the importance of having a high index of suspicion of possible syphilis infection for inflammatory eye conditions to ensure early diagnosis and initiation of antibiotics.

P-238

### Serum Vitamin D Levels in Thai Optic Neuritis Patients

B Puangsricharoen<sup>1</sup>, T Padungkiatsagul<sup>1</sup>, K Vanikieti<sup>1</sup>, P Jindahra<sup>2</sup>.

<sup>1</sup>Ophthalmology, <sup>2</sup>Medicine, Faculty of Medicine Ramathibodi Hospital, Mahidol University, Bangkok, Thailand

**Objective:** To elucidate serum total vitamin D or 25-hydroxyvitamin D [25(OH)D] levels in immune-based optic neuritis (ON) including neuromyelitis optica spectrum disorder (NMOSD)-ON, myelin oligodendrocyte glycoprotein antibody-associated disease (MOGAD)-ON, autoimmune-ON, idiopathic-ON and then compared to age-, and sex-matched healthy controls as the primary objective. The secondary objective was to study the correlation between attack severity (best-corrected visual acuity) and serum 25(OH)D levels.

**Methods:** This was a single-center, retrospective study conducted in Ramathibodi Hospital, Bangkok, Thailand. We enrolled 59 subjects (19 NMOSD-ON, 6 MOGAD-ON, 11 autoimmune-ON, 23 idiopathic-ON) who were diagnosed with acute ON (any ON attacks) over a 11-year period. Electronic medical records were reviewed and demographic data, attack severity (best-corrected visual acuity), serum 25(OH)D levels in acute phase of ON were collected. Serum 25(OH)D levels of 236 age-, and sex- matched healthy controls were assessed.

**Results:** Mean serum 25(OH)D levels were significantly lower in each group of immune-based ON compared to healthy controls ( $p < 0.001$  in each ON group). However, mean serum 25(OH)D levels were not significantly different among each ON group (NMOSD-ON,  $20.18 \pm 5.9$ ; MOGAD-ON,  $23.07 \pm 4.94$ ; autoimmune-ON,  $21.14 \pm 5.29$ ; idiopathic-ON,  $19.56 \pm 5.12$  ng/mL;  $p = 0.525$ ). The prevalence of serum 25(OH)D levels lower than 30 ng/mL (vitamin D insufficiency and deficiency) was 100% in each ON group. This prevalence was more common in each ON group than healthy controls ( $p < 0.001$  in each ON group). No correlations were observed between attack severity and serum 25(OH)D levels.

**Conclusion:** The serum levels of 25(OH)D were significantly lower in immune-based ON subjects as compared to age-, and sex- matched healthy controls. Furthermore, vitamin D insufficiency and deficiency were significantly more common in Thai immune-based ON than healthy controls. Serum 25(OH)D levels were not associated with attack severity. We highly recommend that serum 25(OH)D levels should be screened in all subjects with immune-based ON.

P-241

### Comparison of the effects between a selective EP2 agonist and PGF2 $\alpha$ on the adipogenesis of 3D human orbital fibroblasts spheroids

F Hikage<sup>1</sup>, Y Ida<sup>1</sup>, M Higashide<sup>1</sup>, A Umetsu<sup>1</sup>, Y Tsugeno<sup>1</sup>, S Suzuki<sup>1</sup>, M Watanabe<sup>1</sup>, H Ohguro<sup>1</sup>.

<sup>1</sup>Ophthalmology, Sapporo Medical University, School of Medicine, Sapporo, Japan

**Objective:** The purpose of this study was to investigate the effects between the prostanoid EP2 agonist, Omidenepag (OMD), and PGF2  $\alpha$  on the adipogenesis of human orbital fibroblasts (HOFs) using a three-dimension (3D) cell culture.

**Methods:** During adipogenesis of 3D HOFs spheroids, changes in size, lipids staining, mRNA expression of adipogenesis related genes, PPAR  $\gamma$ , AP2, and ADIPOQ, and extracellular matrix, collagen 1 (COL 1), COL 4, COL 6, and fibronectin (FN), and stiffness by a micro-squeezer were examined in the presence and absence of either 100 nM bimatoprost acid (BIM-A) or 10, 100, or 10,000 nM OMD.

**Results:** The size of the 3D spheroids increased dramatically during adipogenic differentiation (DIF+), and these were further enhanced in the presence of OMD in contrast to the BIM-A-induced suppression effect. The intensity of BODIPY staining was significantly increased upon DIF+, and this increase was inhibited by OMD. The mRNA expression of PPAR  $\gamma$  or AP2 was significantly increased upon DIF+. These DIF+-induced enhancement effects of PPAR  $\gamma$  were suppressed in the presence of BIM-A or OMD. The DIF+-induced downregulation of COL 1 and FN, or the upregulation of the expression of COL 4 and COL 6 were all suppressed in the presence of BIM-A. In contrast, OMD caused similar effects on COL 4, COL 6, or FN expression, but caused a significant increase in COL 1 expression. Stiffness was significantly increased upon DIF+, and was further increased or substantially decreased by BIM-A or OMD, respectively.

**Conclusion:** The present study indicates that the EP2 agonist, OMD, had different effects on 3D HOFs spheroids, as compared to BIM-A. Therefore, OMD may not induce deepening of upper eyelid sulcus (DUES).

P-244

### Dorsal Midbrain Syndrome from Thalamocapsuloganglionic Hemorrhage: A Case Report

J Cabrera<sup>1</sup>, B Mesina<sup>1</sup>.

<sup>1</sup>Ophthalmology & Visual Sciences, Philippine General Hospital, Manila, Philippines

**Objective:** The purpose of this paper is to present the case of a 57-year-old Filipino male who presented with the classical signs of dorsal midbrain syndrome secondary to a parenchymal hemorrhage at the left thalamocapsuloganglionic region, a rarely reported site of a primary lesion causing dorsal midbrain syndrome.

**Methods:** This is a case report of a patient seen at the Neuro-Ophthalmology Clinic of the Philippine General Hospital, Manila, Philippines.

**Results:** This is the case of a 57-year-old Filipino male who came in with a chief complaint of binocular, vertical diplopia at the outpatient clinic of the Philippine General Hospital. His symptoms started four months prior when he experienced sudden-onset headache and subsequent loss of consciousness, prompting immediate consult at a local hospital. A cranial tomography scan was done which revealed a mild stroke, and the patient was discharged well after 1 week of admission.

At the time of our examination, visual acuity at distance was 20/20 OU. Both eyes presented with mild lid retraction. Pupillary examination revealed both pupils at 3 mm, sluggishly reactive to light. On primary gaze, there was a slight left hypertropia. The patient had severe restriction on upgaze of both eyes, with noted binocular vertical diplopia on near and far vision. Extraocular movements were normal in all other cardinal gazes, but the patient presented with skew deviation on further examination. On testing the near response, the patient had convergence-retraction nystagmus and light-near dissociation.

Based on the history and physical examination, a diagnosis of dorsal midbrain syndrome was made. Review of previous CT scan revealed a 5.4cc parenchymal hemorrhage in the left thalamocapsuloganglionic region, with associated compression of the body and posterior horn of the left lateral ventricle and a rightward midline shift. Focal hypodensities likely representing perilesional edema were seen at the tectum, but there was no obvious involvement of the midbrain structures.

**Conclusion:** This is a case of dorsal midbrain syndrome secondary to a left thalamocapsuloganglionic hemorrhage. The patient's signs and symptoms may ultimately be attributable to mass effects of the primary lesion on the dorsal midbrain, affectation of shared vascular supply among dorsal mesencephalic structures, or compromise of supranuclear inputs to the dorsal midbrain. This case provides evidence that dorsal midbrain syndrome may result from lesions without obvious involvement of the said region.

P-246

**Visual field defects in pituitary adenomas – a single-center cross-sectional study**M Chou<sup>1</sup>.<sup>1</sup>*Ophthalmology, Show-Chuan Memorial Hospital, Changhua, Taiwan, China*

**Objective:** To investigate the pattern of visual field defect in patients with pituitary adenomas and the correlation between the tumor size and severity of functional defect.

**Methods:** Eighteen patients with pituitary adenomas who received comprehensive ophthalmic examinations and standard automated perimetry (SAP) with 30-2 programs were included between 2018-2021 in a single center. We defined hemianopia or quadrantanopia as typical visual defects, while other patterns as atypical defects. The severity of functional defect was calculated by mean deviation (MD) of SAP. Tumor volume was measured from brain CT or MRI. Pearson correlation was used to investigate the relationship between both parameters.

**Results:** 16 of the 18 patients (88.9%) had visual field defects, including 12 patients (75%) with typical defects and 4 patients (25%) with atypical pattern. 1 patient (6.3%) had moderate visual field defect ( $6 < MD < 12$ ), 11 patients (68.8%) had severe defects ( $12 < MD < 20$ ), and 4 patients (25%) had advanced defects ( $MD > 20$ ). There was a significant correlation between mean deviation of SAP and tumor volume, with Pearson correlation coefficient  $r=0.87$  ( $p=0.0001$ ).

**Conclusion:** Most patients with pituitary macroadenoma have visual field defects.

Due to the variant involvement in the visual pathway, atypical visual field defects may exist. Severity of visual field defects significantly correlates with tumor size.

P-247

**Secondary Syphilis Presenting as Optic Neuritis in an Immunosuppressive Patient: A Case Report**P Bayu Putra.

**Objective:** Syphilis is a sexually transmitted, systemic infection caused by the spirochete bacterium *Treponema pallidum*. Ocular involvement may be silent or present as anterior uveitis, choroiditis, interstitial keratitis, retinal vasculitis, retinitis, optic neuritis, dacryoadenitis, or scleritis. The observation of optic nerve abnormalities in an ophthalmological examination in a patient with syphilis is highly suggestive of central nervous system (CNS) involvement and should be considered synonymous with neurosyphilis.

**Methods:** This case report was aimed to present secondary syphilis presenting as optic neuritis in a HIV-positive patient.

**Results:** The case reported is a 35-year old male presented with gradual vision loss over 4 months. Visual acuity was counting fingers at 3 meter in the right eye and counting fingers at 2 meter in the left eye. Dilated fundus examination showed edematous optic nerve with exudate, frosted-branch angiitis, and vascular sheathing.erior. The blood work showed a positive VDRL with 1:1 titers, a positive TPHA with >1:640 titers, and a positive HIV-antigen test with CDR cell count of 211 cell/ $\mu$  L.

**Conclusion:** Ophthalmologic findings, including disc oedema, may be the presenting features of syphilis, therefore ophthalmologists have the opportunity to play a key role in the diagnosis and management of this disease, important for a good visual outcome.



P-248

### Traumatic Optica Neuritis Retrospective Analysis with Fifteen Years Multi-Centers Research Database

C Chen<sup>1,2</sup>, N Kuo, M Lin<sup>3</sup>, Y Chen<sup>4</sup>, C Lai<sup>4</sup>.

<sup>1</sup>Ophthalmology, Department of Ophthalmology, Chang Gung Memorial Hospital, Chiayi and Yunlin, Taiwan, Puzi city Chiayi County, <sup>2</sup>Optometry, Chung Hwa University of Medical Technology, Taiwan, Tainan City, <sup>3</sup>Health Information and Epidemiology Laboratory, Chang Gung Memorial Hospital, <sup>4</sup>Ophthalmology, Department of Ophthalmology, Chang Gung Memorial Hospital, Chiayi, Taiwan, Puzi city Chiayi County, Taiwan, China

**Objective:** This study tracks 937 TON patients from 15163 optical neuritis cases by using CHANG GUNG Memorial Hospitals(6 multi-centers), Taiwan. To follow 2 years treatments results of visual acuity.

**Methods:** This retrospective analysis data backtracked TON cases of CGRD from 2007 to 2021. VA outcome has been analyzed in different 4 groups, surgery, IV, oral steroid and none intervention, by converted to Log MAR, at different periods.

**Results:** In total, 15,163 ON cases, 937cases (6.18%) been categorized in TON. In 4 groups, female were 22.6%, 21.3%, 9.5% and 30.5%, and mean age(SD) were 33.2 (14.4), 38.1(18.2), 40.3(16.8), 45.8(20.2), separately. The follow-up cases decreased with time, the total ceases form 599 at 3-months to 136 at 2-years. In VA analysis, the overall mean Log MAR 1.81 (SD, 0.93) at 3-months and Log MAR 1.64 (0.94) at 2-years. The data of follow-up were compared with the 3-months test as the baseline, the better performance was about 35.0%~36.8%, the same was 40.4~45.4%, and the worse was 18.8~22.8%. In surgery group, the better part (23.5-28.6%) was higher than the worse (14.7-18.9%). In IV and oral groups, the betters(25-50%) were more than the worses(0~19.3%). In no intervention group, with the highest worse rate among the four groups at about 22-25% but still less than the better 35.0~39.6%.

**Conclusion:** In this research, the gender and age were related high risk factors of TON. Patients got better in visual outcome were more than that got worse. We recommended patients should get aggressive treatments and regular follow up.

P-249

**Quality of Optometric referrals of suspected papilloedema cases to an urgent referral clinic**S Sadanandan<sup>1</sup>, P Palimar<sup>1</sup>.<sup>1</sup>*Wrightington Wigan and Leigh Teaching Hospital NHS foundation Trust, Wigan, United Kingdom*

**Objective:** Our Urgent Referral Clinic (URC) has seen a surge in referrals for “disc oedema” reflecting the national trend following the gross negligence manslaughter ruling against an optometrist in 2016. The study was done to assess the quality of referrals, analyze the outcomes and make recommendations to improve referral practice.

**Methods:** A retrospective analysis of “Urgent” referrals for ‘Suspected papilledema’, between January to July 2020 was done, which looked at documented history, clinical findings, attached images and visual fields. The outcome was derived from URC records. Patients with known Idiopathic Intracranial Hypertension (IIH) were excluded. A search was undertaken for existing optometric guidelines.

**Results:** Community optometrists accounted for 80% of the 78 new referrals. The median time to be seen was 5 days. Headache was a documented complaint in only 54% (characteristics described in only 59% of these). 42% were referred for blurred/indistinct discs in asymptomatic patients. Attachments included: fundus photograph in 1, OCT images in 5 and Visual fields in 4 cases. 83% were normal and discharged at first visit. Nine cases (11%) were confirmed as papilledema (IIH-7, accelerated hypertension-2). Only 2 detailed optometric referral guidelines were found.

**Conclusion:** Sketchy history taking, insufficient examination and lack of relevant images resulted in inappropriate referrals and difficulties with their vetting (e.g., IIH to routine Neuro-ophthalmology clinics). The results and a new 'referral proforma' were shared with the Education Team of the Local Optometry Committee. Formal feedback to each referring optometrist was agreed upon. A follow-up Audit is scheduled.

P-250

## Papilledema et causa Cerebral Venous Sinus Thrombosis : A Case Report

D Putri Widyavera Hukum<sup>1</sup>, R *Prihatningtias*<sup>1</sup>.

<sup>1</sup>*Neuro-ophthalmology, Diponegoro University, Semarang, Indonesia*

**Objective:** Cerebral Venous Sinus Thrombosis (CVST) is a rare, potentially fatal medical condition that can cause various manifestation. Aim of this case report was to present clinical manifestation, laboratory, neuroimaging and standard medical treatment for CVST.

**Methods:** In this case report presented a 17-year-old female patient presented with blurring of vision in the right eye (RE) and left eye (LE) for 2 weeks before admission after she felt headache since a month before. Her visual acuity was 6/48 in RE and 6/30 in LE. The intraocular pressure (IOP) was 13.7 mmHg (RE) and 14.7 mmHg (LE). In ophthalmologic examination showed pupil diameter 5 mm, with decreased pupillary reflex in both eyes and positive relative afferent pupillary defect (RAPD) in right eye. The funduscopy revealed edematous in both eyes. Thus she underwent magnetic resonance imaging (MRI) and magnetic resonance venography (MRV), confirmed with digital subtraction angiography (DSA) along with heparin. Oral carbonic anhydrase inhibitor therapy was given to maintain intracranial pressure.

**Results:** The result showed normal in MRI examination, even so, right ethmoiditis and filling defect in right transversus sinus was seen from MRV imaging. The result confirmed with DSA that showed thrombus causing partial stenosis in right and left transversosigmoid junction sinus and caused slowing contrast flow in left transversus sinus. After treatment has already done, the patient felt slightly better on her headache and the visual acuity improved to 6/18 (RE) and 6/12 (LE)

**Conclusion:** Papilledema in both eyes may have several differential diagnosis. Neuroimaging is the gold standard and is ultimately required for diagnosis and localization of CVST. Correct diagnosis is important because papilledema can lead to life threatening disorder.

P-251

**Pupil Sparing Third Nerve Palsy With Moderate Ptosis**J Singh.

**Objective:** To look for regression of symptoms on conservative management of partial third nerve palsy with sparing of third nerve. Acquired third nerve palsy depends on the affected area of the oculomotor nerve pathway. It can be divided into partial or complete palsy. Complete 3rd nerve palsy presents with complete ptosis, with the eye positioned downward and outward with the inability to adduct, infraduct, or supraduct, as well as dilated pupil with sluggish reaction. Partial 3rd nerve palsy may be more common, and can present with variable duction limitation of the affected extraocular muscles and with variable degree of ptosis and/or pupillary dysfunction.

**Methods:** A 53 year old male came with the complaint of right eye drooping of eyelid and double vision for the last 2 days. He underwent complete ophthalmic examination. The patient had normal visual acuity, color vision, and visual fields in each eye. The pupils were isocoric and equally and normally reactive to light and near stimulation. He was diagnosed with third nerve palsy with sparing of pupil with moderate ptosis. Patient was a known case of diabetes mellitus on regular oral medications for the last 6 years. Routine blood investigations were sent and patient was found to have hypertriglyceridemia and increased serum VLDL levels.

**Results:** Swinging torch light test showed normal sized normally reacting pupils. Right eye drooping of eyelid was noted. Slit Lamp Examination showed normal anterior segment findings. All of these symptoms supported the diagnosis of third nerve palsy with sparing of pupil with moderate ptosis. Neurology and medicine opinion was sought and patient was managed conservatively

**Conclusion:** The prognosis in most cases of third-nerve palsy is usually good, as spontaneous regression of the symptoms occurs within a few months; however, the degree of recovery depends on the etiology and management.

P-252

**Ultra-widefield SS-OCTA is Comparable or even Superior to Ultra-widefield FA in Detecting RVO Lesions**S Li<sup>1</sup>, Q Zeng<sup>1</sup>, J Qu<sup>1</sup>.<sup>1</sup>Ophthalmology, Peking University People's Hospital, Beijing, People's Republic of China

**Objective:** To compare ultra-widefield swept-source optical coherence tomography angiography (UWF SS-OCTA) with ultra-widefield fundus fluorescein angiography (UWF FA) for detecting retinal vein occlusion (RVO) lesions.

**Methods:** Thirty-four eyes of 32 patients with treatment-naïve RVO were enrolled at Peking University People's Hospital from September 2021 to March 2022. Patients were imaged with a UWF FA(200° ) and a UWF SS-OCTA using 24 x 20 mm scan single capture. Quantitative assessments of RVO lesions such as foveal avascular zone (FAZ) area and perimeter, non-perfusion areas (NPA), number of microaneurysms (MAs), capillary changes and collateral vessels were performed.

**Results:** The median FAZ area was 0.372 (range, 0.276-0.48) and 0.370 (range, 0.277-0.48) mm<sup>2</sup> on SS-OCTA and FA, respectively. The median FAZ perimeter was 2.476 (range, 2.007-2.909) and 2.330 (range, 2.027-2.807) mm on SS-OCTA and FA images, respectively. The measurement FAZ area and perimeter were comparable between SS-OCTA and FA (P=0.830 and 0.596, respectively). ICCs of FAZ area and perimeter between SS-OCTA and FA was high (0.999, [0.997-0.999] and 0.996 [0.992-0.996], respectively), suggesting good agreement between the two imaging modalities. The mean NPA area was larger on SS-OCTA than that on FA (88.864 ± 77.096 vs. 87.944 ± 77.444 mm<sup>2</sup>, P=0.041). The ICC of NPA area was also high (0.999, [0.999-1.000]). The median of total MA count was less on SS-OCTA than on FA (7 (range, 0-19) vs. 12 (range, 0-23), P<0.001). Agreement in detecting MAs between OCTA and FA was found to be good (ICC=0.920, [0.555-0.974]). The mean count of capillary changes in each eye was 11 ± 9 on SS-OCTA compared to 6 ± 7 on FA. SS-OCTA had better performance in detecting capillary changes (P<0.001). Agreement in detecting capillary changes between OCTA and FA was found to be fair (ICC=0.733, [0.081-0.905]). The median count of collateral vessels in each eye was 4 (range, 0-6) on SS-OCTA compared with 0 (range, 0-0) on FA. SS-OCTA performed better in detecting collateral vessels (P<0.001). Agreement in detecting collateral vessels between OCTA and FA was found to be fair (ICC=0.564, [0.039-0.805]).

**Conclusion:** Compared with UWF FA, UWF SS-OCTA (24 x 20 mm) was found comparable or even superior in detecting FAZ, NPA, capillary changes and collateral vessels except MAs in RVO. UWF SS-OCTA may offer a more efficient alternative to FA for diagnosis and monitoring RVO.

P-253

### Using CBCT for Morphometric Evaluation of Bony Nasolacrimal Canal in Patients with Primary Acquired Nasolacrimal Duct Obstruction

W Peihong.

**Objective:** The morphology of bony nasolacrimal duct (BNLD) as a contributory factor in primary acquired nasolacrimal duct obstruction (PANDO) is still controversial. The objective of this study was to evaluate the morphometric differences of BNLDs in unilateral PANDO patients between PANDO and non-PANDO sides, as compared with the control group using Cone Beam Computerized Tomography (CBCT).

**Methods:** Bilateral BNLDs in 42 unilateral PANDO patients and 14 control subjects were retrospectively measured. The length and volume, the minimum transverse diameter (TD), the entrance, minimum and distal end areas of BNLD, relative lacrimal sac-BNLD angle, nasolacrimal duct and nasal floor plane (NLNF) angle as well as the deviation of nasal septum were investigated using the software of GE Advantage Workstation and compared among groups.

**Results:** The BNLD length was significantly longer [(10.14 ± 1.57) mm vs (8.59 ± 1.29) mm,  $p < 0.001$  and (9.92 ± 1.48) mm vs (8.59 ± 1.29) mm,  $p < 0.001$ , respectively] while NLNF angle [89.50(88.70, 91.10) ° vs 87.80(84.73, 88.88) °,  $p < 0.001$  and 89.60(88.60, 90.90) ° vs 87.80(84.73, 88.88) °,  $p < 0.001$ , respectively] was larger and Lacrimal sac-BNLD angle [13.95(12.68, 15.10) ° vs 16.45(13.83, 19.35) °,  $p = 0.02$  and 14.05(12.88, 15.53) ° vs 16.45(13.83, 19.35) °,  $p = 0.01$ , respectively] was smaller within patients both in PANDO and non-PANDO group, as compared with the control group; however, there were no significant differences between PANDO and non-PANDO group within patients (all  $p > 0.05$ ). The volume, the minimum TD, the entrance, minimum and distal end areas of BNLD and the occurrence rates of deviated nasal septum were not significantly different between PANDO patients and control subjects, as well as between PANDO and non-PANDO sides within patients. There was no statistical difference in the BNLD parameters between males and females or among different ages within PANDO patients (all  $P > 0.05$ ).

**Conclusion:** The shorter BNLD length and larger NLNF angle and smaller lacrimal sac-BNLD angle in PANDO patients, in both PANDO and non-PANDO sides, may be associated with PANDO development. The lack of difference between PANDO and non-PANDO sides within patients and some overlap between PANDO patients and control subjects suggest that narrow and short BNLD is not the sole factor.

P-254

### The Diagnostic Accuracy of Optical Coherence Tomography Angiography in Detecting Polypoidal Choroidal Vasculopathy

X Leng<sup>1</sup>, Y Wu<sup>1</sup>, G Li<sup>1</sup>, M Shi<sup>1</sup>, X Lu<sup>1</sup>.

<sup>1</sup>Chengdu University of TCM, Chengdu, People's Republic of China

**Objective:** Polypoidal choroidal vasculopathy (PCV) is an increasingly recognized cause of exudative and hemorrhagic complications in the macula. To evaluate the diagnostic performance of optical coherence tomography angiography (OCTA) for detection of PCV using indocyanine green angiography (ICGA) as the reference standard.

**Methods:** A search of PubMed, EMBASE, Cochrane Library and a supplemental search of clinical trial registries up to March 31, 2020 was performed. The search terms combined synonyms for OCTA, ICGA and PCV were used to identify studies. Studies evaluating the diagnostic performance of OCTA for detection of PCV were selected. In accordance with PRISMA guidelines, multiple authors extracted data from included studies. Results were meta-analyzed for each diagnosis.

**Results:** The pooled sensitivity for OCTA for BVN was 0.90 (95% CI, 0.86-0.93;  $I^2=44.8\%$ ), and specificity was 0.71 (95% CI, 0.59-0.81;  $I^2=78.4\%$ ). Polyps were evaluated by OCTA with a combined sensitivity of 0.70 (95% CI, 0.63-0.77;  $I^2=74.3\%$ ) and specificity of 0.84 (95% CI, 0.71-0.93;  $I^2=21.1\%$ ). The overall sensitivity, specificity, PLR, NLR and AUC for pooled results were 0.73(95% CI, 0.67-0.80;  $I^2=84.4\%$ ), 0.62(95% CI, 0.46-0.77;  $I^2=0\%$ ), 1.40(95% CI, 0.90-2.18;  $I^2=0\%$ ), 0.42(95% CI, 0.21-0.85;  $I^2=32.2\%$ ) and 0.6390 respectively.

**Conclusion:** OCTA has a good performance in identifying the PCV. Although it is not good as ICGA, as a noninvasive medical examination, it should be considered if patients are allergic to contrast agents. The diagnostic accuracy is connected with different continents and types of OCTA. The combination of ICGA and OCTA can significantly minimize the risk of missed lesions which is essential to PCV patients.

P-255

**The OCT and Optic Nerve Head parameters of 100 Afro Caribbean Primary Open Angle Glaucoma Subjects**C Brown, K Funk<sup>1</sup>, B Mcintosh<sup>2</sup>.<sup>1</sup>Case Western University, <sup>2</sup>Case Western Reserve University, Ohio, United States

**Objective:** Our study aims to show that Afro Caribbean Glaucoma subjects have structural differences in the optic nerve head, when compared to other ethnic groups. We suggest that these differences have bearing on diagnosis and management of this disease in this population. The Baltimore Eye Study suggested higher prevalence and worst outcomes for people of African Descent who have been diagnosed with Glaucoma. Several studies, the ADAGES and POAAAG included, point to structural differences in the Optic Nerve in these subjects. However, since the advent of Optical Coherence Tomography in clinical practice, there has not been a paper that focuses on OCT findings in this subgroup of widely affected patients.

**Methods:** All data was taken from charts of patients diagnosed with primary open angle glaucoma with supportive clinical findings and confirmatory visual field defects. All measurements were taken with the Zeiss Cirrus 5000. Univariate analyses were performed to generate summary statistics of the variables

**Results:** The average signal strength was 8.4. The average disc area was 2.20mm<sup>2</sup>. This suggests a larger disc size than other similar populations (eg 2.0mm<sup>2</sup> POAAAG) The other averages were as follows: RNFL 78um, rim area 1.0, average CDR0.7.

**Conclusion:** Afro caribbean Glaucoma subjects have optic nerve head parameters which differ from other ethnic groups. They have larger disc areas, even than afro american subjects, This will have bearing on use of diagnostic tools in earlier detection and lend itself to development of ethnic specific data banks.



P-256

**Optic neuropathy or chorioretinopathy COVID-19 related?**J Cunha, I Poças, P Camacho, P Lino, M Castelhana, F Carvalho, J Almeida, I Prieto.

**Objective:** In Portugal, in March 2022, after 2 years of the emergence of the pandemic by COVID 19 at national level, 3413013 positive cases were counted. It is known that SARS-COVs have neurotropism and that the viruses reach the central nervous system by hematogenous neuronal dissemination. Thus, the human retina as an extension of the CNS may show changes related to COVID-19. This work aims to characterize different chorioretinal metrics in participants recovered from COVID-19 compared to the control group.

**Methods:** Cross-sectional study of a quantitative paradigm, correlational type. The sample (n=96), constituted by the positive PCR group (n=56) and the negative PCR group (n=40) was ophthalmologically characterized. The tomographic study of the retina and optic nerve was performed using SD-OCT, and the choroid with tomograms in EDI mode. The ethical and legal guidelines of the Declaration of Helsinki were considered. For the analysis and treatment of data, the IBM Statistical Package for the Social Sciences for Windows "SPSS Statistics", version 22 was used.

**Results:** A total of 40 controls (27 women [67.5%]) and 56 COVID19 participants (34 women [60.8%]) were included in this first report. Statistical significance was found for nasal total thickness 3mm (p=0.025), inferior 3mm (p=0.049) and temporal 3mm (p=0.009). A decrease in neural layers was clear in the retinal nerve fiber layers (nasal 3m [p=0.049] and temporal [p=0.029] and ganglion cell layer (TS [0.019], NI [0.002], TI [0.046] and total [0.014]). In our study it was found an increased subfoveal choroidal thickness in patients post COVID-19 (278 ± 64 versus 230,9 ± 76 µm [p=0.002]).

**Conclusion:** Our results show a tendency towards a neuropathy like the classic description observed in other neurological, toxic and/or metabolic pathologies. These exploratory results allow us to describe the retinal changes in patients due to the neurotropism of Sars-Cov-2, so the longitudinal follow-up of these patients is important to allow the description of the natural history of a neuropathy secondary to COVID-19 infection. The changes found in the structure of the macula and choroid are not compatible with chorioretinopathy or glaucomatous neuropathy. The increased subfoveal choroidal thickness in healthy patients post COVID-19 may be related to younger mean age of the COVID group or with levels of inflammation related to the pathogenesis of COVID-19.

**P-258****Salvaging Deep anterior lamellar keratoplasty (DALK) with perforation: An ASOCT assisted management.**R Kusumesh, V Singh<sup>1</sup>.<sup>1</sup>*Ophthalmology, Indira Gandhi Institute of Medical Sciences, Patna, India*

**Objective:** DALK is a selective corneal transplantation procedure indicated for corneal opacities limited to the stroma. The most common intraoperative complication is a perforation. Here we describe two cases of manual DALK complicated with intraoperative Descemet membrane (DM) perforation. Both cases were managed and monitored using appropriate measures with ASOCT assistance.

**Methods:** A retrospective study evaluated a series of 8 eyes that had DALK using layer-by-layer manual dissection technique.

**Results:** Intraoperative DM perforation occurred in 2 eyes (25%) during manual deep dissection. In both eyes, dissection could be completed by forming and maintaining the anterior chamber (AC) with air and suture. Subsequently the use of 14% C3F8 enhanced the resolution of residual aqueous. Double AC formation was also encountered in one case following C3F8 which was managed with slit-lamp assisted drainage after localization on ASOCT.

**Conclusion:** Identification and proper management of DM perforation lead to good visual and anatomical outcome.

P-259

**CT Head Lens Exclusion Re-Audit in a UK District General Hospital**M Kurian, A *Bapusamy* .

**Objective:** According to the UK Royal College of Radiologists the lens of the eye should be excluded in performing a CT head scan. Reasons for this include to help reduce radiation to the lens of the eye and the formation of cataracts. This re-audit was performed to determine the number of CT head scans in which the lens was included in the A&E, inpatient and outpatient settings within a UK District General Hospital.

**Methods:** 50 consecutive CT head scans in the study period were reviewed from the A&E and inpatient settings as well as 50 consecutive CT head scans from the outpatient setting. The age, sex of the patient, whether a CT spine was performed and the scan indication were also considered.

The results of the 1st audit cycle was presented at the CT/MRI governance meeting of the district general hospital. The results of the 2nd audit cycle was also disseminated to the radiology and radiography team at the hospital.

**Results: Results from the 1st audit cycle:****A&E and inpatient scans performed between 1/1/2021-3/1/2021:**

42 CT head scans had the lens included from both eyes. 3 patients had just one eye included.

**Outpatient scans performed between 4/1/2021-5/2/2021:**

45 patients had a CT head scan performed with both lenses included. 2 scans included the lens of one eye.

**Results from the 2nd audit cycle:****A&E and inpatient scans performed between 16/6/2021- 21/6/2021:**

46 scans included the lens of both eyes. 4 scans did not include the lens from either eye.

**Outpatient scans performed between 27/5/2021-24/6/2021:**

42 patients had the lens of both eyes included. 2 patients had one lens included, however there was suspicion of an intraocular lens placement in the other eye.

**Conclusion:** Reasons for inclusion of the lens in performing the CT head scan may include difficulty positioning the patient due to reduced GCS, suspected C-spine injury, scanning a paediatric patient, confusion or non-compliance. Additionally, the type of CT scanners used in the department were unable to be angled adequately to avoid scanning the lens.

Ongoing educational support and awareness is needed to further reduce the radiation to the lens.

P-261

### Evaluation of the choroid thickness in myopia patient using wide field swept-source optical coherence tomography

H Leng, J Li, J zhong.

**Objective:** To evaluate the changes of the choroid thickness(CT) in the eyes with myopia using swept-source optical coherence tomography (SS-OCT).

**Methods:** This was a cross-sectional study with a sample of 60 subjects (all with right eye information collected) aged 22-31 years( $26.05 \pm 1.85$ years) with best corrected visual acuity  $\geq 1.0$  (equivalent to 20/20 of Snellen). All participants underwent a series of tests including optometry, intraocular pressure, axial length, Wide-field fundus imaging, OCTA. OCTA scans were obtained using a 400 kHz wide field SS-OCTA instrument, which is capable of capturing images of retinal blood flow in a range of  $24\text{mm} \times 20\text{mm}$  by a single scan. Subjects were divided into emmetropia group ( $SE \geq -0.50\text{D}$ ), mild myopia group ( $-0.50\text{D} > SE \geq -3.00\text{D}$ ), moderate myopia group ( $-3.00\text{D} > SE \geq -6.00\text{D}$ ) and high myopia group ( $SE < -6.00\text{D}$ ) according to the equivalent spherical lens intensity (SE), with 15 subjects in each group. The OCTA scanning range was  $24\text{mm} \times 20\text{mm}$  centered on the macula. The choroid within the scanning range was divided into  $12 \times 12$  grids, and the change of choroid thickness in each grid in different fundus areas was compared and statistically analyzed.

**Results:** The average choroid thickness in posterior  $24\text{mm} \times 20\text{mm}$  area of emmetropia, mild myopia, moderate myopia and high myopia were  $213.52 \pm 37.34 \mu\text{m}$ ,  $202.63 \pm 31.52 \mu\text{m}$ ,  $199.10 \pm 40.62 \mu\text{m}$ ,  $161.52 \pm 14.54 \mu\text{m}$ . The choroid thinning area mainly distributed in the posterior pole and upper and lower parts of the vascular arch (10-20mm from macula). The mean choroid thickness was negatively correlated with axial length ( $r = -0.424$ ,  $P < 0.01$ ).

**Conclusion:** The choroid of myopic patient becomes apparent thinning, increase along with myopic degree, not only the choroid of the posterior pole becomes thinner, the area outside the vascular arch also becomes thinner. and increase along with eye axis, the degree of choroid becomes thin aggravates.

**P-262****Detection and analysis of non-perfusion area in eyes with retinal vein occlusion by ultra-wide OCTA**W Dong, J zhong.

**Objective:** To observe the detection of ultra-wide optical coherence tomography angiography (OCTA) in non-perfusion area and neovascularization of retina in eyes with retinal vein occlusion (RVO), and to evaluate its clinical application in the management of RVO.

**Methods:** A retrospective study. From November 2021 to April 2022, patients with RVO diagnosed in Sichuan Provincial People's Hospital were enrolled in the study. All patients underwent BCVA, fundus photography, FFA and ultra-wide OCTA examination. Angiography 24mm20mm scanning mode centered on the macula was selected for OCTA examination. All images were taken by the same physician and read by the same ophthalmologist. Based on the results of FFA, the performance of ultra-wide OCTA in detecting the non-perfusion area in eyes with RVO was analyzed by receiver operating characteristic curve (ROC curve).

**Results:** A total of 48 patients (48 eyes) with RVO were included. There were 29 males (29 eyes) and 19 females (19 eyes). The age ranged from 39 to 87 years, with an average of  $(58.8 \pm 10.7)$  years. There were 28 eyes (58.3%) with non-perfusion area detected by FFA, of which by OCTA were 27 eyes (96.4%). ROC analysis showed that the sensitivity and specificity of OCTA in detecting non-perfusion area of RVO were 100% and 95% respectively, and AUC was 0.929. The sensitivity and specificity of OCTA in detecting non-perfusion area of BRVO were 100% and 85.7% respectively, and AUC was 0.917. The sensitivity and specificity of OCTA in detecting non-perfusion area of CRVO were 83.3% and 100% respectively, and AUC was 0.957.

**Conclusion:** Ultra-wide OCTA is a fast, reliable and noninvasive method, which can accurately identify the non-perfusion area of RVO patients and can be used for the follow-up management.

**P-263****Multimodal imaging including OCT-A to analyse long-term effects of COVID-19**

J Hall<sup>1</sup>, D Vogel<sup>1</sup>, C Enders<sup>1</sup>.

<sup>1</sup>MVZ Prof. Neuhann GmbH, Munich, Germany

**Objective:** To analyse possible ophthalmological long-term effects of the Covid-19 in a patient suffering from Long Covid

**Methods:** We present an analysis of multimodal imaging results and further diagnostics to evaluate long-term effects of COVID-19 on the eye. On both patient eyes of our female patient we performed Optical Coherence Tomography (OCT) for examination of the macula, retinal nerve fiber layer (RNFL) and ganglion cell layer (GCL). OCT-Angiography (OCT-A) analysed retinal and choroidal vessel and perfusion status. We performed fundus photography, fundus-autofluorescence and multicolor imaging, as well as detailed slit-lamp examination of the anterior and posterior segments and color perception testing using the Ishihara test.

**Results:** In general, the patient complained of a persisting loss of senses of smell and taste. In addition she indicated to suffer from chronic fatigue, but denied ophthalmological symptoms. Our diagnostics showed no abnormal findings in OCT of the macula. RNFL and GCL were within normal limits. OCT-A showed a regular perfusion of retinal vessels. Other multimodal imaging as well as slit lamp examination showed regular status of the anterior segment as well as the vitreous, optic nerve, retinal vessels and the macula. Visual acuity and color perception were normal.

**Conclusion:** In detailed examination of our patient suffering from long-term effects of a COVID-19 disease we were not able to detect any typical or otherwise abnormal ophthalmological findings.

**P-264****Ultrasound of Bilateral Persistent Fetal Vasculature in Premature Infants Mimicking Retinopathy of Prematurity**R Abbas.**Objective:**

The purpose of this study is to show the use of ultrasound in differentiating between bilateral persistent fetal vasculature (PFV) in premature infants, and retinopathy of prematurity (ROP) and how to reveal the traction on the retina caused by the persistent fetal vasculature.

**Methods:** This retrospective study included 30 eyes of 15 infants with a history of premature delivery. This hospital based study was conducted at Watany Research and Development Center (WRDC), Watany Eye Hospital, Cairo, Egypt. It included patients presenting in the period between January 2017 & March 2022. Ultrasound was performed using the Vumax B-scan with a 12 mm probe. Patients with other clinical and sonographic findings combined with PFV were excluded.

**Results:** Results: The study group included 30 eyes of 15 patients with sonographic evidence of bilateral PFV. Five patients were clinically suspected and misdiagnosed as retinopathy of prematurity. Ultrasound showed evidence of central tractional retinal detachment caused by the PFV in 18 eyes (60%) and retina in place in 12 eyes (40%).

**Conclusion:** Conclusion: B-scan ultrasonography can be of great help in diagnosing and differentiating PFV from ROP in premature infants presenting with bilateral leucocoria.

P-265

**Multimodal Imaging of Adult-onset Coats Disease with Epiretinal Membrane, Macular Edema and Macroaneurysm**

W Luo<sup>1</sup>, F Liu<sup>2</sup>, D Liu<sup>1</sup>, B Qin<sup>1</sup>.

<sup>1</sup>Shenzhen Aier Eye Hospital Affiliated to Jinan University, <sup>2</sup>The Second Clinical Medical College of Jinan University, Shenzhen, People's Republic of China

**Objective:** To describe the multimodal imaging of a case of adult-onset Coats disease with epiretinal membrane(ERM), macular edema and macroaneurysm(MA).

**Methods:** Retrospective case report.

**Results:** A 53-year-old male was referred for reduction of vision and metamorphopsia in the right eye for nine months. A multimodal imaging study was performed at the time of presentation. The patient was diagnosed with adult-onset Coats' disease and ERM, macular edema as well as macroaneurysm in the right eye. He was initially treated with retinal photocoagulation and dexamethasone intravitreal implant. Ten days later, the patient showed a rapid alleviation of macular edema and an increased microvascular density in the superficial vascular plexus, and the visual acuity improved to 20/25.

**Conclusion:** Our case indicated that promptly PPV surgery for the ERM with a combination of intravitreal dexamethasone and laser would be a better choice in such Coats disease with macular edema, ERM and capillary MA. ICGA and OCT(A) appear to be the best imaging modalities to recognize the capillary MA.



P-266

### Recurrent Retinal Hemorrhage by the same Retinal Arterial Macroaneurysm

S Sheng.

**Objective:** Recurrent Retinal Hemorrhage by the same Retinal Arterial Macroaneurysm

**Methods:** This is a retrospective case series, clinical practice.

**Results:** Four patients diagnosed with RAM present different layers of retinal hemorrhage and treated by medication or surgery. After several times of observation, the hemorrhage all resolved. The four episode of recurrent hemorrhage interval is about one month for our patients. They denied the use of anticoagulants. And the recurrent hemorrhage located different from the first hemorrhage. Visual acuity, intraocular pressure (IOP), and fundus examination were measured and done immediately after the surgery, in 7 days and in approximately 3 months.

**RESULTS:** We experienced four cases of recurrent hemorrhage from the same re-ruptured RAM in retina within a short time. What the four cases have in common is history of high blood pressure and poor blood pressure control.

After first rupture with hemorrhage, we speculated that the RAM's artery wall is still not fully repaired and blood flow is still in filling condition. So RAM re-ruptured which caused high internal pressure. As for the difference in bleeding site and morphology between the second rupture hemorrhage and the first hemorrhage, our analysis may be related to the following factors: 1) Changes in aneurysm rupture site: the aneurysm rupture site at the time of the first hemorrhage has been relatively stable, and the aneurysm can only look for the tumor weakness again when the aneurysm expands again; 2) Due to the "solidification" of retinal structure around the tumor caused by the first intraretinal hemorrhage, the morphology and location of the second hemorrhage changed. From the perspective of the interval of the second hemorrhage, we speculated that the latter one was more likely.

**Conclusion:** We present four hypertensive patient who had central visual loss caused by RAM rupture. One unusual feature was the presence recurrent hemorrhages. The four case highlights the importance of regular ophthalmologic examination of hypertensive patients in order to detect potential RAMs early enough to permit treatment.

P-267

### An Unexpected Conjunctival Foreign Body

M Boutkhil.

**Objective:** Conjunctival foreign bodies are common and mostly harmless. The most frequently identified ones include dust, eyelashes, contact lens and sand. Our case reports an unusual finding in the conjunctival sac.

**Methods:** A 30 year old male patient presented for a regular ophthalmic check up. The patient did not report any swelling, irritation, itching or redness of the eye. He denied any changes in the visual acuity. The examination noted a 20/20 uncorrected visual acuity in both eyes with a normal refraction and an intraocular pressure in the normal range.

The left bulbar conjunctiva was white and quiet. However, a mild swelling and redness of the right conjunctiva was noted. A thoughtful slit lamp examination with a 25x magnification revealed fortuitously the presence of a bug in the conjunctival sac. Later, the patient admitted working in his garden in the previous few days.

**Results:** The treatment protocol included the insect removal and eye irrigation. The patient was educated on the importance of wearing safety goggles when doing high risk tasks for eye injuries.

**Conclusion:** This case highlights the importance of a rigorous history and physical examination of patients to diagnose asymptomatic conditions as they can lead to serious complications in the future.

P-268

**Review Of a Case Of Isolated Orbital Non-Hodgkin's Lymphoma.**R Solanki<sup>1</sup>, P Shetty<sup>2</sup>.<sup>1</sup>Resident, <sup>2</sup>Oculoplasty, Khan Bahadur Haji Bachooali Charitable Eye Hospital, Mumbai, India

**Objective:** We reported the case of a 63-year-old male with left eye proptosis initially diagnosed and managed as non-specific orbital idiopathic (NSOI) inflammation.

**Methods:** 63-year-old male presented to our opd with left eye protrusion. Patient was initially diagnosed as non specific orbital idiopathic (NSOI) inflammation and treated with 6 doses of weekly iv methylprednisolone, showing no clinical response followed by azathioprine and wysolone. No clinical response was observed. MRI revealed left infraorbital mass involving fusiform enlargement of the inferior rectus muscle, with mild surrounding inflammatory changes, without involvement of optic nerve or globe. Inferior rectus muscle incisional biopsy was done which showed small lymphoid population and numerous high endothelial vessels. On IHC CD20 and CD3 shows admixture of band T cells (B and T lymphoid cells). Mib-1 is 30% in highest proliferating areas. Atypical b-lymphoid proliferation suggestive of marginal zone lymphoma. PET-CT scans showed no metastasis/ other abnormalities. The patient was advised radiotherapy as the hypertrophy was involving only inferior rectus muscle of the left eye.

**Results:** There was a satisfactory response obtained and improvement in the left eye proptosis.

**Conclusion:** A tissue biopsy is mandatory whenever there is a dilemma regarding the proptosis which doesn't respond to initial course of treatment.

P-269

**OPTIC DISC MELANOCYTOMA ASSOCIATED WITH NEURORETINITIS-A RARE PRESENTATION**A Rai.**Objective:** To report incidence of optic disc melanocytoma associated with neuroretinitis.**Methods:** A 40 year old female came to our opd with chief complaints of blurring of vision in right eye which was gradual and progressive in nature. Her vision was 1mfc in right eye and 6/6 in left eye. Pupil was sluggishly reacting to light and IOP was 12 and 13mmhg in right and left eye respectively. Anterior segment was unremarkable Fundoscopy of OD revealed a 3\*2mm pigmented lesion was seen covering the optic nerve head except the inferior margin which was hyperemic and blurred .FA shows hypofluorescence seen with leakage at the disc inferiorly . FAF show hypofluorescence over the disk .OCT shows raised nodular hyperreflectivity at its anterior surface and dense posterior shadowing of all retinal layers with optically empty appearance .**Results:** She was treated with IV methyl prednisolone with tapering of oral steroids. Post treatment her BCVA of right eye improved to 6/36 and she developed macular star with resolving fluid . She was planned with an intravitreal anti VEGF and has been put on close follow up in view of malignant transformation.**Conclusion:** Melanocytoma is a deeply pigmented variant of melanocytic nevus that classically occurs in the optic disk, sometimes with contiguous involvement of the adjacent retina or choroid. Optic disc melanocytoma rarely presents with neuroretinitis. Visual recovery is faster if prompt treatment is given .Although melanocytoma is typically a relatively stationary lesion, it can exhibit malignant transformation into melanoma in 1–2% of cases. A patient with a melanocytoma of the optic disk should be examined annually.

P-270

**Non-Hodgkin Lymphoma of the Lacrimal Sac: A Case Series**K Medina, A *Tan*.

**Objective:** To present cases of lacrimal sac Non-Hodgkin lymphoma in a Philippine population.

**Methods:** In this retrospective case series, three cases (one male, two females; mean age: 59.3 years) of Non-Hodgkin lacrimal sac lymphoma seen in a state-supported tertiary hospital in the Philippines were included. Clinical features and diagnostic findings were collected and reviewed. Treatment outcomes for two of the three cases were also included.

**Results:** All patients presented with non-bloody epiphora and a medial canthal mass that extends above the medial canthal tendon. Imaging studies revealed a lacrimal sac mass with orbital and nasolacrimal duct extension. Histopathological findings and preliminary immunohistochemistry studies revealed three cases of Non-Hodgkin B Cell lymphoma, two cases were subclassified into Diffuse Large B Cell Lymphoma. One case was treated with systemic chemotherapy alone while the other case was treated with a combination of radiotherapy, chemotherapy, and immunotherapy. The remaining patient is still for complete systemic work and initiation of treatment.

**Conclusion:** A high index of suspicion allows early diagnosis of lacrimal sac tumors in the presence of epiphora and medial canthal mass even in the absence of pain or bleeding. Multidisciplinary management is necessary for appropriate staging and management. Combination therapy is an effective treatment for Non-Hodgkin lacrimal sac lymphomas.

P-273

### Prognostic Implication of Yes-Associated Protein (YAP) and its Association with Clinicopathological Parameters in Uveal Melanoma

N Kumar.

**Objective:** Uveal melanoma (UM) is a highly aggressive intraocular malignancy in adults, derived from proliferating atypical melanocytes of the uveal tract. Highly pigmented UMs are resistant to chemotherapy and despite advances in chemotherapy, there is currently no effective treatment for metastatic UM. Yes-associated protein (YAP) is a major effector of Hippo-signaling pathway, which plays an important role in tumorigenesis. It is known to be an important gene for metastasis or the acquisition of resistance to anticancer agents. The present study aims to detect the expression of YAP and its association with clinicopathological parameters.

**Methods:** Expression level of YAP protein was assessed in 31 prospective cases of uveal melanoma by immunohistochemistry, and mRNA expression was measured by quantitative real-time PCR. Kaplan–Meier curves and multivariate analysis by Cox's proportional hazard models were used to analyze the correlation of protein expression with clinicopathological parameters and disease-free survival.

**Results:** In our study, there was male preponderance (17/31) and the mean age of patients were 52.29 years (SD = 12.00, range: 25-73 years). Scleral invasion and high pigmentation were found in 35.4% (n=11) and 74.19% (n=23) cases, respectively. Twenty patients (64.5%) had more than two histopathological high-risk factors (HRFs). Expression of YAP was found in cytoplasm (70.09%) and nucleus (19.35%), which indicates inactive and active status of YAP, respectively. mRNA expression of YAP was statistically significant with distant metastasis ( $p=0.043$ ) and at protein level, nYAP was found in cases with HRFs such as high pigmentation ( $p<0.001$ ), mitotic figure ( $p=0.042$ ) and loss of BAP1 expression ( $p=0.036$ ).

**Conclusion:** Our data suggests that nuclear expression of YAP protein might serve as a poor prognostic biomarker in pathogenesis of uveal melanoma which may lead to increased risk of metastasis. Further functional studies are required to explore the role of YAP in larger cohort of uveal melanoma patients for clinical benefits.

P-274

**Clinical characteristics and treatment outcomes of ocular lymphoma with systemic involvement.**Y Yang<sup>1</sup>, W He<sup>1</sup>.<sup>1</sup>west china hospital, chengdu , People's Republic of China

**Objective:** To describe the clinical characteristics and treatment outcomes of ocular lymphoma (OL) with systemic involvement, and assess the impact of timely biopsy and systemic evaluation on the diagnosis and treatment.

**Methods:** The data of patients presenting OL with systemic involvement at the West China Hospital from January 2010 to June 2021 were retrospectively reviewed.

**Results:** A total of 68 patients (40 men and 28 women) were included in the study, of which 64 had ocular adnexal lymphoma and 4 had intraocular lymphoma. The main histopathological types in our cohort were mucosa-associated lymphoid tissue (MALT) lymphoma, diffuse large B-cell lymphoma (DLBCL) and natural killer/T-cell lymphoma. In addition, 3 patients exhibited dissimilar pathological types of secondary OL compared to the previously diagnosed systemic lymphoma. The most common site of ocular and systemic involvement was the orbit and lymph nodes respectively, and most cases (54%) showed systemic involvement after the diagnosis of OL. Besides, the 5-year overall survival rate of 54 patients with treatment information was 58%. Significant differences were observed among the three main pathological types, MALT lymphoma was associated with the highest OS rate, followed by DLBCL and NK-TL ( $p < 0.0001$ ). In addition, the OS rates were higher for Ann Arbor stage I/II versus stage III/IV patients ( $P = 0.03$ ). At the final follow-up, 20 patients (37%) had achieved complete remission, 12 (22%) were alive with disease. One representative case of a patient with double expressor DLBCL achieved complete remission and visual recovery after prompt diagnosis and treatment.

**Conclusion:** OL with systemic involvement is a relatively rare disease with poor prognosis. Although the disease is usually associated with a more aggressive pathological type of lymphoma, indolent lymphoma is not uncommon. In addition, for patients with a history of lymphoma, the relapsed OL may have a distinct pathological type. Therefore, we recommend prompt excision biopsy of ocular mass and systemic evaluation for all patients diagnosed with OL. The prognosis of OL with systemic involvement depends on the pathological type and disease stage. Even for highly malignant lymphoma, prompt diagnosis and treatment may lead to good visual and survival outcomes.

P-275

**Pregnancy and Plaque Brachytherapy Treatment of Uveal Melanoma : A Retrospective Study**H Wu<sup>1</sup>, Y Liu<sup>1</sup>, W Wei<sup>1</sup>.<sup>1</sup>*Ophthalmology , Beijing Tongren Hospital, Beijing, People's Republic of China*

**Objective:** To examine whether pregnancy affects the prognosis of uveal melanoma (UM) patients undergoing plaque brachytherapy (PBT) and if PBT has any effect on the outcome of such pregnancy.

**Methods:** We conducted a single-center retrospective study at the Beijing Tongren Hospital on the population of women with childbearing age who were diagnosed with uveal melanoma and underwent plaque brachytherapy. The outcome of each pregnancy and the status of the fetus was followed-up. Survival analysis were performed using Kaplan-Meier method, with the metastasis and death as endpoints.

**Results:** 13 patients with 13 full-term pregnancies and 96 non-pregnant women with matched age and tumor size were included. In pregnant group, two patients developed metastasis, one of which died shortly after delivery; local recurrence of UM occurred in 2 patients after or during delivery, and 2 other patients developed secondary glaucoma due to radiation retinopathy. None of the other pregnant patients reported any signs of disease progression. In the control group, 18 metastasis cases including 12 deaths were documented. Pregnant patients and matched control subjects showed no statistical difference in both Metastasis-free survival (hazard ratio (HR): 0.66, 95% confidence interval (CI): 0.15-2.86;  $P=0.576$ ) and overall survival (HR: 0.48, 95% CI: 0.06-3.66;  $P=0.464$ ). All pregnant patients carried the pregnancy to term and delivered healthy babies with no report of placental or infant metastases to date.

**Conclusion:** Pregnancy exerted no adverse effects on the prognosis of UM patients who receive PBT. While PBT had no significant effect on maternal fertility, and did not show teratogenic effect on the fetus so far, long-term effects require further follow-up studies.



P-276

**Thymidine kinase 1 drives skin cutaneous melanoma malignant progression and metabolic reprogramming**L Lu<sup>1</sup>, S Zuo<sup>1</sup>, H Wang<sup>1</sup>, L Li<sup>1</sup>, H Pan<sup>1</sup>.<sup>1</sup>Ninth People's Hospital, Shanghai Jiao Tong University School of Medicine, Shanghai, People's Republic of China

**Objective:** Thymidine kinase 1 (TK1) is a cell cycle-dependent kinase that catalyzes the addition of a gamma-phosphate group to thymidine. The pro-tumorigenic role of TK1 has been reported in various malignancies. However, the role of TK1 in skin cutaneous melanoma (SKCM) remains unclear. This study aimed to explore the molecular function of TK1 in SKCM progression.

**Methods:** Bioinformatics data were acquired from the Cancer Genome Atlas (TCGA) and Gene Expression Omnibus (GEO). Subcutaneous xenografts were established to observe the effect of TK1 knockdown on the proliferation of SKCM cells *in vivo*. RNA sequencing and immunoprecipitation mass spectrometry (IP-MS) were used to analyze TK1-related genes and pathways. Seahorse XFe96 Cell Mito tests and glycolysis stress assays were conducted for metabolic testing.

**Results:** TK1 was upregulated in malignant SKCM compared to that in normal tissues and cell lines. Elevated expression of TK1 was associated with poor prognosis. *In vitro* and *in vivo* assays demonstrated that TK1 promoted the proliferation and migration of SKCM cells. Moreover, TK1 was strongly associated with multiple intracellular metabolic pathways, facilitating cell mitochondrial respiration and glycolysis in SKCM malignant progression.

**Conclusion:** TK1 drives SKCM malignant progression and supports metabolic reprogramming, indicating that TK1 serves as a therapeutic target for SKCM.

P-277

## Ultrasound-Augmented Nano catalytic for Ferroptosis-Apoptosis Combined Anticancer Therapy of metastatic uveal melanoma

Q Wang<sup>1</sup>, J He, M Zhou<sup>2</sup>.

<sup>1</sup>School of Medicine, & Institute of Translational Medicine, Zhejiang University, <sup>2</sup>School of Medicine, & Institute of Translational Medicine, Zhejiang University, Hangzhou, People's Republic of China

**Objective:** Uveal melanoma is one of the most common primary intraocular malignant tumors. In this study, we developed a novel nanosystem named FeP nanoparticles (BSA@GA-Fe(III)@PTX@IR780). The purpose of the research is to explore whether ultrasound-augmented nanoparticles can realize the co-delivery of paclitaxel (PTX) and Fe(III) to achieve a synergistic anti-tumor effect of chemotherapy/ferroptosis/ultrasound on uveal melanoma (B16F10) in situ tumor exploration and distant metastasis.

**Methods:** The particle size and Zeta potential and the mass fraction of each substance in FeP NPs was tested. The cytotoxicity and molecular pathway were observed by CLSM, flow cytometry analysis, metabolite detection and immunofluorescence staining. The bio-distribution of FeP NPs in tumor-bearing mice was observed by *in vivo* imaging. The anti-tumor activity of FeP NPs+US *in vivo* was detected by in situ uveal melanoma tumor model. The growth of ocular tumors in situ, the tumor metastasis of cervical lymph nodes and lung tissues were evaluated, and immunohistochemical staining experiments were conducted to clarify the anti-tumor growth and metastasis effects of FeP NPs *in vivo*. The safety of FeP NPs was discussed by blood tests and H&E of the main organs *in vivo*.

**Results:** Laser confocal and flow cytometry showed the noticeable physiological and morphological changes of ferroptosis in melanoma tumor cells, including a significant increase in intracellular divalent iron content and glutathione depletion, excess production of ROS, and LPO. Molecular biological tests showed that FeP+US could inhibit GPX4 and system XC signal pathways in tumor cells and activate intracellular LPO signal pathways. Animal experiments *in vivo* and immunohistochemical staining of tumor tissue showed that the intraocular tumors were significantly reduced, and the metastasis of cervical lymph nodes and lungs was significantly improved.

**Conclusion:** Overall, we confirmed the excellent therapeutic effect of FeP NPs activated by ultrasound against uveal melanoma *in vivo* and *in vitro*. Animal experiments *in vivo* confirmed that ultrasound combined with FeP NPs could inhibit the production of metastasis-promoting nerve factor (NGFR) by uveal melanoma cells to inhibit the lymph node metastasis pathway of melanoma tumor cells and finally inhibit the distant lung metastasis. Our research is expected to make revolutionary progress in treating uveal melanoma and inhibiting distant metastasis.

P-278

### Choroidal Melanoma Treated with Fractionated Stereotactic Radiotherapy: Globe Conservation in Regions without Plaque Brachytherapy

R V Tanchuling<sup>1</sup>, A Martin<sup>1</sup>.

<sup>1</sup>Eye Institute, St. Luke's Medical Center, Quezon, Philippines

**Objective:** Historically deemed radio-resistant, choroidal melanomas have been primarily managed with enucleation; however, modern approaches now permit eye conservation and metastasis prevention, all while retaining useful vision. Stereotactic radiotherapy is standard, achieving excellent tumor dose delivery while attenuating doses for structures at risk. We report the outcomes of fractionated stereotactic radiotherapy, an eye-conserving modality, in a case of juxtapapillary choroidal melanoma, highlighting the viability of globe and sight-saving treatment in regions without access to plaque brachytherapy, furthering interdisciplinary collaboration.

**Methods:** A 60 year- old female presented with a one year history of progressive unilateral blurring of vision to hand motions before developing photopsias. Examination revealed a large elevated, pigmented subretinal mass obscuring the disc with vitreous hemorrhage and exudative retinal detachment. Juxtapapillary choroidal melanoma was confirmed by B scan ultrasound, showing a button-shaped mass with low-moderate echoes and choroidal excavation, measuring 13mmx13.81mm, abutting the nerve. Systemic workup was negative for metastasis. Due to proximity to the optic nerve and availability, stereotactic radiotherapy of 45 Gray was done in three fractions of 15 Gy following tumor mapping and dose calculation with a radiation oncologist.

**Results:** Treatment with fractionated doses of stereotactic radiotherapy delivered using a linear accelerator system resulted in local control and continuous tumor regression. Repeat B scan measurements at three and nine months post-therapy revealed a decrease in tumor thickness to 10.34 mm and 8.69 mm, respectively, achieving a 33.1% tumor thickness reduction at 9 months post-treatment. A gradual and progressive increase in internal reflectivity was also noted during these serial B scan examinations. Vision at nine months was retained at hand motions.

**Conclusion:** Linear accelerator- based fractionated stereotactic radiotherapy provides excellent local control and tumor regression in choroidal melanomas. This renders support to studies engendering fractionated irradiation as a well-tolerated procedure that can be offered for medium-large or unfavorably-located melanomas in patients who desire globe conservation, serving as a precedent for collaboration with radiation oncologists for future globe salvage therapies in areas without access to plaque brachytherapy.

P-279

## FROM PROSTATE TO PROPTOSIS- ORBITAL APEX SYNDROME CAUSED BY SPHENOID BONE METASTASIS FROM PROSTATIC CARCINOMA

A Ahmad.

**Objective:** The aim of this report is to emphasize an early and accurate clinical acumen would result in visual preservation and ocular salvage.

**Methods:** This is a case report.

**Results:** Prostate cancer is the second most commonly diagnosed cancer among men worldwide. Orbital metastasis especially bony involvement is one of the recognised features but rarely causing orbital apex syndrome (OAS).

A 78-years old Chinese man with underlying Prostate cancer underwent surgical resection in 2019, presented to ophthalmology team with a complain of left unilateral droopy eyelid associated with reduce vision and colour perception. There is also a presence of unilateral axial proptosis on patient's left eye. On top of that he also had limited ocular movement on all gaze over his left eye. Posterior segment examination revealed optic disc swelling with choroidal folds. Urgent CT-brain shows metastatic skull lesions with involvement of the left intraconal space and partially displaced optic nerve. He was then subsequently referred again to the Oncology team for the radiotherapy treatment together with systemic corticosteroid. After a completion of 1 week session of radiotherapy together with systemic corticosteroid , his symptoms was improved.

**Conclusion:** Orbital wall metastasis can cause devastating orbital apex syndrome. Early recognition with prompt treatment provides meaningful chance to save the visual function and quality of life in this group of patient.

P-280

### Orbital Metastasis of Diffuse Large B-cell Lymphoma

K Madhuri<sup>1</sup>, V Gurunadh<sup>1</sup>, K Satish.

<sup>1</sup>Ophthalmology, GSL Medical College, Rajahmundry, India

**Objective:** Metastasis in the orbit is commonly seen in breast and bronchogenic malignancies. However about 5% of all Hodgkin's lymphoma cases and 2.4 % Of NHL can show orbital extension.

**Methods:** A 39 years old male presented painless diminution of vision in left eye of one week duration. Ocular examination revealed ptosis left eye, axial proptosis with restriction of eyeball movements in all gazes of the left eye. Visual acuity was reduced to perception of light with inaccurate PR. Anterior segment examination was WNL except for a mid-dilated sluggish pupil. Fundus examination was found to be normal. Right eye examination was normal. Intra-ocular Pressure was 14 mm Hg applanation both eyes. Patient had a swelling in right axillary region of seven months duration. Examination of the same revealed a 12 x 10 cm firm, fixed, mild tender and matted mass near right axilla with palpable left supraclavicular and axillary lymph nodes. Oral and rhino-laryngeal examination was WNL. Splenomegaly was noted. Both testes were WNL. CECT neck, chest, abdomen showed lymph nodes in right lung and upper lobe of left lung, multiple bilateral axillary lymph nodes (largest: 11 x 6.9 x 10 cm), multiple abdominal lymph nodes, few peritoneal nodules and a 4.5 x 2.5 cm soft tissue lesion abutting right iliac bone. Biopsy of right axillary lymph node revealed Non-Hodgkin's Lymphoma. Leucocyte Common Antigen (LCA) and CD20 were positive. Bone Marrow Aspiration was normal. Immunohistochemical stains showed positive CD20, CD10, BCL 6 and Ki67 value of 50% and interpreted as High grade DLBCL-GCB type. Due to orbital involvement, the final diagnosis was Stage IV diffuse large B-cell lymphoma [DLBCL].

**Results:** Patient was started on chemotherapy. After 3 cycles, axillary mass decreased in size with improvement of proptosis.

**Conclusion:** Lymphoma being aggressive metastatic tumor can show metastasis to extra nodal tissues and rarely to the orbits. Chemotherapy treats the ocular metastasis also.

P-281

**Intra-arterial Chemotherapy for Retinoblastoma**H *Makhdoum*<sup>1</sup>, *S Albadawi*, H *Almuhammad*<sup>2</sup>.<sup>1</sup>*ophthalmology*, <sup>2</sup>*Taibah University, Madinah, Saudi Arabia*

**Objective:** The aim of this article was to review the role of intraarterial chemotherapy in the management of retinoblastoma and its clinical outcomes. In addition, we will review the possible complications of the procedure.

**Methods:** Multiple databases were used to collect articles relevant to our research objectives by reviewing the title and abstract of each article. Irrelevant articles and those that did not meet the inclusion criteria were excluded. This yielded a total of 19 studies.

**Results:** The results indicated that intraarterial chemotherapy is an effective and new modality of treatment for retinoblastoma to salvage the globe and help in the prevention of enucleation with minimal local and systemic complications that are mostly transient.

**Conclusion:** In conclusion, IAC is an effective and new modality of treatment for retinoblastoma to salvage the eyeball and helps in the prevention of enucleation with minimal local and systemic complications that are mostly transient. Although IAC is a complicated procedure, all studies revealed high salvage and success rates and low mortality rates, giving IAC an advantage over other modalities. For future work, we recommend conducting more prospective studies with large samples and long follow-up duration. Also, we recommend future studies focus on assessing visual acuity, as most of the currently available studies did not assess visual acuity, making the judgment on vision preservation with IAC difficult.

P-283

**Bilateral Orbital Metastasis in a case of Renal Cell Carcinoma – A Rare Presentation**

K Madhuri<sup>1</sup>, V Gurunadh<sup>1</sup>, K Satish.

<sup>1</sup>*Ophthalmology, GSL Medical College, Rajahmundry, India*

**Objective:** Renal cell carcinoma is the most common kidney cancer in adults. From the kidneys it can usually spread to lung, bone, lymph nodes, liver, adrenal glands and brain. Atypical metastasis to paranasal sinuses, nose, oral cavity, parotids, thyroid, eyes, skin, reproductive organs and skeletal muscles have been reported so far. Ocular metastasis is one of the rare presentations. Spread to the eye involves uvea more likely, but orbital metastasis is rarer, hence this presentation.

**Methods:** A 37 years old female, presented to OPD with protrusion of both eyeballs along with complaints of decreased vision, restriction of eye movements, redness, watering, discomfort and stickiness of a month's duration. Best corrected visual acuity was 6/12 in both eyes. There was marked restriction of left more than right ocular movement in all the gazes. There was bilateral non-axial proptosis (forward, downward and inward) and severe chemosis inferiorly. There was irregular soft non-tender mass palpable over the outer aspect of both upper eyelids, more in the left eye than in the right. Superior orbital rim of both the eyes can be palpated separately from the mass. Corneal sensations were reduced in both the eyes. Both pupils were reacting briskly to light. Fundoscopy showed established papilledema in both eyes.

**Results:** Patient was a known case of suspected renal cell carcinoma by PET CT was subjected to nephrectomy with renal cell carcinoma confirmed by histopathology of the resected specimen. MRI brain with orbits revealed bilateral extraconal masses in the orbits, most probably metastasis.

**Conclusion:** An unusual case of orbital metastasis in both eyes due to renal cell carcinoma following surgical excision.

**P-284****Sebaceous gland carcinoma of lid: a case series**M Kaur, A Ambroz Singh<sup>1</sup>.<sup>1</sup>SHKM GMC NUH, NUH, India**Objective:** To report a series of 3 cases of sebaceous gland carcinoma of eyelids.**Methods:** The cases presented with different presentations. Surgical excision was done and tissues were sent for histopathological examination which confirmed the diagnosis of sebaceous gland carcinoma. The patients were kept on MMC 0.02% eyedrops postoperatively and followed up.**Results:** One patient died in postoperative period likely due to other associated systemic disease.

2 patients are still under follow -up.

**Conclusion:** Sebaceous gland carcinoma is a rare tumor of the eyelids that can mimick many inflammatory and neoplastic lesions and hence the clinician to identify the tumor and institute early surgical therapy due to the aggressive nature of the tumor.



P-285

### Improvise to Conceptualize: Aids to Enhance Undergraduate Ophthalmic Teaching during Pandemic Era

A Onkar.

**Objective:** To outline the lesser used but useful technological aids to enhance undergraduate medical teaching during pandemics

**Methods:** Use of educational resources and tools like Whiteboard, Scribble/Sketch together, Breakout rooms, Waiting rooms, Telemedicine, WhatsApp videos was explored. Their utility for various components of teaching- conceptualization, case presentations, assessment and feedback is discussed

**Results:** Use of Whiteboards and Scribble/Sketch together like tools can help individualize the learning process and makes it more didactic. Judicious use of Breakout rooms for small group discussion and assessment is helpful. Live Quiz and Waiting rooms can make the assessment feasible and practical. Telemedicine can be utilised for patient interaction/history taking instead of paper cases for clinical history taking assessment. WhatsApp or similar modalities can be utilised for video transmission of case presentation and examination in real-time.

**Conclusion:** Pandemics warrant better use of technology in medical teaching. Improvisations make learning more receptive, interactive and non-monotonous. Interactive whiteboards, drawing boards, quizzes, telemedicine and real time videos can be used to refine online learning and assessment process.

P-288

**Application of multimedia computer-assisted "Internet +" teaching practice in fundus laser for retinal diseases**Z Chen<sup>1</sup>, J Shen<sup>1</sup>, L Zhang<sup>1</sup>.<sup>1</sup>*Ophthalmology, Second Affiliated Hospital, School of Medicine,, Zhejiang University, hangzhou, People's Republic of China*

**Objective:** Aiming at the main problems existing in the teaching process of fundus laser for fundus diseases in ophthalmology in China, our center explore a multimedia computer-assisted "Internet +" teaching practice model.

**Methods:** The experimental control method was used in this study. After completing the 4-week fundus laser teaching, the two groups of residents were examined and investigated by questionnaire, and the survey results were statistically analyzed.

**Results:** The mastery of theory and skills in the experimental group was significantly better than that in the control group, and the satisfaction and recognition with teaching was higher.

**Conclusion:** Multimedia computer-assisted online and offline teaching model is an effective way to promote the standardized development of resident education and improve the quality of education, which has a certain promotion significance.

P-289

### Evaluation of ophthalmology residents concerning intraocular lens power calculating methods

S Ben Aoun<sup>1</sup>, R Maamouri<sup>1</sup>, M Ouederni<sup>1</sup>, K Fekih<sup>1</sup>, F Nefaa<sup>1</sup>, M Cheour<sup>1</sup>.

<sup>1</sup>Ophthalmology department, Habib Thameur Hosiptal, Tunis, Tunisia

**Objective:** To evaluate the acknowledge and the current practices of resident group concerning intraocular lens (IOL) power calculating methods.

**Methods:** Online anonymous questionnaire sent out per e-mail to 112 Tunisian ophthalmology residents from all different educational levels (1st to 5th year) between 1<sup>st</sup> January 2022 and 1<sup>st</sup> April 2022. The survey had 20 items divided in two sections. The first section aimed to evaluate their previous acknowledge. The second one evaluates the current practices and the future perspectives. Data were analyzed using SPSS 21.0.

**Results:** Forty-two ophthalmology residents were included. The rate of received answers was 37% (42 completed questionnaires). Of the participants 78.6 % were female, 21.4 % were male. The mean age was 28 years  $\pm$  3 years. Only 21.4% had academic training concerning IOL power calculating methods. For the first section, 53.8% of the acknowledge questions were responded correctly. For the second section, 50% to 78.6% of residents consider that the main reasons for post-surgery refractive errors are respectively incorrect calculating formulas and absence of verification of IOL powers before surgery. More than  $\frac{1}{2}$  of residents tried to adapt calculation formulas with axial length, astigmatism and IOL features. 92.9% of residents are willing to improve their acknowledge and their competences and introduce new calculating tools such as the "surgeon-induced-astigmatism".

**Conclusion:** Evaluation and continuous education for surgeons and new residents is essential to minimize refractive errors. Despite, the poor rates of academic trainings concerning IOL power calculating methods, the Tunisian residents seem to be willing to improve their competences.

**P-291****An Audit of the Real World Use of Electro Diagnostic Testing**A Cheema, V Nowak.

**Objective:** Ocular Electro Diagnostic Tests (EDTs) are invaluable tools in ophthalmic clinics and practice. The aim of this audit was to assess use of EDT in aiding diagnosis of visual problems at a District General Hospital in England.

**Methods:** Data over a 16-month period was collected and analysed for a combination of 44 paediatric and adult patients. Reasons for patients' referrals to EDT were compared with outcomes of the referrals.

**Results:** This audit suggests that electrodiagnostic investigation made a useful contribution to the diagnosis, overall investigation, and management. In most adult patients a probable diagnosis made on clinical grounds was confirmed or a possible diagnosis excluded.

**Conclusion:** The data in the paediatric group is too small to make any conclusions.

P-292

**The global extent of undetected glaucoma in adults: A systematic review and meta-analysis**

Z Soh<sup>1</sup>, M Yu<sup>1</sup>, B Betzler<sup>2</sup>, S Majithia<sup>1</sup>, S Thakur<sup>1</sup>, Y Tham<sup>1</sup>, T Wong<sup>1</sup>, T Aung<sup>1</sup>, D Friedman<sup>3</sup>, C Cheng<sup>1</sup>.

<sup>1</sup>Singapore Eye Research Institute, <sup>2</sup>National University of Singapore, Singapore, Singapore, <sup>3</sup>Harvard Medical School, Boston, United States

**Objective:** Glaucoma is the leading cause of irreversible blindness despite having good prognosis with early treatment. In this study, we evaluate the global extent of undetected glaucoma and the factors associated with it.

**Methods:** We conducted a systematic review and meta-analysis of population-based studies published between January 1, 1990 to June 1, 2020. Article search was conducted in online databases (PubMed, Web-of-Science), grey literatures (opengrey) and non-government organization (NGOs) reports. Our outcome measure was the proportion of glaucoma cases that were undetected previously. Manifest glaucoma included any form of glaucoma reported in the respective study and may include primary-open-angle-glaucoma (POAG), primary-angle-closure-glaucoma (PACG), and/or secondary glaucoma. Undetected glaucoma was defined as glaucoma cases that were undetected prior to diagnosis in the respective study. Random-effect meta-analysis was used to estimate the pooled proportion and factors associated with undetected glaucoma. We followed the *Preferred Reporting Items for Systematic Reviews and Meta-Analyses* (PRISMA) and *Meta-analysis of Observational Studies in Epidemiology* (MOOSE) guidelines in our study conduct.

**Results:** We identified 61 articles from 55 population-based studies (N= 189,359 participants; N= 6,949 manifest glaucoma; N= 5,558 undetected glaucoma). Globally, more than half of all glaucoma cases were previously undetected in each geographical region. This ranges from 59.09% (95% CI 48.63, 68.79) in Oceania to 83.94% (95% CI 78.02, 88.50) in Asia and 94.13% (95% CI 91.24, 96.11) in Africa. Regionally, Africa (OR 12.70, 95% CI 4.91, 32.86) and Asia (OR 3.41, 95% CI 1.63, 7.16) had higher odds of undetected glaucoma as compared to Europe. Countries with low human development index (HDI, <0.55) had higher proportion of undetected glaucoma as compared to countries of medium, high, and very high HDI ( $\geq 0.55$ , all P <0.001). In 2020, 43.78 million POAG cases were undetected, of which 76.7% reside in Africa and Asia.

**Conclusion:** Undetected glaucoma is highly prevalent across diverse communities worldwide, and more common in Africa and Asia. Strategies to improve detection are needed to prevent excess visual disability and blindness due to glaucoma.

P-293

**The prevalence, clinical and topographic characteristics of keratoconus in young men population in Azerbaijan.**S Huseynli.

**Objective:** To analyse prevalence, clinical and topographic characteristics of keratoconus in young men population in Azerbaijan

**Methods:** In this study, the prevalence of keratoconus was analyzed among 20050 young men aged 17-35 years ( $22,1 \pm 4.8$ ), with various ocular pathologies who attended to the National Ophthalmology Center named after academician Zarifa Aliyeva, from January 2016 to January 2018. Clinical and topographic characteristics of the disease was studied. In addition to full ophthalmologic examinations, young people were involved in a detailed Sheimpflug tomography (WaveLight® ALLEGRO Oculyzer (Alcon, USA)) examination and severity, morphology, and cone location were extracted by analyzing the corneal imaging maps.

**Results:** The prevalence of keratoconus was 3,18% (n =638) (95%, CI 2.6-3.8). Bilateral KCN was detected in 92,3% [n=589] (95%, CI 90,7 - 94,8) of the subjects. The highest frequency of keratoconus was seen in the age group of 20-24 - 45,53% (95 CI: 42,8-48,1), then in the age group 17-20, 26-29, and 30-35 years - 35,64% (95 CI:33,21-38,2), - 10,5%(95 CI:8,12 – 13,2), 8,32%(95 CI: 6,1-10,8), respectively.

The frequency percentage of keratoconus according to severity from Sheimpflug tomography was 27,1% (95%, CI 25,2-29,88), 27,6% (95% CI: 25,1-29,92), 22,3% (95%CI: 19,9-24,7), 17,7% (95 CI: 15,6-19,9) and 1,7% (95%CI: 1,0-2,4) for subclinical, I, II, III and IV stages of KC, respectively. Most of the patients had early and mild keratoconus ( $p < 0,001$ ).

From topomorphological sign 45,1% (95% CI: 41,1-49,3), 53,6 % (95% CI:49,2-57,5), and 1,1 % (95% CI:0,7-1,9) of the cases had nipple, oval, and globus cones, respectively. The cone was central in 46,6% (95%CI: 41.10-53.11), paracentral in 43.5% (95%CI:38.1 -51.04), and peripheral in 9,8% (95%CI: 6,8-13,2) of the cases.

**Conclusion:** The results show that keratoconus is not a rare disease in the young male population, making it necessary to screen for the disease at an earlier stage. Timely monitoring and choosing the right treatment protocols will help prevent the progression of the disease in young men and thereby preserve visual functions.

P-294

**An integrated community-hospital model for diabetic retinopathy screening to achieve early diagnosis and treatment**Y Li, H Wang, W Huang.

**Objective:** Diabetic retinopathy (DR) is one of the most common eye diseases that cause blindness among patients with diabetes mellitus (DM). With the growth of the incident rate of DR, primary ophthalmic screening is necessary for early DR diagnosis and treatment. The Ophthalmologist Medical League is a screening model implemented to refer DM patients from community health center to specialist for retinal screening. This study aimed to explore the prevalence of DR and its risk factors in a diabetic screening cohort referred from eighteen community health center (CHCs) to DR care in a specialist care center in Guangzhou, China.

**Methods:** A total of 3064 adults aged 40-80 with newly diagnosed DM from eighteen CHCs in Yuexiu District, Guangzhou were enrolled at baseline. Patients were then referred to the Zhongshan Ophthalmic Center for comprehensive ophthalmological examinations. The prevalence of DR was identified by the ETDRS-7-field retinal photographs and the grading scheme. Number of referred cases were also calculated to evaluate the effectiveness of the community-hospital screening model. Chi-square test and multiple logistic regression analysis were used for data analysis.

**Results:** Of 3097 appointed patients, 3064 (99.1%) accepted for screening. Overall, 17.8%(n=547) patients with any DR. The prevalence of NPDR was 17.1% (n=524), of which mild NPDR and severe NPDR were 9.7%(n=297) and 1.9%(n=57). The prevalence of SPDR was 0.8%( n=23) . Patients screened with high risk were directly referred to specialist for immediate treatment, moderate risk were advised for regular ophthalmic examination. Those with low risk were not referred but were given lifestyle advices only. Significant predictors of any retinopathy were longer duration of diabetes, being on treatment for hypertension, and use of diabetic medication ( $P<0.001$ ).

**Conclusion:** Referral from community care to specialist care for initial DR screening may provide early prevention and treatment implications for type 2 DM management.

P-295

### Features of the Tear Secretion of the Eyes of the Population in Turkmenistan

S Amansahedov, G *Gurbanova* .

**Objective:** To study the condition of the tear secretion of the eyes of schoolchildren, as well as students and employees of the Oguz Han Engineering and Technology University of Turkmenistan.

**Methods:** In this work 1083 volunteers were examined. Among them, 613 (57%) are women and 470 (43%) are men. By age group, 128 of the volunteers were aged 6-16, 747 aged 17-23, 97 aged 24-30 and 111 aged 31-65. Turkmenistan is located in Central Asia and has a dry, sharply continental climate. The research was carried out in autumn. The assessment of tearing was determined by the method of questioning and the Schirmer test.

**Results:** The results showed that function of tearing in 554 people was at the level of 15 mm and above (51%) according to Schirmer tear strips, in 207 by 9-14 mm (19%) and in 322 people it was 8 mm or less (30%). The level of tearing of 15 mm and above was found in 46% of the women, and in 58.3% of the men, an indicator equal to 9-14 mm is equally common among both sexes. The level of tearing 8 mm and below was 35% in women and 22.3% in men. The level of tear production in schoolchildren aged 6-16 years, the results  $\geq 15$ mm are noted in 65.62%, 9-14 mm in 30.46%, and the rate of 8mm and below is 3.92% of the examined children; in persons aged 17-23 years, results  $\geq 15$  mm are noted in 54.21% of people; 9-14 mm in 16.33% of people, and an indicator of 8 mm and below in 29.46% of the examined; in persons aged 24-30 years, results  $\geq 15$  mm are noted in 40.2% of people, 9-14 mm in 14.43% of people, and an indicator of 8 mm and below in 45.37%; in persons aged 31-65 years, results  $\geq 15$  mm are observed in 23.42% of people, 9-14 mm in 28.83% of people, and an indicator of 8 mm and below in 47.75% of those examined in this age category.

**Conclusion:** According to the study, the level of tearing of 15 mm and above occurs in 51% of the surveyed, the level of 9-14 mm was 19%, and the level of 8 mm and below was in 30% of the surveyed residents. It has been established that the level of tearing in women is markedly reduced compared to men. It was revealed that a decrease in tearing is also found among the examined children (3.92%). With increasing age, the risk of developing dysfunctional changes in the function of tearing of the eyes increases.



P-296

## Trends of Myopia Development Among Primary and Junior School Students in the Post-COVID-19 Epidemic Period

W Zhou, X Wang, Y Liao, H Chen, Q Li.

**Objective:** Investigating the trends of myopia among primary and junior school students in the Post-COVID-19 Epidemic Period.

**Methods:** A cross-sectional study using Spot photoscreenings in 123,538 children among primary and junior school students from 2019 to 2021 was conducted to evaluate the development of myopia in Xuzhou, China in the Post-COVID-19 Epidemic Period.

**Results:** A total of 42918 students in 2019, 41964 students in 2020, and 38656 students in 2021 among primary and junior school students were included in this study. Except for grade 1 ( $0.24 \pm 0.63$  D in 2020,  $0.23 \pm 0.56$  D in 2019), refraction for other grades decreased to varying degrees from 2019 to 2020. The greatest decrease in SER was seen in grades 3 to 5 and 7 to 9 ( $P < 0.001$ ). However, the refraction were hyperopia shift in 2021 compared 2020 for grades 1-5. The prevalence of myopia for all grades increased in 2020 compared to 2019 and the most dramatically change were seen from grades 2 to 5 and grades 7 to 8 ( $P < 0.05$ ). From 2020 to 2021, the changes in myopia rates in grades 1-4 were mild and students in grade 5 had the greatest reduction in myopia. Nevertheless, students in grades 6 and 9 had the greatest growth in myopia prevalence ( $P < 0.05$ ). All grades had higher myopia rates in 2021 than in 2019, except grade 1 ( $P = 0.250$ ). The myopia rate of girls is higher than boys, and urban myopia rate is higher than rural over three years.

**Conclusion:** Myopia progression accelerated in students during the COVID-19 epidemic. However, partial reversal of myopia progression in the lower grades occurs in Post-COVID-19 epidemic period, and slow myopia progression in the upper grades compared to 2020. We should be more concerned about the progression of myopia in graduating grade in the future.

P-297

### Choroidal and Retinal Thickness of the Population in Ejin with Different Refractive Status

X Wu.

**Objective:** To explore the effect of different refractive status on the choroidal and retinal thickness of the population in Ejin, including myopia, emmetropia, and hyperopia.

**Methods:** We performed a cross-sectional study of 1092 participants with different refractive status in Ejin, Inner Mongolia, China. Each participant underwent comprehensive ophthalmic examinations, including optometry, measurement of axial length and optical coherence tomography. The thickness of the choroid and retina was compared among participants with different refractive status groups.

**Results:** The mean central fovea choroidal thickness of all participants was  $247 \pm 63 \mu\text{m}$ . The mean central fovea choroidal thickness of myopes was  $226 \pm 61 \mu\text{m}$ , while the emmetropes' and hyperopes' were  $257 \pm 66 \mu\text{m}$  and  $281 \pm 69 \mu\text{m}$ , respectively. There was no statistical difference found between different refractive groups in the central foveal thickness of the retina. Refractive diopter was negatively associated with central foveal choroidal thickness ( $r = -0.63$ ,  $p = 0.03$ ). And axial length was negatively associated with central foveal choroidal thickness as well ( $r = -0.46$ ,  $p < 0.01$ ). The thickness of the central foveal retina increased with the intraocular pressure ( $r = 0.53$ ,  $p = 0.02$ ). Axial length was negatively associated with total retina thickness ( $r = -0.34$ ,  $p < 0.01$ ), ganglion cell layer ( $r = -0.35$ ,  $p < 0.01$ ) and inner nuclear layer ( $r = -0.46$ ,  $p < 0.01$ ). There was no statistical relevancy between central foveal retinal and choroidal thickness in myopes ( $p = 0.78$ ), emmetropes ( $p = 0.61$ ), or hyperopes ( $p = 0.63$ ).

**Conclusion:** Myopic participants in Ejin have a thinner choroid and a thinner retina in almost all parafoveal (radius 1000 and 2000 $\mu\text{m}$ ) regions. However, there was no significant difference in the thickness of retina, ganglion cell layer, inner nuclear layer and outer nuclear layer among people with different refractive states in the first parafoveal circle (radius 500 $\mu\text{m}$ ). There was no statistical relevancy between central foveal retinal and choroidal thickness. While, refractive diopter and axial length were associated with central foveal choroidal thickness. Intraocular pressure was associated with central foveal retinal thickness.

P-298

## Prevalence And Pattern Of Ocular Morbidities Among Children In Public Primary Schools In Badagry, Lagos State, Nigeria.

I Saliu.

**Objective:** To determine the prevalence and pattern of eye morbidities among public primary school pupils aged 5-12years in Badagry Local Government Area of Lagos State, Nigeria, for planning school eye health in these communities.

**Methods:** It was a descriptive, cross-sectional study carried out in 11 public primary schools in Badagry Local Government Area (LGA), Lagos State, Nigeria. Ethical approval obtained from the Health Research Ethics Committee of Lagos University Teaching Hospital and tenets of Helsinki declaration adhered to during the course of study. A multi-staged sampling technique was used to select the pupils. Approval and permission obtained from the Local Government Education Authority, Badagry, Lagos State. Pupils who consented were registered, interviewed and their eyes were examined. Data analyzed with Epi Info (Version 7.0.1.4.) according to age, gender, class, and type of ocular disorders. Median and interquartile range of age, frequency and percentages were calculated. Graph pad Instat and WinPepi Version 11.60 were used to test statistical significance at  $P < 0.5$ .

**Results:** The study group consisted 1381 school pupils, 792 (57.3%) boys, 589 (42.7%) girls with male: female ratio of 1.35:1, median age of 10 years and interquartile range of 4. Coverage rate was 99.8%. A total of 22 teachers took part in the visual acuity training. Ocular disorders found in 636 (46.1%) pupils. The pattern of ocular morbidities was refractive errors 41.0%, vernal conjunctivitis 33.8%, glaucoma suspect 17.3%, phthisis bulbi 1.7%, cataract 1.3%, optic atrophy 1.1%, corneal opacity 1.0%, esotropia 0.8%, oculocutaneous albinism 0.8%, measles keratopathy 0.6%, macular scar 0.3%, and ptosis 0.3%. The prevalence and pattern of anatomical structure involved are globe 43%, lid/conjunctiva 34.1%, optic nerve 19.1%, cornea 1.6%, lens 1.3%, and retina 0.3%

Of the 2.8% blindness, 42.1% due to trauma, with 55.2% either preventable or treated. Corporal punishment related eye injury was the commonest cause of monocular blindness secondary to trauma. Living close to coastal areas may be a significant risk factor for vernal conjunctivitis.

**Conclusion:** This study showed that early detection from regular eye screening was important and necessary. Corporal punishment should be avoided at least from sensitive organs, like the eye to avoid preventable blindness. Health education and access to a quality eye care facilities will decrease the burden of eye disease and blindness among rural Nigerian children.

**P-299****Psychological Reactions among Staff of a Tertiary Eye Hospital in Eastern Nepal during COVID-19 Pandemic**

P Joshi, R *Gautam Joshi*<sup>1</sup>, P *Shrestha*, P *Subedi Basnet*, P *Mahat*.

<sup>1</sup>*Psychiatry, BP Koirala Institute of Health Science, Dharan, Sunsari, Nepal*

**Objective:** The objective of this study was to find out depression, anxiety, stress and insomnia among Mechi Eye Hospital staff

**Methods:** A web based cross-sectional study among Mechi Eye Hospital staff was done from 1st to 20th July 2020. Insomnia Severity Scale and DASS-21 were used.

**Results:** Out of 220, 190 (86.6%) participated, 63.2% were female and 61.05% were medical staff with an overall mean age of  $31.1 \pm 8.4$  years. Overall prevalence of anxiety, depression, insomnia and stress were 20.5%, 18.9%, 16.3% and 12.6% respectively and those were common in female with 63.9% (p value <0.02), 64.1% (p value 0.5), 58.4% (p value 0.2) and 100% (p value <0.01) respectively. Depression, anxiety and insomnia were common in the age group 30-39 years (50%, p value < 0.02), 20-29 years (56.4%, p value 0.1) and 20-29 years (70.9%, p value 0.8) respectively. Stress was common in 20-29 years and 30-39 years, 45.8% each (p value <0.03). Depression (75%, p value 0.2), anxiety (71.7%, p value 0.9) and stress (70.8%, p value 1.0) were common in medical staff. Insomnia was present in medical staff only (p value <0.01).

**Conclusion:** Mechi Eye Hospital staff had greater prevalence of psychological reaction than the national baseline during the pandemic which was more common in female, younger age and medical staff.

P-301

### Bacterial isolates from the conjunctiva, storage cases and mobile phones of university students using contact lenses.

W Al Momani<sup>1</sup>, L Abu-Ismaïl<sup>2</sup>, S Jankat<sup>3</sup>, W Shihadah<sup>4</sup>.

<sup>1</sup>Department of Basic Medical Sciences, Faculty of Medicine, <sup>2</sup>Department of Clinical Medical Sciences, Faculty of Medicine, Yarmouk University, <sup>3</sup>Department of Nutrition and Food Technology, <sup>4</sup>Department of Special Surgery, Jordan University of Science and Technology, Irbid, Jordan

**Objective:** To investigate the presence of bacterial pathogens on the palpebral conjunctiva, mobile phones, and storage cases of contact lens wearers to study any possible correlation between types of bacteria isolated from the 3 sites and to determine their antibiotic profiles.

**Methods:** One hundred and eighty nine swabs from the conjunctiva, mobile phones, and storage cases were collected from 63 contact lens wearing university students. The swabs were collected and transported to the microbiology laboratory within one hour and inoculated on nutrient agar, MacConkey agar, blood agar and mannitol salt agar. The subsequent bacterial isolates were identified by their cultural, morphological and biochemical characteristics.

**Results:** Nine bacterial species were isolated and identified in the current study namely: Staphylococcus aureus, Streptococcus pyogenes, Enterococcus faecalis, Shigella dysentery, Pseudomonas aeruginosa, Proteus mirabilis, Citrobacter spp., Klebsiella pneumoniae and Escherichia coli. Nine (26%) mobile phone and 7 (21%) conjunctival samples were contaminated with five different bacterial species. The highest level of contamination was detected in contact lens storage cases where 18 (52%) bacterial isolates were detected in cases.

**Conclusion:** The storage cases and mobile phones of contact lens wearing university students were highly contaminated with pathogenic bacteria and may act as a carrier for the transmission of such bacteria to the eye causing eye infections which can be controlled by proper hygiene and using effective disinfectant for storage cases. Pathogenic bacteria were detected with multiple antibiotic resistance indices.

P-304

**Haemolacria: myth and substance**Y Huseva, A Harrison.

**Objective:** to investigate the content of tears to determine the presence of latent blood within the timeline of the female menstrual cycle.

**Methods:** Tear samples from 72 women were studied with the microscopy of tears aspirated with a capillary and stained by Nocht and with a chemical method of test strips with chromogen. Statistical data processing was carried out using packages Statistica 10.0 for Windows, calculation of Pearson's chi-square test, Yule association coefficient, the method of determining sensitivity and specificity.

**Results:** In 30.6% of tear samples erythrocytes were revealed microscopically against 16.7% determined chemically. The prognostic significance of the chemical method was 0.53 of the microscopic one. Correlations between the presence of erythrocytes in the tear and the phase of the menstrual cycle were determined. In the follicular phase erythrocytes were found in 59.1%, which was significantly more compared to 40.9% in the luteal phase of the cycle. Erythrocytes were predominant in the first seven days of the follicular phase consistent with the published incidence of vicarious bleeding from the mucous membranes of extragenital organs in synchronicity with menstruation. Other cells in tear samples with latent haemolacria were identified: neutrophils - in 45.5%, lymphocytes - in 27.3%. An association between latent haemolacria and endometriosis was determined ( $k=0.75$ ,  $p\leq 0.05$ ). Erythrocytes were microscopically detected in 70% of women with a confirmed diagnosis of endometriosis but only 25% in healthy women without it. The proportion of women with erythrocytes in tears determined chemically was 41.7% among patients with endometriosis, which was significantly more than 11.7% among women without it. In endometriosis erythrocytes were found against the background of accumulations of epithelial cells. In tears of women with endometriosis glandular cuboidal epithelial cells morphologically similar to endometrium were found.

**Conclusion:** Microscopic and chemical methods were informative in revealing latent haemolacria. The microscopic - was more sensitive and provided information about other cells, the chemical was faster and technically simpler, can be used as a screening tool. Individual erythrocytes can normally be found in the tears, their number depended on the phase of the menstrual cycle, increasing in the follicular phase. Erythrocytes found in tears together with epitheliocytes and their glandular atypia may indicate a manifestation of extragenital endometriosis.

P-305

**Experimental Study on Pharmacological Efficacy of Liposomal Quercetin in a Corneal Acid-Burn Injury Model**

G Fesiunova, Y Rodina, N Molchaniuk, G Abramova, H Tsybuliak.

**Objective:** To investigate the efficacy of liposomal quercetin (LQ) in different administration modes (topical eye drops, subtenon injection) in a second-degree acid-burn injury of cornea in rabbits.

**Methods:** In rabbits, an acid-burn injury of the cornea was induced by applying a 6-mm round filter paper disc to the cornea. The disc was previously soaked in 3% acetic acid solution with 5-second exposure under local anesthesia (0.4% cocaine). 21 rabbits were assigned to 3 groups, 7 in each group (Group I, II and III). Right eye of every rabbit was treated, the fellow eye was intact. Group I received two drops of saline solution and served as control. Group II received a subtenon injection of LQ, 1 mL every five days (3 injections). Group III received LQ topically; 2 eye drops three times a day until the complete disappearance of the inflammation signs. Treatment started on the next day after inducing an acid-burn injury. All eyes were examined with slit-lamp biomicroscopy. The intensity of the inflammation was assessed using the Draize test according to the condition of the cornea and conjunctiva. Pharmacological activity of the drug was calculated by the degree of inflammation intensity and the reduction of corneal opacity compared with baseline. After 14 Day, the animals were killed and the eyes were enucleated and examined with electron microscopy.

**Results:** Ophthalmic biomicroscopy showed that topical eye drops and subtenon injection of LQ (a) had pronounced anti-inflammatory and anti-edematous effects, (b) stimulated regenerative processes, (c) accelerated the restoration of corneal transparency. At Day 14, 7 eyes in Group II had cloud-like opacity sized  $\geq 3$  burn injury; 5 and 2 eyes in Group III had cloud-like opacity sized  $\geq 2$  and  $\geq 1$  burn injury, respectively; 7 eyes in Group I had cloud-like opacity sized  $\geq 1$  burn injury). The Draize test showed no inflammation signs in the anterior eye at Day 7, Day 10, and Day 14 in Groups II, III, and I, respectively, which indicated the pronounced effect of LQ. Electron microscopy showed that (a) topical LQ significantly decreased swelling in corneal structures, i.e. hyaloplasm and organelles; (b) LQ subtenon injections activated metabolic processes, which resulted in an increased number of organelles aimed at protein synthesis and energy production.

**Conclusion:** Study on the pharmacological action of LQ is a justification for its clinical trial for treatment of corneal burn injuries topically and/or subtenon injections.

P-306

### Comparison of POTS and OTS in Predicting Visual Blindness or Survival of Pediatric Ocular Trauma in a Tertiary Government Hospital

U Yap, J Cruz.

**Objective:** This study establishes the epidemiological characteristics and mechanisms of injury of pediatric patients with penetrating ocular injuries seen at a tertiary government hospital from 2017-2019. It also aims to determine and correlate the prognostic abilities of the Pediatric Ocular Trauma Score (POTS) by Acar and the Ocular Trauma Score (OTS) by Kuhn in the prediction of visual blindness and visual survival of pediatric ocular trauma cases.

**Methods:** Pediatric patients with penetrating ocular injuries with documented visual acuity upon consultation and on the 6th month of follow up were included in the study. The OTS and POTS were calculated for each patient. Their visual outcomes after 6 months were compared with their probable visual outcomes as predicted by the OTS and POTS.

**Results:** Penetrating ocular injuries were more common in males (74.1%) between the ages of 6-10 (48.1%). Injuries were predominantly accidental in nature (74.1%) and knives were identified as the implicated instrument in 33% of patients. Majority of the sample had a VA of light perception to hand movement (40.7%) at time of ER consultation. Among the POTS variables, initial visual acuity and presence of hyphema showed a statistically significant relationship with the final visual acuity ( $p=0.002$  and  $p=0.013$ , respectively).

In assessing whether the assigned OTS and POTS category was associated to the final visual acuity, both tools showed statistical significance with the final visual acuity ( $p=0.031$  and  $p<0.001$ , respectively).

The POTS had a slightly higher accuracy compared to OTS (78% vs 74%) in correctly identifying more visual survivals. The POTS also had a higher sensitivity value than OTS (72% vs 67%) in detecting more true visual survivals. Both the OTS and POTS had 89% specificity in recognizing visual blindness (NLP). In terms of predictive values, POTS had a slightly higher PPV and NPV. POTS had a 93% predictive capacity for visual survival and 62% for predicting visual blindness compared to the 92% PPV and 57% NPV of OTS. This means that POTS had higher predictive utility when compared to OTS.

**Conclusion:** Pediatric ocular trauma is a global health issue that significantly impacts the lives of this vulnerable population. These injuries are prevented simply through proper supervision by parents and caregivers. The POTS is an applicable tool in the prognosis of penetrating ocular injuries and is just as viable as the OTS as a predictor for visual blindness and visual survival in pediatric patients.



P-307

### Ocular trauma prevention with the use of Artificial intelligence (AI) for compliance improvement

V Preda<sup>1</sup>, T Carney<sup>2</sup>, M Wilson<sup>2,3</sup>, J Jabbour<sup>4</sup>.

<sup>1</sup>Faculty of Medicine Human and Health Sciences, Macquarie University, <sup>2</sup>SurgicalXR, <sup>3</sup>Hospital, Macquarie University, <sup>4</sup>Medical Retina, Sydney Eye Specialists, Sydney, Australia

**Objective:** To provide a potential application of artificial intelligence (AI) to detect personal protective eye-equipment (PPE), to reduce workplace ocular laser injuries.

**Methods:** Case presentation and discussion of an AI application to improve PPE compliance

**Results:** A 27 year old female laser technician developed blurred vision and floaters after an accidental workplace exposure to a YAG hair removal laser without using any PPE. On examination the visual acuity was 6/6 OD 6/24 OS. Fundoscopy revealed a left vitreous, subhyaloid, intraretinal and subretinal haemorrhage. The left superotemporal vein was widely dilated and encased in blood on OCT and associated with a large preretinal haemorrhage. A large left chorioretinal scar was noted at the site of accidental cosmetic laser exposure. Follow up confirmed slow resolution of the left subhyaloid and retinal haemorrhage. Further clearing of the vitreous haemorrhage as well as subjective improvement in her bilateral visual acuity to 6/6. To diminish the risk of ocular injury compliance with PPE is needed. Surgical XR AI-PPE platform detects PPE compliance and provides real-time remediation for validation and may be linked to the power supply on switch. This platform is a means of logging personnel entry and exit and their PPE status using AI rather than depending on human compliance.

**Conclusion:** Ocular trauma is a major workplace safety issue across multiple industries with potential for long term loss of vision and as well as economic sequelae. Community laser hair removal is common and ocular trauma has occurred with poor workplace safety. This case is an exemplar of the application of a validated AI system for the identification of PPE, where safety risk exists in the community.

P-308

**Prognosticating Value of Classification Tree And Regression Model on Patients with Open Globe Injuries**D Tomas-Esteban, C Arcinue<sup>1</sup>.<sup>1</sup>*Ophthalmology, Rizal Medical Center, Pasig City, Philippines*

**Objective:** Open globe injury (OGI) is a significant ocular condition; hence, prognosticating visual outcome is relevant for better planning and execution of management. This research is relevant as it highlights the role of Classification Tree and Regression (CART) Model in predicting vision survival in patients with OGI. The study determined the prognosticating value of the CART model by comparing the actual final visual outcome to the predicted visual outcome using the tree.

**Methods:** Retrospective review of 65 consecutive cases of open globe injuries during a two-year period was conducted at Rizal Medical Center. Accuracy of CART prediction was determined by computing the sensitivity, specificity, positive and negative predictive values. Area under the Receiver Operating Curve (AUC) was provided to check its discriminatory capability.

**Results:** Majority of patients had poor visual outcome with secondary cataract as the most common complication. Patients with good to poor visual outcomes were mostly managed with anterior segment repair, while those who had worst vision were enucleated. The sensitivity of CART was 100% while the specificity was at 77.8%. Overall accuracy was very high at 96.9% and AUC was 0.89.

**Conclusion:** Results showed high accuracy in discriminating vision survival (hand movement or better) from no vision (no light perception and enucleation). CART model may be a helpful tool in the stratification of patient's risk of losing vision and provides the patients and their families with valuable information regarding treatment decisions.

**P-311****Traumatic Lens Dislocation in an Eye with Anterior Megalophthalmos**H AlGhadeer.

**Objective:** Anterior megalophthalmos is a rare, bilateral, nonprogressive, hereditary, congenital disorder characterized by the enlargement of all anterior segment structures of the eye, with megalocornea, iris atrophy, and zonular abnormalities. We report a case of an 8-year-old male who presented to the emergency department with a history of visual loss after a blunt ocular trauma to the left eye.

**Methods:** Case report and review of the literature.

**Results:** The patient presented with markedly enlarged corneas and deepened anterior chambers bilaterally. Best-corrected visual acuity (BCVA) was hand motion in the left eye. An Additional examination revealed multiple anterior segment abnormalities, leading to the diagnosis of megalophthalmos and lens dislocation in the anterior chamber. The patient underwent a lensectomy and anterior vitrectomy in the left eye. At six months postoperatively, the BCVA was 20/200 in the left eye. Lens dislocation in patients with megalocornea is rare.

**Conclusion:** Cataract surgery in these patients requires attention to the zonular abnormalities and lens enlargement, resulting in increased rates of intraoperative and postoperative complications. Ophthalmologists should be able to diagnose this rare disorder and manage the associations and complications.

P-312

### Comparison of Prognosis of Non-trapdoor Orbital Blowout Fractures Repaired with Different Timing Operation

X Lin, R Zhou.

**Objective:** To compare the clinical effects of surgical repair of non-trapdoor orbital blowout fractures at different times.

**Methods:** This study is a retrospective analysis. The research subjects were selected from a total of 172 patients with non-trapdoor orbital blowout fractures who underwent surgical treatment in the ophthalmology department of a tertiary A-level hospital from July 2015 to January 2021. According to the different operation time, they were divided into early group ( $\leq 14$  days), middle group (15-30 days) and late group ( $> 30$  days), of which 85 cases (85 eyes) in early group and 57 cases (57 eyes) in middle group, 30 cases (30 eyes) in the late group. Main outcome measures: The best corrected visual acuity (BCVA), diplopia, disorder of ocular movement, proptosis, sensory dysfunction and complications before surgery and at 1, 3, 6, and 12 months after surgery in the three groups. SPSS23.0 statistical software was used for statistical analysis.

**Results:** Diplopia: there was no statistical difference between the three groups before surgery and 1 month after surgery, but there were significant differences between the three groups at 3, 6 and 12 months after surgery, by pairwise comparison, there was a significant difference between the early group and the late group. Disorder of ocular movement: There was no statistical difference between the three groups before surgery, and there were significant differences among the three groups at different time points after surgery. In comparison, there was no significant difference between the early group and the middle group, the middle group and the late group, and there was a significant difference between the early group and the late group. Exophthalmos: There was a significant difference between the three groups before surgery, and there was no statistical difference between the preoperative early group and the mid-term group, There was a statistical difference between the late group and early group, and There was a statistical difference between the late group and middle group.

**Conclusion:** For patients with non-trapdoor orbital blowout fractures, there was no significant difference in diplopia, disorder of ocular movement and ocular retraction between 14-day and 15-30-day surgical repair; About diplopia, movement of eye, and maxillofacial sensation, surgical repair within 14 days is superior to that after 30 days; effective fracture repair can be performed within 30 days of trauma.

P-313

**Demographic Characteristics Of Traumatic Hyphema In The Northeast Of Mexico.**

J Ramirez<sup>1</sup>, A Martinez<sup>1</sup>, J Mohamed<sup>1</sup>, J Mohamed<sup>1</sup>.

<sup>1</sup>*Ophthalmology, University Hospital and Faculty of Medicine, Autonomous University of Nuevo Leon (UANL), Monterrey, Mexico*

**Objective:** To describe the demographic characteristics of patients suffering traumatic hyphema in a northeastern Mexican population.

**Methods:** A retrospective cohort study of all consecutive patients with non-penetrating ocular trauma and hyphema or microhyphema (red blood cells in the anterior chamber not forming a layered clot) between January 2018 and May 2020 registered in the diary of daily consultation of the ophthalmology department of the University Hospital of the UANL and the SBAR diary (Situation, Background, Assessment and Recommendation) for patients who arrived at the emergency department. Demographic characteristics, mechanism of trauma, complications, and surgeries were recorded.

**Results:** Eighty patients were identified with non-penetrating ocular trauma and hyphema. The mean (SD) age of patients was 28.7 (15.7) years, with a predominance of males with 63 patients (79%). The most frequent mechanisms of trauma were punch injury in 24 patients (30%). The most frequent situations in which the trauma occurred were violence in 38 patients (48%), occupational accidents in 13 patients (16%), sports in 12 patients (15%), and home accidents in 8 patients (10%). Both eyes were affected, 45 patients (56%) in the left eye, 34 patients (43%) in the right eye and 1 patient (1%) in both eyes. Microhyphema was present in 15 patients (17%), and 75 patients (83%) presented hyphema. Twenty-two patients (17.6%) only had hyphema, and the rest had the following associated injuries: 28 (22.4%) retinal contusions, 12 (9.6%) orbital fractures, 8 (6.4%) eyelid wounds, 5 (4%) vitreous haemorrhages, 5 (4%) choroidal ruptures, 5 (4%) early intraocular hypertension, 3 (2.4%) traumatic cataracts, 3 (2.4%) subluxation of the lens, 2 (1.6%) cyclodialysis, 2 (1.6%) retinal detachments, and one optic neuropathy, one traumatic macular hole and one occult scleral rupture. Seventy-two patients (90%) required non-surgical treatments, and 8 patients (10%) required surgical treatment. The following surgeries were required: 2 cataract surgeries, 2 retinal surgeries, 2 eyelid surgeries, 1 glaucoma surgery, and 1 enucleation.

**Conclusion:** In this study, the majority of non-penetrating traumatic hyphemas were due to violence; the prevention of ocular trauma in this circumstance requires raising awareness in society about the ocular repercussions of violence, violence prevention programs, and education to the community about the importance of having an ophthalmic examination after traumatic injuries.

P-315

**A rare case of Bilateral Tolosa-Hunt Syndrome in a 10-year-old male child**J Abdon<sup>1</sup>.<sup>1</sup>*Ophthalmology, Vicente Sotto Memorial Medical Center , Cebu City, Philippines*

**Objective:** Tolosa-Hunt Syndrome (THS) is a rare condition that presents with ophthalmoplegia, periorbital pain, diplopia, and ptosis. It is believed to be caused by a granulomatous inflammation in the cavernous sinus, superior orbital fissure, or orbit. Bilateral involvement is rare.

We report a rare case of a bilateral THS in a 10-year-old male child presenting with a generalized headache, bilateral eye pain, diplopia, and ptosis.

**Methods:** Laboratory workup for infection, underlying autoimmune disease, vascular anomalies or tumors were done. The MRI of the orbits showed evidence of bilateral orbital fat stranding and mild perineural enhancements. Intravenous Methylprednisolone (1mg/kg/day) was given for a total of 3 doses with a proton-pump inhibitor, and was monitored daily. He was shifted to oral Prednisone at 1mg/kg/day and was gradually tapered over 10 weeks. Complications of long-term steroid use such as derangement in blood sugar levels, decrease in immune response, early cataract formation and increase in IOP were thoroughly monitored.

**Results:** His visual functions remained unaffected. We noted immediate resolution of his headache and eye pain after steroid therapy. His ophthalmoplegia and ptosis had a more progressive course of improvement. At the end of treatment, our patient reported no recurrence of his headache or eye complaints.

**Conclusion:** The hallmark of THS is a painful ophthalmoplegia that is steroid-responsive. The patient's clinical presentation followed the criteria set in place by the International Headache Society in 2013, in the diagnosis of THS. Our decision to start steroids was both diagnostic and therapeutic. Judicial dose adjustments and careful follow-ups, along with monitoring for possible complications should be emphasized.

P-316

**OCULAR TUBERCULOSIS: THE GREAT MASQUERADER**A Sandig, E Palisoc<sup>1</sup>, A Ortiz<sup>1</sup>, E Morabe<sup>1</sup>.<sup>1</sup>*Ophthalmology, Jose Reyes Memorial Medical Center, Manila, Philippines***Objective:** To present a case of ocular tuberculosis in a young female patient.**Methods:** This is a case report of a 13-year-old female diagnosed with extra-pulmonary tuberculosis manifesting as upper lid mass.**Results:** A young female presented with a one-year history of painless, slowly progressive swelling of her right upper eyelid. She had a history of weight loss, bilateral neck masses, and hoarseness of voice. On initial examination, there was a nodule of 2 x 2 centimeters soft, non-tender, movable, well-circumscribed mass on the right upper eyelid extending to the right eyebrow. Her BCVA was 6/6 in both eyes. Slit lamp examination, fundoscopic assessment, and intraocular pressure evaluations were essentially normal in both eyes. Systemic examination revealed bilateral cervical lymphadenopathies. Computed tomography of the orbits revealed a non-enhancing expansile hypodense mass measuring 3.0 x 2.9 x 3.5 centimeters occupying the right supero-lateral orbital wall with speckled calcifications, lytic, and erosive changes. Differential diagnoses include eosinophilic granuloma, intradiploic epidermoid cyst or possibly a lacrimal gland tumor. Laboratory investigations revealed elevated leukocyte count with normal erythrocyte sedimentation rate. Chest x-ray revealed unremarkable findings, however, she was noted to have positive Mantoux and TB Quantiferon tests. An abscess was drained from the lateral canthal fistula, which revealed negative for acid-fast bacilli staining. A high index of suspicion of ocular tuberculosis prompted referral to Pediatric Department in our institution for co-management. Afterwards, she was started with oral anti-Koch's therapy which included daily dose of Rifampicin 150mg/tab, Isoniazid 75mg/tab, Pyrazinamide 400mg/tab, and Ethambutol 275mg/tab. On last follow-up, the lesion at the lateral orbital rim remarkably improved.**Conclusion:** Diagnosis of ocular tuberculosis can be very difficult as clinical findings can mimic a wide array of various underlying systemic diseases. Accurate diagnosis requires a high index of suspicion, review of accompanying signs and symptoms, coupled with appropriate laboratory testing. While there are still no established definitive criteria for the diagnosis of this disease, the dramatic response to anti-tuberculosis treatment and due to the high incidence of TB in the country, could perhaps confirm the diagnosis of ocular tuberculosis.

P-317

**Dry eyes as an under-recognized presenting symptom of thyroid eye disease**A Ngai<sup>1</sup>, K Lai<sup>1,2</sup>, K Chan<sup>1,3</sup>, K Chong<sup>1,3</sup>, C Pang<sup>1</sup>, C Tham<sup>1</sup>.<sup>1</sup>Department of Ophthalmology and Visual Sciences, The Chinese University of Hong Kong, <sup>2</sup>Department of Ophthalmology, Tung Wah Eastern Hospital, <sup>3</sup>Department of Ophthalmology and Visual Sciences, Prince of Wales Hospital, Hong Kong, Hong Kong, China**Objective:** To investigate the most common presenting and persistent symptoms in patients with thyroid eye disease (TED) and their associations with any demographic, orbital or ocular surface-related parameters.**Methods:** 101 consecutive patients who attended the Thyroid Eye Clinic (TEC) at the Chinese University of Hong Kong from October 2019 to May 2020 were included in this study. Information on patients' recall of first eye-related symptoms, demographics and disease-related parameters were collected using a standard datasheet by a single oculoplastic surgeon. Persistent symptoms were recorded from each patient's latest follow-up, with minimum of 18 months follow-up. TED was assessed by TED-quality-of-life, Graves' Ophthalmopathy-quality-of-life questionnaires, visual acuity, intraocular pressure, clinical activity score(CAS), exophthalmometry, marginal reflex distance, extraocular motility restriction, thyroid function and orbital MRI grading. The presence and severity of dry eye disease (DED) were evaluated by traditional Chinese version of Ocular Surface Disease Index (OSDI), fluorescence tear film break-up time (FBUT) and Schirmer's test (ST).**Results:** A total of 101 patients (female=82) with a mean age of 46.1+/-12.9 year-old were recruited. 85% (86) of patients had abnormal thyroid status in which 95% (82) were hyperthyroid at the time of evaluation. 5 were smokers. The commonest first eye symptom was dry eye, seen in 30 (29.7%) patients, followed by upper eyelid swelling in 27 (26.7%), prominence in 23 (22.8%) and double vision in 16 (15.8%). The mean OSDI score of 28.2+/-24.2 showed moderate disease. Of the 83 patients with FBUT available, 94% (74) patients showed reduced TBUT (<10s) in at least one eye. 51.9% (14) out of 27 patients with ST performed had reduced wetting (<10mm). Double vision became the commonest persistent symptom in 32.7% (33) patients, followed by dry eye in 25.7% (26), upper lid swelling in 23.8% (24) and prominence in 23.8% (24) at patients' latest follow-up, after a minimum of 18 months' follow-up.**Conclusion:** In this Chinese TED cohort, dry eye was the commonest presenting symptom. Increasing the awareness of dry eye as part of TED spectrum may allow earlier detection and ophthalmology referral for better clinical outcomes.



**P-318****Conjoint Fascia Sheath Suspension in Severe Pediatric Congenital Ptosis**L Wei.

**Objective:** There are several surgical treatments for the correction of congenital ptosis with poor levator function, like frontalis sling or maximal levator resection. Conjoint Fascia sheath suspension (CFS) is newly developed procedure of ptosis. We evaluated the clinical efficacy and complications of CFS in treating moderate or severe congenital ptosis.

**Methods:** A retrospective, interventional case series was performed. A total of 21 patients with 24 eyelids (21 unilateral and 3 bilateral ptosis) who underwent conjoint fascia sheath suspension were included. The patients underwent operation between 1 January 2019 and 31 December 2020 by a single surgeon (LC Wei) at Taichung Veterans General Hospital. Inclusion criteria were unilateral severe congenital ptosis or asymmetric bilateral ptosis with poor levator function. Clinical data were reviewed included demographics as well as preoperative margin reflex distance-(MRD1), levator function, and postoperative MRD1.

**Surgical technique:** An upper eyelid incision was made at either 2-3 mm above the cilia line. The levator aponeurosis and Muller muscle were dissected from the superior border of the tarsal plate. The dissection was carried out superiorly along the layer beneath the muller muscle and conjunctiva. Then, the white CFS thickened tissue was exposed. The CFS was pulled down, sutured with 5-0 PDS thread.

**Results:** The mean age at the time of surgery of all patients was  $3.30 \pm 1.31$  years (range, 16 months to 6.5 years). The mean follow-up duration was  $29.71 \pm 7.42$  months (range, 18 to 40 months). There was no statistical difference in demographics between the unilateral and bilateral asymmetric groups. The preoperative MRD1 was  $-0.67 \pm 0.8$  mm (range, -2 to +1 mm) The postoperative MRD1 was  $2.81 \pm 0.52$  mm (range, +1.5 to +3.5 mm) in unilateral group and  $2.58 \pm 0.49$  mm (range, 2 to 3 mm) in bilateral group. The surgical outcomes were not statistically different between the two groups ( $p=0.31$ ) Postoperative complications included lagophthalmos (19 patients, 90.1%), exposure keratitis (2 patients, 9.5%), and transient increase of astigmatism (3 patients, 14.3%). Exposure keratopathy were controlled with artificial tears and ointment. Otherwise, no entropion, conjunctival prolapse, and infection were noted

**Conclusion:** Conjoint Fascia sheath suspension is an effective procedure for congenital ptosis even in patients with poor levator function, which provides improved cosmesis, a natural lid contour, avoids brow scars and mild complications.

P-319

### Deep learning-based image analysis for automated measurement of eyelid morphology before and after blepharoptosis surgery

L Lou, J Ye.

**Objective:** Eyelid position and contour abnormality could lead to various diseases, such as blepharoptosis, which is a common eyelid disease. Accurate assessment of eyelid morphology is important in the management of blepharoptosis. We aimed to propose a novel deep learning-based image analysis to automatically measure eyelid morphological properties before and after blepharoptosis surgery.

**Methods:** This study included 135 ptotic eyes of 103 patients who underwent blepharoptosis surgery. Facial photographs were taken preoperatively and postoperatively. Margin reflex distance (MRD) 1 and 2 of the operated eyes were manually measured by a senior surgeon. Multiple eyelid morphological parameters, such as MRD1, MRD2, upper eyelid length and corneal area, were automatically measured by our deep learning-based image analysis. Agreement between manual and automated measurements, as well as two repeated automated measurements of MRDs were analyzed. Preoperative and postoperative eyelid morphological parameters were compared. Postoperative eyelid contour symmetry was evaluated using multiple mid-pupil lid distances (MPLDs).

**Results:** The intraclass correlation coefficients (ICCs) between manual and automated measurements of MRDs ranged from 0.934 to 0.971 ( $p < 0.001$ ), and the bias ranged from 0.09 mm to 0.15 mm. The ICCs between two repeated automated measurements were up to 0.999 ( $p < 0.001$ ), and the bias was no more than 0.002 mm. After surgery, MRD1 increased significantly from  $0.31 \pm 1.17$  mm to  $2.89 \pm 1.06$  mm, upper eyelid length from  $19.94 \pm 3.61$  mm to  $21.40 \pm 2.40$  mm, and corneal area from  $52.72 \pm 15.97$  mm<sup>2</sup> to  $76.31 \pm 11.31$  mm<sup>2</sup> (all  $p < 0.001$ ). Postoperative binocular MPLDs at different angles (from 0° to 180°) showed no significant differences in the patients.

**Conclusion:** This technique had high accuracy and repeatability for automatically measuring eyelid morphology, which allows objective assessment of blepharoptosis surgical outcomes. Using only patients' photographs, this technique has great potential in diagnosis and management of other eyelid-related diseases.

P-320

**AKT2 was a potential target of miR-29a-3p via microRNA profiling of high proliferation lacrimal gland adenoid cystic carcinoma**

X Liu<sup>1</sup>, J Zhao, J Lin, M Jiang, F Xu, C Zhang, Q Tang, L Zhu, L Dong, T Lin.

<sup>1</sup>Tianjin Medical University Eye Hospital, Tianjin, People's Republic of China

**Objective:** Lacrimal gland adenoid cystic carcinoma (LACC) is a major orbital malignancy. The recurrence rate and mortality rate are higher in high proliferation LACC(HP-LACC) compared with low proliferation LACC(LP-LACC). We used miRNA microarray to explore the differentially expressed miRNAs profiling between HP-LACC and LP-LACC and its potential signaling pathway.

**Methods:** Tissues from 17 LACCs were made into tissue microarrays. Patients were divided into high proliferation group and a low proliferation group based on Ki-67 value. HE, immunofluorescence (IF), and Immunohistochemistry (IHC) were performed on the tissue microarrays. 4 HP-LACC and 4 LP-LACC were made into miRNA microarrays and analyzed for miRNA profiles. Differentially expressed miRNAs were analyzed by volcano plot and heat map. Target gene were predicted using the miRWalk and miRDB for these differentially expressed miRNAs, the intersection of the results are used as targets for further gene ontology and KEGG pathway analysis. The four differentially expressed miRNAs were validated by qRT-PCR, the miRNAs with statistically significant differences validated by dual luciferase reporter and qRT-PCR. Finally, IHC was used for their downstream signaling pathway proteins.

**Results:** HE staining showed tubular, cribriform, and basaloid structures in LACC. IF showed CK7, P63 fluorescence expression in all three structures. Patients were divided into HP-LACC and LP-LACC based on Ki-67 median value of 11%. IHC and survival analysis showed Ki-67 ratio increased, the proportion of P63 decreased, and the expression of P53 increased. The disease-free survival and overall survival of the patients decreased. IHC and survival analysis showed Ki-67 increased, P63 decreased, P53 elevated, with prognosis worse. Heat map and volcano plot yielded 15 differentially expressed miRNAs between HP-LACC and LP-LACC. The 15 differential miRNAs were used to predict target genes in miRWalk and miRDB databases, and there were 559 target genes after intersection. Among the 15 differentially expressed miRNAs, miR-29a-3p was verified to be significant by qRT-PCR. Dual luciferase reporter and tissue microarray immunohistochemical assays validated that AKT2 was a direct target gene of miR-29a-3p.

**Conclusion:** Our studies have identified differentially expressed miRNAs associated with LACCs of variable proliferation ability, and AKT2 is a direct target gene of miR-29a-3p, which will contribute to target gene therapy in patients with high proliferation LACC in the future.

**P-321****Correlation between clinical symptoms and the punctal stenosis by anterior segment optical coherence tomography**Y Lee.

**Objective:** To assess the lower punctum parameters in patients with acquired punctal stenosis using spectral-domain anterior segment optical coherence tomography and to evaluate the correlation to clinical symptoms

**Methods:** This was a prospective case series. 10 puncta from 10 patients (3 males and 7 females) were enrolled. Anterior segment optical coherence tomography was employed to evaluate lower punctum parameters; the inner and outer punctal diameters as well as punctal depth were measured.

**Results:** The average of external punctal diameter, internal punctal diameter and punctal depth were  $446.1 \pm 110.6 \mu\text{m}$ ,  $166.4 \pm 68.6 \mu\text{m}$  and  $189.4 \pm 43 \mu\text{m}$  respectively. The severity of epiphora was negatively correlated to the punctal diameter.

**Conclusion:** Anterior segment optical coherence tomography (ASOCT) could be used as a rapid, noncontact and noninvasive diagnostic modality for evaluating and measuring the lower punctum in patients with punctal stenosis. The result showed negative correlation between the result in ASOCT and the clinical presentations as epiphora.

P-322

**Basal cell carcinoma of the periocular region in adults under 40**

M Karhanova<sup>1</sup>, B Babkova<sup>1</sup>, O Vlaci<sup>1</sup>, S Jakubickova<sup>1</sup>, Z Cyzova<sup>2</sup>, K Pechova<sup>2</sup>.

<sup>1</sup>Department of Ophthalmology, <sup>2</sup>University Hospital Olomouc and Faculty of Medicine and Dentistry of Palacky University Olomouc, Olomouc, Czech Republic

**Objective:** Basal cell carcinoma (BCC) is a slow growing and only locally invasive form of skin cancer. It is commonly diagnosed in elderly population. The aim of the study is to determine the outcomes and recurrence rate of BCC in patients under 40 years of age.

**Methods:** A retrospective analysis of all patients who underwent excision for periocular suspected malignancy was conducted from 2005 to 2018. All patients with histologically confirmed diagnosis of periocular BCC were selected and all patients under the age of 40 were identified.

**Results:** Over the 14-year period 279 BCC were histologically confirmed (158 women, 122 men). The follow up period was 3 – 17 years. We found 8 BCCs present in the population under 40 years (4 woman, 4 men) aged 24 – 39 years. 6 patients presented with lower lid BCCs and 2 patients with medial canthal BCCs. The most common histological subtype was the nodular BCC (4 patients). Recurrence was found only in one patients after 6 months.

**Conclusion:** BCC in patients under 40 years of age are rare and the recurrence rate may be higher than in the elderly population. Although there was only one case of recurrence in our study, we recommend larger excision margins and longer follow up period for these patients. This work was supported by the Ministry of Health of the Czech Republic – Conceptual development of research organisation (FNOL,00098892) and grant no. NU21J-01-00017. All rights reserved.

P-323

### Epidemiology and evolution of Graves' orbitopathy. Experience of a Multidisciplinary Service in Gran Canaria (Spain).

A Rutllan-Farias, P De-Pablos<sup>1</sup>, J Rutllán-Civit<sup>2</sup>, J Gonzalez-Martin<sup>3</sup>, L Farias-Martinez<sup>4</sup>.

<sup>1</sup>Endocrinology, <sup>2</sup>Ophthalmology, <sup>3</sup>Investigation Unit, Doctor Negrin University Hospital, <sup>4</sup>Perpetuo Socorro Hospital, Las Palmas de Gran Canaria, Spain

**Objective:** Describing the experience in the management of Graves' orbitopathy (GO) in the island of Gran Canaria (Spain), and learning about epidemiological and evolutive traits of GO in our environment.

**Methods:** Retrospective observational study involving 77 patients suffering from Graves' orbitopathy attending a specialized multidisciplinary consultation between 2017 and 2021. A descriptive and evolutive analysis was performed. Odds Ratio, chi-square, multivariable analysis and correlation tests were used to search predictors of worse outcome despite treatment.

**Results:** The average length of thyroid orbitopathy in patients of a specialized consultation in ophthalmology resulted in four years. Among them, 58% were smokers, 48% suffered from arterial hypertension, 21% from diabetes mellitus and 42% were obese. Most patients (70%) were women. Predictors of worse outcome found in this study were: arterial hypertension (O.R.=2.74), consecutive hypothyroidism (O.R.=2.40), and smoking habit (O.R.=1.70). Nevertheless, statistical significance was only marginally achieved ( $p = 0,04$ ,  $p=0,05$  and  $p=0,06$  respectively). Duration of hyperthyroidism was also a factor linked to worse outcome despite having treatment (correlation coefficient=0.67).

**Conclusion:** This retrospective study, regarding patients treated by a multidisciplinary team, could demonstrate only a marginal worse outcome of the subset presenting predictors of bad prognosis.

P-325

**Long term effects of Nunchaku-style silicone tube intubation for primary acquired lacrimal drainage obstruction – a case series**M *Loi*, *C Huang*, Y *Ting*, C *Wu*.

**Objective:** To evaluate the outcome of balloon dacryoplasty with Nunchaku-style silicone tube intubation (NSTI) in patients with primary acquired lacrimal drainage obstruction (PALDO) in Taiwan.

**Methods:** The retrospective case series included patients of PALDO in 1 institution between Jan 2019 and May 2021. Diagnosis of PALDO was based on subjective complaints of tearing and clinical evidence of epiphora and nasolacrimal duct irrigation. A 3x15-mm balloon was used and silicone lacrimal tubes were placed. Patients received postoperative topical antibiotics and steroid drops for 1 week. All patients were followed up for 1-year post-surgery. The success of NSTI was deemed as patency on irrigation and subjective complaints of epiphora.

**Results:** A total of 7 patients (7 eyes; 5 female; mean age 57 years) were included. The mean duration of surgery was 45 min (range: 34–88). There was no dacryocystitis in our case series. At a median follow - up of 19 months (range: 12–34), 86 % experienced complete resolution of symptoms and 14% showed improvement but still experienced epiphora. 1 case had silicone tube dislocation, while the patient still had anatomically patency on irrigation. 86% had Nunchaku-style silicone tube in situ without tube - related epiphora or other complications.

**Conclusion:** Balloon dacryoplasty with Nunchaku-style silicone tube intubation as a treatment for PALDO provides long-term relief without complications. The anatomical patency is noted even if the silicone tube is dislocated after long-term implantation. Further studies on larger samples and longer follow-ups are needed.

P-326

### Primary Neuroendocrine Tumors of the Orbit in 3 Cases

J Qiao<sup>1</sup>, W He<sup>1</sup>.

<sup>1</sup>Department of Ophthalmology, West China Hospital of Sichuan University, Chengdu, People's Republic of China

**Objective:** We report 3 cases of primary orbital neuroendocrine tumors in order to improve the understanding, diagnosis and treatment of these diseases.

#### Methods:

Case1, male, 48 years old. Admitted to hospital because of a 2-month history of increased right eye proptosis. Clinical examinations showed proptosis of the right eye, conjunctival congestion and oedema. The CT imaging revealed a well-defined and uniform density, retrobulbar nodule measuring 3.3 × 3.0 × 2.8 cm in the right orbit posterior part, which surrounded the optic nerve and squeezed extraocular muscles.

Case2, female, 82 years old. Sought treatment for a one-month history of progressive mass on the lower eyelid. The examination showed a red mass on the nasal side of the left lower eyelid. CT showed a well defined peribulbar nodule with 2.2 × 1.9 × 2.1 cm in the orbital muscle cone and nasolacrimal duct area. One month later, an MRI was conducted and showed soft tissue mass in the left orbital nasolacrimal canal region with uneven enhancement, the maximum cross-section of the lesion had 4.0 × 3.2 cm.

Case3, female, 48 years old. She was hospitalised in the Endocrinology Department because of "fatigue, general edema for 1 year, hair loss, skin pigmentation for 5 months". Physical examination showed the patient had mildly elevated blood pressure, moon face, central obesity, multiple purple striae on the abdomen, scattered bruises, and proximal muscle weakness. In order to seek the possible cause, we have pituitary MRI. The pituitary was normal, but we found an enhancement in the lateral rectus muscle of the patient's left eye.

**Results:** All the patients underwent surgical resection of the tumor. The case1-2 were pathologically diagnosed as "neuroendocrine carcinoma", and a total body CT and a bone marrow evaluation, which ruled out any occult internal malignancy. The tumor systemic metastasis was found 1 month after operation and died 3 months later. Case 3 was "neuroendocrine tumor", and the symptoms of Cushing syndrome gradually disappeared after the operation, no recurrence was found after a 4 years follow-up.

**Conclusion:** Orbital primary neuroendocrine tumors are extremely rare, their clinical and imaging findings are lack of specificity. The diagnosis depends on pathomorphology and immunohistochemical examination. The malignant patients progress rapidly and the prognosis is poor.



P-327

**Methodology for the prevention of complications in bone orbit decompression: individual surgical cutting guides**

O Prusak, O Petrenko<sup>1</sup>, Y Chepurnyi<sup>2</sup>, A Kopchak<sup>2</sup>, S Rykov<sup>1</sup>, A Slobodianiuk<sup>3</sup>.

<sup>1</sup>P.L. Shupyk National University of Health Care of Ukraine, <sup>2</sup>Bogomolets Institute of Postgraduate Education of the National Medical University, <sup>3</sup>Center of Maxillofacial Surgery and Dentistry of Kyiv Regional Clinical Hospital, Kyiv, Ukraine

**Objective:** According to the literature, the frequency of complications of surgical decompression of the orbit is from 9.3% to 35% (most often - the appearance of secondary diplopia, less often - lesions of the suborbital nerve, bleeding in the orbit, etc). Therefore, the development of ways to prevent complications during bone decompression of the orbit is an actual task of endocrine orbitopathy (EOP) management. Development of a methodology for the prevention of complications in bone orbit decompression in patients with endocrine orbitopathy, based on the use of individual surgical cutting guides.

**Methods:** We analyzed the results of EOP treatment between 17 patients, who underwent bone orbital decompression at the Kyiv Regional Clinical Hospital in the period from 2017 to 2021. The rate of post-surgical complications, as well as exophthalmos severity were evaluated. Digital modeling and subsequent production of surgical guides was performed using Disior orbital software, D2P software and Geomatic Freeform Plus.

**Results:** When performing surgical decompression of the orbit, it is important to "bypass" the following anatomical structures of the orbit: buttresses (places that will serve as a support for the eyeball), attachment of the oculomotor muscles, suborbital nerve canal (to prevent hyposthesia of the II branch of the trigeminal nerve).

**Conclusion:** Surgical decompression of the orbit with the use of surgical guides can achieve a significant reduction in the degree of exophthalmos and reduce the risk of postoperative complications due to damage to the oculomotor muscles and the suborbital nerve.

**P-328****Sudden Visual Loss Following Poly-L-Lactic Acid Injection into the Forehead**Y Wu.

**Objective:** We report a case of a 26-year-old female with blindness and partial ophthalmoplegia of the left eye following subcutaneous injection in the forehead with filler poly-L-lactic acid, which has not been reported previously. The patient suffered from sharp pain and then blurred vision immediately after the injections.

**Methods:** a retrospective case report

**Results:** The patient had permanent vision loss despite immediate ophthalmological intervention and comprehensive therapy with heparin infusion, systemic corticosteroid treatment and hyperbaric therapy.

**Conclusion:** An increasing number of people are pursuing aesthetic enhancement and rejuvenation by means of facial filler injections. Clinicians and patients should be aware of the risk of iatrogenic artery occlusion associated with facial fillers and that immediate treatment is paramount in such an event in order to reduce the likelihood of devastating consequences.

**P-329****Long Term Outcome of Müller's Muscle Conjunctival Resection with Tarsectomy for Moderate-to-Severe Ptosis Correction**C Lin.

**Objective:** To evaluate the long term outcome of Müller's muscle conjunctival resection (MMCR) with tarsectomy for correction of moderate-to-severe upper eyelid ptosis.

**Methods:** Medical records were reviewed for 40 patients who underwent MMCR with tarsectomy for moderate-to-severe ptosis correction. All met the criteria of levator muscle function  $> 4\text{mm}$  and pre-operative margin reflex distance 1 (MRD1)  $< 1\text{ mm}$ . Maximal MMCR procedure was performed and minimal residual tarsus 3mm were arranged for all patients. Follow-up periods were 5 years. Outcome measures were post-operative MRD1, complications, and eyelid symmetry.

**Results:** In 40 patients who underwent 60 MMCR procedures with tarsectomy for correction of upper eyelid ptosis, MRD1 increased on average by 3.3 mm ( $P < 0.01$ ). In 36 patients (90%), eyelid symmetry equal to or less than 1 mm was achieved ( $P < 0.01$ ). At 5-year follow-up period, average post-operative MRD1 decreased to 1.1 mm. Among them, only 3 eyes (5%) suffered from post-operative complication of entropion.

**Conclusion:** Müller's muscle conjunctival resection with tarsectomy is effective and simple procedure for moderate-to-severe ptosis correction in patients with good levator muscle function. Good eyelid symmetry is achieved in most patients. Although post-operative MRD1 decreased gradually due to aging, tissue loss or wound scarring dehiscence, MMCR with tarsectomy is considered as the treatment of choice for correction of moderate-to-severe upper lid ptosis.

P-330

### A Systemic Review of Comparison repair approaches for Upper Eyelid Ptosis in the Asians

J Liou<sup>1</sup>.

<sup>1</sup>*Ophthalmology Department, Chung Shan Medical University Hospital, Taichung, Taiwan, China*

**Objective:** Upper eyelid ptosis is common disorder in the Asians. Numerous modified repair approaches was published for better outcome in the Asians and the comparison between approaches was needed.

**Methods:** The authors conducted a comprehensive systematic literature review of different ptosis repair approaches in the Asians from the PubMed was performed through 2000 with subsequent updates to the begin of 2022.

**Results:** In this review of the available literature, authors found some not randomized, uncontrolled, retrospective or prospective studies on numerous modified repair approaches. Classical repair approaches including Muller muscle-conjunctiva resection (MMCR), a kind of internal approach, and external levator advancement. However, there are basic anatomic characteristics of upper eyelid in the Asians, such as single eyelid with puffiness; low eyelid crease; nasally narrowing downward of crease, and different aponeurosis structure. These results highlight the possibility of alternative and the need to compare different approaches and improve clinical outcomes.

**Conclusion:** The systemic review found present studies provide several different approaches provide reliable, effective outcome and some evaluating markers or formula to improve the precision of outcome. Indeed, additional systematic collection of prospective evidence may be necessary for the repair of upper eyelid ptosis in the Asians into routine practice.

P-331

**Mantle cell lymphoma of the lacrimal gland in Asian males and review of the literature**W Chang<sup>1</sup>.<sup>1</sup>*Ophthalmology, Show-Chwan Memorial Hospital, Changhua, Taiwan, China*

**Objective:** Ocular adnexal lymphomas constitute 2% of all extranodal lymphomas and are the most common malignant neoplasms of the orbit. MCL is a rare type of non-Hodgkin lymphoma(NHL) that originates in mature B cells of the inner mantle zone of lymphoid follicles. Among periocular MCL, 90% of cases having lymphoma present at 2 or more periocular sites and isolated lacrimal gland involvement is less common. In present study, we describe rare cases of male patients suffering from MCL that involve the lacrimal gland.

**Methods:** This was a retrospective review of patients of Mantle cell lymphoma of the lacrimal gland evaluated for between 2020 and 2021. Patients were identified through clinical note queries. Written informed consent for publication of this report was obtained from both patients.

**Results:** In the present study, we describe male patients of MCL involving the lacrimal gland. Patient 1, a 75 year-old man, initially had MCL of ileum and underwent chemotherapy with remission for 2 years. He was considered to have achieved remission but subsequently developed MCL of the lacrimal gland. The patient was receiving target therapy for the recurrence of abdominal MCL currently. On the other hand, Patient 2, a 83 year-old man, initially developed bilateral lacrimal gland lesions as well as bilateral palpable orbital mass, of which were cytogenetically confirmed to be MCL. He was subsequently found to have gastrointestinal tract lesions and bone marrow involvement that were also confirmed to be MCL. The patient was then receiving chemotherapy with Rituximab and Bendamustine.

**Conclusion:** Ocular adnexal MCL tends to occur in elderly males and the orbit is the most commonly involved site. Although MCL of the lacrimal gland is extremely rare, we should include it in the differential diagnosis when encountering elderly male patients with lacrimal gland mass.

P-332

**Periorbital Necrotizing Fasciitis Progressing to Orbital Cellulitis with Osteomyelitis in an Infant**R Barairo, A Ortiz<sup>1</sup>, H Teo<sup>1</sup>.<sup>1</sup>Ophthalmology, Jose R Reyes Memorial Medical Center, Manila, Philippines**Objective:** To report a case of periorbital necrotizing fasciitis in an infant

**Methods:** A 2-month-old female was referred to our institution due to a 2-week history of fever, swelling and erythema of the right lower lid. On examination, patient was lethargic with an eschar measuring 5 x 2.5 cm overlying the right periorbital and nasomaxillary region with mucopurulent discharge. After 3 days, there was increase in the size of the eschar and swelling of the right eye, with -3 abduction deficit, hyperemic and chemotic conjunctiva, and grade-2 corneal edema. Culture of the eye discharge showed growth of *Pseudomonas aeruginosa*. Complete blood count revealed anemia, leukocytosis, thrombocytosis, and neutropenia. Computed Tomography (CT) showed right periorbital soft tissue swelling with fluid densities and air pockets overlying the right extraconal space, eroding the cornea with communication to the anterior chamber. Wound debridement alongside Otorhinolaryngology service was done. Histopathologic examination showed areas of necrosis, abscess, and fungal elements. Patient was placed on broad spectrum intravenous antibiotics, antifungal, and topical antibiotics. Repeat CT scan revealed progression of the soft tissue swelling with findings suggestive of osteomyelitis involving the ethmoid and maxillary regions. Patient was eventually discharged and advised for reconstructive surgery.

**Results:** Necrotizing fasciitis (NF) is a rare infection that involves necrosis of the superficial layers of the skin which rapidly progresses to involve deeper layers such as fat and fascia. Findings associated with NF include skin erythema, edema, discoloration, and extreme pain/anesthesia over the affected areas. It is usually seen in immunocompromised patients and is considered uncommon in pediatric population. Periorbital involvement is rare because of the good blood supply of this area. Imaging modalities commonly used in patients with NF include CT scan and Magnetic Resonance Imaging (MRI). Treatment of NF involves immediate surgical debridement to control the infection, use of broad-spectrum antibiotics, hemodynamic, and metabolic support. Adjuvant hyperbaric oxygen therapy has also been reported to decrease mortality of patients with NF.

**Conclusion:** Initial presentation of NF may seem benign however, this may rapidly progress to fulminant infection. Early suspicion, surgical intervention, prompt antibiotic therapy and supportive treatment is crucial to minimize morbidity and mortality in these patients.

P-333

**Septic cavernous sinus thrombosis with unknown origin in young female - A case report**Y Lee.

**Objective:** To present the clinical presentation in a rare case of septic cavernous sinus thrombosis with unknown origin

**Methods:** A case report

**Results:** This is a 44-year-old woman without major systemic disease. Because of acute onset of left ptosis with diplopia, she was referred to neurologist after visiting the ophthalmic clinics, where no significant ocular problem was found.

In neurologic clinics, ptosis with esotropia and progressed proptosis in the left eye were found. She denied facial, ear, throat discomfort, or any filler/Botox injection at face. Brain MRI shows: 1. Enlarged bilateral cavernous sinus with numerous filling defect; 2. Bilateral cavernous ICA stenosis; 3. Engorged left superior ophthalmic vein. 4. Cavernous sinus thrombosis and bilateral ICA stenosis (suspect thrombophlebitis). Besides, Lab data shows neutrophilia, increased C-reactive protein and D-dimer. Bacterial culture yielded *Parvimonas micra*, and systemic antibiotics was administrated. However, except very mild periodontal disease, no evident infection source was found after systemic survey.

Esotropia was improved to 25 PD at primary gaze about 1 weeks later after using antibiotics. Follow-up MRI was performed 1 month later, and revealed Cavernous sinus thrombosis (thrombophlebitis) with improvement. Around 3 months later, esotropia was almost resolved.

**Conclusion:** Septic cavernous sinus thrombosis (SCST) is a rare, yet severe, process typically arising from infections of the paranasal sinuses (predominately ethmoid and/or sphenoid sinusitis) and less commonly, otogenic, odontogenic, and pharyngeal sources. Clinical symptoms of SCST arise from obstruction of venous drainage from the orbit and compression of the cranial nerves within the cavernous sinus. In the pre-antibiotic era, SCST was considered universally fatal (80-100%); however, with the introduction of antibiotics the overall incidence, morbidity and mortality of SCST have greatly declined. In spite of dramatic improvements, morbidity and mortality remain high, and the majority of patients experienced neurological sequelae. Thus, prompt recognition, diagnosis, and treatment are necessary.

P-334

### Reconstruction of eyelid defects after the excision of basal cell carcinoma

W Chang<sup>1</sup>, H Chang<sup>2</sup>.

<sup>1</sup>Ophthalmology, Show-Chuan Memorial Hospital, <sup>2</sup>Ophthalmology, Show-Chwan Memorial Hospital, Changhua, Taiwan, China

**Objective:** To present the reconstructive options of the medial canthal area and lower eyelid region in patients who have benefited from the excision of basal cell carcinomas.

**Methods:** Retrospective case series of patients who have undergone eyelid reconstruction after excision of basal cell carcinoma in Show-Chuan Memorial Hospital.

**Results:** Three patients between 60 and 80 years old with a surgical wound on the lower eyelid/medial canthal area, after removal of malignant tumors, with defects ranging from approximately 30% to 60% of horizontal extension. All patients underwent Mohs micrographic surgery under local anesthesia. After complete excision of the tumor located in the lower eyelid/medial canthal area, surgical reconstruction was performed, according to the extent and depth, using neighborhood flaps or lid bag fat-removing technique with direct closure. The cosmetic result was highly satisfactory in all cases. There were no major complications or re-operations.

**Case 1:** Post-excisional defect coverage after basal cell carcinoma using modified rhomboid transposition flap. We designed a rhomboid-shaped transpositional flap of adjoining skin and subcutaneous tissue composed two lines horizontal and medial upper forming 120 degrees. The undersurface of the flap is anchored to periosteum to reform the concave contour of the medial canthus.

**Case 2:** Post-excisional defect coverage after basal cell carcinoma using the Hughes procedure. Reconstruction of the posterior lamella was done using advancement of a tarsoconjunctival flap from the upper eyelid to the lower eyelid. Then the second stage involved a Tenzel semicircular rotational flap to construct the anterior lamella.

**Case 3:** Post-excisional defect coverage after basal cell carcinoma using lid bag fat removal followed by direct closure and tarsal strip without skin grafting. This technique can be appropriately performed in old patients.

**Conclusion:** Basal cell carcinomas manifest their malignancy through their local invasion characteristics that cause significant destruction and disfigurement by invading surrounding tissues. The role of the surgeon is to first reestablish the functionality of the invaded eyelid after radically excising the tumor. Also, the aesthetic aspect has to be considered in order to improve quality of life. Having mastery over the periorbital anatomy and surgical options is beneficial in finding an optimal and personalized solution for the patient.



P-335

**Hydrogel scleral buckle explant masquerading as a cystic orbital mass**

M Loi, Y Ting<sup>1</sup>, C Huang<sup>1</sup>, C Wu<sup>1</sup>.

<sup>1</sup>Ophthalmology, Wan Fang Hospital, Taipei Medical University, Taipei City, Taiwan, China

**Objective:** We report a patient who underwent hydrogel scleral buckling for retinal detachment surgery 30 years ago that presented to our clinic with late complications masqueraded as a cystic orbital mass

**Methods:** Case report

**Results:** We report a 80 year old female who presented to our hospital due to left eye exophthalmos with palpable superior and inferior orbital mass. Computed tomography (CT) with contrast media showed a well-defined cystic lesion without contrast enhancement about 3.6 cm in length extending from superior to inferior via the temporal aspect of the left orbit. Distortion of the left globe by the mass lesion was also noted. Possible diagnosis include a lacrimal cystic tumor, epidermoid cyst, or a foreign body. Left eye lateral orbitotomy was undertaken to excise the tumor. Operation revealed a partially transparent and jelly-like material that resembles the the hydrogel scleral buckle. The hydrogel scleral buckle was commonly used back in the 1980s. However, late complications were reported such as ocular movement disorders, scleral buckle material extrusion, and periocular deformities.

**Conclusion:** No re-detachments of the retina were noted upon 1 year postoperative follow up. History taking is very important before any invasive surgical interventions. However, the patient in this case shows an elderly patient that cannot provide sufficient information in history taking. The differential diagnosis would rely heavily on image study. Studies show that CT and MRI images may reveal a hydrogel scleral buckle as a well-circumscribed, homogenous, primarily low-density enhancement lesion consistent with fluid, and would cause distortion of the globe contour. Although hydrogel scleral buckles were no longer used nowadays, we should always keep in mind the late complications of the hydrogel scleral buckle which often masquerades as a cystic orbital mass.

P-336

**Evaluation of eyelid margin abnormality and associated conditions in patients with demodex blepharitis**K Luo<sup>1</sup>, J Liou<sup>1</sup>.<sup>1</sup>Ophthalmology, Chung Shan Medical University Hospital, Taichung City, Taiwan, China**Objective:** Evaluate the eyelid margin abnormality and associated conditions in patients with demodex blepharitis**Methods:** A total of 94 eyes (47 patients) with demodex blepharitis were included in this retrospective analysis. The mean age was  $65.97 \pm 12.62$  years. Twenty patients (21.3%) were male and 74 patients (78.7%) were female. Eyelid-associated symptoms and signs such as: foreign body sensation (FBS), itching, discharge, redness, dryness, lid margin crusting or lash dandruff and ocular pain or stinging were recorded by questionnaire. Lid margin: plugging, vascularity, thickening, and irregularity were also evaluated by Arita's lid margin grading methods.**Results:** The percentage of associated symptoms and signs in patients as following: FBS(76.6%), itching(83.0%), discharge(89.4%), redness(63.8%), dryness(72.3%), lid margin crusting or lash dandruff(55.3%) and ocular pain or stinging(53.2%). The average eyelid grading ad following: lid margin plugging ( $1.98 \pm 0.90$ ), lid margin vascularity ( $1.53 \pm 1.21$ ), lid margin thickening ( $0.88 \pm 0.75$ ) and lid margin irregularity ( $0.71 \pm 0.67$ ).**Conclusion:** Eyelid margin abnormality associated with demodex blepharitis were underestimated. Further and longer follow up for these patients after treatment could provide more informative therapeutic guidance.

P-337

**REACTIVE LYMPHOID HYPERPLASIA OF THE LACRIMA GLAND**

R Maamouri<sup>1</sup>, I Helal<sup>2</sup>, W Nabi<sup>1</sup>, M Daouad<sup>1</sup>, M Ouederni<sup>1</sup>, M Cheour<sup>1</sup>.

<sup>1</sup>Ophthalmology, <sup>2</sup>Pathology, Hospital Habib Thameur, Tunis, Tunisia

**Objective:** To describe a case of bilateral dacryoadenitis due to reactive lymphoid hyperplasia

**Methods:** Single case report

**Results:** A 25-year-old woman with no past medical history, presented with a one-year history of chronic onset of bilateral dacryoadenitis. Systemic examination and laboratory tests were normal including serum IgG4. Orbital imaging detected an important poloidal hypertrophy of the two lacrimal glands with heterogeneous hypo echogenic aspect. Histologic examination of biopsy specimens showed seromucinous glandular structures accompanied by dense lymphoid infiltrate forming many follicles which exhibit germinal centers. It was composed of small to medium-sized lymphocytes. At immunohistochemistry, CD3 highlighted the T-cells in the inter-follicular region. CD20 highlighted the B-cells of the germinal centers. Immunohistochemical analysis excluded the diagnosis of lymphoma and the diagnosis of reactive lymphoid hyperplasia was retained. The patient was treated with short course of oral corticosteroids with good recovery.

**Conclusion:** Lymphoid hyperplasia of the lacrimal gland remains a rare entity that relies on the biopsy. The risk of developing a lacrimal gland lymphoma remains significant, justifying regular, close and rigorous clinical and radiological monitoring.

P-338

**Sebaceous Adenoma of the Caruncle**R Barairo, A Ortiz<sup>1</sup>.<sup>1</sup>*Ophthalmology, Jose R Reyes Memorial Medical Center, Manila, Philippines***Objective:** To report a case of sebaceous adenoma of the caruncle

**Methods:** A 38-year-old man presented with a 5-year history of a gradually enlarging yellowish mass in the right caruncular region associated with foreign body sensation and occasional episodes of mucoid eye discharge. He self-medicated with Tobramycin ointment three times a week for a month which provided no relief. On examination, there was a 6x9x4mm yellowish, pedunculated mass with a papillomatous appearance noted in the right caruncular region. The rest of the ocular examination was non-contributory. Excision biopsy was done revealing a multi-lobulated mass with closely-packed sebaceous lobules separated by connective tissue septa. In the periphery of the lobules, layers of small germinative cells with basaloid appearance were noted. Mitotic figures and infiltrative growth pattern were not noted. These findings were consistent with the diagnosis of sebaceous adenoma. Patient was advised for further work-up to rule out other malignancies.

**Results:** The caruncle is a pink, nodular structure located in the lacus lacrimalis medial to the plica semilunaris. The caruncle contains skin, hair follicles, sebaceous and sweat glands, and lacrimal tissues. Tumors occurring in the caruncular region is uncommon. Sebaceous adenoma is characterized by finger-like projections of normal-appearing sebaceous lobules which often shows connection with or replacement of overlying squamous epithelium. The basaloid germinative cells in the periphery is a distinct characteristic that helps in discriminating it from other sebaceous neoplasms. Treatment of this condition is complete surgical excision to decrease the chance of recurrence. Sebaceous adenoma is also associated with Muir-Torre syndrome (MTS) - an autosomal-dominant condition that is associated with sebaceous gland neoplasms, basal cell carcinoma, keratoacanthoma, and malignancies of the gastro-intestinal tract or other viscera. Sporadic cases has also been documented for this condition. Germline mutations of the mismatch repair genes MLH1, MSH2, and MSH6 are implicated in MTS.

**Conclusion:** Despite being a benign neoplasm, systemic work-up and close monitoring of patients with sebaceous adenoma is important because of its association with Muir-Torre syndrome. Recognition of tumors of the eye and its adnexal structures is important as it may signify a predisposition to develop other malignancies.

P-339

**Succesfull Management of Orbital Cellulitis Secondary to Odontogenic Infection : A Case Report**

S Riza Gustam<sup>1</sup>, P Purwanita<sup>1</sup>, A Tribowo<sup>1</sup>.

<sup>1</sup>Department Ophthalmology, Sriwijaya University, Mohammad Hoesin General Hospital, Palembang, Indonesia

**Objective:** To report a patient with orbital cellulitis from odontogenic origin who evolved with good visual outcome, emphasizing the importance of appropriate combination antibiotics therapy and primary infection management.

**Methods:** A Case report. A 61 years old woman was presented to the emergency with painful progressive protrusion of her left eye. After clinical examination and investigations, the patient was identified as unilateral orbital cellulitis secondary to odontogenic infection.

**Results:** The diagnosis was obtained based on anamnesis and ophthalmology examination. The patient also had a failure treatment from previous hospital. Orbital CT scan revealed soft tissue swelling and hyperintensity on the left optic nerve. Administration of multiple intravenous antibiotics and steroid were done immediately. Prompt to eradicate the primary infection, the patient has been consulted and treated by dentist. At one month follow up the swelling and chemosis of the left eye had markedly decreased and completely resolved at 3 months follow up.

**Conclusion:** This case highlights and shows an appropriate and comprehensive treatment may benefit and prevent sight-threatening condition.

P-341

**A Case of Orbital Abscess**S Sameda, Y *Santiago-Gatmaitan*<sup>1</sup>.<sup>1</sup>*Eye Institute, St. Luke's Medical Center, Quezon City, Philippines***Objective:** To describe a case of orbital abscess secondary to osteomyelitis in an adult female.**Methods:** This is a case report of a 65-year old diabetic female who presented with a 2-month history of orbital mass inferior to the left brow area.**Results:** BCVA was NLP OD and 20/400 OS. The right pupil was dilated at 5 mm with minimal response to light, left eye was 3 mm and sluggishly reactive to light. RAPD was present on the right eye. EOMs were also restricted on both eyes, up to -2 on the right superior rectus and right inferior rectus, and -1 on the rest. External examination revealed inferior displacement of the left globe and a palpable prominence on the left superior orbital rim. MRD and levator function tests were normal on both eyes. Hertel's exophthalmometry showed normal measurements, however the left eye was greater by 3 mm, which suggests possible proptosis of the left eye. There was note of hyperesthesia and decreased sensation on the right hemifacial area, as well as decreased hearing on both ears (80% right, 50% left). Initial MRI showed multiloculated subperiosteal abscess collection along the left superior orbital rim with intraorbital extension along the roof, measuring 3.1 x 3 x 3.8 cm, with mild compression and inferior displacement of the left globe. Work-up revealed increased WBC count with neutrophilia, elevated ESR and CRP, increased ferritin, and a positive serum galactomannan. Patient underwent orbitotomy with Gram stain, culture, and biopsy of the orbital mass and culture of the superior orbital rim bone. Biopsy was negative for malignancy but culture of the mass was positive for *Pseudomonas aeruginosa* and *Enterobacter cloacae*.**Conclusion:** Subperiosteal abscess may occur secondary to direct spread of sinus infection. A history of chronic sinusitis may predispose the patient to infection of the orbital bone. Hence, rapid and thorough diagnosis and treatment are required to achieve complete resolution of the infection and decrease the morbidity and mortality of the patient. Early detection of osteomyelitis can be made through CT and MRI. The treatment goal for osteomyelitis is directed to resolution of the infection while maximising patient function.

P-342

### A Case of Zoledronic Acid Induced Orbital Inflammation

J Morris, N Horgan<sup>1</sup>.

<sup>1</sup>Royal Victoria Eye and Ear Hospital, Adelaide Road, Dublin 2, Ireland, Dublin, Ireland

**Objective:** To describe a case of Zoledronic acid induced orbital inflammation

**Methods:** Case Report

**Results:** A 75-year-old lady presented to the Royal Victoria Eye and Ear Hospital, Dublin, with a four-day history of worsening headache, left orbital swelling, and loss of vision. This followed zoledronic acid infusion five-days previously. She had a past medical history of breast cancer managed with left mastectomy with combined chemo/radiation therapy and no previous ocular history. Visual acuity (VA) was 6.75 OD and 6/18 OS. There was left periorbital swelling, proptosis, conjunctival chemosis, and grossly restricted extra ocular eye movements (EOEM). Colour plates were 13/13 OD and 12/13 OS. Intra-ocular pressure was 21 OD and 28 OS with a normal fundal exam. The impression was of left orbital cellulitis and she was started on intravenous antibiotics along with lubricants and IOP lowering agents. Ear, nose, and throat (ENT) review was requested and although there was a lack of sinonasal symptoms and clear nasendoscopy, her case was treated as orbital cellulitis pending imaging.

CT Orbits and Venogram indicated left periorbital inflammation and proptosis, with no drainable collection, and no evidence of venous sinus thrombosis. MRI Brain and Orbits and MRV Cerebral Veins showed a left proptosis with soft tissue thickening. There was left lacrimal gland enlargement, expansion of the left extra-ocular muscles and distension of the left optic nerve sheath with normal optic nerve signal. There was a differential of idiopathic orbital inflammation, IgG4 disease, vasculitis, and sarcoidosis. Findings were not typical of metastatic disease. However, a literature search indicated zoledronic acid as the primary suspect of the orbital inflammation.

Following reassuring imaging, IV Methylprednisolone was started causing an improvement in symptoms and clinical signs. She was discharged on tapering oral prednisolone with Oculoplastics follow up. At the last outpatient visit she was awaiting rheumatological investigations and remains asymptomatic.

**Conclusion:** Bisphosphonates can rarely cause sight threatening inflammatory orbital disease, which can appear similar to orbital cellulitis. Symptoms tend to onset within 72 hours of bisphosphonate infusion and thankfully subside with corticosteroid treatment. Ophthalmologists should maintain an awareness of this rare but sight threatening side effect of bisphosphonate medications.

P-343

**Maxillary Sinus Carcinoma: an Ophthalmologic Presentation – Case Report**

C P Aguiar<sup>1</sup>, V Miranda<sup>1</sup>, J Chibante-Pedro<sup>1</sup>, R Soares<sup>1</sup>.

<sup>1</sup>Ophthalmology, Centro Hospitalar de Entre o Douro e Vouga, Santa Maria da Feira, Portugal

**Objective:** To present a case of maxillary sinus carcinoma first diagnosed in the ophthalmologic emergency.

**Methods:** Clinical case presentation.

**Results:** 51-year-old man, 29 pack-year smoker, that came to the emergency department with a left periorbital edema associated with pruritus with 1 month evolution. He also complained of epistaxis with 1 week evolution. At the objective evaluation, the most relevant finding was an exotropia with a hyperopia of his left eye, with suppression of it and a medial swelling, hard on palpation, associated with purulent exudation, leading to a temporal deviation of the ocular globe and proptosis. An orbital computerized tomography showed a large space-occupying lesion intersecting the left maxillary sinus, nostril, ethmoidal cells and the orbital left wall. It led to a nasal septum and orbital deviation, as well as of the optic nerve and medial rectus muscle, with left ocular proptosis. A biopsy was performed and the histological examination revealed a squamous cell carcinoma, nonkeratinizing, with stromal invasion. The patient underwent a perinasal sinus and neck computerized tomography that showed large adenopathies, probably metastatic.

**Conclusion:** In situations like this one, a multidisciplinary collaboration namely with otorhinolaryngology, is of extreme importance since some nasal and perinasal diseases may manifest themselves primarily with ophthalmologic signs. We observed that the first signs of an extremely severe disease can be ophthalmologic, when it is already in an advanced stage, with orbital invasion since this carcinoma is very aggressive with poor prognosis. It is crucial for the ophthalmologist to be aware of all signs and symptoms that the patient presents with, through a complete clinical history and a detailed objective evaluation, allowing the identification of the potentially severe cases, in which an orbital invasion might exist, leading to a correct orientation and proper treatment.



P-344

**Intraocular Osseous Metaplasia with Steven-Johnson Syndrome, a Case Report**J Zhao, L Zhu, T Lin, X Liu.

**Objective:** To present an unique clinical-pathological case of intraocular osseous metaplasia secondary to Steven-Johnson syndrome.

**Methods:** A 65 years old man was admitted into our hospital complaining of eye pain of the right eye. He had 30 years history of Steven-Johnson syndrome. Physical examination showed BCVA was no light perception and extensive corneal conjunctivalization of both eyes. Besides severe conjunctival injection and slight conjunctival sac secretions of the right eye, no more details could be observed from slit lamp examination. Since no treatment could help this patient, enucleation of the right eye was performed. During the preoperative examination, orbital CT imaging showed bilateral disorganized globe structure with reduced axial length, and irregular hollow-like area of intraocular calcification. During the surgery, the sclera was reserved and a bony whiteish mass of approximately 2 cm × 1.5 cm was removed along with the intraocular contents. Histopathology examination showed extensive intraocular osseous metaplasia and atrophic retina/uvea. After the surgery, ophthalmalgia was completely resolved and ocular prosthesis was inserted.

**Results:** Intraocular ossification is a rare type of metaplasia. Ectopic ossification is a common phenomenon observed within the extraskeletal soft tissues, however it's not normally seen in globes. Prevalence of intraocular osseous metaplasia was 5.8% reported in enucleated eyes. The pathogenic mechanism of intraocular osseous metaplasia was still unclear. Local pathology like chronic inflammation, retinal detachment and trauma appeared to be precursors for intraocular osseous metaplasia. RPE cells are supposed to be pluripotent and have the capacity to differentiate into osteogenesis inducing cells such as fibroblasts and osteoblasts. Steven-Johnson Syndrome (SJS) is a T-cell-mediated disorder. Ocular symptoms of SJS are characterized by persistent inflammation and ulceration of the ocular surface, which might be a trigger of intraocular osseous metaplasia formation. Histopathologically intraocular osseous metaplasia could be diagnosed one year after the ocular trauma, but radiologically identification usually takes more than decades. However, ossification to the extent seen in this case is seldom reported.

**Conclusion:** As we know, this is the first intraocular osseous metaplasia case ever reported in Steven-Johnson syndrome patient. The etiology of intraocular ossification is multifaceted, trauma and chronic inflammation are the leading causes.

**P-345****When All Odds Are Against Thyroid Orbitopathy; A Diagnostic Dilemma**A S Al-Ghafri.

**Objective:** To report an unusual presentation of thyroid orbitopathy and discuss the importance of thyroid stimulating Immunoglobulins (TSI).

**Methods:** I discuss an unusual case of a 45-year-old male presenting with a severe painless unilateral proptosis, upper eyelid retraction and lag, diplopia, normal thyroid function tests and negative thyrotropin receptor antibodies.

**Results:** The patient's computerized tomography (CT) and magnetic resonance imaging (MRI) revealed atypical pattern of extraocular muscles enlargement, mostly of the superior rectus-levator muscle complex. Additionally, his MRI showed involvement of the muscle tendons which typically corresponds to orbital myositis. His autoimmune work-up was equivocal, with borderline positive anti-nuclear antibodies. Nonetheless, thyroid gland ultrasound revealed a nodule and TSI was high.

**Conclusion:** This case report highlights the importance of widening the scope of differential diagnoses in cases of orbital inflammatory disorders. The diagnosis should be guided by a combination of clinical features, imaging studies and targeted laboratory testing before settling for a single diagnosis, given the complexity of the disease. TSI may play an important role in diagnosing atypical thyroid orbitopathy when all other tests, including other autoantibodies, are negative.

P-346

**Idiopathic Orbital Inflammation with Bone Destruction**Q Guo.

**Objective:** We aimed to describe a rare case of idiopathic orbital inflammation with bone destruction.

**Methods:** This is a case report. Clinical, radiological and histological data were collected from the Department of Ophthalmology, Beijing Tongren Hospital, Capital Medical University. Written informed consent for publication of this report and the accompanying images was obtained from the patient.

**Results:** A 48-year-old female developed redness and swelling of the medial canthus with tearing of the right eye for six months. She also noted a gradually growing mass of the inner eye corner for three months. Ophthalmic examination indicated a visual acuity of 0.6 in the right eye and 1.0 in the left eye. Intraocular pressure were within the normal range bilaterally. The right eye showed nasal conjunctival hyperemia without increased secretion or eye pain. Irrigation testing of the lacrimal passage showed partial lacrimal duct obstruction. A painless palpable mass was presented in the lacrimal sac area with a smooth surface. Other aspects of the examination including the anterior segment, optic disc and fundus were within normal limits in both eyes. There was no palpable regional lymphadenopathy.

Magnetic resonance imaging showed a mass involving the lacrimal sac and lacrimal duct, extending to the right ethmoid sinus via lamina papyracea. Bone destruction of the medial orbital wall were seen. The medial rectus muscle, inferior oblique muscle and portions of the orbital fat were also involved. The left orbit was within normal limits.

Incisional biopsy under general anesthesia was planned. Histological examination disclosed dense fibrous connective tissue with numerous lymphocytes and plasma cells. Immunohistochemistry stains of CD20, CD3, and CD45RO were all positive.

Following the surgery, she was prescribed 50 mg oral prednisone with a 10-mg taper each following week. The symptoms were completely resolved. After 12 months of treatment, no remaining tumor was seen on MRI imaging. At the most recent three-year follow up, there was no evidence of recurrence.

**Conclusion:** Bone destruction is a very rare complications of orbital masses, and their occurrence should always lead to further investigation, including biopsy, to rule out malignancy or other aggressive orbital diseases. Idiopathic orbital inflammation should be considered in the differential diagnosis when bone destruction of the orbital wall was found on imaging.

P-348

**Bilateral ophthalmomyiasis in a patient with basal cell Carcinoma: a case report**J Timones<sup>1</sup>, A Ortiz<sup>1</sup>, R Barairo<sup>1</sup>.<sup>1</sup>*Ophthalmology, Jose R. Reyes Memorial Medical Center, Manila, Philippines*

**Objective:** To report a case of a previously diagnosed case of basal cell carcinoma, which presented with maggots in eyes, bilaterally.

**Methods:** Case Report

**Results:** An 84-year-old man presented at our emergency room due to a chief complaint of foreign body sensation on his eyes. Nine years ago, the patient consulted at a private tertiary hospital where skin punch biopsy was done and revealed pigmented basal cell carcinoma. On examination, there was noted ulcerated wound with rolled-up hyperpigmented borders located in the right maxillary, nasomaxillary, and periorbital region extending to the nasal dorsum and left medial canthal area. Multiple mobile, cream-colored fly larvae measuring 4.0 x 1.0 mm were noted periorbitally, bilateral. Topical lidocaine solution was applied to immobilize the maggots, which were then removed using sterile forceps. Species identification of the maggots was not done since the specimen was not properly preserved. The patient received anti-tetanus vaccine and was subsequently sent home with topical antibiotics over the affected areas and oral broad-spectrum antibiotics with anaerobic coverage.

**Conclusion:** Orbital myiasis is a rare disease and is often caused by poor sanitary and hygienic conditions. Once infested, immediate medical attention should be sought to properly manage and prevent further orbital tissue destruction and potential vision loss.

P-349

**An interesting case of orbital swelling**T Singh<sup>1</sup>, P *Shetty*<sup>2</sup>.<sup>1</sup>General Ophthalmology, <sup>2</sup>Oculoplasty, Khan Bahadur Haji Bachooali charitable eye hospital, Mumbai, India**Objective:** A case report of orbital sarcoidosis**Methods:** The case study involves a 49 year old female presenting with left superior orbital mass. Evaluation of the case was done and after a detailed ocular examination and MRI findings, a superior orbitotomy with incisional biopsy was planned. On histopathological examination, non caseating granulomatous lesion of orbit involving the lacrimal gland were found, which further augmented the need of blood investigations and HRCT. Based on HRCT findings, a diagnosis of sarcoidosis was ascertained.**Results:** The case was managed with oral Mycophenolate Mofetil and tapering steroid doses, with documentation of good response as assessed with improvement in ptosis and mass resolution over time.**Conclusion:** Timely diagnosis based on clinical findings coupled with histopathological and radiological evidence can prevent severe complications by early intervention and ensure long term survival of these patients.

**P-350**

**A Rare Case Of Post Traumatic Mono Elevator Deficit**

A Raghuvanshi.

**Objective:** A rare case of post traumatic mono elevator deficit affecting contralateral eye to the traumatic eye

**Methods:** A 19 year old male patient who had history of trauma right eye in road traffic accident 2 months ago, presented in OPD with sudden loss of vision in right eye and drooping of left eye in down gaze.

On examination, there was traumatic mydriasis with optic atrophy in right eye and restricted extraocular movements in elevation, dextro and levo elevation in left eye.

**Results:** A diagnosis of post traumatic mono elevator deficit affecting left eye was made.

**Conclusion:** The unusual thing about this case is that it is affecting eye other than the traumatic eye.

P-351

## Exploring the Patient Experience of Amblyopia via a Qualitative Literature Review and Patient, Caregiver and Clinician Interviews

S Randhawa<sup>1</sup>, N Griffiths<sup>1</sup>, C Panter<sup>1</sup>, R Harrad<sup>2</sup>, N Khuddus<sup>3</sup>, A Webber<sup>4</sup>, C Bouchet<sup>5</sup>, P O'Brien<sup>6</sup>, F Felizzi<sup>5</sup>.

<sup>1</sup>Adelphi Values, Macclesfield, <sup>2</sup>Bristol Eye Hospital, Bristol, United Kingdom, <sup>3</sup>NKB Services, Gainesville, United States, <sup>4</sup>Queensland University of Technology, School of Optometry and Vision Science, Brisbane, Australia, <sup>5</sup>Novartis Pharma AG, Basel, Switzerland, <sup>6</sup>Novartis Business Services Center, Dublin, Ireland

**Objective:** Amblyopia is reduction in visual acuity in one or both eyes due to abnormal development of the visual pathway. This qualitative study explored the experience of amblyopia in adult and pediatric populations, from patient, caregiver and clinician perspectives. Symptoms, impacts on health-related quality of life (HRQoL) and treatment impacts were explored.

**Methods:** A qualitative literature review involved searching bibliographic databases (PubMed, EMBASE and PSYCHINFO), Google Scholar and key conference proceedings. Findings from social media listening (SML) studies in adult and pediatric populations across several countries were also reviewed. Next, one-hour, qualitative interviews were conducted with amblyopia patients, caregivers of children with amblyopia and ophthalmologists to explore the patient experience of amblyopia. Findings from the qualitative literature review, SML studies and qualitative interviews informed development of an amblyopia conceptual model.

**Results:** Twelve data sources were reviewed, including qualitative studies in the literature and SML studies. Overall, 133 individuals/caregivers of children with amblyopia were interviewed (23 adults, 16 adolescents, 47 child-caregiver dyads), plus 10 ophthalmologists from the US, France and Germany.

Frequently reported visual function symptoms across the literature review and the interviews included: blurry vision, impaired depth perception, impaired peripheral vision, and double vision. Amblyopia impacted several HRQoL domains including: daily activities (reading, sports/leisure, using digital devices), school/work (productivity, reading the board, computer use), physical functioning (bumping into things, catching things), emotional wellbeing (frustration, sadness, low self-confidence), and social functioning (difficulty socializing/playing with friends). Patching and corrective lens treatments impacted daily activities (using digital devices, sports/leisure), ability to move around (bumping into things) and productivity at work/school (tasks taking longer). Treatment also impacts on social functioning (bullying/stigma) and emotional wellbeing (low self-confidence, embarrassment, frustration). Symptoms, HRQoL impacts and treatment impacts reported by ophthalmologists were consistent with those reported by patients/caregivers.

**Conclusion:** Qualitative literature review and interview findings provide valuable insight into adult and pediatric experiences of amblyopia, supporting development of an amblyopia conceptual model.

P-352

### Comparison of PW-ROP, DigiROP and STEP-ROP prediction models in predicting severe retinopathy of prematurity in Chinese population

L Lu<sup>1</sup>, C Lai<sup>2</sup>, M Fan<sup>3</sup>, W Yip<sup>1</sup>, A Young<sup>1</sup>.

<sup>1</sup>Department of Ophthalmology and Visual Sciences, Prince of Wales Hospital, <sup>2</sup>Department of Ophthalmology, Queen Mary Hospital, <sup>3</sup>Department of Ophthalmology, Tung Wah Eastern Hospital, Hong Kong, Hong Kong, China

**Objective:** To compare the accuracy of PW-ROP, DigiROP-Birth and STEP-ROP models for severe retinopathy of prematurity (ROP) requiring treatment in a cohort of Chinese population

**Methods:** In this retrospective cohort study, data from 353 infants who received ROP screening between January 2014 and December 2017 in a tertiary hospital in Hong Kong were used to evaluate the accuracy of three ROP prediction models (PW-ROP, DigiROP-Birth and STEP-ROP) to predict severe ROP requiring treatment. Receiver operating characteristic (ROC) analysis was used to assess the accuracy of these prediction models. The primary outcome measure was the area-under-curve (AUC) of models in ROC analysis. The secondary outcome measures were the sensitivity and specificity of models at the optimal cutoff values.

**Results:** A total of 24 infants (6.8%) developed severe ROP requiring treatment. The AUC values of PW-ROP, DigiROP-Birth and STEP-ROP models were 0.918, 0.834 and 0.794 respectively. The AUC of PW-ROP and DigiROP-Birth were both significantly better than that of STEP-ROP (P=0.005 and P=0.018 respectively). The AUC of PW-ROP was similar to that of DigiROP-Birth (P=0.530). PW-ROP, DigiROP-Birth and STEP-ROP had a sensitivity of 95.8%, 90.5% and 54.2% respectively and a specificity of 75.7%, 60.8% and 95.4% respectively for treatment-requiring ROP at the optimal cutoff values.

**Conclusion:** PW-ROP and DigiROP-Birth were both accurate and better than STEP-ROP in predicting severe ROP requiring treatment in Chinese population. PW-ROP is more useful than DigiROP-Birth since it does not have limits on the range of gestational age that can be tested.



P-353

**Safety and Efficacy of Botulinum Toxin Injection in Consecutive Esotropia.**C Liang<sup>1</sup>.<sup>1</sup>*Ophthalmology, Taichung Veterans General Hospital, Taichung, Taiwan, China*

**Objective:** To investigate the short-term and long-term outcome of botulinum toxin injection for the treatment of consecutive esotropia.

**Methods:** A retrospective study. The treatment outcome of 36 patients with consecutive esotropia who received botulinum toxin injection in the medial rectus muscles was analyzed. The treatment was defined as successful if the final ocular deviation was less than 10 prism diopters (PD).

**Results:** The mean age was  $16.0 \pm 6.2$  years. The mean esodeviation before injection was  $18.8 \pm 6.4$  PD at distance. The mean number of injections per patient was  $1.2 \pm 0.4$ . At 2 months after the final injection, mean angle of deviation was  $5.1 \pm 4.2$  PD at distance and  $5.8 \pm 4.8$  PD at near, and 83.3% of patients showed successful alignment. At 6 months after the final injection, mean angle of deviation was  $7.8 \pm 6.3$  PD at distance and  $7.5 \pm 6.4$  PD at near, and 63.9% of patients showed successful alignment. There was no any recurrence of exotropia noted during the 6-months follow up period. Immediate success, even minor overcorrection at 2 weeks after injection was a favorable predictive factor. The reported complication included ptosis in 6 patients (16.6%) and exotropia in 5 patients (13.8%) within two weeks after injection, and all resolved within 1 month.

**Conclusion:** Botulinum toxin injection for the treatment of consecutive esotropia is safe and effective. Immediate success, even minor overcorrection at 2 weeks after injection was a sign of favorable long-term outcome.

P-354

### Pattern of presentation and management of orbital cellulitis among patients attending Prince Mutaib Bin Abdulazziz Hospital (PMH)

A Akinfe.

**Objective:** To study the risk of orbital cellulitis and multidisciplinary management in Aljouf Region of Northern KSA

**Methods:** A retrospective study of orbital cellulitis managed in Prince Mutaib Bin Abdulazziz Hospital of Aljouf Region was conducted among patients referred and admitted between 2017 and 2019. Orbital Cellulitis was diagnosed among 9 patients all within the pediatric age group (3 – 16) years. The clinical symptoms, signs, investigations performed and the approach of management were recorded into a proforma.

**Results:** Of the nine patients, eight had unilateral disease while one had bilateral orbital cellulitis. Two cases were secondary to trauma. Fever was present in six patients. Upper respiratory tract infection and features of sinusitis were present in four patients. There were no prior abdominal symptoms and signs among the patients. Eight patients had elevated white blood cell count above  $> 10,000 /\text{mm}^3$  and all nine patients had elevated erythrocyte sedimentation rate. Blood culture was negative after 48hrs in all the patients with commencement of broad-spectrum parenteral antibiotic. Chest radiological features of resolving multiple small nodular or reticulonodular opacities was reported in five patients. Positive Computed Tomography (CT) Scan findings (Evidence of soft Tissue Inflammation) was observed in eight patients, especially ethmoidal sinusitis (Figure 1) among older children and maxillary sinusitis. CT-Scan with Cerebral Abscess was found in one patient (Figure 2). All cases had multidisciplinary approach to their management. Eight patients had full recovery with broad spectrum parenteral antibiotic treatment. One patient had surgical intervention of abscess drainage with subsequent full recovery.

**Conclusion:** People with periorbital cellulitis experience a swelling of the eyelid in one eye. A 2020 article notes that it is more common in children than in adults<sup>4</sup>. In rare cases, the infection can cause complications<sup>5</sup>. However, most cases resolve after 5–7 days of taking antibiotics as discovered among all the studied patients<sup>6</sup>.

P-355

**Gradenigo´s Syndrome: Report of a case of twice occurrence**G Yradi García, A Oñate Diaz.**Objective:** To present a clinical case of an uncommon pathology involving eye and ear manifestations.**Methods:** Registration of clinical findings consistent with diagnosis of Gradenigo´s Syndrome on two times in the same patient.**Results:** A diabetic 52-year-old female with history of penetrating trauma in both ears due to a metallic foreign body (hair clip), 7 days later develops left otalgia, periorbital pain and ipsilateral hemicranial headache plus binocular horizontal diplopia; decides to visit a family healthcare practitioner evidencing acute suppurative otitis media and tonsillitis beginning antibiotic treatment (amoxicillin-clavulanic acid) without improvement symptoms. As a result, azithromycin was delivered, persisting diplopia. Eye examination revealed in primary position of gaze: constant esotropia, Hirschberg test + 45° and limitation of abduction on left eye, pupillary light reflex were normal, fundoscopy with no signs of diabetic retinopathy, neurological and systemic examination showed unremarkable. Blood test: HbA1c 9.5%. Normal cranial CT scan. Monthly conservative management in collaboration with an otorhinolaryngologist succeeded complete resolution of paralytic strabismus at 3 months of follow-up. 24 months later, patient consults presenting the same symptoms and etiopathogenic mechanism in opposite eye, currently receiving treatment.**Conclusion:** This syndrome can manifest by clinical triad of otitis media, ipsilateral VI nerve palsy and orbito-facial pain in the distribution of V cranial nerve. It's secondary to petrous apicitis as a complication of acute otitis media. Diagnostic challenges stem from more than half of cases did not show up with classical triad, moreover, petrous apicitis cannot always be demonstrated at the time of diagnosis. Furthermore, widespread use of broad-spectrum antibiotics limits the prevalence of this syndrome, hence currently is a unusual pathology with a low index of suspicion, probably directing initial assessment to differential diagnoses such as compressive intracranial lesions, becoming imaging studies important. Gradenigo´s Syndrome is a rare and potentially life-threatening disease, thereby early diagnosis and treatment are essential, especially in the setting of a patient with recurrences and comorbidities.

P-356

**Effect of Orthokeratology on Moderate to Severe Myopia : A Retrospective Follow-up Analysis**P Kuan<sup>1</sup>.<sup>1</sup>*Ophthalmology, Show-Chuan Memorial Hospital, Changhua, Taiwan, China*

**Objective:** Myopia is a serious public health issue, especially in East Asian. Patients with early onset or moderate myopia in childhood are at higher risk of developing high myopia in the future, and may lead to various complications. Several methods have been used widely for control moderate to severe myopia. In this study, we aimed to report our experience with orthokeratology in retarding axial length elongation.

**Methods:** We conducted a retrospective chart review in Show Chwan Memorial Hospital. We included patients with following criteria: (1) age between 6-18 year-olds, (2) spherical equivalent over 3.00 D under cycloplegia, (3) follow up for at least 18 months and (4) no other ocular pathology were enrolled in our study.

**Results:** There were 135 patients received orthokeratology in the two years interval while another 135 patients received spectacle lens or contact lens correction were set as the control group. The mean spherical equivalent at baseline was  $4.58 \pm 1.97$  D in the study group and  $4.90 \pm 2.23$  D in the control group ( $p=0.34$ ). After the follow interval of 18 months, the mean spherical equivalent showed  $4.53 \pm 2.16$  D in the study group which was better than the spherical equivalent of  $6.77 \pm 3.29$  D in the control group. About the elongation of axial length, the men axial length at baseline was  $24.61 \pm 1.14$  mm in the study group and  $24.45 \pm 1.21$  mm in the control group without statistical significant ( $p=0.31$ ). After the follow-up period, the final axial length is  $24.99 \pm 1.27$  in the study group which similar to the initial length ( $p=0.24$ ) but the final axial length in the control group had prominently elongated ( $27.53 \pm 1.93$ ,  $p=0.03$ ).

**Conclusion:** Orthokeratology is effective in managing moderate to severe myopia and retard axial length elongation.

P-357

**Giant Neonatal Orbital Ganglioglioma with Spontaneous Resolution**C Liang<sup>1</sup>.<sup>1</sup>*Ophthalmology, Taichung Veterans General Hospital, Taichung, Taiwan, China*

**Objective:** To report the nature cause of a case of giant neonatal orbital ganglioglioma originating from ectopic neural tissue.

**Methods:** A case report.

**Results:** An otherwise healthy male baby presented at birth with proptosis and expansion of the left orbit. A giant discrete soft-tissue mass was located inferolateral to the globe with intraconal and intracranial extension. The lesion was proved to be a ganglioglioma by biopsy. After 6 years of conservative observation, the size of tumor gradually decreased. Sequential neuroimage clearly illustrated the nature course of tumor regression. Although the optic nerve was encased by the ganglioglioma, his visual function developed well and his visual acuity reached 20/20 in both eyes at age of 6 years old.

**Conclusion:** Optic nerve gangliogliomas are rare tumors that need to be distinguished clinically from pilocytic astrocytomas and other orbital neoplasms. Ganglioglioma grow slowly, careful follow-up is advised. Fortunately, the tumor of our patient resolved spontaneously without visual function impairment.

P-358

### Study on Ocular Biological Parameters and Visual Function Parameters of Pre-Myopia Children Under Screening

T Wang.

**Objective:** To study and analyze the ocular structural biological parameters and visual function parameters of Pre-Myopia children under screening.

**Methods:** Cross sectional study design. A total of 15082 primary school students in a district of Tianjin, China in 2018 were screened, aged 6-13 years, with an average age of  $(9.16 \pm 1.70)$ . Eye examination included eye health, intraocular pressure, ocular axis length, phoria, stereopsis, accommodative facility, visual fatigue score, etc. According to the Pre-Myopia definition by the International Myopia Institution (IMI), 4002 children with  $-0.50 \text{ D} > \text{SE} \leq +0.75 \text{ D}$  and astigmatism  $< -1.50 \text{ D}$  were screened, with an average age of  $(8.32 \pm 1.40)$  years. The eye function and eye structure were examined.

**Results:** The proportion of these "Pre-Myopia" children in the total screening was 26.53% (4002 / 15082), of which 82.48% (3301 / 4002) had normal binocular vision, 6.95% (278 / 4002) had low binocular vision, and 10.57% (423 / 4002) had low monocular vision. The mean value of the right eye axis was  $(22.94 \pm 0.72)$  mm, the mean value of the left eye axis was  $(22.94 \pm 0.72)$  mm. The mean value of of flat K of right eye was  $(42.47 \pm 1.48)$  D; the average value of steep K of right eye was  $(43.64 \pm 1.53)$  D, the average value of flat K of left eye was  $(42.46 \pm 1.36)$  D, the average value of steep K of left eye was  $(43.67 \pm 1.45)$  D. The average value of right eye corneal diameter was  $(12.06 \pm 0.67)$  mm, the mean corneal diameter of the left eye was  $(12.07 \pm 0.41)$  mm. The mean intraocular pressure of the right eye was  $(16.59 \pm 3.93)$  mmHg and that of the left eye was  $(16.68 \pm 3.44)$  mmHg. The average degree of phoria of these children was  $(-3.70 \pm 5.34)$   $\Delta$ , the average value of stereopsis was  $(70.56 \pm 69.97)$  arc seconds, the average AF of OU was  $(7.19 \pm 3.79)$  cpm, the average AF of OD was  $(8.27 \pm 4.01)$  cpm, the average AF of OS was  $(8.22 \pm 4.03)$  cpm, and the average score of visual fatigue score was  $(8.18 \pm 7.65)$ .

**Conclusion:** It is necessary to pay attention to the ocular structure, biological parameters and visual function of Pre-Myopia children, especially those with low vision, in order to help predict the outcome of refractive power.

P-359

### Dichoptic binocular therapy and electronic devices for amblyopia treatment

M Rodríguez Abarca<sup>1</sup>, S Padilla Alanís<sup>1</sup>, A Rodríguez Martínez<sup>1</sup>, K Mohamed Noriega<sup>1</sup>, M Fernández de Luna<sup>1</sup>.

<sup>1</sup>Department of Ophthalmology, Hospital Dr. José Eleuterio González, Monterrey, Mexico

**Objective:** To determine if binocular dichoptic and monocular occlusive therapies with or without the use of electronic devices are effective for the management of amblyopia in children

**Methods:** A prospective randomized double blinded study was conducted in our institution with 37 amblyopic children, aged from 4 to 10 years. The inclusion criteria were diagnosis of amblyopia anisometric, strabismic and mixed (both). Participants were assigned into 3 groups: the first(1<sup>st</sup>) group: patch on the fellow eye with near vision activities, the second(2<sup>nd</sup>) group: patch on the fellow eye with the use of electronic devices and the third(3<sup>rd</sup>) group: with binocular red-green glasses and electronic devices. The treatment was prescribed for 16 weeks with 2 consecutive hours daily. Study follow-up visits were scheduled every month during treatment and 2 months after to evaluate amblyopia relapse. With assessment of the best corrected visual acuity (BCVA) using the ETDRS chart and stereopsis using the Titmus test. Associations for categorical variables were tested via Pearson's Chi Squared test. A generalized linear model was performed to model the mean change of logmar across time treating time as a categorical variable and by testing group by time interactions. A p value <.05 was pre-specified for statistical significance. All tests were two-tailed. All analyses were done in R statistical package.

**Results:** A total of 37 amblyopic children (18 boys and 19 girls) were recruited, 18 (47%) with anisometric, 13 (35%) with strabismic and 6 (16%) with mixed amblyopia; 27 (73%) were classified as moderate and 10 (27%) with severe amblyopia. In the 1<sup>st</sup> and 2<sup>nd</sup> group were assigned 13 patients each, and 3<sup>rd</sup> one 11 patients. A statistically significant improvement was obtained in the BCVA in all three groups (1st one from 0.69 to 0.45 logMAR  $p=0.024$ , 2nd one from 0.67 to 0.50 logMAR  $p=0.050$  and 3rd one from 0.63 to 0.40 logMAR  $p=0.032$ ) compared from baseline up to 16 weeks of treatment, with stabilization of the visual acuity after cessation of the treatment. No improvement in stereopsis was observed in any of the 3 groups.

**Conclusion:** The binocular red-green glasses group demonstrated improvement of BCVA in the amblyopic eye as well as in the other groups of treatment.

**P-360****Exophoric shift in distance cover test were found after wearing Virtual Reality games 30 minutes in University Students.**

W Lee<sup>1</sup>, K Iuo<sup>1</sup>, C Chen<sup>2</sup>.

<sup>1</sup>Ophthalmology, Chung-Shan Medical University Hospital, <sup>2</sup>Optometry, Chung Shan Medical University, Taichung, Taiwan, China

**Objective:** To compare the binocular vision effects after practiced two different kinds, dynamic and static, of virtual reality (VR) games.

**Methods:** A total of 11 healthy (without ocular injury or surgery) subjects, age 20 to 22, performed two different types of VR games (shooting and space game) and each for 30 minutes. There was a twenty minutes break between two games. Assessments were performed before and after using HTC VIVE™ headset device including visual acuity (VA), intraocular pressure (IOP), cover test, Maddox Rod, Von Graefe, Vergence Range, amplitude of accommodation (AA) and accommodative facility (AF). Also, we investigated subjective performances with questionnaires to understand the habitual of using electronic devices and the feeling after playing the VR games.

**Results:** No significant difference in VA whether at near or distance after VR exposure. IOP in right eye was statistically dropped after playing the static game. There was an exophoric shift at distance cover test both after static and dynamic games which consisted with the subjective assessment. With playing VR games, subjects' distance phoria with cover test seemed to have significant horizontal change both in space game ( $p = 0.031$ ) and shooting game ( $p = 0.035$ ). This did not happen in near phoria with space ( $p = 0.499$ ) and shooting ( $p = 0.396$ ) game. Also, there was no notable change between two games whether at distance ( $p = 0.269$ ) or near ( $p = 0.879$ ). Horizontal phoria in distance by using Maddox rod was not have a significant change after space ( $p = 0.322$ ) and shooting ( $p = 0.688$ ) game or between both two ( $p = 0.641$ ). This also occurred in vertical,  $p = 0.341, 0.341, 0.221$ , after space, shooting and between both, respectively. In near phoria, after playing space, shooting or between two games, there was no notable difference in horizontal ( $p = 0.127, 0.288, 0.508$ , respectively) or vertical ( $p = 0.341$  in all) direction. 71.4% felt more blurred in vision quality through questionnaire after exposure of dynamic game.

**Conclusion:** Though VA at far or near distance and AA were not statistically significant difference, a distance exophoric shift of deviation in cover test and a decreased of IOP were found. Also, worse vision quality after VR games subjectively were observed, especially in dynamic game. Indicated that it could require more visual functions in more exciting games and should be discussed more in the future study.



**P-361****Underestimated poorer compliance of myopia control among first elementary school students in Asian population.**K Luo, W Lee<sup>1</sup>.<sup>1</sup>*ophthalmology, Chung Shan Medical University Hospital, Taichung City, Taiwan, China*

**Objective:** To investigate the status of refractive disorder and current myopia control status in first year of one elementary school students.

**Methods:** With informed consents, we performed screening for refractive status, Axial length (AXL), Best-corrected visual acuity, stereo test and cover/uncovered test for strabismus in first year of one elementary school students.

**Results:** We set-up widescreen station in elementary school and screened total first year of one elementary school students (n=171) and totally 46 kids with refractive myopia (26.9% among total numbers). Further check showed 11 kids (23.9% among myopia children, 6.4% among total numbers) without regular follow up or long term mydriasis for myopia control. In these 11 cases, we found 7 cases with amblyopia (4.1% among total numbers) without any vision training, 3 with tropia/phoria and 6 with abnormal stereometry. The mean myopia conditions of 11 cases as following:  $-1.64D \pm 1.22D$  with cylinder  $-1.34 \pm 0.84(OD)$ ,  $-1.64 \pm 1.78D$  with cylinder  $-1.36 \pm 1.15D(OS)$ . BCVA:  $0.89 \pm 0.46(OD)$ ,  $0.81 \pm 0.54(OS)$ . AXL:  $23.053 \pm 0.936(OD)$ ,  $23.071 \pm 0.923(OS)$ .

**Conclusion:** Underestimated poorer compliance of myopia control and poorer amblyopia training in first year of elementary school students were found in Asian population. Further larger scale and longer follow up as for treatment or not should be conducted for more persuasive comments.

P-362

**Soft peripheral defocus contact lens for myopia control in Asian children: preliminary result**W Lee<sup>1</sup>, K Luo<sup>2</sup>, C Chen<sup>3</sup>.<sup>1</sup>Ophthalmology, Chung-Shan Medical University Hospital, Taichung, <sup>2</sup>Ophthalmology, Chung Shan Medical University Hospital, Taichung City, <sup>3</sup>Optometry, Chung Shan Medical University, Taichung, Taiwan, China**Objective:** To investigate myopia control effect in Asian children who wear two different kinds of daily soft peripheral defocus contact lens.**Methods:** Under the permission of institutional review board (IRB number:CSH1-20136). We got written informed consents from 115 children. Then we recruited group A (n=59) and group B (n=56) children in elementary school age and wear daily disposable peripheral defocus soft contact lens separately. Before study, refractive status and keratometry, best-corrected visual acuity and axial length (AXL) were checked. Proper usage and manual of wearing soft contact lens were instructed to children and parents before study. At least 10 hours of wearing of daily disposable peripheral defocus soft contact lens were enforced. Further check point like 3 months and 6 months so far were inspected.**Results:** In beginning, the mean age in group A and group B was  $11.13 \pm 2.02$  and  $10.66 \pm 1.72$  years old respectively. The mean refractive status in group A: sphere  $-2.55 \pm 1.32D$ , cylinder  $-0.26 \pm 0.36 D(OD)$  and sphere  $-2.57 \pm 1.17 D$ , cylinder  $-0.19 \pm 0.25 D(OS)$ . The mean refractive status in group B: sphere  $-2.09 \pm 1.24D$ , cylinder  $-0.07 \pm 0.15D(OD)$  and sphere  $-2.19 \pm 1.17D$ , cylinder  $-0.10 \pm 0.21D(OS)$ . The mean AXL in group A:  $24.76 \pm 0.90mm(OD)$  and  $24.77 \pm 0.84mm(OS)$ . The mean AXL in group B was  $24.34 \pm 0.89mm(OD)$  and  $24.37 \pm 0.88mm(OS)$ . 6 months later, average 8 hours of wearing every day. The cycloplegic refractive status in group A: sphere  $-2.71 \pm 1.32$  cylinder  $-0.24 \pm 0.37D(OD)$  and sphere  $-2.77 \pm 1.14D$ , cylinder  $-0.16 \pm 0.25D(OS)$ . The cycloplegic refractive status in group B: sphere  $-2.22 \pm 1.25$  cylinder  $-0.07 \pm 0.15D(OD)$  and sphere  $-2.36 \pm 1.16D$ , cylinder  $-0.10 \pm 0.21D(OS)$ . The mean AXL in group A was  $24.87 \pm 0.95mm(OD)$  and  $24.91 \pm 0.87mm(OS)$ . The mean AXL in group B was  $24.48 \pm 0.89mm(OD)$  and  $24.52 \pm 0.90mm(OS)$ . The mean changes of refractive status: In group A sphere more  $-0.16 \pm 0.28D$ , cylinder  $-0.02 \pm 0.10D(OD)$  and sphere  $-0.13 \pm 0.24D$ , cylinder  $-0.02 \pm 0.10D(OS)$ . In group B sphere more  $-0.10 \pm 0.27D$ , cylinder  $-0.00 \pm 0.00D(OD)$  and sphere  $-0.13 \pm 0.23D$ , cylinder  $-0.00 \pm 0.00D(OS)$ . The mean AXL changes in group A was  $+0.12 \pm 0.11(OD)$  and  $+0.10 \pm 0.11(OS)$ . The mean AXL changes in group B was  $+0.10 \pm 0.09(OD)$  and  $+0.11 \pm 0.11(OS)$ . All these parameters showed no significant changes.**Conclusion:** Daily wearing peripheral defocus contact lens could slower the progression of myopia in Asian children. Further and longer follow-up for these kind of soft contact lens should be conducted for long-term evaluation.

P-363

### The Visual Outcomes of Add-on Perceptual Learning for Bilateral Refractive Amblyopic Children in Taiwan

H Huang<sup>1</sup>, H Huang<sup>2</sup>.

<sup>1</sup>Department of Ophthalmology, Chang Gung Memorial Hospital, Chiayi County, <sup>2</sup>Department of Ophthalmology, Chang Gung Memorial Hospital, Kaohsiung City, Taiwan, China

**Objective:** The aim of this study was to evaluate the visual outcomes of standard amblyopic treatment add-on training by perceptual learning in bilateral amblyopic children and identified the associated risk factors for poor response to treatment.

**Methods:** Retrospective charts were reviewed in children with bilateral amblyopia that received add-on Cambridge Visual Stimulator (CAM) training. Bilateral amblyopia was defined as best corrected visual acuity (BCVA) < 20/25 in both eyes and no interocular difference of two lines. The amblyopic children enrolled had worn full-corrected glasses for at least 2 months before add-on CAM training. Children who did not complete the ophthalmological exams or had any types of strabismus, ocular structural abnormalities, or coexisting systemic diseases were excluded. Treatment success was defined as BCVA  $\geq$  20/25. The age at initiation of training, gender, initial BCVA, refractive errors, sessions and duration of training, and final BCVA were recorded and analyzed.

**Results:** A total of 63 children, (mean age  $5.02 \pm 1.04$  years) who had undergone add-on CAM training were enrolled. The mean initial logMAR BCVA was  $0.43 \pm 0.27$ . Six children had hypermetropia (10%), 2 children had myopia (3%) and 50 children had astigmatism (79%). Twenty-eight eyes were mixed type. Nineteen of them were hypermetropia with astigmatism and 9 eyes were myopia with astigmatism. Eighty-seven percent (55/63) of bilateral amblyopic children achieved treatment success with a median of 5 sessions of add-on CAM training. The final BCVA was  $0.06 \pm 0.20$  at 6 months. The poor initial BCVA ( $P < 0.001$ ) and high astigmatism ( $P = 0.007$ ) were the risk factors for treatment failure after add-on CAM training. Neither the age at initiation of treatment, gender, nor types of refractive errors, was associated with treatment success.

**Conclusion:** More than 80% of patients aged 4 to 9 years achieved BCVA  $\geq$  20/25 after add-on CAM training in 2 months. Poor initial BCVA and high astigmatism were important risk factors for treatment failure in bilateral amblyopic children. Add-on CAM training is presumed to be an effective strategy to fasten the VA improvement and promote reaching optimal VA when the effect of standard treatment is limited in amblyopic children.

**P-364****Fourth nerve palsy in a healthy and asymptomatic child with Covid-19 infection**M Kiarudi, A Gharouni.

**Objective:** Covid-19 can affect almost all organs of body. However the most prominent signs and symptoms of corona virus are about respiratory system ; from a mild flu-like symptom to lethal respiratory distress. Covid 19 can cause a wide range of ocular manifestations. The most common ocular manifestation is conjunctivitis. Neuro-ophthalmic presentations of Covid-9 are rare. Some reports has shown sixth and third nerve palsy in Covid-19 infection. Herein, We presented a case of trochlear nerve palsy in a healthy coronavirus infected patient.

**Methods:** A healthy 10-year-old boy presented to our clinic with complaint of acute abnormal head posture. His past medical history was unremarkable.

Complete ophthalmologic examination was performed. Uncorrected visual acuity was 10/10 in each eye. There was no ptosis. Pupils were round and regular and reactive to light. There was no relative afferent pupillary defect. The slit lamp examination and fundus examination were unremarkable. There was left eye hypertropia and esotropia with mild abduction limitation of both eyes. There was no history of ocular trauma. There was also no headache and neurologic or respiratory symptoms.

After interviewing the parents, it was revealed that his mother had recent covid-19 infection confirmed with reverse transcriptase polymerase chain reaction (RT-PCR) for SARS-CoV-2. Because the concern of Covid-19 infection, comprehensive strabismus examination was not performed and the patient was referred to an infectious disease specialist and he got tested for SARS-COV-2 with nasopharyngeal swab specimen. The test was positive and SARS-COV-2 was detected. Also, the patient referred to neurology department. Brain and orbital MRI was performed and was unremarkable. Only conservative treatments was administered and patient was followed. After nine month follow up from May 2021 to April 2021, esotropia and abduction limitation was improved however, there was left hypertropia (10 prism diopters) increased in left gaze and inferior oblique overaction consisting with left superior oblique palsy. Also the patient had compensatory right head tilt.

**Results:** We reported a unilateral acute painless left trochlear nerve palsy in a healthy and asymptomatic boy with Covid-19 infection. Neurologic consult and investigations were also performed and were unremarkable.

**Conclusion:** We emphasize on the need to keeping in mind the possible occult COVID-19 infection among children presenting with abnormal head posture and recent diplopia.

P-365

**Increased frequency of low dose 0.01% atropine in combination of orthokeratology for myopia control**C Chen, Y Ting<sup>1</sup>, C Huang<sup>1</sup>, K Lin<sup>1</sup>.<sup>1</sup>Ophthalmology, Wan Fang Hospital, Taipei Medical University, Taipei, Taiwan, China

**Objective:** Orthokeratology(OK) and low dose atropine have both proved to be effective options in myopic control for children. Recent studies showed synergistic effect of combined OK and atropine treatment for myopia control. However, some children's myopia tends to progress despite under the treatment of OK lens combined with low dose 0.01% atropine eye drops once a day. We demonstrate improved myopia control via increasing the 0.01% atropine eye drops frequency.

**Methods:** This is a retrospective study of children aged under 18 years old who received OK lens combined with atropine eye drops between January 2018 to February 2022. These subjects were followed up for more than 24 months. Myopia control was treated with OK combined with low dose 0.01% atropine eye drops once a day initially. At approximately 6 months follow up, frequency of the 0.01% atropine eye drops was increased to twice a day due to myopia progression. axial length(AL) was measured every 3 months with the AL-Scan (Nidek Co, Ltd., Gamagori, Japan). AL increase rates were monitored for the effectiveness of the treatment.

**Results:** This study enrolled 20 eyes from 10 Taiwanese children who had AL elongation rates exceeding 0.2mm/year despite OK lens combined with low dose 0.01% atropine eye drops once a day. Demographics of the selected patient contains 6 boys and 4 girls, aged 9 to 16 years old (mean age 13.5) with baseline AL ranging from 22.98mm to 27.17mm(mean AL 24.74mm). AL elongation rates of OK combined with low dose atropine once daily was 0.278 mm/year. AL elongation rates decreased to 0.159 mm/year when low dose atropine frequency was increased to twice daily. Doubling the frequency of atropine eye drops showed a 0.119 mm/year decrease in the AL elongation rate (Mean difference= -0.119, 95% Confidence interval= -0.052 to -0.187, p=0.0015).

**Conclusion:** Our study suggests that increasing the frequency of low dose 0.01% atropine eye drops was effective in decreasing the rates of myopia progression in patients who originally had relatively poor control of myopia progression despite OK lens combined with low dose 0.01% atropine eye drops once a day. However, due to the limitations of small sample size and retrospective study, further prospective or randomized controlled trial with larger samples sizes are needed

P-367

**Effect of strabismus surgery and vision therapy on unilateral amblyopia: a retrospective comparative study**J Lo<sup>1,2</sup>, J Wang<sup>2</sup>.<sup>1</sup>Ophthalmology, Chang Gung Memorial Hospital, Kaohsiung, <sup>2</sup>Ophthalmology, Chang Gung Memorial Hospital, Chiayi, Taiwan, China

**Objective:** In this study we aimed to evaluate the effect of strabismus surgery and vision therapy for teenage children and young adults who exhibited unilateral amblyopia and strabismus.

**Methods:** Patients with unilateral amblyopia and strabismus between the ages of 10 and 32 at Kaohsiung and Chiayi Chang Gung Memorial Hospital between 2018 and 2021 were retrospectively reviewed. The study group was patients who received strabismus surgery and further vision therapy, including part-time patching and full refraction correction for at least 6 months. Visual acuity and age-matched unilateral strabismic amblyopes were considered as the control group. The initial and final visual acuity, eye position, and stereopsis were analyzed between the two groups.

**Results:** A total of 10 patients were included in the study group and 12 patients as controls. After receiving strabismus surgery and vision therapy, the study group showed mild improvement in best corrected visual acuity, with a mean of  $0.21 \pm 0.13$  logMAR versus  $0.004 \pm 0.096$  logMAR when comparing with the control group ( $p = 0.045$ ). The eye position of residual or recurrent deviation was less than 10 prism diopters in most of the study group when follow-up 6 months after strabismus surgery, while one patient who received a previous unilateral strabismus surgery in the other hospital presented 15 to 20 prism diopters deviation 3 months after our surgery. The study group also showed improvements in stereopsis from  $230.54 \pm 132.49$  to  $118.27 \pm 59.08$  arc seconds, while there was nearly no change in the control group.

**Conclusion:** Strabismus surgery and vision therapy may help to improve visual acuity, eye position and stereopsis in teenagers and young adults with unilateral amblyopia.

P-368

**Ocular Trauma in School-aged Children in a Metropolitan Hospital in Taiwan: An Retrospective Analysis**P Kuan<sup>1</sup>.<sup>1</sup>*Ophthalmology, Show-Chuan Memorial Hospital, Changhua, Taiwan, China*

**Objective:** Ocular trauma is one of the leading causes of unilateral blindness in children. According to previous studies, 21% to 51% patients retained visual acuity of < 20/40 in the injured eyes despite surgical intervention. The aim of this study is to analyze the cause and visual outcome of school-age children with ocular trauma in a metropolitan hospital in Taiwan.

**Methods:** A retrospective chart review was performed and included school-age child aged 6 to 18 years old, who presented with eyeball rupture to ophthalmology department of the Show Chwan Hospital. Data collected included demographic profile; lesion site; cause of trauma; complications; and best-corrected visual acuity (BCVA) in first and last follow-up visit.

**Results:** There are totally 20 eyes in 20 patients. Twelve patients (60%) were male, average age was 11.3 years, and mean follow-up was 4.1 months. The causes include accidents (16 patients, 80%) and violence (4 patients, 20%). Penetrating ocular injury was the most common trauma (13 patients, 65%), followed by rupture (3 patients, 15%). The preoperative visual acuity ranged from 0.2 to hand move 30cm which revealed. After treatment as eyeball rupture repair and remove intraocular foreign body, our patients have much improvement with mean BCVA reached 0.5 and three patients reached an excellent result of 1.0. About complication, one patient developed endophthalmitis after treatment and received evisceration.

**Conclusion:** Accident is the most common reason for ocular trauma in school-aged children, and most of them presents with penetrating ocular injury. Ocular trauma may lead to complications like endophthalmitis and results in poor visual outcome.

P-369

**Correlation between Routine Blood Indicators and Severity of Retinopathy of Prematurity**Y Wang, Y Xiao.

**Objective:** To analyze the risk factors affecting the onset and severity of retinopathy of prematurity (ROP), and to provide a basis for clinical prevention and treatment and to reduce the severity of ROP.

**Methods:** Retrospective analysis of the results of ROP fundus screening in preterm infants in Kunming Children's Hospital from January 2018 to December 2021, divided into no ROP group, pre-threshold group, threshold group, and aggressive posterior ROP (AP-ROP) group, collected the general condition of children, clinical laboratory data blood routine, analyzed the correlation between risk factors and the onset and severity of ROP, used rank sum test and logistic regression analysis to establish relevant risk factors, and assessed the early predictive value of each index on ROP by plotting the subject work characteristic (ROC) curve.

**Results:** The rank-sum test showed that the differences in gestational age, daytime age, and birth weight were statistically significant ( $P < 0.05$ ) in the four groups compared in the no-ROP, pre-threshold, threshold, and AP-ROP groups. The white blood cell count, neutrophil count, monocyte count, hemoglobin, and NLR ratio were significantly lower and the LMR ratio was significantly higher in the three ROP groups compared to the children in the no-ROP group, and the differences were statistically significant ( $P < 0.05$ ). Multi-factor logistic regression analysis suggested that birth weight, gestational age, hemoglobin, NLR, and LMR were independent risk factors for the development of ROP ( $P < 0.05$ ). The ROC curve showed that the area under the curve for LMR was 0.651 (95% CI: 0.605-0.698), with a best predictive value was 7.36, corresponding to a sensitivity of 55.8% and a specificity of 71.4%.

**Conclusion:** Birth weight, gestational age, hemoglobin, and NLR are independent risk factors for ROP, with birth weight, gestational age, and hemoglobin as protective factors. LMR has some early predictive value for ROP.



**P-370****Retinopathy associated aplastic anemia**A Urióstegui-Rojas.

**Objective:** To present for the international ophthalmology a rare case of retinopathy associated aplastic anemia in a boy of 10 years old.

**Methods:**

After his admission to the pediatrics service, he reports painless and sudden visual loss of 1 day of evolution, Therefore,

Interconsultation is requested to the ophthalmology service, finding visual acuity of 20/400 and 3/200, the funduscopy was found:

Subhyaloidal hemorrhages throughout the posterior pole with foveal involvement as well as in vascular arcades.

**Results:**

It was decided to initiate a joint approach with pediatric hematology, who indicated blood transfusion since he had hemoglobin of 4g/dl;

After this there was improvement in visual acuity at 20/200 both eyes, however the clinical evolution was torpid, achieving with 2 more transfusions; a hemoglobin of 10g/dl, however, presented neurological deterioration, as well as hypovolemic shock and unfortunately died.

**Conclusion:** This is the first case reported in the Mexican literature in a pediatric patient of retinopathy associated with severe aplastic anemia.

P-372

**The role of the establishment of vision health files in the work of children's eye care clinics**J Zheng, D Wang, C Gao.

**Objective:** The objective of this study was to analyze the role of vision health files in children's eye care clinics.

**Methods:** The method was retrospectively analyzed 2011 cases of 3-12-year-old children who established vision health files in children's eye health clinics from 2018 to 2021, of which 1435 cases of vision health files were established for three consecutive years, 576 cases were in the control group who did not establish vision health files for 3 consecutive years, and the development and change of children's refractive status were dynamically observed in the past 3 years, and the changes in children's vision health status, development trends, and the effects of interventions were analyzed and evaluated. The child's current refractive status is observed after the intervention is developed.

**Results:** The refractive status of the children in the control group was greater than that in the observation group, and the observation group of visual health level was better than that of the control group.

**Conclusion:** By establishing a vision health file in a children's eye care clinic, the decisions related to vision health at each step will be based on evidence, more accurate and effective.

P-373

**Long-term safety of V4c posterior chamber intraocular lens implantation for the correction of myopia in China**Y Chen<sup>1</sup>, J Zhou<sup>1</sup>.<sup>1</sup>Refractive surgery department, Chengdu Aier EYE Hospital, Chengdu , People's Republic of China

**Objective:** To observe the long-term safety of V4c posterior chamber intraocular lens implantation (ICL V4c) for the correction of myopia in China over 5 years.

**Methods:** A retrospective study. Patients from Chongqing Aier Eye Hospital with complete 5-year or more follow up were selected which underwent ICL V4c surgery in 2015. The uncorrected distant visual acuity(UCVA), best corrected visual acuity(BCVA), spherical equivalent (SE), intraocular pressure(IOP), corneal endothelial cell density (ECD), axis length (AL), vault, anterior chamber parameters and complications were recorded before and after surgery. A paired t test, Wilcoxon signed rank test and Pearson correlation were used for statistical analysis.

**Results:** A total of 38 eyes from 20 patients were selected. The average follow-up time was ( $52.4 \pm 5.2$ ) months after operation. Before the ICL, the UCVA was  $1.37 \pm 0.26$ , the BCVA was  $0.03 \pm 0.05$ , and the SE was ( $-10.74 \pm 2.74$ )D. At the last visit, the safety index is  $1.21 \pm 0.19$ , and the effective index is  $0.85 \pm 0.29$ ; the mean vaults was ( $424 \pm 250$ )  $\mu\text{m}$  (range, 14 $\mu\text{m}$  to 1060 $\mu\text{m}$ ). The results of the last visit compared with those before operation: the UCVA increased and the BCVA was better, the difference was statistically significant ( $t = 27.63, 5.761, P < 0.001$ ). There was no significant difference in IOP or AL ( $t = 1.737, 5.761, P > 0.05$ ). The ECD decreased by an average of 4.5%. No serious complications were observed.

**Conclusion:** In 5 years of follow-up, the ICL V4c demonstrated high safety and satisfaction in myopic correction.

P-374

**Effects of chilled saline irrigation on small incision lenticule extraction (SMILE) surgery**Y Li, Y Shen<sup>1</sup>, W Li<sup>1</sup>, W Li<sup>1</sup>.<sup>1</sup>*Shenzhen Heima ophthalmology clinic (Shenzhen Branch Hospital of Idearl Eye Hospital Affiliated to Suzhou University) , Shenzhen, People's Republic of China*

**Objective:** To investigate the effect of using the chilled saline(4°C) on small incision lenticule extraction (SMILE) surgery on the effect of ultra-early visual correction and its influence on the prognosis.

**Methods:** In this prospective, single-masked, randomized study, 202 patients(404 eyes) who underwent SMILE were randomly divided into an observation group and an control group, 101 patients(202 eyes) in each group. Immediately after lenticule extraction, in the observation group, the corneal cap and the corneal incision were flushed with chilled saline, while the control group was flushed with room temperature saline. Primary outcomes measured were ocular irritation symptoms, opaque bubble layer (OBL), diffuse interlamellar keratitis(DLK), uncorrected (UCVA) and best-corrected (BCVA) visual acuities.

**Results:** The ocular irritation symptoms in the observation group were milder than those in the control group at 2h postoperatively, and the recovery of visual acuity at 2h and 24h postoperatively was significantly faster than in the control group, but there was no statistical difference in uncorrected visual acuity (UCVA) between the two groups at 7d postoperatively( $p>0.05$ ). The incidence of DLK in the observation group was lower than that in the control group, and the difference was significant( $p=0.041$ ).

**Conclusion:** Chilled saline irrigation can reduce the emergency response of corneal tissue after SMILE, relieve ocular irritation, promote vision recovery, and reduce complication rate.

P-375

## Application of Tomography Biomechanical Index in Preoperative Screening of Early Keratoconus During Refractive Surgery

? 刘, ? 贺<sup>1</sup>.

<sup>1</sup>准分子激光科, 山西省眼科医院, 山西省太原市, People's Republic of China

**Objective:** To evaluate the TBI value in early keratoconus by observing the morphological and biomechanical changes of LASIK and FS-LASIK.

**Methods:** The clinical records for 117 eyes of 72 patients who received LASIK or FS-LASIK were reviewed and analyzed. According to the TBI, they were divided into two groups: normal group (TBI<0.29) and suspicious group (TBI≥0.29). In both groups, Preoperative and postoperative parameters measured by Pentacam anterior segment analyzer and Corneal visualization Scheimpflug technology were both collected.

**Results:** In both two groups, The height of the corneal posterior surface of the thinnest point before surgery were higher than 1 month after surgery (P<0.05). There was no statistically difference in the height of the corneal posterior surface of the thinnest point between 1 month and 3 years after surgery (P≥0.05). And there was no statistically difference in the height of the corneal posterior surface of the thinnest point between the two groups before surgery, 1 month and 3 years after surgery (P≥0.05). Deviation of average pachymetric progression (Dp), deviation of ARTmax (Da) and Pentacam Random Forest Index (PRFI) in the suspicious group were higher than those in the normal group before and 3 years after surgery (P<0.05). Ambrósio's Relational Thickness to the horizontal profile (ARTh) in the suspicious group were lower than the normal group before and 3 years after surgery (P<0.05). Kmax and inferior-superior difference value (I-S value) in the suspicious group were higher than those in the normal group before surgery (P<0.05). There were no statistically differences in PRFI, I-S value, Kmax, Dp, Da and ARTh between the two groups before and 3 years after surgery (P≥0.05). TBI was taken as the dependent variable, and PRFI, I-S value, Dp, Da, ARTh were taken as concomitant variables for multiple logistic regression analysis. PRFI was associated with TBI value changes (B=12.729, OR=21.986, P<0.01).

**Conclusion:** 1. Patients with TBI>0.29 and preoperative corneal posterior surface height of incomplete bridge or decreasing bridge showed no corneal dilation during 3-years follow-up after LASIK and FS-LASIK.

2. When the height pattern of the posterior corneal surface was incomplete or decreased, TBI>0.29 was mainly associated with PRFI.

3. TBI value alone cannot be used as a Biomechanical Index for screening early keratoconus. Change in other parameters should also be considered comprehensively.

P-377

**Intraocular Pressure Compensation vs. Flowrate in a Closed System during Vitreoretinal Surgeries.**M Charles, V Wuyyuru, Y Zhu, K Phan, C Garufis.

**Objective:** Maintaining a stable intraocular pressure (IOP) is important in vitreoretinal surgeries. The purpose of this study was to understand the IOP performance and infusion flow performance during different vitrectomy procedures with IOP controlled by a vitrectomy system in a controlled bench environment.

**Methods:** A hollow acrylic eye model was set up in five different surgical scenarios: 1) injecting Brilliant Blue G (BBG), 2) injecting Triescense, 3) injecting Perfluorocarbon (PFC) 4) during proportional reflux and 5) using high flow with high speed Vit probes. CONSTELLATION® Vision System was used with IOP compensation and infusion pressure setting at 25mmHg. For each injection scenario, 6 runs were performed. For the high flow (300 & 650 mmHg) and the proportional reflux scenarios, 3 different 25G Hypervit beveled vitrectomy probes were used with 3 runs per probe.

A syringe pump (Harvard Apparatus, Pump 33) created an injection speed of 6cc/min. A flow sensor (Transonic Systems Inc, 4PXN) was connected to the infusion canula, and a pressure sensor (OMEGA, PX409-001GUSBH) was connected to an eye model to record instant value of flow and IOP inside the eye. Average IOP, average infusion flow rate, average flow transition time, and average IOP transition time were calculated. Transient time was defined as the time period between two stable statuses.

**Results:** During the injection of BBG, Triescense and PFC, the average negative infusion flows were  $-6.07 \pm 0.06$ ,  $-6.09 \pm 0.49$  and  $-6.45 \pm 0.04$  cc/min and corresponding IOPs were,  $31.86 \pm 0.73$ ,  $31.31 \pm 1.19$ , and  $31.52 \pm 0.43$  mmHg respectively. For proportional reflux scenario, the average negative flow rate and IOP were  $-5.58 \pm 0.22$ cc/min and  $27.25 \pm 0.24$ mmHg. For high flow aspiration at 300 and 650 mmHg vacuum, average positive flow rates were  $8.17 \pm 0.26$ cc/min and  $14.99 \pm 0.35$ cc/min and IOPs were  $25.93 \pm 0.37$  and  $26.80 \pm 0.30$ mmHg respectively

For all the scenarios, the first and second flow transition times ranged from  $1.14 \pm 0.10$  to  $2.29 \pm 0.60$ sec and  $1.04 \pm 0.13$  to  $2.37 \pm 0.45$ sec; first and second IOP transition times ranged from  $0.64 \pm 0.21$  to  $2.82 \pm 0.51$ sec to and  $0.66 \pm 0.15$  to  $4.09 \pm 0.70$ sec.

**Conclusion:** IOP compensation provides a stable environment for vitreoretinal surgeries. The flow and IOP pressure in the eye had an inverse relationship. In a closed system, flow dynamics compliments IOP compensation.

P-379

## Intraocular Pressure (IOP) Performance of 25-Gauge and 27-Gauge Dual-Cutting 20,000cpm Beveled Vitrectomy Probes

V Wuyyuru, Y Zhu<sup>1</sup>, C Garufis<sup>1</sup>.

<sup>1</sup>Alcon, Lake Forest, United States

**Objective:** This study aims to 1) understand the IOP performance of 25+<sup>®</sup> Gauge (Ga) and 27+<sup>®</sup>Ga dual-cutting, 20K cuts per minute (cpm) beveled vitrectomy probes used for vitreous removal during a vitrectomy; 2) understand the operation time of vitreous removal during a vitrectomy.

**Methods:** 25+<sup>®</sup> and 27+<sup>®</sup> Ga HYPERVIT<sup>®</sup> beveled 20K cpm vitrectomy probes were driven by a CONSTELLATION<sup>®</sup> Vision System (Alcon Vision, LLC.) to aspirate vitreous in a hollow acrylic eye model. A digital transducer (OMEGA, PX409-001GUSBH) was connected to the bottom of eye model to detect IOP change during aspiration. 4cc of fresh porcine vitreous was filled into the eye model per testing. For both probe gauges, six samples were tested under core duty cycle, vacuums of 250mmHg, 450mmHg and 650mmHg and cut rate of 20,000cpm. In this study, 1) average vitreous IOP fluctuation during aspiration, 2) final stable BSS IOP and 3) average operation time of vitreous removal were calculated for each test setting.

**Results:** Enabling IOP compensation significantly reduced average vitreous IOP fluctuation rate in the 25+<sup>®</sup> Ga at vacuums of 250, 450 and 650 mmHg ( $p < 0.05$ ). Similarly, average vitreous IOP fluctuation rate significantly decreased with the 27+<sup>®</sup>Ga for the same vacuums compared with IOP off ( $p < 0.05$ ). No significant difference of IOP fluctuation rate was shown between each vacuum setting ( $p > 0.05$ ).

Without IOP compensation, the final stable BSS IOP after removing vitreous with the 25+<sup>®</sup> probes at the three vacuums were  $22.11 \pm 1.80$  mmHg,  $15.12 \pm 0.41$  mmHg and  $7.11 \pm 1.20$  mmHg. With IOP compensation, an average vitreous IOP of  $30.75 \pm 0.24$  mmHg,  $30.72 \pm 0.84$  mmHg, and  $30.52 \pm 0.92$  mmHg was maintained for the same vacuums.

Without IOP compensation, the final stable BSS IOP after removing vitreous with the 27+<sup>®</sup> probes at vacuums of 250, 450, and 650 mmHg were  $23.14 \pm 0.50$ ,  $16.05 \pm 0.79$ , and  $8.49 \pm 0.44$  mmHg, respectively. With IOP compensation, an average of  $31.32 \pm 0.93$ ,  $31.33 \pm 1.01$ , and  $31.46 \pm 1.09$  mmHg was maintained for the same vacuums. Corresponding operation times of complete removal of vitreous were decreased with increasing vacuum settings for all trials.

**Conclusion:** During vitreous removal at the maximum cut rate, 25+<sup>®</sup> Ga and 27+<sup>®</sup> Ga 20K cpm vitrectomy probes with IOP compensation maintain IOP at improved levels with less fluctuations compared with no compensation. Using IOP compensation and 20K cpm vitrectomy probe in 25+<sup>®</sup> and 27+<sup>®</sup> Ga vitrectomy procedure can help surgeons achieve a stable and efficient vitreous removal process.

P-380

### The effect of vitrectomy and ILM- pilling on the vessel density of the macula among patients with macular epiretinal membrane

D Zubkova<sup>1</sup>, Y Dobritsia<sup>2</sup>, I Pastukh<sup>1</sup>, I Chubenko<sup>1</sup>, M Kovtun<sup>1</sup>.

<sup>1</sup>Ophthalmological, N.V. Karazin Kharkiv National University, <sup>2</sup>Ophthalmological, Kharkiv national medical university, Kharkiv, Ukraine

**Objective:** It is obvious that the improvement of surgical techniques makes it possible to successfully treat various vitreoretinal pathologies, including interventions on the layers of the retina. From our point of view, it is interesting to observe the vessel density of the macular zone after vitrectomy and internal limiting membrane (ILM) pilling among patients with idiopathic macular epiretinal membrane which may help to explain the increase in retinal edema after such operations.

**Methods:** In this retrospective study medical records of the 23 patients (aged  $59.3 \pm 7.8$ ) with idiopathic macular epiretinal membrane. Pars plana vitrectomy with ILM-pilling was performed. The difference between preoperative and postoperative small retinal vessel density in the superficial and deep plexus was detected by OCT-A on the 1<sup>st</sup> day, the 1<sup>st</sup>, the 4<sup>th</sup> and the 12<sup>th</sup> week after the operation.

**Results:** There was significant increase in the small retinal vessel density in both superficial and deep plexus at the 1<sup>st</sup> day ( $P < 0,001$ ), the 1<sup>st</sup> ( $P < 0,01$ ), the 4<sup>th</sup> week ( $P < 0,01$ ) after the operation. By 12<sup>th</sup> week, the density of retinal capillaries did not significantly differ from the preoperative one ( $P > 0,05$ ).

**Conclusion:** This study shows that retinal vessel density in both superficial and deep plexus increases in short-term follow-up after vitrectomy and internal limiting membrane pilling among patients with idiopathic macular epiretinal membrane.



P-381

## Development of Surgical Management in Rhegmatogenous Retinal Detachment

L Machanka, A Dalidovich.

**Objective:** To evaluate the evolution of surgical methods over a 12-year period in patients with primary rhegmatogenous retinal detachment (RRD).

**Methods:** This retrospective, nonrandomized comparative study included patients over 18 years of age with primary RRD who underwent surgery at the Ophthalmology Department of the Belarusian State Medical University from January 2008 to December 2019. All patients with RRD underwent either scleral buckling (SB), pars plana vitrectomy (PPV) alone or PPV + SB (encircling band) with 20-gauge (until 2012 year), later - 23-gauge or 25-gauge instrumentation. All surgical procedures were done by two surgeons.

**Results:** In total, 1035 primary retinal detachments were recorded during the 12 - year period. An external approach with scleral buckling was used in 522 cases (50.4%), pars plana vitrectomy alone was used in 476 eyes (46.0%), whereas a combination of PPV + SB in 37 eyes (3.6%). Performing of vitreoretinal surgery increased from 13,6% in 2008 and 34,8% in 2009 to 70,1% in 2018 and 72,4% in 2019. The relative proportion of buckle surgery decreased from 86.7% in 2008 and 67.5% in 2009 to 29.9% in 2018 and 27.6% in 2019. The combination of PPV + SB decreased from 3.4% in 2008 and 11.2% in 2009 to 1.6% in 2016 and not using from 2017. Liquid silicone tamponade was applied less frequently over the years. In retinal detachment surgery, vitreal tamponade was performed using gas in 13.5% of eyes, silicone oil in 74.0% of eyes in 2008, and respectively in 56.3% and 25.8% in 2019.

In terms of the population served by the hospital (about 0.9 million people), the medium prevalence of RRD was 8.1 per 100,000, ranged from 6.7 to 15.6 over 12 years with no consistent upward trend. It was 6.1 in 2008, 7.9 in 2018 and 5.9 in 2019.

**Conclusion:** The strategies for surgical repair of retinal detachment have changed in recent 12 years: less buckle surgery, more vitrectomy, less encircling buckles and silicone tamponade. Nevertheless, the successful treatment of about one-third of patients with SB has its advantages, especially for more younger patients. SB remains a selective treatment for uncomplicated RRDs.

P-382

**Bilateral Endogenous Endophthalmitis in Klebsiella Oxytoca Multiple Organ Dysfunction Syndrome**

D Ee See Ong<sup>1</sup>, S Mohd Khialdin<sup>1</sup>, W Wan Abdul Halim<sup>1</sup>, M Catherine Bastion<sup>1</sup>, Y Meng Hsien<sup>1</sup>, A Bin Omar<sup>1</sup>.

<sup>1</sup>Ophthalmology, Faculty of Medicine, UKM, Kuala Lumpur, Malaysia

**Objective:** To present a case of endogenous endophthalmitis from disseminated Klebsiella oxytoca bacteremia with multiple organ dysfunction syndrome (MODS)

**Methods:** Case report

**Results:** A 55-year-old male with poorly controlled diabetes mellitus presented with high fever, cough, vomiting, diarrhea and lethargy, without initial ophthalmic complaint. He was in septic shock with MODS, causing respiratory distress and liver failure along with renal shutdown, needing inotrope and ventilatory support. Radiologic investigations revealed liver abscesses and hepatic vein thrombosis. Blood culture grew Klebsiella oxytoca. His systemic infection was treated successfully with broad spectrum intravenous antibiotics which was subsequently adjusted according to the culture sensitivity. Referral to ophthalmology happened after one week of admission for his bilateral blurring of vision during admission. Initial ophthalmic assessment revealed visual acuity (VA) of 6/60 OD, 3/60 OS. Anterior segment examination showed bilateral cells with keratic precipitates and Koeppe nodules. Fundus examination showed bilateral dense vitritis, chorioretinitis with choroidal abscess and overlying retinal hemorrhage. He was treated with repeated intravitreal antibiotics with negative vitreous cultures. After two weeks of repeated intravitreal antibiotics treatment on top of his preexisting systemic antibiotic, his condition improved with VA 6/24 OD, 6/18 OS, hence avoided vitrectomy.

**Conclusion:** Klebsiella oxytoca bacteremia is a rare but potentially serious infection with multiorgan involvement compared to other Klebsiella infection. Endogenous endophthalmitis with choroidal abscess caused by Klebsiella oxytoca warrants a prompt ophthalmic intervention to preserve good visual outcome.

P-383

## Global Evaluation of Hospital-based Care Delivery Costs Associated with Vitreoretinal Surgeries: A Targeted Literature Review

H Cheng<sup>1</sup>, C Duperrouzel<sup>2</sup>, A Zhou<sup>2</sup>, R Kara<sup>1</sup>, K Mills<sup>1</sup>.

<sup>1</sup>Alcon Vision, LLC, Fort Worth, Texas, United States, <sup>2</sup>EVERSANA, Burlington, Ontario, Canada

**Objective:** Economic evaluations are an important consideration for the assessment of the overall value of specific interventions. Cost assessments can be evaluated from multiple perspectives, including the patient side and care organization side. These cost inputs should be setting- and region-specific. The purpose of this study was to identify current published global hospital costs associated with vitreoretinal surgeries in different regions of the world.

**Methods:** A targeted literature search was conducted in Ovid EMBASE and MEDLINE for studies published from 2014–2019. Articles in English that reported hospital costs (for diagnostics, procedures, monitoring, staff, facility, medications, anesthesia, consumables, complications, and administration/overhead) for vitreoretinal surgeries were included. Costs were converted and adjusted to 2020 USD.

**Results:** Fifty-one specific costs from five articles were identified that included five countries: Italy, England, Indonesia, Norway, and Greece. The median surgery-specific cost of care delivery was \$1,713.91. The minimum reported overall costs were from Indonesia, where local anesthesia-specific costs were \$233.71, compared to a maximum overall cost reported from England, at \$2,584.99.

**Conclusion:** This review captured a variety of hospital costs for vitrectomy surgeries that may be used for future assessment-of-care-delivery economic models. Dramatic country-specific differences were noted. Increased publication of global- and country-based cost-assessments would be important in the future to help provide benchmarks for the critical value of vitreoretinal surgery.

P-384

### Vitreous Flow Rate of 25-Gauge and 27-Gauge Dual-Cutting 20,000CPM Beveled Vitrectomy Probes during Vitreous Removal

V Wuyyuru, K Phan, Y Zhu, C Garufis.

**Objective:** 1) To evaluate the vitreous flow rate of the 25+<sup>®</sup> Gauge (GA) and 27+<sup>®</sup> GA dual cutting 20,000 cuts per minute (cpm) beveled vitrectomy probes under various system settings; 2) Compare the performance of the 20K beveled probes with previous generation 10K beveled probes

**Methods:** The 25+ GA and 27+ GA HYPERVIT<sup>®</sup> beveled 20K vitrectomy probes were driven by the CONSTELLATION<sup>®</sup> Vision System (Alcon Vision, LLC.) to aspirate porcine vitreous. A precision balance (Mettler Toledo, XS) was used to chart and record mass change during aspiration over 1 minute.

Flow rates were evaluated ranging from 2.5K to 20K cpm. Three duty cycles were evaluated for each cut rate: core, 50/50, and shave. Vacuum was kept constant at 650 mmHg. For each probe gauge, 6 probes were used to measure flow rate and each duty cycles' cut rate was tested 3 times each. Average flow rate was calculated for each setting and statistical analysis was performed using Welch's T-Test with a statistical significance level of  $p < 0.05$ .

**Results:** At the maximum cut rate for the three duty cycles of core, 50/50, and shave, the 25+<sup>®</sup>GA probe flow rates were  $3.52 \pm 0.26$ ,  $3.47 \pm 0.27$ , and  $3.64 \pm 0.15$  cc/min, respectively. Corresponding flow rates for the 27+<sup>®</sup>GA probes were  $2.17 \pm 0.16$ ,  $2.09 \pm 0.18$ , and  $2.07 \pm 0.22$  cc/min, respectively. Statistical analysis indicated significant differences in flow rate for cut rates less than 7.5K cpm compared to the maximum cut rate under same duty cycles and vacuum ( $p < 0.05$ ) and no significant difference was shown between each duty cycle ( $p < 0.05$ ) for both probe gauges.

When operating at maximum cut rate of 20K cpm at core duty cycle, the 25+<sup>®</sup>GA and 27+<sup>®</sup>GA HYPERVIT<sup>®</sup> beveled achieved flow rates 27.54% and 26.90%, respectively, higher than the previous generation 25GA and 27GA Advanced ULTRAVIT<sup>®</sup> probe flow rates at maximum cut rate of 10K cpm, ( $p < 0.05$ ).

**Conclusion:** The aspiration flow rate did not significantly change by duty cycle for all cut rates for both 25+<sup>®</sup>GA and 27+<sup>®</sup>GA HYPERVIT<sup>®</sup> beveled 20K vitrectomy probes. In addition, for all probes, aspiration flow rates increased as cut rate increased. In comparison with previous generation Advanced ULTRAVIT<sup>®</sup> probes, the HYPERVIT<sup>®</sup> beveled vitrectomy probes achieved higher flow rates.

P-385

**Retinal prosthesis implantation surgeries and patient outcomes**J Zhang.

**Objective:** Retinitis pigmentosa is the most common hereditary fundus dystrophy, affecting 1 in 5000 individuals. Retinal prosthesis implantation restores functional vision for blind individuals. This is a review on device- and surgery- related adverse events, determinants of successful surgical outcomes, patient selection criteria for surgeries and variations in surgical procedures.

**Methods:** Published PubMed studies on prosthesis implantation surgeries for retinitis pigmentosa patients during clinical trials and after approval were analysed. Further literature search was conducted to analyse safety profile, surgical procedures, and determinants of surgical outcomes.

**Results:** Younger age at the time of surgery is significant in predicting better performance from multiple regression analysis. A greater number of electrodes activated during assessments and later age of diagnosis tend to lead to favourable outcomes. Above-mentioned patients performed well consistently in several assessment domains and could adapt to the prosthetic vision more effectively. Following successful surgery, the rudimentary visual information permits simple tasks and independent navigation, measured quantitatively and qualitatively, leading to a significant improvement for blind individuals. Ecological validity of functional tests, such as line test, object recognition and object localisation, is limited because of their departure from reality. FLORA, conducted in real-world environments by observers, lacks standardization across subjects. Salient feature identification tests (e.g., picture and face discrimination) demonstrate marked improvement in subsequent testing, suggesting that learning and adaptation to visual prostheses occur with practice.

Modifications to the original surgical procedures reduced complication rates: the scleral flap can protect the sclerotomy site and is self-healing; the use of autograft lowers risks of infections, disease transmission and immune reaction and allows faster graft incorporation. Improved device design, modified surgery and prophylactic antibiotic injection led to improved patient outcomes. Cortical plasticity and perceptual leaning have implications in visual restoration with prostheses. Neuronal remodelling of the retina after long-term disuse may occur in retinitis pigmentosa due to the loss of photoreceptors.

**Conclusion:** Patient outcomes, adverse events, risk factors and modifications to surgical procedures are summarised in this review.

P-386

**Primary result of Advanced UltraVit 10000CPM in rhagmatogenesis retinal detachment**R Gu, J Zhao<sup>1</sup>, C Jiang.<sup>1</sup>EENT hospital, Shanghai, People's Republic of China

**Objective:** To invest the safety and efficiency of high-speed vitreous cutter - Advanced UltraVit 10000CPM in vitrectomy for complicated rhegmatogenous retinal detachment (RRD).

**Methods:** Patients with complicated RRD and received primary vitrectomy in our hospital were included (21.3-21.10). All of them underwent vitrectomy using Constellation and Advanced UltraVit 10000CPM system.

**Results:** 60 RRD patients were included, 16 of them had PVR higher than C, 8 had giant tear, 11 had choroidal detachment, 17 had retinal tears in multi quadrants, 1 had vitreous hemorrhage after trauma, 6 were pseudophatic, 9 had macular holes and together peripheral tears. All were treated successfully with Constellation and 10K IIT system, average surgical duration was 59 minutes, with 0.84 minutes for central vitrectomy, and 22 minutes to clear the periphery vitreous, the average residual peripheral vitreous was about 2/3 the Port-tip distance. Iatrogenic retinal holes happened in 15 cases, with 6 happened directly by the cutter, 6 happened while creating posterior vitreous detachment with the cutter, and 3 caused by other instruments. Silicone oil was injected at the end in 57 cases, and gas in the other 3. At present, mean 6 months after operation; 2 cases underwent another procedure because of retinal redetachment, 28 of them had removed the silicone oil and retina was still attached.

**Conclusion:** The primary results suggested that Advanced UltraVit 10000CPM cutter system was safe and efficient in vitrectomy for complicated RRD.

P-387

**Paracentral acute middle maculopathy secondary to acute retinal necrosis by Zoster Herpes.**

A Moreno Martínez, E Judez<sup>1</sup>, J García García<sup>1</sup>, S Copete<sup>1</sup>.

<sup>1</sup>Hospital Perpetuo Socorro, Albacete, Spain

**Objective:** Paracentral acute middle maculopathy is a tomography finding associated to several ophthalmological and systemic conditions with visual acuity decrease and multiple paracentral scotomas. We present a case of a patient affected by paracentral acute middle maculopathy in acute retinal necrosis context.

**Methods:** We describe a patient with several vascular comorbidities affected by acute retinal necrosis (ARN). Anterior chamber paracentesis and polymerase chain reaction (PCR) confirmed varicella-zoster virus positive. She was treated with oral Valganciclovir and prednisone and intravitreal ganciclovir 2mg/0,1 ml, developing a hyper-reflective band spanning the inner nuclear layer compatible with paracentral acute middle maculopathy (PAMM).

**Results:** A 74-year-old female developed best corrected visual acuity (BCVA) decrease from 0.6 to 0.1 (Snellen chart), macular edema and epiretinal membrane developing a hyper-reflective band spanning the inner nuclear layer, without outer retinal layer affectation, compatible with PAMM. It was resolved six months after of the beginning of the symptoms accompanied of no reactivation signs of ARN and macular edema. In a ARN context, she experimented a retinal detachment that was treated with vitrectomy, scleral buckle and intraocular silicone oil. At final visit, we observed a progressive inner retinal layer thinning with BCVA decreased from 0.1 to 0.01 (Snellen chart).

**Conclusion:** Although no previously described it, PAMM could develop in a ARN context secondary to Zoster herpes virus experimenting permanent visual acuity decrease

P-389

## Anti-Tubercular Therapy in the Treatment of Tubercular Uveitis: A Systematic Review and Meta-analysis

B Betzler<sup>1</sup>, I Putera<sup>23</sup>, I Testi<sup>4</sup>, R La Distia Nora<sup>25</sup>, J Kempen<sup>678</sup>, O Kon<sup>9</sup>, C Pavesio<sup>4</sup>, V Gupta<sup>10</sup>, R Agrawal<sup>111213</sup>.

<sup>1</sup>Yong Loo Lin School of Medicine, National University of Singapore, Singapore, Singapore, <sup>2</sup>Department of Ophthalmology, Faculty of Medicine Universitas Indonesia, Jakarta, Indonesia, <sup>3</sup>Department of Immunology, Erasmus Medical Center, Rotterdam, Netherlands, <sup>4</sup>Moorfields Eye Hospital, London, United Kingdom, <sup>5</sup>Department of Immunology, Erasmus Medical Center, Rotterdam, Netherlands, <sup>6</sup>Department of Ophthalmology, Massachusetts Eye and Ear Infirmary and Harvard Medical School, Boston, United States, <sup>7</sup>Myungsung Christian Medical Center (MCM) Eye Unit, MCM General Hospital and Myungsung Medical School, <sup>8</sup>Department of Ophthalmology, Addis Ababa University School of Medicine, Addis Ababa, Ethiopia, <sup>9</sup>Chest and Allergy Clinic, St Mary's Hospital, London, United Kingdom, <sup>10</sup>Advanced Eye Centre, Postgraduate Institute of Medical Education and Research, Chandigarh, India, <sup>11</sup>National Healthcare Group Eye Institute, Tan Tock Seng Hospital, <sup>12</sup>Lee Kong Chian School of Medicine, <sup>13</sup>Singapore Eye Research Institute, Singapore, Singapore

**Objective:** This meta-analysis quantitatively evaluates the efficacy of anti-tubercular therapy (ATT) in tubercular uveitis (TBU) patients.

**Methods:** Data was pooled using a random-effect models (DerSimonian and Laird method) to evaluate 6 treatment outcomes in patients with versus without ATT: (1) inflammation recurrence; (2) inflammation reduction; (3) complete resolution of inflammation; (4) improved visual acuity (VA); (5) ability to taper corticosteroids to < 10 mg/day without inflammatory progression; (6) use of adjunctive immunosuppressants while on ATT.

**Results:** 940 publication records were identified from the electronic database search, of which 49 studies were included, with a pooled total of 4,017 participants, of which 3,141 received ATT. Substantial heterogeneity in drug combinations and duration for ATT was observed. The most common treatment regimen was H/R/Z/E for four months followed by H/R for two months, with or without systemic/topical/periocular corticosteroids. Pooled treatment success was 74.9% (61.9-86.1) in patients treated for ≤ 6 months, versus 90.2% (82.9-95.9) in patients treated for > 6 months.

### Outcomes with ATT (non-comparative studies)

Incidence of inflammatory recurrence was 13% (95%CI:9-18). Incidence of inflammatory reduction was 81% (95%CI:62-95). Complete resolution of inflammation in 83% (95%CI:77-89). VA improved in 65% (95%CI:51-78).

### Outcomes without ATT (non-comparative studies)

Incidence of inflammatory recurrence was 46% (95%CI:23-69). Complete resolution of inflammation was achieved in 69% (95%CI:29-98).



**Outcomes with versus without ATT (comparative studies)**

OR of inflammatory recurrence was 0.33 (95%CI:0.19-0.60,  $p<0.001$ ) for TBU patients treated with ATT. Complete resolution of inflammation occurred more frequently with ATT (OR=1.33, 95%CI:0.72-2.46,  $p=0.31$ ), although this was insignificant.

**Conclusion:** ATT administration is associated with more favorable resolution of active inflammation, reduced inflammatory recurrence, and better visual acuity outcome in TBU patients. We encourage future longitudinal studies to report robust details on treatment outcomes, duration, complications, loss to follow up, and follow-up duration, in well-delineated subgroups with well-defined regimens and treatment indications.

P-390

**Comparison between HSV-1 and MCMV Induced Anterior Uveitis: in vitro and in vivo**Y Li<sup>1</sup>, K Wang<sup>1</sup>.<sup>1</sup>Eye Center of the 2nd Affiliated Hospital, School of Medicine, Zhejiang University, Hangzhou, People's Republic of China

**Objective:** To compare the differences between herpes simplex virus type 1 (HSV-1) and murine cytomegalovirus (MCMV) induced anterior uveitis (AU), both in vitro and in vivo.

**Methods:** Primary murine trabecular meshwork cells (MTMCs) were infected by HSV-1 and MCMV in a same low multiple of infection (MOI), respectively, to investigate virus replication and morphological changes in vitro. Then, anterior chamber inoculation of HSV-1 and MCMV were performed to establish AU models in rats. Clinical manifestations, intraocular pressure (IOP), and histological characteristics were observed in these two virus-induced AU models.

**Results:** HSV-1 exhibited greater inhibition of viability and developed cytopathy effect (CEP) earlier than MCMV in MTMCs. In vivo, typical AU occurred in both groups, characterized by fibrin exudation, keratic precipitates (KP) in HSV-1 group, whereas MCMV group developed mild inflammation. In contrast to HSV-1 group, half of rats in MCMV group experienced significant IOP elevation in the first week after infection, which was highly correlated with the severity of AU. Examinations of light microscopy, electron microscopy and immunofluorescence revealed that anterior segment tissues, especially trabecular meshwork cells could be infected by both HSV-1 and MCMV. Mitochondrial edema and autophagosome were found only in HSV-1 group.

**Conclusion:** MTMCs were more vulnerable to HSV-1 than MCMV in vitro, and both two viruses had a unique tropism to trabecular meshwork. Trabeculitis and accumulation of inflamed immune cells in the Schlemm's canal might increase the resistance of outflow pathway and lead to IOP elevation.

P-391

**IgG4-related Ophthalmic Disease Manifested as Uveitis: Case Reports of A New Clinical Entity**Y Lee<sup>1</sup>, W Tsao<sup>2</sup>.<sup>1</sup>Department of Ophthalmology, Hualien Tzu Chi Hospital, Buddhist Tzu Chi Medical Foundation, Hualien,<sup>2</sup>Department of Ophthalmology, Yuan's General Hospital, Kaohsiung, Taiwan, China

**Objective:** IgG4-related disease is a newly recognized clinicopathological condition, it has been described in nearly every organ. Regarding ophthalmic involvement, it is well-recognized as sclerosing inflammation in the orbit, adnexa, and sclera. However, little is known about its manifestation as uveitis. There was only limited number of reports showing its presentation as anterior uveitis, panuveitis, retinal vasculitis, or subretinal granuloma. Here in, we share clinical experience of two patients with IgG4-related ophthalmic disease manifested as uveitis, to contribute current understanding of this rare but devastating clinical entity.

**Methods:** Case reports.

**Results:** A 24-year-old female with hyperthyroidism presented with blurred vision of right eye for 2 years. She was treated as sarcoid uveitis at prior hospital. This time, she visited our OPD for second opinion, where examination revealed no anterior chamber cell, but grade 2 of vitreous cells and vitreous haze in the right eye. Optical coherence tomography and fundus fluorescein angiography showed diffuse retinal vasculitis with macular edema. Serology tests reported significant elevations in IgG4, angiotensin-converting enzyme and erythrocyte sedimentation rate, and otherwise normal results. With presumed diagnosis of IgG4-related uveitis OD, the patient was treated with a combination of systemic and topical steroids, and later initiated on immunomodulatory therapy.

Another 73-year-old female with diabetes mellitus and hyperthyroidism presented with blurred vision of her right eye 2 weeks after an uneventful cataract surgery. She had an episode of IgG4-related orbital inflammation treated with oral steroids 4 years ago. On examination, there were trace amount of anterior chamber cells, grade 2 of vitreous cells and vitreous haze. Optical coherence tomography and fundus fluorescein angiography showed posterior retinal involvement. Under the impression of panuveitis OD, we arranged work-up for common etiology and causative pathogens of panuveitis. The serologic studies were all within normal limit except for a significant elevation in IgG4. With presumed diagnosis of IgG4-related panuveitis OD, the patient was prescribed oral steroids, and the intraocular inflammation gradually improved. Her vision returned to normal without sequelae after treatment.

**Conclusion:** When not treated promptly, IgG4-related ophthalmic disease could lead to extirpation of the involved eye. Clinicians should keep awareness of this diagnosis in the survey of uveitis.

P-392

## Occam's Razor Or Hickam's Dictum: Coexistent Ocular Toxocariasis and Juvenile Spondyloarthritis Presenting as Bilateral Panuveitis

R Tanchuling<sup>1</sup>, J Lopez<sup>1,1</sup>, R Maliwat<sup>1</sup>.

<sup>1</sup>Eye Insititute, St. Luke's Medical Center, Quezon City, Philippines

**Objective:** Juvenile spondyloarthritis, an inflammatory disease with a strong genetic association, typically presents with anterior uveitis in 90% of cases; posterior involvement, either isolated or as part of panuveitis, is reported at 10-15%. Meanwhile, ocular toxocariasis, a response to *Toxocara* larval migration, is unilateral in 90%; bilateral toxocariasis is exceedingly rare. We report a case of juvenile spondyloarthritis and presumed ocular toxocariasis affecting both eyes, discussing the pathogenetic contributions of each.

**Methods:** We highlight the case of a 16 year- old male with juvenile spondyloarthritis and presumed ocular toxocariasis affecting both eyes. He presented with generalized pustules, back pain, peripheral polyarthritis, and bilateral panuveitis. Both eyes revealed sequelae of anterior uveitis: anterior and posterior synechiae, corectopia, and occlusio pupillae on the left eye. Right eye fundus photography showed vitritis, disc hyperemia, and granuloma on indentation indirect ophthalmoscopy surrounded by infiltrates and perivascular sheathing. A fibrovascular stalk was seen extending from the granuloma to the disc.

**Results:** B Scan of the left eye showed vitritis and hyperechoic band from the disc to the retinal periphery without aftermovement. Fluorescein angiogram and macular optical coherence tomography of the right eye confirmed cystoid macular edema and papillitis. Lumbosacral magnetic resonance imaging revealed sacroiliitis, fulfilling ILAR and ASAS criteria. Work-up was done to exclude other possible infectious and inflammatory entities. Treatment included steroids and anti-TNF inhibitors with visual acuity stabilization and symptom resolution.

**Conclusion:** This case illustrates a rare co-occurrence of two diseases with significant overlap and unclear pathogenetic contributions from each to cause the observed signs and sequelae. This renders support to studies suggesting the link between rheumatic disease and parasitosis (Zaccone 2006). While diagnostic parsimony by Occam's razor is a good principle to follow in medicine, Hickam's dictum reminds us that Occam's is not the rule, and balance must be maintained.

**P-393****Clinical classification, visual outcomes, and OCT features of 48 patients with posterior sympathetic ophthalmia**H Zhuang<sup>1</sup>.<sup>1</sup>*Eye and ENT Hospital of Fudan University, Shanghai, People's Republic of China*

**Objective:** To investigate the clinical manifestations, visual outcomes and optical coherence tomographic (OCT) features of patients with posterior sympathetic ophthalmia (PSO).

**Methods:** We performed a retrospective review of 48 patients diagnosed with PSO between January 2013 and December 2019. We compared the clinical and OCT features among different clinical types of PSO.

**Results:** PSO could be classified into two types according to whether the fundus exhibited serous retinal detachment (SRD) or multifocal choroiditis (MFC). There were 41 patients (85.4%) with SRD and 7 patients (14.6%) with MFC. The latent period of patients with MFC was significantly longer than that of patients with SRD ( $P = 0.002$ ). The final visual acuity of patients with MFC was significantly worse than that of patients with SRD ( $P = 0.0001$ ). In patients with acute SRD, OCT revealed that the mean height of retinal detachment in the fovea was  $528.8 \pm 437.5 \mu\text{m}$ . After treatment, the retina reattached in all patients and the band structures of the outer retina were restored in most patients (92.7%). In patients with acute MFC, the OCT images revealed inflammatory lesions on the retinal pigment epithelium layer. After treatment, the OCT images showed hyperreflective fibrosis of the lesions and loss of the outer retinal band structures in all patients.

**Conclusion:** We found that PSO could be classified according to the presence of SRD or MFC. The visual prognosis differed significantly between these types of PSO. OCT imaging is useful for clinical classification and monitoring of retinal changes after treatment.

P-394

**Birdshot chorioretinopathy initially misdiagnosed as tubercular multifocal choroiditis**

K Fekih<sup>1</sup>, S khochtali<sup>1</sup>, S Ben Aoun<sup>1</sup>, H Moussa<sup>1</sup>, H Ben Amor<sup>1</sup>, M Khairallah<sup>1</sup>.

<sup>1</sup>ophthalmology, Fattouma Bourguiba university Hospital, Monastir, Tunisia

**Objective:** To report a case of HLA-A29 positive birdshot chorioretinopathy (BCR) initially misdiagnosed as tubercular multifocal choroiditis (MFC).

**Methods:** A single case report. A 45-year-old woman, with a family history of pulmonary tuberculosis, was diagnosed 4 years earlier with tubercular multifocal choroiditis and had received a nine-month regimen of antitubercular therapy associated with systemic steroids.

**Results:** The patient was referred to our department for progressive vision blurring and photopsia. Best-corrected visual acuity was 20/40 in the right eye and 20/32 in the left eye. Anterior segment was calm OU. There was a 2+ vitritis OU. Fundus examination showed bilateral creamy ovoid choroidal lesions involving the posterior pole and the retinal periphery, that were very suggestive of BCR. Fluorescein angiography revealed diffuse periphlebitis. Structural optical coherence tomography showed bilateral epiretinal membrane. Work-up revealed a positive Quantiferon-TB test and a positive HLA-A29. Chest X-Ray was normal and there was no evidence of active extra-ocular tuberculosis. The diagnosis of BCR in a patient with latent tuberculosis was made.

**Conclusion:** BCR may be mistaken for tubercular MFC in patients with latent tuberculosis in countries that are endemic for tuberculosis and where BCR is rare. Careful interpretation of clinical findings and multimodal imaging results are mandatory not to miss the diagnosis of BCR.

P-395

### ICAM-1 and E-Selectin Levels and Their Correlation with Oxidative Stress Markers in Endotoxin-Induced Uveitis

E Doğan<sup>1</sup>, T Goncu Firat<sup>1</sup>, E Oğuz<sup>2</sup>, S Koçarlan<sup>3</sup>, H Sezen<sup>4</sup>.

<sup>1</sup>Ophthalmology, <sup>2</sup>Medical Pharmacology, <sup>3</sup>Medical Pathology, <sup>4</sup>Medical Biochemistry, Harran University School of Medicine, Sanliurfa, Türkiye

**Objective:** To determine the levels of proinflammatory cytokines, intercellular adhesion molecule- 1 (ICAM-1) and E-selectin in an experimental uveitis model. We also aimed to evaluate the oxidative stress and its correlation with ICAM-1 and E-selectin concentrations.

**Methods:** Endotoxin-induced uveitis was induced in Sprague-Dawley rats by lipopolysaccharide injection. After 24 hours, eyes were enucleated, aqueous humor was collected, and the infiltrating cells, protein concentration, and the levels of nitric oxide, tumor necrosis factor- $\alpha$ , interleukin-6, ICAM-1, E-selectin and oxidative stress markers in the aqueous humor were determined. Oxidative stress markers, ICAM-1 and E-selectin concentrations were determined also in the ocular tissue.

**Results:** In uveitis group, infiltrating cells, protein concentration, and inflammatory cytokines were significantly elevated in the aqueous humor compared with the control. E-selectin and ICAM-1 concentrations in the ocular tissue were significantly higher than controls ( $p=0.004$  for both). In the aqueous humor, the increase for E-selectin concentration was significant whereas the increase for ICAM-1 concentration was not statistically significant ( $p=0.004$  and  $p=0.078$  respectively).

**Conclusion:** These results suggest that ICAM-1 and E-selectin increased during the intraocular inflammation. Oxidative stress markers in ocular tissue seem to be more correlated with ICAM-1 and E-selectin levels rather than the aqueous humour oxidative stress markers.

P-396

**Multifunctional Supramolecular Hydrogel with Enhanced Therapeutic Efficacy to Ocular Inflammatory Disease**X Ding<sup>1,2</sup>, X Li<sup>2</sup>.

<sup>1</sup>Aier School of Ophthalmology, Central South University, Changsha, <sup>2</sup>Institute of Biomedical Engineering, School of Ophthalmology & Optometry and Eye Hospital, Wenzhou Medical University, Wenzhou, People's Republic of China

**Objective:** To integrate an antioxidant (3,5-Dihydroxybenzoic acid, DHB), a non-steroidal anti-inflammatory drug (ibuprofen, IPF) and a peptide motif (Gly-Phe-Phe-Tyr-Asp, GFFYD) into an amphiphilic hydrogel eyedrop, and determine whether it can exert synergistic effects to achieve better bioavailability, biocompatibility and therapeutic efficacy to ocular inflammatory disease.

**Methods:** Briefly, 2IPF-DHB-GFFYD was synthesized by solid-phase peptide synthesis method, then characterized by <sup>1</sup>H NMR and LC-MS. Under a heating-cooling procedure, the hydrogel was obtained. Firstly, the microstructure was observed by transmission electron microscope (TEM), the viscoelastic properties by rheometer, the arrangement of chiral molecules by circular dichroism (CD), the releasing behavior by in vitro release test, and resistance to tear flushing by retention test. Secondly, biocompatibility was evaluated by cell viability assay on corneal epithelial cells (HCEC) and macrophages (RAW264.7), and eye irritation test on rabbits. Finally, the anti-inflammatory and antioxidant effect of hydrogel was determined in both the lipopolysaccharide (LPS) -induced RAW264.7 cell model and the endotoxin-induced uveitis (EIU) rabbit model, by means of ELISA, western blot, immunofluorescence, RT-qPCR, flow cytometry, et.al, and validated the underlying molecular mechanisms of NF- $\kappa$ B, JAK-STAT, MAPK, NLRP3, Nrf2 signaling pathways.

**Results:** The hydrogel was relatively transparent with a microstructure of entangled nanofibers and  $\alpha$ -helix-like conformations; rheology results indicated enough mechanical strength, able to resist tear flushing, thereby prolonging ocular retention of drugs which was proved by retention test; in vitro release test indicated an esterase-mediated sustained drug release. In the LPS-induced RAW264.7 model, the hydrogel significantly reduces the production of inflammatory mediator (NO, PGE<sub>2</sub>, IL-1 $\beta$ , IL-6 and TNF- $\alpha$ ) and reactive oxygen species, compared with that of native IPF via the inhibition of NF- $\kappa$ B, JAK-STAT signals and NLRP3 inflammasome activation and the restoration of Nrf2 signals. Moreover, EIU model evidences the superior therapeutic efficacy over clinically used diclofenac sodium eyedrop.

**Conclusion:** The supramolecular hydrogel shared excellent bioavailability, biocompatibility and therapeutic efficacy as a result of the synergistic effect of antioxidant and anti-inflammatory activities and presented the therapeutic value in the treatment of ocular inflammatory disease.



P-397

## Acute Posterior Multifocal Placoid Pigment Epitheliopathy Like Features In A Case Of Vogt-Koyanagi-Harada Disease

A Vyas<sup>1</sup>, A Subramanyam<sup>2</sup>, S Phatak, S tiwari<sup>3</sup>.

<sup>1</sup>Vitreo-retina, KBHB eye and ear hospital, Parel, <sup>2</sup>Vitreo-retina, KBHB charitable eye and ear institute, Parel,

<sup>3</sup>Vitreo-retina, KBHB eye and ear charitable institute, Parel, Mumbai, India

**Objective:** To demonstrate the overlap of Acute Posterior Multifocal Placoid Pigment Epitheliopathy (APMPPE) like clinical features in a case of Vogt-Koyanagi-Harada (VKH) disease

**Methods:** A 38 year old, female presented with sudden, painless diminution of vision, intermittent headache and a constant ringing sensation in the ear over the past three days. Best corrected visual acuity was 20/20 in the right eye and finger count at 1 meter in the left eye. Intraocular pressures were normal. Anterior segment examination unremarkable. Fundos examination of the right eye showed multiple, round creamy white lesions of half disc diameter in size located over the temporal side of macula. Left eye showed macular serous retinal detachment. Optical coherence tomography with enhanced depth imaging of both eyes showed neurosensory detachment with subretinal septae, photoreceptor layer edema along with disorganisation and a thickened choroid. Fundus fluorescein angiography of the left eye showed the classic pin point hyper fluorescence in the early phase. However the right eye demonstrated hypo fluorescent lesions in the early phase, surrounded by hyper fluorescent margins in the mid-phase and hyper fluorescent multilobular lesions in the late stage a characteristic appearance of APMPPE. High dose steroids were initiated and subsequent follow ups noted stabilisation of vision to 20/20 in the right eye and 20/40 in the left eye with yellowish pigmentary changes in the right eye with sunset glow in both eyes. OCT imaging revealed resolution of neurosensory detachment and intraretinal edema with ellipsoid zone discontinuity in the right eye predominantly. Multiple recurrences warranted the initiation of azathioprine and cyclosporine. Subsequently no new episodes were noted.

**Results:** APMPPE like features in a case of VKH is an unusual presentation.

**Conclusion:** Majority of the cases have presented VKH like features overlapping in APMPPE. However in our case we have reported an APMPPE like presentation in a case of VKH and the possibility of them having overlapping features or coexisting at the same time.

P-398

## Posterior Uveitis and Retinal Vasculitis Presenting After Administration of an Inactivated Virus Vaccine Against COVID-19

C Kasala<sup>1</sup>, D Carbonell<sup>1,2</sup>.

<sup>1</sup>Eye and Vision Institute, The Medical City, Pasig, <sup>2</sup>Department of Ophthalmology, The Medical City South Luzon, Santa Rosa, Laguna, Philippines

**Objective:** To discuss one of the possible ocular complications of the CoronaVac vaccine  
To describe the retinal findings noted on examination after vaccination  
To discuss the management done and subsequent clinical course

**Methods:** A case report.

**Results:** A 36-year old Filipino male presented with floaters in the left eye, progressing to blurring of vision 2 months after the first dose of the CoronaVac vaccine. Initial examination showed a visual acuity of 20/20 in the right eye, and HM on the left eye. On DFE, retrolental cells were seen, with a hyperemic optic nerve, pre-retinal hemorrhage, vascular sheathing along the arcades, and peripapillary retinitis. Work-up tested negative for known causes of uveitis. After the second dose of the vaccine, vision in the right eye gradually decreased to 20/80. FA showed intraretinal hemorrhages and retinal vasculitis in both eyes, with a patch of peripapillary retinitis in the left eye. There was no macular edema on OCT. Initially, he was started on oral Prednisone and followed closely. A few months after, he developed a new bleed along the inferior arcade of the right eye, and further attenuation of blood vessels with formation of collateral blood vessels around the area. A total of 3 trans-septal Triamcinolone injections were given. He was also started on oral Methotrexate at 15mg/week while tapering Prednisone. FLT was applied to the leaking blood vessels. Vision improved from 20/80 to 20/60 in the right eye and HM to CF in the left eye.

**Conclusion:** Ophthalmic issues regarding the COVID-19 pandemic are an area of great interest. Clearly, this virus has impacted all facets of healthcare worldwide. Vaccines are indispensable tools against the pandemic; however, they are not without risk. As vaccination rates increase, we are beginning to see possible ocular complications. It has been postulated that Vaccine-Related Uveitis can result from molecular mimicry, delayed hypersensitivity, deposition of immune complexes, or an immune reaction to vaccination adjuvants. The CoronaVac inactivated virus vaccine is thought to cause uveitis through an autoimmune reaction, possibly due to the multiple epitopes which precipitate an abundance of antibody production. Thus, due to the more widespread use of COVID vaccines, we recommend a complete ophthalmic examination once any ocular symptoms are noted, as these can have significant and possibly permanent effects on vision and quality of life in susceptible individuals.

P-400

## Prevalence and Causes of Low Vision and Blindness among Patients at Nigerian Army Eye Centre, Lagos, Nigeria

N Ezinne<sup>1</sup>, O Shittu<sup>2,3</sup>, K Ekemiri<sup>4</sup>, C Ojukwu<sup>5</sup>.

<sup>1</sup>Optometry Unit, Clinical Surgical Sciences, University of the West Indies, Saint Augustine campus, Saint Augustine, Trinidad and Tobago, <sup>2</sup>Department of Optometry, Madonna University Elele Campus, Elele, Nigeria, <sup>3</sup>Eye department, General Hospital, Orile Agege, Lagos, <sup>4</sup>Optometry Unit, Department of Clinical Surgical Sciences, University of the West Indies, Saint Augustine Campus, Saint Augustine, Trinidad and Tobago, <sup>5</sup>Department of Optometry, Madonna University, Elele Campus, Elele, Nigeria

**Objective:** To determine the prevalence and causes of low vision and blindness among patients at Nigerian Army Eye Centre Lagos, Nigeria.

**Methods:** Institution based cross sectional study was carried out from January 2016 to December, 2016 with sample size of 500. Systematic random sampling was used to recruit the study participants. Information including the demographic profile, presenting visual acuity (VA), best corrected visual acuity, and cause of low vision and blindness were recorded. World Health Organization categories of visual impairment were used to define vision status for study participants. VA of less than 3/60 in the better eye was classified as blindness and VA of 3/60 to 6/24 in the better eye as low vision. Data was entered into the Statistical Package for Social Sciences (SPSS) version 24. Descriptive statistics such as frequency, cross tabulation and chi-square test were used for data analysis. *P*-value of less than 0.05 was considered statistically significant.

**Results:** Out of the 500 participants included in the study, 254 (50.8%) were males and majority (50.3%) were  $\geq 60$  years. The mean age of the study participants was 54.07 (SD:  $\pm 21.4$ ) with a range of 5–96 years. The prevalence of low vision and blindness were 22% and 20.6% respectively. Cataract ( $n=213$ , 42.6%), refractive error ( $n=98$ , 19.6%) and glaucoma ( $n=82$ , 16.4%) were the major causes of low vision and blindness. Age ( $p = 0.000$ ), cataract ( $p = 0.01$ ) and glaucoma ( $p = 0.02$ ) were significantly associated with low vision and blindness.

**Conclusion:** The prevalence of low vision and blindness recorded in this study was relatively high especially among those 60 years and above. Early screening for detection and management of cataract, refractive error and glaucoma is highly recommended to reduce the prevalence and burden of visual impairment.

P-401

### The physical properties of the 3D spheroids from human scleral stroma fibroblasts obtained from eyes with different axial lengths

H Katayama<sup>1</sup>, Y Ida<sup>1</sup>, A Umetsu<sup>1</sup>, M Watanabe<sup>1</sup>, F Hikage<sup>1</sup>, H Ohguro<sup>1</sup>.

<sup>1</sup>Ophthalmology, Sapporo Medical University School of Medicine, Hokkaido, Japan

**Objective:** To elucidate the pathological characteristics of myopic scleral stroma, three-dimensional (3D) cultures of human scleral stroma fibroblasts (HSSFs) with several axial lengths (AL, 22.80–30.63 mm) obtained from patients (n = 7) were examined.

**Methods:** Among the three groups of ALs, 30 mm (n = 3), the physical properties of the 3D HSSFs spheroids concerning size and stiffness, the expressions of extracellular matrix (ECM) molecules, including collagen (COL) 1, 4, and 6 and fibronectin (FN) by qPCR and immunohistochemistry (IHC), and the mRNA expression of ECM metabolism modulators including hypoxia-inducible factor 1A (HIF 1A), HIF 2A, lysyl oxidase (LOX), tissue inhibitor of metalloproteinase (TIMP) 1–4, and matrix metalloproteinase (MMP) 2, 9, and 14 as well as several endoplasmic reticulum (ER) stress-related factors were compared.

**Results:** In the largest AL group (>30 mm), the 3D HSSFs spheroids were (1) significantly down-sized and less stiff compared to the other groups, and (2) significant changes were detected in the expression of some ECMs (qPCR; the up-regulation of COL1 and COL4, and the down-regulation of FN, IHC; the up-regulation of COL1 and FN, and down-regulation of COL4). The mRNA expressions of ECM modulators and ER stress-related genes were also altered with increasing AL length (up-regulation of HIF2A, MMP2, XBP1, and MMP14, down-regulation of LOX, TIMP 2 and 3, GRP78, GRP94, IRE1, and ATF6). In addition, a substantial down-regulation of some ER stress-related genes (ATF4, sXPB1, and CHOP) was observed in the 25–30 mm AL group.

**Conclusion:** These findings suggest that small and stiffer 3D HSSFs spheroids in the largest AL group may accurately replicate the pathological significance of scleral thinning and weakening in myopic eyes. In addition, the modulation of several related factors among the different AL groups may also provide significant insights into our understanding of the molecular mechanisms responsible for causing myopic changes in the sclera.

P-402

### The Effect of Aging on Morphological Parameters of the Ciliary Muscle Using AS-OCT Images

H Lin<sup>12</sup>, Y Zhang<sup>12</sup>, L Hu<sup>12</sup>, B Yang<sup>12</sup>, R Higashita<sup>23</sup>, J Liu<sup>1245</sup>.

<sup>1</sup>Research Institute of Trustworthy Autonomous Systems, <sup>2</sup>Department of Computer Science and Engineering, Southern University of Science and Technology, Shenzhen, People's Republic of China, <sup>3</sup>Tomey Corporation, Nagoya, Japan, <sup>4</sup>Guangdong Provincial Key Laboratory of Brain-inspired Intelligent Computation, Department of Computer Science and Engineering, Southern University of Science and Technology, Shenzhen, <sup>5</sup> School of Ophthalmology and Optometry, Wenzhou Medical University, Wenzhou, People's Republic of China

**Objective:** Past anatomical studies have shown that the ciliary muscle changes have a contributory effect on presbyopia. However, due to the limitations of imaging techniques, there are few studies on ciliary muscle morphology and function based on in vivo data. Anterior segment optical coherence tomography(AS-OCT) provides an effective tool for in vivo observation of the ciliary body. The primary purpose of our experiment is to investigate the correlation between changes in ciliary muscle morphological parameters and presbyopia using the Tomey CASIA2 AS-OCT device.

**Methods:** This cross-sectional, observational study is based on AS-OCT images from 104 healthy eyes observed under an identical environment and machine setting. To explore the potential correlation between ciliary muscle and presbyopia, we segment the ciliary muscle area from AS-OCT images using a custom developed deep learning model and analyzed its physiological morphological characteristics.

Thickness-related parameters ciliary body thickness (CBT), ciliary maximum thickness (CMT), and area-related parameter ciliary body area (CBA) are measured for further statistical analysis. For each parameter, the difference between gender and ethnicity is tested through t-test or one-way ANOVA. Correlation tests are done between age and each parameter separately.

**Results:** The 104 participants include 80 males and 24 females with mean age of  $39.2 \pm 11.3$  yrs. Among the quantified thickness and area parameters, total CBA (OS  $2.57 \pm 0.46 \text{mm}^2$ /OD  $2.59 \pm 0.40 \text{mm}^2$ ) shows significant difference ( $p < 0.05$ ) on the temporal side among different gender groups, meanwhile significant positive correlation ( $p < 0.05$ ) is found between temporal side CMT(OS  $1.07 \pm 0.17 \text{mm}$ /OD  $1.16 \pm 0.15 \text{mm}$ ) and age. We do not observe significant results among the other CBT and CBA parameters.

**Conclusion:** Quantification analysis suggests that gender groups are significantly different in the total ciliary muscle area. Also, the maximum thickness of ciliary muscle increase with the aging process. Specific processes associated with the development of presbyopia may primarily affect the temporal side of the eye.

P-404

**Verteporfin-mediated on/off photoswitching functions synergistically to treat choroidal vascular diseases**Y Ju<sup>1</sup>, P Gu<sup>1</sup>.

<sup>1</sup>Department of Ophthalmology, Ninth People's Hospital, Shanghai JiaoTong University School of Medicine, Shanghai, People's Republic of China

**Objective:** The objective of this study is to develop an in situ verteporfin (VP) drug delivery system using bio-responsive hydrogel to improve drug bioavailability and avoid the risk of systemic adverse events, thereby optimizing the application of VP in the treatment of choroidal vascular diseases, such as age-related macular degeneration.

**Methods:** Triglycerol monostearate (TGMS) was used to encapsulate VP to form VP-TGMS hydrogel and administered to laser-induced CNV mice model by intravitreal injection. Characterization of VP-TGMS hydrogel including rheological properties, pH value, osmolarity, and swelling capacity was investigated. The in vitro release of VP was tested. Then histological staining and other in vitro and in vivo experiments were conducted to evaluate the biocompatibility of hydrogel. Under light-on and light-off conditions, the photodynamic effect and anti-angiogenic effect of VP were evaluated by live/dead staining, migration assay, tube formation assay, fluorescein angiography and fluorescence imaging of RPE-choroid flat-mounts.

**Results:** VP-TGMS with good biocompatibility could degrade in response to the high expression of MMP-2/9 in the vitreous of CVD patients to release VP. Under light-on conditions, VP-mediated photodynamic therapy effectively occurs and this leads to vascular occlusion. Under light-off conditions, non-photoactive verteporfin negatively regulates vascular endothelial growth factor-induced angiogenesis as a Yes-associated protein inhibitor.

**Conclusion:** Our system serves as an intraocular verteporfin reservoir to improve the bioavailability of verteporfin by innovatively exploiting its photochemical and biological functions. This study provides a promising strategy with synergistic antiangiogenic effects for the treatment of choroidal vascular diseases.

P-405

**Colony Size Influences self-organization of embryonic stem cell in vitro**S Hao<sup>1</sup>, K Yao<sup>1</sup>.

<sup>1</sup>Eye Center of Second Affiliated Hospital of Zhejiang University, School of Medicine, Hangzhou, People's Republic of China

**Objective:** Colony sizes has significant contribution during the stem cell differentiation and tissue regeneration. However, the effect of colony size on self-organization of stem cells has been rarely explored.

**Methods:** In our research, we designed a PDMS stamp with patches in distinct diameter using soft lithography, and microcontact printing of Matrigel can effectively control the colony size of embryonic stem cells, after eye field induction, expression of genes related to early stage of eye development, like SOX2, RAX, PAX6 and P63, were measured by qPCR.

**Results:** We found that the expression of these genes was inhibited in smaller colonies, and expression recovery emerged after colony were reseeded and expanded without pattern limitation, suggesting colony size has reversible influence on the early eye development.

**Conclusion:** These colonies possibly mimic the process of microphthalmia that occurs at early stage of eye development, which has potential to become disease model for research in the future.

P-406

**Association study on eye health and influencing factors of college students in a region of northern China during the COVID-19**N Liu<sup>1</sup>, X Xu<sup>1</sup>, H Ren<sup>1</sup>, J Zhang<sup>1</sup>, H Cai<sup>1</sup>.<sup>1</sup>Tianjin medical university, Tianjin, People's Republic of China

**Objective:** To explore the correlation between eye use and factors affecting eye health of college students in a certain northern area before and after the COVID-19.

**Methods:** From October to December 2021, a questionnaire survey was conducted on 799 college students from a number of colleges and universities in northern China during the COVID-19, and the correlation statistical analysis was performed on the survey results.

**Results:** During the COVID-19, college students used electronic equipment frequently, which increased the symptoms of eye discomfort mainly including eye itching (62.08%), dry eyes (60.58%), tears (53.32%), heavy eyelids (52.19%) and decreased vision (50.31%), and the systemic symptoms mainly including low back pain (53.07%), neck pain (52.07%), headache (51.69%), upper limb and shoulder pain (49.44%) and emotional vulnerability (45.43%). Moreover, we found related protective factors for the degree of myopia change before and after the epidemic, such as wearing glasses during operation, high average daily drinking water, long operation distance of using mobile phones, and large contrast between terminal brightness and surrounding environment. In addition, during the COVID-19, different grades of college students had a significant negative correlation with the average daily outdoor activity time ( $r=-0.121$ ) and lunch break habits ( $r=-0.072$ ), and have obvious positive correlation with the average daily time of watching video terminals at night ( $r = 0.140$ ), the average daily time of wearing masks ( $r = 0.137$ ) and the average daily amount of drinking water ( $r = 0.104$ ).

**Conclusion:** During the COVID-19, college students have increasingly serious eye health problems, with varying degrees of eye discomfort and systemic symptoms. Smoking or drinking, average daily viewing time of video terminals are the main risk factors affecting the eye health of college students, while lunch break, eye rubbing habits and eye exercises are protective factors. Therefore, in the post-epidemic era, it is necessary to establish a behavior management model for college students' eye health during the COVID-19 epidemic.



P-407

### CircRNA-vgll3 promotes ADSCs osteogenic differentiation by modulating miRNA-dependent integrin $\alpha 5$ expression

N Ni, P Gu.

**Objective:** In this study, we aim to explore the functional roles and underlying mechanisms of circRNAs in regulating ADSC osteogenic differentiation for the first time. Exon-derived circRNA-vgll3 played a positive role in modulating ADSC osteogenic differentiation. Besides, the effects of combination of circRNA-vgll3-modified ADSCs with synthetic calcium phosphate cement (CPC) scaffolds, which are acknowledged biocompatible hard tissue biomedical materials, for repairing critical-sized bone defects in vivo were explored further.

**Methods:** In vitro, PCR, ICC and western-blot analysis were applied for evaluating the gene and protein expression in each group. Besides, RNA pull-down assay, RIP experiment, Luciferase assay and FISH experiment were performed to verify the binding among circRNA-vgll3 and miR-326-5p and integrin  $\alpha 5$ . Moreover, a critical-sized defect model in rats was applied in assessing the therapeutic potential of circRNA-vgll3-modified ADSCs.

**Results:** Here, we show that circRNA-vgll3 originating from the vgll3 locus markedly enhances osteogenic differentiation of ADSCs; nevertheless, silencing of circRNA-vgll3 dramatically attenuates ADSC osteogenesis. Furthermore, we validate that circRNA-vgll3 functions in ADSC osteogenesis through a circRNA-vgll3/miR-326-5p/integrin  $\alpha 5$  (Itga5) pathway. Itga5 promotes ADSC osteogenic differentiation and miR-326-5p suppresses Itga5 translation. CircRNA-vgll3 directly sequesters miR-326-5p in the cytoplasm and inhibits its activity to promote osteogenic differentiation. Moreover, the therapeutic potential of circRNA-vgll3-modified ADSCs with calcium phosphate cement (CPC) scaffolds was systematically evaluated in a critical-sized defect model in rats.

**Conclusion:** Our results demonstrate that circRNA-vgll3 markedly enhances new bone formation with upregulated bone mineral density, bone volume/tissue volume, trabeculae number, and increased new bone generation. This study reveals the important role of circRNA-vgll3 during new bone biogenesis. Thus, circRNA-vgll3 engineered ADSCs may be effective potential therapeutic targets for bone regenerative medicine.

***CASE***

***PRESENTATIONS***

C-003

**Ocular and Systemic Findings of a Patient with Alkaptonuria: A Case Report**M Okutucu, S Bostan<sup>1</sup>.<sup>1</sup>*Dermatology, Recep Tayyip Erdogan University, Rize, Türkiye***Objective:** To report the ocular and systemic findings of an alkaptonuria (AKU) patient.**Methods:** The patient's ocular and systemic findings were evaluated using biomicroscopy, fundoscopy, anterior segment color picture, corneal topography, skin imaging, X-ray imaging, and laboratory tests.**Results:** A 68-year-old man was referred to our department by the medical board for routine examination. During the ophthalmoscopic examination, the patient's best-corrected visual acuities with Snellen's chart were 6/10 and 7/10 in the right and left eyes, respectively. The following were determined from biomicroscopic examination: nuclear sclerosis in both eyes, dark pigment accumulation in the scleral region consistent with the space between the nasal and temporal lids, and globular dark pigment accumulation in the conjunctiva. The intraocular pressure was 17/15 mmHg. The findings of the dilated fundus examination were considered clinically insignificant. Pigment accumulation was observed in the forehead, nose, and left malar regions. Aortic and mitral valve insufficiency, aortic annular calcification, and aortic valve sclerosis were observed on cardiological examination. The patient underwent knee and hip joint replacement surgery because of a joint injury caused by AKU. Advanced joint space narrowing was observed on the X-ray of the shoulder joint. The level of homogentisic acid (HGA) was 1235,23 mmol/mol creatinine in urine analysis, performed by the endocrinology department. Corneal topography of the patient was unremarkable. Routine ocular control was recommended once every six months.**Conclusion:** AKU is a metabolic disorder that causes injury to tissues, including cartilage, leading to the accumulation of HGA. It may have several ocular and systemic manifestations. When clinicians encounter dark pigmentation in ocular tissues, they should consider that this could be an accumulation of HGA due to AKU, and a detailed ophthalmological examination and systemic investigation should be performed meticulously.

C-004

### Temporal Association of Corneal Stromal Opacities with Alpelisib

O Akaniru<sup>1</sup>, E Koo<sup>2</sup>.

<sup>1</sup>University of Miami Miller School of Medicine, <sup>2</sup>Ophthalmology, Bascom Palmer Eye Institute, Miami, United States

**Objective:** This is a case report of a patient who developed corneal stromal opacities with vision changes after starting treatment with Alpelisib for breast cancer treatment.

**Methods:** A complete ophthalmologic evaluation, treatment and follow-up for a 46-year-old female patient who presents with corneal opacities with vision changes after starting oral Alpelisib for treatment of metastatic breast cancer.

**Results:** This is a 46-year-old female patient with a history of recurrent metastatic breast first diagnosed in 2013. She presented to our institution with complaints of decreasing vision over the last three months. She reports that the onset of visual symptoms coincided with the timing with starting oral Alpelisib for metastatic breast cancer. Her corrected visual acuity was 20/25 in the right eye and 20/60 in the left eye. Slit-lamp examination showed bilateral, anterior stromal, mid-peripheral rings of corneal opacities. The rest of her ophthalmological exam was normal. Topical prednisolone acetate 1% were initiated at four times daily. Upon her follow-up visit at 1 month, she reported improving vision. The corrected visual acuity at this visit was 20/20 in the right eye and 20/25 in the left eye. Slit-lamp examination showed improvement in corneal opacities. Optical Coherence Tomography (OCT) confirmed improvement of the stromal opacities. The prednisolone acetate dosage was reduced to three times daily. After three months, patient reported continued subjective improvement of her vision. The slit-lamp examination and OCT imaging showed near-resolution of the stromal opacities. Her corrected visual acuity was 20/20 in each eye. All this while, patient had continued her oral Alpelisib at her oncologist's recommendation. Thus, she was maintained on Prednisolone acetate 1% once daily given continuation of Alpelisib for breast cancer therapy.

**Conclusion:** This is the first reported case of corneal opacities as a possible side effect of Alpelisib. Topical corticosteroids appeared to aid in resolution of corneal opacities, suggesting an ocular immune-mediated effect with this medication.

C-005

**Peter's Anomaly with Macular Dysplasia: An Unusual Finding of Optical Coherence Tomography**Y Yang<sup>1</sup>, F Lu<sup>1</sup>.<sup>1</sup>Department of Ophthalmology, West China Hospital, Sichuan University, Chengdu, People's Republic of China

**Objective:** To report an unusual case of Peter's anomaly with macular dysplasia revealed by optical coherence tomography (OCT) during surgery.

**Methods:** A 3-year-old child was admitted to our hospital with a main complaint of bilateral leukocoria since birth. Examination with flashlight revealed bilateral nystagmus, diffuse corneal opacity with multiple blood vessels, cloudy lens with central adhesion to the posterior corneal surface, and disappeared anterior chamber of both eyes. The patient was diagnosed with Peter's anomaly and was treated by operations including vitrectomy and extracapsular cataract extraction of both eyes.

**Results:** During the operation, OCT showed close adhesion of cornea, iris and lens. Fundus photography revealed disappeared light reflection of macular fovea while fluorescein angiography demonstrated small blood vessels in the macular area. Fovea centralis of both eyes was not found, and each layer of retina was continuous on OCT.

**Conclusion:** Peter's anomaly is a congenital ocular anomaly, which usually affects the anterior segment and causes structural abnormalities of cornea, iris and lens. We report this case to show an unusual situation when macular dysplasia occurs with Peter's anomaly.

C-006

**DMEK for the treatment of interface fluid syndrome secondary to failed DSAEK graft : a case report and review of the literature**

N Coelho<sup>1234</sup>, E Arrondo<sup>25</sup>, R Papa-Vettorazzi<sup>1</sup>, J Cunha<sup>46</sup>, J Güell<sup>127</sup>.

<sup>1</sup>Cornea and Refractive Surgery Unit, IMO Grupo Miranza Barcelona, Barcelona, Spain, <sup>2</sup>Ophthalmology, European School for Advanced Studies in Ophthalmology (ESASO), Lugano, Switzerland, <sup>3</sup>Ophthalmology, NOVA Medical School | Faculdade de Ciências Médicas, <sup>4</sup>Ophthalmology, Escola Superior de Tecnologias da Saúde de Lisboa (ESTeSL), Lisbon, Portugal, <sup>5</sup>Glaucoma Department, IMO Grupo Miranza Barcelona, Barcelona, Spain, <sup>6</sup>Ophthalmology, Hospital CUF Cascais, Lisbon, Portugal, <sup>7</sup>Ophthalmology, Universidad Autónoma de Barcelona, Barcelona, Spain

**Objective:** To report a case of Descemet membrane endothelial keratoplasty (DMEK) for the management of post-laser in situ keratomileusis (LASIK) interface fluid syndrome (IFS) secondary to failed Descemet stripping automated endothelial keratoplasty (DSAEK) graft, and to provide a literature review on endothelial keratoplasty (EK) for this indication.

**Methods:** A 52-year-old patient presented with LASIK interface fluid accumulation and a non-functioning primary DSAEK graft. Past ophthalmic history was relevant for: (1) phakic intraocular lens (PIOL) implantation with later refinement by LASIK; (2) combined PIOL explantation and refractive lens exchange due to accelerated endothelial cell loss (ECL); (3) primary DSAEK due to corneal decompensation. A secondary EK graft (DMEK) was performed, and the patient was prospectively followed for 6 months (M6).

**Results:** DMEK surgery was uneventful, without postoperative graft detachment. Corneal clearing and resolution of interface fluid accumulation occurred during the first postoperative month. Best-corrected visual acuity (BCVA) improved from 20/800 Snellen to 20/25 Snellen at 3-month follow-up, remaining stable at M6. Due to a persistent rise in intraocular pressure (IOP), the patient underwent uneventful non-penetrating deep sclerectomy 2 months after DMEK, with controlled IOP and without accelerated ECL.

**Conclusion:** DMEK is feasible, effective, and safe in the management of IFS in cases where corneal endothelial failure plays a major role, even in complex eyes with previous EK grafts. Aggressive postoperative IOP control is warranted to decrease the risk of interface fluid recurrence and damage to the optic nerve. Studies with larger patient numbers are encouraged to ascertain the role of EK for this indication.

**C-007****Timely management of a Post Injection Cluster Endophthalmitis (PICE) in a low-resource setting, Guatemala**R Jule.

**Objective:** To prove that prompt evaluation post intravitreal antibiotics (12 hours at the most) and not deferral of vitrectomy improves visual outcomes in PICE patients.

**Methods:** Retrospective analysis of a Fulminant PICE that occurred in the first week of January 2020 after poor handled multi-dose bevacizumab bottle; At first visit, all patients were managed with intravitreal antibiotics (IVATB), topical and oral antibiotics, and topical corticosteroids. Second visits was scheduled 12 hours after, if their condition worsened, they were admitted for pars plana vitrectomy (PPV); contrary, if their condition remained stable or improved. Patients were then evaluated daily. UCVA and slit lamp examination were obtained in every follow up visit.

**Results:** Achrombacter xylosoxi was isolated in the bevacizumab bottle In total, 13 eyes of 10 patients were studied. Pre-event BCVA was a mean of 20/80 (ETDRS chart). Immediately after the infection was diagnosed, mean VA decreased to a mean of hand motion (HM). Posterior pars plana vitrectomy was performed in 9 patients (5 on the 2nd visit and 4 on the 3rd visit); the rest of patients were managed as described above. 1 week after treatment, BCVA was a mean of 20 400. Three months post infection BCVA was a mean of 20/80. Only one patient remained with a poor VA, as of her pre-event evaluation.

**Conclusion:** Prompt diagnosis and aggressive treatment of PICE (IVATB / prompt PPV) can result in excellent visual and anatomical outcomes as in the pre-event setting of patients.

C-008

**Guillain-Barré Syndrome with Associated Bilateral Neurotrophic Keratopathy**D Qin<sup>1</sup>, H Yin<sup>1</sup>.<sup>1</sup>*Ophthalmology, West China Hospital of Sichuan University, Chengdu, People's Republic of China*

**Objective:** Guillain-Barré syndrome (GBS) is an immune-mediated polyradiculoneuropathy, that can involve different parts of the eye. The most common ocular presentation is ophthalmoplegia. Abnormal corneal sensitivity associated with this condition has not been reported previously and can be easily ignored by neurologists, which may delay its timely diagnosis and treatment. This study aimed to report a case of severe bilateral neurotrophic keratopathy (NK) potentially secondary to GBS, in order to provoke neurologists' attention to this ocular complication in GBS patients.

**Methods:** Here we report a case of severe bilateral NK potentially secondary to GBS in an adult female patient.

**Results:** An adult woman presented to our hospital with symmetric pain and numbness ascending from hands to arms. She also felt leg weakness at the same time and rapidly progressed to inability to move without assistance. Cerebrospinal fluid (CSF) analysis revealed elevated protein content and a normal cell count, which suggested a diagnosis of GBS. 5 days after admission, she complained of blurred vision of both eyes, and physical examination demonstrated absence of corneal sensation. Confocal microscopy (CCM) examinations showed an almost complete absence of corneal subbasal nerve plexus. The examination of her fundus revealed no obvious abnormalities. The diagnosis of NK was established then and treated immediately. Although her muscle weakness improved thereafter with treatment, her left eye had progressive ulceration and rapid worsening of vision even with intense therapy. Prognosis of this patient was poor, with the severe dry eye, ocular surface dyshomeostasis, and visual function impairment.

**Conclusion:** This case opens the question of the association of NK with GBS, and suggests that the incidence of this complication may be highly underestimated. The aim of our report is to strengthen the observation of corneal sensitivity and to prevent severe NK in GBS patients.



C-009

**Ethambutol toxicity or MOG positive optic neuritis: chasing the thief to full recovery (6/6)**K Kumari, J Sukhija<sup>1</sup>, S Kaur<sup>1</sup>.<sup>1</sup>Ophthalmology, Post graduate institute of Medical research and education, Chandigarh, India

**Objective:** To describe the dilemma of diagnosis and management in young female on antitubercular treatment with gradual onset, fast progressing vision loss and disc edema

**Methods:** A 26 years old female diagnosed with pulmonary tuberculosis and on antitubercular treatment (HRZE), developed bilateral gradual in onset, fast progressing vision loss. Patient was diagnosed as optic neuritis at local hospital and was given a pulse of methylprednisolone followed by no improvement in vision and was referred to us. Best corrected visual acuity of both eyes was counting fingers close to face. No RAPD was noted, color vision and contrast sensitivity were decreased. Visual fields showed bilateral centrocecal scotomas, OCT-GCL also showed corresponding thinning. Ethambutol was stopped, but led to no improvement in progression of vision loss, so Isoniazid was also stopped. CE-MRI brain with optic nerve cuts was suggestive of bilateral retrobulbar neuritis. Also VEP showed decreased amplitudes. We planned for anti-NMO, MOG antibody titres and to repeat pulse of methylprednisolone after consultation with pulmonology department. Anti-MOG antibodies came out to be positive. After pulse, vision improved to counting finger 3 meters in right eye, 6/60 left eye. Patient was shifted on oral steroids with slow tapering. At no point of time RAPD was present, also no sign of demyelination on MRI brain, anti-MOG antibodies were repeated and were negative. So, steroids were tapered and tab. coenzyme-Q was continued. After 4 month follow up patient has vision 6/6 with normal visual fields.

**Results:** After stopping ethambutol and Isoniazid and receiving two pulses of methylprednisolone, vision and visual fields improved.

**Conclusion:** Patients on ATT with vision loss, should be worked up in detail. CE-MRI brain with optic nerve is justifiable if any visual field defect is noted or optic neuritis is suspected. If any activity is suspected, methylprednisolone pulse should be considered. Also, close collaboration of ophthalmologist, pulmonologist and neurologist is required for adequate treatment in such cases.

**C-010****A case of orbit metastasis from salivary duct carcinoma of the parotid gland**P Wang.**Objective:** To report a case of orbit metastasis from salivary duct carcinoma of the parotid gland.**Methods:** A 37-year-old man visited to the hospital in September 2021 with swelling and painful of the left orbit and left parotid gland. Form his past medical history, a no-painful firm to hard non-tender soft tissue mass was palpated in the left orbit last for 3 months, and visited in another hospital in May 2020, orbit MRI was performed and showed that a mass was inside and below of the orbit. A diagnosis of an inflammatory pseudoma was suspected, and the patient was advised biopsy, but he refused operation. The patient accepted gradually reduce the amount oral prednisolone last for 3 months by himself, and the pain was disappear.1 months later, the left parotid gland was swelling and the left eye was swelling and painful again. An incisional biospy of orbit tumor and an ultrasound-guided Fine needle aspiration biopsy of the left parotid gland were performed. The histopathological examination revealed the low differentiation cancer.**Results:** After Multidisciplinary Treatment (MDT), the patient underwent a second operation, include a total orbit enucleation, parotidectomy and lymph node dissection (levels I–V) . The pathology turned out to be a salivary duct carcinoma. Following histopathological confirmation, the patient receive chemical and radiological treatment after operation in oncology department. The patient remained on maintenance therapy and under our follow-up care.**Conclusion:** Metastatic salivary duct carcinoma to the orbit is extremely rare. In few cases of unusual orbit tumor presentations need a early biopsy for clearly diagnosed.

**C-011****Successful treatment of OSSN with both intraocular and orbital invasion using external beam radiation therapy and chemotherapy**

D Kurian, K *Mulay*, V *Reddy*, S *Honavar*.

**Objective:** Ocular surface squamous neoplasia (OSSN) is typically not considered an aggressive tumour, but 2-12 % of patients with OSSN can have intra-ocular or orbital extension. Most common treatment options in these cases include extended enucleation or exenteration. Orbital disease alone has been reported to have been treated with external beam radiation therapy (EBRT), whereas intra-ocular diseases have been treated with plaque brachytherapy or modified eyewall resection. We present the case of a 30 years old gentleman with both intra-ocular and intra-orbital extension of OSSN who was treated with EBRT.

**Methods:** Case report

**Results:** Following EBRT along with Cisplatin based chemosensitizer, there was complete regression of tumour, with no recurrence at over three years. Radiation induced keratopathy, cataract and early retinopathy were the observed side-effects.

**Conclusion:** To the best of our knowledge this is the first report of a patient, with both intra-ocular and orbital involvement of OSSN, treated successfully with EBRT.

**C-013****Siderosis Bulbi : A case report and analysis of qualitative visual outcome.**

S Makhija, S Jain, T Singh, N Vyas Joshi.

**Objective:** To report a rare case of a retained metallic intraocular foreign body resulting in siderosis bulbi and to measure and compare quantitative and qualitative visual outcome using optical ray tracing aberrometry.

**Methods:** We report a case of a 21 year old boy with history of trauma 3 years back. The patient underwent preliminary work up. Investigations included anterior segment optical coherence tomography, ultrasound sonography, ray tracing aberrometry, Electroretinogram as well as Xray and computerized tomography scan of the orbit to localize the IOFB. We found to have a retained metallic intraocular foreign body lodged in the posterior segment with correlating changes in the cornea and lens. The patient underwent lensectomy, intraocular lens implantation and IOFB removal. Ray tracing aberrometry was performed 5 months after the surgery and the results were analysed.

**Results:** The results of the wave front aberrometry of the eye after surgery showed a declining trend in dysfunctional lens index. The total higher order aberrations also declined owing to the decline of internal higher order aberrations which were probably due to improvement in vitreous. The corneal higher order aberrations however remained unchanged because of the non resolving corneal deposits for a follow up period of 5 months.

**Conclusion:** Siderosis bulbi is an ineludible chronic sequelae of retained metallic intraocular foreign body. Removal of IOFB, though imperative, does not necessarily ensure improvement in qualitative visual outcome owing to the irreversible corneal deposits and corresponding aberrations.

**C-014****Delayed endophthalmitis of *Stenotrophomonas maltophilia* after penetrating ocular trauma**

S Sheng.

**Objective:** *Stenotrophomonas maltophilia* is emerging as an important opportunistic ocular pathogen. Most of the reports in the literature showed that endophthalmitis of *Stenotrophomonas maltophilia* is rare. We report a case of delayed endophthalmitis of *Stenotrophomonas maltophilia* 2 months after penetrating ocular trauma.

**Methods:** A 47-year-old male presented to us with a history of penetrating ocular trauma by tile with acute deterioration of vision in the left eye for 1h. On examination, visual acuity for his left eye 0.08. Slit lamp microscope found irregular laceration of the cornea at 5 o'clock, partial iris prolapse. The lens was clear. The fundus examination found vitreous hemorrhage and poor visibility in the rest. He was diagnosed with "penetrating ocular trauma" and had surgical suture. Postoperative he was treated with routine anti-inflammatory treatment. At 14 days postoperatively, BCVA was 1.0 and no obvious retinal abnormalities were observed. Two months after the operation, the patient complained of sudden blurred vision in his left eye, BCVA 0.3. There is no obvious abnormality in the anterior segment. Large area of vessel had white linear changes and punctate hemorrhage can be seen in the retina. A white mass exudate is seen anterior to the retina. FFA showed blotted leakage fluorescence and patchy shadowing fluorescence in the early inferior retina of the left eye. Vitrectomy of the left eye combined with anterior chamber and vitreous injection (vancomycin + ceftazidime + voriconazole) was performed on the same day. Bacterial culture on the second day after surgery showed *Stenotrophomonas maltophilia* infection.

**Results:** The patient was stable after systemic application of cotrimoxazole and levofloxacin, and eye drop of levofloxacin and chloramphenicol. 1 year after surgery, BCVA of left eye was 0.8. Fundus is stable.

**Conclusion:** *Stenotrophomonas maltophilia* can cause delayed endophthalmitis, and sensitive antibiotic treatment is effective and the prognosis is good.

**C-015****Asymptomatic Post-Traumatic Bilateral Ophthalmic Vein and Cavernous Sinus Thrombosis**M Kvopka.

**Objective:** To present a diagnostically-challenging bilateral post-traumatic SOVT in the absence of neurological or ophthalmic signs or symptoms.

**Methods:** Superior ophthalmic vein thrombosis is a rare, but potentially devastating, condition with a reported incidence of 3-4 cases/million/year. The condition may present with orbital signs mimicking cavernous sinus thrombosis or orbital cellulitis. Diagnosis is made radiologically using CT or magnetic resonance angiography. Early diagnosis and suitable treatment initiation are important in reducing the risk of permanent visual and neurological impairment.

Herein, we present a diagnostically-challenging bilateral post-traumatic SOVT in the absence of neurological or ophthalmic signs or symptoms. This report adhered to the ethical principles outlined in the Declaration of Helsinki as amended in 2013.

**Results:** A 54-year-old female with no significant past medical history presented to a tertiary trauma and referral hospital after falling from a ladder and sustaining significant head and torso polytrauma. Contrast CT imaging confirmed the presence of bilateral superior and inferior ophthalmic, and cavernous sinus thrombi without carotid-cavernous fistula. The patient's presentation occurred in the absence of any neurological or ophthalmic signs or symptoms, and her visual acuity remained normal throughout follow-up. Successful resolution of all thrombi occurred following treatment with systemic anticoagulation.

**Conclusion:** Bilateral superior ophthalmic vein and cavernous sinus thrombosis is an extremely rare occurrence. Aetiology of superior ophthalmic vein thrombosis in our patient posed a diagnostic dilemma and warranted thorough thrombophilia screening. The cause was deemed post-traumatic, although contribution from recent nVoC-19 vaccination was investigated. Clinicians should maintain an index of suspicion for superior ophthalmic vein thrombosis despite the absence of ophthalmic or neurological symptoms and be aware of its traumatic and vaccine-induced aetiologies. Management of the condition is dependent on its aetiology, but anticoagulation appears to be safe and effective. Serial imaging with contrast CT or MRI is an essential part of diagnosis and monitoring progression of the condition.

**C-016****Use of Combined Superficial Temporal Fascia Flap for Orbital Deformity Reconstruction Secondary to Orbital Rhabdomyosarcoma**

L Zhu, J Zhao, T Lin, X Liu.

**Objective:** To present an unique clinical case using combined superficial temporal fascia flap for the reconstruction of total eyelid in an orbital hypoplasia patient secondary to rhabdomyosarcomas.

**Methods:** A 21 years old man was admitted to our department for eyelid reconstruction. He first come to our hospital diagnosed with left orbit rhabdomyosarcomas at the age of 8. He received exenteration of orbit followed by multiple courses of chemoradiotherapy. Ten years passed, there was no sign of tumor recurrence, however, due to the absence of eyelid tissue and shallow conjunctival sac, there wasn't enough space for artificial eye implantation. Physical examination showed sunken orbit with conjunctival sac contracture in the left eye and there were no functional upper and lower eyelids with thin subcutaneous tissue.

**Results:** A combined flaps based on the superficial temporal vascular system were used for eyelid reconstruction. A fascia flap based on parietal branch was used for filling subcutaneous tissue, and a hairless skin flap based on frontal branch was harvested for replacement of total eyelid. Each flap was separated into two pedicle branches for reconstruction of upper and lower eyelid. Suction catheters were placed under the flaps. No complication was observed and all flaps survived successfully. Six months later, artificial eye was installed, effectively improve the appearance of the patient with scar hidden along the hairline.

**Conclusion:** Orbital rhabdomyosarcomas accounts for approximately 10% of the primary area all over the body. However, localized treatment such as surgery and radiotherapy could develop secondary orbital late effects such as orbital hypoplasia or orbital atrophy, especially in patients at younger ages. The reconstruction of orbital hypoplasia is a major challenge for ophthalmologists, which is mainly caused by orbital deformity, reduced blood supply and lack of orbital content after treatments. Temporal fascia tissue flap is a tissue flap pedicled with superficial temporal vessels. The flap has the advantages of reliable blood supply, high survival rate, strong anti-infection ability, and flexible transfer, which made it a good tissue material for correcting orbital depression. Preoperative design of combined flaps supported by various superficial temporal vascular could provide multiple types of grafts for serious orbital deformity.

C-017

**Complete Response of Secondary Orbital Melanoma to a Combination of Ipilimumab and Nivolumab: Case Report with Literature Review.**

F Alhammad MD<sup>1</sup>, K Alburayk, K Albadri<sup>1</sup>, F Azzam<sup>2</sup>, S Butt<sup>3</sup>.

<sup>1</sup>oculoplastic division, Dhahran Eye specialist hospital, Dhahran, <sup>2</sup>Medical oncology, KFSH, Dammam, <sup>3</sup>Regional Lab and Blood Bank, MOH, Dammam, Saudi Arabia

**Objective:** To document a case of orbital melanoma secondary to resected conjunctival melanoma (CM) that responded completely to a combined Ipilimumab and Nivolumab, in addition, to review the previously reported cases in the English literature of advanced CM and orbital metastasis from primary cutaneous melanoma (PCM) that had treated with immune checkpoint inhibitors (ICI).

**Methods:** Both a retrospective chart review of one case presented to our clinic and a comprehensive literature review were performed. The English literature was reviewed through the MEDLINE database using the following search terms: “melanoma”, “conjunctival melanoma”, “orbit”, “immune checkpoint inhibitors”, “CTLA4 inhibitors”, “PD1 inhibitors”, “ipilimumab”, “pembrolizumab”, and “nivolumab”. Outcomes included the number of cases, their response to ICI, and associated side effects.

**Results:** The literature included 25 patients treated with ICI. They were 13 females and 12 males. The median age was 68 years. There were 9 cases with orbital involvement, three were secondary to CM, and six were metastasis from PCM. A complete resolution of ocular melanoma was achieved in 13 patients, representing 52% of the cases. The orbital metastasis from PCM had regressed following treatment with ICI agents, whereas those secondary to CM had resolved completely. The current reported case showed complete response and she is disease-free after 4.5 years of follow-up. During treatment with Nivolumab, she developed subcutaneous panniculitis-like T cell lymphoma, which is not a previously reported adverse event in the literature.

**Conclusion:** Orbital melanoma secondary to conjunctival melanoma responds well to immune checkpoint inhibitors which have manageable toxic effects.



**C-018****A mutation in the filamin c gene causes paralytic strabismus: a case report**

C Fuyao<sup>1</sup>, T Xiajing<sup>1</sup>.

<sup>1</sup>Eye Center, The Second Affiliated Hospital, Zhejiang University School of Medicine, Hangzhou, Zhejiang,, People's Republic of China

**Objective:** To report the clinical and genetic feature in a patient who suffered filamin C-related MFM, with symptoms of paralytic strabismus.

**Methods:** A 25-year-old male presented with difficulty in squatting, standing and closing both eyes voluntarily for 10 months, accompanied by foreign body sensation in the eyes. Since childhood, the patient had experienced a restriction of eye movement. The patient underwent anterior section slit-lamp examination, retinal condition, eye position, and eye movement examination. In addition, whole exon sequencing(WES) were analyzed.

**Results:** Specialist examination: bilateral eyelid hypophasis of moderate level, there were no significant abnormality in stroma and internal eye. The corneal light reflection test showed a right position of optical reflection. The BCVA was 0.3 in the right eye and 0.5 in the left eye. The motility examination revealed both eyes were in normal position, and the left eye was limited in abduction and adduction, while the right eye in abduction. Whole exon sequencing(WES) detected a heterozygous missense mutation in exon 45 of the FLNC gene (c.7423G>A;p.Val2475Tle). Excluding other etiologies, the patient was diagnosed initially with paralytic strabismus caused by FLNC myopathy.

**Conclusion:** This report describes a sporadic case of FLNC myopathy caused by missense mutations in China. The typical presenting characteristics were proximal weakness of the lower limbs and paralytic strabismus. a heterozygous missense FLNC mutation (c.7423G>A;p.Val2475Tle) were discovered.

## C-019

**Medial rectus plication in the management of dissociated horizontal deviation**

M Kiarudi<sup>1</sup>, B Tafaghodi<sup>2</sup>, A Sabermoghadam<sup>3</sup>, A Es'haghi<sup>4</sup>.

<sup>1</sup>Eye Research Center, Mashhad University of Medical Sciences, <sup>2</sup>Eye Reserch Center, <sup>3</sup>Eye Research Center, Mashhad, <sup>4</sup>Eye Research Center, Rassoul akram Hospital, Tehran, Iran, Islamic Republic Of

**Objective:** Dissociated horizontal deviation (DHD) is a part of dissociated strabismus complex (DSC) characterized by slow outward movement of the eye in visual inattention periods. It usually accompanies dissociated vertical deviation (DVD). However, DHD is less well-known than DVD and DVDs are more prominent than DHDs in most cases. Herein, we present successful treatment of a case of residual DHD treated with medial rectus plication, as a novel surgical approach in the management of DHD.

**Methods:** A 20-year-old woman with chief complaint of left eye outward deviation since childhood was referred to strabismus clinic. On examination, best-corrected visual acuity (BCVA) of 20/25 in the right eye and 20/30 in the left eye were detected. The diagnosis of DHD was made according to the detection of unilateral or asymmetric slow abduction of the non-fixating eye during visual inattention or cover testing. The exoshift of the left eye was variable and DHD was measured 30 prism diopters (PD) that increased up to 50 PD depending on the visual attention and concentration of the patient. There was concomitant vertical deviation (DVD) of left eye. However, the horizontal misalignment was predominant. The patient had no gross stereoacuity. At the first operation, the left LR was recessed 8 mm with posterior fixation suture (PFS). In the early postoperative period, the control of DHD was improved; however, after 6 months, the patient and her parents complained of frequent observation of exoshift of left eye. On examination, she had 20 PD residual DHD increasing up to 30D with visual inattention. For the better control of DHD, medial rectus plication of the left eye was considered as the second operation.

**Results:** After 6 months follow up, the control of deviation was improved and there was no manifest deviation. No consecutive exoshift was occurred. Mild bumping observed on the nasal conjunctiva in the early postoperative period, decreased gradually to an unnoticeable level at the final follow up visit.

**Conclusion:** Surgical managements of Dissociated Strabismus Complexes have never eliminated the strabismus and the aim of these procedures are to help the patient to better control the manifest deviation. There are several options for surgical management of the DHD . Medial rectus plication can be considered as one of the reversible options and can be used in recurrences of DHD after the first surgical procedure.

**C-020****Severe sterile inflammatory keratitis associated with recurrent epithelial erosion after small-incision lenticule extraction**

J Hou, Y Lei<sup>1</sup>.

<sup>1</sup>Jinan mingshui Eye Hospital, Jinan, People's Republic of China

**Objective:** To report a case of atypical severe sterile inflammatory keratitis associated with recurrent epithelial erosion after small-incision lenticule extraction (SMILE).

**Methods:** This case report entailed the use of slit-lamp photography and anterior segment optical coherence tomography (AS-OCT) to evaluate the cornea in a patient with an atypical DLK in the right eye who underwent SMILE.

**Results:** A 32-year-old man had SMILE that was complicated by intraoperative epithelial detachment in the right eye. Corneal epithelial erosion reoccurred at 2 and 4 months after surgery. At the third time of epithelial erosion, slit-lamp examination revealed dense white infiltrates throughout the corneal cap-stromal interface. The patient was initially managed with high-dose topical antibiotics. After the negative culture and Gram staining results from the interface wash out, DLK was confirmed and topical steroids were administered immediately. The inflammation resolved and corneal transparency was achieved after the treatment.

**Conclusion:** This case demonstrates the rare and severe clinical presentation of DLK after SMILE, which was triggered by recurrent epithelial erosion. Timely diagnosis and appropriate treatment are highly critical for prognosis.

**C-021****Autologous retina transplantation surgery for refractory giant macular hole closure in Guatemala. Case report.**

R *Jule*, R *Jule Arana*.

**Objective:** To report two cases of patients with refractory macular holes treated with a novel technique of autologous retina transplantation (ART) surgery.

**Methods:** Case presentation. We retrospectively review two cases of patients with refractory macular holes, treated with autologous retina transplant. Ocular Coherence Tomography (OCT) images and fundus pictures are presented to highlight the ART surgery potential on refractory macular holes.

**Results:** First case an 82-year-old retired woman with history of retinal detachment surgery 8 years before consultation, and a failed free inner limiting membrane flap surgery for macular hole within the past 4 years. Best corrected visual acuity on left eye was 20/1600 (Snellen), had 1.15mm full thickness macular hole. She underwent ART surgery and 1 month after, macular hole was closed, autologous retinal graft in place and best corrected visual acuity was 20/200 (Snellen). Second case, a 77-year-old woman with history of retinal detachment surgery 3 years before presentation with 1.35 mm full thickness macular hole in her right eye, best corrected visual acuity was 20/2000 (Snellen). Patient underwent successful ART surgery and 1 month after, macular hole was closed, autologous retinal graft in place, with best corrected visual acuity reported 20/140 (Snellen).

**Conclusion:** According to the presenting case, autologous retinal transplantation surgery achieved both anatomical and functional success. ART surgery seems to be effective surgical intervention in cases of refractory giant macular hole, nevertheless longer follow up need to be done.

C-023

**BILATERAL RETINAL VASCULITIS DUE TO SARCOIDOSIS WITH RICKETTSIAL RETINITIS AND TEAR BIOMARKER CORRELATION**

I Acharya, P Mahendradas<sup>1</sup>, P B.V<sup>2</sup>, V K. Rao<sup>3</sup>.

<sup>1</sup>Uvea, <sup>2</sup>Retina, Narayana Nethralaya Foundation, <sup>3</sup>Rheumatology, Divisha Arthritis & Medical centre, Bangalore, India

**Objective:** To describe a case of bilateral retinal vasculitis due to sarcoidosis with rickettsial retinitis

**Methods:** A retrospective case report

**Results:** A 16-year-old male presented with complaints of diminution of vision in the left eye (LE) for 5 days following fever 1 month back. Best corrected visual acuity (BCVA) was 20/20 in the right eye (RE) and 20/160 in LE. Anterior segment was within normal limits. Posterior segment showed vitritis, snow ball opacities, peri-arcade sheathing (candle wax dripping sign), hard exudates and yellowish-white retinal lesions at posterior pole in both the eyes. Few haemorrhages and neovascularisation at the inferotemporal quadrant (ITQ) in the RE were noted.

Optical coherence tomography (OCT) revealed hard exudates, periarcade hyperreflective retinitis lesion with back shadowing in the RE while cystoid macular oedema and parafoveal retinitis lesions in the LE. Fundus fluorescein angiography (FFA) observed perivascular leakage, collaterals, neovascularisation and capillary nonperfusion (CNP) areas in the ITQ in the RE and similar findings in LE except neovascularisation and CNP areas. Weil felix test was positive with raised ACE levels. Topical, oral steroid and doxycycline were started and targeted laser therapy to CNP areas was done. Later, oral methotrexate (MTX) 15mg/week with folic acid was also started. A month later, intravitreal Ozurdex™ was injected to the left eye in view of incomplete resolution of macular oedema with persistence of retinal vasculitis and dose of MTX was increased to 20mg/week. BCVA on the last visit had improved to 20/30 in LE with retention of 20/20 BCVA in the right eye and OCT showed complete disappearance of macular oedema in LE and marked reduction in the hard exudates in RE. Tear biomarker analysis showed raised ICAM-1 levels in both eyes and a raised MMP-9 levels in RE on presentation which significantly reduced on the final visit. However, MMP-9 levels increased after a month in LE which eventually showed drastic reduction following intravitreal Ozurdex™ injection on the final visit.

**Conclusion:** Ocular sarcoidosis with rickettsial infection is a rare association. Tear biomarkers correlated well with clinical and imaging manifestations. High index of suspicion and aggressive anti-inflammatory therapy can help control inflammation and restore good vision.

C-024

## Isolated Intraocular Relapse of B-Cell Acute Lymphoblastic Leukemia Masquerading as Ciliary Body Masses in a Filipino Child

M Jereza<sup>1</sup>, B Mesina<sup>1</sup>.

<sup>1</sup>Department of Ophthalmology and Visual Sciences, Philippine General Hospital, Manila, Philippines

**Objective:** To report the case of a pediatric patient with isolated intraocular relapse of B-Cell ALL initially presenting as bilateral ciliary body masses.

**Methods:** A 7-year-old female with underlying B-Cell ALL in remission presented with a three-week history of right eye redness, photophobia, and tearing. The right eye had decreased visual acuity at 20/167 (logMAR 0.92). Slit-lamp biomicroscopy of the right eye revealed a hazy cornea with bedewing, hyphema, a shallow anterior chamber, anterior bowing of the iris, and intraocular pressure was elevated at 38 mmHg. The left eye initially had unremarkable findings, however, after one month, developed fine, non-pigmented keratic precipitates, anterior chamber cells 1+, and anterior bowing of the temporal iris. Ultrasound biomicroscopy revealed large ciliary body masses on all clock hours of both eyes. Bone marrow aspiration biopsy and cerebrospinal fluid analysis were negative for leukemic cells which strongly suggested the diagnosis of isolated ocular relapse.

**Results:** Acute lymphoblastic leukemia (ALL) relapse occurs in 15-20% of cases of pediatric ALL. Ocular relapse of ALL is uncommon, which comprises 0.5%-2.5% of leukemic relapse. From other studies, presence of ophthalmologic manifestations is considered a marker of poor prognosis due to a higher incidence of central nervous system leukemia. In our case, remission reinduction chemotherapy was initiated, resulting in symptomatic and clinical improvement. On repeat ultrasound biomicroscopy done after the first month of chemotherapy, the ciliary body masses previously seen were no longer appreciated.

**Conclusion:** Ocular infiltration may be the only manifestation of B-Cell ALL relapse. This case highlights the importance of having a high index of suspicion when a known case of ALL presents with ocular symptoms. Prompt diagnosis and initiation of chemotherapy and radiotherapy produce more favorable ophthalmologic and systemic outcomes, hence will have an impact on the prognosis of patients with ALL relapse.

# *VIDEOS*

**V-001****CSI Heidelberg: A view from inside**

G U Auffarth, T Yildirim<sup>1</sup>, M Hammer<sup>1</sup>, L Zhang<sup>1</sup>, W Yan<sup>1</sup>, S Schickhardt<sup>1</sup>, P Merz<sup>1</sup>.

<sup>1</sup>Dept. of Ophthalmology - University of Heidelberg, International Vision Correction Research Centre (IVCRC) & David J Apple International Laboratory for Ocular Pathology, UNIVERSITY OF HEIDELBERG, Heidelberg, Germany

**Objective:** Complex optics or optical systems are sometimes difficult to implant. How does it look from the inside of the eye using the Myaki Apple technique and other techniques at the D. J. Apple International Laboratory for Ocular Pathology

**Methods:** We look at the performance of the new system such the Samsara Implantable Miniature Telescope (IMT) for AMD, and duet implantations and other specific optics, and analyze the performance in the capsular bag

**Results:** The video analysis shows what implants are easy and what implants are difficult to implant, what structures can be altered or how secure and safe these implantations are.

**Conclusion:** The video analysis shows what implants are easy and what implants are difficult to implant, what structures can be altered or how secure and safe these implantations are.



**V-002****The lost world gained again**

O Sarkar<sup>1</sup>, S Mandal<sup>1</sup>, A Maitra<sup>1</sup>.

<sup>1</sup>*Ophthalmology , Regional Institute of ophthalmology Medical College Calcutta, kolkata, India*

**Objective:** To determine how to remove the opacified foldable IOL from the capsular bag without making a larger incision. and postoperative assessment of visual out come and astigmatism

**Methods:** Prospective interventional case series of 6 cases. All the cases had operated two years back. A group of patients reported in the OPD with gradual onset severe loss of vision few years after successful Phacoemulsification. On examination all the cases were found to have opacified IOL material. The plan is to exchange the IOL from the bag with minimum manipulation and minimum incision length. There is risk of severe adhesion of IOL haptic in the capsular bag and posterior capsular rent due to previously performed YAG laser capsulotomy from misdiagnosis.

**Results:** In all the cases optic have been lifted out of the capsular bag into the anterior chamber after cutting the haptic and keeping it in situ in capsular bag. Then guitar wire in the form of a fine loop was introduced through the unloader cartilage which is previously widened by cutting the tip of the unloader with a scalpel blade make it flexible during IOL delivery. It is passed through 2.8 mm corneal wound to remove the opacified IOL. Each case tramcinolone acetonide injection given to detach the vitreous in ac. Limited Anterior Vitrectomy was done, if required. Foldable IOL was placed in the sulcus

**Conclusion:** This is a novel technique of IOL exchange where entry and exit is the same wound 2.8 mm incision. All the patient gained their lost vision. In future this is one of the modalities of IOL exchange.

**V-003****A story of Pupilloplasty in a case of traumatic subluxated mature cataract**

N Tank<sup>1</sup>, S Dixit<sup>2</sup>, K Jain<sup>3</sup>.

<sup>1</sup>Cornea, Cataract, Refractive, <sup>2</sup>Glaucoma, <sup>3</sup>Retina & Uvea, SRJ Netralaya, Indore, India

**Objective:** The objective of this video is to demonstrate the technique of phacoemulsification and pupilloplasty in a case of traumatic subluxated mature white cataract with pupillary spincter damage and traumatic mydriasis.

**Methods:** After appropriate informed and written consent, patient was taken in the operation theater for phacoemulsification + Capsular hook + Capsular tension ring implantation + 3 Piece Intraocular lens (IOL) + pupilloplasty under local anaesthesia. Surgeon approached from temporal side and 2 side port incisions and 1 main 2.8 mm incision were created. Mature cataract was decompressed using 26 G straight needle to decrease the intralenticular pressure, Following which capsulorhexis was initiated using rhexis forceps. Using high molecular weight OVD and micro rhexis forceps rest of the capsulorhexis was completed. Single iris hook was used as capsular hook at 5 clock hours and then soft lens matter was aspirated using co-axial irrigation - aspiration probe using low flow rate and low vacuum settings. A 12mm capsular tension ring was implanted in the bag and then iris hook was removed. 3 piece monofocal IOL was implanted in the bag. After injecting pilocarpine (0.5% w/v) in the anterior chamber pupil was pulled in from all around to bring it to natural state. 2 Single pass four throw pupilloplasty sutures (originally described by Dr. Amar Agarwal) were passed from inferior iris tissue to reshape the pupil. OVD was removed and wounds were sealed using hydration. Total surgical time was 1 hour 20 minutes for this case.

**Results:** Patient had good visual and anatomical outcome. Patient's vision improved from hand movement and perception of light pre operatively to best corrected distance vision of 6/9 at the end of 1 month. His pupil size of left eye was 2 -3 mm as compared to 5- 6 mm pre operatively.

**Conclusion:** Mature traumatic subluxated cataract can be managed with appropriate phaco settings and extra tools like iris hooks & capsular tension ring. Single pass four throw pupilloplasty is effective and easy technique for management of traumatic mydriasis.

**V-005****An Eye of a Cataract Surgeon with An Intraoperative OCT**P Gireesh.**Objective:** Use of technology in ophthalmology has grown leaps and bounce.**Methods:** The introduction of the intraoperative OCT provided new insights in the surgical management of ophthalmic surgeries.**Results:** This video shares how the intraoperative OCT aided in cataract surgery in various scenarios like wound construction, posterior polar cataract, zonular dialysis , femtosecond laser assisted cataract surgery , loop technique , small pupil management , and also explain its limitations**Conclusion:** Intraoperative OCT will be a good asset for the cataract surgeon.

**V-006****Posterior capsule rupture management during Phacoemulsification: A stitch in time saves nine!**Z I Khatib.

**Objective:** To demonstrate a less understood, but very important surgical pearl in the management of posterior capsule rupture during phaco surgery.

**Methods:** Posterior capsule rupture is a dreaded complication during phaco surgery, but it is well known that if managed appropriately, can minimize complications. This video demonstrates 2 surgical cases to highlight a very important surgical tip for PCR management: immediate lowering of the infusion pressure when the PCR is detected.

**Results:** The first surgical case shows that when the infusion pressure is not lowered, how the collateral damage can increase, and management of the remaining steps becomes cumbersome. The second surgical case shows that if the infusion pressure is lowered, how easily the rest of the surgery proceeds in a controlled environment.

**Conclusion:** In PCR management, timing is everything. If one waits for too long to think, the damage is already done. Truly said: a stitch in time saves nine.

V-007

### Transscleral IOL Fixation via Z-suture Technique

S Someda.

**Objective:** Transscleral suture fixation of intraocular lens commonly involves creating a knot, which can lead to suture erosion.

**Methods:** This is a case of a 76-year old female with pseudoexfoliation syndrome who had complications during cataract surgery of her right eye. The aphakic patient was scheduled for a secondary intraocular lens implantation 3 months after her cataract surgery.

**Results:** IOL was successfully implanted and the patient regained 20/20 vision on her right eye.

**Conclusion:** The surgery demonstrates a knotless technique by passing the suture intrasclerally in a zigzag pattern to help reduce suture-related complications.

V-008

**Triple trouble , resilient pupil, runaway rhexis ,and brown cataract**S Mitra, S Paul<sup>1</sup>, A Paul<sup>2</sup>.<sup>1</sup>*ophthalmology, AMRI Medical Centre,* <sup>2</sup>*ophthalmology, B.B.Eye Foundation, Kolkata, India*

**Objective:** The covid -19 pandemic had deffered ennumerous disease treatment and management and one of them is cataract. A case is reported here of such a deffered cataract with a poorly dilating pupil .Intraoperatively there was a runaway rhexis along with a resilient pupil. But this was managed successfully

**Methods:** An old lady with poor dilated white on brown cataract underwent phacoemulsification. The pupil size was 5.5 mm and 5mm rhexis marker was used. Trypan blue was used to stain the anterior capsule. At the nick with cystitome there was milky fluid escape and so decompression was done with a cannula fitted with an empty syringe by sucking fluid from below the capsule. Viscodilatation and drugs to dilate were used . But the rhexis was small. As the case proceeded to phacoemulsification it went further to 3 mm.The Chopping was incomplete due to thick leathery plate, less place in the bag, and small rhexis . So 5 hooks were used to dilate the pupil.While enlarging, the rhexis ran away. But with controlled fluidics in closed chamber under direct visualisation Phaco was Continued. The nucleus could not be cracked centrally . There was triple trouble now. But peripheral debulking and slow Phacoemulsification under high density viscoelastics saved the case .

**Results:** There was triple trouble of a poorly dilated pupil, small rhexis which had a runaway on enlarment and the cataract was learthery hard. The 5 hooks used to dilate the pupil made the debulking from periphery easier in a leathery cataract. Technique used were , second instrument to feed the nucleus into the probe, phacoemulsification under direct visualisation , manintaining stable anterior chamber depth and using high vaccum to chop the hard cataract. High density viscoelastics to protect the posterior capsule and endothelium of cornea were used. Finally the nucleus management from periphery to centre completed the case and the intraocular lens was inserted in the bag after removal of the pupil dilators. The wounds were hydrated and closed

**Conclusion:** Dealing with hard cataracts we need to be ready for intraoperative surprises. Hooks are pupil dilators universally accepted for small pupils and should be there in the OT. A leathery cataract requires sharp intrumentation, good OVD and correct technique with friendly fluidics to complete such cases . Finally patience and controlled surgery can bring success in such challenges

**V-009****Simplified Cataract Surgery**R Nacouzi<sup>1</sup>.<sup>1</sup>*Pole Santé Sud, LE MANS, France*

**Objective:** To operate cataract without hydrodissection, without hydrodelineation and without nucleus rotation.

**Methods:** For years, hydrodissection, hydrodelineation and nucleus rotation were mandatory for a successful phacoemulsification. Simplified Cataract Surgery is phacoemulsification without hydrodissection, without hydrodelineation, and without nucleus rotation.

**Results:** Simplified Cataract Surgery is faster and safer than the traditional techniques (divide and conquer, phaco chop, ...) since it excludes Hydrodissection related Complications, and there is practically no zonular stress. The technique is explained, step-by-step, through several examples, from very hard to soft and polar subcapsular cataract.

**Conclusion:** Simplified Cataract Surgery is a simplified phacoemulsification technique that does not use hydrodissection, hydrodelineation nor nucleus rotation.

**V-013****Cosmetic Iris Implant Removal Complicated by Inferior Iridotomy.**O Al Nahrawy.

**Objective:** Desire for cosmesis has been pushing large number of people, females and males, to have an iris implant prosthesis surgery to change eye color. This off-label procedure, over years, has been a reason for many serious ocular complications, like ocular hypertension, endothelial cell loss, cataract and glaucoma.

**Methods:** This video shows a removal technique for an iris implant. There has been an inferior iridotomy as a complication during removal. It was intended not to make a pupilloplasty to manage this iridotomy, in order to reduce manipulations over the lens capsule, and also it was expected when the pupil closes, the little deformity of the pupil may not disturb vision.

**Results:** Surgical removal of cosmetic iris implants, although it should be done, but it may add further complications to the complications of the implants.

**Conclusion:** Cosmetic Iris implant surgery is a high risk surgery that would result into a number of serious ocular complications. Surgical removal of these implants should be performed and carries possible surgical risks.



**V-014****IOL scaffold for Posterior Capsular Rupture in Phacoemulsification**N Dr. R *Tammineni*.

**Objective:** To find a method to complete the surgery without extending the section in the adverse event of intraoperative posterior capsular rupture in phacoemulsification.

To prevent dislocation of lens particles into vitreous during PCR.

To minimise astigmatism postoperatively.

**Methods:** As soon as PCR is noticed intraoperatively in phacoemulsification surgery without becoming panic inject viscoelastic through the side port and slowly withdraw the phaco probe by stabilising the chamber. Nuclear remnants to be brought into anterior chamber above Iris. Inject Foldable IOL in anterior chamber entirely or with one haptic on sulcus through same incision. Emulsification of remaining lens, Anterior vitrectomy safely can be done using IOL as scaffold. Then the second haptic placed on sulcus.

**Results:** Post operatively cornea is clear and IOL is well positioned on sulcus with no astigmatism.

**Conclusion:** IOL scaffolding is a safer procedure in intra operative PCR in phacoemulsification to prevent lens dislocation and to avoid the postoperative astigmatism.

**V-016****3-year-old boy traumatic cataract with penetrating corneal history four weeks ago**

S Zırtıloğlu.

**Objective:** To discuss the cataract operation of a patient who had a corneal laceration about 4 weeks ago due to penetrating trauma and therefore sutured to the cornea.

**Methods:** We observed that the patient had a traumatic cataract on the postoperative 1st day after suturing his cornea. Since the capsule was intact, the cataract operation was waited for approximately four weeks to heal the wound. The procedure did not wait for a longer time so that amblyopia did not develop.

**Results:** Firstly, corneal sutures were removed. We stained the capsule with trypan blue under-air. The capsule tear was difficult to open. After that, capsulorhexis is also difficult to complete. The capsule was fibrotic, not elastic, as expected in young children. So in some places, it was necessary to cut the capsule. Finally, after capsulorhexis completing, while the capsule was removing, we observed that the vitreous was in the anterior chamber. First, an attempt was made to cut the vitreous by manual dissection. Since manual dissection was not enough, anterior vitrectomy was performed with the phaco device. We performed gentle hydro dissection without waiting for the liquid to return to the full-back of the lens. We aspirated the patient's lens with cortex aspiration. We saw the posterior capsule rupture after the lens aspiration was complete. The anterior hyaloid was removed by enlarging the posterior capsule opening with the anterior vitrectomy tip.

We placed inverted IOL capture with the legs of the 3-piece lens to the sulcus and the body to the capsule. The eye closed after intracameral antibiotics and subconjunctival steroid injections after suturing all access points.

**Conclusion:** It is essential whether there is vitreous in the anterior chamber in patients with traumatic cataracts. In our case; Since the child is too young, the examination with slit-lamp microscopy could not perform very efficiently preoperatively, so we did not recognize vitreous band was there before the operation. Performing anterior vitrectomy before initiating capsulorhexis will facilitate the capsulorhexis stage and reduce potential vitreous shrinkage.

V-017

## A Mole In The Eye Managed With Excision and Amniotic Graft Patch

A Sinha<sup>1</sup>, J Bose<sup>2</sup>.

<sup>1</sup>Ophthalmology, Worcestershire Acute Hospitals NHS Trust, Worcester, United Kingdom, <sup>2</sup>Ophthalmology, EyeQ Hospitals, Gurgaon, India

**Objective:** Conjunctival nevi are the most common benign tumors of the conjunctiva accounting for 28% of all neoplastic lesions and form 53% of all excised conjunctival lesions. It is a melanocytic hamartoma that arises during childhood and becomes prominent at puberty. It can be mistaken for malignant melanoma. Melanocytic nevus cells are developmentally abnormal cells that retain melanin due to lack of dendritic pattern found in normal melanocytes.

**Methods:** A 19-year old girl presented to our institution with a pigmented lesion of conjunctiva in right eye since 10 years duration. Lesion was painless and non-progressive but was aesthetically unacceptable to the patient. It was a nasal, juxta-limbal, single, moderately pigmented, slightly raised, avascular, mobile lesion with well demarcated margins extending from 1'o clock to 4'o clock and measuring approximately 2 x 1 cm in dimension. A simple excisional biopsy with cryotherapy and amniotic membrane graft patch was performed.

**Results:** Post operatively patient was put on topical steroids and antibiotic that were tapered gradually and stopped. Histopathological findings revealed presence of nevus cells at the interface of conjunctival epithelium and underlying stroma with intracytoplasmic melanin pigment intraepithelial mucus cells.

**Conclusion:** The diagnosis was based purely on histopathological findings. All conjunctival nevi don't require surgical excision and biopsy. But the ones with atypical appearance should not be ignored due to their resemblance to other benign pigmented lesions of conjunctiva and their propensity to turn malignant.

V-019

**Hand Sanitizer Induced Alkaline Chemical Corneal Injury In a 4-Year-Old Child: Case Report**

M Ahmad<sup>1</sup>, O Azzam, B Armstrong<sup>2</sup>.

<sup>1</sup>Ras Al Khaimah Medical and Health Sciences University, Ras Al Khaimah, <sup>2</sup>Cleveland Clinic Abu Dhabi Hospital, Abu Dhabi, United Arab Emirates

**Objective:** The COVID-19 global pandemic has led to alcohol-based hand sanitizer (ABHS) dispensers being more prevalent in public spaces for hand hygiene. The purpose of this case report is to emphasize that ocular exposure to ABHS can induce a vision threatening chemical injury.

**Methods:** In this report, we cover a case of a four-year-old girl who suffered accidental exposure of ABHS to her right eye, causing a grade 1 chemical injury with a near total corneal epithelial defect and corneal haze. The patient's mother provided signed informed consent permitting us to publish the details of the case and related clinical non-identifiable imaging/pictures. On presentation, the eye was aggressively irrigated, and there were no signs of limbal or conjunctival ischemia. After topical therapy and pressure patching resulted in minimal to no healing, a Prokera (Bio Tissue Inc., Doral, 1997) amniotic membrane was placed under general anesthesia.

**Results:** One week later, the Prokera was removed, and the patient had complete recovery of the corneal abrasion. There was diffuse superficial punctate keratopathy and grade 1 corneal subepithelial haze. She was then placed on artificial tears and prednisolone 1% ophthalmic drops 4 times daily. Three weeks later, the patient presented to the clinic with complete resolution of the erosions and corneal haze, and vision was back to baseline.

**Conclusion:** This case highlights both the importance of parental supervision to avoid accidental ocular exposure to ABHS and the benefit of utilizing a self-retaining amniotic membrane in the management of a pediatric chemical ocular injury.

**V-020****Therapeutic Penetrating Keratoplasty (PKP) for Resistant Corneal Abscess and Opacity after PRK**O Al Nahrawy.

**Objective:** The patient is a 35 years old lady, living in the countryside and poor hygienic environment. She had a photorefractive keratectomy to manage poor vision due to moderate myopia (-3.5 DS OU). She developed corneal infection and abscess that was resistant to antibiotic, antifungal treatment and was resistant to Ribroflavin - Ultraviolet cross linking. She developed a dense corneal opacity, and vision dropped to hand motion.

**Methods:** The patient received local anesthesia. An 8.00 mm graft was obtained from a cornea bank. The corneal pathology was removed with a 7.5 mm trephine. The graft was fitted to the recipient bed with 8 preplaced sutures and two runs of 10/0 nylon sutures. The anterior chamber was left deeply formed, the eye pressurized and the wound air-tight and water-tight.

**Results:** Therapeutic penetrating keratoplasty technique, when done properly without intra-operative or post-operative complications, is a final intervention. This technique could restore vision for cases with dense scarring complicating resistant corneal infections after PRK..

**Conclusion:** Photorefractive keratectomy may have serious complications, up to corneal abscess and scarring. Post-operative antisepsis and hygienic environmental conditions should be available. Therapeutic penetrating keratoplasty could be used to manage corneal scarring after complicated cases.

## V-023

**Novel Use of the Intra-Operative Optical Coherence Tomography in Trabecular Bypass Minimally Invasive Glaucoma Surgery**

B C Ang<sup>1,2</sup>, S Lim<sup>3</sup>, B Betzler<sup>4</sup>.

<sup>1</sup>Department of Ophthalmology, Tan Tock Seng Hospital, National Healthcare Group Eye Institute, <sup>2</sup>Department of Ophthalmology, Woodlands Health Campus, National Healthcare Group Eye Institute, <sup>3</sup>Army Medical Services, Singapore Armed Forces, <sup>4</sup>Yong Loo Lin School of Medicine, National University of Singapore, Singapore, Singapore

**Objective:** The use of intra-operative optical coherence tomography (iOCT) has been gaining popularity in glaucoma surgery and more recently, in minimally invasive glaucoma surgery (MIGS), with the aim of improving intra-operative visualization and achieving better post-operative outcomes. In angle-based MIGS, surgical precision is critical yet challenging, given the difficulty in intra-operative visualization within the small space of the angle.

**Methods:** This video uses real-life case examples to demonstrate how the iOCT may aid in ensuring optimal placement of two trabecular bypass MIGS devices – the iStent inject W and the Hydrus Microstent.

**Results:** A good understanding of the anatomical correlation between MIGS devices and their appearance on iOCT images is critical in enhancing the utility of the iOCT in trabecular bypass MIGS. The iOCT aids the surgeon in identifying inadvertent underimplantation of the iStent inject W, which may be occasionally missed due to the larger-diameter flange of this latest-generation iStent obscuring the exposed thorax of an underimplanted stent. The iOCT also aids the surgeon in ensuring optimal placement of the Hydrus Microstent in the Schlemm's canal, particularly where the microstent windows cannot be visualized behind a heavily pigmented trabecular meshwork (TM) or dense iris processes.

**Conclusion:** The iOCT may be a feasible and useful adjunct to MIGS, particularly in ensuring the optimal placement of trabecular bypass MIGS devices. The iOCT may aid the surgeon in identifying an under-implanted iStent inject W, and in ensuring optimal placement of the Hydrus Microstent in the Schlemm's canal despite challenging visualization of the microstent windows through heavy angle pigmentation or dense iris processes.

V-024

**Successful Clinical Experiences using the iStent inject® W Recovery Device**K Yasuoka<sup>1</sup>.<sup>1</sup>*Yasuoka eye clinic, Kochi, Japan*

**Objective:** To report the efficacy of the iStent *inject*® W (Glaukos Corporation) recovery device called the iStent Saver©. The iStent *inject*® W (the iStent) is the world's smallest trabecular micro-bypass stent (body diameter: 360 µm) and is inserted into Schlemm's canal to lower intraocular pressure. In some cases of implant failure, the device dislocates from Schlemm's canal and floats into the anterior chamber, becoming extremely difficult to capture and reinsert intraocularly. I have experienced situations where there was a risk of serious complications, including the device becoming lost or migrating. To avoid these complications, I have developed a recovery device called the iStent Saver©, which is safer and easier to remove via aspiration. Nine procedures were performed using iStent Saver© at the Yasuoka Eye Clinic between October 2020 and September 2021.

**Methods:** A 22-gage intravenous catheter polyethylene outer tube was used because it is large enough (lumen size: 650 µm) to accommodate the iStent. The metal needle from the outer tube was removed, and then the tube was cut to the corneal diameter of approximately 12 mm and attached to a 2.5ml syringe. The tube tip was inserted through the corneal incision for phacoemulsification and aspiration of cataract surgery and placed close to the iStent, and suction was applied to remove the iStent. The tube was removed and flushed, and the iStent was placed in an external container. After the iStent was reattached to the iStent injector using a microscope, the injector was reinserted into the anterior chamber through the corneal incision, and the iStent was re-implanted into Schlemm's canal.

**Results:** All nine procedures using the iStent Saver© were performed safely and successfully.

**Conclusion:** The iStent Saver© is a useful recovery device for the iStent *inject*® W. It is easy to assemble and use safely and has a good cost-performance ratio.

**V-025****Transconjunctival XEN Implantation in the Eye with Scleromalacia Caused by 'Eye-Whitening Surgery'**J Choi, M Kim<sup>1</sup>.<sup>1</sup>*Glaucoma Service, CENTRAL SEOUL EYE CENTER, Seoul, Korea, Republic Of*

**Objective:** This video is to elucidate what glaucoma surgical procedure is best suitable in the eye with scleromalacia caused by 'eye-whitening surgery', and to present the clinical course of a transconjunctival XEN implantation in this eye.

**Methods:** The 'eye-whitening surgery' is a once-popular cosmetic eye surgery in South Korea, which removes conjunctiva and Tenon's capsule on the temporal and nasal quadrants to relieve chronic conjunctival hyperemia. Due to the serious postoperative complication issues including scleromalacia, it has been prohibited by law in Korea. The selection of glaucoma surgery in these eyes is extremely difficult, as normal ocular surface structure was destroyed. A 65-year-old male patient who previously had had 'eye-whitening surgery' 15 years ago underwent transconjunctival XEN implantation. 0.1ml of 0.04% Mitomycin C injection was done at the start of surgery.

**Results:** Low-lying diffuse bleb persisted over the follow-up period of more than 1 year. Intraocular pressure was controlled without any topical anti-glaucoma medication, and no serious complication was noted. Anterior segment OCT examination revealed that the bleb was mixed with subconjunctival reservoir and multiple porous spaces.

**Conclusion:** Transconjunctival XEN implantation could be considered as the first-line surgical treatment in the glaucomatous eye with scleromalacia caused by 'eye-whitening surgery'.



V-027

**Saving Private I-STENT**

R Maroto Cejudo<sup>1</sup>, G Yañez Castro<sup>1</sup>, M Rojo Arnao<sup>1</sup>, D Espinosa Encalada<sup>1</sup>, M Gonzalez Garrido<sup>1</sup>.

<sup>1</sup>Hospital Virgen de la Luz, Cuenca, Spain

**Objective:** To present a clinical case of a difficult implantation of i-Stent inject W (Glaukos®) trabecular device.

**Methods:** A 75 year old female with mild open angle glaucoma treated with double therapy (bimatoprost and timoptol) that develops cataract in left eye. Cataract surgery in association with i-stent inject W implant is performed.

**Results:** After making corneal incisions and depression of the conjunctiva in order to increase episcleral venous pressure (for better gonioscopic visualization of Schlemm's canal), the anterior chamber is filled with cohesive OVD. The trabecular meshwork is identified with a gonioscopic lens and with the help of the injector, the first i-stent W implant is placed in the trabecular meshwork. Unfortunately, the second implant is released at the same time, with the first shot, remaining free in the anterior chamber. A series of maneuvers must be carried out to rescue it, insert it back into the injector and place it again in the trabecular meshwork, considering that the i-stent device have only two additional shots for these cases. These surgical images are interspersed with scenes from the movie "Saving Private Ryan."

**Conclusion:** In certain occasions there are difficulties when implanting i-Stent inject W trabecular device. However, it is possible to overcome them, resulting in a successful surgery.

V-028

**Art Of Remolding**S Liu<sup>1</sup>, J Wang<sup>2</sup>.<sup>1</sup>weifang eye hospital, weifang, <sup>2</sup>weifang eye hospital, shandong weifang, People's Republic of China

**Objective:** To present a case of capsule contraction syndrome in acute angle-closure glaucoma after the phacoemulsification combined with intraocular lens implantation, capsular tension ring implantation and goniosynechialysis.

**Methods:** This was a 59-year-old female patient. The chief complaint was blurred vision with acute pain in the right eye for 2 days. It was diagnosed with acute angle-closure glaucoma. For the right eye, it was operated phacoemulsification combined with intraocular lens implantation, capsular tension ring implantation and goniosynechialysis. Left eye was operated with phacoemulsification combined with intraocular lens implantation, and goniosynechialysis. Postoperative 2 weeks, the BCVA of right eye was 0.5 with a IOP of 13 mmHg. Postoperative 1 month, it showed mydriasis and capsule contracted. Two months later, blurred vision emerged in the right eye, capsular contracture was aggravated with the OSI of 4.8. It was diagnosed with capsule contraction syndrome and required the intervention. The second operation was performed: removing the contracted anterior capsule and circle suture of pupil to normal size using the purse-string method.

**Results:** The patient felt much better after the intervention. 3 weeks later, UCVA of the eye was 1.0 with an IOP of 15 mmHg without medication. The pupil was round and the size nearly the same to the other eye. Visual quality was significantly improved, with the OSI of 1.2 compared to 4.8 preoperatively.

**Conclusion:** The purse-string suture mydrioplasty is used for the treatment of patients with acute angle-closure glaucoma with mydriasis, which is of great significance for improving visual quality and stabilizing the level of intraocular pressure. Acute angle-closure glaucoma is often accompanied by capsular and zonular laxity, which requires implantation of a capsule tension ring, and the radius of capsulorhexis should be proper to prevent the occurrence of capsular contracture syndrome.

**V-029****Phaco-endocycloplastic resolution of acute-on-chronic angle (A-O-C) closure glaucoma**V Pathak Ray.

**Objective:** Objective: Primary Angle Closure Glaucoma (PACG) is a chronic and largely asymptomatic disease (unless presentation is late). However, this may occasionally be intercepted by a symptomatic acute presentation in the presence of glaucomatous disc changes. We present a video with the outcomes in a series of such eyes which underwent phaco-endoscopic cycloplasty (phaco-ECPL) for resolution of the condition and control of intraocular pressure (IOP).

**Methods:** Methods: Consecutive eyes with A-O-C PACG that underwent lens extraction and endoscopic cycloplasty for resolution of the condition after laser peripheral iridotomy (LPI), and control of inflammation were included.

**Results:** Results: Six eyes of 5 patients with A-O-C PACG underwent phaco-ECPL; all were female. All eyes presented with pain and high IOP, increased lens thickness (LT) and had variable degrees of synechial angle closure gonioscopically. All eyes achieved satisfactory resolution of the acute event, control of IOP and reduction in topical anti-glaucoma medication. No serious sight threatening complications occurred in any of these eyes.

**Conclusion:** Conclusion: Phaco-endocycloplasty is an effective and safe procedure for the resolution of acute angle closure in PACG along with control of IOP with reduced topical medications and without compromising safety.

**V-030****See to feel****Peru-three decades'figh against blindness**C Wong-Cam, C *Wong-Morales*.

**Objective:** A documentary of the programs to combat blindness carried out in Peru is presented by Doctor Carlos Wong-Cam who founded and directed the Peruvian Organization to Combat Blindness (Organización Peruana de Lucha contra la Ceguera -OPELUCE), a non-profit institution. The presentation comprises three decades of work in poor and remote populations lacking specialized eye care , describing unique aspects that made him a pioneer in the prevention of blindness in Latin America

**Methods:** Blindness is a growing public health problema, so eliminating avoidable blindness is a priority. The methodology used aims to provide comprehensive care, which highlights primary eye care, clinical and surgical ophthalmological care, epidemiological research and rural rehabilitation of blind people  
The conditions in which these programs were carried out show with harsh enough the environment of marked poverty and terrorist violence that prevailed in this country, to remind us of a not too distant past that serves as a testimony and example for future generations

**Results:** The images include patients with relevant ophthalmic pathology and surgical interventions in hostile environments under precarious conditions, where the protagonism of the volunteer ophthalmologist doctors project an image in which they draw strength of their sense of solidarity, transmitting the message of faith and hope with visual recovery.

The painstakingly images collected over many years as casual impressions of reality, some with extreme ocular deterioration, beyond the imaginable, cruel but loaded human-depth images, as a legitimate and necessary approach. Images that even most doctors will never see, but that will contribute not only to discovering the world but also help transform it

**Conclusion:** In addition, this documentary aims to sensitize ophthalmologists, health authorities and the general population so as not to fail to respectfully recognize the importance of preventive work in ophthalmology  
This documentary was produced in 2021, it is presented only as information to World Ophthalmology Congress (WOC) because we believe that it could contribute to the knowledge of other aspects of community eye health

**V-031****MRI interpretation - The eyes see what the mind knows**

R Bansal<sup>1</sup>, S Honavar<sup>1</sup>.

<sup>1</sup>*Ocular oncology and oculoplasty, Centre for Sight, Hyderabad, India*

**Objective:** In 1978, the advent of Magnetic Resonance Imaging (MRI) was a remarkable volte-face in the world of diagnostics. Employing the phenomenon of nuclear resonance enables us to exploit the properties of differential protons in living tissue. The ability of providing higher and variable contrast and the absence of ionizing radiations, makes it superior to Computed Tomography (CT). Being the diagnostic tool of choice, it is an indispensable part of assessment of the location and characteristics of different ocular and orbital pathologies (vascular, inflammatory and neoplastic).

**Methods:** In this video, we shall be displaying the anatomical, clinical and radiological aspect of MRI with an overlap to make it easier to understand the implications of this miraculous invention.

**Results:** The intrinsic and extrinsic properties of MRI provide multi-parametric imaging, making it of paramount importance in ophthalmological evaluation. Also, MRI-dynamic colour mapping provides non-invasive and quantitative assessment of soft tissues in motion. An in-depth knowledge of the basic principle and technique of MRI aids in diagnosing as well optimal planning of surgical interventions.

**Conclusion:** A good understanding of MRI analysis makes the ophthalmologists independent and helps in ruling out the differential diagnoses, exact extent and invasion, precise surgical planning and therefore, avoiding tragic outcomes.

V-032

**Plaque brachytherapy – Radiating positivity**R Bansal<sup>1,1</sup>, S Honavar<sup>1</sup>, V Reddy<sup>2</sup>.<sup>1</sup>Ocular oncology and oculoplasty, Centre for Sight, <sup>2</sup>Oncology, Apollo Hospitals, Hyderabad, India

**Objective:** Plaque brachytherapy is an evolving yet effective globe and vision-sparing modality for the treatment of intraocular tumors by transscleral irradiation of the tumor base with a radioactive implant. The American Brachytherapy Society (ABS) along with the collaboration of the international multi-center Ophthalmic Oncology Task Force (OOTF) was assembled to reach a consensus regarding establishing practise guidelines and setting standards of care for intra-ocular tumors.

**Methods:** In this video, we shall display the concept of plaque brachytherapy, the various types of plaques available, different radiations sources, planning dosimetry and calculations, target disease spectrum, surgical placement, post-radiation outcomes in terms of local tumor control and prognosis.

**Results:** This technique provides the advantage of focal radiation thus eliminating the damage to the adjacent structures, minimal periorbital tissue damage, absence of cosmetic disfigurement owing to lack of retarded bone growth as seen in external beam radiotherapy. Thus, reduces the risk of metastasis and with the recent advances, it provides a shorter duration of treatment.

**Conclusion:** The advent of plaque brachytherapy has revolutionized the outcomes of intra-ocular tumors thus ensuring globe salvage, reducing morbidity and mortality; and avoiding cosmetic disfigurement. A well-planned dosimetry for plaque brachytherapy results in achieving local tumor control and excellent prognosis.

V-033

### Evisceration By Equatorial Sclerotomy Technique

A Aishwarya, S Honavar.

**Objective:** To discuss various techniques and principles of evisceration to restore volume and to prevent enophthalmos with emphasis on Evisceration by Equatorial Sclerotomy Technique.

**Methods:** In this video, we demonstrate evisceration in a 39-year-old male with a painful blind eye following trauma. We use the novel circumferential complete equatorial relaxing incision technique in evisceration.

**Results:** This technique allowed a larger implant with anterior placement and thus preservation of orbital volume.

**Conclusion:** It is a simple procedure that allows the placement of a stable and an optimally sized implant following evisceration in the setting of atrophic bulbi or phthisis bulbi.

V-036

**ASPI (Anterior Segment photography with Intraocular lens) for Residents: An Innovative learning tool**H V GOSALIA<sup>1</sup>, P CHANDRAKANTH<sup>2</sup>.*<sup>1</sup>general, <sup>2</sup>vitreo-retinal service, ARAVIND EYE HOSPITAL, COIMBATORE, Coimbatore, India*

**Objective:** Slit lamp is the most essential tool in every ophthalmologist's clinic. Conventional slit lamp photography is expensive while the usage of mobile adapters needs the aid of slit lamp for photography. Anterior segment photography is important especially in peripheral or vision centers devoid of expensive equipments and expert opinions. We developed an innovative tool which was especially important for residents as a beginner for learning and using it for expert opinion without the aid of slit lamps.

**Methods:** We used ASPI; in which a 15D intraocular lens was attached to the back of the smartphone camera to capture the anterior segment findings made with the help of chartpaper and intraocular lens (used or expired). This was a do it yourself cheap frugal tool which could be prepared by anyone.

**Results:** Various ocular surface pathologies like lid, corneal surface, pupillary pathologies etc. could be captured with this user-friendly technique just with the aid of a smartphone and ASPI. These pictures could be shared online to experts or seniors for case-based discussions and decision on treatment. This setup is also useful for bedridden and ICU patients as opposed to slit lamps which is static and requires the patient to sit in front of the examiner.

**Conclusion:** This video is based on a resident's perspective of how ASPI; an innovative cost-effective DIY essential tool has transformed her academic journey in every aspect especially for case discussions, treatment opinion, publications and photo documentation in rural and emergency setups devoid of slit lamps.



**V-037****The First One-Hundred Capsulorhexes**E Roditi.

**Objective:** Performing a successful well-centred and correctly sized circular curvilinear capsulorhexis (CCC) is an essential skill for cataract surgeons. The journey from first attempts to perfection of this crucial step in modern cataract surgery is timely and challenging. In this video, I present my first one hundred capsulorhexes with pitfalls and pearls that I have learned along the way.

**Methods:** A review of cataract surgical videos performed during my first years of ophthalmology residency.

**Results:** The journey begins as I review the literature, watch endless surgical videos and shadow senior surgeons in the operating room. It progresses to wet labs and virtual reality surgical simulators. The day finally arrives when I attempt my first real capsulorhexis, and I fail... yet I persevere, until success. I'm starting to understand, but more challenges arrive: sizing issues, baby rhexis, huge rhexis, run-out, Littel maneuver, challenging viewing conditions, trypan blue, small pupils, intumescent cataracts. Slowly I continue to improve and before I know it I have completed one hundred capsulorhexes.

**Conclusion:** Even after performing one hundred capsulorhexes the journey to mastery is long. Surely, with continued learning and perseverance, we can all eventually arrive.

**V-038****SLIM : Slit Lamp Based Intraocular Lens Microscope**

P Chandrakanth, H Gosalia<sup>1</sup>.

<sup>1</sup>DNB RESIDENT, Aravind eye hospital, Coimbatore, India

**Objective:** To describe a frugal innovative do it yourself smartphone based microscope which will convert the slit lamp into a point of care diagnostic for diagnosing microorganisms

**Methods:** The emergence of smartphone based imaging devices have been a boon in the field of ophthalmology especially in obtaining high quality ocular images. The use of smartphone in diagnosing microscopic organisms have never been described. Here we show a video where one can make their own do it yourself IOLSCOPE - smartphone based microscope (made using 4 30D intraocular lens on a chart paper attached to the smartphone camera which cost less than 1\$ to make) and how to attach it to the slit lamp thereby utilizing it to get live, on spot, point of care diagnostic of fungal hyphae, parasites and other microorganisms. A corneal ulcer patient can get diagnosed using iolscope right at the slit lamp without any delay helping us provide prompt treatment for the patient. This innovative do it yourself novel modification is especially useful in peripheral centres, vision centres and local clinics for immediate screening and identification of microbial pathogens like fungi and ocular surface parasites. This is by far the only smartphone microscope which can be attached to the slit lamp and provide POC Diagnosis

**Results:** With the SLIM we can now take on spot images and video of microorganisms especially from corneal ulcer to differentiate fungal ulcers from bacterial and to start targeted treatment to patient allowing us to efficiently manage the disease. also to diagnose and rule out different parasite infestation which can be removed from the eyelashed causing ulcer mgd etc..

**Conclusion:** SLIM is a do it yourself frugal innovative smartphone based ophthalmic device which can be used to detect microorganism and can be used as a point of diagnostic device to rule out diagnose and treat various ophthalmic pathologies

**V-040****Complex Ocular reconstruction in severely damaged traumatic eyes.**

M Calatayud-Pinuaga, J Farrando<sup>1</sup>.

<sup>1</sup>*Retina and vitreous surgery, Clinica Delfos, Barcelona, Spain*

**Objective:** Traumatic eyes are very difficult to treat to achieve the best visual acuity, we describe a technique to combine iris remnants with and artificial humanoptics iris prosthesis to implant an iris-claw lens in an aphakic patient with partial aniridia and partial anterior capsule.

**Methods:** A 14y-o boy with traumatic partial aniridia, aphakia and epiretinal membrane is treated to restore the visual acuity and the anatomy of the globe. There was a previous vitrectomy to remove the intraocular metal foreign body ( a pellet). We start with the posterior pole, dyeing the posterior hyaloid with trimacinelone, dissecting it and then using dual blue to stain the membrane and peel it off. Once the vitrectomy is finished, we restore the anterior segment with a gently dissection of the iris stroma, trying to preserve as much as possible tissue to be enough to implant an Artisan IOL. A humanoptics artificial iris prosthesis is then cut to 10 mm diameter with a peripheral iridectomy to avoid glaucoma in the postoperative period. We locate the prosthesis into the sulcus, and hook the aphakia IOL under the iris remnants.

**Results:** The best corrected ( 80° -1.25 -1.00) visual acuity after one month is 20/20 after macular edema improves and the stitches are removed. There are no complications related to intraocular pressure or corneal endothelium

**Conclusion:** Traumatic eye surgery is an exciting subspecialty which requires an experienced surgeon capable of making decisions based on previous knowledge and the correct use of combined intraocular prostheses to obtain the best anatomical and visual results. Artificial iris prosthesis (humanoptics) may be combined with iris remnants and a small capsular support with iris-claw lenses to reach good results.

V-041

**Implantation of Fiber-Free Aniridia Prosthesis in a Posttraumatic in-the-bag Intraocular Lens Dislocation**

F González del Valle<sup>1</sup>, A Núñez Sánchez<sup>1</sup>, M Domínguez Fernández<sup>1</sup>, A Arias Palomero<sup>1</sup>, J Celis Sánchez<sup>1</sup>, J Zarco Tejada<sup>1</sup>, E Gándara Rodríguez de Campoamor<sup>1</sup>, L Riveira Villalobos<sup>1</sup>, E López Mondéjar<sup>1</sup>.

<sup>1</sup>Ophthalmology, La Mancha-Centro Hospital, Alcázar de San Juan, Spain

**Objective:** To show a new surgical technique for the fixation of aniridia prosthesis without fiber mesh in this case without capsular support.

**Methods:** We report a case of a 60 year-old man with aniridia and a posttraumatic in-the-bag intraocular lens (IOL) subluxation. In this patient, the in-the-bag IOL dislocation was refixed by two cow hitches grasping one of the haptics of the IOL and a new haptic donor that was introduced in the capsular bag. This allowed the implantation of a fiber-free iris prosthesis over the repaired in-the-bag IOL. The follow period was of 60 months.

**Results:** Correct stability and centering of the artificial iris prosthesis was achieved and maintained throughout the follow-up period. There were no postoperative complications.

**Conclusion:** Complications such as glaucoma, and need for consecutive anterior segment surgery could be associated with artificial iris implants with integrated fiber mesh. Therefore the fiber-free iris prosthesis would be the recommended option in cases of aniridia. This video shows a new technique to place a foldable artificial iris prosthesis without fiber mesh in a in-the-bag IOL dislocation. This technique could be a good alternative to avoiding the use of iris prosthesis with fiber mesh, even in absence of capsular support.

**V-045****Unveiling the Veil – A Vignette of Intra-Operative Evidence of Anatomical Variations of the Levator**D Kurian, S Honavar.

**Objective:** Knowledge about the anatomy of Levator palpebrae superioris (LPS) is imperative to the success of oculoplastic surgery. However, there exists significant controversy regarding the levator including the rules in ptosis surgery. The varied practice patterns and variable post-operative outcomes could only mean that there could be other contributing factors including biological variations as well as poor understanding of their intra-operative appearances. This video aims to explain these clinically relevant factors.

**Methods:** This video compiles some of the observable surgical anatomy of the LPS, its adjoining structures along with their intra-operative deviations.

**Results:** From fatty infiltration to double layered aponeurosis, racial differences, accessory levator bands and septal configurations, there is a lot to understand about the LPS.

**Conclusion:** Although anatomical variations are observable intra-operatively, there is equivocal thoughts on the ideal approach to surgeries involving the levator. A videographic demonstration of these variations could be the first step to better understanding of the same.

**V-046****Hell to heaven**

S Mandal<sup>1</sup>, A Maitra<sup>1</sup>, P Ray<sup>1</sup>, O Sarkar<sup>1</sup>, M Gayen<sup>1</sup>.

<sup>1</sup>*Ophthalmology , Regional Institute of ophthalmology Medical College Calcutta, kolkata, India*

**Objective:** 73 yrs old female complaints of big mass in the right eye since 1 yrs.It bleeds on touch and foul smelling discharge from the wound. It is painful and fungating mass . Due to poverty, this elderly patient was neglected severely leads to malignant tumors, infested maggot. At this moment patient fills alone ,old age , poverty , burden of the family ,etc moves towards death. Life is almost in hell. This patient ultimately came into tertiary hospital

**Methods:** Kind hearted doctors removed the maggots with the use of turbine oil or ether.As soon as it is given most of live maggots comes out of the wound.Simultaneously daily dressing with normal saline and Betadine 1%,make the wound maggot free . Broad spectrum systemic antibiotic given to make the the tumor mass non infected.

**Results:** Plan for removal of tumor with upper lid reconstruction by total tarsal plate replacement with autogenous auricular cartilage by means of modified cutler beard procedure. Here the created defect after tumor excision is 100%.As a rule it needs architectural support. We harvest auricular cartilage from the back of the ear pinna. Ultimately tumor was excised with lid reconstruction was done .Not only Save the patient's life we will give the social security .After two month 2<sup>nd</sup> stage cutler beard performed to open eyelids

**Conclusion:** This surgical procedure was functionally cosmetically accepted. Patient psychological status is highly improved .Due to maggot infestation she is thrown out of the family everybody expected her death. But this is challenge to us not only save the life from deadly sebaceous gland carcinoma, bring the patient in front of the society with her smiling face with acceptable cosmopsis .She enters from hell to heaven

V-047

### The Unrealistic Reality

P Mandal, D Maitra<sup>1</sup>, D Ray<sup>1</sup>, M Gayen.

<sup>1</sup>Ophthalmology, Regional Institute of ophthalmology Medical College Calcutta, Kolkata, India

**Objective:** One of the patient in the study presents as history and surgical procedures, follow up and surgical outcomes as video format To evaluate the cost, safety, surgical outcome, and efficacy of modified cutler beard eyelid reconstruction utilizing a silicone plate for tarsal plate replacement in the repair of 60-100% eyelid defects following excision of large malignant tumors.

**Methods:** Prospective, non-comparative, Interventional study of forty eyes over three years. Nineteen patients were female; twenty-one patients were male. In all the cases, a silicone plate, the synthetic, artificial tarsal plate was utilized for a total or subtotal replacement of the tarsal plate. The created defect was measured in mm (length and width) and later expressed in percentage. Pre and post-operative action of Levator palpebrae superioris (LPS) were measured. Pre and post-operative measurements of the margin of reflex distance (MRD1) were noted.

**Results:** Preoperative Levator palpebrae superioris (LPS) action was 1.23mm  $\pm$  1.35, while post-operative LPS actions were at the end of 1wk 11.8mm  $\pm$  0.88, 1 Month 12.23mm  $\pm$  0.77, 6 months 13.36mm SD  $\pm$  0.76, 18 months 13.53mm  $\pm$  0.73. Preoperative margin-to-reflex distance (MRD1) was -3.0mm  $\pm$  1.144 while post-operative MRD1 values were at the end of 1wk 2.18mm  $\pm$  0.27, 1 month 3.1mm  $\pm$  0.20, 6 months 4.0mm  $\pm$  0.32, 18 months 4.16mm  $\pm$  0.35, respectively. Created Defect after removal of the tumor was 87.87mm  $\pm$  11.10. The silicone plate used in this study was measured by 27.53mm  $\pm$  2.48. The follow-up period is eighteen months.

**Conclusion:** The synthetic silicone plate was successful as a tarsal plate replacement. A second surgical site for ear cartilage harvesting is avoided. Cadaver transfer of Achilles tendon carries the risk of transmission of communicable diseases, e.g. hepatitis B and HIV. Silicone is an inert, non-reacting, tissue tested material, thus eliminating the possibility of graft rejection. This material is readily available and cost-effective. The silicone plate should be considered as a material of choice in tarsal plate replacement in future generations.

V-048

**Black fungus : The annihilator of the Indian civilians**A Maitra<sup>1</sup>, S Mandal<sup>1</sup>, O Sarkar<sup>1</sup>.<sup>1</sup>Ophthalmology, Regional Institute of ophthalmology Medical College Calcutta, kolkata, India

**Objective:** Conventional orbital exenteration can be a life-preserving surgery in the management of rhino-orbital cerebral mucormycosis (ROCM); however, is associated with significant morbidity. We evaluated the clinical, functional, and aesthetic outcomes of a novel eye lash and lid-sparing orbital exenteration (LSOE) technique for management of ROCM.

**Methods:** We performed a retrospective, interventional case series of 17 ROCM cases limited to the orbital apex and floor over an 18-month period. We describe a novel LSOE technique and compare the surgical outcomes of FESS alone or combined with LSOE. In the LSOE technique we utilized upper and lower lid 4-0 silk traction sutures. A lateral canthal incision was made and the periosteum was dissected from the orbital rim circumferentially to permit removal of all orbital contents and debridement of the orbital walls and apex. Betadine and a bolster pack were applied and the lateral orbitotomy incision was closed in simple interrupted fashion. Post-operative lid position, levator function (LF), margin to reflex distance (MRD1), palpebral fissure height (PFH), psychosocial status, and disease recurrence were evaluated at 1-month and 6-month follow ups.

**Results:** Of 17 cases, 8 patients underwent FESS and 9 patients underwent FESS combined with LSOE. All cases demonstrated upper and lower eyelid inversion with reduced orbital volume on postoperative MRI at 6 months. LF, MRD1, and PFH ranges were 14-16 mm, 4-4.5 mm, and 9-11 mm, respectively, in cases treated with FESS alone. In patients treated with FESS combined with LSOE, the ranges LF, MRD1, and PFH were 0, 4, and 0 mm, respectively. One patient required a second debridement. At most recent follow up all patients were alive was no evidence of disease recurrence

**Conclusion:** We report 9 of 17 cases of patients with RCOM who underwent FESS with LSOE. FESS alone was found to be useful in mucormycosis limited to the nose and paranasal sinuses. In patients with infiltration of the posterior orbit, our LSOE technique demonstrated more favorable functional and aesthetic outcomes to conventional orbital exenteration and was not associated with disease recurrence in the 1-year follow up period. This technique may not only lessen the psychological trauma of conventional exenteration, but may also permit future socket reconstruction and prosthetic placement.



**V-051****Gore-tex a magic sheet for symblepharon prevention**

D Venugopal.

**Objective:** To present a case of severe grade symblepharon following grade 4 chemical injury, surgically treated with symblepharon lysis, Living related conjunctival allograft, Amniotic membrane graft and Gore-tex.

**Methods:** A 28 year old male presented with defective vision, redness and pain in the right eye one year back, following fall of alkali. On examination, his vision in the right eye (RE) was 6/36 and in the left eye (LE) 6/6. His right eye revealed grade 4 chemical injury with 360 degree limbal ischemia, total epithelial defect and stromal haze. The anterior segment was not visualised due to stromal haze. The color of the PH strip matched with value 8 (alkali). He underwent thorough saline wash with foreign body removal from the fornices and tenonplasty with amniotic membrane grafting in the operation theatre immediately. The postoperative period was uneventful; the patient was treated with topical 0.5% gatifloxacin and 0.1% dexamethasone combination eye drops for 10 days along with oral doxycycline 100mg two times a day, Tab Vitamin C 500 mg three times a day and topical lubricants and prophylactic antibiotics were prescribed. The patient was lost to follow-up due to COVID pandemic and reviewed with total symblepharon and obliteration of both upper and lower fornices. The vision was Hand movements in RE and 6/6 in LE. He was planned for symblepharon lysis, Living related conjunctival allograft, Amniotic membrane graft and Gore-tex.

**Results:** The recurrence of growth in these type cases would be severe due to two reasons, young patients and severe limbal stem cell deficiency; hence they would be associated with extreme fibroblastic response, wound contraction, and angiogenic sprouting. The addition of Gore-tex prevented the fibrosis between adjacent tissues in our case.

**Conclusion:** Gore-tex is an inert, biocompatible synthetic material left in place during the phase of inflammation, would effectively prevent recurrence of growth.

**V-052****Strabismus following scleral buckle surgery- Owners envy, Neighbors pride**D Joshi, L KS, R Krishnaprasad.

**Objective:** To describe different modalities of management in a patient with strabismus post scleral buckling for retinal detachment surgery.

**Methods:** This video highlights enhanced technique of strabismus management in three post scleral buckle patients who presented to a tertiary eye care center in South India. One patient was managed conservatively with prisms, other two required surgery. Strabismus surgery in such patients requires extensive dissection with use of antimetabolic agents owing to extreme adhesions. Hangback sutures and conjunctival recession were of additional benefit. Despite all these steps, persistent strabismus remained in one patient due to extreme ocular muscle injury. Buckle was retained in two patients and was removed in one patient. Outcomes were considered successful if there was  $\leq 10$  prism diopters (PD) residual horizontal and/or  $\leq 4$  PD residual vertical deviations. Statistical analyses were performed using Fisher's exact test, Mann-Whitney test, and nominal logistic regression.

**Results:** Success using our criteria of motor alignment was noted in 2 of three patients. No retinal redetachments occurred after scleral buckle removal.

**Conclusion:** Management of nonresolving strabismus post scleral buckling is challenge owing to varied underlying mechanisms. Treatment needs to be individualized and surgery needs to be modified by using special aforementioned techniques.

**V-053****Tale of three missing muscles- Straightening the eyes that went astray**D Joshi, L KS, K R.

**Objective:** Congenital absence or missing muscles due to various causes is a rare cause of strabismus. Through this video we want to highlight different modalities of management of three such cases of strabismus due to missing muscles.

**Methods:** Through this video we describe three cases of missing muscles and their management. First case had squint due to torn and absent inferior rectus muscle secondary to scleral buckle surgery. The case was managed by inferior oblique transposition. Second case had congenital aplasia of lateral rectus muscle associated with large angle esotropia. The case was diagnosed by imaging and was managed by transposition of superior and inferior rectus to presumed lateral rectus site. Third case was absent medial rectus muscle due to orbital trauma. The case was managed by medial rectus exploration, reattachment and periosteal fixation.

**Results:** All three cases showed satisfactory alignment with post operative deviation less than ten prism diopters. No anterior segment ischemia or post operative pattern deviation was noted.

**Conclusion:** Cases of missing muscles do not mean missing hopes. Specialised strabismus surgery involving periosteal fixation and transposition procedures help us to manage satisfactory postoperative outcome. The MRI allowed effective surgical planning to correct the deviation.

**V-054****Don't (let the same dog) bite (you) twice: One surgery does it all**

S Kaur, J *SUKHIJA*<sup>1</sup>, K *Choudhary*<sup>1</sup>.

<sup>1</sup>*PGIMER, CHANDIGARH, India*

**Objective:** The purpose of this video is to demonstrate how a single strabismus surgery could correct a large hypertropia in a young adult, after the inferior rectus was injured in a dog bite.

**Methods:** A thirty-year male presented with diplopia persisting for one year after a dog bite on the inferior lid of his left eye. His visual acuity was 20/20 OU with normal anterior and posterior segment examination. He had a retraction of the left lid with left hypertropia measuring 30 PD in primary gaze and increasing to 42 PD in laevo-depression. He complained of intorsion which was measured to be 15 degree subjectively.

**Results:** Forced duction of the left superior rectus was free at the time of surgery. Inferior rectus of the left eye was explored and was found to be lost in the orbit. A modification of inferior Nishida procedure was performed. Post operatively the patient was relieved of the diplopia and torsion.

**Conclusion:** Meticulous planning and knowledge of relevant anatomy helped in the successful management of the complex strabismus in one sitting.

**V-055****Pediatric Ectopia Lentis: Tailored approach**

J Sukhija, S Kaur, K Choudhary, A Markaan.

**Objective:** To discuss the surgical management of Ectopia Lentis based on the etiology

**Methods:** Three children diagnosed with Simple ectopia lentis, Marfans syndrome and Ectopia lentis et pupillae were operated with different techniques which was decided based on the aetiology of subluxation. The first case where the subluxation was less than 9 clock hours was managed with Cionni capsular tension ring with IOL placement in the bag. The child with Marfans Syndrome underwent lensectomy with posterior iris claw lens and the third patients underwent lensectomy with scleral fixated IOL using the Yamane technique.

**Results:** Visual acuity improved in all three children. The intraocular lens was stable and centred in all three cases.

**Conclusion:** Pediatric ectopia lentis has a varied etiology and each case should be managed after deciphering the cause because of iris abnormalities and scleral thinning in such progressive disorders which could help in deciding the surgical technique to be planned.

**V-056****Magical Pill!**

J Sukhija, S Kaur, K Choudhary.

**Objective:** To demonstrate the efficacy of ICAM (intracameral anaesthetic mydriatic) solution for pupillary dilatation in children undergoing cataract surgery

**Methods:** Children undergoing cataract surgery were dilated using commercially available combination of phenylephrine 0.31%, tropicamide 0.02% and lidocaine 1% (Phenocaine plus, Entod Gujarat, India). The aetiology of cataract included congenital, uveitis with synechiae and subluxated lenses (syndromic). None of the patients received any preoperative dilating drops. Intracameral injection of this solution was given through a paracentesis and the effect on dilatation was assessed by the size maintained till the end of surgery.

**Results:** A minimum of 6 mm dilatation was achieved in most. The stability of dilatation was maintained till the end of surgery. There were no systemic side effects as these children were monitored under general anaesthesia. None of the patients required any additional supplementation

**Conclusion:** Intracameral combination of mydriatic anaesthetic is a viable option in dilating the pupil in paediatric cataract surgery. It provides targeted delivery with miniscule dose and avoids the ill effects of drops.

V-057

**Optic Transplant**

F González del Valle<sup>1</sup>, M Domínguez Fernández<sup>1</sup>, S López-Romero Moraleda<sup>1</sup>, Á Barrajon Rodríguez<sup>1</sup>, C González Polo<sup>1</sup>, E Asensio del Pozo<sup>1</sup>, A Abbas Khoja<sup>1</sup>, J Valdés González<sup>1</sup>, L García-Filoso Moraleda<sup>1</sup>, J Rivera Salazar<sup>1</sup>.

<sup>1</sup>Ophthalmology, La Mancha-Centro Hospital, Alcázar de San Juan, Spain

**Objective:** To describe a new surgical technique to treat a refractive error and an intraocular lens (IOL) opacification in only one surgery.

**Methods:** A 63 year-old female was operated for cataract and hyperopia 2 decades ago using a piggy-back technique, resulting in a postoperative refractive error. Two years ago she was diagnosed with secondary posterior capsular opacification and she received multiple sessions of Nd:YAG laser, damaging the optics of the two IOLs. The surgery consisted in the explantation of the optics of all of the three pieces IOLs, leaving their respective haptics in-the-bag, the implantation of a new intraocular multifocal optics without haptics and the coupling of the in-the-bag haptics in the new multifocal optics.

**Results:** After surgery a complete stabilization and centering of the multifocal optics was achieved, resolving the previous refractive error.

**Conclusion:** Refractive error and secondary opacification of the IOL are a frequent cause of the removal of them. However, in specific cases, it is possible to exchange only the optic of the IOL, maintaining the original haptics in-the-bag. This surgical maneuver allows us to get the correct positioning of the in-the-bag IOL, even in posterior capsulotomy cases.

V-058

**Man Over Machine**A Ghosh, S Chandrashekharan<sup>1</sup>.<sup>1</sup>*Cataract and IOL services, Aravind Eye Hospital , Tirunelveli, India*

**Objective:** Due to an ever increasing demand of the patients for a 6/6 distance unaided vision, Femto-second Laser Assisted Cataract (FLACS) with TORIC Intraocular lens (IOL) implantation has become very popular in the current times. It requires compliant patient; competent surgeon and efficient machine for successful surgery. A compromise on any of the above factors leads to sub-optimal visual results. This video demonstrates anterior lens capsular star formation simultaneously with the nucleotomy due to a fault in the Femto docking machine, and how it was skilfully managed by the surgeon with TORIC IOL implantation in the capsular bag.

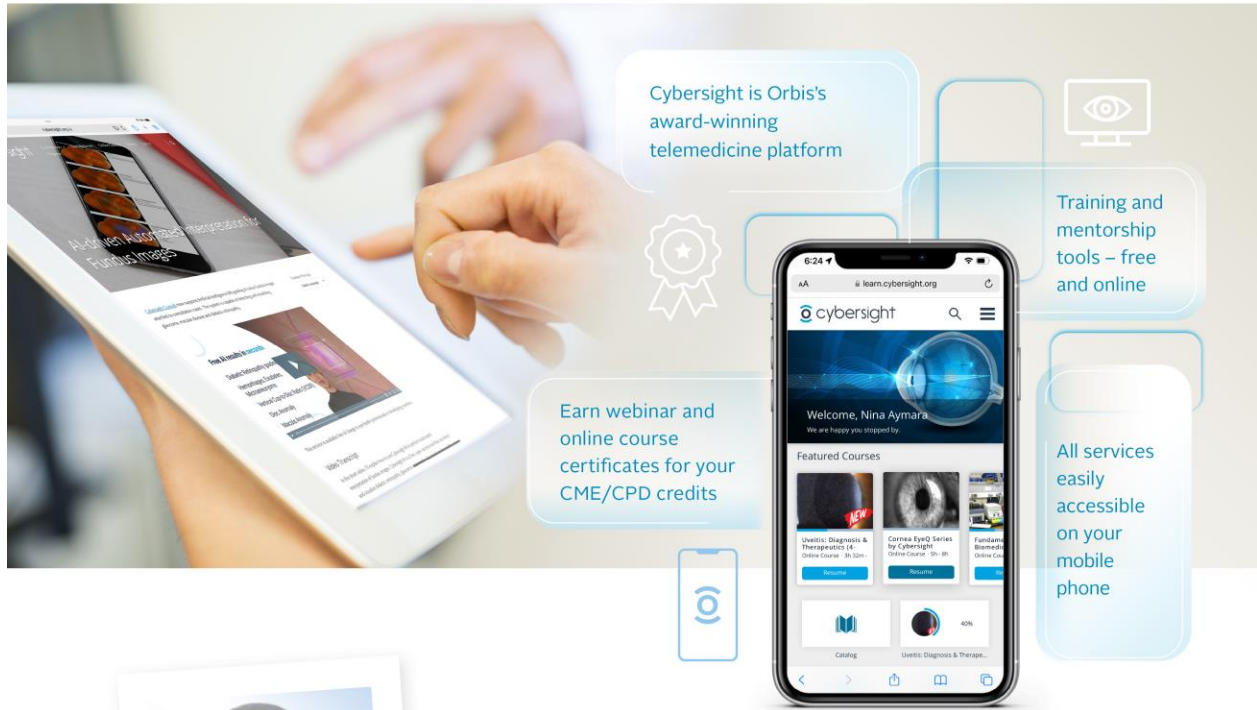
**Methods:** The surgeon uses 26 Gauge cystitome for checking the extent of radial extensions and initiating the capsulorhexis . The points at which it is felt that the capsulorhexis is tending to radialize via the capsular extensions ,it is brought back with the help of Capsulorhexis/Utrata forceps .Once the Intact Circular Capsulorhexis is achieved ,the rest of the steps of of Femtosecond LaserAssisted cataract surgery become very easy .The Nucleus is emulsified like in routine cataract cases .An intact Capsulorhexis ensures that the TORIC intraocular lens can be placed in the capsular bag .

**Results:** A Round ,circular intact capsulorhexis is achieved despite Anterior capsular star formation. This enables safe phacoemulsification of the nucleus within the capsular bag .It is possible to implant a TORIC intraocular lens in the bag with a 360 degree overlap of the Intraocular lens with the Anterior capsular Rim which is very important in case of refractive surgery with premium lenses.

**Conclusion:** Despite having Predictable and Reliable results with Femtosecond Laser Assisted Cataract surgery , Sometimes , it is good not to depend totally on the machines , as the possibility of faulty technical errors can never be negated .

Thus despite recent advancements in cataract surgery, it is sometimes the MAN who wins over the MACHINES.





Cybersight is Orbis's award-winning telemedicine platform

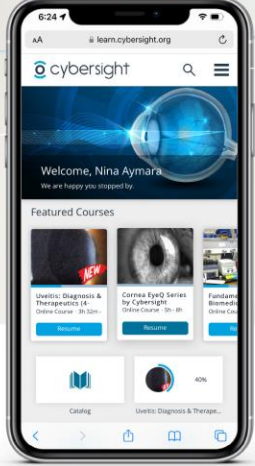

Training and mentorship tools – free and online



Earn webinar and online course certificates for your CME/CPD credits

All services easily accessible on your mobile phone



**“Cybersight had an incredibly positive impact for me ... experientially, knowledge and confidence-wise.”**

DR DOAA KOTOB is an ophthalmologist in Egypt. She sees approximately 5000 patients per year.

**LIVE, INTERACTIVE WEBINARS** and surgical demonstrations, discussing comprehensive ophthalmology topics with expert Q&A.

**ON-DEMAND ADVICE** and mentorship from international ophthalmology experts on complex patient cases.

**MULTI-MEDIA ONLINE COURSES** in ophthalmology and related fields, optimised for mobile devices.

**LIVING LIBRARY** of ophthalmic resources, including lectures, 3D surgical videos, quizzes and textbooks, accessible in multiple languages.

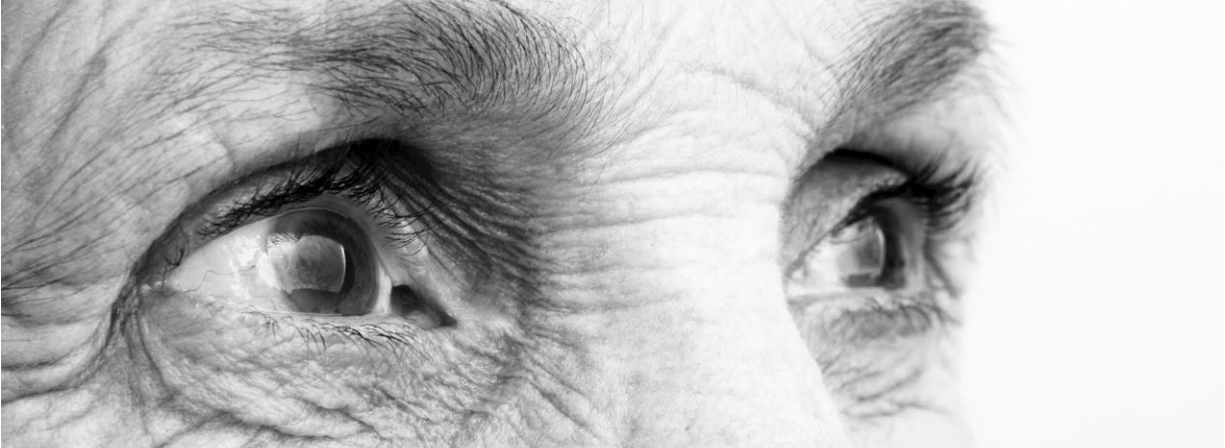**CYBERSIGHT ARTIFICIAL INTELLIGENCE** for quick and accurate clinical decision support.



**OVER 60,000** eye professionals are benefiting from Cybersight across the world. Use this QR code to register.



[cybersight.org](http://cybersight.org)  
CHANGING THE WAY THE WORLD SEES.



**Apellis is committed to leading** the development of therapies that target the **complement system** with the goal of **slowing GA progression**.

Overactivation of the complement system is associated with the development of lesions in geographic atrophy (GA).<sup>1</sup>

Due to continuous and irreversible vision loss, there is a high unmet need to slow GA lesion progression.<sup>2</sup>

1. Katschke KJ et al. Classical and alternative complement activation on photoreceptor outer segments drives monocyte-dependent retinal atrophy. *Sci Rep* 2018;8:13055.

2. Fleckenstein M et al. The Progression of Geographic Atrophy Secondary to Age-Related Macular Degeneration. *Ophthalmology* 2018;125:369-390.





IVERIC  
BIO

TRANSFORMATIVE  
THERAPIES  
FOR RETINAL DISEASES

---

We are focused on developing treatments for patients suffering from retinal diseases with significant unmet medical needs.

Geographic Atrophy

Stargardt Disease

Inherited Retinal Diseases

Learn more at [IvericBio.com](https://IvericBio.com)