



Diagnosis and classification of optic neuritis

Axel Petzold, Clare L Fraser, Mathias Abegg, Raed Alroughani, Daniah Alshowaeir, Regina Alvarenga, Cécile Andris, Nasrin Asgari, Yael Barnett, Roberto Battistella, Raed Behbehani, Thomas Berger, Mukharram M Bikbov, Damien Biotti, Valerie Biousse, Antonella Boschi, Milan Brazdil, Andrei Brezhnev, Peter A Calabresi, Monique Cordonnier, Fiona Costello, Franz M Cruz, Leonardo Provetti Cunha, Smail Daoudi, Romain Deschamps, Jerome de Seze, Ricarda Diem, Masoud Etemadifar, Jose Flores-Rivera, Pedro Fonseca, Jette Frederiksen, Elliot Frohman, Teresa Frohman, Caroline Froment Tilikete, Kazuo Fujihara, Alberto Gálvez, Riadh Gouider, Fernando Gracia, Nikolaos Grigoriadis, José M Guajardo, Mario Habek, Marko Hawlina, Elena H Martínez-Lapiscina, Juzar Hooker, Jyh Yung Hor, William Howlett, Yumin Huang-Link, Zhannat Idrissova, Zsolt Illes, Jasna Jancic, Panitha Jindahra, Dimitrios Karussis, Emilia Kerty, Ho Jin Kim, Wolf Lagrèze, Letizia Leocani, Netta Levin, Petra Liskova, Yaou Liu, Youssoufa Maiga, Romain Marignier, Chris McGuigan, Dália Meira, Harold Merle, Mário L R Monteiro, Anand Moodley, Frederico Moura, Silvia Muñoz, Sharik Mustafa, Ichiro Nakashima, Susana Noval, Carlos Oehninger, Olufunmilola Ogun, Afekhide Omoti, Lekha Pandit, Friedemann Paul, Gema Rebolleda, Stephen Reddel, Konrad Rejdak, Robert Rejdak, Alfonso J Rodriguez-Morales, Marie-Bénédicte Rougier, Maria Jose Sa, Bernardo Sanchez-Dalmau, Deanna Saylor, Ismail Shatriah, Aksel Siva, Hadas Stiebel-Kalish, Gabriella Szatmary, Linh Ta, Silvia Tenembaum, Huy Tran, Yevgen Trufanov, Vincent van Pesch, An-Guor Wang, Mike P Wattjes, Ernest Willoughby, Magd Zakaria, Jasmin Zvornicanin, Laura Balcer, Gordon T Plant

There is no consensus regarding the classification of optic neuritis, and precise diagnostic criteria are not available. This reality means that the diagnosis of disorders that have optic neuritis as the first manifestation can be challenging. Accurate diagnosis of optic neuritis at presentation can facilitate the timely treatment of individuals with multiple sclerosis, neuromyelitis optica spectrum disorder, or myelin oligodendrocyte glycoprotein antibody-associated disease. Epidemiological data show that, cumulatively, optic neuritis is most frequently caused by many conditions other than multiple sclerosis. Worldwide, the cause and management of optic neuritis varies with geographical location, treatment availability, and ethnic background. We have developed diagnostic criteria for optic neuritis and a classification of optic neuritis subgroups. Our diagnostic criteria are based on clinical features that permit a diagnosis of possible optic neuritis; further paraclinical tests, utilising brain, orbital, and retinal imaging, together with antibody and other protein biomarker data, can lead to a diagnosis of definite optic neuritis. Paraclinical tests can also be applied retrospectively on stored samples and historical brain or retinal scans, which will be useful for future validation studies. Our criteria have the potential to reduce the risk of misdiagnosis, provide information on optic neuritis disease course that can guide future treatment trial design, and enable physicians to judge the likelihood of a need for long-term pharmacological management, which might differ according to optic neuritis subgroups.

Introduction

New diagnostic criteria and a new classification of optic neuritis are required. The need has arisen as a result of several advances: (1) the precision of autoantibody-related diagnosis has increased;^{1–3} (2) epidemiological data have confirmed that optic neuritis is associated with more disorders and that the prevalence of optic neuritis subgroups is geographically more heterogeneous than was previously thought;^{4,5} (3) the accuracy of neuroimaging to identify optic neuritis subgroups has improved;^{6,7} (4) the value of retinal optical coherence tomography (OCT) for diagnosis and monitoring has become apparent;^{8,9} and (5) more treatment options have become available for patients with optic neuritis.^{10–15}

Despite the improved diagnostic potential, 35 of 38 studies of OCT in patients with optic neuritis included in a 2017 meta-analysis did not use peer-reviewed diagnostic criteria for optic neuritis.⁸ Furthermore, in a clinic-based study, 73 of 122 (60%) individuals thought to have optic neuritis did not have optic neuritis,¹⁶ a result flagged as alarming.¹⁷ Many other causes of monocular visual loss can mimic optic neuritis,^{16,18,19} and the consequences of wrong or delayed treatment can be catastrophic for visual outcome.²⁰ So-called red flags identifying individuals at risk for

relapsing or progressive visual loss have been described, but not yet included in a systematic classification.^{18,19}

On a clinical level, there are many reasons why a diagnosis should be made as early as possible.^{21,22} The greatest challenge is to promptly identify optic neuritis subtypes that are due to seropositive autoimmune disease or that are likely to show corticosteroid dependence.^{23,24}

To address the need for new diagnostic criteria, a panel of 101 international experts consisting of neurologists, ophthalmologists, neuro-ophthalmologists, and neuroradiologists convened electronically between April 20, 2018, and March 31, 2021 (appendix p 9). We used a validated Delphi process-based approach (appendix pp 8, 32–33) to develop criteria for diagnosis (panel 1) and classification of optic neuritis (figure). Our classification scheme has three levels. Level 1 comprises whether the diagnosis is likely to be relapsing or monophasic. Level 2 comprises classification of autoimmune optic neuritis subtypes that are likely to be relapsing and a list of conditions associated with a likely monophasic disease course. Level 3 comprises rarer subtypes of optic neuritis recognised by individual experts, but for which consensus was not reached. Our diagnostic criteria and classification will be subject to regular review, which will take into account the different

Lancet Neurol 2022

Published Online
September 27, 2022
[https://doi.org/10.1016/S1474-4422\(22\)00200-9](https://doi.org/10.1016/S1474-4422(22)00200-9)

See Online/Comment
[https://doi.org/10.1016/S1474-4422\(22\)00334-9](https://doi.org/10.1016/S1474-4422(22)00334-9)

The National Hospital for Neurology and Neurosurgery, University College London, London, UK (A Petzold MD PhD); Moorfields Eye Hospital, London, UK (A Petzold); Neuro-ophthalmology Expert Centre, Amsterdam University Medical Center, Amsterdam, Netherlands (A Petzold); Department of Ophthalmology, University of Sydney, Sydney, NSW, Australia (Prof C L Fraser MMed FRANZCO); Department of Ophthalmology, University of Bern, Bern, Switzerland (Prof M Abegg PhD); Division of Neurology, Department of Medicine, Al-Amiri Hospital, Kuwait City, Kuwait (R Alroughani MD FRCP); Department of Ophthalmology, King Saud University, Riyadh, Saudi Arabia (Prof D Alshowaeir PhD); Department of Neurology, Universidade Federal do Estado do Rio de Janeiro (UNIRIO), Rio de Janeiro, Brazil (Prof R Alvarenga PhD); Department of Ophthalmology, University Hospital Liege, University of Liège, Liège, Belgium (C Andris MD); Department of Neurology, Slagelse and Institute of Regional Health Research, and Institute of Molecular Medicine, University of Southern Denmark,

Panel 1: Diagnostic criteria for optic neuritis**Clinical criteria**

- A: Monocular, subacute loss of vision associated with orbital pain worsening on eye movements, reduced contrast and colour vision, and relative afferent pupillary deficit
- B: Painless with all other features of (A).
- C: Binocular loss of vision with all features of (A) or (B).

Paraclinical criteria

- OCT: Corresponding optic disc swelling acutely or an inter-eye difference in the mGCIPL of >4% or >4 µm or in the pRNFL of >5% or >5 µm within 3 months after onset.
- MRI: Contrast enhancement of the symptomatic optic nerve and sheaths acutely or an intrinsic signal (looking brighter) increase within 3 months.
- Biomarker: AQP4, MOG, or CRMP5 antibody seropositive, or intrathecal CSF IgG (oligoclonal bands).

Application of the clinical and paraclinical criteria*Definite optic neuritis*

- (A) and one paraclinical test
- (B) and two paraclinical tests of different modality
- (C) and two different paraclinical tests of which one is MRI

Possible optic neuritis

- (A), (B), or (C) if seen acutely but in absence of paraclinical tests, with fundus examination typical for optic neuritis and consistent with the natural history during follow-up
- Positive paraclinical test or tests, with a medical history suggestive of optic neuritis

Clinical and paraclinical information is combined to reach a diagnosis of either definite or possible optic neuritis. In the absence of paraclinical tests, a diagnosis of possible optic neuritis can be made on clear clinical grounds (A) alone. To make a diagnosis of definite optic neuritis, supporting evidence from at least one paraclinical test is required. For clinically more ambiguous presentations (B and C) more evidence is required from paraclinical tests of complementary modality. The interpretation of OCT and MRI findings is different in the acute compared with the chronic (≥3 months) phase of optic neuritis. AQP4=aquaporin 4. CRMP5=collapsin response mediator protein 5. mGCIPL=macular ganglion cell inner plexiform layer. MOG=myelin oligodendrocyte glycoprotein. OCT=optical coherence tomography. pRNFL=peripapillary retinal nerve fibre layer. RAPD=relative afferent pupillary deficit.

Odense, Denmark
(Prof N Asgari PhD DMSc);
Department of
Neuroradiology, St Vincent's
Hospital, Sydney, NSW,
Australia
(Prof Y Barnett FRANZCR);
Department of
Neuro-Ophthalmology,
University of São Paulo,
São Paulo, Brazil
(Prof R Battistella MD);
Neuro-Ophthalmology Unit,
Ibn Sina Hospital, Kuwait City,
Kuwait (R Behbehani FRCS);
Department of Neurology,
Medical University of Vienna,
Vienna, Austria
(Prof T Berger MD); Ufa Eye
Research Institute, Ufa, Russia
(Prof M M Bikbov PhD); Unité de
Neurologie Inflammatoire B4,
CHU Pierre-Paul Riquet/
Purpan, Toulouse, France
(D Biotti, MD); Neuro-
Ophthalmology Unit, Emory
Eye Center, Emory University,

disorders associated with optic neuritis across medical specialties⁵ and in multiethnic populations worldwide.

Here, we first define the terminology we have used (panel 2). Next, we summarise the pertinent clinical findings for making a diagnosis of optic neuritis and classification as either relapsing or monophasic (level 1). Making the diagnosis is followed by the further subclassification of optic neuritis, for which we present an in-depth description of the subgroup consensus classification (level 2). We summarise evidence used to distinguish between the level 2 classifications of optic neuritis structured by anatomy, biomarkers, disease course, and imaging. We will critically appraise the role of additional paraclinical tests. For a future revision of the classification, a complete list of optic neuritis subgroups only reaching level 3 will be given in the appendix. Finally, we present treatment options and provide advice on the design of future treatment trials.

Diagnosis

Symptoms and signs of optic neuritis can either be present or no longer present, depending on how long

after symptom onset a patient is seen in the clinic. Clinical presentation can differ if patients are seen in the acute phase (<7 days from symptom onset), subacute phase (1 week to 3 months), or chronic phase (>3 months), or with a first attack or recurrent attack (panel 3).^{19,23,24} Spontaneous, recurrent attacks need to be distinguished from attacks occurring on withdrawal of immunosuppression.²⁰ The clinical features of optic neuritis can be further affected by the patient's individual characteristics,⁴ including ethnic background, geographical location, age, and sex.^{1,4,20}

Clinicians should ask for other information from the patient's medical or family history regarding, for example, cancer, autoimmune disease, infection, vascular disease, and inherited conditions (panel 3).^{18,20} These details are relevant to make treatment decisions and provide prognostic information to the patient. Against this background, symptoms and signs observed need to be matched with the natural history of optic neuritis.²⁴ Any mismatch of what is expected from the natural disease course needs to be explained or will require additional investigations to allow clinicians to detect features that have been described as red flags for an alternative diagnosis or for urgent treatment.^{18,19} The timely recognition of features suggestive of red flags can also help to distinguish subgroups of optic neuritis, have been updated from previous reviews on optic neuritis (panel 3).^{1,18,19,28}

The extent and pattern of acquired dyschromatopsia helps to separate optic neuritis (which is characterised by acquired impairment of colour vision) from typical retinal pathology (generally associated with preserved colour vision or a hereditary deficit).^{18,19,24} For the same reason, loss of low-contrast visual acuity is more severe in optic neuritis than is loss of high contrast visual acuity, explaining why there is so frequently a central scotoma in optic neuritis. Depending on the site of inflammation, however, any type of visual field defect can be observed in acute optic neuritis.^{24,29} Presumably due to vulnerability of the intrinsically photosensitive retinal ganglion cell pathway, the pupil light reflex is frequently affected (relative afferent pupillary deficit). However, in the clinic this deficit of the pupil light reflex is easily demonstrable only if unilateral or very asymmetric between the two eyes.²⁴ A small proportion of patients also report positive symptoms (photopsia) such as flashes of lights, geometric patterns, or shimmering edges or borders around such patterns or scotomas. The presence of positive symptoms is more common in retinal dysfunction than in optic nerve dysfunction, but can result from ephaptic transmission between optic nerve axons.^{18,19,23,24}

Taken together, these clinical points are required to make a diagnosis of possible optic neuritis, prepare the ground for a diagnosis of definite optic neuritis, or identify patients who do not have optic neuritis (figure A; panel 1).

Classification level 1

More than 60 disorders can be the subsequent diagnosis after an initial episode of optic neuritis or can cause optic neuritis at any time during the disorder.²⁸ Infections can involve the optic nerve directly, and infections or vaccinations can also trigger post-infectious or post-vaccination optic neuritis.^{16,18,19} Typically, the disease course is monophasic in all optic neuritis that is not autoimmune in origin. The clinical decision for long-term pharmacological management depends on the likely disease course.^{10,13–15}

Relapsing optic neuritis that is of autoimmune cause will require long-term immunomodulation or suppression. By contrast, post-infectious or post-vaccination optic neuritis, or optic neuritis caused by other systemic diseases, is monophasic and does not require long-term immunosuppression. Therefore, the top-level classification of optic neuritis dichotomises to these two categories (relapsing and monophasic), with 95% (93 of 98 experts) consensus (figure B), although we acknowledge that there might be a small degree of overlap between a monophasic and relapsing disease course. For example, the forme fruste of optic neuritis associated with multiple sclerosis, myelin oligodendrocyte glycoprotein, and neuromyelitis optica remains monophasic. Likewise, there are individuals with optic neuritis associated with acute demyelinating encephalomyelitis (ADEM) who experience future relapses

Classification level 2

The level 2 classification (figure B) concerns optic neuritis subtypes for which evidence on the clinical features or paraclinical test results was sufficient for the panel to consider them distinct. We accept that there might be other optic neuritis subtypes, reviewed elsewhere, which are currently regarded as level 3 but that might reach level 2 in a future revision of our classification.²¹

The level 2 classification had to combine the following considerations: the possibility of an optic neuritis event occurring in the context of almost any infection or vaccination or a large range of systemic diseases (panel 4); the high likelihood of optic neuritis occurring in the context of multiple sclerosis,³⁰ neuromyelitis optica spectrum disorder (NMOSD),^{31,32} or myelin oligodendrocyte glycoprotein (MOG) antibody-associated disease (MOGAD);³³ and whether there is isolated pathology to the optic nerve at the time of presentation.²⁸ We have taken all these considerations into account by combining an anatomical compartment model and immunological biomarkers with chronological clinical features, OCT findings, and MRI findings (panel 5).

Anatomical classification

One novel aspect of our classification is based on the anatomy of the optic nerve. The entire pathway of the

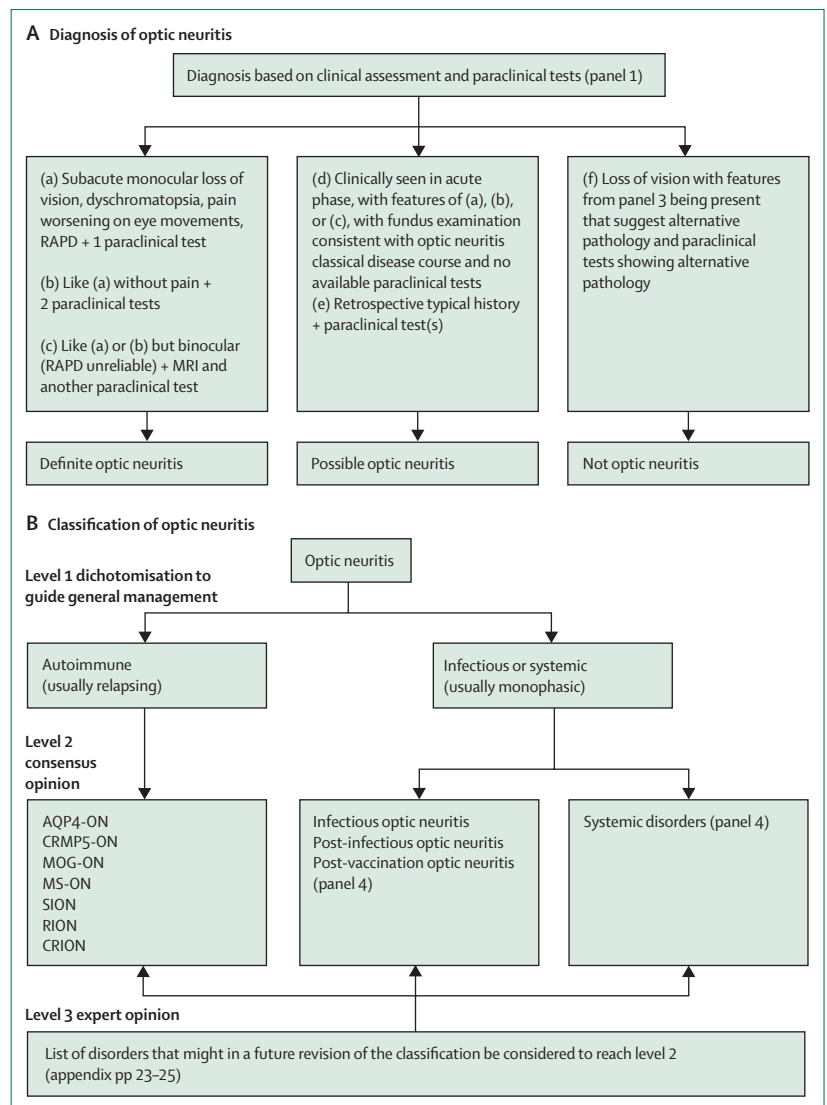


Figure: Diagnosis and classification of optic neuritis

(A) Diagnostic criteria for optic neuritis depend on clinical assessment and are supported by paraclinical tests. (B) Classification of optic neuritis. The level 1 classification of optic neuritis is intended to inform the general management with regards to whether to immunosuppress based on the likelihood of a future relapse. The level 2 classification is aimed at readers with subspecialty interest and advises on more specific treatment options that might only be available in specialist centres. Finally, a large list of individual and anecdotal descriptions of optic neuritis is documented (level 3; appendix pp 23–25), which might have sufficient evidence and consensus to move to the level 2 classification in future revisions of the classification. AQP4=aquaporin 4. CRION=chronic RION. CRMP5=collapsin response mediator protein 5. MOG=myelin oligodendrocyte glycoprotein. MS=multiple sclerosis. ON=optic neuritis. RAPD=relative afferent pupillary deficit. RION=relapsing isolated optic neuritis. SION=single isolated optic neuritis.

relevant axons had to be considered.²⁸ Agreement in favour of this compartmentalised model (appendix p 27) in the Delphi process was 93% (87 of 94 experts), but we acknowledge that the proposed compartment model will need to be developed further to better understand compartmentalised autoimmunity.

The anatomical pathway includes the non-myelinated, prelaminar retinal ganglion cell axons in the retina and optic disc, and, beyond the lamina cribosa (the barrier

Atlanta, GA, USA
Prof V Biousse PhD);
Department of Head and Neck,
Université Catholique de
Louvain, Brussels, Belgium
(A Boschi MD); Department of
Ophthalmology, Cliniques
Universitaires Saint Luc,
Brussels, Belgium (A Boschi);
Department of Neurology,
Masaryk University, Brno,

Panel 2: Terminology

Disease course of optic neuritis

Defined clinically as monophasic, spontaneous relapsing, immune-suppression-dependent relapsing, or progressive.

Isolated optic neuritis

Evidence for optic neuritis with neither pathologically related lesions elsewhere in the brain or spinal cord, nor finding of a potentially pathogenic antibody.

Forme fruste of optic neuritis

Antibody seropositive or intrathecal IgG (CSF oligoclonal bands) in isolated monophasic optic neuritis.

Compartment

An anatomically and immunologically defined space as relevant to pathogenesis of optic neuritis:

- dural, intradural, and extradural (whole body)
- intradural (including CSF compartment)
- extradural and dural (includes optic nerve sheath and surrounding tissue)
- choroidal (includes retina and uveal tract)

Antibody production can be intradural, extradural, or choroidal, and the target antigen can be limited to one or more compartments.

Retinal ganglion cell

The cell body of the neurons with axons that project from the retina to the brain.

Retinal nerve fibre layer

The non-myelinated axons within the retina up to the lamina cribrosa.

Lamina cribrosa

The barrier between the choroidal and intradural optic nerve compartments.

Optic nerve

The myelinated section between the lamina cribrosa and the optic chiasm (divided into intraorbital and intracranial regions).

Optic tract

The myelinated section between the optic chiasm and the dorsal lateral geniculate nucleus.

Czech Republic
 Prof M Brazdil PhD; St Anne's
 University Hospital, Brno,
 Czech Republic (M Brazdil);
 Department of
 Ophthalmology, Kursk State
 Medical University, Kursk,
 Russia (Prof A Brezhnev PhD);
 The Solomon H Snyder
 Department of Neuroscience,
 Johns Hopkins University
 School of Medicine, Baltimore,
 MD, USA (Prof P Calabresi PhD);
 Department of
 Ophthalmology, Université
 Libre de Bruxelles, Bruxelles,
 Belgium
 (Prof M Cordonnier PhD);
 Department of Clinical
 Neurosciences, University of
 Calgary, Calgary, AB, Canada
 (Prof F Costello PhD); College of
 Medicine, University of the

between the choroidal and intradural optic nerve compartment), the myelinated retinal ganglion cell axons within the retrolaminar optic nerve.^{8,28} Along their path, axons pass through immunologically adjacent compartments.^{34–36} The proposed compartment model accommodates the wide clinical range from asymptomatic optic neuritis, through optic neuritis without disc oedema, to optic neuritis with severe disc oedema, and finally to the presence of retinal changes other than inner retinal layer atrophy.^{24,37} The model also permits for a rare presentation of autoimmune optic neuritis that remains monophasic, the forme fruste of optic neuritis (panel 2). Anteriorly, this model might in the future be refined to include subgroups of optic neuritis associated with vitritis, neuroretinitis, retinitis, or choroiditis.^{34,38} Posteriorly, the model can be developed to explain the differing susceptibility to disease from the retro-laminar intra-orbital nerve to the optic chiasm and optic tract:^{21,28} hence the different patterns of lesion location on MRI between

Panel 3: Signs and symptoms aiding the clinical classification of optic neuritis and exclusion of alternative pathologies

Clinical presentation*:

- Sequence of symptoms over time
- Preceding infection or vaccination
- Ethnic background or location
- Progression of pain or visual loss (>2 weeks)
- Absence of pain
- Associated epilepsy†
- Simultaneous bilateral ON
- Evidence of retinitis or retinal dysfunction from OCT or electrophysiology
- Presence of severe optic disc oedema
- Absence of optic disc oedema
- Unexplained optic atrophy in either eye at onset
- Fever or other systemic symptoms and signs‡
- Other focal neurological signs

Disease course§:

- Progressive loss of vision
- Progressive retinal layer atrophy for more than 12 months
- Sequential bilateral optic neuritis
- Absence of spontaneous recovery (>3 months)
- Corticosteroid dependence

Medical history:

- Medical history of cancer or diseases listed in panel 4
- Family history of a suspected hereditary optic neuropathy
- Family history of other mitochondrial cytopathy

MOGAD=myelin oligodendrocyte glycoprotein antibody disease. NMDA=N-methyl-D-aspartate. OCT=optical coherence tomography. ON=optic neuritis. *Clinical features refers to the first time that the patient is seen in the clinic. †Seizures with optic neuritis are reported in MOGAD^{35,36} or NMDA encephalitis.²⁷ ‡Enlarged or painful lymph nodes, weight loss, rash, arthritis, cough, night sweats, anorexia, depression, and polymyalgia. §Disease course refers to what you observe at follow-up in your clinic.

optic neuritis associated with multiple sclerosis, optic neuritis associated with anti-MOG antibodies, and optic neuritis associated with aquaporin 4 antibodies.^{7,39,40} The optic nerve has a dural sheath only intra-orbitally; intracranially, the optic nerve is cisternal with a covering of pia only. The location of optic nerve inflammation in relation to the dura mater defines, anatomically, the compartments relevant for level 2 classification.

Whole-body compartment

The whole body is included when considering the dural, intradural, and extradural compartments. This choice was made because all these compartments can be affected by the list of infections and systemic diseases that can cause optic neuritis (panel 4).

Optic neuritis can occur at any time in the course of various systemic diseases (panel 4).^{17,28,37} Ethnic background is relevant because of the differences in incidence of systemic diseases, with sarcoidosis being

Panel 4: Infections and systemic disorders associated with optic neuritis

Causes of infectious and post-infectious optic neuritis

Bartonella, brucella, Chikungunya fever, cytomegalovirus, coronavirus, *Coxiella burnetii*, dengue, Epstein–Barr virus, echovirus, ehrlichiosis, Henoch–Schönlein purpura, hepatitis B and C, herpes simplex, histoplasma, HIV, human herpesvirus 6, hypertrophic pachymeningitis, IgG subclass deficiency, Inoue–Melnick virus, leprosy, Lyme disease, measles, mumps, *Mycoplasma pneumoniae*, neurotoxocarosis, ocular cat-scratch disease, post-vaccination optic neuritis, rubella, streptococcus, syphilis, tick-borne encephalitis, toxoplasmosis, tuberculosis, typhus, varicella zoster virus, West Nile virus, Whipple disease, and Zika virus.

Systemic disorders causing optic neuritis

Allergic granulomatous angiitis, ANCA associated vasculitis, ankylosing spondylitis, Behçet's disease, Churg–Strauss disease, Cogan syndrome, giant cell arteritis, granulomatosis with polyangiitis, IgG 4 disease, Kawasaki disease, microscopic polyangiitis, polyarteritis nodosa, primary antiphospholipid syndrome, rheumatic disease, sarcoidosis, Sjögren syndrome, systemic lupus erythematosus, Susac syndrome, systemic sclerosis, Takayasu arteritis, treatment side-effect,* ulcerative colitis, and Wegener granulomatosis.

The differential diagnosis²⁹ of infectious, post-infectious optic neuritis, and optic neuritis in systemic diseases, which includes primary, secondary, and reactive vasculitis. Bilateral, simultaneous post-infectious or post-vaccination optic neuritis, particularly in children, is frequently associated with acute demyelinating encephalomyelitis.² ANCA=anti-neutrophil cytoplasmic autoantibody. *Optic neuritis is a recognised treatment side-effect of TNF- α and immune checkpoint inhibitors.

particularly common in individuals of African Caribbean origin and optic neuritis associated with aquaporin 4 antibodies being more frequent in individuals of Asian origin.⁴ The relevance of ethnic background was systematically addressed in a series of reports arising from the Global Burden of Diseases, Injuries, and Risk Factors Study 2015.⁴¹ A proportion of cases of optic neuritis are related to primary or secondary systemic vasculitis.^{5,16,28} It is necessary to differentiate primarily ischaemic optic neuropathy secondary to vasculitic vascular occlusion or thrombophilia (arterial or venous) from optic neuritis consistent with our diagnostic criteria.^{16,17,37,42} Chiasmal involvement is also seen with post-infectious chiasmitis and as a complication of treatment with, for example, TNF α or immune checkpoint inhibitors.

It is very important to recognise direct infection of the optic nerve and surrounding tissue to initiate appropriate treatment,^{7,17,18} including testing for disorders from panel 4 that are likely to be attributable to geographical region or travel history. The patient is at risk of deterioration if corticosteroids are given without antibiotics or antivirals in the acute phase of some of these conditions.

Panel 5: Subtypes of optic neuritis (level 2 classification)

ADEM-ON

Acute demyelinating encephalomyelitis associated optical neuritis. Bilateral, simultaneous optic neuritis after an infection or vaccination typically, but not exclusively, in childhood.

AQP4-ON

Aquaporin 4 antibody associated optic neuritis. Diagnosis requires an aquaporin 4-antibody test. Isolated AQP4-ON is a forme fruste of the spectrum of NMOSD.

CRMP5-ON

Collapsin response mediator protein 5 associated optic neuritis. Diagnosis requires a CRMP5-antibody test in prelamina optic neuritis.

MOG-ON

Myelin oligodendrocyte glycoprotein antibody associated optic neuritis. Diagnosis requires a positive MOG-antibody test. Isolated MOG-ON is a forme fruste of MOGAD.

MS-ON

Multiple sclerosis associated optic neuritis as the first presentation of a clinical isolated syndrome with MRI or CSF findings compatible with multiple sclerosis; can also occur as a multiple sclerosis relapse. Isolated MS-ON is a forme fruste of multiple sclerosis.

SION

Single isolated optic neuritis is a single event of optic neuritis that is restricted to the optic nerve and is negative for known optic neuritis related autoantibodies.

RION

Relapsing isolated optic neuritis is a spontaneous relapse of optic neuritis that remains restricted to the optic nerve and is negative for known optic neuritis related autoantibodies.

CRION

Chronic relapsing inflammatory optic neuropathy. Diagnosis requires demonstration of dependence on immunosuppressive treatment to prevent relapses in optic neuritis.

Prelaminar optic neuritis

The most anterior manifestation of optic neuritis, which involves the non-myelinated retinal axons and ganglion cell layer and which remains restricted to the prelaminar optic nerve. Acutely, the MRI of the retrobulbar optic nerve does not show an abnormality. Prelaminar optic neuritis is an anatomically based description that applies to all subforms of optic neuritis.

PPON

Primary progressive optic neuritis. Diagnosis requires progressive atrophy or progressive visual loss, or both for >12 months. Diagnosis of PPON is based on time and applies to all subforms of ON that present with a progressive rather than a relapsing disease course.

Philippines—Philippine General Hospital, Manila, Philippines (F M Cruz MD); Surgery Department of Juiz de Fora Medical School, Federal University of Juiz de Fora, Juiz de Fora, Brazil (Prof L P Cunha PhD); Department of Neurology, University Mouloud Mammeri de Tizi Ouzou, Tizi Ouzou, Algeria (Prof S Daoudi MD); Department of Neurology, Hospital Foundation Adolphe de Rothschild, Paris, France (R Deschamps MD); Department of Neurology, Hopitaux Universitaires Strasbourg, Strasbourg, France (Prof J de Seze PhD); Department of Neurology, University Clinic Heidelberg, Heidelberg, Germany (Prof R Diem PhD); Department of Neurosurgery, Isfahan University of Medical Sciences, Isfahan, Iran (Prof M Etemadifar MD); Universidad Nacional Autónoma de México, Instituto Nacional de Neurología y Neurocirugía, Centro Médico ABC, Mexico City, Mexico (Prof J Flores-Rivera PhD); Department of Ophthalmology, Centro Hospitalar e Universitário de Coimbra, Coimbra, Portugal (P L Fonseca MD); Coimbra Institute for Biomedical Imaging and Translational Research (CIBIT), University of Coimbra, Coimbra, Portugal (P L Fonseca); Department of Clinical Medicine, University of Copenhagen, Copenhagen, Denmark (Prof J L Frederiksen MD); Department of Neurology, Copenhagen University Hospital, Copenhagen, Denmark (J L Frederiksen); Department of Neurology, Laboratory of Neuroimmunology, Stanford University School of Medicine, Palo Alto, CA, USA (Prof E Frohman MD, T Frohman PA-C); Lyon Neurosciences Research Center, Lyon I University, Lyon France (Prof C F Tilikete PhD); Neuro-Ophthalmology Unit, Hospices Civils de Lyon, Lyon, France (Prof C F Tilikete); Department of Multiple Sclerosis Therapeutics, Fukushima Medical University School of Medicine, Koriyama, Japan (Prof K Fujihara MD); Department of

Ophthalmology, University of Alberta, AB, Canada (Prof A Gálvez PhD); Department of Neurology, Razi University Hospital, University of Tunis El Manar, Tunis, Tunisia (Prof R Gouider PhD); Department of Neurology, Hospital Santo Tomás, Panama City, Panama (Prof F Gracia MD); Instituto Conmemorativo Gorgas de Estudios de la Salud, Universidad Interamericana de Panama, Panama City, Panama (F Gracia); Department of Neurology, Aristotle University of Thessaloniki, Thessaloniki, Greece (Prof N Grigoriadis PhD); Servicio de Oftalmología, Facultad de Medicina, Clínica Alemana Universidad del Desarrollo, Santiago, Chile (J Guajardo MD); Department of Neurology, University of Zagreb School of Medicine, Zagreb, Croatia (Prof M Habek MD); Department of Neurology, University Hospital Center Zagreb, Zagreb, Croatia (Prof M Habek); Eye Hospital, University Medical Centre, Ljubljana, Slovenia (Prof M Hawlina PhD); Department of Neurology, Hospital Clinic of Barcelona, Barcelona, Spain (E H Martínez-Lapiscina PhD); Institut d'Investigacions Biomèdiques August Pi i Sunyer (IDIBAPS), Barcelona, Spain (E H Martínez-Lapiscina); Aga Khan University Hospital, Nairobi, Kenya (J Hooker MD); Department of Neurology, Penang General Hospital, Penang, Malaysia (J Y Hor MD); Department of Neurology, Kilimanjaro Christian Medical Center (KCMC), Moshi, Tanzania (Prof W Howlett MD); Department of Neurology, Linköping University Hospital, Linköping, Sweden (Prof Y Huang-Link PhD); Department of Neurology, Asfendiyarov Kazakh National Medical University, Almaty, Kazakhstan (Prof Z Idrissova PhD); Department of Neurology, Odense University Hospital, Odense, Denmark (Prof Z Illes MD); Clinic of Neurology and Psychiatry for Children and Youth, Faculty of Medicine University of Belgrade, Belgrade, Serbia (Prof J Jancic PhD); Department of Medicine, Faculty of Medicine Ramathibodi

Similarly, there is a large number of potential differential diagnoses for post-infectious or post-vaccination optic neuritis (panel 4).²⁸ Post-vaccination optic neuritis is very rare.⁴³ The consensus agreement (88 of 94, 94%) was that post-infectious or post-vaccination optic neuritis can be diagnosed within 28 days after the suspected trigger if other causes are ruled out. A special situation develops in children, in whom optic neuritis can be associated with features of ADEM.^{33,44} The manifestation of optic neuritis in ADEM is typically bilateral and severe with substantial brain involvement. Extending the interval in which optic neuritis can be considered post-vaccination or post-infection to 3 months was supported by 38 of 94 (40%) experts only, but it was accepted by the panel that proof of causality (eg, by molecular mimicry) in specific instances might alter this view.

The brain compartment

We use the term brain compartment to refer to the intradural compartment that includes the entire CNS and CSF. This definition recognises that diseases such as ADEM, multiple sclerosis, NMOs, and MOGAD can all be associated with optic neuritis. Milestone revisions of diagnostic criteria for multiple sclerosis between 1965 and 2017 showed increasing sensitivity, permitting earlier diagnosis and treatment of the disease.^{45–48} Importantly, multiple sclerosis can now be distinguished from NMOs and MOGAD, leading to a separate classification of these three conditions.^{31,33}

Long optic nerve lesions extending intracranially are seen in optic neuritis associated with aquaporin 4 antibodies. Chiasmal involvement is also a feature of this subtype of optic neuritis, but rarely of optic neuritis associated with multiple sclerosis anti-MOG antibodies. Isolated intracranial lesions will not cause the pain during eye movement present typically with optic neuritis in the posterior orbit, but such lesions can be seen in all types of optic neuritis. Within the manifold clinical presentations of NMOs (and to an extent multiple sclerosis) there are however cases that will turn out to be anti-MOG antibody seropositive.^{2,33,49,50}

The clinical features of optic neuritis associated with anti-MOG antibodies is more variable regarding prognosis than either optic neuritis associated with multiple sclerosis or optic neuritis associated with aquaporin 4 antibodies. The incidence and clinical features vary with ethnicity, geographical location, and age.⁴⁵¹ Patients with NMOs or MOGAD have been under-represented in clinical trials of optic neuritis, which were hitherto dominated by patients with multiple sclerosis.^{2,4,52}

The orbital compartment

The orbital compartment encompasses the extradural and dural space that includes the optic nerve and surrounding tissue. Classically, post-infectious optic

neuritis and optic neuritis associated with multiple sclerosis affect the retrolaminar area. Patients have pain that worsens on eye movement because of the inflamed optic nerve within this compartment. If the inflammation extends to the perineural tissues and into the orbital fat, then the optic neuritis can be part of an orbital inflammatory process. Perineural changes are a defining feature in optic neuritis associated with anti-MOG antibodies clinically and on MRI.

Extrinsic inflammation (perineuritis) tends to cause more pain than intrinsic inflammation because of dural involvement. When inflammation involves the intracranial optic nerve, pain is unusual as the nerve has a pial covering only.^{53,54}

The prelaminar compartment

The prelaminar compartment includes the retina, which is important because extremely anterior optic neuritis involves the prelaminar optic nerve and possibly the ganglion cell layer and retinal axons.⁵⁵ Extensive subretinal fluid is common, possibly an exudate, giving rise later to the macular star, which is the hallmark of neuroretinitis.^{37,56} There is no abnormality of the retrolbulbar optic nerve on imaging in the acute phase. Associated intraocular inflammation and retinal changes such as oedema, infiltrates, or vasculitis can be seen in some forms of optic neuritis.^{18–20,37,57}

As prelaminar axons are unmyelinated, inclusion of this compartment highlights that not all forms of optic neuritis have to involve demyelination. Prelaminar, axonal, optic neuritis can have a different pathogenesis from anterior, demyelinating, optic neuritis with disc swelling, which can also be a consequence of impaired axonal transport rather than direct inflammation affecting the prelaminar optic disc.⁵⁸

Disc swelling can also occur in association with vitritis.^{37,38} Visual function seems not to be affected in disc swelling secondary to vitritis; therefore, vitritis should probably not be considered as optic neuritis because there appears to be impairment of axonal transport but not neural function, which might be the case with early disc swelling due to raised intracranial pressure or low intraocular pressure.

Biomarker classification

There was a strong level of agreement in the panel (99%) that specific, validated biomarkers can be helpful for three key areas: the diagnostic work up, monitoring, and treatment. In contrast, unvalidated biomarkers were considered unhelpful by 97% of the experts.

Among diagnostic tests, autoantibodies are the most precise biomarker.^{24,31,33} A challenge remains to understand why patients who have the monophasic, forme fruste (panel 2) of optic neuritis can have the same immunology as patients with relapsing pathology, which has important treatment implications because of the need for immunomodulatory or suppressive

treatment in relapsing disease. Currently, there are three clinically validated and specific autoantibodies in optic neuritis, which bind to aquaporin 4, MOG, and collapsin response mediator protein 5 (CRMP5).^{3,24,33,38,49,59,60}

In the diagnosis of optic neuritis subgroups,^{28,31,33} future research will need to focus on discovery and validation of diagnostic antibodies that are currently not validated. This should be a high priority research area for patients who have optic neuritis but are seronegative for aquaporin 4, MOG, and CRMP5.^{28,61} In the monitoring of disease activity, there is a need for biomarkers that indicate when autoimmunity becomes more active, increasing the likelihood of a clinical relapse.^{62,63} This disease activity includes the spectrum from relapsing isolated optic neuritis to chronic relapsing inflammatory optic neuropathy, the diagnosis of which presently depends on careful clinical monitoring.^{3,20} Such biomarkers are likely to become particularly important to address the question of whether the disease activity has decreased and immune suppression can be discontinued. Biomarkers also have a role in optic neuritis treatment trials:⁶⁴ they can be used at enrolment to help with inclusion, exclusion, and identification of likely treatment responders; during the trial to help with safety and recognition of treatment-related neurotoxicity; and as an outcome measure. Standardised sample processing and storage are strongly recommended.^{24,25} Many more candidate antibodies do not yet reach the level of analytical and clinical validation to reach consensus.^{28,65}

Aquaporin 4

Aquaporin 4 is a water channel present on astrocytes and Müller cells.^{66,67} The polarised cellular expression of aquaporin 4 in astrocytic foot processes that wrap around blood vessels explains the strong association between aquaporin 4 seropositivity and optic neuritis.⁶⁷ Aquaporin 4-seropositive individuals have a high risk for recurring attacks involving the optic nerve or other specific CNS regions.^{32,68} Consequently, testing for aquaporin 4 is now recommended in patients with optic neuritis not associated with multiple sclerosis, whether the episode is the first or a recurrent episode.²⁴

MOG

Myelin is an abundant ultrastructure of the CNS.⁶⁹ The main component of myelin is cholesterol (about 40%), followed by long-chain fatty acids enriched by glycosphingolipids (about 20%). Only about 0.05% of myelin is composed of MOG (26–28 kDa). Testing for MOG is recommended in patients with relapsing optic neuritis who are seronegative for aquaporin 4 or who have perineuritis visible on the MRI scan or orbital inflammation on MRI at first presentation.³³ If possible, we recommend simultaneous testing for aquaporin 4 and MOG autoantibodies.

CRMP5

CRMP5, also known as CV2, is a (60–66 kDa) protein that has a role in neuronal differentiation and axonal growth through interaction with microtubules.⁷⁰ In the differentiated nervous system, CRMP5 is expressed by oligodendrocytes and is an important autoimmune target antigen.³⁸

There are around a hundred anecdotal reports on the association between paraneoplastic antibodies and optic neuritis.²⁸ Mostly, this association has been shown in individuals who were CRMP5 seropositive and had optic neuritis with uveitis and retinitis.^{28,38} In all reported cases, the cause was small-cell lung cancer. Other CNS involvement (eg, myelitis) has been reported.³⁸ Our classification permits other paraneoplastic antibodies to be included as causes of optic neuritis; if sufficient evidence emerges it also permits primary involvement of the prelaminar, non-myelinated axons.

CSF IgG

Evidence for intrathecal IgG synthesis in a patient with optic neuritis who has radiological evidence for dissemination in space is suggestive of multiple sclerosis.^{48,71,72} Generally, presence of oligoclonal bands in the CSF is a sign of pathology, but not specific for multiple sclerosis.⁷¹

Biomarkers of progression

Progression of axonal degeneration in optic neuritis can be quantified in the CSF, blood, and vitreous by neurofilament proteins.^{63,73,74} Adjustment for demographic data is relevant and such adjustments have been validated for Z scores.⁷⁵ There are no validated biomarkers for quantification of demyelination in optic neuritis, but acute astrocytic damage in optic neuritis associated with aquaporin-4 antibodies can be measured by CSF and serum GFAP.^{61,76,77}

Chronological classification

Optic neuritis can be defined clinically as monophasic, spontaneous relapsing, immune-suppression-dependent relapsing, or progressive. It is important to distinguish between acute and subacute optic neuritis because of treatment implications.^{78–80}

Acute optic neuritis

Our consensus for classifying optic neuritis as acute is that symptoms, including prodromal pain, have been present for fewer than 7 days (appendix pp 27–29). The inflammatory process in acute optic neuritis can be intrinsic or extrinsic to the optic nerve.⁸¹ If eye pain is present, it is frequently the first symptom of optic neuritis and can precede visual loss. Headaches precede optic neuritis in about 50% of patients whose optic neuritis is associated with anti-MOG antibodies.⁸² Inflammation has an immediate disabling effect on axons, which is the foundation of early acute loss of vision that is reversible

Hospital, Mahidol University, Bangkok, Thailand (Prof P Jindahra PhD); Neuro-Ophthalmology Unit at Rabin Medical Center, Sackler School of Medicine, Tel-Aviv University, Tel-Aviv, Israel (Prof H Stiebel-Kalish PhD); Multiple Sclerosis Center, Sheba Medical Center, Sackler School of Medicine, Tel-Aviv University, Tel-Aviv, Israel (Prof D Karussis PhD); Department of Neurology, Oslo University Hospital, Rikshospitalet, Oslo, Norway (Prof E Kerty MD); Department of Neurology, National Cancer Center, Goyang, South Korea (Prof H J Kim PhD); Eye Center, Medical Center, Medical Faculty, University of Freiburg, Germany (Prof W Lagrèze MD); Vita-Salute San Raffaele University, Experimental Neurophysiology Unit, Institute of Experimental Neurology-INSPE, Scientific Institute San Raffaele, Milan, Italy (Prof L Leocani PhD); Department of Neurology, Hadassah Medical Center and Faculty of Medicine, Hebrew University, Jerusalem, Israel (Prof N Levin MD PhD); Department of Paediatrics and Inherited Metabolic Disorders, and Department of Ophthalmology, First Faculty of Medicine, Charles University and General University Hospital in Prague, Prague, Czech Republic (Prof P Liskova PhD); Department of Radiology, Beijing Tiantan Hospital, Capital Medical University, Beijing, China (Prof Y Liu PhD); Department of Neurology, Gabriel Touré University Hospital, Bamako, Mali (Prof Y Maiga MD); Service de Neurologie, Sclérose en Plaques, Pathologies de la Myéline et NeuroInflammation, and Centre de Référence des Maladies Inflammatoires Rares du Cerveau et de la Moelle, Hôpital Neurologique Pierre Wertheimer, Bron, France (Prof R Marignier MD); School of Medicine, University College Dublin, Dublin, Ireland (Prof C McGuigan FRCP FRCP); Department of Neurology, St Vincent's University Hospital, Dublin, Ireland (Prof C McGuigan); Centro Hospitalar de Vila Nova de Gaia/Espinho, Portugal

(Prof D Meira MD); Department of Ophthalmology, University Hospital of Martinique, Martinique, French West Indies, France

(Prof H Merle PhD); Division of Ophthalmology, University of São Paulo Medical School, São Paulo, Brazil

(Prof M Monteiro PhD);

Department of Neurology, University of KwaZulu-Natal, Durban, South Africa

(Prof A A Moodley PhD);

Department of Neuro-Ophthalmology, Instituto Paulista Da Visão, Higienópolis, Brazil (Prof F Moura PhD);

Department of

Ophthalmology, Hospital Universitari de Bellvitge, L'Hospitalet de Llobregat, Barcelona, Spain (S Muñoz MD);

Department of Neurology, Prime Healthcare Group, Dubai, United Arab Emirates

(Prof M Sharik DM); Department of Neurology, Tohoku Medical and Pharmaceutical University, Sendai, Japan

(Prof I Nakashima MD);

Department of Ophthalmology, Hospital Universitario La Paz, Madrid, Spain (Prof S Noval PhD);

Department of Neurology, School of Medicine UDELAR, Montevideo, Uruguay

(Prof C Oehninger PhD);

Department of Ophthalmology, College of Medicine, University of Ibadan, Ibadan, Nigeria

(Prof O A Ogun FWACS);

Department of Ophthalmology, University of Benin, Benin City, Nigeria

(Prof A Omoti FMC(oph)); Center for Advanced Neurological Research, Nitte University, Karnataka, India

(Prof L Pandit PhD);

Experimental and Clinical Research Center, Max Delbrueck Center for Molecular Medicine and Charité-Universitätsmedizin Berlin, Berlin, Germany

(Prof F Paul MD); Department of Ophthalmology of Ramon y Cajal Hospital, and Alcala University Madrid, Madrid, Spain (Prof G Rebolledo MD);

Sydney Neurology, Sydney, NSW, Australia (S Reddel PhD);

Department of Neurology, Medical University of Lublin, Lublin, Poland

(Prof K Rejdak PhD);

Department of General and Pediatric Ophthalmology

with spontaneous recovery or treatment with corticosteroids.^{79,80} Permanent visual loss depends on axonal loss (permanent loss) or demyelination with conduction block, which starts in the acute phase (potential for recovery).

Subacute optic neuritis

The subacute interval is between 7 days and 3 months after onset. The clinical assessment of patients with their first episode of optic neuritis is often delayed.^{16,20} More symptoms develop in the subacute interval that require that a careful history of symptoms is taken from the patient. With resolution of inflammation, the pain on eye movements ceases, typically within less than 2 weeks after onset. Conduction block and demyelination can persist far into the subacute phase. In most cases of optic neuritis associated with multiple sclerosis, the nadir of visual loss is reached in less than 1 month. During subsequent resolution of conduction block and demyelination, patients report a range of visual symptoms such as Uhthoff's phenomenon,^{83,84} Pulfrich phenomenon,^{85,86} light intolerance,³¹ impaired dark-light adaptation, and visual fading (a physiological phenomenon that is much more prominent in patients who have optic neuritis than in healthy individuals).⁵⁷

Relapsing optic neuritis

Optic neuritis that relapses independent of corticosteroid withdrawal, that is seronegative for aquaporin 4, MOG, and CRMP5, and that is confined to the extradural and dural compartment, is defined as relapsing isolated optic neuritis. Relapsing isolated optic neuritis resembles in all other respects optic neuritis associated with multiple sclerosis, NMOSD, or MOGAD but without any other features due to pathology of other brain and spinal cord areas associated with these disorders.²⁴ With extensive follow-up, a patient with relapsing isolated optic neuritis can be diagnosed with one of these three conditions, with lesions appearing in the intradural compartment.

There is emerging evidence that very early treatment, in the acute phase of optic neuritis, is more effective than delayed treatment;^{64,78–80,88,89} such early treatment is more practical for a relapse than for the first episode. Relapsing optic neuritis can be triggered by systemic infection or rarely by vaccination,⁴³ which have also been described as rare potential triggers of relapses in patients with multiple sclerosis.^{90,91}

The term chronic relapsing inflammatory optic neuropathy was introduced to define patients who have optic neuritis when corticosteroids are withdrawn.^{20,57} The published consensus advice has been to taper corticosteroids more slowly than in the standard multiple sclerosis protocols, particularly if there had been a previous episode with a poor visual outcome in the same or fellow eye or an atypical disease course (panel 3).^{20,33} Patients should be monitored carefully

during tapering and instructed to report pain or visual loss immediately.

Once the relationship between immunosuppression and optic neuritis relapse is established, corticosteroid sparing agents are indicated. Use of these agents is important because all damage to the optic nerve in complement-mediated autoimmune optic neuritis, such as that associated with NMOSD or MOGAD, is currently understood to be attack related.^{20,28,33,49} Clinical identification of patients who have, and prediction of those who will go on to develop, relapsing corticosteroid-dependent optic neuritis is a high priority for further research, particularly if P4 (predictive, preventive, personalised, and participatory) medicine is to be achieved for these patients.⁹²

Chronic optic neuritis

It takes, on average, 3 months for an individual to recover from an attack of optic neuritis if they do not have progressive optic neuritis (panel 3).^{18,19} Patients seen after this time will have some degree of retinal nerve fibre layer loss in the affected eye compared with the spared eye.²⁴

Frequently, persistent symptoms and signs, even after improvement of Snellen visual acuity, include poor low contrast visual acuity, dyschromatopsia, visual field changes, and a relative afferent pupillary deficit. However, eye pain and other transient symptoms in the subacute phase should have completely subsided.^{18,19,83} If still present, treatment for glare disability and Pulfrich phenomenon is available.^{85,86} Refraction should be optimised because low contrast acuities are strongly affected by poor refraction.²⁴ The clinical work-up for late presenting optic neuritis for patients with optic neuritis who are first seen more than 3 months after symptom onset, is mainly to identify risk factors for a future relapse.^{24,31,33} Single isolated optic neuritis, in which there is no evidence of multiple sclerosis, needs to be distinguished from the heterogeneous group of relapsing and progressive optic neuritis subtypes.

Primary progressive optic neuritis

Primary progressive optic neuritis is very rare, with only anecdotal observations shared by experts on our panel. Because the analogy to a diagnosis of primary progressive multiple sclerosis is now well established, this subcategory of optic neuritis has been included here, although we acknowledge that it did not reach formal consensus for level 2. The concept is that of an insidiously progressive form of optic neuritis. Primary progressive optic neuritis can occur in patients with secondary progressive multiple sclerosis but is poorly documented in the literature.⁹³ It is important to test whether patients suspected to have primary progressive optic neuritis are seropositive for aquaporin 4, MOG, or CRMP5, and whether they are corticosteroid responsive, because untreated optic neuritis that is associated with NMOSD or MOGAD and chronic relapsing inflammatory optic neuropathy are important

differential diagnoses.²⁰ There is also a need to exclude a genetic cause such as mutations to mitochondrial DNA, or the *OPA1* or *OPA3* genes.³⁷ We propose that primary progressive optic neuritis is defined as insidious progression of structural measures of atrophy or visual loss for at least 12 months after symptom onset.

MRI

Radiological examination can assist in the classification of optic neuritis subtypes. The latest radiological consensus recommendations for multiple sclerosis address the use of MRI,³⁹ including the need for caution and avoidance of unnecessary imaging in childhood, pregnancy, and the post-partum period, as well as avoidance of use of contrast.

Sequences and sensitivity

For investigation of suspected optic neuritis, the field strengths should be 1.5 T or greater, with an image field that covers the optic nerve and chiasm and with the axial scans being aligned to these structures. The slice thickness should be 2–3 mm or less without gaps, providing a resolution of 1 mm×1 mm or less. It was recommended^{24,39} to use sequences such as the short tau inversion recovery (STIR), fat suppressed T2-weighted sequences, or frequency-specific selective partial inversion recovery.

The sensitivity of MRI to detect optic neuritis is 20–44%, depending on the subtype of optic neuritis. Pioneering studies included subtypes of optic neuritis not recognised as such at the time.⁹⁴ Later studies that included mostly patients with optic neuritis associated with multiple sclerosis reported a higher sensitivity of MRI than did older studies. For the intraorbital region the sensitivity of MRI is poorer.^{94–96} In acute prelaminar optic neuritis, the MRI of the optic nerve does not show any lesions. The use of three-dimensional double inversion recovery might increase sensitivity to 61.2–82.2%,⁹⁷ but implementation of this sequence for optic nerve imaging is presently not possible with most devices.

Lesion location

Optic nerve lesion location and length as seen on MRI can be helpful in diagnosis. Contrast enhancement around the optic nerve and of the retro-ocular orbital fat and longitudinal enhancement of the optic nerve sheath indicate perineuritis.^{7,53,81} Perineuritis is more frequent in optic neuritis in patients seropositive for anti-MOG antibodies or infectious optic neuritis than in other optic neuritis subtypes, and should prompt serological testing for diseases suspected from the history (panel 4), if not already done.^{33,40,81}

Lesion activity

MRI is very helpful in demonstrating acute damage superimposed on chronic damage, because gadolinium enhancement will be seen in cases with active

inflammation on axial and coronal fat-suppressed T1-weighted sequences.³⁹ MRI permits longitudinal quantification of progression of optic atrophy. The atrophy results in signal intensity increase within the optic nerve, due to axonal degeneration and signal intensity increase around the optic nerve owing to an enlarged CSF space.

OCT

Retinal OCT provides an accurate quantitative metric in optic neuritis and adds detailed qualitative information.^{8,55} The earliest changes of atrophy are found in the macular ganglion cell inner plexiform layer (mGCIPL) because the axons (peripapillary retinal nerve fibre layer [pRNFL]) can remain swollen for several weeks after acute optic neuritis.⁹⁸

Retinal asymmetry

In addition to monocular atrophy, other metrics of retinal asymmetry include the inter-eye difference for the pRNFL or for the mGCIPL. An inter-eye difference of more than 3–5% (or 3–5 µm because the standard is about 100 µm for pRNFL) is diagnostic for unilateral optic neuropathy (panel 1, >4% [4 µm] for mGCIPL and >5% [5 µm] for pRNFL).^{9,99–104} The highest diagnostic specificity (69–97%) was found for the inter-eye difference for the macular inner plexiform and ganglion cell layers, with corresponding sensitivity levels of 61–100%.^{9,99,100,104}

Pattern recognition

Microcystic macular oedema is more frequent within patients who have optic neuritis associated with aquaporin-4 antibodies or severe single isolated optic neuritis than in patients with optic neuritis associated with multiple sclerosis.^{97,105–108} The association of microcystic macular oedema with severe atrophy of the caecocentral projection, also called the papillomacular bundle, raises the possibility of the future value of this finding in the differential diagnosis of bilateral severe loss between optic neuritis associated with antibodies to MOG or aquaporin 4, NMOSD, hereditary optic neuropathies, and severe nutritional toxic optic neuropathy.^{24,28,109–111} Nasal pRNFL atrophy is more frequent in optic neuritis associated with anti-MOG antibodies than in optic neuritis associated with multiple sclerosis, where temporal pRNFL dominates. Sectoral atrophy of the peripapillary retinal nerve fibre layer elsewhere at the optic disc alerts to other differential diagnoses, such as ischaemic damage.¹¹²

Diffuse atrophy of the RNFL and mGCIPL in the range of about 10–20 µm is common, with pathology directly involving the optic nerve, whereas an atrophy of about 2–10 µm can be the result of retrograde-trans-synaptic axonal degeneration from brain pathology.^{8,55,113}

The use of OCT is exceptionally suitable for analysis of big data.¹⁰⁴ Large-scale, population-based OCT studies now exist in many countries, with a recent linkage

Medical University of Lublin, Lublin, Poland (Prof R Rejdak MD); Grupo de Investigación Biomedicina, Facultad de Medicina, Fundación Universitaria Autónoma de las Américas, Risaralda, Colombia (Prof A Rodríguez-Morales DSc); Department of Ophthalmology, University Hospital of Bordeaux, Bordeaux, France (Prof M B Rougier PhD); Department of Neurology, Centro Hospitalar Universitário São João and Faculty of Health Sciences, University Fernando Pessoa, Porto, Portugal (Prof M J Sa PhD); Department of Ophthalmology, Hospital Clinic of Barcelona, Barcelona, Spain (Prof B Sanchez-Dalmau MD); Department of Ophthalmology, Johns Hopkins University School of Medicine, Baltimore, MD, USA (Prof D Saylor MD); Department of Ophthalmology and Visual Science, School of Medical Sciences, Universiti Sains Malaysia, Kelantan, Malaysia (Prof I Shatriah MD); Department of Neurology, Istanbul University-Cerrahpasa, Cerrahpasa School of Medicine, Istanbul, Türkiye (Prof A Siva MD); Department of Ophthalmology, University of Mississippi Medical Center, Jackson, MS, USA (Prof G Szatmary PhD); Department of General Planning, Ho Chi Minh City Eye Hospital, Ho Chi Minh City, Vietnam (Prof L Ta MD); Department of Neurology, National Paediatric Hospital Dr Juan P Garrahan, Buenos Aires, Argentina (Prof S Tenenbaum MD); Department of Ophthalmology, Faculty of Medicine, Ho Chi Minh City University of Medicine and Pharmacy, and Hai Yen Vision Institute, Ho Chi Minh City, Vietnam (Prof H Tran PhD); Department of Neurology and Reflexology, The Shupyk National Healthcare University of Ukraine, Kyiv, Ukraine (Prof Y Trufanov PhD); Department of Neurology, Cliniques Universitaires Saint-Luc Brussels, Belgium (Prof V van Pesch MD PhD); Neurochemistry Unit, Institute of Neuroscience, UCLouvain, Brussels, Belgium (Prof V van Pesch). Department

of Ophthalmology, Taipei Veterans General Hospital, National Yang-Ming Chiao-Tung University School of Medicine, Taipei, Taiwan (Prof A G Wang PhD); Department of Diagnostic and Interventional Neuroradiology, Hannover Medical School, Hannover, Germany (Prof M Wattjes PhD); Department of Neurology, Auckland City Hospital, Auckland, New Zealand (E W Willoughby FRACP); Department of Neurology, Ain Shams University Hospitals, Cairo, Egypt (Prof M Zakaria PhD); Department of Ophthalmology, University Clinical Center Tuzla, Tuzla, Bosnia and Herzegovina (J Zvornicanin PhD); Department of Neurology, Department of Population Health, and Department of Ophthalmology, New York University Grossman School of Medicine, New York, NY, USA (Prof L J Balcer MD); Department of Brain Repair and Rehabilitation, UCL Institute of Neurology, Faculty of Brain Sciences, London, UK (G T Plant MD)

Correspondence to: Dr Axel Petzold, The National Hospital for Neurology and Neurosurgery, Queen Square, London, WC1N 3BG, UK a.petzold@ucl.ac.uk
See Online for appendix

study encompassing 6261931 retinal images.¹¹⁴ Many optometrists in high-income countries now have an OCT device permitting retinal imaging to be scaled up to be used at the population level for research purposes. Existing databases will be useful for validating and further refining our diagnostic criteria.^{104,111,114} We recommend that OCT assessment of individuals suspected of having optic neuritis includes images from the optic disc and the macula.²⁴ Quality control of individual B-scans is advised.¹¹⁵ Reporting of results from OCT studies using big data should be compliant with existing guidelines.¹¹⁶

Electrodiagnostic investigations

The electroretinogram or pattern-electroretinogram can be helpful in the diagnostic work-up of prelaminar optic neuritis, or if an occult form of maculopathy is suspected. Visual evoked potentials (VEPs) have also been used but should not be interpreted without additional pattern or multifocal electroretinogram recordings, because the VEP is driven by the central macular responses. VEPs have a role in clinical trials assessing optic nerve remyelination.¹¹⁷ In contemporary clinical practice, wide experience with VEPs has declined (appendix p 26). In the acute situation, VEPs are less useful than at follow-up, when they help with the differential diagnosis of complex cases, including patients with functional visual loss.^{16,24}

Treatment

The level 2 classification of optic neuritis subtypes relies, in part, on monitoring the treatment response to corticosteroids. The panel was divided on the need for immunosuppression in patients in whom the risk for future relapse was difficult to predict. However, such prognostic information is important for three reasons: (1) health-care system sustainability, given that some of these treatments are very expensive; (2) highlighting the need for biomarkers and genetic profiling, which can help with accurate prediction of the risk of future relapse (appendix p 33); and (3) treatment trial design, to avoid regression to the mean in individuals who have a good prognosis either because of monophasic or non-progressive illness.

How to decide who to treat

In the literature and from our personal experience, there is no consensus on the use of corticosteroids in optic neuritis. The prolonged use of corticosteroids is generally not recommended in children. A prolonged course of treatment will require careful weighing of the risks and benefits on an individual basis. For an acute attack of optic neuritis, high-dose corticosteroids are given either intravenously or orally, the bioequivalent of 1 g methylprednisolone intravenously or the bioequivalent of 1.25 g prednisone per day.¹¹⁷ The intravenous treatment dose varied between centres with members on our panel, from 0.5 to 1.0 g methylprednisolone. The treatment

duration also ranges between centres from 3 to 5 days, but can occasionally be up to 10 days in severe cases. The clinical experience with chronic relapsing inflammatory optic neuropathy, and subsequently optic neuritis associated with antibodies to aquaporin 4 or MOG, makes a case for high-dose methylprednisolone to be followed by a slow oral taper with prednisolone at a starting dose of around 1 mg/kg.^{20,33} There is no consensus on how long this oral taper should be.³³ New trials are needed to investigate how quickly treatment should be initiated;⁶⁴ hyperacute treatment might improve outcome compared with delayed treatment.^{64,78–80,88,89,119} Plasma exchange can also be administered in severe refractory cases.^{20,89}

Who needs long-term immunosuppression?

Individuals who have relapses after reduction of corticosteroids need immunosuppression (56 of 58, 97% expert agreement, but poor expert response rate, appendix p 16). Five novel biological agents (eculizumab, inebilizumab, satralizumab, tocilizumab, and ublituximab) are highly effective for the treatment of NMOSD.^{10–15} Over a dozen disease-modifying treatments have been approved for multiple sclerosis, but the efficacy for optic neuritis alone is not known.²⁶ Other immunosuppressive strategies frequently used to treat optic neuritis associated with antibodies to MOG or aquaporin 4 and chronic relapsing inflammatory optic neuropathy are azathioprine, methotrexate, mycophenolate, rituximab, immunoglobulin, and plasma exchange.^{20,33,89} Our Delphi process highlighted the challenges that the panel had regarding when to initiate these treatment options (appendix pp 30–31).

Conclusions and future directions

In conclusion, this consensus paper on optic neuritis breaks new ground on four levels. First, it implements an anatomical classification by explicitly including the entire pathway of the retinal ganglion cell axon. This approach clarifies that ambiguously classified presentations, such as paraneoplastic syndromes in the retina, are now defined as prelaminar optic neuritis. Additionally, the anatomical grouping includes four immunologically overlapping compartments that will also be helpful for guiding future research on autoimmune causes. This definition acknowledges that pathology can start as a compartmentalised autoimmune reaction but permits for breakthrough disease activity into another compartment. This distinction will be informative for research, for example because it separates a forme fruste of optic neuritis that remains compartmentalised from optic neuritis that breaks through to the intradural compartment developing to multiple sclerosis,³⁰ MOGAD,³³ or NMOSD.³¹

Second, the 3-year Delphi process included clinical neurologists and ophthalmologists from all around the world as equal partners (appendix p 13). As a result, and

Search strategy and selection criteria

We searched Google Scholar and PubMed for references without language restrictions up to Jan 1, 2021, for the Delphi process, and again until April 1, 2022, for an update of the literature review. We gave preference to papers we considered to be major contributions over the past decade, but some older key references were also included. The search terms used were “optic neuritis” in combination with the following terms and abbreviations: “acute demyelinating encephalomyelitis” (ADEM), “aquaporin 4” (AQP4), “central nervous system” (CNS), “chronic relapsing inflammatory optic neuropathy” (CRION), “collapsin response mediator protein 5” (CRMP5), “cerebrospinal fluid” (CSF), “3D double inversion recovery” (DIR), “electroretinogram” (ERG), “inner plexiform and ganglion cell layers” (GCIPL), “ganglion cell layer” (GCL), “glial fibrillary acidic protein” (GFAP), “tetrasialoganglioside” (GQ1b), “intravenous immunoglobulin” (IVIG), “immunoglobulin G” (IgG), “Jo 1 antigen on the microspheres” (Jo1), “microcystic macular oedema” (MMO), “myelin oligodendrocyte glycoprotein” (MOG), “MOG associated optic neuritis” (MOG-ON), “MOG antibody disease” (MOGAD), “magnetic resonance imaging” (MRI), “multiple sclerosis” (MS), “MS associated optic neuritis” (MS-ON), “N-methyl-D-aspartate receptor” (NMDAR), “neuromyelitis optica” (NMO), “NMO IgG” (NMO-IgG), “NMO associated optic neuritis” (NMO-ON), “NMO spectrum disease” (NMOSD), “progressive optic neuritis” (PPON), “optical coherence tomography” (OCT), “optic neuritis” (ON), “Optic atrophy protein 1” (OPA), “relative afferent pupillary deficit” (RAPD), “relapsing isolated optic neuritis” (RION), “retinal nerve fibre layer” (RNFL), “single isolated optic neuritis” (SION), “short tau inversion recovery” (STIR), “visual evoked potentials” (VEP), “cytoplasmatic staining patten of the antineutrophilic cytoplasmic antibody” (c-ANCA), “macular GCIPL” (mGCIPL), “mitochondrial DNA” (mtDNA), and “peripapillary RNFL” (pRNFL). We selected major reviews, meta-analyses, and original work.

consistent with very large epidemiological data,⁵ multiple sclerosis, which has hitherto dominated in the differential diagnosis of optic neuritis, has become a very well defined partner among individually rare but cumulatively more frequent presentations.^{4,5} The small regional variations in the clinical presentation are entirely consistent with the majority of pathologies seen in these geographical regions (appendix p 19). Experts also exhibited greater than 90% agreement on the central roles of OCT, MRI, and serum biomarkers as paraclinical tests.

Third, transparent diagnostic criteria for optic neuritis are presented (panel 1). These criteria are based on the reviewed data and combine three key clinical scenarios (panel 1 [A-C] and figure) with supportive paraclinical tests (OCT, MRI, and serum biomarkers). A novel aspect of these criteria is that they are applicable to big data. With the rise of artificial intelligence-based methods, diagnostic criteria are needed as a reference standard

(also called ground truth in big data research).²⁷ Future validation studies will need to test and further optimise the sensitivity and specificity of present criteria for different optic neuritis subgroups.

Lastly, the lack of consensus in our Delphi process regarding treatment options showed an area in which treating physicians need more information. Although the panel was very confident about what to do with highly active disease and almost equally sure what to do with a monophasic presentation, uncertainty remains for less extreme clinical presentations. In routine clinical practice, the less extreme cases are probably most common. The implications for guidance on treatment are relevant because of the downstream effects for health-care system sustainability. Some treatment options are very expensive and pose unnecessary risks to patients who have very low disease activity or even a monophasic disease course. Future treatment trials are needed to address these issues. Our proposed diagnostic criteria and classification of optic neuritis might be helpful for the design of such trials.

Taken together, consensus is needed on treating optic neuritis, and our classification might enable recruitment of more homogeneous optic neuritis subgroups. These trials will need to accommodate regional variations in the access to treatment options. Discussion within the panel, including with paediatric experts, suggests that three age ranges—17 years and younger, 18–40 years, and older than 40 years—should be studied independently to capture the higher likelihood of optic neuritis associated with multiple sclerosis in the group aged 18–40 years as opposed to younger and older patients.

Contributors

AP wrote the first draft and was responsible for study design, data collection and analysis, literature search, and review and editing of the paper. All other authors performed data collection and analysis, literature searches, and review and editing of the paper.

Editorial note: The Lancet Group takes a neutral position with respect to territorial claims in published maps and institutional affiliations.

Declaration of interests

AP received grant support for remyelination trials in multiple sclerosis to the Amsterdam University Medical Centre, Department of Neurology, MS Centre (RESTORE trial), and UCL, London RECOVER trial; received grant fees from Fight for Sight (nimodipine in optic neuritis trial); received royalties or licenses from Up-to-Date (Wolters Kluwer) for a book chapter; received speaker fees for the Heidelberg Academy; participates on advisory board for SC Zeiss OCTA Angi-Network, and the SC Novartis OCTiMS study; holds leadership roles for governing board IMSVISUAL; was chairman of ERN-EYE Neuro-ophthalmology (until Oct, 2020); is board member of National Dutch Neuro-ophthalmology Association; received equipment from OCTA from Zeiss (Plex Elite); and received medical writing support from Novartis for a manuscript (<https://doi.org/10.1002/acn3.51473>). CF received consulting fees from Invex Therapeutics; received speaker honoraria from University of Dunedin; and holds leadership as Director of Royal Australian and New Zealand College of Ophthalmologists. VB received personal fees as consultant for Gensight and Neurophoenix. PC obtained grants from Annexon, Biogen, Genentech; received royalties from Cambridge Press for an OCT book; received consulting fees from Disarm Therapeutics, Nervgen, Biogen, Avidia; received honoraria from NY Academy of Sciences; and received equipment from Myelin Repair Foundation, Academic CME, Neuraly, and Landos. FC received speaker

honoraria from Alexion, Accure Therapeutics, and the Sumiara Foundation. RDe obtained consulting fees from Alexion. JdS received consulting fees from Biogen, Teva, BMS Celegene, Roche, Novartis, Janssen, Merck, Alexion, CSL Behring; and honoraria from Biogen, Teva, BMS Celegene, Roche, Novartis, Janssen, Merck, Alexion, and CSL Behring. JFR received consulting fees from Roche, and Sanofi. EF holds honoraria from Alexion, Genzyme, Biogen, Novartis, and Janssen. TF holds honoraria from Alexion. CFT received honoraria from Novartis; and received support for attending meetings and travel from Novartis and Teva. KF obtained grants from Ministry of Education, Science and Technology of Japan as well as the Ministry of Health, Welfare and Labor of Japan; received consulting fees from Alexion Chugai-Roche Mitsubishi Tanabe, Novartis, Biogen, Eisai, Takeda, Teijin, Viela Bio, UCB, Merck, Japan Tobacco Pharma, and Abbvie; received honoraria from Alexion, Chugai-Roche, Mitsubishi Tanabe, Novartis, Biogen, Eisai, Takeda, Asahi Kasei Medical, Teijin, and Bayer; participated on a data safety monitoring board or advisory board from Alexion, Chugai, Mitsubishi Tanabe, Novartis, Biogen, Eisai, Takeda, Asahi Kasei Medical, Teijin, UCB, and Viela Bio; and received medical writing support from Oxford PharmaGenesis and Apothecon. RG acquired personal fees for participation on data safety monitoring boards, and served on the advisory boards for Biogen, Hikma, Merck, Roche, and Sanofi as well as receiving a grant from Roche. FG received grants or contracts from Roche (NMO epidemiologic studies) and Novartis (MS epidemiologic studies); received honoraria from lectures from Roche, Novartis, Stendhal, and Merck; received support for attending meetings from the European Charcot Foundation, andECTRIMS; and reports leadership of FOCEM (Foro Centroamericano y del Caribe de la Esclerosis Múltiple y otras enfermedades desmielinizantes del Sistema Nervioso Central) and Academia Panameña de Medicina y Cirugía (both unpaid). MHab obtained honoraria from Biogen, Sanofi Genzyme, Merck, Bayer, Novartis, Pliva-Teva, Roche, and Zentiva; received support for attending meetings from Biogen, Sanofi Genzyme, Merck, Bayer, Novartis, Pliva-Teva, and Roche; and participated on advisory board for Biogen, Sanofi Genzyme, Merck, Bayer, Novartis, Pliva-Teva, and Roche. ZII obtained grants or contracts from Biogen and Alexion; received honoraria from Biogen, Novartis, Roche, Merck, and Alexion; received payment for expert testimony from Roche; received support for attending meetings and travel from Biogen and Sanofi; and participated on a data safety monitoring board or advisory board from Biogen, Novartis, Merck, Sanofi, Roche, and Alexion. HJK received grants or contracts from National Research Foundation of Korea, Aprilbio, and Eisai; received consulting fees from Aprilbio, Daewoong, HanAll BioPharma, MDimune, Roche, Sanofi Genzyme, Teva-Handok, UCB, and Viela Bio; and received honoraria from Alexion, Biogen, Celltrion, Eisai, G C Pharma, Merck Serono, Novartis, Sanofi Genzyme, and Teva-Handok. RM received consulting fees from UCB, Alexion, Merck, Viela Bio, Novartis, and Roche; and participated on an advisory board for Viela Bio and Roche. FP obtained research support from Alexion; received grants or contracts from German Ministry for Research Support Recipient Charité Education and Research (BMBF), Deutsche Forschungsgemeinschaft (DFG), Einstein Foundation, Guthy Jackson Charitable Foundation, EU FP7 Framework Program, Biogen, Genzyme, Merck, Serono, Novartis, Bayer, Roche, Parexel, and Almirall; received honoraria from the Guthy Jackson Foundation, Bayer, Biogen, Merck Serono, Sanofi Genzyme, Novartis, Viela Bio, Roche, UCB, Mitsubishi Tanabe, and Celgene; received support for attending meetings from Guthy Jackson Foundation, Bayer, Biogen, Merck Serono, Sanofi Genzyme, Novartis, Alexion, Viela Bio, Roche, UCB, Mitsubishi Tanabe, and Celgene; participated on an advisory board for Celgene, Roche, UCB, Merck; and reports leadership as academic editor for *Plos One*, and associate editor for *Neurology*, *Neuroimmunology*, and *Neuroinflammation*. MBR received support for attending meeting from Novartis. BSD received consulting fees from Chiesi; received honoraria from Chiesi and Sanofi; received support for attending meetings from Bausch + Lomb; participated on an advisory board for Chiesi; and has stock options from Accure Therapeutics. DS received grants or contracts from National Institute of Neurological Disorders and Stroke (NINDS), National Institute of Mental Health (NIMH), American Academy of Neurology (AAN), National Institute of Aging (NIA), National Multiple Sclerosis Society (NMSS), and United States Department of State; and was a

committee member for Multiple Sclerosis International Federation (MSIF) and American Neurological Association (ANA). AS received grants or contracts from the Turkish MS society, and Istanbul University Research Support Grants; received consulting fees from Roche, Merck Serono, Biogen, Gen Pharma of Türkiye, Sanofi Genzyme, and Novartis; received honoraria from Sanofi Genzyme, Novartis, Roche, and Teva; and received support for attending meetings from Sanofi Genzyme. VvP obtained grants or contracts from Biogen; received consulting fees from Biogen, Merck, Sanofi, BMS, Novartis, Janssen, Almirall, and Roche; received honoraria from Biogen, Merck, Sanofi, BMS, Novartis, Roche; and received support for attending meetings from Biogen, Roche, and Almirall. MPW received royalties from Springer Healthcare and Elsevier; received consulting fees from Biogen, Roche, Biologix, Novartis, BMS-Celgene, Imcysc, Merck Serono, Sanofi Aventis, IXICO, and Icometrix; received honoraria from Bayer, Biogen, Biologix, Genilac, Novartis, Medison, Merck Serono, Roche, Sanofi Aventis, and BMS-Celgene; and participated on a data safety monitoring board for VU University Medical Center. LB received consulting fees as editor for the *Journal of Neuro-Ophthalmology*. GTP is an Emeritus editor for *Neuro-ophthalmology*. All other authors declare no competing interests.

Acknowledgments

Yevgen Trufanov and Zhannat Idrissova were supported by the YNT-Schering Fellowship on Multiple Sclerosis which has since matured into the ECTRIMS fellowship program. We are grateful for feedback on the manuscript from members of the Dutch Neuro-ophthalmology patient organisation, Simone Rietveld, Christian Waters, and Nils Wiegerinck.

References

- Soelberg K, Jarius S, Skejoe H, et al. A population-based prospective study of optic neuritis. *Mult Scler* 2017; **23**: 1893–901.
- Chen JJ, Tobin WO, Majeed M, et al. Prevalence of myelin oligodendrocyte glycoprotein and aquaporin-4-IgG in patients in the optic neuritis treatment trial. *JAMA Ophthalmol* 2018; **136**: 419–22.
- Petzold A, Woodhall M, Khaleeli Z, et al. Aquaporin-4 and myelin oligodendrocyte glycoprotein antibodies in immune-mediated optic neuritis at long-term follow-up. *J Neurol Psychiatry* 2019; **90**: 1021–26.
- Hickman SJ, Petzold A. Update on optic neuritis: An international view. *Neuroophthalmology* 2022; **46**: 1–8.
- Braithwaite T, Subramanian A, Petzold A, et al. Trends in optic neuritis incidence and prevalence in the UK and association with systemic and neurologic disease. *JAMA Neurol* 2020; **77**: 1514.
- Ramanathan S, Fraser C, Curnow SR, et al. Uveitis and optic perineuritis in the context of myelin oligodendrocyte glycoprotein antibody seropositivity. *Eur J Neurol* 2019; **26**: 1137–e75.
- Deschamps R, Poillon G, Marill A, Marignier R, Gout O, Sene T. Myelin oligodendrocyte glycoprotein antibody-associated diffuse orbital inflammation. *Mult Scler* 2020; **26**: 1441–3.
- Petzold A, Balcer LJ, Calabresi PA, et al. Retinal layer segmentation in multiple sclerosis: a systematic review and meta-analysis. *Lancet Neurol* 2017; **16**: 797–812.
- Behbehani R, Ali A, Al-Omairah H, Rousseff RT. Optimization of spectral domain optical coherence tomography and visual evoked potentials to identify unilateral optic neuritis. *Mult Scler Relat Disord* 2020; **41**: 101988.
- Yamamura T, Kleiter I, Fujihara K, et al. Trial of satralizumab in neuromyelitis optica spectrum disorder. *New Engl J Med* 2019; **381**: 2114–24.
- Cree BAC, Bennett JL, Kim HJ, et al. Inebilizumab for the treatment of neuromyelitis optica spectrum disorder (n-MOmentum): a double-blind, randomised placebo-controlled phase 2/3 trial. *Lancet* 2019; **394**: 1352–63.
- Mealy MA, Levy M. A pilot safety study of ublituximab, a monoclonal antibody against CD20, in acute relapses of neuromyelitis optica spectrum disorder. *Medicine* 2019; **98**: e15944.
- Pittock SJ, Berthele A, Fujihara K, et al. Eculizumab in aquaporin-4 positive neuromyelitis optica spectrum disorder. *N Engl J Med* 2019; **381**: 614–25.

- 14 Traboulsee A, Greenberg BM, Bennett JL, et al. Safety and efficacy of satralizumab monotherapy in neuromyelitis optica spectrum disorder: a randomised, double-blind, multicentre, placebo-controlled phase 3 trial. *Lancet Neurol* 2020; **19**: 402–12.
- 15 Zhang C, Zhang M, Qiu W, et al. Safety and efficacy of tocilizumab versus azathioprine in highly relapsing neuromyelitis optica spectrum disorder (TANGO): an open-label, multicentre, randomised, phase 2 trial. *Lancet Neurol* 2020; **19**: 391–401.
- 16 Stunkel L, Kung NH, Wilson B, McClelland CM, Van Stavern GP. Incidence and causes of overdiagnosis of optic neuritis. *JAMA Ophthalmol* 2018; **136**: 76–81.
- 17 Stunkel L, Newman NJ, Biousse V. Diagnostic error and neuro-ophthalmology. *Curr Opin Neurol* 2019; **32**: 62–67.
- 18 Hickman S, Dalton C, Miller D, Plant G. Management of acute optic neuritis. *Lancet* 2002; **360**: 1953–62.
- 19 Balcer LJ. Clinical practice. Optic neuritis. *N Engl J Med* 2006; **354**: 1273–80.
- 20 Petzold A, Plant GT. Chronic relapsing inflammatory optic neuropathy: a systematic review of 122 cases reported. *J Neurol* 2014; **261**: 17–26.
- 21 Bennett JL, Costello F, Chen JJ, et al. Optic neuritis and autoimmune optic neuropathies: advances in diagnosis and treatment. *Lancet Neurology* 2022; published online Sept 22, 2022 [https://doi.org/10.1016/S1474-4422\(22\)00187-9](https://doi.org/10.1016/S1474-4422(22)00187-9)
- 22 Petzold A. Applying the 2017 McDonald diagnostic criteria for multiple sclerosis. *Lancet Neurol* 2018; **17**: 496–97.
- 23 Toosy AT, Mason DF, Miller DH. Optic neuritis. *Lancet Neurol* 2014; **13**: 83–99.
- 24 Petzold A, Wattjes MP, Costello F, et al. The investigation of acute optic neuritis: a review and proposed protocol. *Nat Rev Neurol* 2014; **10**: 447–58.
- 25 Teunissen CE, Petzold A, Bennett JL, et al. A consensus protocol for the standardization of cerebrospinal fluid collection and biobanking. *Neurology* 2009; **73**: 1914–22.
- 26 Goldschmidt C, McGinley MP. Advances in the treatment of multiple sclerosis. *Neurol Clin* 2021; **39**: 21–33.
- 27 Petzold A, Albrecht P, Balcer L, et al. Artificial intelligence extension of the OSCAR-IB criteria. *Ann Clin Transl Neurol* 2021; **8**: 1528–42.
- 28 Petzold A, Wong S, Plant GT. Autoimmunity in visual loss. *Handb Clin Neurol* 2016; **133**: 353–76.
- 29 Keltner JL, Johnson CA, Cello KE, et al. Visual field profile of optic neuritis: a final follow-up report from the optic neuritis treatment trial from baseline through 15 years. *Arch Ophthalmol* 2010; **128**: 330–37.
- 30 Thompson AJ, Montalban X, Barkhof F, et al. Diagnostic criteria for primary progressive multiple sclerosis: A position paper. *Ann Neurol* 2000; **47**: 831–35.
- 31 Wingerchuk DM, Banwell B, Bennett JL, et al. International consensus diagnostic criteria for neuromyelitis optica spectrum disorders. *Neurology* 2015; **85**: 177–89.
- 32 Matiello M, Lennon VA, Jacob A, et al. NMO-IgG predicts the outcome of recurrent optic neuritis. *Neurology* 2008; **70**: 2197–200.
- 33 Marignier R, Hacohen Y, Cobo-Calvo A, et al. Myelin-oligodendrocyte glycoprotein antibody-associated disease. *Lancet Neurol* 2021; **20**: 762–72.
- 34 Boehm MRR, Oellers P, Thanos S. Inflammation and immunology of the vitreoretinal compartment. *Inflamm Allergy Drug Targets* 2011; **10**: 283–309.
- 35 Haas J, Bekeredjian-Ding I, Milkova M, et al. B cells undergo unique compartmentalized redistribution in multiple sclerosis. *J Autoimmun* 2011; **37**: 289–99.
- 36 Machado-Santos J, Saji E, Tröscher AR, et al. The compartmentalized inflammatory response in the multiple sclerosis brain is composed of tissue-resident CD8 T lymphocytes and B cells. *Brain* 2018; **141**: 2066–82.
- 37 Biousse V, Newman NJ. Diagnosis and clinical features of common optic neuropathies. *Lancet Neurol* 2016; **15**: 1355–67.
- 38 Dubey D, Lennon VA, Gadoth A, et al. Autoimmune CRMP5 neuropathy phenotype and outcome defined from 105 cases. *Neurology* 2017; **90**: e103–10.
- 39 Wattjes MP, Ciccarelli O, Reich DS, et al. 2021 MAGNIMS-CMSC-NAIMS consensus recommendations on the use of MRI in patients with multiple sclerosis. *Lancet Neurol* 2021; **20**: 653–70.
- 40 Denève M, Biotti D, Patsoura S, et al. MRI features of demyelinating disease associated with anti-MOG antibodies in adults. *J Neuroradiol* 2019; **46**: 312–18.
- 41 The Lancet. GBD 2015: From big data to meaningful change. *Lancet* 2016; **388**: 1447.
- 42 Petzold A, Islam N, Hu H-H, Plant GT. Embolic and nonembolic transient monocular visual field loss: a clinicopathologic review. *Surv Ophthalmol* 2013; **58**: 42–62.
- 43 Alvarez LM, Neo YN, Davagnanam I, et al. Post vaccination optic neuritis: observations from the SARS-CoV-2 pandemic. *SSRN* 2021.
- 44 Fujii K, Suyama M, Chiba K, Okunishi T, Oikawa J, Kohno Y. Acute disseminated encephalomyelitis following 2009 H1N1 influenza vaccine. *Pediatr Int* 2012; **54**: 539–41.
- 45 Schumacher G, Beebe G, Kebler R, et al. Problems of experimental trials of therapy in multiple sclerosis. *Ann N Y Acad Sci* 1965; **122**: 552–68.
- 46 Poser CM, Paty DW, Scheinberg L, et al. New diagnostic criteria for multiple sclerosis: guidelines for research protocols. *Ann Neurol* 1983; **13**: 227–31.
- 47 McDonald WI, Compston A, Edan G, et al. Recommended diagnostic criteria for multiple sclerosis: Guidelines from the international panel on the diagnosis of multiple sclerosis. *Ann Neurol* 2001; **50**: 121–27.
- 48 Thompson AJ, Banwell BL, Barkhof F, et al. Diagnosis of multiple sclerosis: 2017 revisions of the McDonald criteria. *Lancet Neurol* 2018; **17**: 162–73.
- 49 Reindl M, Di Pauli F, Rostásy K, Berger T. The spectrum of MOG autoantibody-associated demyelinating diseases. *Nat Rev Neurol* 2013; **9**: 455–61.
- 50 Cobo-Calvo Álvaro, d'Indy H, Ruiz A, et al. Frequency of myelin oligodendrocyte glycoprotein antibody in multiple sclerosis. *Neurol Neuroimmunol Neuroinflamm* 2019; **7**: e649.
- 51 Papp V, Magyari M, Aktas O, et al. Worldwide incidence and prevalence of neuromyelitis optica: a systematic review. *Neurology* 2021; **96**: 59–77.
- 52 Beck RW, Cleary PA, Anderson M Jr, et al. A randomized, controlled trial of corticosteroids in the treatment of acute optic neuritis. The optic neuritis study group. *N Engl J Med* 1992; **326**: 581–88.
- 53 Hickman SJ. Optic perineuritis. *Curr Neurol Neurosci Rep* 2016; **16**: 16.
- 54 Coppens S, Petzold A, de Graaf P, de Vries-Knoppert WAEJ. Recurrent optic perineuritis after intranasal cocaine abuse. *Neuroophthalmology* 2014; **38**: 91–95.
- 55 Petzold A, de Boer JF, Schippling S, et al. Optical coherence tomography in multiple sclerosis: a systematic review and meta-analysis. *Lancet Neurol* 2010; **9**: 921–32.
- 56 Gass JD. Diseases of the optic nerve that may simulate macular disease. *Trans Sect Ophthalmol Am Acad Ophthalmol Otolaryngol* 1977; **83**: 763–70.
- 57 Kidd D, Burton B, Plant G, Graham E. Chronic relapsing inflammatory optic neuropathy (CRION). *Brain* 2003; **126**: 276–84.
- 58 Petzold A, Coric D, Balk LJ, et al. Longitudinal development of peripapillary hyper-reflective ovoid masslike structures suggests a novel pathological pathway in multiple sclerosis. *Ann Neurol* 2020; **88**: 309–19.
- 59 Waters P, Reindl M, Saiz A, et al. Multicentre comparison of a diagnostic assay: aquaporin-4 antibodies in neuromyelitis optica. *J Neurol Neurosurg Psychiatry* 2016; **87**: 1005–15.
- 60 Bruijstens AL, Breu M, Wendel E-M, et al. E.u. Paediatric MOG consortium consensus: part 4 outcome of paediatric myelin oligodendrocyte glycoprotein antibody-associated disorders. *Eur J Paediatr Neurol* 2020; **29**: 32–40.
- 61 Kleerekooper I, Herbert MK, Kuiperij HB, et al. CSF levels of glutamine synthetase and GFAP to explore astrocytic damage in seronegative NMOSD. *J Neurol Neurosurg Psychiatry* 2020; **91**: 605–11.
- 62 Kuhle J, Kropshofer H, Haering DA, et al. Blood neurofilament light chain as a biomarker of MS disease activity and treatment response. *Neurology* 2019; **92**: e1007–15.
- 63 Petzold A, Rejdak K, Plant G. Axonal degeneration and inflammation in acute optic neuritis. *J Neurol Neurosurg Psychiatry* 2004; **75**: 1178–80.

- 64 Petzold A, Braithwaite T, van Oosten BW, et al. Case for a new corticosteroid treatment trial in optic neuritis: review of updated evidence. *J Neurol Neurosurg Psychiatry* 2019; **91**: 9–14.
- 65 Jindahra P, Phuphuakrat A, Tangjaisanong T, et al. Clinical characteristics of HIV-associated optic neuritis. *Int Med Case Rep J* 2020; **13**: 609–16.
- 66 Hamann S, Zeuthen T, La Cour M, et al. Aquaporins in complex tissues: distribution of aquaporins 1-5 in human and rat eye. *Am J Physiol* 1998; **274**: C1332–45.
- 67 Pittock SJ, Weinschenker BG, Lucchinetti CF, Wingerchuk DM, Corboy JR, Lennon VA. Neuromyelitis optica brain lesions localized at sites of high aquaporin 4 expression. *Arch Neurol* 2006; **63**: 964–68.
- 68 Jarius S, Frederikson J, Waters P, et al. Frequency and prognostic impact of antibodies to aquaporin-4 in patients with optic neuritis. *J Neurol Sci* 2010; **298**: 158–62.
- 69 Stadelmann C, Timmler S, Barrantes-Freer A, Simons M. Myelin in the central nervous system: structure, function, and pathology. *Physiol Rev* 2019; **99**: 1381–431.
- 70 Charrier E, Reibel S, Rogemond V, Aguera M, Thomasset N, Honnorat J. Collapsin response mediator proteins (CRMPs): involvement in nervous system development and adult neurodegenerative disorders. *Mol Neurobiol* 2003; **28**: 51–64.
- 71 Petzold A. Intrathecal oligoclonal IgG synthesis in multiple sclerosis. *J Neuroimmunol* 2013; **262**: 1–10.
- 72 Stangel M, Fredrikson S, Meinl E, Petzold A, Stüve O, Tumani H. The utility of cerebrospinal fluid analysis in patients with multiple sclerosis. *Nat Rev Neurol* 2013; **9**: 267–76.
- 73 Petzold A, Junemann A, Rejdak K, et al. A novel biomarker for retinal degeneration: Vitreous body neurofilament proteins. *J Neural Transm* 2009; **116**: 1601–06.
- 74 Khalil M, Teunissen CE, Otto M, et al. Neurofilaments as biomarkers in neurological disorders. *Nature Reviews Neurol* 2018; **14**: 577–89.
- 75 Benkert P, Meier S, Schaedelin S, et al. Serum neurofilament light chain for individual prognostication of disease activity in people with multiple sclerosis: A retrospective modelling and validation study. *Lancet Neurol* 2022; **21**: 246–57.
- 76 Storoni M, Verbeek MM, Illes Z, et al. Serum GFAP levels in optic neuropathies. *J Neurol Sci* 2012; **317**: 117–22.
- 77 Abdelhak A, Foschi M, Abu-Rumeileh S, et al. Blood GFAP as an emerging biomarker in brain and spinal cord disorders. *Nat Rev Neurol* 2022; **18**: 158–72.
- 78 Akaishi T, Takeshita T, Himori N, et al. Rapid administration of high-dose intravenous methylprednisolone improves visual outcomes after optic neuritis in patients with AQP4-IgG-positive NMOSD. *Front Neurol* 2020; **11**: 932.
- 79 Osinga E, van Oosten B, de Vries-Knoppert W, Petzold A. Time is vision in recurrent optic neuritis. *Brain Res* 2017; **1673**: 95–101.
- 80 Stiebel-Kalish H, Hellmann MA, Mimouni M, et al. Does time equal vision in the acute treatment of a cohort of AQP4 and MOG optic neuritis? *Neurol Neuroimmunol Neuroinflamm* 2019; **6**: e572.
- 81 Shor N, Deschamps R, Calvo AC, et al. MRI characteristics of MOG-ab associated disease in adults: an update. *Rev Neurol* 2021; **177**: 39–50.
- 82 Asseyer S, Hamblin J, Messina S, et al. Prodromal headache in MOG-antibody positive optic neuritis. *Mult Scler Relat Disord* 2020; **40**: 101965.
- 83 Fraser CL, Davagnanam I, Radon M, Plant GT. The time course and phenotype of Uhthoff phenomenon following optic neuritis. *Mult Scler* 2012; **18**: 1042–44.
- 84 Frohman TC, Davis SL, Beh S, Greenberg BM, Remington G, Frohman EM. Uhthoffs phenomena in MS clinical features and pathophysiology. *Nat Rev Neurol* 2013; **9**: 535–40.
- 85 Sobhanian MJ, Agarwal R, Meltzer E, et al. Identification and treatment of the visual processing asymmetry in MS patients with optic neuritis: the Pulfrich phenomenon. *J Neurol Sci* 2018; **387**: 60–69.
- 86 Farr J, McGarva E, Bijvank JN, et al. The Pulfrich phenomenon: practical implications of the assessment of cases and effectiveness of treatment. *Neuroophthalmology* 2018; **42**: 349–55.
- 87 Serra A, Petzold A. Can stability of visual fixation be a measure for disability in multiple sclerosis? *Mult Scler* 2020; **26**: 264–65.
- 88 Plant GT, Sibtan NA, Thomas D. Hyperacute corticosteroid treatment of optic neuritis at the onset of pain may prevent visual loss: a case series. *Mult Scler Int* 2011; **2011**: 815068.
- 89 Kleiter I, Gahlen A, Borisow N, et al. Apheresis therapies for NMOSD attacks. *Neurol Neuroimmunol Neuroinflamm* 2018; **5**: e504.
- 90 Steelman AJ. Infection as an environmental trigger of multiple sclerosis disease exacerbation. *Front Immunol* 2015; **6**: 520.
- 91 Marrodan M, Alessandro L, Farez MF, Correale J. The role of infections in multiple sclerosis. *Mult Scler* 2019; **25**: 891–901.
- 92 Hood L, Flores M. A personal view on systems medicine and the emergence of proactive P4 medicine: predictive, preventive, personalized and participatory. *N Biotechnol* 2012; **29**: 613–24.
- 93 Ashworth B. Chronic retrobulbar and chiasmal neuritis. *Br J Ophthalmol* 1967; **51**: 698.
- 94 Miller DH, Newton MR, van der Poel JC, et al. Magnetic resonance imaging of the optic nerve in optic neuritis. *Neurology* 1988; **38**: 175–79.
- 95 Hadhoum N, Hodel J, Defoort-Dhellemmes S, et al. Length of optic nerve double inversion recovery hypersignal is associated with retinal axonal loss. *Mult Scler* 2015; **22**: 649–58.
- 96 Healy GM, Redmond CE, Gaughan M, et al. The accuracy of standard multiple sclerosis MRI brain sequences for the diagnosis of optic neuropathy. *Mult Scler Relat Disord* 2020; **38**: 101521.
- 97 Davion J-B, Lopes R, Drumez É, et al. Asymptomatic optic nerve lesions: an underestimated cause of silent retinal atrophy in MS. *Neurology* 2020; **94**: e2468–78.
- 98 Soelberg K, Specovius S, Zimmermann HG, et al. Optical coherence tomography in acute optic neuritis: a population-based study. *Acta Neurol Scand* 2018; **138**: 566–73.
- 99 Coric D, Balk LJ, Uitdehaag BMJ, Petzold A. Diagnostic accuracy of optical coherence tomography inter-eye percentage difference (IEPD) for optic neuritis in multiple sclerosis. *Eur J Neurol* 2017; **24**: 1479–84.
- 100 Nolan-Kenney RC, Liu M, Akhand O, et al. Optimal intereye difference thresholds by optical coherence tomography in multiple sclerosis: an international study. *Ann Neurol* 2019; **85**: 618–29.
- 101 Bsteh G, Hegen H, Altmann P, et al. Validation of inter-eye difference thresholds in optical coherence tomography for identification of optic neuritis in multiple sclerosis. *Mult Scler Relat Disord* 2020; **45**: 102403.
- 102 London F, Zéphir H, Drumez E, et al. Optical coherence tomography: a window to the optic nerve in clinically isolated syndrome. *Brain* 2019; **142**: 903–15.
- 103 Xu SC, Kardon RH, Leavitt JA, Flanagan EP, Pittock SJ, Chen JJ. Optical coherence tomography is highly sensitive in detecting prior optic neuritis. *Neurology* 2019; **92**: e527–35.
- 104 Petzold A, Chua SYL, Khawaja AP, et al. Retinal asymmetry in multiple sclerosis. *Brain* 2020; **144**: 224–35.
- 105 Gelfand JM, Nolan R, Schwartz DM, Graves J, Green AJ. Microcystic macular oedema in multiple sclerosis is associated with disease severity. *Brain* 2012; **135**: 1786–93.
- 106 Gelfand JM, Cree BA, Nolan R, Arnov S, Green AJ. Microcystic inner nuclear layer abnormalities and neuromyelitis optica. *JAMA Neurol* 2013; **70**: 1–5.
- 107 Balk LJ, Killestein J, Polman CH, Uitdehaag BMJ, Petzold A. Microcystic macular oedema confirmed, but not specific for multiple sclerosis. *Brain* 2012; **135**: e226.
- 108 Balk LJ, Coric D, Knier B, et al. Retinal inner nuclear layer volume reflects inflammatory disease activity in multiple sclerosis: a longitudinal OCT study. *Mult Scler J Exp Transl Clin* 2019; **5**: 2055217319871582.
- 109 Kisimbi J, Shalchi Z, Mahroo OA, et al. Macular spectral domain optical coherence tomography findings in Tanzanian endemic optic neuropathy. *Brain* 2013; **136**: 3418–26.
- 110 Barboni P, Carelli V, Savini G, Carbonelli M, La Morgia C, Sadun AA. Microcystic macular degeneration from optic neuropathy: not inflammatory, not trans-synaptic degeneration. *Brain* 2013; **136**: e239.
- 111 Oertel FC, Specovius S, Zimmermann HG, et al. Retinal optical coherence tomography in neuromyelitis optica. *Neurol Neuroimmunol Neuroinflamm* 2021; **8**: e1068.
- 112 Petzold A. Three 'red lines' for pattern recognition-based differential diagnosis using optical coherence tomography in clinical practice. *J Neuroophthalmol* 2021; **41**: 385–98.

- 113 Sinnecker T, Oberwahrenbrock T, Metz I, et al. Optic radiation damage in multiple sclerosis is associated with visual dysfunction and retinal thinning - an ultrahigh-field MR pilot study. *Eur Radiol* 2014; **25**: 122–31.
- 114 Wagner S, Hughes F, Cortina Borja M, et al. AlzEye: longitudinal record-level linkage of ophthalmic imaging and hospital admissions of 1 353 157 patients in London, UK. *BMJ Open* 2022; **12**: e058552.
- 115 Tewarie P, Balk L, Costello F, et al. The OSCAR-IB consensus criteria for retinal OCT quality assessment. *PLoS One* 2012; **7**: e34823.
- 116 Aytulun A, Cruz-Herranz A, Aktas O, et al. The APOSTEL 2.0 recommendations for reporting quantitative optical coherence tomography studies. *Neurology* 2021; **97**: 68–79.
- 117 Green AJ, Gelfand JM, Cree BA, et al. Clemastine fumarate as a remyelinating therapy for multiple sclerosis (ReBUILD): a randomised, controlled, double-blind, crossover trial. *Lancet* 2017; **390**: 2481–89.
- 118 Morrow SA, Fraser JA, Day C, et al. Effect of treating acute optic neuritis with bioequivalent oral vs intravenous corticosteroids: a randomized clinical trial. *JAMA Neurol* 2018; **75**: 690.
- 119 Bonnan M, Valentino R, Debeugny S, et al. Short delay to initiate plasma exchange is the strongest predictor of outcome in severe attacks of NMO spectrum disorders. *J Neurol Neurosurg Psychiatry* 2017; **89**: 346–51.

Copyright © 2022 Published by Elsevier Ltd. All rights reserved.