

Empty nose syndrome pathogenesis and cell-based biotechnology products as a new option for treatment

Inna M Gordiienko, Olga S Gubar, Roman Sulik, Taras Kunakh, Igor Zlatskiy, Alona Zlatska

ORCID number: Inna M Gordiienko [0000-0003-3759-6138](https://orcid.org/0000-0003-3759-6138); Olga S Gubar [0000-0001-5224-7118](https://orcid.org/0000-0001-5224-7118); Roman Sulik [0000-0003-1519-3979](https://orcid.org/0000-0003-1519-3979); Taras Kunakh [0000-0003-1008-4685](https://orcid.org/0000-0003-1008-4685); Igor Zlatskiy [0000-0001-7114-4691](https://orcid.org/0000-0001-7114-4691); Alona Zlatska [0000-0002-5834-2834](https://orcid.org/0000-0002-5834-2834).

Author contributions: All authors contributed equally to this work.

Conflict-of-interest statement:

Authors declare no conflict of interests for this article.

Open-Access: This article is an open-access article that was selected by an in-house editor and fully peer-reviewed by external reviewers. It is distributed in accordance with the Creative Commons Attribution NonCommercial (CC BY-NC 4.0) license, which permits others to distribute, remix, adapt, build upon this work non-commercially, and license their derivative works on different terms, provided the original work is properly cited and the use is non-commercial. See: <http://creativecommons.org/licenses/by-nc/4.0/>

Manuscript source: Invited manuscript

Specialty type: Cell biology

Country/Territory of origin: Ukraine

Peer-review report's scientific

Inna M Gordiienko, Roman Sulik, Taras Kunakh, Alona Zlatska, Biotechnology Laboratory, Medical Company “Good Cells”, Kyiv 03115, Ukraine

Inna M Gordiienko, R.E. Kavetsky Institute of Experimental Pathology, Oncology and Radiobiology NAS of Ukraine, Kyiv 03022, Ukraine

Olga S Gubar, Institute of Molecular Biology and Genetics NAS of Ukraine, Kyiv 03143, Ukraine

Igor Zlatskiy, Alona Zlatska, State Institute of Genetic and Regenerative Medicine, National Academy of Medical Sciences of Ukraine, Kyiv 04114, Ukraine

Corresponding author: Igor Zlatskiy, PhD, Senior Researcher, State Institute of Genetic and Regenerative Medicine, National Academy of Medical Sciences of Ukraine, Vyshgorodskaja Street, 67, Kyiv 04114, Ukraine. zlatskiy@ukr.net

Abstract

Empty nose syndrome (ENS) is a rare complication that develops after partial or complete turbinectomy. The main feature of ENS is paradoxical nasal obstruction feeling despite objectively wide nasal airway. ENS pathogenesis is multifactorial and includes changes in laminar physiological airflow, disruption of mucosa functions and deficient neural sensation. This leads to the development of ENS symptomatology such as dyspnea, nasal dryness, nasal burning, nasal obstruction, feeling of suffocation and even comorbid psychiatric disorders that significantly impairs life quality. Specific effective treatment of ENS does not exist up to date. In this review we outline existing biomaterial for surgical reconstitution of nasal anatomy and discuss the perspective of stem cell-based technologies in ENS management. The main focus is directed to justification of rationality application of adult mesenchymal stem cells (MSCs) from different tissues origin and neural crest-derived stem cells (NCSCs) based on their intrinsic biological properties. MSCs transplantation may stimulate mucosa tissue regeneration *via* trophic factors secretion, direct transdifferentiation into epithelial cells and pronounced immunosuppressive effect. From the other hand, NCSCs based on their high neuroprotective properties may reconstitute nerve structure and functioning leading to normal sensation in ENS patients. We postulate that application of cell-based and tissue-engineered products can help to significantly improve ENS symptomatology only as complex approach aimed at reconstitution of nasal anatomy, recovery the nasal mucosa functionality and neural tissue sensation.

quality classification

Grade A (Excellent): 0
 Grade B (Very good): B, B
 Grade C (Good): 0
 Grade D (Fair): 0
 Grade E (Poor): 0

Received: February 28, 2021

Peer-review started: February 28, 2021

First decision: April 19, 2021

Revised: April 29, 2021

Accepted: August 13, 2021

Article in press: August 13, 2021

Published online: September 26, 2021

P-Reviewer: Gong N, Salzano FA

S-Editor: Wang JL

L-Editor: A

P-Editor: Xing YX



Key Words: Empty nose syndrome; Stem-cell-based technologies; Implants biomaterials; Grafts; Hydrogels; Mesenchymal stem cells

©The Author(s) 2021. Published by Baishideng Publishing Group Inc. All rights reserved.

Core Tip: Empty nose syndrome is a complex disease, which pathogenesis is associated not only with changes in the architecture of the nasal passages, but also with changes in the receptor status of the nasal mucosa and disorders of perception of external stimuli at the systemic level. Due to the lack of effective conventional protocols for the treatment of this disease, there is a need to find new approaches to restoring the normal structure of the architecture of the nasal passages and return the functionality of the nasal mucosa. In addition, the proposed methods should be minimally invasive, implemented by injection. The advancement of regenerative medicine and biotechnology contributes to the development of new cell-based products in combination with various materials, which in the future will be able to help develop protocols for treatment patients with empty nose syndrome.

Citation: Gordiienko IM, Gubar OS, Sulik R, Kunakh T, Zlatskiy I, Zlatska A. Empty nose syndrome pathogenesis and cell-based biotechnology products as a new option for treatment. *World J Stem Cells* 2021; 13(9): 1293-1306

URL: <https://www.wjgnet.com/1948-0210/full/v13/i9/1293.htm>

DOI: <https://dx.doi.org/10.4252/wjsc.v13.i9.1293>

INTRODUCTION

For the first time, the term "empty nose syndrome" (ENS) was introduced into medical practice by E. Kern and M. Stenkvis in 1994 to describe empty space in the place of inferior and middle turbinate on computed tomography in patients who had partial or total turbinectomy[1]. Today, ENS can be defined as a rare rhinological disease developed as complication of turbinate surgery and characterized by paradoxical obstruction feeling despite an objectively broad nasal airway[2]. ENS symptoms development is usually delayed, from months to years postoperatively, and the symptoms severity is not strictly dependent on the resected tissue volume[3]. ENS frequency is not known exactly, several studies reported about 8%-22% ENS occurrence rate in patients who have undergone turbinate resection[4]. Submucosal cautery, submucosal resection, laser therapy, and cryosurgery can also lead to ENS development if performed in an overly aggressive manner[5]. Existing methods of ENS diagnostics and treatment have some drawbacks as ENS pathogenesis is not fully understood. In this review we focus on the latest concept of ENS pathogenesis and discuss cell-based technologies as new therapeutic option for ENS management.

ETIOLOGY AND PATHOGENESIS

ENS is divided into at least four subtypes depending on the turbinate resected: ENS inferior turbinate (ENS-IT), ENS middle turbinate (ENS-MT), and ENS-both, which means both the inferior and middle turbinates removal; and ENS after turbinate-sparing procedures (ENS-type)[6]. ENS-IT is the most common type[7]. Patients with ENS frequently report symptoms of dyspnea, nasal dryness, nasal burning, nasal obstruction, and feelings of suffocation. Other symptoms may be sensation of excessive airflow; lack of sensation of nasal airflow; hypersensitivity to cold air; dyspnea (also paradoxical), breathlessness, hyperventilation; nasal pain of variable, sometimes pseudoneuralgic, types; headache; nasal and pharyngeal dryness; difficulty falling asleep, general fatigue (Figure 1)[8]. Anxiety, depression, loss of productivity are main psychological symptoms of ENS[9]. Depression was reported in 71 % of ENS patients, but there was no correlation between nasal cavity volume and depression severity[10]. ENS diagnosis is mainly based on the patient's subjective symptoms since no reliable objective tests exist. This makes ENS diagnostics and treatment effectivity

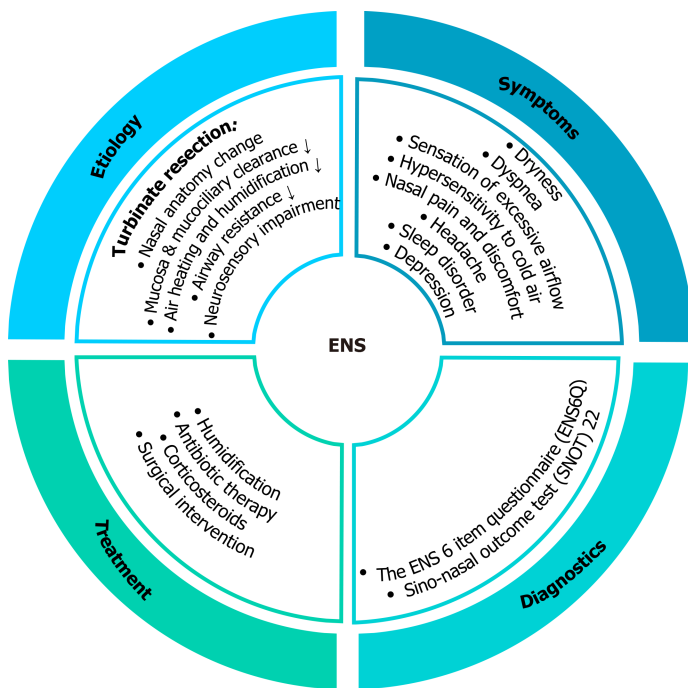


Figure 1 Empty nose syndrome: Causes, symptoms, diagnostics and current treatment strategy. ENS: Empty nose syndrome.

evaluation very challenging.

The nasal patency depends on adequate mucosa cooling and appropriate number of functioning TRPM8 (transient receptor potential cation channel subfamily M member 8) thermoreceptors[11]. In case of ENS, turbinate resection leads to reducing general nasal surface area causing changes in laminar airflow characteristics. The mucosa reduction leads to decreasing in number of TRPM8 receptors and violation of inspired air heating and humidification due to increased nasal cavity, reduced contact between air and mucosa, and the lowered nasal airway resistance[12]. Complete removal of the inferior turbinate can reduce heating and humidity by 23%[2]. This leads to increased mucosa heating as a compensatory mechanism. Consequently, effective mucosal cooling does not occur and TRPM8 is not activated causing restricted signaling to respiratory center which is misinterpreted as obstruction or apnea, and, in turn, leads to increased breathing efforts. It is important to note that resection of inferior turbinate is associated with higher risk of ENS development than middle turbinate removal. Thus it is recommended to preserve at least 50% of inferior turbinate during any surgical procedure that allows to save sufficient mucosa and keep moderate nasal volume essential for normal airflow and in this way minimize ENS occurrence[13].

Reduction of mucosal tissue after surgery causes significant compensatory structure changes that result in squamous metaplasia, a higher rate of submucosal fibrosis, goblet cell metaplasia and lower number of submucosal glands in ENS patients. However, in some cases, normal respiratory epithelium similar to atrophic rhinitis and absence of inflammation can be preserved[14].

Taking together, ENS pathogenesis is multifactorial including changes in anatomical turbinate structure, disruption of normal nasal mucosa function and neural sensation deficiency.

CURRENT MANAGEMENT STRATEGY

Taking into consideration the polygenic pathophysiology of ENS, the effective treatment strategy should be complex and overcome the three main challenges: (1) Reconstitute the nasal anatomical structure that will allow the nasal airway resistance increasing; (2) Recover damaged nasal mucosa that will result in edema decreasing, normalizing air heating and humidifying; and (3) Stimulate nerve recovery and renew tissue sensitivity.

The arsenal of conservative ENS treatment methods is limited today to measures that increase humidification (nasal saline irrigation, nasal saline sprays, moisturizing agents, and humidifiers), local antibiotics and corticosteroids application (Figure 1)[2].

Psychological symptoms in ENS patients could be successfully treated by inhibitors of serotonin and norepinephrine reuptake inhibitors or cognitive behavior therapy[15]. The main goal of surgical techniques in ENS treatment is to reconstitute anatomical structure of nasal cavity to restore physiological airflow. Positioning an implant on the septum, floor or lateral wall is a basic principle in ENS surgery[8]. Unfortunately, the results of surgery with different types of biomaterial implantation are not unambiguous and require further investigation and improvements.

OVERVIEW OF IMPLANT MATERIALS

What type of implant could be used for nasal cavity reconstitution? Synthetic or natural materials that are used in medicine to treat, augment or replace tissues and organs are called biomaterials[16]. Biomaterials could be used for implant construction or as a scaffold for stem cells seeding to replace damaged tissue[17]. Physical and chemical properties of biomaterials are varied, but their medicine application imposes certain requirements as biocompatibility, biofunctionality, biodegradation, bioresorbability, non-toxicity. Namely, save and maximally effective biomaterial should safely integrate with host cells and tissue without any adverse effects, its mechanical properties should correspond to those of replaced part of the body, it should not produce any toxic compounds from the surface, pores or during degradation[18]. The most common synthetic biomaterials that are used in tissue engineering are synthetic polymers, which include relatively hydrophobic materials such as the α -hydroxy acids, polyanhydrides, and others[19]. However, synthetic biomaterials have some disadvantages since their composition and structure differ significantly from tissues/organ nature, so their ability to induce tissue remodeling is low[20]. Collagen, gelatin, silk, cellulose, chitin/chitosan, decellularized dermal matrix are examples of natural biomaterials that are widely used as instruments of regenerative medicine.

Not all implant materials can be used to repair empty nose syndrome. From one side biomaterial should be inert, have good biocompatibility, compact and dense enough to avoid extrusion or shrinkage, keep shape well, should not induce inflammation and rejection[21]. The most common biomaterials used in surgical inferior turbinate reconstruction in ENS patients are porous polyethylene (Medpor), cartilage, and acellular dermis (Alloderm)[22].

Commercialized porous polyethylene (Medpor) is an alloplastic biomaterial, medical-grade, high density polyethylene in the form of a flexible framework of interconnecting pores[23]. Pore size in Medpor is more than 150 μm in diameter that allows host tissues, blood vessels, and nerve ingrowth, together with collagen deposition thus forming stable complex which reconstitutes absent part of tissue/organ. Submucosal implantation of Medpor to the ENS patients showed optimistic results. All studies described significant improvement based on SNOT (sino-nasal outcome test) score, level of depression and anxiety symptoms (Table 1)[14,24-28]. The results of Medpor transplantation were stable at least one year after surgery[14,24-27]. Huang *et al*[14] noted absence of nasal crusting and facial pain/pressure improvement after Medpor transplantation. At the same time, a serious drawback of Medpor was partial implant extrusion in some patients 6 mo after surgery[24,25]. Besides, it was reported that chronic atrophic rhinitis has been developed in 1 from 16 patients 4 years after Medpor implantation[25].

The conchal cartilage implantation for turbinate reconstitution may provide the best resistance to infection and a low degree of resorption compared to synthetic biomaterial[29]. From the other hand, usage of autologous cartilage requires additional surgery that is traumatic and results in longer post-operative period. Submucoperiosteal implantation of autologous conchal cartilage into lateral nasal wall showed significant decreasing of SNOT-25 score and good mucosal healing in ENS patients for up to 12 mo[30]. However, difficulties in autologous conchal cartilage harvesting and restricted data about its effectivity after implantation limit conchal cartilage usage for ENS treatment.

Another popular defect reconstitution material in ENS is Alloderm[®], a cell-free dermal allograft comprised of structurally integrated basement membrane complex and extracellular matrix in which collagen bundles and elastic fibers are the main components[21]. Since alien cells are not present in Alloderm, it does not cause inflammation and immune rejection compared to other allografts. Alloderm implantation showed improvement of ENS patients' symptoms based on SNOT-20/25 score[5,31,32]. However, similar to Medpor implant, Alloderm showed partial extrusion in some cases. Besides, it is subject to shrinkage in time. Taken together, these are significant

Table 1 Comparative analysis of existing empty nose syndrome treatment approaches, clinical results

No.	No. of patients	Type of study	Material used for transplantation (implant material?)	Treatment details	ENS score before surgical intervention	ENS score after surgical intervention	Other effects	Complications, undesired effects	Follow-up time	Ref.
1	19	Prospective self-controlled study	Porous polyethylene (Medpor)	Submucosal implantation into the inferior turbinate and (or) lateral nasal wall and (or) nasal septum opposite the nasal concha	50.1 ± 18.7 (SNOT-20)	22.6 ± 15.8 (3 mo; $P = 0.037$); 20.4 ± 18.9 (6 mo; $P = 0.007$); 37.7 ± 7.6 (12 mo; $P = 0.736$) (SNOT-20)	Improvements of nasal resistance, nasal volume, and minimum cross-sectional area ($P < 0.05$) (CT, acoustic rhinometry); mucociliary clearance improved non-significantly	Partial implant extrusion in one patient at 6 mo follow-up	3-18 mo	[24]
2	16	Retrospective clinical study	Porous polyethylene (Medpor)	Submucosal implantation mainly in septum and nasal floor, unilaterally or bilaterally	39.25 ± 21.44 (SNOT-22)	19.81 ± 16.17 (3 mo, $P < 0.05$); 16.19 ± 13.98 (1 yr, $P < 0.05$) (SNOT-22)	Not evaluated	Chronic hypertrophic rhinitis in 1 patient 4 yr after implantation. Implant protrusion in 1 patient 6 mo after surgery	3 mo-1 yr	[25]
3	13	Prospective cohort study in a tertiary medical center	Porous polyethylene (Medpor)	Submucosal implantation into nasal floor	19 (BAI); 24.4 (BDI-II)	6.8 (BAI); 6.25 (BDI-II)	Mucosa covering the graft was smooth and intact on the lateral nasal wall (endoscopy)	Not reported	1 yr	[26]
4	14	Retrospective study in a tertiary medical center	Porous polyethylene (Medpor)	Inferior nasal wall submucosal implantation	40.7 ± 23.4 (SNOT-22); 22.6 ± 27.0 (BDI-II); 13.8 ± 19.5 (BAI)	21.1 ($P = 0.002$) (SNOT-22); BDI-II decrease ($P = 0.031$); BAI decrease ($P = 0.004$)	Not evaluated	Not reported	1 yr	[27]
5	18 (16 followed-up)	Retrospective study in a tertiary medical center	Porous polyethylene (Medpor)	Lateral nasal wall submucosal implantation	49.3 ± 20.5 (SNOT-22); 20.5 ± 15.1 (BDI-II); 20.1 ± 15.2 (BAI)	11.8 ($P < 0.001$) (SNOT-22); BDI-II decrease ($P < 0.001$); BAI decrease ($P < 0.001$)	Not evaluated	Not reported	1 yr	[27]
6	68 (39 followed-up)	Prospective clinical study	Porous polyethylene (Medpor)	Submucosal implantation into the nasal floor or lateral wall	62.9 ± 25.3 (SNOT-25); 19.3 ± 15.0 (BDI-II); 17.7 ± 12.9 (BAI)	35.5 ± 24.4 ($P < 0.001$) (SNOT-25); 8.4 ± 10.1 ($P < 0.001$) (BDI-II); 10.5 ± 11.5 ($P < 0.001$) (BAI)	Not evaluated	Not improved nasal crusting and facial pain/pressure	6 mo	[28]
7	54 (46-38 followed-up)	Prospective case series in a tertiary medical center	Porous polyethylene (Medpor)	Submucosal implantation into the nasal floor or lateral wall	64.9 ± 24.7 (SNOT-25); 20.7 ± 15.3 (BDI-II); 19.8 ± 13.3 (BAI)	32.9 ± 20.7 (3 mo); 30.2 ± 22.9 (6 mo); 29.1 ± 23.8 (12 mo); ($P < 0.01$) (SNOT-25); 8.2 ± 11.2 (3 mo); 8.0 ± 9.8 (6 mo); 7.8 ± 10.7 (12 mo); ($P < 0.01$) (BDI-II); 8.5 ± 9.8 (3 mo); 9.6 ± 11.0 (6 mo); 8.7 ± 10.1 (12 mo); ($P < 0.01$) (BAI)	Not evaluated	Not reported	3-12 mo	[14]
8	1	Case report	Hydroxyapatite cement	Implantation into subperiosteal tunnel on the lateral nasal wall	Not evaluated	Not evaluated	Not evaluated	Not reported	1 yr	[60]

9	3	Clinical study	Hyaluronic acid	Submucosal injections into the inferior nasal concha and under the mucous membrane of the septum	Not evaluated	Not evaluated	Subjective symptoms improvement, improved acoustic rhinometry results (3-6 mo)	After 1 yr the implant was absorbed in 2 patients, symptoms restored	1 yr	[61]
10	5	Prospective observational study in a tertiary medical center	β -tricalcium phosphate	Implantation into submucoperiosteal pocket along the lateral nasal wall, at the site of the former inferior turbinate head between the nasal floor and the ostium of the nasolacrimal duct	90 (90-95) (NOSE); 18.7 (18.7-43.7) (RhinoQoL frequency); 30 (20-43.3) (RhinoQoL bothersomeness); 62.5 (57.6-68.7) (RhinoQoL impact)	5 (5-25) ($P = 0.01$) (NOSE); 81.2 (75-81.2) ($P = 0.01$) (RhinoQoL frequency); 81 (76.7-90) ($P = 0.05$) (RhinoQoL bothersomeness); 8.3 (5.5-11) ($P = 0.01$) (RhinoQoL impact)	Median nasolacrimal duct aperture (DNLI) 4.2 mm (1.8-6.6) (CT)	One case of partial implant extrusion 6 d after surgery	13.5 mo (8.2-21)	[20]
11	12	Prospective randomized blind clinical study	Silastic sheet	Implantation into submucoperichondrial and/or submucoperiosteal pockets fashioned along the septum, nasal floor, and lateral nasal wall	61.4 \pm 16.3 (SNOT-25)	33.6 \pm 17.1 (SNOT-25)	Decreased crustling (anterior rhinoscopy and endoscopic examination)	Partial implant extrusion in 4 patients	9-24 mo	[32]
12	14	Clinical study	Carboxymethylcellulose/glycerin gel (Prolaryn)	Submucosal injection into the inferior meatuses	20.8 \pm 4.9 (ENS6Q); 50.3 \pm 15.2 (SNOT-22); 8.6 (GAD-7)11.6 (PHQ-9)	ENS6Q: 10.5 (1 wk; $P < 0.0001$); 13.7 (1 mo, $P = 0.002$); 15.5 (3 mo; $P > 0.05$); SNOT-22: 29.3 (1 wk; $P = 0.01$); 35.5 (1 mo, $P = 0.04$); 39.3 (3 mo, $P > 0.05$); GAD-7: 5.4 (1 wk, $P > 0.05$); 4.9 (1 mo, $P = 0.02$); 5 (3 mo, $P = 0.02$); PHQ-9: 6.6 (1 wk; $P = 0.01$); 7 (1 mo, $P = 0.004$); 7.4 (3 mo, $P > 0.05$)	Not evaluated	Not reported	1 wk - 3 mo	[62]
13	3	Observational prospective cohort study	Porcine small intestine submucosal xenograft	Inferior turbinate reconstruction, implantation into submucosal pocket in the lateral nasal wall	77.6 (SNOT-25)	65 (1 wk); 57 (4 wk, $P < 0.01$); 55 (12 wk, $P < 0.01$) (SNOT-25)	Not evaluated	Mild partial implant reabsorption	1-12 wk	[63]
14	12	Retrospective clinical chart review	Autologous septal or conchal cartilage; autologous or homologous costal cartilage	Submucosal implantation into lateral nasal wall	Not evaluated	Not evaluated	75% were satisfied with outcome; significantly decreased excessive airflow, nasal obstruction, and nasal or facial pain ($P < 0.05$) (VAS)	Under correction in 3 patients	11.8 mo (6-27 mo)	[64]
15	17	Case series with chart review	Conchal cartilage (autologous)	Submucoperiosteal implantation into lateral nasal wall	54.0 (27.0-57.8) (SNOT-25)	35.9 (24.0-51.5) ($P = 0.007$) (SNOT-25)	Good mucosal healing (endoscopy)	Not reported	6-12 mo	[30]
16	14	Case series with chart review	Costal cartilage (autologous or homologous)	Submucoperiosteal implantation into lateral nasal wall	46.6 (45-67.5) (SNOT-25)	21.9 (9.0-40.8) ($P = 0.002$) (SNOT-25)	Good mucosal healing (endoscopy)	Not reported	6-12 mo	[30]
17	7	Prospective cohort study in a tertiary	Autologous bone graft from septal bone	Submucosal implantation into nasal floor	19 (BAI); 24.4 (BDI-II)	6.8 (BAI); 6.25 (BDI-II)	Mucosa covering the graft was smooth and intact on the lateral nasal wall	Not reported	1 yr	[26]

		medical center				(endoscopy)			
18	1	Case report	Acellular dermis (Alloderm) + Cymetra (injectable acellular dermis)	Submucoperiosteal implantation	Not evaluated	Not evaluated	40% better (subjective)	Not reported	3 mo [31]
19	8	Case series	Acellular dermis (Alloderm)	Submucoperichondrial and submucoperiosteal implantation into the former inferior turbinate; or into nasal septum and/or floor	58.3 (SNOT-20)	38.3 ($P \leq 0.02$) (SNOT-20)	Subjective improvement in smell threshold	The initial graft shrinks, and then the graft appears to maintain stable size for years	6 mo - 4 yr [5]
20	12	Prospective randomized blind clinical study	Acellular dermis (Alloderm)	Implantation into submucoperichondrial and/or submucoperiosteal pockets fashioned along the septum, nasal floor, and lateral nasal wall	63.7 ± 15.4 (SNOT-25)	34.2 ± 15.2 (SNOT-25)	Decreased crustling (anterior rhinoscopy and endoscopic examination)	Partial implant extrusion in 3 patients during the first 2 wk, but all healed with no sequelae. Partial graft shrinkage in 2 cases 2 mo postoperatively	9-24 mo [32]
21	9	Prospective observational clinical study	Autologous stromal vascular fraction (SVF)	Injection into medial surface of inferior turbinates	70.1 ± 24.7 (SNOT-25)	62.4 ± 35.8 ($P > 0.05$) (SNOT-25)	Decreased IL-1 β and IL-8 ($P < 0.005$) (ELISA)	Seroma in 1 patient	6 mo [47]
22	30	Clinical study	Autologous ADSCs combined with autologous fat granules	Injections into the areas of mucosal damage (every 10 d, 3 in total)	Not evaluated	Not evaluated	Inflammation significantly reduced, collagenous fibers became aligned, fewer deposits observed, and the mucosal proteins increased 1 mo post-op (H&E, Masson's, and AB-PAS stainings). Nasal resistance, nasal volume, minimum crosssectional area, and mucociliary clearance improved (acoustic rhinometry)	Not reported	3-9 mo [49]

disadvantages of this type of implant[5,32].

Single studies showed application of hydroxyapatite cement, hyaluronic acid, β -tricalcium phosphate, silastic sheet, carboxymethylcellulose/glycerin gel (Prolaryn), autologous bone graft from septal bone, porcine small intestine submucosal xenograft for turbinate restoring in ENS patients (Table 1). Small number of enrolled patients and drawbacks detected impose restrictions on the use of these implants for ENS treatment. Despite meta-analysis[21] showing that implantation of autograft/allograft is more effective than foreign graft materials, searching for optimal implant biomaterials with good biocompatibility, stability and host tissue integration is still an actual task for regenerative medicine in line of ENS treatment. Moreover, none of presented surgical or conventional treatments solves all the key issues which underlie ENS pathogenesis that results in their low effectivity and/or not sustainable effect, not

enough to significantly improve ENS patient's symptoms. We postulate that new developing cell technologies could overcome the existing treatment limitations and lead to the significant and stable improvement in quality of life of ENS patients.

Adipose tissue derived extracellular matrix and methylcellulose hydrogels are new alternative biomaterials that could be potentially used for the inferior turbinate reconstruction. Strong limitation of fat transplantation despite of excellent biocompatibility is its high resorption up to 90% during 5 mo[33]. Decellularized adipose derived extracellular matrix (ECM) is a new alternative to fat transplantation. It was shown that combination of ECM and methylcellulose hydrogels are promising material for injection laryngoplasty for stable vocal fold augmentation. ECM/MC hydrogel did not cause inflammation or fibrosis in injection site, but number of collagen fibers and fatty granules increased[34]. Other study demonstrated that ECM/MC hydrogels are excellent scaffold for injectable stem cell delivery. Transplantation of ADSCs in ECM/MC hydrogels in cutaneous would lead to rapid re-epithelialization, neovascularization and minimal scar formation[35]. The main advantages of ECM/MC hydrogel composition are high biocompatibility, thermosensitivity that allow to inject material with minimal traumatization for patients, stability and possibility to combine with stem cells.

PERSPECTIVES OF STEM CELL-BASED THERAPY

Stem cells-based therapy belonging to advances therapy medical products is an innovative treatment strategy that could give chance for those diseases, where conventional therapies are inefficient. Stem cells application show great potential for replacing or regenerating damaged cells, tissues and organs. Different types of stem cells, including adult stem cells, derivatives of embryonic and induced pluripotent stem cells undergo clinical trials for evaluation of their safety and effectivity[36]. Anti-aging therapy, wound healing, neurodegenerative diseases, metabolic disorders, musculoskeletal system disorders, autoimmune diseases are all targets for stem cells application. Taking into consideration ethical, legal and political concerns, tissue-specific adults stem cells are preferable source for use in regenerative medicine. Due to a multilineage differentiation potential, immunomodulatory properties, production of large number of soluble or vesicle-bound growth factors, cytokines, and microRNAs, multipotent mesenchymal stromal cells (MSCs) become the key player in rapidly growing field of cell-based therapy during last 30 years[37]. More than 950 clinical trial based on using MSCs were registered worldwide during 2011-2018[37,38]. Significant therapeutic effect of MSCs has been shown in treating graft *vs* host diseases, complex perianal fistulas in Crohn's disease, osteoarthritis, type II diabetes, and wound healing [39-41]. Bone marrow, adipose tissue, umbilical cord and placenta are the most abundant sources for MSCs isolation and expansion with the next application in regenerative medicine taking into consideration ethical problems, cell source availability and quantity of MSCs output[37]. All MSCs types isolated from different tissues are characterized by common features: adhesion to plastic, fibroblast-like morphology, positive for CD73, CD90, CD105 and negative for CD34, CD45, CD14 or CD11b, CD79- α or CD19, HLA-DR cell surface markers, ability multilineage differentiation into adipocytes, chondrocytes and osteocytes *in vitro*[37,42]. The broad-range of MSCs therapeutic potential could be explained by their biological properties[43]. High proliferation potential – MSCs proliferate rapidly *in vitro* allowing biotechnologists to expand cells to the appropriate amount for application. (1) Multipotency – ability to differentiate into multiple cell types under the appropriate stimuli and replace damaged cells; (2) Trophic function – MSCs secrete numerous growth factors (Ang-1, EGF, FGF, GDNF, BDNF, HGF, IGF-1, PDGF, SDF-1, VEGF) to support the local tissue regeneration[44]; (3) Homing/migration – MSCs are able to migrate to damaged tissues after systemic application; they express adhesion molecules (CD44 and integrins), chemokines receptors (CCR2, CCR7, CCR10, CXCR4, CXCR5, CXCR6), and metalloproteinases (MMP-1, MMP-9); and (4) Immunomodulation function – MSCs suppress the proliferation and activity of CD4+ T helper cells, CD8+ cytotoxic T cells, proinflammatory macrophages, neutrophils, nature killer cells and B cells. At the same time, MSCs stimulate regulatory T and B cells, anti-inflammation macrophages and immature dendritic cells. Immunomodulation properties of MSCs are realized by secretion of TGF- β , IL-6, IL-10, prostaglandin E2 (PGE2), LIF, TSG-6, inducible nitric oxide synthase (iNOS) and indoleamine 2,3-dioxygenase (IDO), *etc.*[45].

Stem cells, including MSCs, use different mechanisms to repair injured tissues. These are direct cell replenishment by MSCs differentiation, paracrine effect by growth

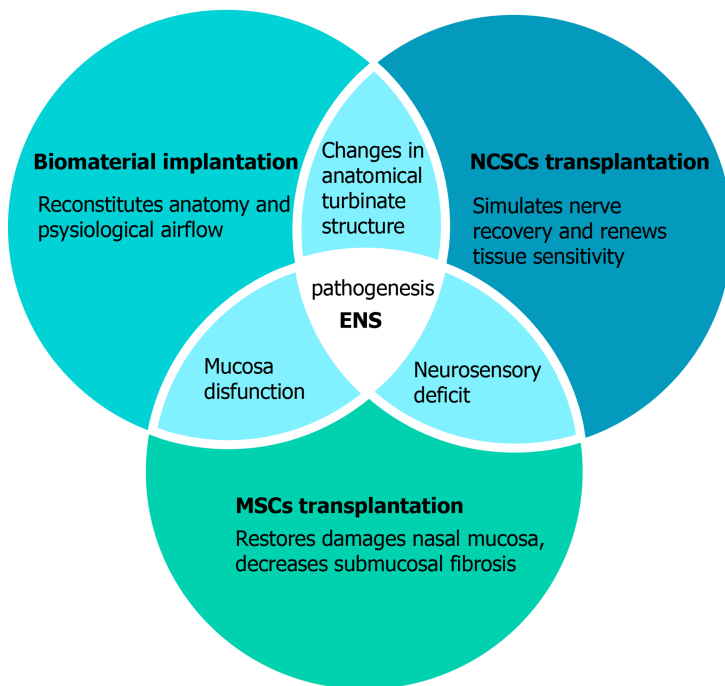


Figure 2 Conception of complex approach in treatment of empty nose syndrome using cell-based technologies and tissue engineering.

The empty nose syndrome treatment should be complex and solving three main issues: Changes in turbinate anatomy, mucosa tissue dysfunction and nerve sensing disruption. Biomaterial implantation may be performed alone or together with encapsulated stem cells to restore turbinate structure and physiological airflow. The main function of mesenchymal stem cells injection is directed to decrease inflammation and regenerate nasal mucosa, while neural crest-derived stem cells should stimulate neurosensory system sensitivity. ENS: Empty nose syndrome; MSCs: Mesenchymal stem cells; NCSCs: Neural crest-derived stem cells.

factors, cytokines and hormones secretion, and protein/peptide and miRNA transfer *via* MSCs-derived extracellular vesicles[46].

Published data about MSCs application for ENS treatment are limited. Kim *et al*[47] reported that injection of the autologous stromal vascular fraction (SVF) from adipose tissue partially improved ENS symptoms. Two of nine enrolled patients felt improvement, but totally there was no statistically significant differences in SNOT-25 score. However, the level of inflammatory cytokines IL-1 β and IL-8 in nasal secretions decreased after SVF injection[48]. The low effectivity of SVF for ENS treatment could be explained by the fact that SVF is a non-cultivated mixture of differentiated and progenitor cells with very low percent of real stem cells (up to 3%)[48] which vary between the patients. It was shown that the combination of fat particles with adipose tissue-derived MSCs led to significantly improved symptoms in ENS patients[49]. The potential of MSCs to recover nasal mucosa was confirmed by Friji *et al*[50] when lipoaspirate in combination with PRP was injected to five patients with primary atrophy rhinitis. This resulted in mucosal regeneration and improvement of mucosa appearance from atrophied mucosa with crusting to normal glistening mucosa[50]. We suppose that using more homogeneous and enriched population of MSCs isolated from umbilical cord or adipose tissue for ENS management will have more prominent regenerative effect (Figures 2 and 3), than lipoaspirate or SVF application.

As mentioned previously, reduction of nasal surface area after turbinate resection leads to different level of nerve damage and reduction of TRPM8 thermoreceptors number[2] that results in abnormal patient's sensation. Role of nerve signaling in pathophysiology of ENS to find approach for nerve recovery and tissue sensitivity renewal. Injection of cell-based products enriched with trophic factors is one of possible solutions. Besides already known PRP, SVF, and MSCs we purpose to use another stem cell type with high neuroprotective properties and ability to neural differentiation that could force nerve regeneration in ENS patients. Adult neural-crest derived stem cells (NCSCs) are unique rare population of stem cells found in the hair follicle, skin dermis, adipose tissue, bone marrow, palate, nasal mucosa, dental pulp *etc*[51]. Numerous studies demonstrate that NCSCs have wider range of differentiation potential compared to MSCs, precisely in neuronal and glial cell lineages[52]. Moreover, NCSCs produce rich spectrum of cytokines and growth factors like IL-2Ra, IL-3, IL-5, IL-8, IL-16, MCP-1, SDF1a, GM-CSF, M-CSF, VEGF, HGF, bFGF, as well as specific neurotrophic factors NGF, NTF3, NTF4, BDNF, GDNF[53]. The trans-

Cell-based therapy

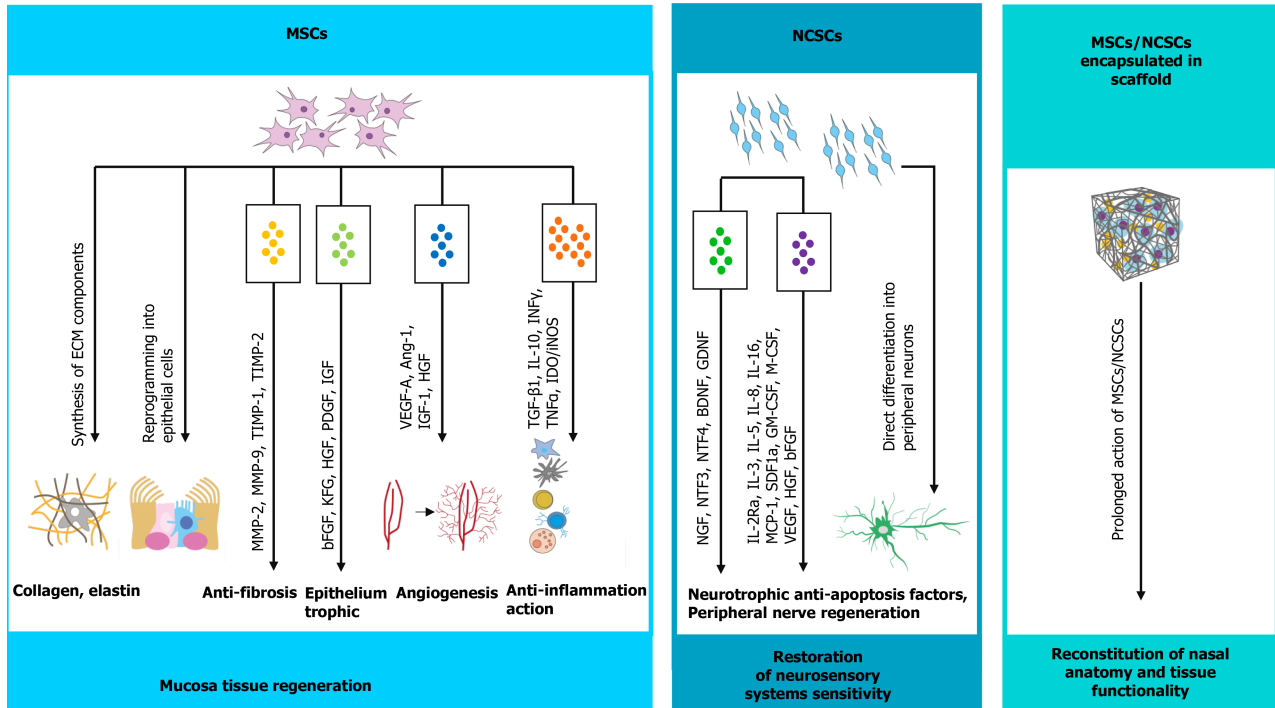


Figure 3 Realization of stem cells therapeutic potential in management of empty nose syndrome (possible mechanisms). The therapeutic effect of stem cell transplantation could be realized by two main ways. The first one is direct differentiation of transplanted stem cells under the impact of specific environmental factors, such as hypoxia and inflammation. Mesenchymal stem cells (MSCs) have the ability to transdifferentiate in mucosa epithelial cells, while neural crest-derived stem cells (NCSCs) can form peripheral neurons. However, very small amount, around 1-3%, of transplanted stem cells can differentiate. The 95% of stem cells therapeutic potential are implemented in indirect way via secreting plethora of paracrine factors and extracellular vesicles. MSCs-derived secretory factors promote neovascularization, immunomodulatory anti-inflammatory effect, anti-apoptotic and anti-fibrotic effect, and reduce oxidative stress that create favorable environment for mucosa regeneration. NCSCs, in particular, have strong neuroprotective properties, thus local NCSCs injection in empty nose syndrome patients could also stimulate nerve recovery by trophic support or direct reintegration in damaged tissue. MSCs: Mesenchymal stem cells; NCSCs: Neural crest-derived stem cells.

plantation of cultured adults NCSCs resulted in the restoration of bone defects[54], damaged peripheral nerves[55] and spinal cord[56] in rats. The NCSCs transplantation in an experimental model of glaucoma was effective and caused reduction of edema and restoration of the cytoarchitectonics of the layers[57]. Application of the NCSCs after the experimental orbital trauma stimulated the oculomotor muscles and retrobulbar fat tissue recovery[58]. All abovementioned biological properties of NCSCs, successful pre-clinical and clinical results of their transplantation together with several accessible sources in adult organism make NCSCs attractive candidates for regenerative medicine use, especially in field of neurology. NCSCs local injection to patients with ENS could lead not only to regeneration of nasal mucosa, but also stimulate nerve recovery by trophic support or direct reintegration in damaged tissue (Figures 2 and 3).

Efficiency of stem cell-based product application for ENS patients management may depend on numerous factors: severity of symptoms, autologous or donor stem cells, source of stem cells, their amount and quality *etc.* Based on our own experimental and clinical experiences in stem cells-based treatment of neurodegenerative diseases and ENS patients (not published), we suggest using transplantation of NCSCs alone or in combination with MSCs to archive more valuable therapeutic results depending on the case severity (Figure 2). The local injection of MSCs alone could induce regeneration of nasal mucosa epithelium and decrease inflammation, but that is not efficient for neurosensory system recovery (Figures 2 and 3). Taking into account the intrinsic neuroprotective properties of NCSCs, the following application of high quality cultured NCSCs may reconstitute nerve structure and functioning leading to normal sensation in ENS patients (Figure 3). Thus, the therapy based on the combination of NCSCs and MSCs might improve the proper functioning of epithelial cells of the nasal mucosa, reduce inflammation and, consequently, mucosal edema, recover neurosensory systems, which will contribute to the regression of ENS symptoms.

There are some ways to improve stem cell-based therapy. One option is tissue engineering approach, thus application of stem cells encapsulated in bioactive materials whose chemical and physical properties would support cell survival and proliferation. Biomaterials may increase therapeutic potential of stem cells due to imitation of physiological niche of the cells allowing to cell interaction with each other and with artificial "extracellular matrix" in 3D dimension. Such approach results in reducing cells' stress after transplantation, increased stem cells survival, their secretome enrichment, *etc.*[59]. Thus, depending on ENS severity, MSCs and NCSCs encapsulated in biomaterial could be used both to reconstitute the anatomical nasal structure and restore mucosa functionality, specifically inhibit inflammation after surgical manipulation, reduce edema, stimulate mucosa epithelium regeneration and improve local neurosensation. In case of tissue-engineering methods use we expect to achieve lifetime positive effect. Such a complex approach may help patients obtain long-awaited relief as well as reduce their time and costs.

CONCLUSION

With the advancement of stem cell technologies, the use of this regenerative medicine instrument for reconstruction of damaged nasal cavity may greatly improve conventional methods of ENS treatment, gaining not only anatomical structure but returning lost function. In recent years, stem cell-based therapies were extensively studied, and promising results were acquired for various stem cell types combined with different grafts and biomaterials. However, there remain some challenges to be solved, such as the low survival rate of transplanted cells and the difficulty of restoring the proper volume and normal architecture of the organ tissue.

REFERENCES

- 1 **Scheithauer MO.** Surgery of the turbinates and "empty nose" syndrome. *GMS Curr Top Otorhinolaryngol Head Neck Surg* 2010; **9**: Doc03 [PMID: 22073107 DOI: 10.3205/cto000067]
- 2 **Gill AS, Said M, Tollefson TT, Steele TO.** Update on empty nose syndrome: disease mechanisms, diagnostic tools, and treatment strategies. *Curr Opin Otolaryngol Head Neck Surg* 2019; **27**: 237-242 [PMID: 31116142 DOI: 10.1097/MOO.0000000000000544]
- 3 **Keime-Guibert F, Napolitano M, Delattre JY.** Neurological complications of radiotherapy and chemotherapy. *J Neurol* 1998; **245**: 695-708 [PMID: 9808237 DOI: 10.1007/s004150050271]
- 4 **Di Girolamo S, editor.** Atrophic Rhinitis: From the Voluptuary Nasal Pathology to the Empty Nose Syndrome. Springer, 2020: XII, 202 [DOI: 10.1007/978-3-030-51705-2]
- 5 **Houser SM.** Surgical treatment for empty nose syndrome. *Arch Otolaryngol Head Neck Surg* 2007; **133**: 858-863 [PMID: 17875850 DOI: 10.1001/archotol.133.9.858]
- 6 **Kuan EC, Suh JD, Wang MB.** Empty nose syndrome. *Curr Allergy Asthma Rep* 2015; **15**: 493 [PMID: 25430954 DOI: 10.1007/s11882-014-0493-x]
- 7 **Sozansky J, Houser SM.** Pathophysiology of empty nose syndrome. *Laryngoscope* 2015; **125**: 70-74 [PMID: 24978195 DOI: 10.1002/lary.24813]
- 8 **Coste A, Dessi P, Serrano E.** Empty nose syndrome. *Eur Ann Otorhinolaryngol Head Neck Dis* 2012; **129**: 93-97 [PMID: 22513047 DOI: 10.1016/j.anorl.2012.02.001]
- 9 **Manji J, Nayak JV, Thamboo A.** The functional and psychological burden of empty nose syndrome. *Int Forum Allergy Rhinol* 2018; **8**: 707-712 [PMID: 29443458 DOI: 10.1002/alr.22097]
- 10 **Kim CH, Kim J, Song JA, Choi GS, Kwon JH.** The Degree of Stress in Patients With Empty Nose Syndrome, Compared With Chronic Rhinosinusitis and Allergic Rhinitis. *Ear Nose Throat J* 2021; **100**: NP87-NP92 [PMID: 31272211 DOI: 10.1177/0145561319858912]
- 11 **Thune EL, Kosinski P, Balakin BV, Alyaev S.** A numerical study of flow field and particle deposition in nasal channels with deviant geometry. *Eng App Comput Fluid Mech* 2021; **15**: 180-193 [DOI: 10.1080/19942060.2020.1863267]
- 12 **Freund W, Wunderlich AP, Stöcker T, Schmitz BL, Scheithauer MO.** Empty nose syndrome: limbic system activation observed by functional magnetic resonance imaging. *Laryngoscope* 2011; **121**: 2019-2025 [PMID: 22024858 DOI: 10.1002/lary.21903]
- 13 **Bhandarkar ND, Smith TL.** Outcomes of surgery for inferior turbinate hypertrophy. *Curr Opin Otolaryngol Head Neck Surg* 2010; **18**: 49-53 [PMID: 19915467 DOI: 10.1097/MOO.0b013e328334d974]
- 14 **Huang CC, Wu PW, Fu CH, Huang CC, Chang PH, Lee TJ.** Impact of Psychologic Burden on Surgical Outcome in Empty Nose Syndrome. *Laryngoscope* 2021; **131**: E694-E701 [PMID: 32692881 DOI: 10.1002/lary.28845]
- 15 **Lemogne C, Consoli SM, Limosin F, Bonfils P.** Treating empty nose syndrome as a somatic symptom disorder. *Gen Hosp Psychiatry* 2015; **37**: 273.e9-273.10 [PMID: 25754986 DOI: 10.1016/j.genhosppsych.2015.05.001]

- 10.1016/j.genhosppsy.2015.02.005]
- 16 **Xu Y**, Chen C, Hellwarth PB, Bao X. Biomaterials for stem cell engineering and biomanufacturing. *Bioact Mater* 2019; **4**: 366-379 [PMID: 31872161 DOI: 10.1016/j.bioactmat.2019.11.002]
 - 17 **Sekula M**, Zuba-Surma EK. Biomaterials and Stem Cells: Promising Tools in Tissue Engineering and Biomedical Applications. In: Dobrzański LA, editor. Biomaterials in Regenerative Medicine. IntechOpen, 2017 [DOI: 10.5772/intechopen.70122]
 - 18 **Kohane DS**, Langer R. Polymeric biomaterials in tissue engineering. *Pediatr Res* 2008; **63**: 487-491 [PMID: 18427292 DOI: 10.1203/01.pdr.0000305937.26105.e7]
 - 19 **Ha TLB**, Quan TM, Vu DN, Si DM. Naturally Derived Biomaterials: Preparation and Application. In: Andrades JA, editor. Regenerative Medicine and Tissue Engineering. IntechOpen, 2013 [DOI: 10.5772/55668]
 - 20 **Bastier PL**, Bennani-Baiti AA, Stoll D, de Gabory L. β -Tricalcium phosphate implant to repair empty nose syndrome: preliminary results. *Otolaryngol Head Neck Surg* 2013; **148**: 519-522 [PMID: 23300225 DOI: 10.1177/0194599812472436]
 - 21 **Ma ZX**, Quan-Zeng, Jie-Liu, Hu GH. Assessment of postsurgical outcomes between different implants in patients with empty nose syndrome: A meta-analysis. *J Int Med Res* 2017; **45**: 1939-1948 [PMID: 29098901 DOI: 10.1177/0300060517715167]
 - 22 **Khorasani M**, Janbaz P, Rayati F. Maxillofacial reconstruction with Medpor porous polyethylene implant: a case series study. *J Korean Assoc Oral Maxillofac Surg* 2018; **44**: 128-135 [PMID: 29963494 DOI: 10.5125/jkaoms.2018.44.3.128]
 - 23 **Boccieri A**, Marano A. The conchal cartilage graft in nasal reconstruction. *J Plast Reconstr Aesthet Surg* 2007; **60**: 188-194 [PMID: 17223517 DOI: 10.1016/j.bjps.2006.02.005]
 - 24 **Jiang C**, Shi R, Sun Y. Study of inferior turbinate reconstruction with Medpor for the treatment of empty nose syndrome. *Laryngoscope* 2013; **123**: 1106-1111 [PMID: 23208803 DOI: 10.1002/lary.23908]
 - 25 **Tam YY**, Lee TJ, Wu CC, Chang PH, Chen YW, Fu CH, Huang CC. Clinical analysis of submucosal Medpor implantation for empty nose syndrome. *Rhinology* 2014; **52**: 35-40 [PMID: 24618626 DOI: 10.4193/Rhin13.086]
 - 26 **Lee TJ**, Fu CH, Wu CL, Tam YY, Huang CC, Chang PH, Chen YW, Wu MH. Evaluation of depression and anxiety in empty nose syndrome after surgical treatment. *Laryngoscope* 2016; **126**: 1284-1289 [PMID: 26667794 DOI: 10.1002/lary.25814]
 - 27 **Lee TJ**, Fu CH, Wu CL, Lee YC, Huang CC, Chang PH, Chen YW, Tseng HJ. Surgical outcome for empty nose syndrome: Impact of implantation site. *Laryngoscope* 2018; **128**: 554-559 [PMID: 28714537 DOI: 10.1002/lary.26769]
 - 28 **Huang CC**, Wu PW, Fu CH, Huang CC, Chang PH, Wu CL, Lee TJ. What drives depression in empty nose syndrome? *Rhinology* 2019; **57**: 469-476 [PMID: 31502597 DOI: 10.4193/Rhin19.085]
 - 29 **Agarwal C**, Kumar BT, Mehta DS. An acellular dermal matrix allograft (Alloderm®) for increasing keratinized attached gingiva: A case series. *J Indian Soc Periodontol* 2015; **19**: 216-220 [PMID: 26015676 DOI: 10.4103/0972-124X.149938]
 - 30 **Jung JH**, Baguindali MA, Park JT, Jang YJ. Costal cartilage is a superior implant material than conchal cartilage in the treatment of empty nose syndrome. *Otolaryngol Head Neck Surg* 2013; **149**: 500-505 [PMID: 23728068 DOI: 10.1177/0194599813491223]
 - 31 **Houser SM**. Empty nose syndrome associated with middle turbinate resection. *Otolaryngol Head Neck Surg* 2006; **135**: 972-973 [PMID: 17141099 DOI: 10.1016/j.otohns.2005.04.017]
 - 32 **Saafan ME**. Acellular dermal (alloderm) grafts versus silastic sheets implants for management of empty nose syndrome. *Eur Arch Otorhinolaryngol* 2013; **270**: 527-533 [PMID: 22526572 DOI: 10.1007/s00405-012-1955-1]
 - 33 **Patrick CW Jr**. Tissue engineering strategies for adipose tissue repair. *Anat Rec* 2001; **263**: 361-366 [PMID: 11500812 DOI: 10.1002/ar.1113]
 - 34 **Kim DW**, Kim EJ, Kim EN, Sung MW, Kwon TK, Cho YW, Kwon SK. Human Adipose Tissue Derived Extracellular Matrix and Methylcellulose Hydrogels Augments and Regenerates the Paralyzed Vocal Fold. *PLoS One* 2016; **11**: e0165265 [PMID: 27768757 DOI: 10.1371/journal.pone.0165265]
 - 35 **Kim EJ**, Choi JS, Kim JS, Choi YC, Cho YW. Injectable and Thermosensitive Soluble Extracellular Matrix and Methylcellulose Hydrogels for Stem Cell Delivery in Skin Wounds. *Biomacromolecules* 2016; **17**: 4-11 [PMID: 26607961 DOI: 10.1021/acs.biomac.5b01566]
 - 36 **Balistreri CR**, De Falco E, Bordin A, Maslova O, Koliada A, Vaiserman A. Stem cell therapy: old challenges and new solutions. *Mol Biol Rep* 2020; **47**: 3117-3131 [PMID: 32128709 DOI: 10.1007/s11033-020-05353-2]
 - 37 **Pittenger MF**, Discher DE, Péault BM, Phinney DG, Hare JM, Caplan AI. Mesenchymal stem cell perspective: cell biology to clinical progress. *NPJ Regen Med* 2019; **4**: 22 [PMID: 31815001 DOI: 10.1038/s41536-019-0083-6]
 - 38 **Hoogduijn MJ**, Lombardo E. Mesenchymal Stromal Cells Anno 2019: Dawn of the Therapeutic Era? *Stem Cells Transl Med* 2019; **8**: 1126-1134 [PMID: 31282113 DOI: 10.1002/sctm.19-0073]
 - 39 **Godoy JAP**, Paiva RMA, Souza AM, Kondo AT, Kutner JM, Okamoto OK. Clinical Translation of Mesenchymal Stromal Cell Therapy for Graft Versus Host Disease. *Front Cell Dev Biol* 2019; **7**: 255 [PMID: 31824942 DOI: 10.3389/fcell.2019.00255]
 - 40 **Galipeau J**, Sensébé L. Mesenchymal Stromal Cells: Clinical Challenges and Therapeutic Opportunities. *Cell Stem Cell* 2018; **22**: 824-833 [PMID: 29859173 DOI: 10.1016/j.stem.2018.05.005]

- 10.1016/j.stem.2018.05.004]
- 41 **Shariatzadeh M**, Song J, Wilson SL. The efficacy of different sources of mesenchymal stem cells for the treatment of knee osteoarthritis. *Cell Tissue Res* 2019; **378**: 399-410 [PMID: [31309317](#) DOI: [10.1007/s00441-019-03069-9](#)]
 - 42 **Fitzsimmons REB**, Mazurek MS, Soos A, Simmons CA. Mesenchymal Stromal/Stem Cells in Regenerative Medicine and Tissue Engineering. *Stem Cells Int* 2018; **2018**: 8031718 [PMID: [30210552](#) DOI: [10.1155/2018/8031718](#)]
 - 43 **Naji A**, Eitoku M, Favier B, Deschaseaux F, Rouas-Freiss N, Sukanuma N. Biological functions of mesenchymal stem cells and clinical implications. *Cell Mol Life Sci* 2019; **76**: 3323-3348 [PMID: [31055643](#) DOI: [10.1007/s00018-019-03125-1](#)]
 - 44 **Harrell CR**, Fellabaum C, Jovicic N, Djonov V, Arsenijevic N, Volarevic V. Molecular Mechanisms Responsible for Therapeutic Potential of Mesenchymal Stem Cell-Derived Secretome. *Cells* 2019; **8** [PMID: [31100966](#) DOI: [10.3390/cells8050467](#)]
 - 45 **Shi Y**, Wang Y, Li Q, Liu K, Hou J, Shao C. Immunoregulatory mechanisms of mesenchymal stem and stromal cells in inflammatory diseases. *Nat Rev Nephrol* 2018; **14**: 493-507 [PMID: [29895977](#) DOI: [10.1038/s41581-018-0023-5](#)]
 - 46 **Spees JL**, Lee RH, Gregory CA. Mechanisms of mesenchymal stem/stromal cell function. *Stem Cell Res Ther* 2016; **7**: 125 [PMID: [27581859](#) DOI: [10.1186/s13287-016-0363-7](#)]
 - 47 **Kim DY**, Hong HR, Choi EW, Yoon SW, Jang YJ. Efficacy and Safety of Autologous Stromal Vascular Fraction in the Treatment of Empty Nose Syndrome. *Clin Exp Otorhinolaryngol* 2018; **11**: 281-287 [PMID: [29764011](#) DOI: [10.21053/ceo.2017.01634](#)]
 - 48 **Baer PC**, Geiger H. Adipose-derived mesenchymal stromal/stem cells: tissue localization, characterization, and heterogeneity. *Stem Cells Int* 2012; **2012**: 812693 [PMID: [22577397](#) DOI: [10.1155/2012/812693](#)]
 - 49 **Xu X**, Li L, Wang C, Liu Y, Chen C, Yan J, Ding H, Tang SY. The expansion of autologous adipose-derived stem cells in vitro for the functional reconstruction of nasal mucosal tissue. *Cell Biosci* 2015; **5**: 54 [PMID: [26388989](#) DOI: [10.1186/s13578-015-0045-7](#)]
 - 50 **Friji MT**, Gopalakrishnan S, Verma SK, Parida PK, Mohapatra DP. New regenerative approach to atrophic rhinitis using autologous lipoaspirate transfer and platelet-rich plasma in five patients: Our Experience. *Clin Otolaryngol* 2014; **39**: 289-292 [PMID: [24938860](#) DOI: [10.1111/coa.12269](#)]
 - 51 **Mehrotra P**, Tseropoulos G, Bronner ME, Andreadis ST. Adult tissue-derived neural crest-like stem cells: Sources, regulatory networks, and translational potential. *Stem Cells Transl Med* 2020; **9**: 328-341 [PMID: [31738018](#) DOI: [10.1002/scrm.19-0173](#)]
 - 52 **Vasyliiev RG**, Gubar OS, Gordiienko IM, Litvinova LS, Rodnichenko AE, Shupletsova VV, Zlatska AV, Yurova KA, Todosenko NM, Khadzhyanova VE, Shulha MV, Novikova SN, Zubov DO. Comparative Analysis of Biological Properties of Large-Scale Expanded Adult Neural Crest-Derived Stem Cells Isolated from Human Hair Follicle and Skin Dermis. *Stem Cells Int* 2019; **2019**: 9640790 [PMID: [30915126](#) DOI: [10.1155/2019/9640790](#)]
 - 53 **Nagoshi N**, Shibata S, Nakamura M, Matsuzaki Y, Toyama Y, Okano H. Neural crest-derived stem cells display a wide variety of characteristics. *J Cell Biochem* 2009; **107**: 1046-1052 [PMID: [19479900](#) DOI: [10.1002/jcb.22213](#)]
 - 54 **Pelttari K**, Pippenger B, Mumme M, Feliciano S, Scotti C, Mainil-Varlet P, Prociño A, von Rechenberg B, Schwamborn T, Jakob M, Cillo C, Barbero A, Martin I. Adult human neural crest-derived cells for articular cartilage repair. *Sci Transl Med* 2014; **6**: 251ra119 [PMID: [25163479](#) DOI: [10.1126/scitranslmed.3009688](#)]
 - 55 **Pisciotta A**, Bertoni L, Vallarola A, Bertani G, Mecugni D, Carnevale G. Neural crest derived stem cells from dental pulp and tooth-associated stem cells for peripheral nerve regeneration. *Neural Regen Res* 2020; **15**: 373-381 [PMID: [31571644](#) DOI: [10.4103/1673-5374.266043](#)]
 - 56 **Neirinckx V**, Cantinieaux D, Coste C, Rogister B, Franzen R, Wislet-Gendebien S. Concise review: Spinal cord injuries: how could adult mesenchymal and neural crest stem cells take up the challenge? *Stem Cells* 2014; **32**: 829-843 [PMID: [24155224](#) DOI: [10.1002/stem.1579](#)]
 - 57 **Rykov S**, Petrenko O, Yakovets A, Zubov D, Vasyliiev R. Experimental rationale of the use of cell therapy for the treatment of glaucoma optical neuropathy. *Eureka Health Sci* 2020; **2**: 40-46 [DOI: [10.21303/2504-5679.2020.001187](#)]
 - 58 **Chepurnyi YV**, Kustrjo TV, Korsak AV, Likhodievskiy VV, Rodnichenko AE, Gubar OS, Zlatska OV, Kopchak AV, Zabala AO, Olefir SS, Zubov DO, Vasyliiev RG, Chaikovskiy YB. Influence of Adult Neural Crest-Derived Multipotent Stem Cells on Regeneration of Orbital Soft Tissue Content After Experimental Injury. *Probl Cryobiol Cryomed* 2018; **28**: 59-63 [DOI: [10.15407/cryo28.01.059](#)]
 - 59 **Zhao X**, Cui K, Li Z. The role of biomaterials in stem cell-based regenerative medicine. *Future Med Chem* 2019; **11**: 1777-1790 [PMID: [31288586](#) DOI: [10.4155/fmc-2018-0347](#)]
 - 60 **Rice DH**. Rebuilding the inferior turbinate with hydroxyapatite cement. *Ear Nose Throat J* 2000; **79**: 276-277 [PMID: [10786390](#)]
 - 61 **Modrzyński M**. Hyaluronic acid gel in the treatment of empty nose syndrome. *Am J Rhinol Allergy* 2011; **25**: 103-106 [PMID: [21679513](#) DOI: [10.2500/ajra.2011.25.3577](#)]
 - 62 **Borchard NA**, Dholakia SS, Yan CH, Zarabanda D, Thamboo A, Nayak JV. Use of intranasal submucosal fillers as a transient implant to alter upper airway aerodynamics: implications for the assessment of empty nose syndrome. *Int Forum Allergy Rhinol* 2019; **9**: 681-687 [PMID: [30715801](#) DOI: [10.1002/alr.22299](#)]
 - 63 **Velasquez N**, Huang Z, Humphreys IM, Nayak JV. Inferior turbinate reconstruction using porcine

- small intestine submucosal xenograft demonstrates improved quality of life outcomes in patients with empty nose syndrome. *Int Forum Allergy Rhinol* 2015; **5**: 1077-1081 [PMID: [26332403](#) DOI: [10.1002/alr.21633](#)]
- 64 **Jang YJ**, Kim JH, Song HY. Empty nose syndrome: radiologic findings and treatment outcomes of endonasal microplasty using cartilage implants. *Laryngoscope* 2011; **121**: 1308-1312 [PMID: [21557228](#) DOI: [10.1002/lary.21734](#)]



Published by **Baishideng Publishing Group Inc**
7041 Koll Center Parkway, Suite 160, Pleasanton, CA 94566, USA

Telephone: +1-925-3991568

E-mail: bpgoffice@wjgnet.com

Help Desk: <https://www.f6publishing.com/helpdesk>

<https://www.wjgnet.com>

