

Sapunkov O.D.,  
Kosakovskiy A.L.,  
Sapunkova S.S.,  
Bogdanova L.O.

*Department of Pediatric Surgery and Otolaryngology, HSEE of Ukraine "Bukovinian State Medical University", Chernivtsi, Ukraine*

## TYMPANIC CAVITY STRUCTURE OF THE HUMAN FETUSES NINE MONTHS OF THE DEVELOPMENT

**Abstract.** *The structure of the middle ear and syntopy studied in 7 human fetuses of nine months of development. It was investigated that during this period the formation of the inferior and anterior wall of the tympanic cavity continues. The internal carotid artery and jugular bulb participate in this process. Tympanic holes of the auditory tube continue to move from the bottom upwards tympanic cavity.*

**Keywords:** *tympanic opening of auditory tube, tympanic cavity, auditory tube, the canal of the internal carotid artery, the bulb jugular vein.*

**Introduction.** The influence of a number of adverse factors (occupational hazards, parental education, smoking, alcoholism, the age of a mother younger than 17 and over 30, "deficient" nutrition of a pregnant woman, etc., led to a significant increase in the percentage of non-pregnancy in recent decades [2]. According to WHO experts now it is of 5-18% [3].

At the same time, modernization of maternity homes, the construction of modern perinatal centers, active training of personnel allow not only to reduce neonatal mortality, but also to nurse premature infants with a low and extremely low body weight. It became possible due to the provision of specialized medical care immediately after birth [1].

For the nurse of premature infants of all ages, currently the doctors of various specialties are engaged, including otolaryngologists. As a result, the prevention of disability and the timely rehabilitation of such children are becoming an important problem for them to.

It is so important because from the very beginning of the nurse of premature infants there are pathological changes in the nose and nasopharynx in connection with the prolonged use of artificial ventilation of lungs and CPAP therapy (Continuous Positive Airway Pressure) of severe and extremely difficult premature infants

[4]. The binasal cannula used in CPAP has a constant pressure on the nasal septum and immature soft tissues, which leads to bedsores, soft tissue necrosis and rhinogenic sepsis [5].

These traumatic lesions of soft tissues of the nose and nasopharynx in premature infants lead to pathological processes in the middle ear, which can increase for 42% [6]. At the same time, in 10% of premature infants, the otitis media is quite difficult and in the future there may appear the need of surgical intervention [6].

That's why the study of embryological aspects of the development of the middle ear, its anatomy and topographic anatomy in the fetuses remains actual.

**The aim of the study.** To study of the topographic anatomical features of the tympanic cavity in the fetuses of 9 months of fetal development and to substantiate the morphological interconnection of its forming processes with adjacent structures.

**Materials and methods.** The study was performed on 7 human fetuses of 311.0-345.0 mm of parietal-coccygeal length (PCL).

In the course of the study the following methods were used: fine anatomization of the middle ear and adjacent areas under the control of binocular enlarging lens; macro- and microscopy; morphometry; photomacrography of

the "OLIMPUS  $\mu$  1000 All-weather 10.0 Mpix" digital camera.

**Result.** In the fetuses of the ninth month of prenatal development, the tympanic cavity becomes more irregular in shape, numerous cells appear on its walls (Fig. 1). The inferior and the anterior walls of the tympanic cavity increase their size. The inferior wall restricts the jugular fossa, and the anterior is the wall of the canal of the external carotid artery. The increase of these walls contributes to an increase in the diameter of the vessels - the internal jugular vein and the internal carotid artery and, accordingly, the increase of the canal of the internal carotid artery and the jugular fossa (Fig. 2). In the process of growth of the inferior and anterior walls of the tympanic cavity, the lower edge of the annulus tympanicus goes even further away from the promontory, and the angle of inclination of the upper edge increases. As a result, the tympanic cavity from the almost horizontal position moves into inclined one. Tympanic openings are shifted to the top even more than at the previous period. The canal of the internal carotid artery passes at an angle of  $55^\circ$  to the base of the skull and lies on the inferior surface of the temporal bone, which during this period of the development is in the form of a triangular pyramid. The diameter of the canal of the internal carotid artery is  $2,56 \pm 0,04$  mm. The width of the jugular fossa -  $7,25 \pm 0,18$  mm, length -  $9,50 \pm 0,24$  mm (Figure 3). Dimensions of the tympanic cavity: length from below -  $7,60 \pm 0,19$  mm, length at the promontory level -  $9,75 \pm 0,18$  mm, length from above -  $7,40 \pm 0,23$  mm. Vertical dimensions of the tympanic cavity: in front -  $8,15 \pm 0,19$  mm, opposite the promontory -  $9,68 \pm 0,34$  mm, behind -  $7,15 \pm 0,17$  mm. The width of the tympanic cavity: in the inferior anterior portion -  $2,22 \pm 0,05$  mm, in the inferior posterior portion -  $5,22 \pm 0,12$  mm, in the anterior superior portion -  $3,85 \pm 0,15$  mm, in the posterior superior portion -  $4,82 \pm 0,19$  mm. The thickness of the walls of the tympanic cavity is: the superior -  $0,99 \pm 0,03$  mm, the superior -  $0,62 \pm 0,03$  mm, the inferior -  $0,72 \pm 0,02$  mm. The long diameter of the annulus tympanicus with tympanic membrane is  $8,12 \pm 0,19$  mm, the short diameter is  $7,25 \pm 0,23$  mm.

**Discussion.** During this period the formation of

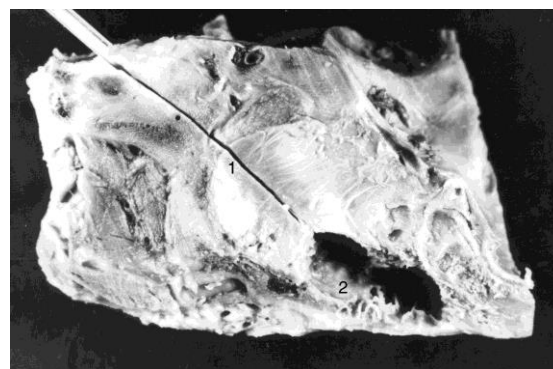


Fig. 1. Horizontal section of the temporal bone of the fetus 344.0 mm PCL. Macropreparation. Increase  $3,2^x$ : 1 - auditory tube, 2 - tympanic cavity

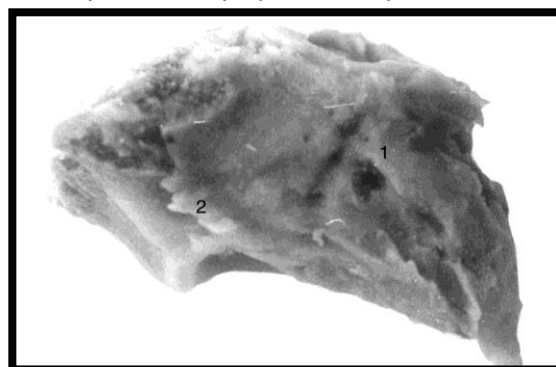


Fig. 2. The temporal bone of the fetus is 336.0 mm PCL (bottom view). Macropreparation. Increase  $3,2^x$ : 1 - internal carotid artery canal, 2 - jugular fossa.

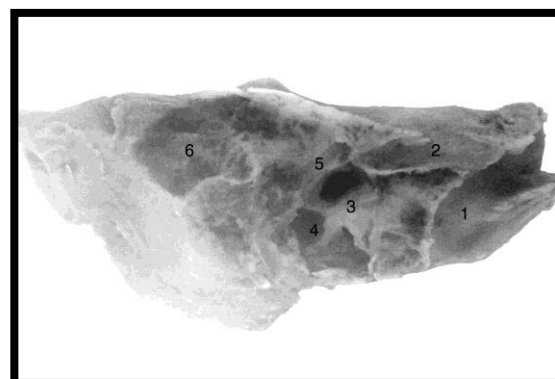


Fig. 3. The sagittal section of the temporal bone of the fetus is 340.0 mm PCL. Macropreparation. Increase  $3,2^x$ : 1 - internal carotid artery canal, 2 - auditory tube, 3 - oval window, 4 - round window, 5 - facial nerve canal, 6 - antrum.

the inferior and anterior wall of the tympanic cavity continues. The internal carotid artery and jugular bulb participate in this process. Tympanic holes of the auditory tube continue to move from the bottom upwards tympanic cavity to the upwards.

**Conclusions.** 1. The inferior and anterior walls of the tympanic cavity, epitympanum continue to form from the fetuses of this age.

2. The tympanic openings of the auditory tubes begin to move from the inferior part of the

tympanum to the upwards.

3. The identified features are important in improving the technology and the adequacy of surgical treatment and manipulations in premature babies.

#### References:

1. Богомилский МР, Рахманова ИВ, Матроскин АГ, Морозов СЛ, Шабельникова ЕИ. Профилактика инвалидизации недоношенных детей в оториноларингологии. Российский вестник перинатологии и педиатрии. 2016;61(5):30-3. DOI:10.21508/1027-4065-2016-61-5-30-33
2. Lineva O. I., Katasonova O. I., Katasonova Z. A. Risk factors for miscarriage in the industrialized city. *Izvestija Samarskogo nauchnogo centra Rossijskoj akademii nauk*. 2009;11(5):887-90.
3. Molokanova NP, Gavrikov LK. The use of parenteral nutrition in children neonodents. *Vopr sovremen pediatr*. 2015;14(2):207-11.
4. Rush VV, Rakhmanova IV, Bogomil'skij MR, Volodin NN. Posttraumatic damages of nasal soft tissues under CPAP and methods of their prevention. *J Mat - Fet Neonat Med*. 2010;23(1):607.
5. Rash VV, Volodin NN, Bogomil'skij MR. Prevention of jatrogenic damage binazalnaya cannulas nasal soft tissue on background of respiratory support CPAP. *Vopr ginekol, akush i perinatol* 2011;10(3):38-43.
6. Rahmanova IV, Zinker GM, Matroskin AG. Pathology of the middle ear in premature infants of different gestational-age-TA. *Vestnik RGMU* 2015;(1):21-5.