



# ЗДОРОВ'Я

# СУСПІЛЬСТВА

ЗДОРОВЬЕ ОБЩЕСТВА  
*The HEALTH of SOCIETY*

№1-2  
2016

UDC 616.31-002.828-036.11-036.87-092.6/.9

ACUTE AND RECURRENT ORAL CANDIDIASIS UNDER EXPERIMENTAL  
CONDITIONS: CHARACTERISTICS OF ITS PATHOGENESIS

G. Beketova<sup>1</sup>, MD, PhD, Professor

N. Savychuk<sup>1</sup>, MD, PhD, Professor

A. Savychuk<sup>2</sup>, MD, PhD, Professor

<sup>1</sup>Shupyk National Medical Academy of Postgraduate Education (Kyiv, Ukraine)

<sup>2</sup>Bogomolets National Medical University (Kyiv, Ukraine)

**Summary.** An experimental model of chronic oral candidiasis, which adequately reproduces the recurrence of the disease and can be used to study the major pathogenic mechanisms of the disease and determine the effectiveness of antifungal drugs. Under the experimental conditions studied pathological changes that occur at different stages of infection in the mouth, the digestive system, liver, and spleen of experimental animals. The dynamics of the immune response during relapse of experimental oral candidiasis and stages of secondary immunodeficiency postinfection.

**Key words:** experimental model in laboratory animals, oral candidiasis, chronic candidiasis, pathological changes postinfection laboratory markers of immune deficiency.

**Резюме.** В статті представлені дані щодо розробленої експериментальної моделі гострого і рецидивуючого кандидозу порожнини рота, яка адекватно відтворює рецидив захворювання і може використовуватися для вивчення головних патогенетичних механізмів захворювання та визначення ефективності протигрибкових препаратів. В умовах експерименту вивчені патоморфологічні зміни, які виникають на різних етапах інфекційного процесу в порожнині рота, системі травлення, печінці і селезінці експериментальних тварин. Вивчена динаміка імунної відповіді під час рецидиву експериментального кандидозу порожнини рота та етапи формування вторинного постінфекційного імунодефіциту.

**Ключові слова:** експериментальна модель на лабораторних тваринах, кандидоз порожнини рота, рецидивуючий кандидоз, патоморфологічні зміни, лабораторні маркери постінфекційного імунодефіциту

**Резюме.** В статье представлены данные, касающиеся разработанной экспериментальной модели острого и рецидивирующего кандидоза полости рта, которая адекватно воспроизводит рецидив заболевания и может использоваться для изучения главных патогенетических механизмов заболевания и определения эффективности противогрибковых препаратов. В условиях эксперимента изучены патоморфологические изменения, которые возникают на различных этапах инфекционного процесса в полости рта, системе пищеварения, печени и селезенке экспериментальных животных. Изучена динамика иммунного ответа во время рецидива экспериментального кандидоза полости рта и этапы формирования вторичного постинфекционного иммунодефицита.

**Ключевые слова:** экспериментальная модель на лабораторных животных, кандидоз полости рта, рецидивирующий кандидоз, патоморфологические изменения, лабораторные маркеры постинфекционного иммунодефицита

Chronic lesions of oral mucosa are one of the topical problems of modern pediatric dentistry and gastroenterology due to its prevalence, severe clinical deployments and risks of recurrency. Traditionally, the most common agent of chronic lesions of oral mucosa is yeasts of genus *Candida*. The specific weight of candidial lesions of oral mucosa has increased significantly due to the augmentation of a number of severe and atypical clinical forms, which are resistant to traditional therapy, high risk of complications and infection generalization. The specified state of the problem is defined by total influence of several injurious factors as ecological, social and iatrogenic. The pathogenic speciality of candidiasis as a chronic infectious disease is desintegration of anti-infective resistance mechanisms. And this is the character of these disorders, which defines a disease clinical course and infection generalization risks in patients with local lesion forms (1-6).

Aim of the research is to study pathological characteristics of chronic oral candidiasis under conditions of adequate experimental modeling.

**Research materials and methods. Characteristics of experimental material and procedure of the experiment.**

The essence of the experimental research lied in: extrapolation criteria selection; object and experimental animals optimal sample size defining; development and simulation of acute oral candidiasis model on the experimental animals, its modification and elaboration of infection recurrence model; histomorphological and immunological research complex implementation about clinical observations recurrency dynamics, and investigation of ethiotropic (antifungal) drugs combination efficiency on oral candidiasis recurrency model.

The research was performed on 71 Wistar white rats of both sexes at 7-75 days of its life. During the infection and clinical manifestation period of acute candidiasis, test groups rats were in suckling age (7-21 days of life), which is extrapolated on a traditional infecting period by specified agents in humans (7).

First-stage objective of experimental research are:

Reproduction of acute candidiasis of oral mucosa on Wistar white rats;

Implementation of oral candidiasis recurrency model implementation;

Studying of disease morphogenesis and immunal response dynamics on experimental models, and determination of characteristics, inherent to this lesion form.

For candidiasis reproduction we used two-day-old strain culture of (BKПFY-1006/1869 *Candida albicans*), adapted for reproduction in rats' organism, which was obligingly provided by P.N. Kashkin Scientific Research Institute of Medical Mycology 10<sup>9</sup> (RAMS Scientific Research Laboratory of Fungal Morphology and Biology) (Saint Petersburg). Accumulation of *Candida* species yeasts biomass was implemented standardly by reseeding in Sabouraud agar with following formation of fungal cells suspension (volume 20 mcl, infecting dose  $3 \times 10^5 - 3 \times 10^7$  fungal blastospores to 1 rat) (8).

To choose experimental models, which would match the objectives of the research we have worked with it using 7-8-day-old Wistar rats weighing 10-12 g. Acute candidiasis of oral mucosa was reconstructed via two models (9, 10). Fungal cells suspension was administrated with a microdosator to the rats from the first group (volume 20 mcl, infecting dose  $3 \times 10^5 - 3 \times 10^7$  of fungal blastospores) 1 time a day during 3 days. The rats from the second group were placed into a bath filled with fungal suspension ( $10^5 - 10^6$  cells per 1 ml), where it swallowed the suspension spontaneously. When both of these models were simulated, on the second-third day of the infection, it was observed, that the rats had dyspepsia symptoms, eating habits changes, there were lesion elements on tongue and jaw, which might be described as candidial ones. The specified changes were expressed better in animals from the second group. On the 3-5th day after the infecting, all the rats from the second group and 1 from the first have died. Thus, the first variant of candidiasis of oral mucosa model appeared to be more applicable for utilization in the experiment. When using this model, it is accomplished the simulation of oral mucosa lesion in all the rats, and there is a low level of animal's death induced by generalized forms of candidiasis. The specified model was used in the experiment as a basic one.

Acute candidiasis of oral mucosa was simulated on 65 7-8-day-old Wistar white rats, weighing 9-10.5 g, (34 males, 31 females) by the procedure of V. L. Bykov (1987). During the first 3 days of the experiment, it was administrated to the animals per os via automatic dosator 20 mcl of *Candida* fungal suspension ( $3 \times 10^5 - 3 \times 10^7$  of blastospores). During the next 2-14 days after infecting, the clinical symptoms of acute candidiasis were observed as eating habits disorder, onset of white coatings and erosions on tongue and oral mucosa, and in some cases - occurrence of dyspepsia. Primary symptoms of acute candidiasis in most of the animals started to manifest on the third day after infecting. The specified period was considered as a disease inception (day 0). Through the simulation of acute oral candidiasis, 9 (13.8%) animals have been eliminated from the experiment because of a generalized form of disease. The clinical symptoms of acute candidiasis of oral mucosa under experimental conditions and the terms of basic model simulation were corresponding with authors' data (9, 10).

During the first 3 weeks of the experiment, the rats were in its nests together with females, and then it was seated into separate cages (4-6 animals in each). Cultural micological studies on the third day after infecting has appeared to be positive in all the animals of the specified group, while semination rates of oral mucosa by *Candida* species yeasts were high (4,51-0,10 lgCFU/ml). On the 7th and 21th days of the disease, infecting was micologically confirmed in 82.1% and 66.1% of the rats, which survived with sufficiently high semination by *Candida* species yeasts (2.00-0.21 lgCFU/ml; 2.50-0.14 lgCFU/ml), which is indicative of chronic candidiasis of oral mucosa. Selective virological observations of animals from the specified group (by 10) on 7 and 14 day of disease have appeared to be negative.

In 5 weeks after infecting, it was reconstructed a recurrency of chronic candidiasis via application of prostaglandin E2 (PGE2) in the form of gel Prostin E on the oral mucosa of 56 animals, which was implemented during 3 days under light ether narcosis. Use of PGE2 is conditioned by its characteristics as a tissue hormone — inflammatory mediator. PGE2 action mechanism is determinated by decreasing of cAMP level and inhibition of adenylate cyclase, which promote trombocytes agregation and its dense granules contents (serotonin etc.) releasing. Due to the action of released mediators, biochemical and morphological changes, which are specific for the inceptive stage of nonspecific inflammation, occur in tissues. We would note that under the influence of PGE2, the permeability of both keratinized and non-keratinized squamous epithelium is highly increased, that largely contributes to fungal cells adhesion and its invasion (11).

During the next 2 - 4 days, the clinical symptoms the recurrency of candidiasis of oral mucosa were manifested in 46 (82.1%) rats. In most of the animals from specified group, it was observed the clinical symptoms of oral candidiasis on the third day after the stimulation procedure, which is why the signified day was considered as a recurrency inception (day P0).

To confirm the ethiological role of *Candida* species yeasts, it was implemented the scrape from the surface of oral mucosa, with the following sowing of the material onto a selective medium, and the procedure of identification, using standard procedures (12). In all the animals with clinical symptoms of candidiasis recurrency, have appeared to be a high rate of *Candida* species yeasts semination (3.93-0.26 lgCFU/ml). The studying of the major clinical characteristics of candidial infection was implemented by observation of the experimental animals, using the recomendations of S. Dundarov et al. (1991) in our modification. And it were considered the intensity of the following clinical symptoms on a 4-point grading scale: general behavior (agility, static character, agressiveness); feeding behavior (frequency of manger and water-trough using, expression of feeding reflexes); nervous system lesions (sudden debilitation, lack of response to painful stimuli, head nutation, circular motions, hyperkinesia, convulsion, paresis); dyspepsia (diarrhoea, vomiting, gut bloating); eye lesions (conjunctivitis, keratitis, ptosis); nasal mucous membrane lesions (rhinitis, lesion elements); skin lesion (number of lesion components, its dynamics); fur condition (luster, density, presence of alopecia). The changes on oral mucosa was rated the intensity of infectious lesion (number of components, its localization, growth dynamics, duration of epithelization period), involvement of gingiva into the pathological process. With lack of changes, the symptom intensity was given 0 points, with insignificant changes - 1 point, with medium and significant intensity - 2 and 3 points respectively.

For objectivization and the ability to compare general appearance of infectious lesion on every step of the disease progress in all the animal groups, it was defined a pathology integral rate (ИПП) due to the procedure (13).

$$\text{ИПП} = a_1 \Sigma A + a_2 \Sigma B + a_3 \Sigma C + \dots + a_n \Sigma X,$$

where  $a$  — is a frequency of occurrence of every symptom,

$\Sigma$  — a sum of points of every symptom.

To study the characteristics of disease morphogenesis and the immunal response dynamics, the slaughter of the rats from experimental and control groups was implemented at the P0, 7, 14 and 21 day. The material for mycological, morphological and histochemical studies was withdrawn and investigated according to current requirements of the International Committee for Biomedical Research Involving Animals [Международного комитета по проведению медико-

биологических исследований с использованием животных] and the Order of MH USSR № 755 from 12.08.1977. "About the sanctions for further elaboration of organising forms of work involving experimental animals" [Приказом МЗ СССР № 755 от 12.08.1977г. "О мерах по дальнейшему совершенствованию организационных форм работы с использованием экспериментальных животных"]. Considering 24-hours fluctuation of lymphocytes cell populations and eventual biorhythmic dependence of other indexes, the procedure of slaughter was implemented in the afternoon.

Condition of collagen and muscle fiber was rated by Van-Gieson stain. Brachet's method was used to educe cellular DNA and RNA. MSB method in D. D. Zerbino, L. L. Lukasevich modification (1984) was used to indicate fibrin with diverse rate of polymerization and cellular components of blood in the sections (14). Metachromasia reaction with alcian blue at pH = 2.6 in addition to PAS-reaction was used to indicate mast cells.

Immunological researches under experimental conditions were implemented by traditional procedures, adapted to rats (determination of total white blood cells, T- and B-white cells). Condition of oxygen-dependent metabolism of neutrophil granulocytes was rated by NST-test, counting the percentage of active cells and cytochemical index (15). Spontaneous (SLMC) and antibody-dependent lymphocyte mediated cytotoxicity (ADLMC) was determined by procedure (16). Total amount of IFNs was determined by traditional procedures (15).

**Clinical pathogenic characteristics of experimental oral candidiasis.**

In all the animals, infected by Candida species yeasts, on the 2-3 day after the administration of infecting agent (disease inception - day 0) appeared clinical symptoms of acute oral candidiasis – lesion of general (1,52-0,07 points) and feeding (1,43-0,07 points) behaviour, dyspepsia (1.58-0.10 points), hyperemia of oral mucosa with the onset of white coatings and erosions on tongue (93.8%), jaws mucosa (32.3%), palate (18.5%).

During the next 3 days, condition of 56 (86.2%) animals from the specified group has gradually become to stabilize: the symptoms intensity of lesion of general (1.37-0.07 points, 0.05) and feeding (1.24-0.05 points, 0.03) behaviour, dyspepsia (1.21-0.08 points, p-0.01) reduced. Clinical symptoms of oral mucosa lesion remained unchanged, however the symptoms of gingivitis have become more intense (1.38-0.07 points, 0.01).

In 9 (13.8%) animals during the first 3-7 days of acute experimental oral candidiasis, it were progressing the symptoms of infection generalization (lesions of general and feeding (2.96-0.21 points) behaviour, dyspepsia (2.84-0.19 points), resulted in the death of animals and its elimination from the experiment.

On the 7th day after the inception of oral candidiasis clinical symptoms, general condition of 56 (86.2%) survived animals continued to improve. In 38 (67.9%) animals from the signified group, lesion symptoms of oral mucosa have disappeared or were minimal, and in 10 (17.9%) - there were manifestations of candidal glossitis and gingivitis. And only in 8 (14.3%) animals, there were no clinical symptoms dynamics observed. Lesion components, specific for oral candidiasis, in rats from specified group, were epithelialized on the average 7.64-0.14 day, and a recovery from clinical symptoms happened on 10.3-0.20 day (fig. 1).

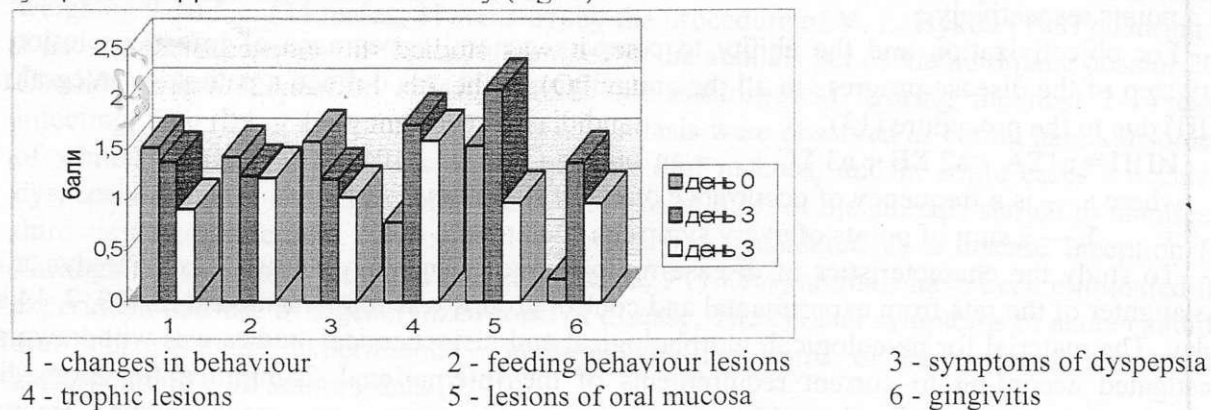
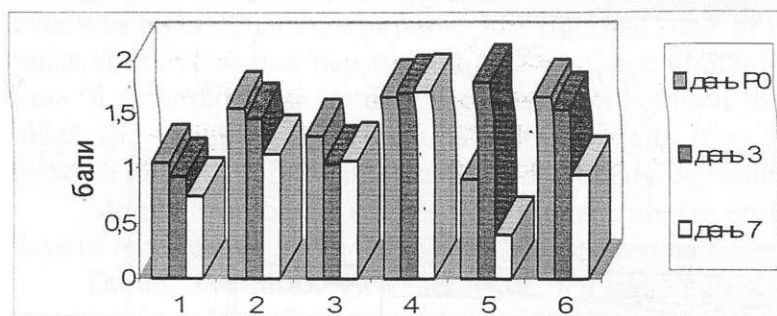


Fig. 1. The intensity of the clinical symptoms of acute oral candidiasis under experimental conditions

In 56 animals, which survived after the acute form of oral candidiasis, it was observed a significant reduction in body weight from the animal control group (11.5-0.2 g compared to 15.7-0.3 g, 0.01).

During the next 4 weeks, in 12 (21.4%) animals, it was determined hyperemia of gums and separate sections of oral mucosa with small erosions on an upper surface of tongue; in retromolar transitory folds sections, there was a white-grey coating. In 50.0% (28) of animals, the dyspepsia symptoms and flatulence persisted. Compared to the control group of healthy animals, the rats from the signified group looked cachectic; its fur lost the luster and thinned out (1.75-0.07 points).

In 5 weeks after the experiment start, it was stimulated a recurrency of candidiasis by lubrication of rats' oral mucosa with PGE2 in the form of gel Prostin E under light ether narcosis during 3 days. In 46 (82.1%) animals on the 2-3 day after the stimulation (inception of the recurrency - day P0) the symptoms of oral candidiasis became more intense. In diverse sections of oral mucosa (tongue, hard palate, in retromolar sections, on gums) originated the hyperemia nidi, erosions with the ragged edges, covered with white coating. More often, the clinical symptoms of candidiasis were observed on an upper surface of tongue (80.4%). In 19.6% of the cases, into the pathological process were involved several sections of oral mucosa. Condition of the animals at the inception of oral candidiasis recurrency is defined by lesions of general (1.05-0.03 point) and feeding (1.55-0.07 points) behavior, occurrence of dyspepsia (1.29-0.08 points) (fig. 2).



1 - changes in behaviour                      2 - feeding behaviour lesions                      3 - symptoms of dyspepsia  
4 - trophic lesions                              5 - lesions of oral mucosa                      6 - gingivitis

Fig. 1. The intensity of the clinical symptoms of oral candidiasis recurrency under experimental conditions

7 days after the recurrency inception, general (0.75-0.06 points, 0.001) and feeding (1.13-0.04 points; 0.001) behaviour of animals improved, expression of dyspepsia decreased (1.07-0.07 points; 0.01). Positive dynamics in clinical appearance of oral mucosa lesions was observed in 69.6% of animals. Average duration of components epithelization was 7.11-0.20 days, and a complete clinical recovery occurred on the 9.86-0.20 day (see fig.1). In 30.4% of rats from the specified group, it was observed no positive dynamics in local disease symptoms, it were persisted the occurrences of general intoxication and dyspepsia (2.31-0.21 points).


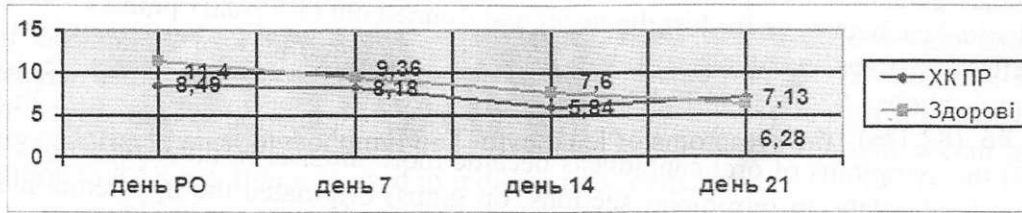
During the period of recurrency, the rats gained weight poorly (68.1-1.3 g compared to 72.4-1.2 g in the control group, 0.03). The symptoms of trophic disorders in the forms of general or local (in the rear end of the body) fur alopecia occurred in 48.2% of animals (1.71-0.08 points).

To define the character of immune response, it was studied the indexes of specific and nonspecific immunity at the recurrency inception (day P0), in the 7th, 14th and 21th day. (Fig. 3).

Clinical appearance of experimental oral candidiasis recurrency (day P0) ran its course against the background of leukocyto- и lymphocytopenia ( $11.5-0.3E10^9/l$   $8.49-0.54E10^9/l$ ,  $p-0.001$ ) and decrease of specific weight of  $\gamma$ - cells ( $3.74-0.26E10^9/l$ ,  $p-0.01$ ). Activity of oxygen-dependent mechanisms of phagocytosis, antibody-dependent cell-mediated cytotoxicity, and amount of INFs in blood serum were higher than those in the control group of noninfected animals ( $p-0.05$   $0.001$ ). The study of correlational relationships between the immunal response indexes at the recurrency inception of experimental oral candidiasis allowed to ascertain the dependance between the cells immunity indexes ( $r = [0.63 - 0.95]$ ). Equivalent type of correlation in the specified period of the disease is between neutrophilic leukocytes phagocytosis index and cytotoxic activity of lymphocytes ( $r = [0.68 - 0.89]$ ).

On the 7th day of the recurrency above mentioned changes persisted, and the indexes of credibly decreased ( $25.9 \pm 1.54\%$ ,  $p < 0.01$ ). In the cell link of the immunal response was stored the symptoms of integration against the background of the appearance of invert correlation between T-lymphocytes level and phagocytosis indexes ( $r = [(-0.77)-(-0.89)]$ ), and killer activity of lymphocytes ( $r = [(-0.87)-(-0.89)]$ ).

aCL ( $\times 10^9/l$ )



- lymphocytes ( $\times 10^9/l$ )  
B-lymphocytes ( $\times 10^9/l$ )

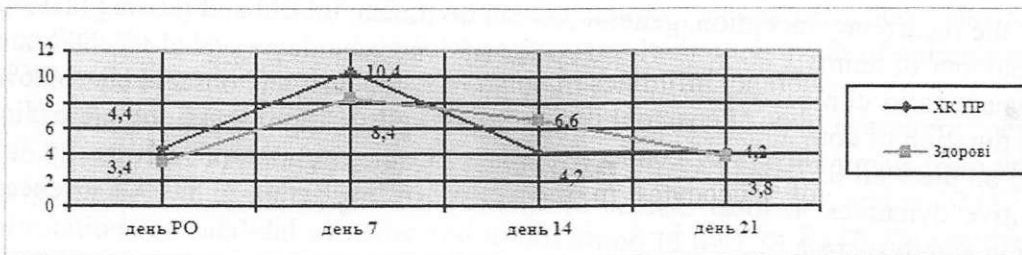
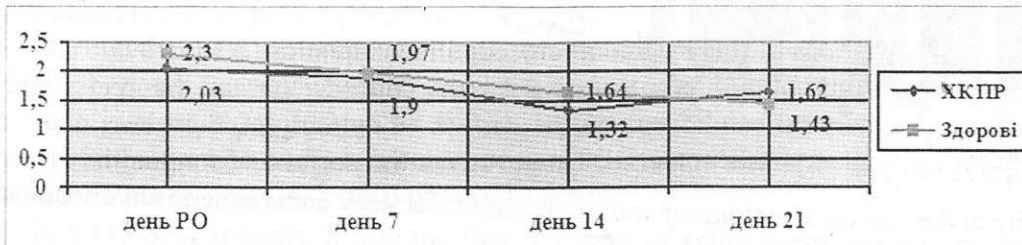
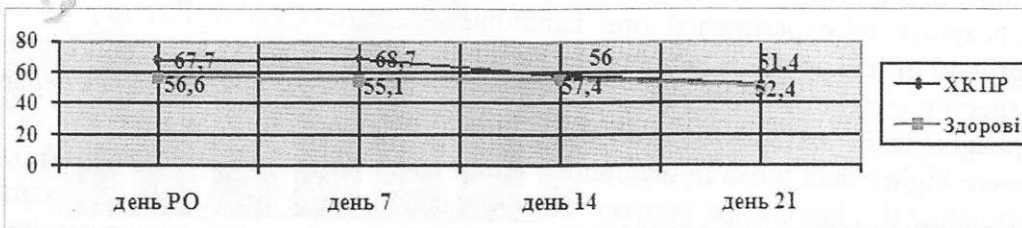



Fig. 3. Dynamics of cell-mediated and humoral immunity indexes and interferonogenesis during the recurrency of experimental oral candidiasis

NST-test (%)  
Cytochemical index



(%)



(%)

On the 14 day of the disease, the symptoms of leukocyto- and lymphocytopenia persisted; the phagocytosis indexes, the killer activity of lymphocytes and value of INFs in blood serum stabilized and reached the age norm. The specified period of the disease passed against the background of disbalance of all the immunity links. However, the inverse correlational relationships between the value of T-lymphocytes and antibody-dependent lymphocyte-mediated cytotoxicity persisted ( $r = [(-0.80)]$ ).

In 21 days after the recurrency inception of an experimental oral candidiasis the value of T-lymphocytes normalized ( $1.91-0.14E10^9/l$ ), and the B-lymphocytes level ( $1.62-0.07E10^9/l$ ,  $p=0.04$ ) even was higher than the age norm. The signified stage of immunal response was characterized by a renewal of correlation between the cell-mediated immunity indexes ( $r = [0.66-0.81]$ ). In the same time, it occurred close unidirectional relation between the value of B-lymphocytes, cytochemical index and spontaneous cell-mediated cytotoxicity ( $r = [0.71-0.97]$ ), and differently directed — between the value of B-lymphocytes and antibody-dependent cytotoxicity ( $r = [-0.70]$ ).

Morphohistological studies were implemented in observation dynamics (days P0, 7, 14 and 21 days of recurrency), using the methods of macro- and microscopic visualization.

During the histological study of animals' organs, it was educed, that at the recurrency inception (day P0) of experimental oral candidiasis on the surface of epithelium, there was not yet observed the significant bunching of yeasts' material. However, on the surface of tongue the zones of submersible growth of the basal layers of epithelium occur, in which the yeasts' components is differentiated. Compared to healthy animals, the epithelialic layer was refined, with a reduction of keratin coatings. In tongue and jaw tissues were noted dystrophy manifestations, lamination of superlayer of epithelium, hyperemia of submucous layer vessels, and medium leucocyte infiltration of lamina propria of the mucous membrane. Infiltrates mainly consisted of lymphoid and histiocytic row components, with increased number of eosinophiles and mast cells. In some sections, specified changes proliferated on submucous layers of connective tissue. In the sections of salivary gland, there were manifested bunchings of leucocytes in the forms of infiltrates and PAS-positive components. In one animal, in the section of tongue root, it was detected necrosis nidus with single dystrophic yeastlike cells, which was on the stage of calcification.

In stomach and gut, there was observed productive inflammation with leucocytic infiltration of submucous layer. The infiltrates occupied significant areas, and sometimes proliferated on a basal segment of mucous membrane. Infiltrates were composed of many young components of lymphoid row, eosinophiles. However, described changes were more expressed in stomach and less — in gut. At the same time, the components of Candida species yeasts weren't detected.

Morphological characteristics of submandibular lymph nodes, adrenal gland, liver and spleen didn't differ from healthy animals of the same age.

On the 7th day of recurrency, changes in microstructure of observable organs became more expressed. The surface of tongue on a significant area is covered with PAS-positive coating, consisting of desquamated laminae of keratin, DPC (from single ones to colonies), small groups of red and white blood cells (fig. 4). Frequently among these components occurred bunching of cocci.






Fig. 4. PAS-positive coating on tongue papillae with elements of *Candida* species yeasts. Edema of submucous layer. Recurrency of an experimental oral candidiasis. PAS-reaction. O6. 10, ok. 10

Elements of yeasts and microflora manifested directly on tongue papillae, against the background of the lysis symptoms of keratin and squamous layer of epithelium (fig. 5). When yeasts penetrate the deeper layers of epithelium, ulcer-like destructions down to submucous layer occur (fig. 6). In the sections of mucous membrane defects in submucous layer, there takes place dense lympho-histiocytic infiltration, which in some places proliferates on muscle tissues. Among the infiltrate cells, the shadows of necrotized dynamic proprioceptive correction are indicated, as well as double refracting fragments of chlamidospores and yeasts cells.

In most of animals, on the 7th day of recurrency, there are indicated expressed local lesions of tongue root on the border with larynx, appearing in the same place as previous granulomatous changes. In some cases, it is a centre of muscle tissue necrosis in the area of a large candidal colony, which consists of a big number of DPC, chlamidospores, pseudomycelium fragments.

In most of animals, on the 7th day of recurrency, there are indicated expressed local lesions of tongue root on the border with larynx, appearing in the same place as previous granulomatous changes. In some cases, it is a centre of muscle tissue necrosis in the area of a large candidal colony, which consists of a big number of DPC, chlamidospores, pseudomycelium fragments.

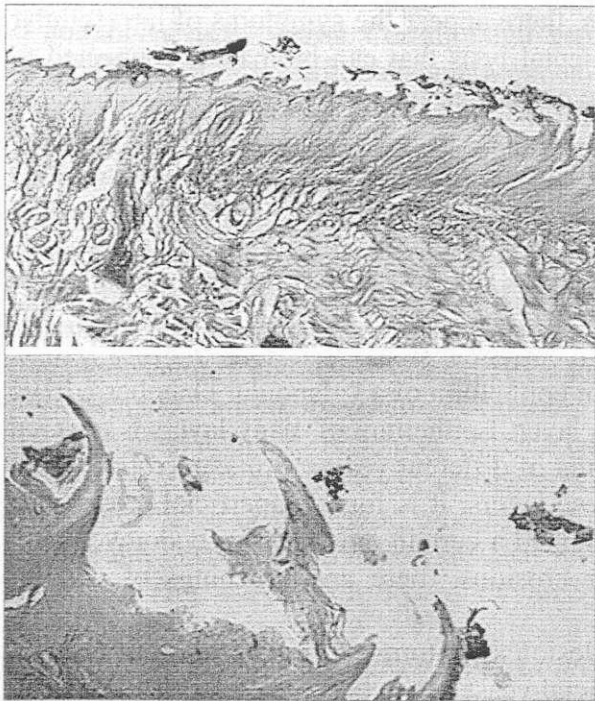


Fig. 5. Desquamation of tongue papillae. PAS-positive coating contains *Candida* species yeasts and keratin laminae. Recurrency of experimental oral candida-herpetic infection. PAS-reaction: a) O6.10, ok. 10; б) O6.10, ok. 20.




Fig. 6. Invasion of *Candida* species yeasts into epithelium of tongue mucous membrane. Recurrency of chronic oral candidiasis. PAS-reaction. O6.10, ok. 40.

It is in free state and inside of the destructed macrophages. In one of the animals, in the same area, there were found calcinates with conidia and DPC. In the contiguous to the calcinate muscle layer, there are fibrous scar and vessel plethora. In the larynx cartilage tissues, there are symptoms of destruction due to a candidal invasion. In submucous and muscle layers of tongue, there is noted a significant diffusive interstitial edema. Veins look plethoric, with occurrence of thrombosis and white cells marginal straddling. In wide ranges, microhematomae, perivascular and pericapillar lympho-histiocytic infiltration occur. Many of arteries have hypertrophied media with intensified collagen component and corrugated interior lissom membrane.

Presence of a significant number of mast cells in perivascular spaces, which are on the different stages of degranulation, engages attention. As you know, substances, which are secreted by mastocytes, appear to be proinflammatory factors and mediators of allergic inflammation, which influence the tone and permeability of the walls of blood microvessels. That's why, tissue infiltration by lymphocytes, eosinophiles and mast cells with the symptoms of its degranulation against the background of vascularization disorder, may point at the formation of inflammation with the allergic component.

Against the background of discirculatory changes, there appear the symptoms of intracellular edema and muscle fibers dystrophy down to the segmental lysis that can be mainly connected to tissue hypoxia. Direct candidal lesions of myocytes are confirmed by a presence of intracellularly-situated yeasts.

In the jaw structure in the animals from this group, there are no large abscesses and calcifications. Morphological changes are characterized by the appearance of small scars in a muscle tissue and in the place of gland location. As for the rest, changes in jaw and tongue tissues are analogous (fig. 7). All the above described manifestations are the result of the direct local effect on tissues of actively vegetating *Candida* species yeasts.

On the 7th day of experimental oral candidiasis recurrency, stomach lesions are localized in the area of fold, which delimitates two chambers, and in epithelium of a "glandular chamber". ДПК is localized in stratified flat epithelium and submucous layer. Epithelium of many layers is covered by PAS-positive material, containing a significant amount of different yeasts forms, necrotized cells of covering epithelium, solitary white cells. Under these layers, it is found superficial erosions in mucous membrane, on the bottom of which it is determined a certain amount of pseudomycelium. In an interstitial tissue, on the level of holes under erosions, there are bunchings of double-refracting material of dead yeasts.

Deep layers of gastric epithelium don't have the lesion symptoms. Lamina propria of mucous membrane and submucous layer in the zones of superficial yeast vegetation are plethoric, dropsical, infiltrated by lymphocytes and the components of monocytic row with the impurities of eosinophiles. In muscle and serous gastric membranes, DPC occurs.



Fig. 7. Superficial erosion on jaw mucous membrane with infiltration of submucous layer. Recurrency of experimental oral candida-herpetic infection. Hematoxylin-eosin. O6.10, ok. 10.

Morphological changes in the gut are notable for larger prevalence of erosions, intensity of diffusive leukocytic infiltration of lamina propria and muscularis of mucous membrane and its significant edema, and a detachment of serous membrane from the muscle one. At the same time, in the lumen of the intestine, in a mass of nutritious detritus, there appear not only the vegetating forms of yeasts, but also the significant colonies of microorganisms.

In one of the animals from the specified group, on the 7th day of experimental oral candidiasis recurrency, there were expressed the symptoms of candida sepsis with maximal manifestations in liver tissues. Most of the hepatocytes were on the stages of necrobiosis and necrosis. In the lumen of the vessels, there frequently occurred the thrombs, containing a big amount of different forms of DPC. Candida invasion proliferated on the walls of the vessels, beyond it and occurred inside of the hepatic lobules. Despite a significant intensity of the alternative processes in liver tissues, reaction for it, as well as in other organs, consisted only in vessel hyperemia and edema with minimal or lack of cellular infiltration.

Spleen of the animals from this group was plethoric, with very small centres of proliferation or its absence, which confirms the thesis about the depression of central mechanisms of immunogenesis by yeasts. Certain number of yasts cells manifests in a connective tissue of salivary gland, thymus, submundibular lymph nodes, and separate components - in kidneys.

In 14 days after the recurrency inception of experimental oral candidiasis, in tongue preparations, there were clearly determined the tendency for smoothing of papillae and its clarification from the PAS-positive layers. However, in some cells on a stratified flat keratinized epithelium of tongue, the active forms of yeasts continue to vegetate, causing the lysis of epitheliocytes. In tongue root, solitary deeper and older erosions occur with the symptoms of regeneration, in a form of growth of 1-2 layers of epitheliocytes on the defect edge. On the bottom of such erosions, it is differentiated a dystrophied, poorly coloured by PAS-reactive, pseudomycelium and DPC. Destructive changes of mucous membrane are accompanied by a significant inflammatory reaction of deeper layers of tongue in the form of increase in hyperemied microvessels number, bunching of cell components of lymphoid and monocytic rows with a fibroblasts impurity. Moreover, it is noted a vasodilatation of microcapillars, which is indicative of the proliferation of resorption processes of a necrotic mass from the destruction nidi. Bunching of yeasts and destructive changes are also found in some of the salivary glands (fig. 8) and larynx cartilages (fig. 9). It is followed by leucocytic infiltration with the symptoms of organization inception.

*All the described local changes in tongue tissues are more dropsical*, than on the 7th day of disease. The diffusive infiltration and the amount of mast cells, especially with the symptoms of degranulation, are decreasing. The veins remain plethoric; there occur a significant number of extended lymphatic vessels. Arteries and arterioles are notable for medias hypertrophy.

In some jaw preparates, there are registered the symptoms of proliferation of covering epithelium with its submersible growth into muscle tissue, with no changes in basal membrane integrity. The other symptoms of candidiasis on jaw are analogous to those on tongue.

In gastric tissues of all the animals, on the 14th day of the experimental oral candidiasis recurrency, there is indicated the destruction of superficial layer of epithelium. In desquamated layers of cells, there are a lot of pseudomycelium with conidia whorls, as well as a freely located ДПК, including the bud-forming ones. In the submucous layer, the symptoms of hyperemia and leucocytic infiltration against the background of excessive amount of eosinophiles, manifest. In some of the animals, the yeasts components are associated with a significant amount of cocci microflora colonies.

In small intestine, there are also notified the necrosis and superficial layers of epithelium (apical part of villi) desquamation symptoms, resulted by an active yeasts growth. In large intestine, the pseudomycelium and DPC components are more usually in the state of dystrophy, and are associated with the groups of E.coli. However, the symptoms of erosion regeneration become to manifest brightly.

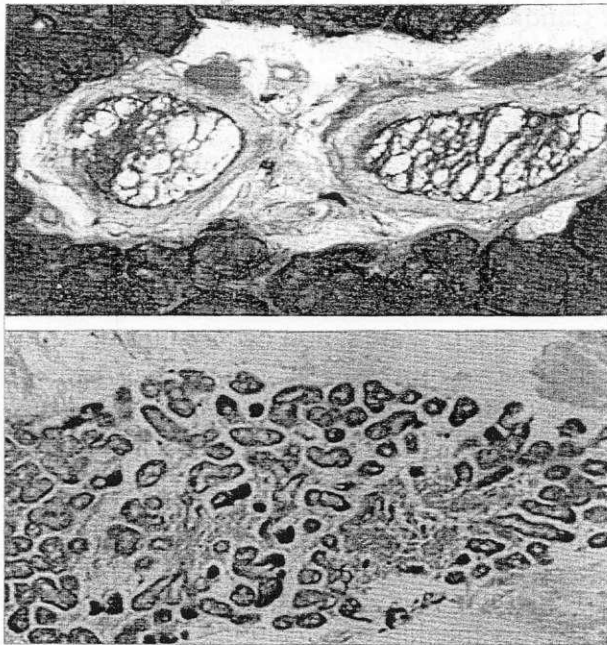


Fig. 8. Lesion of salivary gland by Candida species yeasts during the experimental oral candidiasis recurrency:

a) invasion of submandibular gland ducts. PAS-reaction. Oб. 10, ок.40;

б) destruction of salivary gland with leucocytic infiltration. Hematoxylin-eosin. Oб. 10, ок. 10.

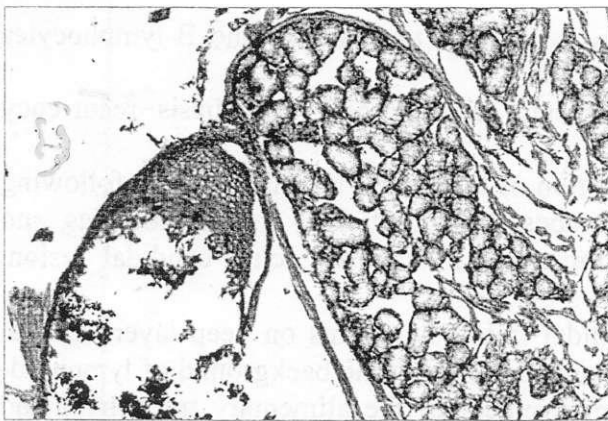


Fig. 9. Destruction of larynx cartilage, salivary gland lysis in experimental animals with the chronic oral candidiasis recurrency. Hematoxylin-eosin. Oб.10, ок. 10.

In liver, on the 14th day of the recurrency of experimental oral candidiasis, there are notified vein plethora, inconsiderable interstitial edema and abstinent fatty dystrophy of hepatocytes. Solitary components of yeasts appear under the capsule, especially in the sections of fatty dystrophy of hepatocytes. Somewhere in biliary ducts, mycelium is found.

The spleen, as well as on the 7th day of recurrency, is notable for a significant plethora of sinuses. Its follicles are relatively large, but with no proliferation centres. Around the follicles, it is localized the bunchings of macrophages, containing in its plasma PAS-positive detritus.

Thus, the experimental oral candidiasis recurrency begins from the activation of candida-infection cells, which are located in the sections of submersible growth of epithelium basal layer, and in granulemas. During the development of the pathological process, the destructive changes of different depth on oral mucosa surface occur, which are more expressed in the places of organized primary lesion components. Due to the infiltration by lymphocytes, eosinophiles and mast cells with high secretory activity on an early stage of the recurrency formation, the inflammation gains the allergic symptoms. Due to the development of the productive inflammation, the symptoms of a sustained circulation disorder occur, that leads to hypoxia. In the course of the recurrency, there are contact and lympho- and hematogenic proliferation of *Candida* species yeasts, with the formation of specific for candida-infection changes in other sections of the gut, liver, submandibular lymph nodes, thymus and spleen. The intensity of these changes may gain the symptoms of candida-sepsis. The direct alteration of immunocompetent organs against the background of intoxication, allergization and hypoxia cause the changes on a morphological level, which confirms a significant role of immunodeficiency in pathogenesis of the disease.

Thus, as the result of the experiment about the simulation of oral candidiasis recurrency on the experimental model, and the determination of immunal response and histomorphological dynamics, we can make the following conclusions.

1. The developed experimental model simulates the oral candidiasis recurrency adequately, and can be used for studying of the main pathogenic mechanisms of the disease and for determination of the efficiency of antifungal drugs.

2. Immunal response dynamics during the experimental oral candidiasis recurrency can be characterized in a following way:

at the recurrency inception (day P0), the deficiency of immunity cellular section (lymphocytopenia, decreasing of T-lymphocytes value) occurs, against the background of compensatory increase of lymphocyte-mediated cytotoxicity and the factors of non-specific immunity (phagocytosis, interferonogenesis);

during the next 7 days, there is no positive dynamics in immunal response, and antibody-dependent lymphocyte-mediated cytotoxicity decreases;

on the 14th day of the recurrency, the conditions of oxygen-dependent mechanisms of phagocytic activity of neutrophils, spontaneous and antibody-dependent lymphocyte-mediated cytotoxicity and interferon formation are restored;

on the 21th day of the recurrency, T-lymphocytes value is normalized, and B-lymphocytes value – exceeds the indexes of non-infected animals a little.

3. Morphohistological changes in the experimental chronic oral candidiasis recurrency manifest:

at the recurrency inception (day P0) – proliferation of the fungal infection in two following ways – due to the infiltration of epithelium of oral mucosa by superficially located colonies, and activation of deeply located nidi, which are immature, in case of acute candidal lesion, granulemas;

during the next 7 days, – proliferation of candidal lesion symptoms on deep layers of oral mucosa, destruction of the tissues in the places of granulemas against the background of lymphoid-macrophagal reaction, hypoxia, local hemostasis; involvement of the alimentary tract, liver and immune-endocrine system into the pathological process by lymphogenic and hematogenic dissemination of yeasts;

through 7-21 days of the recurrency – activation of regenerative processes in the sections of previous lesions, with formation of microabscesses in the zones of perivascular vegetation of yeasts colonies.

### References

1. Jarvis William R. Epidemiology of Nosocomial Fungal Infections, with Emphasis on Candida Species. //Clin. Infect. Dis. (1995) 20 (6):1526-1530.
2. Betts Robert F., Nucci Marcio, Talwar Deepak et all. A Multicenter, Double-Blind Trial of a High-Dose Caspofungin Treatment Regimen versus a Standard Caspofungin Treatment Regimen for Adult Patients with Invasive Candidiasis. //Clin. Infect. Dis. (2009) 48 (12):1676-1684.
3. Leroy Olivier, Gangneux Jean-Pierre, Montravers Philippe Epidemiology, management, and risk factors for death of invasive Candida infections in critical care: A multicenter, prospective, observational study in France (2005-2006). // Critical Care Medicine:May 2009 - Volume 37 - Issue 5 - pp 1612-1618.
4. Сергеев А.Ю., Сергеев Ю.В. Кандидоз. Природа инфекции, механизмы агрессии и защиты, лабораторная диагностика, клиника и лечение. / Ю.В. Сергеев, А.Ю. Сергеев. – М.: «ТриадаХ». – 2001. – 472 с.
5. Хмельницкий О.К., Шевяков М.А. О дифференциальной диагностике кандидоносительства и кандидоза кишечника. /М.А Шевяков, О.К. Хмельницкий // Проблемы медицинской микологии. – 1999. – №4. – С. 19–22.
6. Бекетова Г.В., Савичук Н.О. Кандидоз органов пищеварения у детей и подростков (клиническая лекция). // Мистецтво лікування.-2009.-№1 (57).-С.41-43.
7. Западнюк М.П., Западнюк В.И., Захарина Е.А. Лабораторные животные. Использование в эксперименте.-К.: Вища школа, 1983. – 878 с.
8. Лещенко В.М. Лабораторная диагностика грибковых заболеваний. – М.: Медицина. - 1982. – 142 с.
9. Быков В.Л. Экспериментальный кандидоз органов пищеварительного тракта новорожденных. // Архив патологии.-1987. - №4.- С. 45-49.
10. Быков В.Л. Экспериментально-гистологическое исследование кандидозного стоматита новорожденных. // Стоматология.-1987.- №6. -С. 45 -49.
11. Теппермен Дж., Теппермен Х. Физиология обмена веществ и эндокринной системы. – М.: Мир, 1989. – 656 с.
12. Murray P.R., Baron E.J., Tenover F.C. Manual of Clinical Microbiology.- Washington: ASM Press, 1995.- 1482 p.
13. Лукьянова Е.М., Макеев С.М. Современные методы медицинской информатики в педиатрической науке и практике // Педиатрия.- 1988. - №3. - С. 5 - 8.
14. Зербино Д.Д., Лукасевич Л.Л. Методы для определения возраста фибрина при синдроме диссеминированного внутрисосудистого свертывания. //Архив патологии.- 1984. - №8. – С. 72 – 75.
15. Фримель Х.Б.И. Основы иммунологии.- М.: Мир, 1986. – 254 с.
16. Чернушенко Е.Ф., Круглова И.Ф., Круглов Ю.В. Модификация метода определения цитотоксической активности киллерных клеток: Информационное письмо. - Киев, 1989.- 3 с.